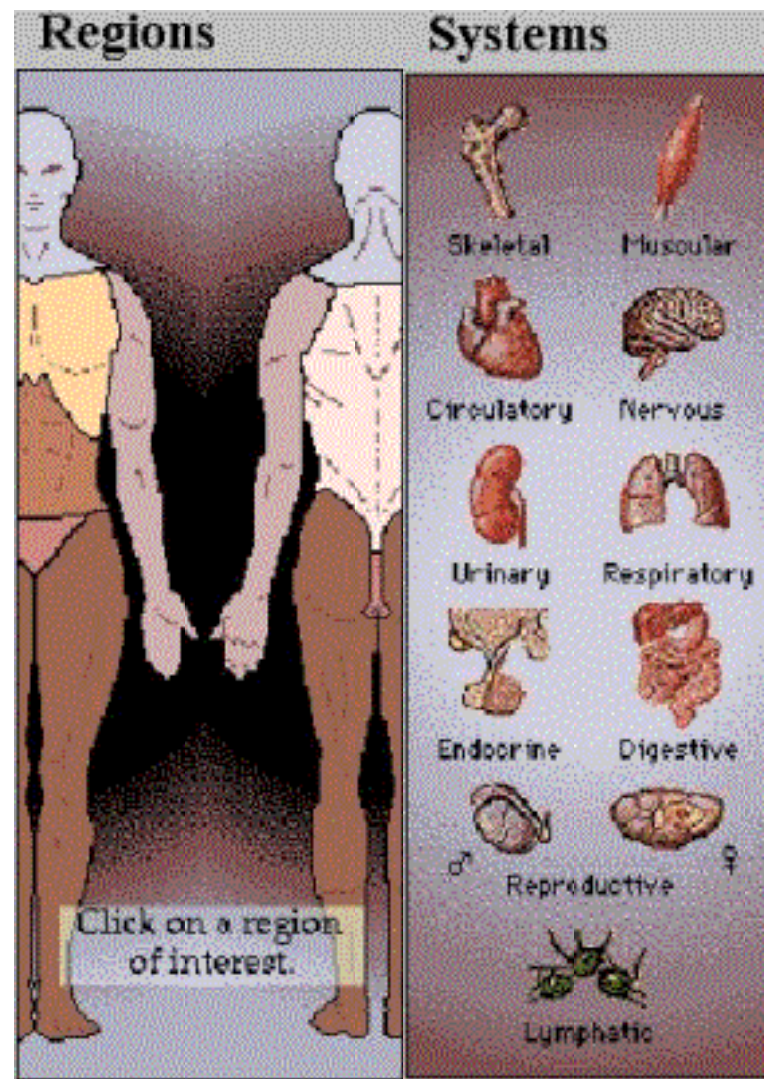


Netter for Isilo 3.0

Made by agoodbear(NDMC)

[Contents](#)



[Regions](#)

[Systems](#)

Region content

[\[Head and Neck \]](#),[\[Back and Spinal\]](#) , [\[Thorax\]](#) , [\[Abdomen\]](#) ,[\[Pelvis and Perinium\]](#) ,[\[Upper limb\]](#) ,[\[Lower limb\]](#)

Head and Neck [\[Back to system\]](#)

[Bones and Ligaments](#)
[Superficial face](#)
[Neck](#)
[Nasal region](#)
[Oral region](#)
[Pharynx](#)
[Thyroid gland and Larynx](#)
[Orbit and contents](#)
[Ear](#)
[Meninges and Brain](#)
[Cranial and cervical nerves](#)
[Cerebral vasculature](#)

Back and Spinal [\[Back to system\]](#)

[Bones and ligaments](#)
[Spinal cord](#)
[Muscles and nerves](#)

Thorax [\[Back to system\]](#)

[Mammary gland](#)
[Body wall](#)
[Lungs](#)
[Heart](#)
[Mediastinum](#)

Abdomen [\[Back to system\]](#)

[Body wall](#)
[Peritoneal cavity](#)
[Viscera\(Gut\)](#)
[Viscera\(accessory organs\)](#)
[Visceral vasculature](#)
[Innervation](#)
[Kidneys and suprarenal glands](#)

Pelvic and Pernium [\[Back to system\]](#)

[Bones and ligaments](#)
[Pelvic floor and contents](#)
[Female structures](#)
[Male structures](#)
[Rectum](#)
[Vasculature](#)
[Innervation](#)

Upper Limb [\[Back to system\]](#)

[Shoulder and axilla](#)
[Arm](#)
[Elbow and forearm](#)
[Wrist and hand](#)
[Neurovasculature](#)

Lower Limb [\[Back to system\]](#)

[Hip and thigh](#)
[Knee](#)
[Leg](#)
[Ankle and foot](#)
[Neurovasculature](#)

Bones and Ligaments [\[Back to system\]](#)

[1A Skull: Anterior View](#)
[1B Right Orbit: Frontal and Slightly Lateral View](#)
[2A Skull: Lateral View](#)
[2B Skull - Infratemporal Fossa Exposed: Lateral View](#)
[3A Skull: Midsagittal Section](#)
[3B Skull - Nasal Conchae Exposed: Sagittal Section](#)

[4A Calvaria: Superior View](#)
[4B Calvaria: Inferior View](#)
[5 Cranial Base: Inferior View](#)
[6 Bones of Cranial Base: Superior View](#)
[7 Foramina of Cranial Base: Superior View](#)
[8A Skull of Newborn: Lateral View](#)
[8B Skull of Newborn: Superior View](#)
[9A Bony Framework of Head and Neck: Lateral View](#)
[9B Bony Framework of Head - Mandible Removed: Lateral View](#)
[10A Mandible: Anterolateral Superior View](#)
[10B Mandible: Left Posterior View](#)
[11A Temporomandibular Joint: Lateral and Medial Views](#)
[11B Temporomandibular Joint: Joint Action](#)
[12A Cervical Vertebrae: Atlas and Axis](#)
[12B Cervical Vertebrae \[C1-C4\] Assembled: Posterosuperior View](#)
[13A Cervical Vertebrae \[C4 and C7\]: Superior Views](#)
[13B Cervical Vertebrae \[C2-T1\] Assembled: Right Lateral View](#)
[13C Cervical Vertebrae \[C3-C5\] Assembled: Anterior View](#)
[14A External Craniocervical Ligaments: Anterior and Posterior Views](#)
[14B External Craniocervical Ligaments: Right Lateral View](#)
[15A Internal Craniocervical Ligaments](#)
[15B Internal Craniocervical Ligaments \[Continued\]](#)
[16A Atlantooccipital Junction](#)
[16B Atlantooccipital Junction: McGregor's Line](#)
[16C Atlantooccipital Junction: Odontoid Abnormalities](#)

Superficial face

[\[Back to system\]](#)

[17A Superficial Arteries and Veins of Face and Scalp](#)
[17B Superficial Face: Sources of Arterial Supply](#)
[18A Cutaneous Nerves of Head and Neck](#)
[18B Dermatomes of Head and Neck](#)
[19A Facial Nerve Branches and Parotid Gland in Situ](#)
[19B Facial Nerve Branches and Parotid Gland: Sectioned](#)
[20A Muscles of Facial Expression: Anterior View](#)
[20B Superficial Face: Course of Wrinkle Lines of Skin](#)
[21 Muscles of Facial Expression: Lateral View](#)

Neck

[\[Back to system\]](#)

[22 Muscles of Neck: Lateral View](#)
[23 Muscles of Neck: Anterior View](#)
[24A Infrahyoid and Suprahyoid Muscles](#)
[24B Infrahyoid and Suprahyoid Muscles and their Action: Schema](#)
[25 Scalene and Prevertebral Muscles](#)
[26 Superficial Veins and Cutaneous Nerves of Neck](#)
[27A Cervical Plexus in Situ](#)
[27B Cervical Plexus: Schema](#)
[28A Subclavian Artery: Right Anterior Dissection](#)
[28B Subclavian Artery: Right Lateral Schematic View](#)
[29A Carotid Arteries - Parotid Fossa: Right Lateral Dissection](#)
[29B External Carotid Artery and Branches: Schema](#)
[30A Fascial Layers of Neck: Cross Section](#)
[30B Fascial Layers of Neck: Sagittal Section](#)

Nasal region

[\[Back to system\]](#)

[31A External Nose \[Skeleton\]: Anterolateral and Inferior Views](#)
[31B External Nose \[Skeleton\] in Situ: Lateral View](#)
[32A Lateral Nasal Wall](#)
[32B Nasal Cavity: Speculum View](#)
[32C Lateral Nasal Wall - Nasal Conchae Removed](#)
[33A Lateral Nasal Wall - Bony Structure](#)
[33B Lateral Nasal Wall - Bony Structure: Nasal Conchae Partly Removed](#)
[34A Medial Nasal Wall \[Septum\]](#)
[34B Medial Nasal Wall \[Septum\]: Bones and Cartilages](#)
[35A Maxillary Artery: Orbitomaxillary Distribution](#)
[35B Maxillary Artery: Nasopalatine Distribution](#)
[36 Arteries of Nasal Cavity: Schematic Hinge](#)
[37 Nerves of Nasal Cavity: Schematic Hinge](#)
[38A Nerves of Nasal Cavity: Distribution of Olfactory Mucosa](#)
[38B Nerves of Nasal Cavity: Lateral Nasal Wall](#)

[38C Nerves of Nasal Cavity: Nasal Septum](#)
[39 Autonomic Innervation of Nasal Cavity](#)
[40 Ophthalmic and Maxillary Nerves](#)
[41A Mandibular Nerve \[V3\]: Lateral View](#)
[41B Mandibular Nerve \[V3\]: Medial View](#)
[42A Paranasal Sinuses: Coronal Section](#)
[42B Paranasal Sinuses: Horizontal Section](#)
[43A Paranasal Sinuses: Sagittal Section](#)
[43B Paranasal Sinuses: Lateral Dissection](#)
[44A Paranasal Sinuses: At Birth](#)
[44B Paranasal Sinuses: Growth throughout Life](#)

Oral region

[\[Back to system\]](#)

[45A Inspection of Oral Cavity: Dorsum of Tongue and Palate](#)
[45B Inspection of Oral Cavity: Sublingual Region - Anterior Vestibule](#)
[45C Inspection of Oral Cavity: Lateral Oral Vestibule](#)
[46A Roof of Mouth - Hard and Soft Palates: Anterior View](#)
[46B Roof of Mouth - Soft Palate: Posterior View](#)
[47A Floor of Mouth - Musculature: Lateral Slightly Inferior View](#)
[47B Floor of Mouth - Musculature: Anteroinferior View](#)
[47C Floor of Mouth - Musculature: Posterosuperior View](#)
[48A Muscles Involved in Mastication: Lateral View](#)
[48B Muscles Involved in Mastication - Masseter Removed: Lateral View](#)
[49A Muscles Involved in Mastication \[Deep\]: Lateral View](#)
[49B Muscles Involved in Mastication \[Deep\]: Posterior View](#)
[50A Teeth - Deciduous and Permanent: Age of Eruptions](#)
[50B Teeth - Upper and Lower Permanent](#)
[51A Anatomy of a Tooth](#)
[51B Teeth - Left Upper and Left Lower Permanent: Labiobuccal View](#)
[52A Tongue: Dorsum](#)
[52B Tongue - Schematic Stereogram: Area Indicated on Plate 52A](#)
[53A Muscles of Tongue: Sagittal Section](#)
[53B Tongue and Related Structures: Sagittal Section](#)
[54A Tongue and Mouth: Horizontal Section - Superior View](#)
[54B Tongue and Mouth: Frontal Section - Anterior View](#)
[55A Salivary Glands: Dissection](#)
[55B Salivary Glands: Histology](#)
[56A Afferent Innervation of Mouth and Pharynx: Anterior View](#)
[56B Afferent Innervation of Mouth and Pharynx: Lateral View](#)
[56C Afferent Innervation of Mouth and Pharynx: Dorsum of Tongue](#)

Pharynx

[\[Back to system\]](#)

[57 Pharynx: Sagittal Section](#)
[58A Fauces: Medial Sagittal View](#)
[58B Fauces: Pharyngeal Mucosa Removed](#)
[59 Muscles of Pharynx: Sagittal Section](#)
[60 Pharynx: Opened Posterior View](#)
[61 Muscles of Pharynx: Partially Opened Posterior View](#)
[62 Muscles of Pharynx: Lateral View](#)
[63 Arteries of Oral and Pharyngeal Regions](#)
[64 Veins of Oral and Pharyngeal Regions](#)
[65 Nerves of Oral and Pharyngeal Regions](#)
[66 Lymph Vessels and Nodes of Oral and Pharyngeal Regions](#)
[67A Lymphatic Drainage of Pharynx: Posterior View](#)
[67B Lymphatic Drainage of Tongue: Lateral View](#)

Thyroid gland and Larynx

[\[Back to system\]](#)

[68A Thyroid Gland: Anterior View](#)
[68B Thyroid Gland in Situ: Anterior View](#)
[69 Thyroid Gland and Pharynx: Posterior View](#)
[70A Parathyroid Glands: Posterior View](#)

[70B Parathyroid Glands: Right Lateral View](#)
[71A Cartilages of Larynx: Anterior View](#)
[71B Cartilages of Larynx: Posterior View](#)
[71C Cartilages of Larynx: Anterosuperior View](#)
[71D Cartilages of Larynx: Right Lateral View](#)
[71E Cartilages of Larynx: Sagittal Section](#)
[72A Intrinsic Muscles of Larynx: Posterior View](#)
[72B Intrinsic Muscles of Larynx: Right Lateral View](#)
[72C Intrinsic Muscles of Larynx: Lateral Dissection](#)
[72D Intrinsic Muscles of Larynx: Superior View](#)
[73 Action of Intrinsic Muscles of Larynx](#)
[74A Nerves of Larynx: Right Lateral Views](#)
[74B Nerves of Larynx: Anterior View](#)
[75A Inspection of Larynx: Technique](#)
[75B Inspection of Larynx: Views during Inspiration and Phonation](#)

Orbit and contents

[\[Back](#)

[to system\]](#)

[76A Eyelids: Anterior View](#)
[76B Eyelids and Anterior Orbital Structures: Sagittal Section](#)
[76C Eyelids - Dissection: Anterior View](#)
[77A Lacrimal Apparatus in Situ](#)
[77B Lacrimal Apparatus: Dissection](#)
[78A Fascia of Orbit and Eyeball: Horizontal Section](#)
[78B Fascia of Orbit and Eyeball: Frontal Section and Entering Structures](#)
[79A Extrinsic Eye Muscles: Right Lateral View](#)
[79B Extrinsic Eye Muscles: Superior View](#)
[79C Extrinsic Eye Muscles - Innervation and Action: Anterior View of Left Eye](#)
[80A Arteries and Veins of Orbit and Eyelids: Superior View](#)
[80B Arteries and Veins of Orbit and Eyelids: Anterior View](#)
[80C Arteries and Veins of Orbit and Eyelids: Lateral View](#)
[81A Nerves of Orbit: Superior View](#)
[81B Nerves of Orbit - Muscles Partially Cut Away: Superior View](#)
[82 Eyeball: Cross Section](#)
[83 Anterior and Posterior Chambers of Eye](#)
[84A Anterior Chamber Angle of Eye](#)
[84B Anterior Chamber Angle of Eye: Gonioscopic Views](#)
[85A Lens and Supporting Structures: Section in Frontal Plane](#)
[85B Lens and Supporting Structures: Horizontal Section](#)
[85C Lens and Supporting Structures: Segment Outlined in Plate 85A](#)
[86A Intrinsic Arteries and Veins of Eye: Horizontal Section](#)
[86B Intrinsic Arteries and Veins of Eye: Ophthalmoscopic View](#)

Ear

[\[Back to system\]](#)

[87 Pathway of Sound Reception](#)
[88A External Ear: Right Auricle](#)
[88B External Ear: Right Tympanic Membrane](#)
[88C Tympanic Cavity: Viewed from External Acoustic Meatus](#)
[88D External Ear and Tympanic Cavity: Coronal Oblique Section](#)
[88E Tympanic Cavity: Auditory Ossicles](#)
[89A Tympanic Cavity - Lateral Wall: Medial View](#)
[89B Tympanic Cavity - Medial Wall: Lateral View](#)
[90A Right Osseous Labyrinth: Anterolateral View](#)
[90B Right Osseous Labyrinth - Dissected: Membranous Labyrinth Removed](#)
[90C Right Membranous Labyrinth with Nerves: Posteromedial View](#)
[91A Osseous and Membranous Labyrinths: Schema](#)
[91B Osseous and Membranous Labyrinths: Section Through Turn of Cochlea](#)
[92A Orientation of Labyrinth in Skull: Superior Projection](#)
[92B Orientation of Labyrinth in Skull: Lateral Projection](#)
[93A Cartilage of Auditory Tube at Base of Skull: Inferior View](#)
[93B Auditory Tube - Section through Cartilage: Tube Closed](#)
[93C Auditory Tube - Section through Cartilage: Tube Open](#)

Meninges and

Brain

[\[Back to system\]](#)

[94A Meninges and Diploic Veins: Coronal Dissection](#)
[94B Diploic and Emissary Veins of Skull](#)
[95A Meningeal Arteries](#)
[95B Meningeal Arteries \[Continued\]](#)
[96A Meninges and Superficial Cerebral Veins: Frontal Section](#)
[96B Meninges and Superficial Cerebral Veins: Dura Mater Lifted](#)
[97 Venous Sinuses of Dura Mater: Sagittal Section](#)
[98A Venous Sinuses of Dura Mater: Cranial Floor - Superior View](#)
[98B Cavernous Sinus: Coronal Section](#)
[99A Cerebrum: Lateral View](#)
[99B Cerebrum - Lobes: Lateral View](#)
[99C Cerebrum - Insula \[Island of Reil\]: Lateral View](#)
[100A Cerebrum - Brain in Situ: Sagittal Section - Medial View](#)
[100B Cerebrum - Hemisphere with Brainstem Excised: Medial View](#)
[101 Cerebrum: Inferior View](#)
[102A Ventricles of Brain: Left Lateral Phantom View](#)
[102B Ventricles of Brain: Coronal Section - Posterior View](#)
[103 Circulation of Cerebrospinal Fluid](#)
[104A Basal Ganglia: Horizontal Sections through Cerebrum](#)
[104B Basal Ganglia - Schema: Left Lateral View](#)
[105A Thalamus](#)
[105B Thalamus: Schematic Section](#)
[105C Thalamus: Schematic Representation of Thalamus](#)
[106A Hippocampus and Fornix: Superior Dissection](#)
[106B Hippocampus and Fornix: Schema of Fornix](#)
[106C Hippocampus and Fornix: Coronal Section - Posterior View](#)
[107A Cerebellum: Superior Surface](#)
[107B Cerebellum: Inferior Surface](#)
[107C Cerebellum: Section in Plane of Superior Cerebellar Peduncle](#)
[108A Brainstem: Posterolateral View](#)
[108B Brainstem: Anterioinferior View](#)
[109A Fourth Ventricle and Cerebellum: Posterior View](#)
[109B Fourth Ventricle and Cerebellum: Median Sagittal Section](#)

Cranial and cervical nerves

[\[Back to system\]](#)

[110 Cranial Nerve Nuclei in Brainstem: Schema - Posterior Phantom View](#)
[111 Cranial Nerve Nuclei in Brainstem: Schema - Medial Dissection](#)
[112 Cranial Nerves \[Motor and Sensory Distribution\]: Schema](#)
[113A Olfactory Nerve: Schema](#)
[113B Olfactory Nerve - Olfactory Bulb Cells: Schema](#)
[114A Optic Nerve \[Visual Pathway\]: Schema](#)
[114B Optic Nerve \[Visual Pathway\] - Structure of Retina: Schema](#)
[115 Oculomotor Trochlear and Abducens Nerves: Schema](#)
[116 Trigeminal Nerve: Schema](#)
[117 Facial Nerve: Schema](#)
[118 Vestibulocochlear Nerve: Schema](#)
[119 Glossopharyngeal Nerve: Schema](#)
[120 Vagus Nerve: Schema](#)
[121 Accessory Nerve: Schema](#)
[122 Hypoglossal Nerve: Schema](#)
[123 Cervical Plexus: Schema](#)
[124 Autonomic Nerves in Neck](#)
[125 Autonomic Nerves in Head](#)
[126 Ciliary Ganglion: Schema](#)
[127 Pterygopalatine and Submandibular Ganglia: Schema](#)
[128 Otic Ganglion: Schema](#)
[129 Taste Pathways: Schema](#)

Cerebral

vasculature

[\[Back to system\]](#)

[130 Arteries to Brain and Meninges](#)
[131 Arteries to Brain: Schema](#)
[132A Arteries of Brain: Inferior View](#)
[132B Arteries of Brain \[Continued\]: Inferior View](#)
[133A Circle of Willis - Vessels Dissected Out: Inferior View](#)
[133B Circle of Willis - Vessels in Situ: Inferior View](#)
[134A Arteries of Brain: Frontal View](#)
[134B Arteries of Brain: Frontal Section](#)
[135A Arteries of Brain: Lateral View](#)
[135B Arteries of Brain: Medial View](#)
[136 Arteries of Posterior Cranial Fossa](#)
[137 Veins of Posterior Cranial Fossa](#)
[138A Deep Veins of Brain - Dissection: Superior View](#)
[138B Deep Veins of Brain - Dissection: Inferior View](#)
[139 Subependymal Veins of Brain](#)
[140A Hypothalamus - Principal Nuclei](#)
[140B Adenohypophysis and Neurohypophysis](#)
[141 Arteries and Veins of Hypothalamus and Hypophysis](#)

Bones and ligaments

[\[Back to system\]](#)

[142 Vertebral Column](#)
[143A Thoracic Vertebrae \[T6\]: Superior View](#)
[143B Thoracic Vertebrae \[T6\]: Lateral View](#)
[143C Thoracic Vertebrae \[T12\]: Lateral View](#)
[143D Thoracic Vertebrae \[T7-T9\] - Assembled: Posterior View](#)
[144A Lumbar Vertebrae \[L2\]: Superior View](#)
[144B Lumbar Vertebrae: Intervertebral Disc](#)
[144C Lumbar Vertebrae \[L3-L4\] - Assembled: Posterior View](#)
[144D Lumbar Vertebrae \[L1-L5\] - Assembled: Left Lateral View](#)
[145A Sacrum and Coccyx: Pelvic Surface](#)
[145B Sacrum and Coccyx: Median Sagittal Section](#)
[145C Sacrum: Transverse Section through S1 Foramina](#)
[145D Sacrum and Coccyx: Dorsal Surface](#)
[146A Vertebral Ligaments of Lumbar Region: Left Lateral View - Partially Sectioned](#)
[146B Vertebral Ligaments of Lumbar Region: Anterior Vertebral Segments - Posterior View](#)
[146C Vertebral Ligaments of Lumbar Region: Posterior Vertebral Segments - Anterior View](#)
[147A Vertebral Ligaments of Lumbosacral Region: Left Lateral View](#)
[147B Vertebral Ligaments of Lumbosacral Region: Posterior View](#)

Spinal cord

[\[Back to system\]](#)

[148 Spinal Cord in Situ](#)
[149A Relation of Spinal Nerve Roots to Vertebrae](#)
[149B Relation of Spinal Nerve Roots to Vertebrae: Lateral Protrusion](#)
[149C Relation of Spinal Nerve Roots to Vertebrae: Medial Protrusion](#)
[150 Dermatomes](#)
[151A Spinal Cord Cross Sections](#)
[151B Spinal Cord Cross Sections: Fiber Tracts](#)
[152 Autonomic Nervous System: General Topography](#)
[153 Autonomic Nervous System: Schema](#)
[154 Cholinergic and Adrenergic Synapses: Schema](#)
[155A Spinal Membranes and Nerve Roots: Posterior View](#)
[155B Spinal Membranes and Nerve Roots: Anterior View](#)
[156A Spinal Nerve Origin: Section through Thoracic Vertebra](#)
[156B Spinal Nerve Origin: Section through Lumbar Vertebra](#)
[157 Arteries of Spinal Cord: Schema](#)
[158A Arteries of Spinal Cord - Intrinsic Distribution: Thoracic Section](#)
[158B Arteries of Spinal Cord - Intrinsic Distribution: Schema](#)
[159A Veins of Spinal Cord: Sagittal Section \[without Cord\]](#)
[159B Veins of Spinal Cord: Superior View \[without Cord\]](#)
[159C Veins of Spinal Cord: Superior View \[Magnified with Cord\]](#)

Muscles and nerves

[\[Back to system\]](#)

- [160 Muscles of Back: Superficial Layers](#)
- [161 Muscles of Back: Intermediate Layers](#)
- [162 Muscles of Back: Deep Layers](#)
- [163 Nerves of Back](#)
- [164 Suboccipital Triangle](#)
- [165 Lumbar Region of Back: Cross Section](#)
- [166 Typical Thoracic Spinal Nerve](#)

Mammary gland

[\[Back to system\]](#)

- [167A Mammary Gland: Anterolateral Dissection](#)
- [167B Mammary Gland: Sagittal Section](#)
- [168 Arteries of Mammary Gland](#)
- [169 Lymph Vessels and Nodes of Mammary Gland](#)

Body wall

[\[Back to system\]](#)

- [170A Bony Framework of Thorax: Anterior View](#)
- [170B Bony Framework of Thorax: Posterior View](#)
- [171A Left 1st and 2nd Ribs: Superior Views](#)
- [171B Sternocostal Articulations: Anterior View](#)
- [171C Middle Rib: Posterior View](#)
- [172A Costovertebral Joints: Left Lateral View](#)
- [172B Costovertebral Joints: Transverse Section - Superior View](#)
- [172C Costovertebral Joints: Right Posterolateral View](#)
- [173A Cervical Ribs and Related Anomalies 1](#)
- [173B Cervical Ribs and Related Anomalies 2](#)
- [173C Cervical Ribs and Related Anomalies 3](#)
- [174 Anterior Thoracic Wall](#)
- [175 Anterior Thoracic Wall \[Continued\]](#)
- [176 Anterior Thoracic Wall: Internal View](#)
- [177A Deep Posterior Thoracic Wall](#)
- [177B Lateral Thoracic Wall](#)
- [178 Posterior Thoracic Wall](#)
- [179 Intercostal Nerves and Arteries](#)
- [180 Diaphragm: Thoracic Surface](#)
- [181 Diaphragm: Abdominal Surface](#)
- [182A Phrenic Nerve in Situ](#)
- [182B Phrenic Nerve: Schema](#)
- [183 Muscles of Respiration](#)

Lungs

[\[Back to system\]](#)

- [184 Topography of Lungs: Anterior View](#)
- [185 Topography of Lungs: Posterior View](#)
- [186 Lungs in Situ: Anterior View](#)
- [187A Right Lung: Medial View](#)
- [187B Left Lung: Medial View](#)
- [188A Bronchopulmonary Segments: Anterior View](#)
- [188B Bronchopulmonary Segments: Posterior View](#)
- [189A Bronchopulmonary Segments: Lateral Views](#)
- [189B Bronchopulmonary Segments: Medial Views](#)
- [190A Trachea and Major Bronchi: Anterior View](#)
- [190B Trachea: Cross Section](#)

[191 Nomenclature of Bronchi: Schema](#)
[192 Intrapulmonary Airways: Schema](#)
[193 Intrapulmonary Blood Circulation: Schema](#)
[194 Pulmonary Arteries and Veins](#)
[195 Main Bronchi With Pulmonary Arteries and Veins in Situ](#)
[196A Bronchial Arteries](#)
[196B Bronchial Arteries: Variations](#)
[196C Bronchial Veins](#)
[197 Lymph Vessels and Nodes of Lung](#)
[198 Autonomic Nerves in Thorax](#)
[199 Innervation of Tracheobronchial Tree: Schema](#)

Heart

[\[Back to system\]](#)

[200 Heart in Situ](#)
[201 Heart: Anterior Exposure](#)
[202A Heart - Basal Surface: Posterior View](#)
[202B Heart - Diaphragmatic Surface: Posteroinferior View](#)
[203A Pericardial Sac - Heart Drawn Out: Left Lateral View](#)
[203B Pericardial Sac - Heart Removed: Anterior View](#)
[204A Coronary Arteries and Cardiac Veins: Sternocostal Surface](#)
[204B Coronary Arteries and Cardiac Veins: Diaphragmatic Surface](#)
[205A Coronary Arteries and Cardiac Veins: Variations 1](#)
[205B Coronary Arteries and Cardiac Veins: Variations 2](#)
[206A Right Coronary Artery: Arteriographic View 1](#)
[206B Right Coronary Artery: Arteriographic View 2](#)
[207A Left Coronary Artery: Arteriographic View 1](#)
[207B Left Coronary Artery: Arteriographic View 2](#)
[208A Opened Right Atrium: Right Lateral View](#)
[208B Opened Right Ventricle: Anterior View](#)
[209A Left Ventricle: Flap Opened in Posterolateral Wall](#)
[209B Left Atrium and Ventricle: Sectioned with Mitral Valve Cut Away](#)
[210A Valves of Heart in Diastole](#)
[210B Valves of Heart in Systole](#)
[211A Aortic Valve](#)
[211B Tricuspid \[Right Atrioventricular\] Valve](#)
[211C Mitral \[Left Atrioventricular\] Valve](#)
[212 Atria Ventricles and Interventricular Septum](#)
[213A Conduction System of Heart: Right Side](#)
[213B Conduction System of Heart: Left Side](#)
[214 Nerves of Heart](#)
[215 Innervation of Heart: Schema](#)
[216 Innervation of Blood Vessels: Schema](#)
[217A Prenatal Circulation](#)
[217B Postnatal Circulation](#)

Mediastinum

[\[Back to system\]](#)

[218 Mediastinum: Right Lateral View](#)
[219 Mediastinum: Left Lateral View](#)
[220 Esophagus in Situ](#)
[221A Topography and Constrictions of Esophagus: Schema - Anterior View](#)
[221B Topography and Constrictions of Esophagus: Lateral View](#)
[222A Musculature of Esophagus 1](#)
[222B Musculature of Esophagus 2](#)
[223 Pharyngoesophageal Junction](#)
[224A Esophagogastric Junction: Coronal Section](#)
[224B Esophagogastric Junction: Anterior View](#)
[225A Arteries of Esophagus](#)
[225B Arteries of Esophagus: Variations](#)
[226A Veins of Esophagus](#)
[226B Veins of Esophagus: Submucous Venous Plexus](#)
[227 Lymph Vessels and Nodes of Esophagus](#)
[228A Nerves of Esophagus: Anterior View](#)
[228B Nerves of Esophagus: Posterior View](#)
[229A Nerves of Esophagus: Variations](#)
[229B Intrinsic Nerves of Esophagus: Schema](#)
[230 Mediastinum: Cross Section](#)

Body wall

[\[Back to system\]](#)

[231 Bony Framework of Abdomen](#)

[232 Anterior Abdominal Wall: Superficial Dissection](#)
[233 Anterior Abdominal Wall: Intermediate Dissection](#)
[234 Anterior Abdominal Wall: Deep Dissection](#)
[235A Rectus Sheath: Cross Section Above Arcuate Line](#)
[235B Rectus Sheath: Cross Section Below Arcuate Line](#)
[236 Anterior Abdominal Wall: Internal View](#)
[237A Posterolateral Abdominal Wall](#)
[237B Posterolateral Abdominal Wall \[Continued\]](#)
[238 Arteries of Anterior Abdominal Wall](#)
[239 Veins of Anterior Abdominal Wall](#)
[240 Nerves of Anterior Abdominal Wall](#)
[241 Thoracoabdominal Nerves](#)
[242A Inguinal and Femoral Regions: Subcutaneous Fascia Removed](#)
[242B Inguinal and Femoral Regions: Cribriform Fascia Removed](#)
[243A Inguinal Region: Dissection - Anterior View](#)
[243B Inguinal Region: Dissection - Posterior \[Internal\] View](#)
[244A Femoral Sheath and Inguinal Canal](#)
[244B Femoral Sheath and Inguinal Canal \[Deep\]](#)
[245 Inguinal Canal and Spermatic Cord](#)
[246 Posterior Abdominal Wall: Internal View](#)
[247 Arteries of Posterior Abdominal Wall](#)
[248 Veins of Posterior Abdominal Wall](#)
[249 Lymph Vessels and Nodes of Posterior Abdominal Wall](#)
[250 Nerves of Posterior Abdominal Wall](#)

Peritoneal cavity

[\[Back to system\]](#)

[251A Quadrants of Abdomen](#)
[251B Regions and Planes of Abdomen](#)
[252A Greater Omentum and Abdominal Viscera](#)
[252B Greater Omentum and Abdominal Viscera: Omentum Raised](#)
[253A Mesenteric Relations of Intestines: Transverse Colon Elevated](#)
[253B Mesenteric Relations of Intestines: Suspensory Muscle of Duodenum](#)
[254A Mesenteric Relations of Intestines: Small Intestine Removed](#)
[254B Mesenteric Relations of Intestines: Sigmoid Colon Reflected](#)
[255 Omental Bursa: Stomach Reflected](#)
[256 Omental Bursa: Cross Section](#)
[257 Peritoneum of Posterior Abdominal Wall](#)

Viscera(Gut) [\[Back to system\]](#)

[258A Stomach in Situ](#)
[258B Stomach: Variations in Position and Contour](#)
[259A Mucosa of Stomach](#)
[259B Mucosa of Stomach: Histology](#)
[260A Musculature of Stomach](#)
[260B Musculature of Stomach \[Continued\]](#)
[261 Duodenum in Situ](#)
[262A Mucosa of Duodenum](#)
[262B Musculature of Duodenum: Layers of Wall](#)
[263A Mucosa and Musculature of Jejunum](#)
[263B Mucosa and Musculature of Ileum](#)
[264A Ileocecal Region](#)
[264B Ileocecal Region: Retrocecal Recess Exposed](#)
[264C Ileocecal Region: Variations in Posterior Peritoneal Attachment](#)
[265A Ileocecal Region: Labial Form of Ileocecal Sphincter](#)
[265B Ileocecal Region: Papillary Form of Ileocecal Sphincter](#)
[265C Ileocecal Region: Schema of Muscle Fibers at Ileocecal Sphincter](#)
[266A Vermiform Appendix: Variations in Position](#)
[266B Vermiform Appendix: Fixed Retrocecal](#)
[266C Vermiform Appendix: Cross Section](#)
[267 Mucosa and Musculature of Large Intestine](#)
[268A Sigmoid Colon: Variations in Position](#)
[268B Sigmoid Colon \[Continued\]: Variations in Position](#)

Viscera(accessory organs) [\[Back to system\]](#)

[269A Topography of Liver: Anterior and Posterior Views](#)
[269B Topography of Liver: Lateral View](#)
[270A Surfaces and Bed of Liver: Anterior View](#)
[270B Surfaces and Bed of Liver: Visceral Surface](#)
[270C Surfaces and Bed of Liver: Posterior View and Bed of Liver](#)
[271A Liver in Situ](#)
[271B Variations in Form of Liver](#)
[272A Liver Segments and Lobules: Parietal Surface](#)
[272B Liver Segments and Lobules: Visceral Surface](#)
[272C Distribution of Vessels and Ducts of Liver](#)
[273A Intrahepatic Vascular and Duct Systems: Schema](#)
[273B Normal Lobular Pattern of Liver](#)
[274 Liver Structure: Schema](#)
[275A Intrahepatic Biliary System: Schema](#)
[275B Intrahepatic Biliary System: Histology](#)
[276A Gallbladder and Extrahepatic Bile Ducts](#)
[276B Gallbladder and Extrahepatic Bile Ducts: Sectioned](#)
[277A Variations in Cystic Duct](#)

[277B Variations in Accessory \[Aberrant\] Hepatic Ducts](#)
[278A Choledochoduodenal Junction](#)
[278B Choledochoduodenal Junction: Dissection](#)
[278C Choledochoduodenal Junction: Reconstruction](#)
[278D Variations in Union of Bile and Pancreatic Ducts](#)
[279A Pancreas in Situ](#)
[279B Pancreas: Histology](#)
[279C Pancreas](#)
[280A Variations in Pancreatic Ducts](#)
[280B Variations in Pancreatic Ducts \[Continued\]](#)
[281A Spleen: Visceral and Diaphragmatic Surfaces](#)
[281B Spleen: Cross Section](#)
[281C Spleen in Situ](#)

Visceral vasculature

[\[Back to system\]](#)

[282 Arteries of Stomach Liver and Spleen](#)
[283 Arteries of Stomach Duodenum Pancreas and Spleen](#)
[284 Arteries of Liver Pancreas Duodenum and Spleen](#)
[285A Arteries of Duodenum and Head of Pancreas: Reflected to Left](#)
[285B Arteries of Duodenum and Head of Pancreas: Posterior View](#)
[286 Arteries of Small Intestine](#)
[287 Arteries of Large Intestine](#)
[288A Variations in Celiac Trunk](#)
[288B Variations in Celiac Trunk \[Continued\]](#)
[289A Variations in Hepatic Arteries](#)
[289B Variations in Hepatic Arteries \[Continued\]](#)
[290A Variations in Cystic Artery 1](#)
[290B Variations in Cystic Artery 2](#)
[290C Variations in Cystic Artery 3](#)
[290D Variations in Cystic Artery 4](#)
[290E Variations in Cystic Artery 5](#)
[291A Variations in Colic Arteries 1](#)
[291B Variations in Colic Arteries 2](#)
[291C Variations in Colic Arteries 3](#)
[291D Variations in Colic Arteries 4](#)
[291E Variations in Colic Arteries 5](#)
[291F Variations in Colic Arteries 6](#)
[292A Variations in Colic Arteries 7](#)
[292B Variations in Colic Arteries 8](#)
[292C Variations in Colic Arteries 9](#)
[292D Variations in Colic Arteries 10](#)
[292E Variations in Colic Arteries 11](#)
[292F Variations in Colic Arteries 12](#)
[293A Variations in Cecal and Appendicular Arteries 1](#)
[293B Variations in Cecal and Appendicular Arteries 2](#)
[293C Variations in Cecal and Appendicular Arteries 3](#)
[293D Variations in Cecal and Appendicular Arteries 4](#)
[293E Variations in Cecal and Appendicular Arteries 5](#)
[293F Variations in Cecal and Appendicular Arteries 6](#)
[293G Variations in Cecal and Appendicular Arteries 7](#)
[293H Variations in Cecal and Appendicular Arteries 8](#)
[293I Variations in Cecal and Appendicular Arteries 9](#)
[294A Veins of Stomach Duodenum and Pancreas](#)
[294B Veins of Stomach Duodenum and Pancreas \[Continued\]](#)
[295A Veins of Small Intestine: Transverse Colon Cut](#)
[295B Veins of Small Intestine: Transverse Colon Elevated](#)
[296 Veins of Small and Large Intestines](#)
[297 Portal Vein Tributaries: Portacaval Anastomoses](#)
[298A Typical Arrangement of Portal Vein](#)
[298B Variations of Portal Vein](#)
[298C Variations of Portal Vein \[Continued\]](#)
[298D Anomalies of Portal Vein](#)
[299A Lymph Vessels and Nodes of Stomach](#)
[299B Lymph Vessels and Nodes of Stomach: Stomach Reflected](#)
[300 Lymph Vessels and Nodes of Small Intestine](#)
[301A Lymph Vessels and Nodes of Large Intestine](#)
[301B Lymph Vessels and Nodes of Large Intestine \[Continued\]](#)
[302A Lymph Vessels and Nodes of Liver: Histology](#)
[302B Lymph Vessels and Nodes of Liver](#)
[303A Lymph Vessels and Nodes of Pancreas: Anterior View](#)
[303B Lymph Vessels and Nodes of Pancreas: Posterior View](#)

Innervation

[\[Back to system\]](#)

[304 Autonomic Nerves and Ganglia of Abdomen](#)
[305 Nerves of Stomach and Duodenum](#)
[306A Nerves of Stomach and Duodenum: View with Stomach Reflected](#)
[306B Nerves of Stomach and Duodenum: Hiatal Region](#)
[307 Innervation of Stomach and Duodenum: Schema](#)
[308 Nerves of Small Intestine](#)
[309 Nerves of Large Intestine](#)
[310A Innervation of Small and Large Intestines: Left Side of Schema](#)
[310B Innervation of Small and Large Intestines: Right Side of Schema](#)
[311 Autonomic Reflex Pathways: Schema](#)
[312 Intrinsic Autonomic Plexuses of Intestine: Schema](#)
[313A Common Areas of Referred Pain in Biliary Disease](#)
[313B Innervation of Liver and Biliary Tract: Schema](#)
[313C Innervation of Liver: Nerve Fibers around Fine Branch of Hepatic Artery](#)
[314A Common Areas of Pancreatic Pain](#)
[314B Innervation of Pancreas: Schema](#)
[314C Schema of Intrinsic Nerve Supply of Pancreas](#)

Kidneys and suprarenal glands

[\[Back to](#)

[system\]](#)

[315A Kidneys in Situ: Anterior View](#)
[315B Kidneys in Situ: Anterior Relations of Kidneys](#)
[316A Kidneys in Situ: Posterior View](#)
[316B Kidneys in Situ: Posterior Relations of Kidneys](#)
[317A Anterior Surface of Right Kidney](#)
[317B Right Kidney Sectioned in Several Planes](#)
[317C Suprarenal Gland and Lobulated Kidney of Infant](#)
[318 Renal Artery and Vein in Situ](#)
[319A Intrarenal Arteries: Frontal Section of Left Kidney - Anterior View](#)
[319B Vascular Renal Segments](#)
[320A Variations in Renal Artery](#)
[320B Variations in Renal Vein](#)
[320C Variations in Renal Vein \[Continued\]](#)
[321 Nephron and Collecting Tubule: Schema](#)
[322 Blood Vessels in Kidney Parenchyma: Schema](#)
[323A Ureters in Male: Anterior View](#)
[323B Diagonal Course of Ureter through Bladder Wall](#)
[323C Ureters in Female: Superior View](#)
[324 Arteries of Ureters and Urinary Bladder](#)
[325 Lymph Vessels and Nodes of Kidneys and Urinary Bladder](#)
[326 Nerves of Kidneys Ureters and Urinary Bladder](#)
[327 Innervation of Kidneys and Upper Ureters: Schema](#)
[328A Renal Fascia: Transverse Section through 2nd Lumbar Vertebra](#)
[328B Renal Fascia: Sagittal Section through Right Kidney](#)
[329A Arteries and Veins of Right Suprarenal Gland in Situ](#)
[329B Arteries and Veins of Left Suprarenal Gland in Situ](#)
[329C Cross Section through Suprarenal Gland](#)
[330A Nerves of Suprarenal Glands: Dissection](#)
[330B Nerves of Suprarenal Glands: Schema](#)
[331 Abdominal Wall and Viscera: Cross Section at T12](#)
[332 Abdominal Wall and Viscera: Cross Section Between L2 and L3](#)
[333A Abdominal Wall and Viscera \[Above L4\]: Midsagittal Section](#)
[333B Abdominal Wall and Viscera \[Below L4\]: Midsagittal Section](#)

Bones and

ligaments

[\[Back to system\]](#)

[334A Bones and Ligaments of Pelvis: Midsagittal Section](#)
[334B Bones and Ligaments of Pelvis: Lateral View](#)
[335A Bones and Ligaments of Pelvis: Posterior View](#)
[335B Bones and Ligaments of Pelvis: Anterior View](#)
[336A Female Pelvis: Measurements - Anterior View](#)
[336B Male Pelvis: Measurements - Anterior View](#)
[336C Female Pelvis: Measurements - Inferior View](#)
[336D Female Pelvis: Measurements - Sagittal Section](#)

Pelvic floor and contents

[\[Back to system\]](#)

[337A Pelvic Diaphragm of Female: Superior View](#)
[337B Pelvic Diaphragm of Female: Medial View](#)
[338A Pelvic Diaphragm of Female: Inferior View](#)
[338B Pelvic Diaphragm of Female: Lateral View](#)
[339 Pelvic Diaphragm of Male: Superior View - Viscera Removed](#)
[340 Pelvic Diaphragm of Male: Inferior View](#)
[341A Pelvic Viscera and Perineum of Female: Midsagittal Section](#)
[341B Pelvic Viscera and Perineum of Female: Paramedian Sagittal Section](#)
[342A Pelvic Viscera and Perineum of Male: Paramedian Sagittal Section](#)
[342B Pelvic Viscera and Perineum of Male: Midsagittal Section](#)
[343 Pelvic Contents of Female: Superior View](#)
[344 Pelvic Contents of Male: Superior View](#)
[345 Endopelvic Fascia and Spaces of Female: Superior View](#)
[346A Urinary Bladder - Orientation and Supports: Midsagittal Section](#)
[346B Urinary Bladder - Orientation and Supports: Superior View](#)
[347A Urinary Bladder of Female: Frontal Section](#)
[347B Urinary Bladder of Male: Frontal Section](#)

Female structures

[\[Back to](#)

[system\]](#)

[348A Pelvic Viscera of Female: Superior View - Peritoneum Intact](#)
[348B Pelvic Viscera of Female: Superior View - Peritoneum Removed](#)
[349 Uterus, Vagina and Supporting Structures](#)
[350A Uterus and Adnexa: Posterior View](#)
[350B Uterus and Adnexa: Frontal Section](#)
[351A Uterus: Changes with Age](#)
[351B Uterus: Schema of Musculature](#)
[352A Uterus: Variations in Position](#)
[352B Uterus \[Continued\]: Variations in Position](#)
[353A Infant Ovary and Ripening Follicle: Histology](#)
[353B Stages of Ovum and Follicle](#)
[354A Perineum and External Genitalia of Female](#)
[354B Perineum and External Genitalia of Female \[Continued\]](#)
[355A Perineum of Female: Superficial Dissection](#)
[355B Perineum of Female: Midsagittal Section](#)
[356A Perineum and Urogenital Diaphragm of Female](#)
[356B Perineum and Urogenital Diaphragm of Female: Deep Dissection](#)
[357A Urethra of Female: Frontal Section](#)
[357B Urethra of Female: Schematic Reconstruction](#)

Male structures

[\[Back to system\]](#)

[358A Perineum and External Genitalia of Male: Superficial Dissection](#)

[358B Perineum of Male: Regions \[Triangles\] and Surface Topography](#)
[359A Perineum and External Genitalia of Male: Deep Dissection](#)
[359B Section through Body of Penis](#)
[360A Penis](#)
[360B Penis \[Continued\]](#)
[361A Urogenital Diaphragm of Male: Dissection](#)
[361B Urogenital Diaphragm of Male: Deep Dissection](#)
[361C Urogenital Diaphragm of Male: Frontal Section - Schema](#)
[362A Prostate and Seminal Vesicles: Frontal Section](#)
[362B Prostate and Seminal Vesicles: Sagittal Section](#)
[362C Prostate and Seminal Vesicles: Posterior View](#)
[362D Prostate and Seminal Vesicles: Cross Section through Prostate](#)
[363 Urethra: Male](#)
[364A Descent of Testis: 8 Weeks](#)
[364B Descent of Testis: 11 Weeks](#)
[364C Descent of Testis: 4 Lunar Months](#)
[364D Descent of Testis: 8 Lunar Months](#)
[365A Scrotum and Contents: Anterior View](#)
[365B Scrotum and Contents: Lateral View](#)
[366A Testis, Epididymis and Ductus Deferens: Frontal Section](#)
[366B Testis, Epididymis and Ductus Deferens: Schema](#)
[366C Testis, Epididymis and Ductus Deferens: Cross Section](#)

Rectum

[\[Back to system\]](#)

[367A Rectum of Male in Situ](#)
[367B Rectum of Female in Situ](#)
[368 Ischiorectal Fossa](#)
[369 Rectum and Anal Canal](#)
[370A Anorectal Musculature: Anterior View](#)
[370B Anorectal Musculature: Frontal Section](#)
[371A External Anal Sphincter Muscle of Male: Perineal View](#)
[371B External Anal Sphincter Muscle of Female: Perineal View](#)
[372A Perineopelvic Spaces: Sagittal Section](#)
[372B Perineopelvic Spaces: Perineal View](#)

Vasculature

[\[Back to system\]](#)

[373 Arteries of Rectum and Anal Canal](#)
[374 Veins of Rectum and Anal Canal](#)
[375 Arteries and Veins of Pelvic Organs: Female](#)
[376 Arteries and Veins of Testis](#)
[377A Arteries and Veins of Pelvis: Female - Sagittal Section](#)
[377B Arteries and Veins of Pelvis: Female - Right Paramedian Section](#)
[378A Arteries and Veins of Pelvis: Male - Left Paramedian Section](#)
[378B Arterial Supply of Prostate](#)
[379A Arteries and Veins of Perineum: Female](#)
[379B Arteries and Veins of Uterus](#)
[380A Arteries and Veins of Perineum: Male](#)
[380B Arteries and Veins of Perineum \[Continued\]: Male](#)
[381 Lymph Vessels and Nodes of Pelvis and Genitalia: Female](#)
[382 Lymph Vessels and Nodes of Perineum: Female](#)
[383A Lymph Vessels and Nodes of Pelvis and Genitalia: Male](#)
[383B Lymphatic Drainage from Prostate](#)

Innervation

[\[Back to system\]](#)

[384 Nerves of External Genitalia: Male](#)
[385 Nerves of Pelvic Viscera: Male](#)
[386A Nerves of Perineum: Male - Perineal View](#)
[386B Nerves of Perineum: Male - Inferior View](#)
[387A Nerves of Pelvic Viscera: Female - Sagittal Section](#)
[387B Nerves of Pelvic Viscera: Female - Superior View](#)
[388A Nerves of Perineum and External Genitalia: Female](#)
[388B Block Anesthesia of Perineal Area: Primarily Pudendal Nerve](#)
[389A Neuropathways in Parturition](#)
[389B Neuropathways in Parturition: Pelvic Area Enlarged](#)
[390 Innervation of Female Reproductive Organs: Schema](#)
[391 Innervation of Male Reproductive Organs: Schema](#)
[392 Innervation of Urinary Bladder and Lower Ureter: Schema](#)
[393A Homologues of External Genitalia: Undifferentiated Stage](#)
[393B Homologues of External Genitalia: Fully Developed Male and Female](#)

[394A Homologues of Internal Genitalia: Undifferentiated Stage](#)
[394B Homologues of Internal Genitalia: Fully Developed Male and Female](#)

Shoulder and axilla

[\[Back to system\]](#)

[395A Right Clavicle - Features](#)
[395B Right Clavicle - Muscle Attachments](#)
[395C Sternoclavicular Joint](#)
[396A Humerus and Scapula: Anterior View - Features](#)
[396B Humerus and Scapula: Anterior View - Muscle Attachments](#)
[397A Humerus and Scapula: Posterior View - Features](#)
[397B Humerus and Scapula: Posterior View - Muscle Attachments](#)
[398A Glenohumeral Joint: Anterior View - Tendons and Ligaments](#)
[398B Glenohumeral Joint: Anterior View - Supporting Muscles](#)
[398C Glenohumeral Joint \[Opened\]: Lateral View](#)
[398D Glenohumeral Joint: Coronal Section through Joint](#)
[399A Muscles of Shoulder: Posterior View](#)
[399B Muscles of Shoulder: Anterior View](#)
[400A Muscles of Rotator Cuff: Superior View](#)
[400B Muscles of Rotator Cuff: Anterior View](#)
[400C Muscles of Rotator Cuff: Posterior View](#)
[401A Scapulohumeral Dissection: Anterior View](#)
[401B Scapulohumeral Dissection: Posterior View](#)
[402A Axillary Artery and Anastomoses Around Scapula: Anterior View](#)
[402B Axillary Artery and Anastomoses Around Scapula: Posterior View](#)
[403A Pectoral Clavipectoral and Axillary Fasciae: Anterior View](#)
[403B Pectoral Clavipectoral and Axillary Fasciae: Section of Axilla](#)
[404 Axilla \[Dissection\]: Anterior View](#)
[405 Brachial Plexus: Schema](#)

Arm

[\[Back to system\]](#)

[406A Muscles of Arm: Anterior View - Superficial Layer](#)
[406B Muscles of Arm: Anterior View - Deep Layer](#)
[407A Muscles of Arm: Posterior View - Superficial Layer](#)
[407B Muscles of Arm: Posterior View - Deep Layer](#)
[408 Brachial Artery in Situ](#)
[409 Brachial Artery and Anastomoses Around Elbow](#)
[410A Arm: Proximal Cross Section](#)
[410B Arm: Middle Cross Section](#)
[410C Arm: Distal Cross Section](#)

Elbow and forearm

[\[Back to system\]](#)

[411A Bones of Elbow in Extension: Anterior and Posterior Views](#)
[411B Bones of Elbow in Extension: Lateral and Medial Views](#)
[411C Bones of Elbow in 90° Flexion: Lateral and Medial Views](#)
[412A Ligaments of Elbow: Right Elbow - Anterior View](#)
[412B Ligaments of Elbow in 90° Flexion: Lateral and Medial Views](#)
[412C Elbow Joint \[Opened\]: Anterior and Posterior Views](#)
[413A Right Radius and Ulna in Supination: Anterior View](#)
[413B Right Radius and Ulna in Pronation: Anterior View](#)
[413C Bones of Forearm: Carpal Articular Surface and Section of Radius](#)
[414A Individual Muscles of Forearm: Rotators of Radius - Supination](#)
[414B Individual Muscles of Forearm: Rotators of Radius - Pronation](#)
[415A Individual Muscles of Forearm: Extensors of Wrist and Digits](#)
[415B Individual Muscles of Forearm \[Continued\]: Extensors of Wrist and Digits](#)
[416 Individual Muscles of Forearm: Flexors of Wrist](#)
[417A Individual Muscles of Forearm: Flexors of Digits](#)
[417B Individual Muscles of Forearm \[Continued\]: Flexors of Digits](#)
[418 Muscles of Forearm \[Superficial Layer\]: Posterior View](#)
[419 Muscles of Forearm \[Deep Layer\]: Posterior View](#)
[420 Muscles of Forearm \[Superficial Layer\]: Anterior View](#)
[421 Muscles of Forearm \[Intermediate Layer\]: Anterior View](#)
[422 Muscles of Forearm \[Deep Layer\]: Anterior View](#)
[423A Forearm: Proximal Cross Section](#)
[423B Forearm: Middle Cross Section](#)

[423C Forearm: Distal Cross Section](#)
[424 Bony Attachments of Muscles of Forearm: Anterior View](#)
[425 Bony Attachments of Muscles of Forearm: Posterior View](#)

Wrist and hand

[\[Back to system\]](#)

[426A Carpal Bones: Anterior \[Palmar\] View](#)
[426B Carpal Bones: Posterior \[Dorsal\] View](#)
[427A Movements of Wrist: Hand in Abduction - Anterior \[Palmar\] View](#)
[427B Movements of Wrist: Hand in Adduction - Anterior \[Palmar\] View](#)
[427C Movements of Wrist: Sagittal Sections](#)
[428A Ligaments of Wrist: Carpal Tunnel - Palmar View](#)
[428B Ligaments of Wrist: Flexor Retinaculum Removed - Palmar View](#)
[429A Ligaments of Wrist: Posterior \[Dorsal\] View](#)
[429B Ligaments of Wrist: Coronal Section - Dorsal View](#)
[430A Bones of Right Wrist and Hand: Anterior \[Palmar\] View](#)
[430B Bones of Right Wrist and Hand: Posterior \[Dorsal\] View](#)
[431A Metacarpophalangeal and Interphalangeal Ligaments: Palmar View](#)
[431B Metacarpophalangeal and Interphalangeal Ligaments: Medial Views](#)
[432A Wrist and Hand: Superficial Palmar Dissections](#)
[432B Wrist and Hand: Superficial Palmar Dissections \[Continued\]](#)
[433A Wrist and Hand: Deeper Palmar Dissections](#)
[433B Wrist and Hand: Deeper Palmar Dissections \[Continued\]](#)
[434A Flexor Tendons Arteries and Nerves at Wrist: Palmar View](#)
[434B Flexor Tendons Arteries and Nerves at Wrist: Cross Section](#)
[435A Bursae Spaces and Tendon Sheaths of Hand: Palmar View](#)
[435B Bursae Spaces and Tendon Sheaths of Hand: Cross Section](#)
[436A Lumbrical Muscles and Bursae Spaces and Sheaths: Schema](#)
[436B Lumbrical Muscles: Schema](#)
[437A Flexor and Extensor Tendons in Fingers: Posterior \[Dorsal\] View](#)
[437B Flexor and Extensor Tendons in Fingers: Extended - Lateral View](#)
[437C Flexor and Extensor Tendons in Fingers: Flexed - Lateral View](#)
[438A Intrinsic Muscles of Hand: Anterior \[Palmar\] View](#)
[438B Intrinsic Muscles of Hand: Posterior \[Dorsal\] View](#)
[438C Intrinsic Muscles of Hand: Deep Anterior \[Palmar\] View](#)
[439A Arteries and Nerves of Hand: Palmar View](#)
[439B Arteries and Nerves of Hand: Deep Palmar View](#)
[440 Wrist and Hand: Superficial Radial Dissection](#)
[441 Wrist and Hand: Superficial Dorsal Dissection](#)
[442 Wrist and Hand: Deep Dorsal Dissection](#)
[443A Extensor Tendons at Wrist: Posterior \[Dorsal\] View](#)
[443B Extensor Tendons at Wrist: Cross Section at Proximal Wrist](#)
[444A Fingers: Sagittal Section](#)
[444B Fingers: Cross Section through Distal Phalanx](#)
[444C Fingers: Arteries and Nerves](#)

Neurovasculature

[\[Back to system\]](#)

[445A Cutaneous Nerves of Wrist and Hand: Anterior \[Palmar\] View](#)
[445B Cutaneous Nerves of Wrist and Hand: Posterior \[Dorsal\] View](#)
[446 Arteries and Nerves of Upper Limb](#)
[447 Musculocutaneous Nerve](#)
[448 Median Nerve](#)
[449 Ulnar Nerve](#)
[450 Radial Nerve in Arm and Nerves of Posterior Shoulder](#)
[451A Radial Nerve in Forearm: Posterior View](#)
[451B Radial and Axillary Nerves: Cutaneous Innervation](#)
[452A Superficial Nerves and Veins of Shoulder and Arm: Anterior View](#)
[452B Superficial Nerves and Veins of Shoulder and Arm: Posterior View](#)
[453A Cutaneous Nerves and Superficial Veins of Forearm: Anterior \(Palmar\) View](#)
[453B Cutaneous Nerves and Superficial Veins of Forearm: Posterior \(Dorsal\) View](#)
[454A Cutaneous Innervation of Upper Limb: Anterior \[Palmar\] View](#)
[454B Cutaneous Innervation of Upper Limb: Posterior \[Dorsal\] View](#)
[455A Dermatomes of Upper Limb: Anterior View](#)
[455B Dermatomes of Upper Limb: Posterior View](#)
[456A Lymph Vessels and Nodes of Upper Limb](#)
[456B Lymph Vessels of Hand](#)

Hip and thigh

[\[Back to system\]](#)

[457A Coxal Bone: Lateral View](#)
[457B Coxal Bone: Medial View](#)

[458A Hip Joint: Anterior View](#)
[458B Hip Joint: Posterior View](#)
[458C Hip Joint \[Opened\]: Lateral View](#)
[459A Femur: Anterior View](#)
[459B Femur: Posterior View](#)
[460 Bony Attachments of Muscles of Hip and Thigh: Anterior View](#)
[461 Bony Attachments of Muscles of Hip and Thigh: Posterior View](#)
[462A Muscles of Thigh: Anterior View - Superficial Dissection](#)
[462B Muscles of Thigh: Anterior View - Deeper Dissection](#)
[463 Muscles of Thigh: Anterior View - Deepest Dissection](#)
[464 Muscles of Hip and Thigh: Lateral View](#)
[465A Muscles of Hip and Thigh: Posterior View - Superficial Dissection](#)
[465B Muscles of Hip and Thigh: Posterior View - Deeper Dissection](#)
[466A Psoas and Iliacus Muscles](#)
[466B Psoas and Iliacus Muscles: Action](#)
[467 Lumbosacral and Coccygeal Plexuses](#)
[468A Lumbar Plexus: Schema](#)
[468B Lumbar Plexus in Situ](#)
[469A Sacral and Coccygeal Plexuses: Schema](#)
[469B Sacral and Coccygeal Plexuses in Situ](#)
[470A Arteries and Nerves of Thigh: Superficial Anterior View](#)
[470B Arteries and Nerves of Thigh: Deeper Anterior View](#)
[471 Arteries and Nerves of Thigh: Deepest Anterior View](#)
[472 Arteries and Nerves of Thigh: Posterior View](#)
[473 Nerves of Hip and Buttock](#)
[474A Arteries of Femoral Head and Neck: Anterior and Posterior Views](#)
[474B Arteries of Femoral Head and Neck: Coronal Section](#)
[474C Arteries of Femoral Head and Neck: Femur of Child - Anterior View](#)
[474D Arteries of Femoral Head and Neck: Anterior View in Situ](#)
[475A Thigh: Proximal Cross Section](#)
[475B Thigh: Middle Cross Section](#)
[475C Thigh: Distal Cross Section](#)

Knee

[\[Back to system\]](#)

[476A Knee: Lateral View](#)
[476B Knee: Medial View](#)
[477A Knee in Extension: Anterior View](#)
[477B Knee: Right Knee Slightly in Flexion \[Joint Opened\]](#)
[478A Knee - Interior: Inferior View](#)
[478B Knee - Interior: Superior View](#)
[478C Knee - Interior: Superior View Ligaments and Cartilage Removed](#)
[479A Knee - Cruciate and Collateral Ligaments: Right Knee in Flexion](#)
[479B Knee - Cruciate and Collateral Ligaments: Right Knee in Extension](#)
[480A Knee: Posterior View](#)
[480B Knee: Parasagittal Section - Lateral to Midline](#)
[481 Arteries of Thigh and Knee: Schema](#)

Leg

[\[Back to system\]](#)

[482A Tibia and Fibula of Right Leg: Anterior View](#)
[482B Tibia and Fibula of Right Leg: Posterior View](#)
[483A Tibia and Fibula of Right Leg: Anterior View - Ligament Attachments](#)
[483B Tibia and Fibula of Right Leg: Superior View](#)
[483C Tibia and Fibula of Right Leg: Cross Section](#)
[483D Tibia and Fibula of Right Leg: Inferior View](#)
[484A Bony Attachments of Muscles of Leg: Anterior View](#)
[484B Bony Attachments of Muscles of Leg: Posterior View](#)
[485 Muscles of Leg \[Superficial Dissection\]: Posterior View](#)
[486 Muscles of Leg \[Intermediate Dissection\]: Posterior View](#)
[487 Muscles of Leg \[Deep Dissection\]: Posterior View](#)
[488 Muscles of Leg \[Superficial Dissection\]: Anterior View](#)
[489 Muscles of Leg \[Deep Dissection\]: Anterior View](#)
[490 Muscles of Leg: Lateral View](#)
[491A Leg: Cross Section - Fascial Compartments](#)
[491B Leg: Cross Section just above Middle of Left Leg](#)

Ankle and foot

[\[Back to system\]](#)

[492A Bones of Foot: Dorsal View](#)
[492B Bones of Foot: Plantar View](#)
[493A Bones of Foot: Lateral View](#)

[493B Bones of Foot: Medial View](#)
[494A Calcaneus of Right Foot: Lateral and Superior Views](#)
[494B Calcaneus of Right Foot: Medial and Posterior Views](#)
[494C Calcaneus of Right Foot: Posterior View with Ligaments](#)
[494D Calcaneus of Right Foot: Functional Relations of Calcaneus](#)
[495A Ligaments and Tendons of Right Ankle: Lateral View](#)
[495B Ligaments and Tendons of Right Ankle: Medial View](#)
[496A Ligaments and Tendons of Foot: Plantar View](#)
[496B Metatarsophalangeal and Interphalangeal Joints: Lateral View](#)
[497A Tendon Sheaths of Ankle: Lateral View](#)
[497B Tendon Sheaths of Ankle: Medial View](#)
[498 Muscles of Dorsum of Foot: Superficial Dissection](#)
[499 Dorsum of Foot: Deep Dissection](#)
[500 Sole of Foot: Superficial Dissection](#)
[501 Muscles of Sole of Foot: First Layer](#)
[502 Muscles of Sole of Foot: Second Layer](#)
[503 Muscles of Sole of Foot: Third Layer](#)
[504A Interosseous Muscles and Deep Arteries of Foot: Dorsal View](#)
[504B Interosseous Muscles and Deep Arteries of Foot: Plantar View](#)
[505A Interosseous Muscles of Foot: Dorsal View](#)
[505B Interosseous Muscles of Foot: Plantar View](#)

Neurovasculature

[\[Back to system\]](#)

[506A Femoral and Lateral Femoral Cutaneous Nerves](#)
[506B Femoral and Lateral Femoral Cutaneous Nerves: Cutaneous Innervation](#)
[507A Obturator Nerve](#)
[507B Obturator Nerve: Cutaneous Innervation](#)
[508A Sciatic and Posterior Femoral Cutaneous Nerves](#)
[508B Sciatic and Posterior Femoral Cutaneous Nerves: Cutaneous Innervation](#)
[509A Tibial Nerve](#)
[509B Tibial Nerve: Plantar View](#)
[509C Tibial Nerve: Cutaneous Innervation of Sole of Foot](#)
[510A Common Peroneal Nerve](#)
[510B Common Peroneal Nerve: Cutaneous Innervation](#)
[511A Dermatomes of Lower Limb: Anterior and Posterior Views](#)
[511B Segmental Innervation of Lower Limb Movements](#)
[512 Superficial Nerves and Veins of Lower Limb: Anterior View](#)
[513 Superficial Nerves and Veins of Lower Limb: Posterior View](#)
[514A Lymph Vessels and Nodes of Lower Limb: Anterior View](#)
[514B Lymph Vessels and Nodes of Lower Limb: Posterior View](#)
[514C Lymph Vessels and Nodes of Lower Limb: Inguinal Region](#)

System contents

[\[Skeletal\]](#) , [\[Muscle\]](#) , [\[Circulatory\]](#) , [\[Nerve\]](#) , [\[Urinary\]](#) , [\[Respiratory\]](#) , [\[Endocrine\]](#) , [\[Digestive\]](#) , [\[Reproductive\]](#) , [\[Lymphatic\]](#)

Skeletal

[\[Back to regional\]](#)

[Axial-Skull](#)
[Axial-Vetebral column](#)
[Axial-Ribs and sternum](#)
[Appendicular upper limb](#)
[Appendicular lower limb](#)

Muscle

[\[Back to regional\]](#)

[Head](#)
[Neck](#)
[Throax](#)
[Back](#)
[Pelvis and perinum](#)
[Upper limb\(Shoulder and Arm\)](#)
[Upper limb\(Forearm and Hand\)](#)
[Lower limb\(Hip and Thigh\)](#)
[Lower limb\(Leg and Foot\)](#)

Circulatory

[\[Back to regional\]](#)

[Heart](#)
[Artery-Head and Neck](#)
[Artery-Back and Spinal](#)
[Artery-Throax](#)
[Artery-abdomen](#)
[Artery-Pelvis and perinum](#)
[Artery-Upper limb](#)
[Artery-Lower limb](#)
[Vein-Head and Neck](#)
[Vein-Back and Spinal](#)
[Vein-Throax](#)
[Vein-abdomen](#)
[Vein-Pelvis and perinum](#)
[Vein-Upper limb](#)
[Vein-Lower limb](#)

Nerve

[\[Back to regional\]](#)

[Central: Brain](#)
[Central: Spinal](#)
[Peripheral: CN. And branch](#)
[Peripheral: Spinal nerve/plexuses](#)
[Peripheral: Upper limb](#)
[Peripheral: Lower limb](#)
[Dermatomes/Cutaneous Innervation](#)
[ANS](#)
[Special senses](#)

Urinary

[\[Back to regional\]](#)

[Kidney](#)
[Ureter](#)
[Bladder](#)
[Urethra](#)

Respiratory

[\[Back to regional\]](#)

[Sinuses/Nose](#)

[Larynx](#)

[Trachea](#)

[Bronchi](#)

[Lungs](#)

[Diaphragm](#)

Endocrine

[\[Back to regional\]](#)

[Pituitary gland](#)

[Thyroid/Parathyroid/Thymus gland](#)

[Adrenal gland](#)

[Pancreas](#)

[Testes](#)

[Ovaries](#)

Digestive

[\[Back to regional\]](#)

[Mouth and Pharynx/Salivary glands](#)

[Esophagus and Stomach](#)

[Small intestine](#)

[Large intestine/Rectum](#)

[Gallbladder and Liver](#)

[Pancreas](#)

Reproductive

[\[Back to regional\]](#)

[External genitalia\(male\)](#)

[Pelvic structure\(male\)](#)

[Mammary gland\(female\)](#)

[External genitalia\(female\)](#)

[Pelvic structure\(female\)](#)

Lymphatic

[\[Back to regional\]](#)

[Head and Neck](#)

[Throat](#)

[Abdomen](#)

[Pelvis and Perinum](#)

[Limbs](#)

Axial-Skull

[\[Back to regional\]](#)

1A Skull: Anterior View

1B Right Orbit: Frontal and Slightly Lateral View

2A Skull: Lateral View

2B Skull - Infratemporal Fossa Exposed: Lateral View

3A Skull: Midsagittal Section

3B Skull - Nasal Conchae Exposed: Sagittal Section

4A Calvaria: Superior View

4B Calvaria: Inferior View

5 Cranial Base: Inferior View

6 Bones of Cranial Base: Superior View

7 Foramina of Cranial Base: Superior View

8A Skull of Newborn: Lateral View

8B Skull of Newborn: Superior View

9A Bony Framework of Head and Neck: Lateral View

9B Bony Framework of Head - Mandible Removed: Lateral View
10A Mandible: Anterolateral Superior View
10B Mandible: Left Posterior View
11A Temporomandibular Joint: Lateral and Medial Views
11B Temporomandibular Joint: Joint Action
16A Atlantooccipital Junction
16B Atlantooccipital Junction: McGregor's Line
16C Atlantooccipital Junction: Odontoid Abnormalities
24B Infrahyoid and Suprahyoid Muscles and their Action: Schema
30B Fascial Layers of Neck: Sagittal Section
31A External Nose [Skeleton]: Anterolateral and Inferior Views
32A Lateral Nasal Wall
32C Lateral Nasal Wall - Nasal Conchae Removed
33A Lateral Nasal Wall - Bony Structure
33B Lateral Nasal Wall - Bony Structure: Nasal Conchae Partly Removed
34A Medial Nasal Wall [Septum]
34B Medial Nasal Wall [Septum]: Bones and Cartilages
35A Maxillary Artery: Orbitomaxillary Distribution
35B Maxillary Artery: Nasopalatine Distribution
36 Arteries of Nasal Cavity: Schematic Hinge
37 Nerves of Nasal Cavity: Schematic Hinge
38B Nerves of Nasal Cavity: Lateral Nasal Wall
38C Nerves of Nasal Cavity: Nasal Septum
40 Ophthalmic and Maxillary Nerves
41A Mandibular Nerve [V3]: Lateral View
41B Mandibular Nerve [V3]: Medial View
47A Floor of Mouth - Musculature: Lateral Slightly Inferior View
47B Floor of Mouth - Musculature: Anteroinferior View
47C Floor of Mouth - Musculature: Posterosuperior View
48A Muscles Involved in Mastication: Lateral View
48B Muscles Involved in Mastication - Masseter Removed: Lateral View
49A Muscles Involved in Mastication [Deep]: Lateral View
49B Muscles Involved in Mastication [Deep]: Posterior View
54A Tongue and Mouth: Horizontal Section - Superior View
54B Tongue and Mouth: Frontal Section - Anterior View
57 Pharynx: Sagittal Section
58A Fauces: Medial Sagittal View
58B Fauces: Pharyngeal Mucosa Removed
59 Muscles of Pharynx: Sagittal Section
62 Muscles of Pharynx: Lateral View
63 Arteries of Oral and Pharyngeal Regions
64 Veins of Oral and Pharyngeal Regions
65 Nerves of Oral and Pharyngeal Regions
66 Lymph Vessels and Nodes of Oral and Pharyngeal Regions
87 Pathway of Sound Reception
88B External Ear: Right Tympanic Membrane
88C Tympanic Cavity: Viewed from External Acoustic Meatus
88D External Ear and Tympanic Cavity: Coronal Oblique Section
88E Tympanic Cavity: Auditory Ossicles
89A Tympanic Cavity - Lateral Wall: Medial View
89B Tympanic Cavity - Medial Wall: Lateral View
91A Osseous and Membranous Labyrinths: Schema
92A Orientation of Labyrinth in Skull: Superior Projection
93A Cartilage of Auditory Tube at Base of Skull: Inferior View
93B Auditory Tube - Section through Cartilage: Tube Closed
93C Auditory Tube - Section through Cartilage: Tube Open
94A Meninges and Diploic Veins: Coronal Dissection
94B Diploic and Emissary Veins of Skull
95A Meningeal Arteries
95B Meningeal Arteries [Continued]
96A Meninges and Superficial Cerebral Veins: Frontal Section
98A Venous Sinuses of Dura Mater: Cranial Floor - Superior View
98B Cavernous Sinus: Coronal Section

Axial-Vertebral column

[\[Back to regional\]](#)

9A Bony Framework of Head and Neck: Lateral View
12A Cervical Vertebrae: Atlas and Axis
12B Cervical Vertebrae [C1-C4] Assembled: Posterosuperior View
13A Cervical Vertebrae [C4 and C7]: Superior Views
13B Cervical Vertebrae [C2-T1] Assembled: Right Lateral View
13C Cervical Vertebrae [C3-C5] Assembled: Anterior View
14A External Craniocervical Ligaments: Anterior and Posterior Views
14B External Craniocervical Ligaments: Right Lateral View
15A Internal Craniocervical Ligaments
15B Internal Craniocervical Ligaments [Continued]
16A Atlantooccipital Junction
16B Atlantooccipital Junction: McGregor's Line

16C Atlantooccipital Junction: Odontoid Abnormalities
28B Subclavian Artery: Right Lateral Schematic View
30A Fascial Layers of Neck: Cross Section
30B Fascial Layers of Neck: Sagittal Section
57 Pharynx: Sagittal Section
59 Muscles of Pharynx: Sagittal Section
142 Vertebral Column
143A Thoracic Vertebrae [T6]: Superior View
143B Thoracic Vertebrae [T6]: Lateral View
143C Thoracic Vertebrae [T12]: Lateral View
143D Thoracic Vertebrae [T7-T9] - Assembled: Posterior View
144A Lumbar Vertebrae [L2]: Superior View
144B Lumbar Vertebrae: Intervertebral Disc
144C Lumbar Vertebrae [L3-L4] - Assembled: Posterior View
144D Lumbar Vertebrae [L1-L5] - Assembled: Left Lateral View
145A Sacrum and Coccyx: Pelvic Surface
145B Sacrum and Coccyx: Median Sagittal Section
145C Sacrum: Transverse Section through S1 Foramina
145D Sacrum and Coccyx: Dorsal Surface
146A Vertebral Ligaments of Lumbar Region: Left Lateral View - Partially Sectioned
146B Vertebral Ligaments of Lumbar Region: Anterior Vertebral Segments - Posterior View
146C Vertebral Ligaments of Lumbar Region: Posterior Vertebral Segments - Anterior View
147A Vertebral Ligaments of Lumbosacral Region: Left Lateral View
147B Vertebral Ligaments of Lumbosacral Region: Posterior View
148 Spinal Cord in Situ
149A Relation of Spinal Nerve Roots to Vertebrae
149B Relation of Spinal Nerve Roots to Vertebrae: Lateral Protrusion
149C Relation of Spinal Nerve Roots to Vertebrae: Medial Protrusion
159A Veins of Spinal Cord: Sagittal Section [without Cord]
170A Bony Framework of Thorax: Anterior View
170B Bony Framework of Thorax: Posterior View
179 Intercostal Nerves and Arteries
180 Diaphragm: Thoracic Surface
185 Topography of Lungs: Posterior View
188B Bronchopulmonary Segments: Posterior View
230 Mediastinum: Cross Section
231 Bony Framework of Abdomen
269A Topography of Liver: Anterior and Posterior Views
328A Renal Fascia: Transverse Section through 2nd Lumbar Vertebra
333A Abdominal Wall and Viscera [Above L4]: Midsagittal Section
333B Abdominal Wall and Viscera [Below L4]: Midsagittal Section
334A Bones and Ligaments of Pelvis: Midsagittal Section
334B Bones and Ligaments of Pelvis: Lateral View
335A Bones and Ligaments of Pelvis: Posterior View
335B Bones and Ligaments of Pelvis: Anterior View
336A Female Pelvis: Measurements - Anterior View
336B Male Pelvis: Measurements - Anterior View
336C Female Pelvis: Measurements - Inferior View
336D Female Pelvis: Measurements - Sagittal Section

Axial-Ribs and sternum [\[Back to regional\]](#)

170A Bony Framework of Thorax: Anterior View
170B Bony Framework of Thorax: Posterior View
171A Left 1st and 2nd Ribs: Superior Views
171B Sternocostal Articulations: Anterior View
171C Middle Rib: Posterior View
172A Costovertebral Joints: Left Lateral View
172B Costovertebral Joints: Transverse Section - Superior View
172C Costovertebral Joints: Right Posterolateral View
173A Cervical Ribs and Related Anomalies 1
173B Cervical Ribs and Related Anomalies 2
173C Cervical Ribs and Related Anomalies 3
176 Anterior Thoracic Wall: Internal View
179 Intercostal Nerves and Arteries
180 Diaphragm: Thoracic Surface
184 Topography of Lungs: Anterior View
185 Topography of Lungs: Posterior View
188A Bronchopulmonary Segments: Anterior View
230 Mediastinum: Cross Section
231 Bony Framework of Abdomen
269A Topography of Liver: Anterior and Posterior Views
269B Topography of Liver: Lateral View
316A Kidneys in Situ: Posterior View
395C Sternoclavicular Joint

Appendicular upper limb [\[Back to regional\]](#)

395A Right Clavicle - Features
395B Right Clavicle - Muscle Attachments
396A Humerus and Scapula: Anterior View - Features
396B Humerus and Scapula: Anterior View - Muscle Attachments
397A Humerus and Scapula: Posterior View - Features
397B Humerus and Scapula: Posterior View - Muscle Attachments
398A Glenohumeral Joint: Anterior View - Tendons and Ligaments
398B Glenohumeral Joint: Anterior View - Supporting Muscles
398C Glenohumeral Joint [Opened]: Lateral View
398D Glenohumeral Joint: Coronal Section through Joint
400A Muscles of Rotator Cuff: Superior View
410A Arm: Proximal Cross Section
410B Arm: Middle Cross Section
410C Arm: Distal Cross Section

411A Bones of Elbow in Extension: Anterior and Posterior Views
411B Bones of Elbow in Extension: Lateral and Medial Views
411C Bones of Elbow in 90° Flexion: Lateral and Medial Views
412A Ligaments of Elbow: Right Elbow - Anterior View
412B Ligaments of Elbow in 90° Flexion: Lateral and Medial Views
412C Elbow Joint [Opened]: Anterior and Posterior Views
413A Right Radius and Ulna in Supination: Anterior View
413B Right Radius and Ulna in Pronation: Anterior View
413C Bones of Forearm: Carpal Articular Surface and Section of Radius
414A Individual Muscles of Forearm: Rotators of Radius - Supination
414B Individual Muscles of Forearm: Rotators of Radius - Pronation
415A Individual Muscles of Forearm: Extensors of Wrist and Digits
415B Individual Muscles of Forearm [Continued]: Extensors of Wrist and Digits
416 Individual Muscles of Forearm: Flexors of Wrist
417A Individual Muscles of Forearm: Flexors of Digits
417B Individual Muscles of Forearm [Continued]: Flexors of Digits
423A Forearm: Proximal Cross Section
423B Forearm: Middle Cross Section
423C Forearm: Distal Cross Section
424 Bony Attachments of Muscles of Forearm: Anterior View
425 Bony Attachments of Muscles of Forearm: Posterior View
426A Carpal Bones: Anterior [Palmar] View
426B Carpal Bones: Posterior [Dorsal] View
427A Movements of Wrist: Hand in Abduction - Anterior [Palmar] View
427B Movements of Wrist: Hand in Adduction - Anterior [Palmar] View
427C Movements of Wrist: Sagittal Sections
428A Ligaments of Wrist: Carpal Tunnel - Palmar View
428B Ligaments of Wrist: Flexor Retinaculum Removed - Palmar View
429A Ligaments of Wrist: Posterior [Dorsal] View
429B Ligaments of Wrist: Coronal Section - Dorsal View
430A Bones of Right Wrist and Hand: Anterior [Palmar] View
430B Bones of Right Wrist and Hand: Posterior [Dorsal] View
431A Metacarpophalangeal and Interphalangeal Ligaments: Palmar View
431B Metacarpophalangeal and Interphalangeal Ligaments: Medial Views
444A Fingers: Sagittal Section
444B Fingers: Cross Section through Distal Phalanx

Appendicular lower limb

[\[Back to regional\]](#)

147B Vertebral Ligaments of Lumbosacral Region: Posterior View
231 Bony Framework of Abdomen
334A Bones and Ligaments of Pelvis: Midsagittal Section
334B Bones and Ligaments of Pelvis: Lateral View
335A Bones and Ligaments of Pelvis: Posterior View
335B Bones and Ligaments of Pelvis: Anterior View
336A Female Pelvis: Measurements - Anterior View
336B Male Pelvis: Measurements - Anterior View
336C Female Pelvis: Measurements - Inferior View
336D Female Pelvis: Measurements - Sagittal Section
337A Pelvic Diaphragm of Female: Superior View
337B Pelvic Diaphragm of Female: Medial View
338A Pelvic Diaphragm of Female: Inferior View
338B Pelvic Diaphragm of Female: Lateral View
339 Pelvic Diaphragm of Male: Superior View - Viscera Removed
340 Pelvic Diaphragm of Male: Inferior View
346B Urinary Bladder - Orientation and Supports: Superior View
361A Urogenital Diaphragm of Male: Dissection
361B Urogenital Diaphragm of Male: Deep Dissection
361C Urogenital Diaphragm of Male: Frontal Section - Schema
373 Arteries of Rectum and Anal Canal
457A Coxal Bone: Lateral View
457B Coxal Bone: Medial View
458A Hip Joint: Anterior View
458B Hip Joint: Posterior View
458C Hip Joint [Opened]: Lateral View
459A Femur: Anterior View
459B Femur: Posterior View
460 Bony Attachments of Muscles of Hip and Thigh: Anterior View
461 Bony Attachments of Muscles of Hip and Thigh: Posterior View
474A Arteries of Femoral Head and Neck: Anterior and Posterior Views
474B Arteries of Femoral Head and Neck: Coronal Section
474C Arteries of Femoral Head and Neck: Femur of Child - Anterior View
474D Arteries of Femoral Head and Neck: Anterior View in Situ
475A Thigh: Proximal Cross Section
475B Thigh: Middle Cross Section
475C Thigh: Distal Cross Section
477B Knee: Right Knee Slightly in Flexion [Joint Opened]
478A Knee - Interior: Inferior View

478B Knee - Interior: Superior View
478C Knee - Interior: Superior View, Ligaments and Cartilage Removed
479A Knee - Cruciate and Collateral Ligaments: Right Knee in Flexion
479B Knee - Cruciate and Collateral Ligaments: Right Knee in Extension
480A Knee: Posterior View
480B Knee: Parasagittal Section - Lateral to Midline
482A Tibia and Fibula of Right Leg: Anterior View
482B Tibia and Fibula of Right Leg: Posterior View
483A Tibia and Fibula of Right Leg: Anterior View - Ligament Attachments
483B Tibia and Fibula of Right Leg: Superior View
483C Tibia and Fibula of Right Leg: Cross Section
483D Tibia and Fibula of Right Leg: Inferior View
484A Bony Attachments of Muscles of Leg: Anterior View
484B Bony Attachments of Muscles of Leg: Posterior View
491A Leg: Cross Section - Fascial Compartments
491B Leg: Cross Section just above Middle of Left Leg
492A Bones of Foot: Dorsal View
492B Bones of Foot: Plantar View
493A Bones of Foot: Lateral View
493B Bones of Foot: Medial View
494A Calcaneus of Right Foot: Lateral and Superior Views
494B Calcaneus of Right Foot: Medial and Posterior Views
494C Calcaneus of Right Foot: Posterior View with Ligaments
494D Calcaneus of Right Foot: Functional Relations of Calcaneus
495A Ligaments and Tendons of Right Ankle: Lateral View
495B Ligaments and Tendons of Right Ankle: Medial View
496A Ligaments and Tendons of Foot: Plantar View
496B Metatarsophalangeal and Interphalangeal Joints: Lateral View
504A Interosseous Muscles and Deep Arteries of Foot: Dorsal View
504B Interosseous Muscles and Deep Arteries of Foot: Plantar View
505A Interosseous Muscles of Foot: Dorsal View
505B Interosseous Muscles of Foot: Plantar View

Head

[\[Back to regional\]](#)

20A Muscles of Facial Expression: Anterior View
20B Superficial Face: Course of Wrinkle Lines of Skin
21 Muscles of Facial Expression: Lateral View
29A Carotid Arteries - Parotid Fossa: Right Lateral Dissection
31B External Nose [Skeleton] in Situ: Lateral View
46A Roof of Mouth - Hard and Soft Palates: Anterior View
46B Roof of Mouth - Soft Palate: Posterior View
47A Floor of Mouth - Musculature: Lateral Slightly Inferior View
47B Floor of Mouth - Musculature: Anteroinferior View
47C Floor of Mouth - Musculature: Posterosuperior View
48A Muscles Involved in Mastication: Lateral View
48B Muscles Involved in Mastication - Masseter Removed: Lateral View
49A Muscles Involved in Mastication [Deep]: Lateral View
49B Muscles Involved in Mastication [Deep]: Posterior View
53A Muscles of Tongue: Sagittal Section
53B Tongue and Related Structures: Sagittal Section
54A Tongue and Mouth: Horizontal Section - Superior View
54B Tongue and Mouth: Frontal Section - Anterior View
55A Salivary Glands: Dissection
57 Pharynx: Sagittal Section
59 Muscles of Pharynx: Sagittal Section
62 Muscles of Pharynx: Lateral View
63 Arteries of Oral and Pharyngeal Regions
64 Veins of Oral and Pharyngeal Regions
65 Nerves of Oral and Pharyngeal Regions
66 Lymph Vessels and Nodes of Oral and Pharyngeal Regions
67B Lymphatic Drainage of Tongue: Lateral View
76B Eyelids and Anterior Orbital Structures: Sagittal Section
78A Fascia of Orbit and Eyeball: Horizontal Section
78B Fascia of Orbit and Eyeball: Frontal Section and Entering Structures
79A Extrinsic Eye Muscles: Right Lateral View
79B Extrinsic Eye Muscles: Superior View
79C Extrinsic Eye Muscles - Innervation and Action: Anterior View of Left Eye
80A Arteries and Veins of Orbit and Eyelids: Superior View
83 Anterior and Posterior Chambers of Eye
88D External Ear and Tympanic Cavity: Coronal Oblique Section
89A Tympanic Cavity - Lateral Wall: Medial View
89B Tympanic Cavity - Medial Wall: Lateral View
115 Oculomotor Trochlear and Abducens Nerves: Schema
117 Facial Nerve: Schema
122 Hypoglossal Nerve: Schema
164 Suboccipital Triangle

Neck

[\[Back to regional\]](#)

21 Muscles of Facial Expression: Lateral View
22 Muscles of Neck: Lateral View
23 Muscles of Neck: Anterior View
24A Infrahyoid and Suprahyoid Muscles
24B Infrahyoid and Suprahyoid Muscles and their Action: Schema
25 Scalene and Prevertebral Muscles

26 Superficial Veins and Cutaneous Nerves of Neck
27A Cervical Plexus in Situ
28A Subclavian Artery: Right Anterior Dissection
29A Carotid Arteries - Parotid Fossa: Right Lateral Dissection
30A Fascial Layers of Neck: Cross Section
47A Floor of Mouth - Musculature: Lateral Slightly Inferior View
47B Floor of Mouth - Musculature: Anteroinferior View
47C Floor of Mouth - Musculature: Posterosuperior View
57 Pharynx: Sagittal Section
59 Muscles of Pharynx: Sagittal Section
61 Muscles of Pharynx: Partially Opened Posterior View
62 Muscles of Pharynx: Lateral View
63 Arteries of Oral and Pharyngeal Regions
64 Veins of Oral and Pharyngeal Regions
65 Nerves of Oral and Pharyngeal Regions
66 Lymph Vessels and Nodes of Oral and Pharyngeal Regions
67A Lymphatic Drainage of Pharynx: Posterior View
67B Lymphatic Drainage of Tongue: Lateral View
69 Thyroid Gland and Pharynx: Posterior View
70A Parathyroid Glands: Posterior View
70B Parathyroid Glands: Right Lateral View
72A Intrinsic Muscles of Larynx: Posterior View
72B Intrinsic Muscles of Larynx: Right Lateral View
72C Intrinsic Muscles of Larynx: Lateral Dissection
72D Intrinsic Muscles of Larynx: Superior View
73 Action of Intrinsic Muscles of Larynx
74A Nerves of Larynx: Right Lateral Views
120 Vagus Nerve: Schema
122 Hypoglossal Nerve: Schema
123 Cervical Plexus: Schema
160 Muscles of Back: Superficial Layers
161 Muscles of Back: Intermediate Layers
162 Muscles of Back: Deep Layers
164 Suboccipital Triangle
171A Left 1st and 2nd Ribs: Superior Views
173A Cervical Ribs and Related Anomalies 1
178 Posterior Thoracic Wall
186 Lungs in Situ: Anterior View
395B Right Clavicle - Muscle Attachments
399A Muscles of Shoulder: Posterior View

Throat [\[Back to regional\]](#)

167A Mammary Gland: Anterolateral Dissection
167B Mammary Gland: Sagittal Section
168 Arteries of Mammary Gland
171A Left 1st and 2nd Ribs: Superior Views
174 Anterior Thoracic Wall
175 Anterior Thoracic Wall [Continued]
176 Anterior Thoracic Wall: Internal View
177B Lateral Thoracic Wall
179 Intercostal Nerves and Arteries
180 Diaphragm: Thoracic Surface
183 Muscles of Respiration
230 Mediastinum: Cross Section
232 Anterior Abdominal Wall: Superficial Dissection
233 Anterior Abdominal Wall: Intermediate Dissection
234 Anterior Abdominal Wall: Deep Dissection
238 Arteries of Anterior Abdominal Wall
239 Veins of Anterior Abdominal Wall
240 Nerves of Anterior Abdominal Wall
241 Thoracoabdominal Nerves
395B Right Clavicle - Muscle Attachments
396B Humerus and Scapula: Anterior View - Muscle Attachments
404 Axilla [Dissection]: Anterior View

Abdomen [\[Back to regional\]](#)

160 Muscles of Back: Superficial Layers
161 Muscles of Back: Intermediate Layers
162 Muscles of Back: Deep Layers
165 Lumbar Region of Back: Cross Section
166 Typical Thoracic Spinal Nerve
183 Muscles of Respiration
232 Anterior Abdominal Wall: Superficial Dissection
233 Anterior Abdominal Wall: Intermediate Dissection
234 Anterior Abdominal Wall: Deep Dissection
235A Rectus Sheath: Cross Section Above Arcuate Line
235B Rectus Sheath: Cross Section Below Arcuate Line
236 Anterior Abdominal Wall: Internal View
237A Posterolateral Abdominal Wall
237B Posterolateral Abdominal Wall [Continued]
238 Arteries of Anterior Abdominal Wall
239 Veins of Anterior Abdominal Wall
240 Nerves of Anterior Abdominal Wall
241 Thoracoabdominal Nerves
242A Inguinal and Femoral Regions: Subcutaneous Fascia Removed
242B Inguinal and Femoral Regions: Cribriform Fascia Removed
243A Inguinal Region: Dissection - Anterior View
243B Inguinal Region: Dissection - Posterior [Internal] View
245 Inguinal Canal and Spermatic Cord
246 Posterior Abdominal Wall: Internal View

247 Arteries of Posterior Abdominal Wall
248 Veins of Posterior Abdominal Wall
250 Nerves of Posterior Abdominal Wall
257 Peritoneum of Posterior Abdominal Wall
331 Abdominal Wall and Viscera: Cross Section at T12
332 Abdominal Wall and Viscera: Cross Section Between L2 and L3
333A Abdominal Wall and Viscera [Above L4]: Midsagittal Section
333B Abdominal Wall and Viscera [Below L4]: Midsagittal Section
345 Endopelvic Fascia and Spaces of Female: Superior View

Back [\[Back to regional\]](#)

25 Scalene and Prevertebral Muscles
160 Muscles of Back: Superficial Layers
161 Muscles of Back: Intermediate Layers
162 Muscles of Back: Deep Layers
163 Nerves of Back
165 Lumbar Region of Back: Cross Section
166 Typical Thoracic Spinal Nerve
177A Deep Posterior Thoracic Wall
230 Mediastinum: Cross Section
237A Posterolateral Abdominal Wall
237B Posterolateral Abdominal Wall [Continued]
246 Posterior Abdominal Wall: Internal View
247 Arteries of Posterior Abdominal Wall
248 Veins of Posterior Abdominal Wall
250 Nerves of Posterior Abdominal Wall
316A Kidneys in Situ: Posterior View
328A Renal Fascia: Transverse Section through 2nd Lumbar Vertebra
331 Abdominal Wall and Viscera: Cross Section at T12
332 Abdominal Wall and Viscera: Cross Section Between L2 and L3
345 Endopelvic Fascia and Spaces of Female: Superior View
395B Right Clavicle - Muscle Attachments
396B Humerus and Scapula: Anterior View - Muscle Attachments
397B Humerus and Scapula: Posterior View - Muscle Attachments
450 Radial Nerve in Arm and Nerves of Posterior Shoulder
460 Bony Attachments of Muscles of Hip and Thigh: Anterior View
466A Psoas and Iliacus Muscles
466B Psoas and Iliacus Muscles: Action
468B Lumbar Plexus in Situ

Pelvis and perinum [\[Back to regional\]](#)

236 Anterior Abdominal Wall: Internal View
257 Peritoneum of Posterior Abdominal Wall
337A Pelvic Diaphragm of Female: Superior View
337B Pelvic Diaphragm of Female: Medial View
338A Pelvic Diaphragm of Female: Inferior View
338B Pelvic Diaphragm of Female: Lateral View
339 Pelvic Diaphragm of Male: Superior View - Viscera Removed
340 Pelvic Diaphragm of Male: Inferior View
346A Urinary Bladder - Orientation and Supports: Midsagittal Section
347A Urinary Bladder of Female: Frontal Section
347B Urinary Bladder of Male: Frontal Section
349 Uterus Vagina and Supporting Structures
355A Perineum of Female: Superficial Dissection
356A Perineum and Urogenital Diaphragm of Female
356B Perineum and Urogenital Diaphragm of Female: Deep Dissection
357A Urethra of Female: Frontal Section
359A Perineum and External Genitalia of Male: Deep Dissection
360A Penis
367A Rectum of Male in Situ
367B Rectum of Female in Situ
368 Ischiorectal Fossa
369 Rectum and Anal Canal
370A Anorectal Musculature: Anterior View
370B Anorectal Musculature: Frontal Section
371A External Anal Sphincter Muscle of Male: Perineal View
371B External Anal Sphincter Muscle of Female: Perineal View
372A Perineopelvic Spaces: Sagittal Section
372B Perineopelvic Spaces: Perineal View
373 Arteries of Rectum and Anal Canal
374 Veins of Rectum and Anal Canal
379A Arteries and Veins of Perineum: Female
380A Arteries and Veins of Perineum: Male
386A Nerves of Perineum: Male - Perineal View
386B Nerves of Perineum: Male - Inferior View
460 Bony Attachments of Muscles of Hip and Thigh: Anterior View
466A Psoas and Iliacus Muscles
466B Psoas and Iliacus Muscles: Action
468B Lumbar Plexus in Situ
469B Sacral and Coccygeal Plexuses in Situ
506A Femoral and Lateral Femoral Cutaneous Nerves

Upper limb(Shoulder and Arm) [\[Back to regional\]](#)

160 Muscles of Back: Superficial Layers
163 Nerves of Back
395B Right Clavicle - Muscle Attachments
396B Humerus and Scapula: Anterior View - Muscle Attachments
397B Humerus and Scapula: Posterior View - Muscle Attachments
398B Glenohumeral Joint: Anterior View - Supporting Muscles

398C Glenohumeral Joint [Opened]: Lateral View
398D Glenohumeral Joint: Coronal Section through Joint
399A Muscles of Shoulder: Posterior View
399B Muscles of Shoulder: Anterior View
400A Muscles of Rotator Cuff: Superior View
400B Muscles of Rotator Cuff: Anterior View
400C Muscles of Rotator Cuff: Posterior View
401A Scapulohumeral Dissection: Anterior View
401B Scapulohumeral Dissection: Posterior View
403A Pectoral Clavipectoral and Axillary Fasciae: Anterior View
403B Pectoral Clavipectoral and Axillary Fasciae: Section of Axilla
404 Axilla [Dissection]: Anterior View
406A Muscles of Arm: Anterior View - Superficial Layer
406B Muscles of Arm: Anterior View - Deep Layer
407A Muscles of Arm: Posterior View - Superficial Layer
407B Muscles of Arm: Posterior View - Deep Layer
408 Brachial Artery in Situ
410A Arm: Proximal Cross Section
410B Arm: Middle Cross Section
410C Arm: Distal Cross Section
424 Bony Attachments of Muscles of Forearm: Anterior View
425 Bony Attachments of Muscles of Forearm: Posterior View
446 Arteries and Nerves of Upper Limb
447 Musculocutaneous Nerve
450 Radial Nerve in Arm and Nerves of Posterior Shoulder

Upper limb(Forearm and Hand) [\[Back to regional\]](#)

414A Individual Muscles of Forearm: Rotators of Radius - Supination
414B Individual Muscles of Forearm: Rotators of Radius - Pronation
415A Individual Muscles of Forearm: Extensors of Wrist and Digits
415B Individual Muscles of Forearm [Continued]: Extensors of Wrist and Digits
416 Individual Muscles of Forearm: Flexors of Wrist
417A Individual Muscles of Forearm: Flexors of Digits
417B Individual Muscles of Forearm [Continued]: Flexors of Digits
418 Muscles of Forearm [Superficial Layer]: Posterior View
419 Muscles of Forearm [Deep Layer]: Posterior View
420 Muscles of Forearm [Superficial Layer]: Anterior View
421 Muscles of Forearm [Intermediate Layer]: Anterior View
422 Muscles of Forearm [Deep Layer]: Anterior View
423A Forearm: Proximal Cross Section
423B Forearm: Middle Cross Section
423C Forearm: Distal Cross Section
424 Bony Attachments of Muscles of Forearm: Anterior View
425 Bony Attachments of Muscles of Forearm: Posterior View
428A Ligaments of Wrist: Carpal Tunnel - Palmar View
432A Wrist and Hand: Superficial Palmar Dissections
432B Wrist and Hand: Superficial Palmar Dissections [Continued]
433A Wrist and Hand: Deeper Palmar Dissections
433B Wrist and Hand: Deeper Palmar Dissections [Continued]
434A Flexor Tendons Arteries and Nerves at Wrist: Palmar View
434B Flexor Tendons Arteries and Nerves at Wrist: Cross Section
435A Bursae Spaces and Tendon Sheaths of Hand: Palmar View
435B Bursae Spaces and Tendon Sheaths of Hand: Cross Section
436A Lumbrical Muscles and Bursae Spaces and Sheaths: Schema
436B Lumbrical Muscles: Schema
437A Flexor and Extensor Tendons in Fingers: Posterior [Dorsal] View
437B Flexor and Extensor Tendons in Fingers: Extended - Lateral View
437C Flexor and Extensor Tendons in Fingers: Flexed - Lateral View
438A Intrinsic Muscles of Hand: Anterior [Palmar] View
438B Intrinsic Muscles of Hand: Posterior [Dorsal] View
438C Intrinsic Muscles of Hand: Deep Anterior [Palmar] View
442 Wrist and Hand: Deep Dorsal Dissection
443A Extensor Tendons at Wrist: Posterior [Dorsal] View
443B Extensor Tendons at Wrist: Cross Section at Proximal Wrist
444A Fingers: Sagittal Section
446 Arteries and Nerves of Upper Limb
448 Median Nerve
449 Ulnar Nerve
451A Radial Nerve in Forearm: Posterior View

Lower limb(Hip and Thigh) [\[Back to regional\]](#)

460 Bony Attachments of Muscles of Hip and Thigh: Anterior View
461 Bony Attachments of Muscles of Hip and Thigh: Posterior View
462A Muscles of Thigh: Anterior View - Superficial Dissection
462B Muscles of Thigh: Anterior View - Deeper Dissection
463 Muscles of Thigh: Anterior View - Deepest Dissection
464 Muscles of Hip and Thigh: Lateral View
465A Muscles of Hip and Thigh: Posterior View - Superficial Dissection
465B Muscles of Hip and Thigh: Posterior View - Deeper Dissection
466B Psoas and Iliacus Muscles: Action
470A Arteries and Nerves of Thigh: Superficial Anterior View
470B Arteries and Nerves of Thigh: Deeper Anterior View
471 Arteries and Nerves of Thigh: Deepest Anterior View
472 Arteries and Nerves of Thigh: Posterior View
473 Nerves of Hip and Buttock
475A Thigh: Proximal Cross Section
475B Thigh: Middle Cross Section
475C Thigh: Distal Cross Section
476A Knee: Lateral View
476B Knee: Medial View

477A Knee in Extension: Anterior View
484A Bony Attachments of Muscles of Leg: Anterior View
484B Bony Attachments of Muscles of Leg: Posterior View
506A Femoral and Lateral Femoral Cutaneous Nerves
507A Obturator Nerve
508A Sciatic and Posterior Femoral Cutaneous Nerves

Lower limb(Leg and Foot) [\[Back to regional\]](#)

476A Knee: Lateral View
476B Knee: Medial View
477A Knee in Extension: Anterior View
484A Bony Attachments of Muscles of Leg: Anterior View
484B Bony Attachments of Muscles of Leg: Posterior View
485 Muscles of Leg [Superficial Dissection]: Posterior View
486 Muscles of Leg [Intermediate Dissection]: Posterior View
487 Muscles of Leg [Deep Dissection]: Posterior View
488 Muscles of Leg [Superficial Dissection]: Anterior View
489 Muscles of Leg [Deep Dissection]: Anterior View
490 Muscles of Leg: Lateral View
491A Leg: Cross Section - Fascial Compartments
491B Leg: Cross Section just above Middle of Left Leg
496A Ligaments and Tendons of Foot: Plantar View
497A Tendon Sheaths of Ankle: Lateral View
497B Tendon Sheaths of Ankle: Medial View
498 Muscles of Dorsum of Foot: Superficial Dissection
499 Dorsum of Foot: Deep Dissection
500 Sole of Foot: Superficial Dissection
501 Muscles of Sole of Foot: First Layer
502 Muscles of Sole of Foot: Second Layer
503 Muscles of Sole of Foot: Third Layer
504A Interosseous Muscles and Deep Arteries of Foot: Dorsal View
504B Interosseous Muscles and Deep Arteries of Foot: Plantar View
505A Interosseous Muscles of Foot: Dorsal View
505B Interosseous Muscles of Foot: Plantar View
508A Sciatic and Posterior Femoral Cutaneous Nerves
509A Tibial Nerve
509C Tibial Nerve: Cutaneous Innervation of Sole of Foot
510A Common Peroneal Nerve

Heart [\[Back to regional\]](#)

120 Vagus Nerve: Schema
194 Pulmonary Arteries and Veins
200 Heart in Situ
201 Heart: Anterior Exposure
202A Heart - Basal Surface: Posterior View
202B Heart - Diaphragmatic Surface: Posteroinferior View
203A Pericardial Sac - Heart Drawn Out: Left Lateral View
203B Pericardial Sac - Heart Removed: Anterior View
204A Coronary Arteries and Cardiac Veins: Sternocostal Surface
204B Coronary Arteries and Cardiac Veins: Diaphragmatic Surface
205A Coronary Arteries and Cardiac Veins: Variations 1
205B Coronary Arteries and Cardiac Veins: Variations 2
206A Right Coronary Artery: Arteriographic View 1
206B Right Coronary Artery: Arteriographic View 2
207A Left Coronary Artery: Arteriographic View 1
207B Left Coronary Artery: Arteriographic View 2
208A Opened Right Atrium: Right Lateral View
208B Opened Right Ventricle: Anterior View
209A Left Ventricle: Flap Opened in Posterolateral Wall
209B Left Atrium and Ventricle: Sectioned with Mitral Valve Cut Away
210A Valves of Heart in Diastole
210B Valves of Heart in Systole
211A Aortic Valve
211B Tricuspid [Right Atrioventricular] Valve
211C Mitral [Left Atrioventricular] Valve
212 Atria Ventricles and Interventricular Septum
213A Conduction System of Heart: Right Side
213B Conduction System of Heart: Left Side
214 Nerves of Heart
215 Innervation of Heart: Schema
217A Prenatal Circulation
217B Postnatal Circulation
218 Mediastinum: Right Lateral View
219 Mediastinum: Left Lateral View
230 Mediastinum: Cross Section
269A Topography of Liver: Anterior and Posterior Views

Artery-Head and Neck [\[Back to regional\]](#)

11A Temporomandibular Joint: Lateral and Medial Views
14A External Craniocervical Ligaments: Anterior and Posterior Views
14B External Craniocervical Ligaments: Right Lateral View
17A Superficial Arteries and Veins of Face and Scalp
17B Superficial Face: Sources of Arterial Supply
23 Muscles of Neck: Anterior View
24A Infrahyoid and Suprahyoid Muscles
27A Cervical Plexus in Situ
28A Subclavian Artery: Right Anterior Dissection
28B Subclavian Artery: Right Lateral Schematic View
29A Carotid Arteries - Parotid Fossa: Right Lateral Dissection

29B External Carotid Artery and Branches: Schema
30A Fascial Layers of Neck: Cross Section
31B External Nose [Skeleton] in Situ: Lateral View
35A Maxillary Artery: Orbitomaxillary Distribution
35B Maxillary Artery: Nasopalatine Distribution
36 Arteries of Nasal Cavity: Schematic Hinge
41A Mandibular Nerve [V3]: Lateral View
41B Mandibular Nerve [V3]: Medial View
46A Roof of Mouth - Hard and Soft Palates: Anterior View
47C Floor of Mouth - Musculature: Posterosuperior View
53B Tongue and Related Structures: Sagittal Section
54A Tongue and Mouth: Horizontal Section - Superior View
54B Tongue and Mouth: Frontal Section - Anterior View
55A Salivary Glands: Dissection
58B Fauces: Pharyngeal Mucosa Removed
63 Arteries of Oral and Pharyngeal Regions
66 Lymph Vessels and Nodes of Oral and Pharyngeal Regions
67A Lymphatic Drainage of Pharynx: Posterior View
67B Lymphatic Drainage of Tongue: Lateral View
68A Thyroid Gland: Anterior View
69 Thyroid Gland and Pharynx: Posterior View
70A Parathyroid Glands: Posterior View
70B Parathyroid Glands: Right Lateral View
74B Nerves of Larynx: Anterior View
78B Fascia of Orbit and Eyeball: Frontal Section and Entering Structures
80A Arteries and Veins of Orbit and Eyelids: Superior View
80B Arteries and Veins of Orbit and Eyelids: Anterior View
86A Intrinsic Arteries and Veins of Eye: Horizontal Section
86B Intrinsic Arteries and Veins of Eye: Ophthalmoscopic View
93A Cartilage of Auditory Tube at Base of Skull: Inferior View
93B Auditory Tube - Section through Cartilage: Tube Closed
93C Auditory Tube - Section through Cartilage: Tube Open
94A Meninges and Diploic Veins: Coronal Dissection
95A Meningeal Arteries
95B Meningeal Arteries [Continued]
98A Venous Sinuses of Dura Mater: Cranial Floor - Superior View
98B Cavernous Sinus: Coronal Section
119 Glossopharyngeal Nerve: Schema
120 Vagus Nerve: Schema
124 Autonomic Nerves in Neck
125 Autonomic Nerves in Head
130 Arteries to Brain and Meninges
131 Arteries to Brain: Schema
132A Arteries of Brain: Inferior View
132B Arteries of Brain [Continued]: Inferior View
133A Circle of Willis - Vessels Dissected Out: Inferior View
133B Circle of Willis - Vessels in Situ: Inferior View
134A Arteries of Brain: Frontal View
134B Arteries of Brain: Frontal Section
135A Arteries of Brain: Lateral View
135B Arteries of Brain: Medial View
136 Arteries of Posterior Cranial Fossa
141 Arteries and Veins of Hypothalamus and Hypophysis
164 Suboccipital Triangle
186 Lungs in Situ: Anterior View

Artery-Back and Spinal [\[Back to regional\]](#)

28B Subclavian Artery: Right Lateral Schematic View
157 Arteries of Spinal Cord: Schema
158A Arteries of Spinal Cord - Intrinsic Distribution: Thoracic Section
158B Arteries of Spinal Cord - Intrinsic Distribution: Schema
177B Lateral Thoracic Wall
178 Posterior Thoracic Wall
179 Intercostal Nerves and Arteries
180 Diaphragm: Thoracic Surface
247 Arteries of Posterior Abdominal Wall
401A Scapulohumeral Dissection: Anterior View
401B Scapulohumeral Dissection: Posterior View

Artery-Throax [\[Back to regional\]](#)

25 Scalene and Prevertebral Muscles
28B Subclavian Artery: Right Lateral Schematic View
168 Arteries of Mammary Gland
174 Anterior Thoracic Wall
175 Anterior Thoracic Wall [Continued]
176 Anterior Thoracic Wall: Internal View
177B Lateral Thoracic Wall
179 Intercostal Nerves and Arteries
180 Diaphragm: Thoracic Surface
186 Lungs in Situ: Anterior View
193 Intrapulmonary Blood Circulation: Schema
194 Pulmonary Arteries and Veins
195 Main Bronchi With Pulmonary Arteries and Veins in Situ
196A Bronchial Arteries
196B Bronchial Arteries: Variations
200 Heart in Situ
201 Heart: Anterior Exposure
217A Prenatal Circulation
217B Postnatal Circulation
218 Mediastinum: Right Lateral View

219 Mediastinum: Left Lateral View
220 Esophagus in Situ
225A Arteries of Esophagus
230 Mediastinum: Cross Section
234 Anterior Abdominal Wall: Deep Dissection
238 Arteries of Anterior Abdominal Wall
402A Axillary Artery and Anastomoses Around Scapula: Anterior View
404 Axilla [Dissection]: Anterior View

Artery-abdomen [\[Back to regional\]](#)

165 Lumbar Region of Back: Cross Section
181 Diaphragm: Abdominal Surface
217A Prenatal Circulation
217B Postnatal Circulation
225B Arteries of Esophagus: Variations
234 Anterior Abdominal Wall: Deep Dissection
236 Anterior Abdominal Wall: Internal View
238 Arteries of Anterior Abdominal Wall
243B Inguinal Region: Dissection - Posterior [Internal] View
244A Femoral Sheath and Inguinal Canal
244B Femoral Sheath and Inguinal Canal [Deep]
245 Inguinal Canal and Spermatic Cord
247 Arteries of Posterior Abdominal Wall
248 Veins of Posterior Abdominal Wall
253A Mesenteric Relations of Intestines: Transverse Colon Elevated
253B Mesenteric Relations of Intestines: Suspensory Muscle of Duodenum
256 Omental Bursa: Cross Section
257 Peritoneum of Posterior Abdominal Wall
261 Duodenum in Situ
263A Mucosa and Musculature of Jejunum
263B Mucosa and Musculature of Ileum
264A Ileocecal Region
264B Ileocecal Region: Retrocecal Recess Exposed
282 Arteries of Stomach Liver and Spleen
283 Arteries of Stomach Duodenum Pancreas and Spleen
284 Arteries of Liver Pancreas Duodenum and Spleen
285A Arteries of Duodenum and Head of Pancreas: Reflected to Left
285B Arteries of Duodenum and Head of Pancreas: Posterior View
286 Arteries of Small Intestine
287 Arteries of Large Intestine
288A Variations in Celiac Trunk
288B Variations in Celiac Trunk [Continued]
289A Variations in Hepatic Arteries
289B Variations in Hepatic Arteries [Continued]
290A Variations in Cystic Artery 1
290B Variations in Cystic Artery 2
290C Variations in Cystic Artery 3
290D Variations in Cystic Artery 4
290E Variations in Cystic Artery 5
291A Variations in Colic Arteries 1
291B Variations in Colic Arteries 2
291C Variations in Colic Arteries 3
291D Variations in Colic Arteries 4
291E Variations in Colic Arteries 5
291F Variations in Colic Arteries 6
292A Variations in Colic Arteries 7
292B Variations in Colic Arteries 8
292C Variations in Colic Arteries 9
292D Variations in Colic Arteries 10
292E Variations in Colic Arteries 11
292F Variations in Colic Arteries 12
293A Variations in Cecal and Appendicular Arteries 1
293B Variations in Cecal and Appendicular Arteries 2
293C Variations in Cecal and Appendicular Arteries 3
293D Variations in Cecal and Appendicular Arteries 4
293E Variations in Cecal and Appendicular Arteries 5
293F Variations in Cecal and Appendicular Arteries 6
293G Variations in Cecal and Appendicular Arteries 7
293H Variations in Cecal and Appendicular Arteries 8
301B Lymph Vessels and Nodes of Large Intestine [Continued]
304 Autonomic Nerves and Ganglia of Abdomen
315A Kidneys in Situ: Anterior View
318 Renal Artery and Vein in Situ
319A Intrarenal Arteries: Frontal Section of Left Kidney - Anterior View
320A Variations in Renal Artery
323A Ureters in Male: Anterior View
324 Arteries of Ureters and Urinary Bladder
328A Renal Fascia: Transverse Section through 2nd Lumbar Vertebra
329A Arteries and Veins of Right Suprarenal Gland in Situ
329B Arteries and Veins of Left Suprarenal Gland in Situ
330A Nerves of Suprarenal Glands: Dissection
331 Abdominal Wall and Viscera: Cross Section at T12
332 Abdominal Wall and Viscera: Cross Section Between L2 and L3
333A Abdominal Wall and Viscera [Above L4]: Midsagittal Section
333B Abdominal Wall and Viscera [Below L4]: Midsagittal Section
373 Arteries of Rectum and Anal Canal

Artery-Pelvis and perinum

[\[Back to regional\]](#)

242A Inguinal and Femoral Regions: Subcutaneous Fascia Removed
247 Arteries of Posterior Abdominal Wall
343 Pelvic Contents of Female: Superior View
344 Pelvic Contents of Male: Superior View
345 Endopelvic Fascia and Spaces of Female: Superior View
348A Pelvic Viscera of Female: Superior View - Peritoneum Intact
348B Pelvic Viscera of Female: Superior View - Peritoneum Removed
359B Section through Body of Penis
361A Urogenital Diaphragm of Male: Dissection
361B Urogenital Diaphragm of Male: Deep Dissection
368 Ischiorectal Fossa
373 Arteries of Rectum and Anal Canal
375 Arteries and Veins of Pelvic Organs: Female
376 Arteries and Veins of Testis
377A Arteries and Veins of Pelvis: Female - Sagittal Section
377B Arteries and Veins of Pelvis: Female - Right Paramedian Section
378A Arteries and Veins of Pelvis: Male - Left Paramedian Section
378B Arterial Supply of Prostate
379A Arteries and Veins of Perineum: Female
379B Arteries and Veins of Uterus
380A Arteries and Veins of Perineum: Male
380B Arteries and Veins of Perineum [Continued]: Male
381 Lymph Vessels and Nodes of Pelvis and Genitalia: Female
382 Lymph Vessels and Nodes of Perineum: Female
383A Lymph Vessels and Nodes of Pelvis and Genitalia: Male
383B Lymphatic Drainage from Prostate
384 Nerves of External Genitalia: Male
385 Nerves of Pelvic Viscera: Male
387A Nerves of Pelvic Viscera: Female - Sagittal Section
387B Nerves of Pelvic Viscera: Female - Superior View
389A Neuropathways in Parturition
389B Neuropathways in Parturition: Pelvic Area Enlarged
390 Innervation of Female Reproductive Organs: Schema
391 Innervation of Male Reproductive Organs: Schema
392 Innervation of Urinary Bladder and Lower Ureter: Schema
469B Sacral and Coccygeal Plexuses in Situ

Artery-Upper limb [\[Back to regional\]](#)

401A Scapulohumeral Dissection: Anterior View
401B Scapulohumeral Dissection: Posterior View
402A Axillary Artery and Anastomoses Around Scapula: Anterior View
402B Axillary Artery and Anastomoses Around Scapula: Posterior View
403A Pectoral Clavipectoral and Axillary Fasciae: Anterior View
403B Pectoral Clavipectoral and Axillary Fasciae: Section of Axilla
404 Axilla [Dissection]: Anterior View
406A Muscles of Arm: Anterior View - Superficial Layer
407A Muscles of Arm: Posterior View - Superficial Layer
407B Muscles of Arm: Posterior View - Deep Layer
408 Brachial Artery in Situ
409 Brachial Artery and Anastomoses Around Elbow
410A Arm: Proximal Cross Section
410B Arm: Middle Cross Section
410C Arm: Distal Cross Section
419 Muscles of Forearm [Deep Layer]: Posterior View
420 Muscles of Forearm [Superficial Layer]: Anterior View
421 Muscles of Forearm [Intermediate Layer]: Anterior View
422 Muscles of Forearm [Deep Layer]: Anterior View
423A Forearm: Proximal Cross Section
423B Forearm: Middle Cross Section
423C Forearm: Distal Cross Section
428A Ligaments of Wrist: Carpal Tunnel - Palmar View
432A Wrist and Hand: Superficial Palmar Dissections
432B Wrist and Hand: Superficial Palmar Dissections [Continued]
433A Wrist and Hand: Deeper Palmar Dissections
433B Wrist and Hand: Deeper Palmar Dissections [Continued]
434A Flexor Tendons Arteries and Nerves at Wrist: Palmar View
434B Flexor Tendons Arteries and Nerves at Wrist: Cross Section
438A Intrinsic Muscles of Hand: Anterior [Palmar] View
439A Arteries and Nerves of Hand: Palmar View
439B Arteries and Nerves of Hand: Deep Palmar View
440 Wrist and Hand: Superficial Radial Dissection
442 Wrist and Hand: Deep Dorsal Dissection
443A Extensor Tendons at Wrist: Posterior [Dorsal] View
444B Fingers: Cross Section through Distal Phalanx
444C Fingers: Arteries and Nerves

Artery-Lower limb [\[Back to regional\]](#)

463 Muscles of Thigh: Anterior View - Deepest Dissection
465A Muscles of Hip and Thigh: Posterior View - Superficial Dissection
465B Muscles of Hip and Thigh: Posterior View - Deeper Dissection
470A Arteries and Nerves of Thigh: Superficial Anterior View
470B Arteries and Nerves of Thigh: Deeper Anterior View
471 Arteries and Nerves of Thigh: Deepest Anterior View
472 Arteries and Nerves of Thigh: Posterior View
474A Arteries of Femoral Head and Neck: Anterior and Posterior Views
474B Arteries of Femoral Head and Neck: Coronal Section
474C Arteries of Femoral Head and Neck: Femur of Child - Anterior View
474D Arteries of Femoral Head and Neck: Anterior View in Situ
475A Thigh: Proximal Cross Section
475B Thigh: Middle Cross Section
475C Thigh: Distal Cross Section
481 Arteries of Thigh and Knee: Schema
485 Muscles of Leg [Superficial Dissection]: Posterior View
486 Muscles of Leg [Intermediate Dissection]: Posterior View
487 Muscles of Leg [Deep Dissection]: Posterior View
488 Muscles of Leg [Superficial Dissection]: Anterior View
489 Muscles of Leg [Deep Dissection]: Anterior View
491B Leg: Cross Section just above Middle of Left Leg
498 Muscles of Dorsum of Foot: Superficial Dissection
499 Dorsum of Foot: Deep Dissection
500 Sole of Foot: Superficial Dissection
501 Muscles of Sole of Foot: First Layer
502 Muscles of Sole of Foot: Second Layer
503 Muscles of Sole of Foot: Third Layer
504A Interosseous Muscles and Deep Arteries of Foot: Dorsal View
504B Interosseous Muscles and Deep Arteries of Foot: Plantar View
514C Lymph Vessels and Nodes of Lower Limb: Inguinal Region

Vein-Head and Neck [\[Back to regional\]](#)

23 Muscles of Neck: Anterior View
24A Infrahyoid and Suprahyoid Muscles
26 Superficial Veins and Cutaneous Nerves of Neck
27A Cervical Plexus in Situ
28A Subclavian Artery: Right Anterior Dissection
29A Carotid Arteries - Parotid Fossa: Right Lateral Dissection
30A Fascial Layers of Neck: Cross Section
53B Tongue and Related Structures: Sagittal Section
54A Tongue and Mouth: Horizontal Section - Superior View
54B Tongue and Mouth: Frontal Section - Anterior View
55A Salivary Glands: Dissection
58B Fauces: Pharyngeal Mucosa Removed
64 Veins of Oral and Pharyngeal Regions
66 Lymph Vessels and Nodes of Oral and Pharyngeal Regions
67A Lymphatic Drainage of Pharynx: Posterior View
67B Lymphatic Drainage of Tongue: Lateral View
68A Thyroid Gland: Anterior View
69 Thyroid Gland and Pharynx: Posterior View
70B Parathyroid Glands: Right Lateral View
78B Fascia of Orbit and Eyeball: Frontal Section and Entering Structures
80C Arteries and Veins of Orbit and Eyelids: Lateral View
86A Intrinsic Arteries and Veins of Eye: Horizontal Section
86B Intrinsic Arteries and Veins of Eye: Ophthalmoscopic View
92B Orientation of Labyrinth in Skull: Lateral Projection
94A Meninges and Diploic Veins: Coronal Dissection
94B Diploic and Emissary Veins of Skull
96A Meninges and Superficial Cerebral Veins: Frontal Section
96B Meninges and Superficial Cerebral Veins: Dura Mater Lifted
97 Venous Sinuses of Dura Mater: Sagittal Section
98A Venous Sinuses of Dura Mater: Cranial Floor - Superior View
98B Cavernous Sinus: Coronal Section
103 Circulation of Cerebrospinal Fluid
137 Veins of Posterior Cranial Fossa
138A Deep Veins of Brain - Dissection: Superior View
138B Deep Veins of Brain - Dissection: Inferior View
139 Subependymal Veins of Brain
141 Arteries and Veins of Hypothalamus and Hypophysis
174 Anterior Thoracic Wall
186 Lungs in Situ: Anterior View

Vein-Back and Spinal [\[Back to regional\]](#)

159A Veins of Spinal Cord: Sagittal Section [without Cord]
159B Veins of Spinal Cord: Superior View [without Cord]
159C Veins of Spinal Cord: Superior View [Magnified with Cord]
177B Lateral Thoracic Wall
248 Veins of Posterior Abdominal Wall

Vein-Throax [\[Back to regional\]](#)

25 Scalene and Prevertebral Muscles
176 Anterior Thoracic Wall: Internal View
177B Lateral Thoracic Wall
180 Diaphragm: Thoracic Surface

186 Lungs in Situ: Anterior View
194 Pulmonary Arteries and Veins
195 Main Bronchi With Pulmonary Arteries and Veins in Situ
196C Bronchial Veins
200 Heart in Situ
201 Heart: Anterior Exposure
217A Prenatal Circulation
217B Postnatal Circulation
218 Mediastinum: Right Lateral View
219 Mediastinum: Left Lateral View
226A Veins of Esophagus
226B Veins of Esophagus: Submucous Venous Plexus
230 Mediastinum: Cross Section
234 Anterior Abdominal Wall: Deep Dissection
239 Veins of Anterior Abdominal Wall

Vein-abdomen [\[Back to regional\]](#)

165 Lumbar Region of Back: Cross Section
217A Prenatal Circulation
217B Postnatal Circulation
226A Veins of Esophagus
234 Anterior Abdominal Wall: Deep Dissection
236 Anterior Abdominal Wall: Internal View
239 Veins of Anterior Abdominal Wall
243B Inguinal Region: Dissection - Posterior [Internal] View
244A Femoral Sheath and Inguinal Canal
244B Femoral Sheath and Inguinal Canal [Deep]
245 Inguinal Canal and Spermatic Cord
248 Veins of Posterior Abdominal Wall
253A Mesenteric Relations of Intestines: Transverse Colon Elevated
256 Omental Bursa: Cross Section
257 Peritoneum of Posterior Abdominal Wall
273A Intrahepatic Vascular and Duct Systems: Schema
274 Liver Structure: Schema
275A Intrahepatic Biliary System: Schema
279A Pancreas in Situ
294A Veins of Stomach Duodenum and Pancreas
294B Veins of Stomach Duodenum and Pancreas [Continued]
295A Veins of Small Intestine: Transverse Colon Cut
295B Veins of Small Intestine: Transverse Colon Elevated
296 Veins of Small and Large Intestines
297 Portal Vein Tributaries: Portacaval Anastomoses
298A Typical Arrangement of Portal Vein
298B Variations of Portal Vein
298C Variations of Portal Vein [Continued]
298D Anomalies of Portal Vein
315A Kidneys in Situ: Anterior View
318 Renal Artery and Vein in Situ
320B Variations in Renal Vein
320C Variations in Renal Vein [Continued]
323A Ureters in Male: Anterior View
324 Arteries of Ureters and Urinary Bladder
328A Renal Fascia: Transverse Section through 2nd Lumbar Vertebra
331 Abdominal Wall and Viscera: Cross Section at T12
332 Abdominal Wall and Viscera: Cross Section Between L2 and L3
333A Abdominal Wall and Viscera [Above L4]: Midsagittal Section
333B Abdominal Wall and Viscera [Below L4]: Midsagittal Section

Vein-Pelvis and perinum [\[Back to regional\]](#)

232 Anterior Abdominal Wall: Superficial Dissection
233 Anterior Abdominal Wall: Intermediate Dissection
242A Inguinal and Femoral Regions: Subcutaneous Fascia Removed
242B Inguinal and Femoral Regions: Cribriform Fascia Removed
248 Veins of Posterior Abdominal Wall
343 Pelvic Contents of Female: Superior View
344 Pelvic Contents of Male: Superior View
345 Endopelvic Fascia and Spaces of Female: Superior View
348A Pelvic Viscera of Female: Superior View - Peritoneum Intact
348B Pelvic Viscera of Female: Superior View - Peritoneum Removed
359B Section through Body of Penis
365A Scrotum and Contents: Anterior View
368 Ischiorectal Fossa
369 Rectum and Anal Canal
370B Anorectal Musculature: Frontal Section
374 Veins of Rectum and Anal Canal
375 Arteries and Veins of Pelvic Organs: Female
376 Arteries and Veins of Testis
377A Arteries and Veins of Pelvis: Female - Sagittal Section
377B Arteries and Veins of Pelvis: Female - Right Paramedian Section
378A Arteries and Veins of Pelvis: Male - Left Paramedian Section
379B Arteries and Veins of Uterus
381 Lymph Vessels and Nodes of Pelvis and Genitalia: Female
382 Lymph Vessels and Nodes of Perineum: Female
383A Lymph Vessels and Nodes of Pelvis and Genitalia: Male
383B Lymphatic Drainage from Prostate
384 Nerves of External Genitalia: Male
387A Nerves of Pelvic Viscera: Female - Sagittal Section
387B Nerves of Pelvic Viscera: Female - Superior View

Vein-Upper limb [\[Back to regional\]](#)

169 Lymph Vessels and Nodes of Mammary Gland
174 Anterior Thoracic Wall
175 Anterior Thoracic Wall [Continued]
399B Muscles of Shoulder: Anterior View
403A Pectoral Clavipectoral and Axillary Fasciae: Anterior View
403B Pectoral Clavipectoral and Axillary Fasciae: Section of Axilla
404 Axilla [Dissection]: Anterior View
410A Arm: Proximal Cross Section
410B Arm: Middle Cross Section
410C Arm: Distal Cross Section
423A Forearm: Proximal Cross Section
423B Forearm: Middle Cross Section
423C Forearm: Distal Cross Section
441 Wrist and Hand: Superficial Dorsal Dissection
452A Superficial Nerves and Veins of Shoulder and Arm: Anterior View
452B Superficial Nerves and Veins of Shoulder and Arm: Posterior View
453A Cutaneous Nerves and Superficial Veins of Forearm: Anterior (Palmar) View
453B Cutaneous Nerves and Superficial Veins of Forearm: Posterior (Dorsal) View

Vein-Lower limb [\[Back to regional\]](#)

465A Muscles of Hip and Thigh: Posterior View - Superficial Dissection
465B Muscles of Hip and Thigh: Posterior View - Deeper Dissection
470A Arteries and Nerves of Thigh: Superficial Anterior View
470B Arteries and Nerves of Thigh: Deeper Anterior View
471 Arteries and Nerves of Thigh: Deepest Anterior View
472 Arteries and Nerves of Thigh: Posterior View
475A Thigh: Proximal Cross Section
475B Thigh: Middle Cross Section
475C Thigh: Distal Cross Section
485 Muscles of Leg [Superficial Dissection]: Posterior View
486 Muscles of Leg [Intermediate Dissection]: Posterior View
491B Leg: Cross Section just above Middle of Left Leg
512 Superficial Nerves and Veins of Lower Limb: Anterior View
513 Superficial Nerves and Veins of Lower Limb: Posterior View
514A Lymph Vessels and Nodes of Lower Limb: Anterior View
514B Lymph Vessels and Nodes of Lower Limb: Posterior View
514C Lymph Vessels and Nodes of Lower Limb: Inguinal Region

Central: Brain [\[Back to regional\]](#)

38B Nerves of Nasal Cavity: Lateral Nasal Wall
38C Nerves of Nasal Cavity: Nasal Septum
42A Paranasal Sinuses: Coronal Section
42B Paranasal Sinuses: Horizontal Section
92B Orientation of Labyrinth in Skull: Lateral Projection
94A Meninges and Diploic Veins: Coronal Dissection
96A Meninges and Superficial Cerebral Veins: Frontal Section
96B Meninges and Superficial Cerebral Veins: Dura Mater Lifted
99A Cerebrum: Lateral View
99B Cerebrum - Lobes: Lateral View
99C Cerebrum - Insula [Island of Reil]: Lateral View
100A Cerebrum - Brain in Situ: Sagittal Section - Medial View
100B Cerebrum - Hemisphere with Brainstem Excised: Medial View
101 Cerebrum: Inferior View
102A Ventricles of Brain: Left Lateral Phantom View
102B Ventricles of Brain: Coronal Section - Posterior View
103 Circulation of Cerebrospinal Fluid
104A Basal Ganglia: Horizontal Sections through Cerebrum
104B Basal Ganglia - Schema: Left Lateral View
105A Thalamus
105B Thalamus: Schematic Section
105C Thalamus: Schematic Representation of Thalamus
106A Hippocampus and Fornix: Superior Dissection
106B Hippocampus and Fornix: Schema of Fornix
106C Hippocampus and Fornix: Coronal Section - Posterior View
107A Cerebellum: Superior Surface
107B Cerebellum: Inferior Surface
107C Cerebellum: Section in Plane of Superior Cerebellar Peduncle
108A Brainstem: Posterolateral View
108B Brainstem: Anteroinferior View
109A Fourth Ventricle and Cerebellum: Posterior View
109B Fourth Ventricle and Cerebellum: Median Sagittal Section
110 Cranial Nerve Nuclei in Brainstem: Schema - Posterior Phantom View
111 Cranial Nerve Nuclei in Brainstem: Schema - Medial Dissection
112 Cranial Nerves [Motor and Sensory Distribution]: Schema
113A Olfactory Nerve: Schema
113B Olfactory Nerve - Olfactory Bulb Cells: Schema
114A Optic Nerve [Visual Pathway]: Schema
114B Optic Nerve [Visual Pathway] - Structure of Retina: Schema
115 Oculomotor Trochlear and Abducens Nerves: Schema
116 Trigeminal Nerve: Schema
117 Facial Nerve: Schema
118 Vestibulocochlear Nerve: Schema
119 Glossopharyngeal Nerve: Schema
120 Vagus Nerve: Schema
121 Accessory Nerve: Schema
122 Hypoglossal Nerve: Schema
126 Ciliary Ganglion: Schema
127 Pterygopalatine and Submandibular Ganglia: Schema
128 Otic Ganglion: Schema

129 Taste Pathways: Schema
131 Arteries to Brain: Schema
132A Arteries of Brain: Inferior View
132B Arteries of Brain [Continued]: Inferior View
133A Circle of Willis - Vessels Dissected Out: Inferior View
133B Circle of Willis - Vessels in Situ: Inferior View
134A Arteries of Brain: Frontal View
134B Arteries of Brain: Frontal Section
135A Arteries of Brain: Lateral View
135B Arteries of Brain: Medial View
136 Arteries of Posterior Cranial Fossa
137 Veins of Posterior Cranial Fossa
138A Deep Veins of Brain - Dissection: Superior View
138B Deep Veins of Brain - Dissection: Inferior View
139 Subependymal Veins of Brain
140A Hypothalamus - Principal Nuclei
140B Adenohypophysis and Neurohypophysis
141 Arteries and Veins of Hypothalamus and Hypophysis

Central: Spinal [\[Back to regional\]](#)

121 Accessory Nerve: Schema
126 Ciliary Ganglion: Schema
127 Pterygopalatine and Submandibular Ganglia: Schema
128 Otic Ganglion: Schema
148 Spinal Cord in Situ
149A Relation of Spinal Nerve Roots to Vertebrae
149B Relation of Spinal Nerve Roots to Vertebrae: Lateral Protrusion
149C Relation of Spinal Nerve Roots to Vertebrae: Medial Protrusion
151A Spinal Cord Cross Sections
151B Spinal Cord Cross Sections: Fiber Tracts
154 Cholinergic and Adrenergic Synapses: Schema
155A Spinal Membranes and Nerve Roots: Posterior View
155B Spinal Membranes and Nerve Roots: Anterior View
156A Spinal Nerve Origin: Section through Thoracic Vertebra
156B Spinal Nerve Origin: Section through Lumbar Vertebra
157 Arteries of Spinal Cord: Schema
158A Arteries of Spinal Cord - Intrinsic Distribution: Thoracic Section
158B Arteries of Spinal Cord - Intrinsic Distribution: Schema
159A Veins of Spinal Cord: Sagittal Section [without Cord]
159B Veins of Spinal Cord: Superior View [without Cord]
159C Veins of Spinal Cord: Superior View [Magnified with Cord]
165 Lumbar Region of Back: Cross Section

Peripheral: CN. And branch [\[Back to regional\]](#)

11A Temporomandibular Joint: Lateral and Medial Views
18A Cutaneous Nerves of Head and Neck
18B Dermatomes of Head and Neck
19A Facial Nerve Branches and Parotid Gland in Situ
19B Facial Nerve Branches and Parotid Gland: Sectioned
27B Cervical Plexus: Schema
28A Subclavian Artery: Right Anterior Dissection
29A Carotid Arteries - Parotid Fossa: Right Lateral Dissection
30A Fascial Layers of Neck: Cross Section
31B External Nose [Skeleton] in Situ: Lateral View
37 Nerves of Nasal Cavity: Schematic Hinge
38B Nerves of Nasal Cavity: Lateral Nasal Wall
39 Autonomic Innervation of Nasal Cavity
40 Ophthalmic and Maxillary Nerves
41A Mandibular Nerve [V3]: Lateral View
41B Mandibular Nerve [V3]: Medial View
46A Roof of Mouth - Hard and Soft Palates: Anterior View
47C Floor of Mouth - Musculature: Posterosuperior View
53B Tongue and Related Structures: Sagittal Section
54A Tongue and Mouth: Horizontal Section - Superior View
54B Tongue and Mouth: Frontal Section - Anterior View
55A Salivary Glands: Dissection
56A Afferent Innervation of Mouth and Pharynx: Anterior View
56B Afferent Innervation of Mouth and Pharynx: Lateral View
56C Afferent Innervation of Mouth and Pharynx: Dorsum of Tongue
58B Fauces: Pharyngeal Mucosa Removed
63 Arteries of Oral and Pharyngeal Regions
65 Nerves of Oral and Pharyngeal Regions
68A Thyroid Gland: Anterior View
69 Thyroid Gland and Pharynx: Posterior View
70A Parathyroid Glands: Posterior View
70B Parathyroid Glands: Right Lateral View
74A Nerves of Larynx: Right Lateral Views
74B Nerves of Larynx: Anterior View
78B Fascia of Orbit and Eyeball: Frontal Section and Entering Structures
81A Nerves of Orbit: Superior View
81B Nerves of Orbit - Muscles Partially Cut Away: Superior View
87 Pathway of Sound Reception
88C Tympanic Cavity: Viewed from External Acoustic Meatus
89A Tympanic Cavity - Lateral Wall: Medial View
89B Tympanic Cavity - Medial Wall: Lateral View
90C Right Membranous Labyrinth with Nerves: Posteromedial View
91B Osseous and Membranous Labyrinths: Section Through Turn of Cochlea
92A Orientation of Labyrinth in Skull: Superior Projection
92B Orientation of Labyrinth in Skull: Lateral Projection
93B Auditory Tube - Section through Cartilage: Tube Closed

93C Auditory Tube - Section through Cartilage: Tube Open
98A Venous Sinuses of Dura Mater: Cranial Floor - Superior View
98B Cavernous Sinus: Coronal Section
100B Cerebrum - Hemisphere with Brainstem Excised: Medial View
101 Cerebrum: Inferior View
108A Brainstem: Posterolateral View
108B Brainstem: Anterioinferior View
110 Cranial Nerve Nuclei in Brainstem: Schema - Posterior Phantom View
111 Cranial Nerve Nuclei in Brainstem: Schema - Medial Dissection
112 Cranial Nerves [Motor and Sensory Distribution]: Schema
113A Olfactory Nerve: Schema
113B Olfactory Nerve - Olfactory Bulb Cells: Schema
114A Optic Nerve [Visual Pathway]: Schema
114B Optic Nerve [Visual Pathway] - Structure of Retina: Schema
115 Oculomotor, Trochlear and Abducens Nerves: Schema
116 Trigeminal Nerve: Schema
117 Facial Nerve: Schema
118 Vestibulocochlear Nerve: Schema
119 Glossopharyngeal Nerve: Schema
120 Vagus Nerve: Schema
123 Cervical Plexus: Schema
136 Arteries of Posterior Cranial Fossa
163 Nerves of Back
182A Phrenic Nerve in Situ
199 Innervation of Tracheobronchial Tree: Schema
214 Nerves of Heart
220 Esophagus in Situ

Peripheral: Spinal nerve/plexuses [\[Back to regional\]](#)

25 Scalene and Prevertebral Muscles
27A Cervical Plexus in Situ
27B Cervical Plexus: Schema
28A Subclavian Artery: Right Anterior Dissection
30A Fascial Layers of Neck: Cross Section
63 Arteries of Oral and Pharyngeal Regions
65 Nerves of Oral and Pharyngeal Regions
68A Thyroid Gland: Anterior View
123 Cervical Plexus: Schema
147A Vertebral Ligaments of Lumbosacral Region: Left Lateral View
148 Spinal Cord in Situ
149A Relation of Spinal Nerve Roots to Vertebrae
149B Relation of Spinal Nerve Roots to Vertebrae: Lateral Protrusion
149C Relation of Spinal Nerve Roots to Vertebrae: Medial Protrusion
155A Spinal Membranes and Nerve Roots: Posterior View
155B Spinal Membranes and Nerve Roots: Anterior View
156A Spinal Nerve Origin: Section through Thoracic Vertebra
156B Spinal Nerve Origin: Section through Lumbar Vertebra
163 Nerves of Back
164 Suboccipital Triangle
166 Typical Thoracic Spinal Nerve
168 Arteries of Mammary Gland
173B Cervical Ribs and Related Anomalies 2
173C Cervical Ribs and Related Anomalies 3
174 Anterior Thoracic Wall
175 Anterior Thoracic Wall [Continued]
176 Anterior Thoracic Wall: Internal View
178 Posterior Thoracic Wall
179 Intercostal Nerves and Arteries
181 Diaphragm: Abdominal Surface
182A Phrenic Nerve in Situ
182B Phrenic Nerve: Schema
195 Main Bronchi With Pulmonary Arteries and Veins in Situ
200 Heart in Situ
214 Nerves of Heart
215 Innervation of Heart: Schema
228A Nerves of Esophagus: Anterior View
228B Nerves of Esophagus: Posterior View
237A Posterolateral Abdominal Wall
237B Posterolateral Abdominal Wall [Continued]
240 Nerves of Anterior Abdominal Wall
241 Thoracoabdominal Nerves
244B Femoral Sheath and Inguinal Canal [Deep]
250 Nerves of Posterior Abdominal Wall
305 Nerves of Stomach and Duodenum
306A Nerves of Stomach and Duodenum: View with Stomach Reflected
306B Nerves of Stomach and Duodenum: Hiatal Region
307 Innervation of Stomach and Duodenum: Schema
308 Nerves of Small Intestine
309 Nerves of Large Intestine
310A Innervation of Small and Large Intestines: Left Side of Schema
310B Innervation of Small and Large Intestines: Right Side of Schema
313A Common Areas of Referred Pain in Biliary Disease
313B Innervation of Liver and Biliary Tract: Schema
313C Innervation of Liver: Nerve Fibers around Fine Branch of Hepatic Artery
314A Common Areas of Pancreatic Pain
314B Innervation of Pancreas: Schema
314C Schema of Intrinsic Nerve Supply of Pancreas
315A Kidneys in Situ: Anterior View
326 Nerves of Kidneys Ureters and Urinary Bladder
327 Innervation of Kidneys and Upper Ureters: Schema
330A Nerves of Suprarenal Glands: Dissection
330B Nerves of Suprarenal Glands: Schema

343 Pelvic Contents of Female: Superior View
344 Pelvic Contents of Male: Superior View
361A Urogenital Diaphragm of Male: Dissection
361B Urogenital Diaphragm of Male: Deep Dissection
368 Ischiorectal Fossa
384 Nerves of External Genitalia: Male
385 Nerves of Pelvic Viscera: Male
386A Nerves of Perineum: Male - Perineal View
386B Nerves of Perineum: Male - Inferior View
387A Nerves of Pelvic Viscera: Female - Sagittal Section
387B Nerves of Pelvic Viscera: Female - Superior View
388A Nerves of Perineum and External Genitalia: Female
388B Block Anesthesia of Perineal Area: Primarily Pudendal Nerve
389A Neuropathways in Parturition
389B Neuropathways in Parturition: Pelvic Area Enlarged
390 Innervation of Female Reproductive Organs: Schema
391 Innervation of Male Reproductive Organs: Schema
392 Innervation of Urinary Bladder and Lower Ureter: Schema
403B Pectoral Claviopectoral and Axillary Fasciae: Section of Axilla
404 Axilla [Dissection]: Anterior View
405 Brachial Plexus: Schema
408 Brachial Artery in Situ
466A Psoas and Iliacus Muscles
467 Lumbosacral and Coccygeal Plexuses
468A Lumbar Plexus: Schema
468B Lumbar Plexus in Situ
469A Sacral and Coccygeal Plexuses: Schema
469B Sacral and Coccygeal Plexuses in Situ
506A Femoral and Lateral Femoral Cutaneous Nerves
507A Obturator Nerve
508A Sciatic and Posterior Femoral Cutaneous Nerves
511B Segmental Innervation of Lower Limb Movements

Peripheral: Upper limb [\[Back to regional\]](#)

168 Arteries of Mammary Gland
401A Scapulohumeral Dissection: Anterior View
401B Scapulohumeral Dissection: Posterior View
404 Axilla [Dissection]: Anterior View
405 Brachial Plexus: Schema
406A Muscles of Arm: Anterior View - Superficial Layer
406B Muscles of Arm: Anterior View - Deep Layer
407A Muscles of Arm: Posterior View - Superficial Layer
407B Muscles of Arm: Posterior View - Deep Layer
408 Brachial Artery in Situ
410A Arm: Proximal Cross Section
410B Arm: Middle Cross Section
410C Arm: Distal Cross Section
419 Muscles of Forearm [Deep Layer]: Posterior View
420 Muscles of Forearm [Superficial Layer]: Anterior View
421 Muscles of Forearm [Intermediate Layer]: Anterior View
422 Muscles of Forearm [Deep Layer]: Anterior View
423A Forearm: Proximal Cross Section
423B Forearm: Middle Cross Section
423C Forearm: Distal Cross Section
428A Ligaments of Wrist: Carpal Tunnel - Palmar View
432A Wrist and Hand: Superficial Palmar Dissections
432B Wrist and Hand: Superficial Palmar Dissections [Continued]
433A Wrist and Hand: Deeper Palmar Dissections
433B Wrist and Hand: Deeper Palmar Dissections [Continued]
434A Flexor Tendons Arteries and Nerves at Wrist: Palmar View
434B Flexor Tendons Arteries and Nerves at Wrist: Cross Section
438A Intrinsic Muscles of Hand: Anterior [Palmar] View
439B Arteries and Nerves of Hand: Deep Palmar View
440 Wrist and Hand: Superficial Radial Dissection
441 Wrist and Hand: Superficial Dorsal Dissection
442 Wrist and Hand: Deep Dorsal Dissection
444B Fingers: Cross Section through Distal Phalanx
444C Fingers: Arteries and Nerves
445A Cutaneous Nerves of Wrist and Hand: Anterior [Palmar] View
445B Cutaneous Nerves of Wrist and Hand: Posterior [Dorsal] View
446 Arteries and Nerves of Upper Limb
447 Musculocutaneous Nerve
448 Median Nerve
449 Ulnar Nerve
450 Radial Nerve in Arm and Nerves of Posterior Shoulder
451A Radial Nerve in Forearm: Posterior View
451B Radial and Axillary Nerves: Cutaneous Innervation
452A Superficial Nerves and Veins of Shoulder and Arm: Anterior View
452B Superficial Nerves and Veins of Shoulder and Arm: Posterior View
453A Cutaneous Nerves and Superficial Veins of Forearm: Anterior (Palmar) View
453B Cutaneous Nerves and Superficial Veins of Forearm: Posterior (Dorsal) View
454A Cutaneous Innervation of Upper Limb: Anterior [Palmar] View
454B Cutaneous Innervation of Upper Limb: Posterior [Dorsal] View
455A Dermatomes of Upper Limb: Anterior View
455B Dermatomes of Upper Limb: Posterior View

Peripheral: Lower limb [\[Back to regional\]](#)

465A Muscles of Hip and Thigh: Posterior View - Superficial Dissection
465B Muscles of Hip and Thigh: Posterior View - Deeper Dissection
466A Psoas and Iliacus Muscles

467 Lumbosacral and Coccygeal Plexuses
468A Lumbar Plexus: Schema
468B Lumbar Plexus in Situ
469A Sacral and Coccygeal Plexuses: Schema
469B Sacral and Coccygeal Plexuses in Situ
470A Arteries and Nerves of Thigh: Superficial Anterior View
470B Arteries and Nerves of Thigh: Deeper Anterior View
471 Arteries and Nerves of Thigh: Deepest Anterior View
472 Arteries and Nerves of Thigh: Posterior View
473 Nerves of Hip and Buttock
475A Thigh: Proximal Cross Section
475B Thigh: Middle Cross Section
475C Thigh: Distal Cross Section
485 Muscles of Leg [Superficial Dissection]: Posterior View
486 Muscles of Leg [Intermediate Dissection]: Posterior View
487 Muscles of Leg [Deep Dissection]: Posterior View
488 Muscles of Leg [Superficial Dissection]: Anterior View
489 Muscles of Leg [Deep Dissection]: Anterior View
490 Muscles of Leg: Lateral View
491B Leg: Cross Section just above Middle of Left Leg
498 Muscles of Dorsum of Foot: Superficial Dissection
499 Dorsum of Foot: Deep Dissection
500 Sole of Foot: Superficial Dissection
501 Muscles of Sole of Foot: First Layer
502 Muscles of Sole of Foot: Second Layer
503 Muscles of Sole of Foot: Third Layer
506A Femoral and Lateral Femoral Cutaneous Nerves
506B Femoral and Lateral Femoral Cutaneous Nerves: Cutaneous Innervation
507A Obturator Nerve
507B Obturator Nerve: Cutaneous Innervation
508A Sciatic and Posterior Femoral Cutaneous Nerves
508B Sciatic and Posterior Femoral Cutaneous Nerves: Cutaneous Innervation
509A Tibial Nerve
509B Tibial Nerve: Plantar View
509C Tibial Nerve: Cutaneous Innervation of Sole of Foot
510A Common Peroneal Nerve
510B Common Peroneal Nerve: Cutaneous Innervation
511A Dermatomes of Lower Limb: Anterior and Posterior Views
511B Segmental Innervation of Lower Limb Movements
512 Superficial Nerves and Veins of Lower Limb: Anterior View
513 Superficial Nerves and Veins of Lower Limb: Posterior View
514C Lymph Vessels and Nodes of Lower Limb: Inguinal Region

Dermatomes/Cutaneous Innervation [\[Back to regional\]](#)

18A Cutaneous Nerves of Head and Neck
18B Dermatomes of Head and Neck
26 Superficial Veins and Cutaneous Nerves of Neck
31B External Nose [Skeleton] in Situ: Lateral View
150 Dermatomes
163 Nerves of Back
164 Suboccipital Triangle
166 Typical Thoracic Spinal Nerve
240 Nerves of Anterior Abdominal Wall
241 Thoracoabdominal Nerves
250 Nerves of Posterior Abdominal Wall
445A Cutaneous Nerves of Wrist and Hand: Anterior [Palmar] View
445B Cutaneous Nerves of Wrist and Hand: Posterior [Dorsal] View
447 Musculocutaneous Nerve
448 Median Nerve
449 Ulnar Nerve
451A Radial Nerve in Forearm: Posterior View
454A Cutaneous Innervation of Upper Limb: Anterior [Palmar] View
454B Cutaneous Innervation of Upper Limb: Posterior [Dorsal] View
455A Dermatomes of Upper Limb: Anterior View
455B Dermatomes of Upper Limb: Posterior View
506B Femoral and Lateral Femoral Cutaneous Nerves: Cutaneous Innervation
507B Obturator Nerve: Cutaneous Innervation
508B Sciatic and Posterior Femoral Cutaneous Nerves: Cutaneous Innervation
509B Tibial Nerve: Plantar View
510B Common Peroneal Nerve: Cutaneous Innervation
511A Dermatomes of Lower Limb: Anterior and Posterior Views
512 Superficial Nerves and Veins of Lower Limb: Anterior View
513 Superficial Nerves and Veins of Lower Limb: Posterior View

ANS [\[Back to regional\]](#)

11A Temporomandibular Joint: Lateral and Medial Views
28A Subclavian Artery: Right Anterior Dissection
38B Nerves of Nasal Cavity: Lateral Nasal Wall
39 Autonomic Innervation of Nasal Cavity
40 Ophthalmic and Maxillary Nerves
41A Mandibular Nerve [V3]: Lateral View
41B Mandibular Nerve [V3]: Medial View
49B Muscles Involved in Mastication [Deep]: Posterior View
53B Tongue and Related Structures: Sagittal Section
63 Arteries of Oral and Pharyngeal Regions
65 Nerves of Oral and Pharyngeal Regions
115 Oculomotor Trochlear and Abducens Nerves: Schema
116 Trigeminal Nerve: Schema
117 Facial Nerve: Schema
118 Vestibulocochlear Nerve: Schema

119 Glossopharyngeal Nerve: Schema
120 Vagus Nerve: Schema
124 Autonomic Nerves in Neck
125 Autonomic Nerves in Head
126 Ciliary Ganglion: Schema
127 Pterygopalatine and Submandibular Ganglia: Schema
128 Otic Ganglion: Schema
152 Autonomic Nervous System: General Topography
153 Autonomic Nervous System: Schema
154 Cholinergic and Adrenergic Synapses: Schema
179 Intercostal Nerves and Arteries
198 Autonomic Nerves in Thorax
199 Innervation of Tracheobronchial Tree: Schema
214 Nerves of Heart
215 Innervation of Heart: Schema
216 Innervation of Blood Vessels: Schema
218 Mediastinum: Right Lateral View
219 Mediastinum: Left Lateral View
220 Esophagus in Situ
228A Nerves of Esophagus: Anterior View
228B Nerves of Esophagus: Posterior View
229A Nerves of Esophagus: Variations
229B Intrinsic Nerves of Esophagus: Schema
304 Autonomic Nerves and Ganglia of Abdomen
307 Innervation of Stomach and Duodenum: Schema
310A Innervation of Small and Large Intestines: Left Side of Schema
310B Innervation of Small and Large Intestines: Right Side of Schema
311 Autonomic Reflex Pathways: Schema
312 Intrinsic Autonomic Plexuses of Intestine: Schema
313A Common Areas of Referred Pain in Biliary Disease
313B Innervation of Liver and Biliary Tract: Schema
313C Innervation of Liver: Nerve Fibers around Fine Branch of Hepatic Artery
314A Common Areas of Pancreatic Pain
314B Innervation of Pancreas: Schema
314C Schema of Intrinsic Nerve Supply of Pancreas
326 Nerves of Kidneys Ureters and Urinary Bladder
327 Innervation of Kidneys and Upper Ureters: Schema
384 Nerves of External Genitalia: Male
385 Nerves of Pelvic Viscera: Male
387A Nerves of Pelvic Viscera: Female - Sagittal Section
387B Nerves of Pelvic Viscera: Female - Superior View
388A Nerves of Perineum and External Genitalia: Female
388B Block Anesthesia of Perineal Area: Primarily Pudendal Nerve
389A Neuropathways in Parturition
389B Neuropathways in Parturition: Pelvic Area Enlarged
390 Innervation of Female Reproductive Organs: Schema
391 Innervation of Male Reproductive Organs: Schema
392 Innervation of Urinary Bladder and Lower Ureter: Schema

Special senses [\[Back to regional\]](#)

37 Nerves of Nasal Cavity: Schematic Hinge
38A Nerves of Nasal Cavity: Distribution of Olfactory Mucosa
38B Nerves of Nasal Cavity: Lateral Nasal Wall
38C Nerves of Nasal Cavity: Nasal Septum
39 Autonomic Innervation of Nasal Cavity
52A Tongue: Dorsum
52B Tongue - Schematic Stereogram: Area Indicated on Plate 52A
53B Tongue and Related Structures: Sagittal Section
55A Salivary Glands: Dissection
56A Afferent Innervation of Mouth and Pharynx: Anterior View
56B Afferent Innervation of Mouth and Pharynx: Lateral View
56C Afferent Innervation of Mouth and Pharynx: Dorsum of Tongue
76A Eyelids: Anterior View
76B Eyelids and Anterior Orbital Structures: Sagittal Section
76C Eyelids - Dissection: Anterior View
77A Lacrimal Apparatus in Situ
77B Lacrimal Apparatus: Dissection
78A Fascia of Orbit and Eyeball: Horizontal Section
78B Fascia of Orbit and Eyeball: Frontal Section and Entering Structures
79A Extrinsic Eye Muscles: Right Lateral View
79B Extrinsic Eye Muscles: Superior View
79C Extrinsic Eye Muscles - Innervation and Action: Anterior View of Left Eye
80A Arteries and Veins of Orbit and Eyelids: Superior View
80B Arteries and Veins of Orbit and Eyelids: Anterior View
80C Arteries and Veins of Orbit and Eyelids: Lateral View
81A Nerves of Orbit: Superior View
81B Nerves of Orbit - Muscles Partially Cut Away: Superior View
82 Eyeball: Cross Section
83 Anterior and Posterior Chambers of Eye
84A Anterior Chamber Angle of Eye
84B Anterior Chamber Angle of Eye: Gonioscopic Views
85A Lens and Supporting Structures: Section in Frontal Plane
85B Lens and Supporting Structures: Horizontal Section
85C Lens and Supporting Structures: Segment Outlined in Plate 85A
86A Intrinsic Arteries and Veins of Eye: Horizontal Section
86B Intrinsic Arteries and Veins of Eye: Ophthalmoscopic View
87 Pathway of Sound Reception
88A External Ear: Right Auricle
88B External Ear: Right Tympanic Membrane
88C Tympanic Cavity: Viewed from External Acoustic Meatus
88D External Ear and Tympanic Cavity: Coronal Oblique Section
88E Tympanic Cavity: Auditory Ossicles

89A Tympanic Cavity - Lateral Wall: Medial View
89B Tympanic Cavity - Medial Wall: Lateral View
90A Right Osseous Labyrinth: Anterolateral View
90B Right Osseous Labyrinth - Dissected: Membranous Labyrinth Removed
90C Right Membranous Labyrinth with Nerves: Posteromedial View
91A Osseous and Membranous Labyrinths: Schema
91B Osseous and Membranous Labyrinths: Section Through Turn of Cochlea
92A Orientation of Labyrinth in Skull: Superior Projection
92B Orientation of Labyrinth in Skull: Lateral Projection
93A Cartilage of Auditory Tube at Base of Skull: Inferior View
93B Auditory Tube - Section through Cartilage: Tube Closed
93C Auditory Tube - Section through Cartilage: Tube Open
113A Olfactory Nerve: Schema
113B Olfactory Nerve - Olfactory Bulb Cells: Schema
114A Optic Nerve [Visual Pathway]: Schema
114B Optic Nerve [Visual Pathway] - Structure of Retina: Schema
115 Oculomotor, Trochlear and Abducens Nerves: Schema
116 Trigeminal Nerve: Schema
117 Facial Nerve: Schema
118 Vestibulocochlear Nerve: Schema
119 Glossopharyngeal Nerve: Schema
120 Vagus Nerve: Schema
121 Accessory Nerve: Schema
125 Autonomic Nerves in Head
126 Ciliary Ganglion: Schema
127 Pterygopalatine and Submandibular Ganglia: Schema
129 Taste Pathways: Schema

Kidney [\[Back to regional\]](#)

165 Lumbar Region of Back: Cross Section
247 Arteries of Posterior Abdominal Wall
248 Veins of Posterior Abdominal Wall
256 Omental Bursa: Cross Section
257 Peritoneum of Posterior Abdominal Wall
261 Duodenum in Situ
279A Pancreas in Situ
304 Autonomic Nerves and Ganglia of Abdomen
315A Kidneys in Situ: Anterior View
315B Kidneys in Situ: Anterior Relations of Kidneys
316A Kidneys in Situ: Posterior View
316B Kidneys in Situ: Posterior Relations of Kidneys
317A Anterior Surface of Right Kidney
317B Right Kidney Sectioned in Several Planes
317C Suprarenal Gland and Lobulated Kidney of Infant
318 Renal Artery and Vein in Situ
319A Intrarenal Arteries: Frontal Section of Left Kidney - Anterior View
319B Vascular Renal Segments
320A Variations in Renal Artery
320B Variations in Renal Vein
320C Variations in Renal Vein [Continued]
321 Nephron and Collecting Tubule: Schema
322 Blood Vessels in Kidney Parenchyma: Schema
323A Ureters in Male: Anterior View
324 Arteries of Ureters and Urinary Bladder
325 Lymph Vessels and Nodes of Kidneys and Urinary Bladder
326 Nerves of Kidneys Ureters and Urinary Bladder
327 Innervation of Kidneys and Upper Ureters: Schema
328A Renal Fascia: Transverse Section through 2nd Lumbar Vertebra
328B Renal Fascia: Sagittal Section through Right Kidney
329B Arteries and Veins of Left Suprarenal Gland in Situ
330A Nerves of Suprarenal Glands: Dissection
331 Abdominal Wall and Viscera: Cross Section at T12
375 Arteries and Veins of Pelvic Organs: Female
376 Arteries and Veins of Testis

Ureter [\[Back to regional\]](#)

257 Peritoneum of Posterior Abdominal Wall
315A Kidneys in Situ: Anterior View
317A Anterior Surface of Right Kidney
317C Suprarenal Gland and Lobulated Kidney of Infant
319A Intrarenal Arteries: Frontal Section of Left Kidney - Anterior View
323A Ureters in Male: Anterior View
323B Diagonal Course of Ureter through Bladder Wall
323C Ureters in Female: Superior View
324 Arteries of Ureters and Urinary Bladder
325 Lymph Vessels and Nodes of Kidneys and Urinary Bladder
326 Nerves of Kidneys Ureters and Urinary Bladder
327 Innervation of Kidneys and Upper Ureters: Schema
332 Abdominal Wall and Viscera: Cross Section Between L2 and L3
343 Pelvic Contents of Female: Superior View
344 Pelvic Contents of Male: Superior View
348B Pelvic Viscera of Female: Superior View - Peritoneum Removed
368 Ischiorectal Fossa
375 Arteries and Veins of Pelvic Organs: Female
376 Arteries and Veins of Testis
377B Arteries and Veins of Pelvis: Female - Right Paramedian Section

Bladder [\[Back to regional\]](#)

236 Anterior Abdominal Wall: Internal View

244A Femoral Sheath and Inguinal Canal
257 Peritoneum of Posterior Abdominal Wall
315A Kidneys in Situ: Anterior View
323A Ureters in Male: Anterior View
323B Diagonal Course of Ureter through Bladder Wall
323C Ureters in Female: Superior View
324 Arteries of Ureters and Urinary Bladder
325 Lymph Vessels and Nodes of Kidneys and Urinary Bladder
326 Nerves of Kidneys Ureters and Urinary Bladder
333A Abdominal Wall and Viscera [Above L4]: Midsagittal Section
333B Abdominal Wall and Viscera [Below L4]: Midsagittal Section
341A Pelvic Viscera and Perineum of Female: Midsagittal Section
341B Pelvic Viscera and Perineum of Female: Paramedian Sagittal Section
342A Pelvic Viscera and Perineum of Male: Paramedian Sagittal Section
342B Pelvic Viscera and Perineum of Male: Midsagittal Section
343 Pelvic Contents of Female: Superior View
344 Pelvic Contents of Male: Superior View
345 Endopelvic Fascia and Spaces of Female: Superior View
346A Urinary Bladder - Orientation and Supports: Midsagittal Section
346B Urinary Bladder - Orientation and Supports: Superior View
347A Urinary Bladder of Female: Frontal Section
347B Urinary Bladder of Male: Frontal Section
348A Pelvic Viscera of Female: Superior View - Peritoneum Intact
348B Pelvic Viscera of Female: Superior View - Peritoneum Removed
357A Urethra of Female: Frontal Section
362A Prostate and Seminal Vesicles: Frontal Section
362B Prostate and Seminal Vesicles: Sagittal Section
362C Prostate and Seminal Vesicles: Posterior View
363 Urethra: Male
375 Arteries and Veins of Pelvic Organs: Female
376 Arteries and Veins of Testis
378A Arteries and Veins of Pelvis: Male - Left Paramedian Section
381 Lymph Vessels and Nodes of Pelvis and Genitalia: Female
392 Innervation of Urinary Bladder and Lower Ureter: Schema

Urethra [\[Back to regional\]](#)

341A Pelvic Viscera and Perineum of Female: Midsagittal Section
346A Urinary Bladder - Orientation and Supports: Midsagittal Section
347A Urinary Bladder of Female: Frontal Section
347B Urinary Bladder of Male: Frontal Section
356B Perineum and Urogenital Diaphragm of Female: Deep Dissection
357A Urethra of Female: Frontal Section
357B Urethra of Female: Schematic Reconstruction
359B Section through Body of Penis
361A Urogenital Diaphragm of Male: Dissection
361B Urogenital Diaphragm of Male: Deep Dissection
361C Urogenital Diaphragm of Male: Frontal Section - Schema
362A Prostate and Seminal Vesicles: Frontal Section
362B Prostate and Seminal Vesicles: Sagittal Section
363 Urethra: Male
378B Arterial Supply of Prostate

Sinuses/Nose [\[Back to regional\]](#)

32A Lateral Nasal Wall
32C Lateral Nasal Wall - Nasal Conchae Removed
33A Lateral Nasal Wall - Bony Structure
33B Lateral Nasal Wall - Bony Structure: Nasal Conchae Partly Removed
34A Medial Nasal Wall [Septum]
34B Medial Nasal Wall [Septum]: Bones and Cartilages
35B Maxillary Artery: Nasopalatine Distribution
36 Arteries of Nasal Cavity: Schematic Hinge
37 Nerves of Nasal Cavity: Schematic Hinge
38A Nerves of Nasal Cavity: Distribution of Olfactory Mucosa
42A Paranasal Sinuses: Coronal Section
42B Paranasal Sinuses: Horizontal Section
43A Paranasal Sinuses: Sagittal Section
43B Paranasal Sinuses: Lateral Dissection
44A Paranasal Sinuses: At Birth
44B Paranasal Sinuses: Growth throughout Life
57 Pharynx: Sagittal Section
77B Lacrimal Apparatus: Dissection
98B Cavernous Sinus: Coronal Section

Larynx [\[Back to regional\]](#)

30B Fascial Layers of Neck: Sagittal Section
46B Roof of Mouth - Soft Palate: Posterior View
49B Muscles Involved in Mastication [Deep]: Posterior View
54A Tongue and Mouth: Horizontal Section - Superior View
57 Pharynx: Sagittal Section
58A Fauces: Medial Sagittal View
58B Fauces: Pharyngeal Mucosa Removed
59 Muscles of Pharynx: Sagittal Section
60 Pharynx: Opened Posterior View
61 Muscles of Pharynx: Partially Opened Posterior View
68A Thyroid Gland: Anterior View
68B Thyroid Gland in Situ: Anterior View
71A Cartilages of Larynx: Anterior View
71B Cartilages of Larynx: Posterior View
71C Cartilages of Larynx: Anterosuperior View

71D Cartilages of Larynx: Right Lateral View
71E Cartilages of Larynx: Sagittal Section
72A Intrinsic Muscles of Larynx: Posterior View
72B Intrinsic Muscles of Larynx: Right Lateral View
72C Intrinsic Muscles of Larynx: Lateral Dissection
72D Intrinsic Muscles of Larynx: Superior View
73 Action of Intrinsic Muscles of Larynx
74A Nerves of Larynx: Right Lateral Views
74B Nerves of Larynx: Anterior View
75A Inspection of Larynx: Technique
75B Inspection of Larynx: Views during Inspiration and Phonation
77B Lacrimal Apparatus: Dissection
129 Taste Pathways: Schema
199 Innervation of Tracheobronchial Tree: Schema

Trachea [\[Back to regional\]](#)

30A Fascial Layers of Neck: Cross Section
30B Fascial Layers of Neck: Sagittal Section
57 Pharynx: Sagittal Section
59 Muscles of Pharynx: Sagittal Section
62 Muscles of Pharynx: Lateral View
68A Thyroid Gland: Anterior View
68B Thyroid Gland in Situ: Anterior View
74A Nerves of Larynx: Right Lateral Views
74B Nerves of Larynx: Anterior View
190A Trachea and Major Bronchi: Anterior View
190B Trachea: Cross Section
191 Nomenclature of Bronchi: Schema
194 Pulmonary Arteries and Veins
199 Innervation of Tracheobronchial Tree: Schema

Bronchi [\[Back to regional\]](#)

190A Trachea and Major Bronchi: Anterior View
190B Trachea: Cross Section
191 Nomenclature of Bronchi: Schema
192 Intrapulmonary Airways: Schema
193 Intrapulmonary Blood Circulation: Schema
194 Pulmonary Arteries and Veins
195 Main Bronchi With Pulmonary Arteries and Veins in Situ
196A Bronchial Arteries
196B Bronchial Arteries: Variations
196C Bronchial Veins
197 Lymph Vessels and Nodes of Lung
199 Innervation of Tracheobronchial Tree: Schema
230 Mediastinum: Cross Section

Lungs [\[Back to regional\]](#)

184 Topography of Lungs: Anterior View
185 Topography of Lungs: Posterior View
186 Lungs in Situ: Anterior View
187A Right Lung: Medial View
187B Left Lung: Medial View
188A Bronchopulmonary Segments: Anterior View
188B Bronchopulmonary Segments: Posterior View
189A Bronchopulmonary Segments: Lateral Views
189B Bronchopulmonary Segments: Medial Views
192 Intrapulmonary Airways: Schema
193 Intrapulmonary Blood Circulation: Schema
194 Pulmonary Arteries and Veins
195 Main Bronchi With Pulmonary Arteries and Veins in Situ
197 Lymph Vessels and Nodes of Lung
200 Heart in Situ
201 Heart: Anterior Exposure
230 Mediastinum: Cross Section
269A Topography of Liver: Anterior and Posterior Views
269B Topography of Liver: Lateral View
298C Variations of Portal Vein [Continued]

Diaphragm [\[Back to regional\]](#)

176 Anterior Thoracic Wall: Internal View
180 Diaphragm: Thoracic Surface
181 Diaphragm: Abdominal Surface
218 Mediastinum: Right Lateral View
219 Mediastinum: Left Lateral View
328B Renal Fascia: Sagittal Section through Right Kidney
333A Abdominal Wall and Viscera [Above L4]: Midsagittal Section
333B Abdominal Wall and Viscera [Below L4]: Midsagittal Section

Pituitary gland [\[Back to regional\]](#)

98A Venous Sinuses of Dura Mater: Cranial Floor - Superior View
98B Cavernous Sinus: Coronal Section
100A Cerebrum - Brain in Situ: Sagittal Section - Medial View
101 Cerebrum: Inferior View
109B Fourth Ventricle and Cerebellum: Median Sagittal Section
133B Circle of Willis - Vessels in Situ: Inferior View

140A Hypothalamus - Principal Nuclei
140B Adenohypophysis and Neurohypophysis
141 Arteries and Veins of Hypothalamus and Hypophysis

Thyroid/Parathyroid/Thymus gland [\[Back to regional\]](#)

24A Infrahyoid and Suprahyoid Muscles
28A Subclavian Artery: Right Anterior Dissection
30B Fascial Layers of Neck: Sagittal Section
63 Arteries of Oral and Pharyngeal Regions
64 Veins of Oral and Pharyngeal Regions
66 Lymph Vessels and Nodes of Oral and Pharyngeal Regions
68A Thyroid Gland: Anterior View
68B Thyroid Gland in Situ: Anterior View
69 Thyroid Gland and Pharynx: Posterior View
70A Parathyroid Glands: Posterior View
70B Parathyroid Glands: Right Lateral View
124 Autonomic Nerves in Neck
130 Arteries to Brain and Meninges
182A Phrenic Nerve in Situ
184 Topography of Lungs: Anterior View
186 Lungs in Situ: Anterior View
195 Main Bronchi With Pulmonary Arteries and Veins in Situ
200 Heart in Situ

Adrenal gland [\[Back to regional\]](#)

257 Peritoneum of Posterior Abdominal Wall
261 Duodenum in Situ
317B Right Kidney Sectioned in Several Planes
318 Renal Artery and Vein in Situ
320A Variations in Renal Artery
329A Arteries and Veins of Right Suprarenal Gland in Situ
329B Arteries and Veins of Left Suprarenal Gland in Situ
329C Cross Section through Suprarenal Gland
330A Nerves of Suprarenal Glands: Dissection
330B Nerves of Suprarenal Glands: Schema
331 Abdominal Wall and Viscera: Cross Section at T12

Pancreas [\[Back to regional\]](#)

255 Omental Bursa: Stomach Reflected
256 Omental Bursa: Cross Section
257 Peritoneum of Posterior Abdominal Wall
262A Mucosa of Duodenum
279A Pancreas in Situ
279B Pancreas: Histology
279C Pancreas
280A Variations in Pancreatic Ducts
280B Variations in Pancreatic Ducts [Continued]
283 Arteries of Stomach Duodenum Pancreas and Spleen
284 Arteries of Liver Pancreas Duodenum and Spleen
285A Arteries of Duodenum and Head of Pancreas: Reflected to Left
285B Arteries of Duodenum and Head of Pancreas: Posterior View
299B Lymph Vessels and Nodes of Stomach: Stomach Reflected
303A Lymph Vessels and Nodes of Pancreas: Anterior View
303B Lymph Vessels and Nodes of Pancreas: Posterior View

Testes [\[Back to regional\]](#)

342A Pelvic Viscera and Perineum of Male: Paramedian Sagittal Section
342B Pelvic Viscera and Perineum of Male: Midsagittal Section
364A Descent of Testis: 8 Weeks
364B Descent of Testis: 11 Weeks
364C Descent of Testis: 4 Lunar Months
364D Descent of Testis: 8 Lunar Months
365A Scrotum and Contents: Anterior View
365B Scrotum and Contents: Lateral View
366A Testis Epididymis and Ductus Deferens: Frontal Section
366B Testis Epididymis and Ductus Deferens: Schema
366C Testis Epididymis and Ductus Deferens: Cross Section
367A Rectum of Male in Situ
371A External Anal Sphincter Muscle of Male: Perineal View
378A Arteries and Veins of Pelvis: Male - Left Paramedian Section
380A Arteries and Veins of Perineum: Male
380B Arteries and Veins of Perineum [Continued]: Male
383A Lymph Vessels and Nodes of Pelvis and Genitalia: Male
383B Lymphatic Drainage from Prostate
384 Nerves of External Genitalia: Male
386A Nerves of Perineum: Male - Perineal View
391 Innervation of Male Reproductive Organs: Schema
393A Homologues of External Genitalia: Undifferentiated Stage
393B Homologues of External Genitalia: Fully Developed Male and Female
394A Homologues of Internal Genitalia: Undifferentiated Stage

394B Homologues of Internal Genitalia: Fully Developed Male and Female

Ovaries [\[Back to regional\]](#)

341A Pelvic Viscera and Perineum of Female: Midsagittal Section
341B Pelvic Viscera and Perineum of Female: Paramedian Sagittal Section
343 Pelvic Contents of Female: Superior View
348A Pelvic Viscera of Female: Superior View - Peritoneum Intact
349 Uterus, Vagina and Supporting Structures
350A Uterus and Adnexa: Posterior View
350B Uterus and Adnexa: Frontal Section
353A Infant Ovary and Ripening Follicle: Histology
353B Stages of Ovum and Follicle
379B Arteries and Veins of Uterus
387A Nerves of Pelvic Viscera: Female - Sagittal Section
387B Nerves of Pelvic Viscera: Female - Superior View
394A Homologues of Internal Genitalia: Undifferentiated Stage
394B Homologues of Internal Genitalia: Fully Developed Male and Female

Mouth and Pharynx/Salivary glands [\[Back to regional\]](#)

19A Facial Nerve Branches and Parotid Gland in Situ
19B Facial Nerve Branches and Parotid Gland: Sectioned
22 Muscles of Neck: Lateral View
23 Muscles of Neck: Anterior View
30B Fascial Layers of Neck: Sagittal Section
32A Lateral Nasal Wall
34A Medial Nasal Wall [Septum]
45A Inspection of Oral Cavity: Dorsum of Tongue and Palate
45B Inspection of Oral Cavity: Sublingual Region - Anterior Vestibule
45C Inspection of Oral Cavity: Lateral Oral Vestibule
46A Roof of Mouth - Hard and Soft Palates: Anterior View
46B Roof of Mouth - Soft Palate: Posterior View
47C Floor of Mouth - Musculature: Posterosuperior View
48A Muscles Involved in Mastication: Lateral View
48B Muscles Involved in Mastication - Masseter Removed: Lateral View
49A Muscles Involved in Mastication [Deep]: Lateral View
50A Teeth - Deciduous and Permanent: Age of Eruptions
50B Teeth - Upper and Lower Permanent
51A Anatomy of a Tooth
51B Teeth - Left Upper and Left Lower Permanent: Labiobuccal View
52A Tongue: Dorsum
52B Tongue - Schematic Stereogram: Area Indicated on Plate 52A
53A Muscles of Tongue: Sagittal Section
53B Tongue and Related Structures: Sagittal Section
54B Tongue and Mouth: Frontal Section - Anterior View
55A Salivary Glands: Dissection
55B Salivary Glands: Histology
56A Afferent Innervation of Mouth and Pharynx: Anterior View
56B Afferent Innervation of Mouth and Pharynx: Lateral View
56C Afferent Innervation of Mouth and Pharynx: Dorsum of Tongue
57 Pharynx: Sagittal Section
58A Fauces: Medial Sagittal View
58B Fauces: Pharyngeal Mucosa Removed
59 Muscles of Pharynx: Sagittal Section
60 Pharynx: Opened Posterior View
61 Muscles of Pharynx: Partially Opened Posterior View
63 Arteries of Oral and Pharyngeal Regions
64 Veins of Oral and Pharyngeal Regions
65 Nerves of Oral and Pharyngeal Regions
66 Lymph Vessels and Nodes of Oral and Pharyngeal Regions
67A Lymphatic Drainage of Pharynx: Posterior View
67B Lymphatic Drainage of Tongue: Lateral View
69 Thyroid Gland and Pharynx: Posterior View
70B Parathyroid Glands: Right Lateral View
116 Trigeminal Nerve: Schema
117 Facial Nerve: Schema
119 Glossopharyngeal Nerve: Schema
120 Vagus Nerve: Schema
128 Otic Ganglion: Schema
223 Pharyngoesophageal Junction

Esophagus and Stomach [\[Back to regional\]](#)

30A Fascial Layers of Neck: Cross Section
30B Fascial Layers of Neck: Sagittal Section
57 Pharynx: Sagittal Section

60 Pharynx: Opened Posterior View
61 Muscles of Pharynx: Partially Opened Posterior View
62 Muscles of Pharynx: Lateral View
69 Thyroid Gland and Pharynx: Posterior View
70A Parathyroid Glands: Posterior View
120 Vagus Nerve: Schema
180 Diaphragm: Thoracic Surface
196A Bronchial Arteries
220 Esophagus in Situ
221A Topography and Constrictions of Esophagus: Schema - Anterior View
221B Topography and Constrictions of Esophagus: Lateral View
222A Musculature of Esophagus 1
222B Musculature of Esophagus 2
223 Pharyngoesophageal Junction
224A Esophagogastric Junction: Coronal Section
224B Esophagogastric Junction: Anterior View
225A Arteries of Esophagus
225B Arteries of Esophagus: Variations
226A Veins of Esophagus
226B Veins of Esophagus: Submucous Venous Plexus
227 Lymph Vessels and Nodes of Esophagus
228A Nerves of Esophagus: Anterior View
228B Nerves of Esophagus: Posterior View
229A Nerves of Esophagus: Variations
229B Intrinsic Nerves of Esophagus: Schema
255 Omental Bursa: Stomach Reflected
256 Omental Bursa: Cross Section
258A Stomach in Situ
258B Stomach: Variations in Position and Contour
259A Mucosa of Stomach
259B Mucosa of Stomach: Histology
260A Musculature of Stomach
260B Musculature of Stomach [Continued]
270C Surfaces and Bed of Liver: Posterior View and Bed of Liver
271A Liver in Situ
282 Arteries of Stomach Liver and Spleen
283 Arteries of Stomach Duodenum Pancreas and Spleen
292F Variations in Colic Arteries 12
294A Veins of Stomach Duodenum and Pancreas
294B Veins of Stomach Duodenum and Pancreas [Continued]
297 Portal Vein Tributaries: Portacaval Anastomoses
299A Lymph Vessels and Nodes of Stomach
299B Lymph Vessels and Nodes of Stomach: Stomach Reflected
305 Nerves of Stomach and Duodenum
306A Nerves of Stomach and Duodenum: View with Stomach Reflected
306B Nerves of Stomach and Duodenum: Hiatal Region
307 Innervation of Stomach and Duodenum: Schema
331 Abdominal Wall and Viscera: Cross Section at T12
333A Abdominal Wall and Viscera [Above L4]: Midsagittal Section
333B Abdominal Wall and Viscera [Below L4]: Midsagittal Section

Small intestine [\[Back to regional\]](#)

120 Vagus Nerve: Schema
165 Lumbar Region of Back: Cross Section
252A Greater Omentum and Abdominal Viscera
252B Greater Omentum and Abdominal Viscera: Omentum Raised
253A Mesenteric Relations of Intestines: Transverse Colon Elevated
253B Mesenteric Relations of Intestines: Suspensory Muscle of Duodenum
256 Omental Bursa: Cross Section
261 Duodenum in Situ
262A Mucosa of Duodenum
262B Musculature of Duodenum: Layers of Wall
263A Mucosa and Musculature of Jejunum
263B Mucosa and Musculature of Ileum
264A Ileocecal Region
264B Ileocecal Region: Retrocecal Recess Exposed
264C Ileocecal Region: Variations in Posterior Peritoneal Attachment
265A Ileocecal Region: Labial Form of Ileocecal Sphincter
265B Ileocecal Region: Papillary Form of Ileocecal Sphincter
265C Ileocecal Region: Schema of Muscle Fibers at Ileocecal Sphincter
266A Vermiform Appendix: Variations in Position
266B Vermiform Appendix: Fixed Retrocecal
278A Choledochoduodenal Junction
278B Choledochoduodenal Junction: Dissection
278C Choledochoduodenal Junction: Reconstruction
278D Variations in Union of Bile and Pancreatic Ducts
279A Pancreas in Situ
283 Arteries of Stomach Duodenum Pancreas and Spleen
284 Arteries of Liver Pancreas Duodenum and Spleen
285A Arteries of Duodenum and Head of Pancreas: Reflected to Left
285B Arteries of Duodenum and Head of Pancreas: Posterior View
286 Arteries of Small Intestine
294A Veins of Stomach Duodenum and Pancreas
294B Veins of Stomach Duodenum and Pancreas [Continued]
295A Veins of Small Intestine: Transverse Colon Cut
295B Veins of Small Intestine: Transverse Colon Elevated
296 Veins of Small and Large Intestines
297 Portal Vein Tributaries: Portacaval Anastomoses
300 Lymph Vessels and Nodes of Small Intestine
305 Nerves of Stomach and Duodenum
306A Nerves of Stomach and Duodenum: View with Stomach Reflected
307 Innervation of Stomach and Duodenum: Schema

308 Nerves of Small Intestine
310A Innervation of Small and Large Intestines: Left Side of Schema
310B Innervation of Small and Large Intestines: Right Side of Schema
311 Autonomic Reflex Pathways: Schema
312 Intrinsic Autonomic Plexuses of Intestine: Schema
328A Renal Fascia: Transverse Section through 2nd Lumbar Vertebra
332 Abdominal Wall and Viscera: Cross Section Between L2 and L3
333A Abdominal Wall and Viscera [Above L4]: Midsagittal Section
333B Abdominal Wall and Viscera [Below L4]: Midsagittal Section

Large intestine/Rectum [\[Back to regional\]](#)

120 Vagus Nerve: Schema
251A Quadrants of Abdomen
251B Regions and Planes of Abdomen
252A Greater Omentum and Abdominal Viscera
252B Greater Omentum and Abdominal Viscera: Omentum Raised
253A Mesenteric Relations of Intestines: Transverse Colon Elevated
253B Mesenteric Relations of Intestines: Suspensory Muscle of Duodenum
254A Mesenteric Relations of Intestines: Small Intestine Removed
254B Mesenteric Relations of Intestines: Sigmoid Colon Reflected
255 Omental Bursa: Stomach Reflected
257 Peritoneum of Posterior Abdominal Wall
258A Stomach in Situ
264A Ileocecal Region
264B Ileocecal Region: Retrocecal Recess Exposed
264C Ileocecal Region: Variations in Posterior Peritoneal Attachment
265A Ileocecal Region: Labial Form of Ileocecal Sphincter
265B Ileocecal Region: Papillary Form of Ileocecal Sphincter
265C Ileocecal Region: Schema of Muscle Fibers at Ileocecal Sphincter
266A Vermiform Appendix: Variations in Position
266B Vermiform Appendix: Fixed Retrocecal
266C Vermiform Appendix: Cross Section
268A Sigmoid Colon: Variations in Position
268B Sigmoid Colon [Continued]: Variations in Position
269A Topography of Liver: Anterior and Posterior Views
269B Topography of Liver: Lateral View
279A Pancreas in Situ
287 Arteries of Large Intestine
291A Variations in Colic Arteries 1
291B Variations in Colic Arteries 2
291C Variations in Colic Arteries 3
291D Variations in Colic Arteries 4
291E Variations in Colic Arteries 5
291F Variations in Colic Arteries 6
292A Variations in Colic Arteries 7
292B Variations in Colic Arteries 8
292C Variations in Colic Arteries 9
292D Variations in Colic Arteries 10
292E Variations in Colic Arteries 11
292F Variations in Colic Arteries 12
293A Variations in Cecal and Appendicular Arteries 1
293B Variations in Cecal and Appendicular Arteries 2
293C Variations in Cecal and Appendicular Arteries 3
293D Variations in Cecal and Appendicular Arteries 4
293E Variations in Cecal and Appendicular Arteries 5
293F Variations in Cecal and Appendicular Arteries 6
293G Variations in Cecal and Appendicular Arteries 7
293H Variations in Cecal and Appendicular Arteries 8
296 Veins of Small and Large Intestines
297 Portal Vein Tributaries: Portacaval Anastomoses
301A Lymph Vessels and Nodes of Large Intestine
309 Nerves of Large Intestine
310A Innervation of Small and Large Intestines: Left Side of Schema
310B Innervation of Small and Large Intestines: Right Side of Schema
311 Autonomic Reflex Pathways: Schema
312 Intrinsic Autonomic Plexuses of Intestine: Schema
328A Renal Fascia: Transverse Section through 2nd Lumbar Vertebra
328B Renal Fascia: Sagittal Section through Right Kidney
332 Abdominal Wall and Viscera: Cross Section Between L2 and L3
333A Abdominal Wall and Viscera [Above L4]: Midsagittal Section
333B Abdominal Wall and Viscera [Below L4]: Midsagittal Section
341A Pelvic Viscera and Perineum of Female: Midsagittal Section
341B Pelvic Viscera and Perineum of Female: Paramedian Sagittal Section
342A Pelvic Viscera and Perineum of Male: Paramedian Sagittal Section
342B Pelvic Viscera and Perineum of Male: Midsagittal Section
343 Pelvic Contents of Female: Superior View
344 Pelvic Contents of Male: Superior View
346A Urinary Bladder - Orientation and Supports: Midsagittal Section
367A Rectum of Male in Situ
367B Rectum of Female in Situ
368 Ischiorectal Fossa
369 Rectum and Anal Canal
370A Anorectal Musculature: Anterior View
370B Anorectal Musculature: Frontal Section
373 Arteries of Rectum and Anal Canal
374 Veins of Rectum and Anal Canal

Gallbladder and Liver [\[Back to regional\]](#)

120 Vagus Nerve: Schema
251A Quadrants of Abdomen

251B Regions and Planes of Abdomen
252A Greater Omentum and Abdominal Viscera
252B Greater Omentum and Abdominal Viscera: Omentum Raised
255 Omental Bursa: Stomach Reflected
258A Stomach in Situ
269A Topography of Liver: Anterior and Posterior Views
269B Topography of Liver: Lateral View
270A Surfaces and Bed of Liver: Anterior View
270B Surfaces and Bed of Liver: Visceral Surface
270C Surfaces and Bed of Liver: Posterior View and Bed of Liver
271A Liver in Situ
271B Variations in Form of Liver
272A Liver Segments and Lobules: Parietal Surface
272B Liver Segments and Lobules: Visceral Surface
272C Distribution of Vessels and Ducts of Liver
273A Intrahepatic Vascular and Duct Systems: Schema
273B Normal Lobular Pattern of Liver
274 Liver Structure: Schema
275A Intrahepatic Biliary System: Schema
275B Intrahepatic Biliary System: Histology
276A Gallbladder and Extrahepatic Bile Ducts
276B Gallbladder and Extrahepatic Bile Ducts: Sectioned
277A Variations in Cystic Duct
277B Variations in Accessory [Aberrant] Hepatic Ducts
278A Choledochoduodenal Junction
278B Choledochoduodenal Junction: Dissection
278C Choledochoduodenal Junction: Reconstruction
278D Variations in Union of Bile and Pancreatic Ducts
282 Arteries of Stomach Liver and Spleen
284 Arteries of Liver Pancreas Duodenum and Spleen
289A Variations in Hepatic Arteries
289B Variations in Hepatic Arteries [Continued]
290A Variations in Cystic Artery 1
290B Variations in Cystic Artery 2
290C Variations in Cystic Artery 3
290D Variations in Cystic Artery 4
290E Variations in Cystic Artery 5
292E Variations in Colic Arteries 11
294A Veins of Stomach Duodenum and Pancreas
294B Veins of Stomach Duodenum and Pancreas [Continued]
297 Portal Vein Tributaries: Portacaval Anastomoses
298A Typical Arrangement of Portal Vein
298B Variations of Portal Vein
298C Variations of Portal Vein [Continued]
298D Anomalies of Portal Vein
302A Lymph Vessels and Nodes of Liver: Histology
302B Lymph Vessels and Nodes of Liver
313A Common Areas of Referred Pain in Biliary Disease
313B Innervation of Liver and Biliary Tract: Schema
313C Innervation of Liver: Nerve Fibers around Fine Branch of Hepatic Artery
328A Renal Fascia: Transverse Section through 2nd Lumbar Vertebra
328B Renal Fascia: Sagittal Section through Right Kidney
331 Abdominal Wall and Viscera: Cross Section at T12
333A Abdominal Wall and Viscera [Above L4]: Midsagittal Section
333B Abdominal Wall and Viscera [Below L4]: Midsagittal Section

Pancreas [\[Back to regional\]](#)

120 Vagus Nerve: Schema
165 Lumbar Region of Back: Cross Section
256 Omental Bursa: Cross Section
279A Pancreas in Situ
279B Pancreas: Histology
279C Pancreas
280A Variations in Pancreatic Ducts
280B Variations in Pancreatic Ducts [Continued]
283 Arteries of Stomach, Duodenum, Pancreas and Spleen
284 Arteries of Liver, Pancreas, Duodenum and Spleen
285A Arteries of Duodenum and Head of Pancreas: Reflected to Left
285B Arteries of Duodenum and Head of Pancreas: Posterior View
294A Veins of Stomach, Duodenum and Pancreas
294B Veins of Stomach, Duodenum and Pancreas [Continued]
297 Portal Vein Tributaries: Portacaval Anastomoses
299B Lymph Vessels and Nodes of Stomach: Stomach Reflected
303A Lymph Vessels and Nodes of Pancreas: Anterior View
303B Lymph Vessels and Nodes of Pancreas: Posterior View
314A Common Areas of Pancreatic Pain
314B Innervation of Pancreas: Schema
314C Schema of Intrinsic Nerve Supply of Pancreas
333A Abdominal Wall and Viscera [Above L4]: Midsagittal Section
333B Abdominal Wall and Viscera [Below L4]: Midsagittal Section

External genitalia(male) [\[Back to regional\]](#)

232 Anterior Abdominal Wall: Superficial Dissection
233 Anterior Abdominal Wall: Intermediate Dissection
234 Anterior Abdominal Wall: Deep Dissection
238 Arteries of Anterior Abdominal Wall
239 Veins of Anterior Abdominal Wall
240 Nerves of Anterior Abdominal Wall
243A Inguinal Region: Dissection - Anterior View
333A Abdominal Wall and Viscera [Above L4]: Midsagittal Section

333B Abdominal Wall and Viscera [Below L4]: Midsagittal Section
342A Pelvic Viscera and Perineum of Male: Paramedian Sagittal Section
342B Pelvic Viscera and Perineum of Male: Midsagittal Section
358A Perineum and External Genitalia of Male: Superficial Dissection
358B Perineum of Male: Regions [Triangles] and Surface Topography
359A Perineum and External Genitalia of Male: Deep Dissection
359B Section through Body of Penis
360A Penis
360B Penis [Continued]
363 Urethra: Male
364A Descent of Testis: 8 Weeks
364B Descent of Testis: 11 Weeks
364C Descent of Testis: 4 Lunar Months
364D Descent of Testis: 8 Lunar Months
365A Scrotum and Contents: Anterior View
365B Scrotum and Contents: Lateral View
366A Testis Epididymis and Ductus Deferens: Frontal Section
366B Testis Epididymis and Ductus Deferens: Schema
366C Testis Epididymis and Ductus Deferens: Cross Section
367A Rectum of Male in Situ
371A External Anal Sphincter Muscle of Male: Perineal View
372B Perineopelvic Spaces: Perineal View
376 Arteries and Veins of Testis
378A Arteries and Veins of Pelvis: Male - Left Paramedian Section
380A Arteries and Veins of Perineum: Male
380B Arteries and Veins of Perineum [Continued]: Male
383A Lymph Vessels and Nodes of Pelvis and Genitalia: Male
383B Lymphatic Drainage from Prostate
384 Nerves of External Genitalia: Male
386A Nerves of Perineum: Male - Perineal View
393A Homologues of External Genitalia: Undifferentiated Stage
393B Homologues of External Genitalia: Fully Developed Male and Female

Pelvic structure(male) [\[Back to regional\]](#)

236 Anterior Abdominal Wall: Internal View
245 Inguinal Canal and Spermatic Cord
333A Abdominal Wall and Viscera [Above L4]: Midsagittal Section
333B Abdominal Wall and Viscera [Below L4]: Midsagittal Section
340 Pelvic Diaphragm of Male: Inferior View
342A Pelvic Viscera and Perineum of Male: Paramedian Sagittal Section
342B Pelvic Viscera and Perineum of Male: Midsagittal Section
344 Pelvic Contents of Male: Superior View
347B Urinary Bladder of Male: Frontal Section
361A Urogenital Diaphragm of Male: Dissection
361B Urogenital Diaphragm of Male: Deep Dissection
361C Urogenital Diaphragm of Male: Frontal Section - Schema
362A Prostate and Seminal Vesicles: Frontal Section
362B Prostate and Seminal Vesicles: Sagittal Section
362C Prostate and Seminal Vesicles: Posterior View
362D Prostate and Seminal Vesicles: Cross Section through Prostate
363 Urethra: Male
367A Rectum of Male in Situ
371B External Anal Sphincter Muscle of Female: Perineal View
372A Perineopelvic Spaces: Sagittal Section
376 Arteries and Veins of Testis
378A Arteries and Veins of Pelvis: Male - Left Paramedian Section
378B Arterial Supply of Prostate
380A Arteries and Veins of Perineum: Male
380B Arteries and Veins of Perineum [Continued]: Male
383A Lymph Vessels and Nodes of Pelvis and Genitalia: Male
383B Lymphatic Drainage from Prostate
384 Nerves of External Genitalia: Male
385 Nerves of Pelvic Viscera: Male
386A Nerves of Perineum: Male - Perineal View
391 Innervation of Male Reproductive Organs: Schema
394A Homologues of Internal Genitalia: Undifferentiated Stage
394B Homologues of Internal Genitalia: Fully Developed Male and Female

Mammary gland(female) [\[Back to regional\]](#)

167A Mammary Gland: Anterolateral Dissection
167B Mammary Gland: Sagittal Section
168 Arteries of Mammary Gland
169 Lymph Vessels and Nodes of Mammary Gland

External genitalia(female) [\[Back to regional\]](#)

341A Pelvic Viscera and Perineum of Female: Midsagittal Section
341B Pelvic Viscera and Perineum of Female: Paramedian Sagittal Section
346A Urinary Bladder - Orientation and Supports: Midsagittal Section
347A Urinary Bladder of Female: Frontal Section
349 Uterus Vagina and Supporting Structures
354A Perineum and External Genitalia of Female
354B Perineum and External Genitalia of Female [Continued]
355A Perineum of Female: Superficial Dissection
356A Perineum and Urogenital Diaphragm of Female
356B Perineum and Urogenital Diaphragm of Female: Deep Dissection
379A Arteries and Veins of Perineum: Female
382 Lymph Vessels and Nodes of Perineum: Female
388A Nerves of Perineum and External Genitalia: Female
388B Block Anesthesia of Perineal Area: Primarily Pudendal Nerve

393A Homologues of External Genitalia: Undifferentiated Stage
393B Homologues of External Genitalia: Fully Developed Male and Female

Pelvic structure(female) [\[Back to regional\]](#)

337A Pelvic Diaphragm of Female: Superior View
337B Pelvic Diaphragm of Female: Medial View
338A Pelvic Diaphragm of Female: Inferior View
338B Pelvic Diaphragm of Female: Lateral View
341A Pelvic Viscera and Perineum of Female: Midsagittal Section
341B Pelvic Viscera and Perineum of Female: Paramedian Sagittal Section
343 Pelvic Contents of Female: Superior View
345 Endopelvic Fascia and Spaces of Female: Superior View
346A Urinary Bladder - Orientation and Supports: Midsagittal Section
347A Urinary Bladder of Female: Frontal Section
348A Pelvic Viscera of Female: Superior View - Peritoneum Intact
348B Pelvic Viscera of Female: Superior View - Peritoneum Removed
349 Uterus Vagina and Supporting Structures
350A Uterus and Adnexa: Posterior View
350B Uterus and Adnexa: Frontal Section
351A Uterus: Changes with Age
351B Uterus: Schema of Musculature
352A Uterus: Variations in Position
352B Uterus [Continued]: Variations in Position
353A Infant Ovary and Ripening Follicle: Histology
353B Stages of Ovum and Follicle
355B Perineum of Female: Midsagittal Section
356A Perineum and Urogenital Diaphragm of Female
356B Perineum and Urogenital Diaphragm of Female: Deep Dissection
367B Rectum of Female in Situ
375 Arteries and Veins of Pelvic Organs: Female
377A Arteries and Veins of Pelvis: Female - Sagittal Section
377B Arteries and Veins of Pelvis: Female - Right Paramedian Section
379B Arteries and Veins of Uterus
381 Lymph Vessels and Nodes of Pelvis and Genitalia: Female
389A Neuropathways in Parturition
389B Neuropathways in Parturition: Pelvic Area Enlarged
390 Innervation of Female Reproductive Organs: Schema
394A Homologues of Internal Genitalia: Undifferentiated Stage
394B Homologues of Internal Genitalia: Fully Developed Male and Female

Head and Neck [\[Back to regional\]](#)

66 Lymph Vessels and Nodes of Oral and Pharyngeal Regions
67A Lymphatic Drainage of Pharynx: Posterior View
67B Lymphatic Drainage of Tongue: Lateral View

Throat [\[Back to regional\]](#)

169 Lymph Vessels and Nodes of Mammary Gland
197 Lymph Vessels and Nodes of Lung
227 Lymph Vessels and Nodes of Esophagus
249 Lymph Vessels and Nodes of Posterior Abdominal Wall

Abdomen [\[Back to regional\]](#)

227 Lymph Vessels and Nodes of Esophagus
244B Femoral Sheath and Inguinal Canal [Deep]
249 Lymph Vessels and Nodes of Posterior Abdominal Wall
281A Spleen: Visceral and Diaphragmatic Surfaces
281B Spleen: Cross Section
281C Spleen in Situ
282 Arteries of Stomach Liver and Spleen
283 Arteries of Stomach Duodenum Pancreas and Spleen
284 Arteries of Liver Pancreas Duodenum and Spleen
299A Lymph Vessels and Nodes of Stomach
299B Lymph Vessels and Nodes of Stomach: Stomach Reflected
300 Lymph Vessels and Nodes of Small Intestine
301A Lymph Vessels and Nodes of Large Intestine
301B Lymph Vessels and Nodes of Large Intestine [Continued]
302A Lymph Vessels and Nodes of Liver: Histology
302B Lymph Vessels and Nodes of Liver
303A Lymph Vessels and Nodes of Pancreas: Anterior View
303B Lymph Vessels and Nodes of Pancreas: Posterior View
325 Lymph Vessels and Nodes of Kidneys and Urinary Bladder

Pelvis and Perinum [\[Back to regional\]](#)

249 Lymph Vessels and Nodes of Posterior Abdominal Wall
381 Lymph Vessels and Nodes of Pelvis and Genitalia: Female
382 Lymph Vessels and Nodes of Perineum: Female
383A Lymph Vessels and Nodes of Pelvis and Genitalia: Male
383B Lymphatic Drainage from Prostate

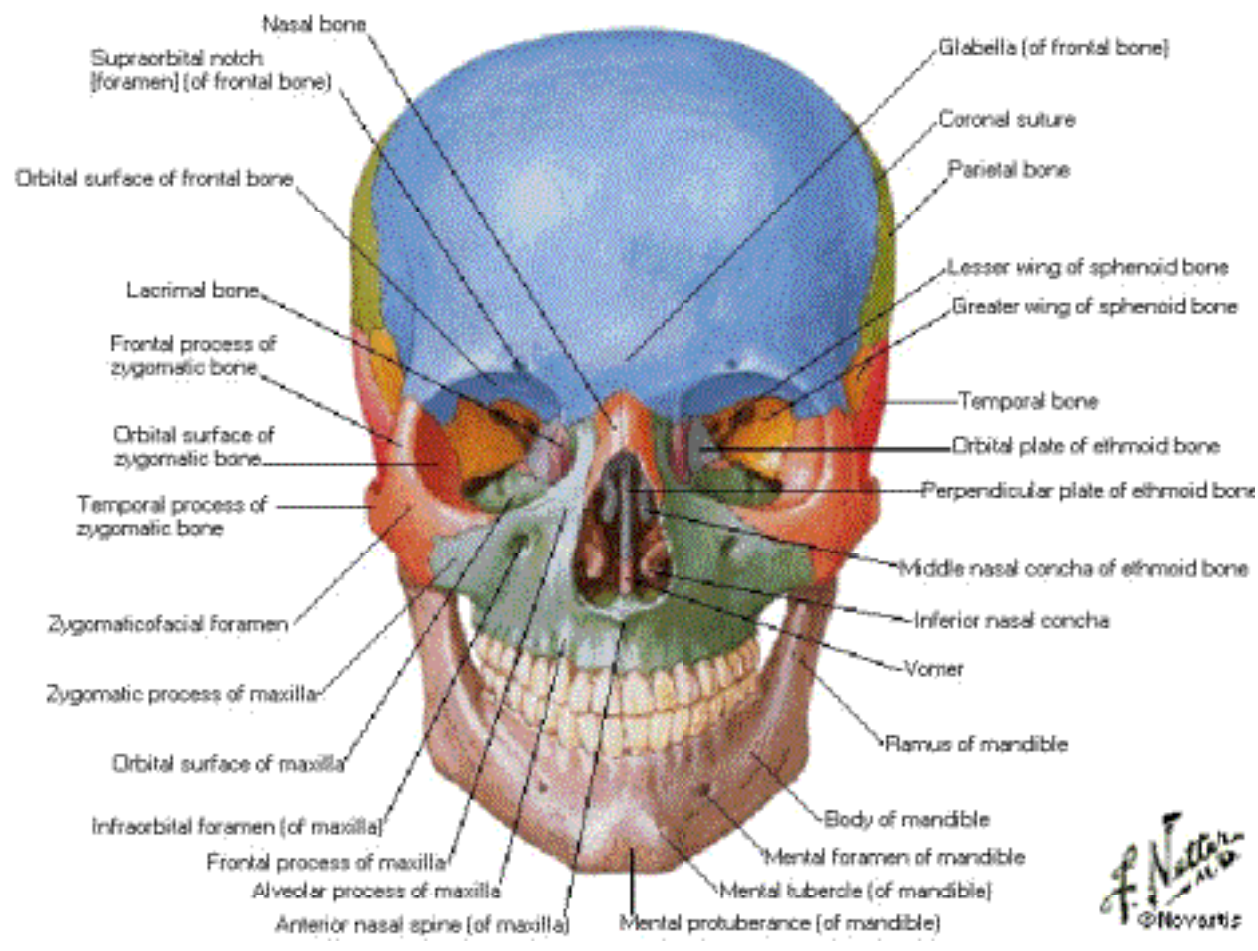
Limbs [\[Back to regional\]](#)

169 Lymph Vessels and Nodes of Mammary Gland
403B Pectoral, Claviopectoral and Axillary Fasciae: Section of Axilla
441 Wrist and Hand: Superficial Dorsal Dissection
456A Lymph Vessels and Nodes of Upper Limb

456B Lymph Vessels of Hand
514A Lymph Vessels and Nodes of Lower Limb: Anterior View
514B Lymph Vessels and Nodes of Lower Limb: Posterior View
514C Lymph Vessels and Nodes of Lower Limb: Inguinal Region

Skull

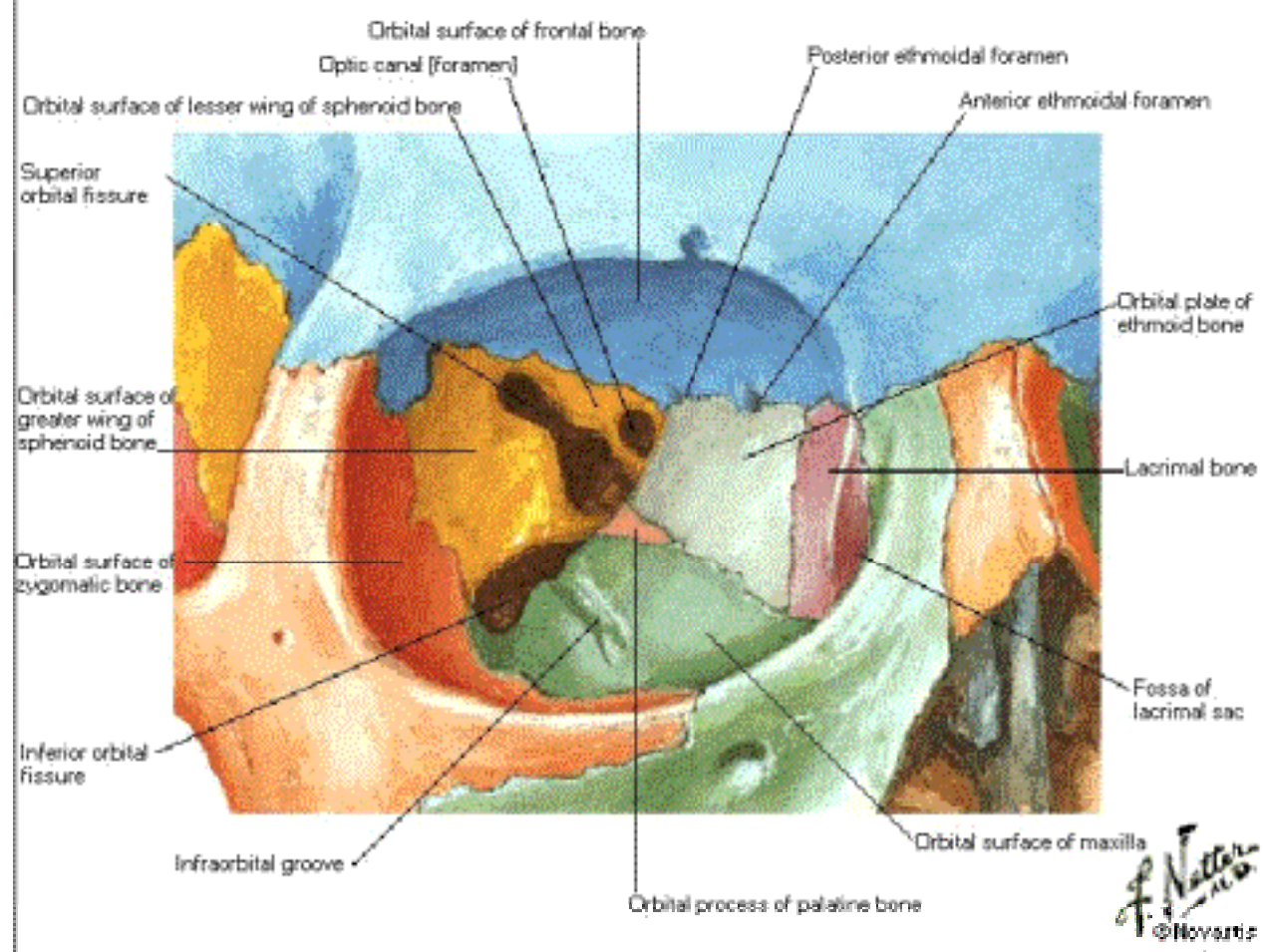
Anterior View



F. Netter
© Novartis

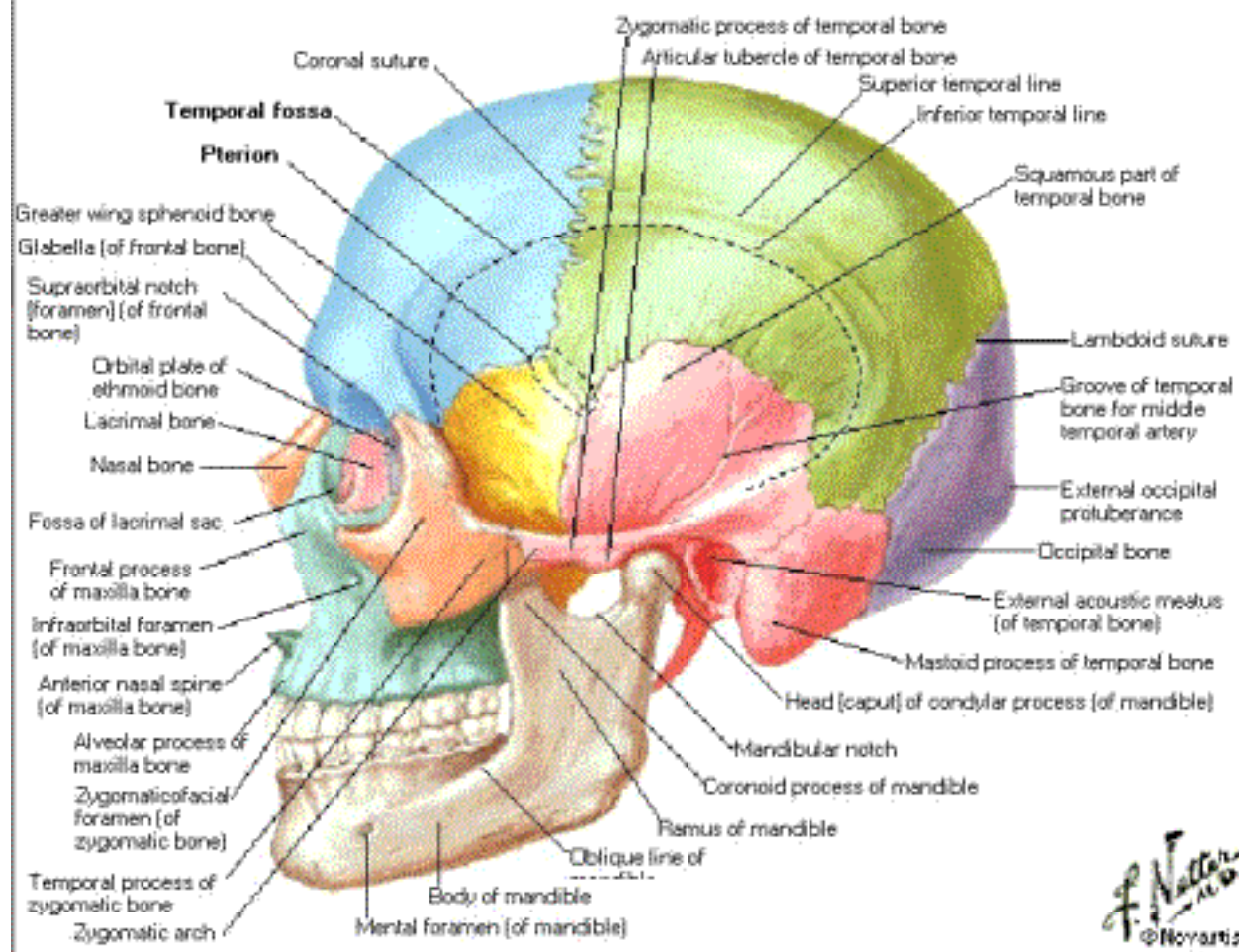
Right Orbit

Frontal and Slightly Lateral View



Skull

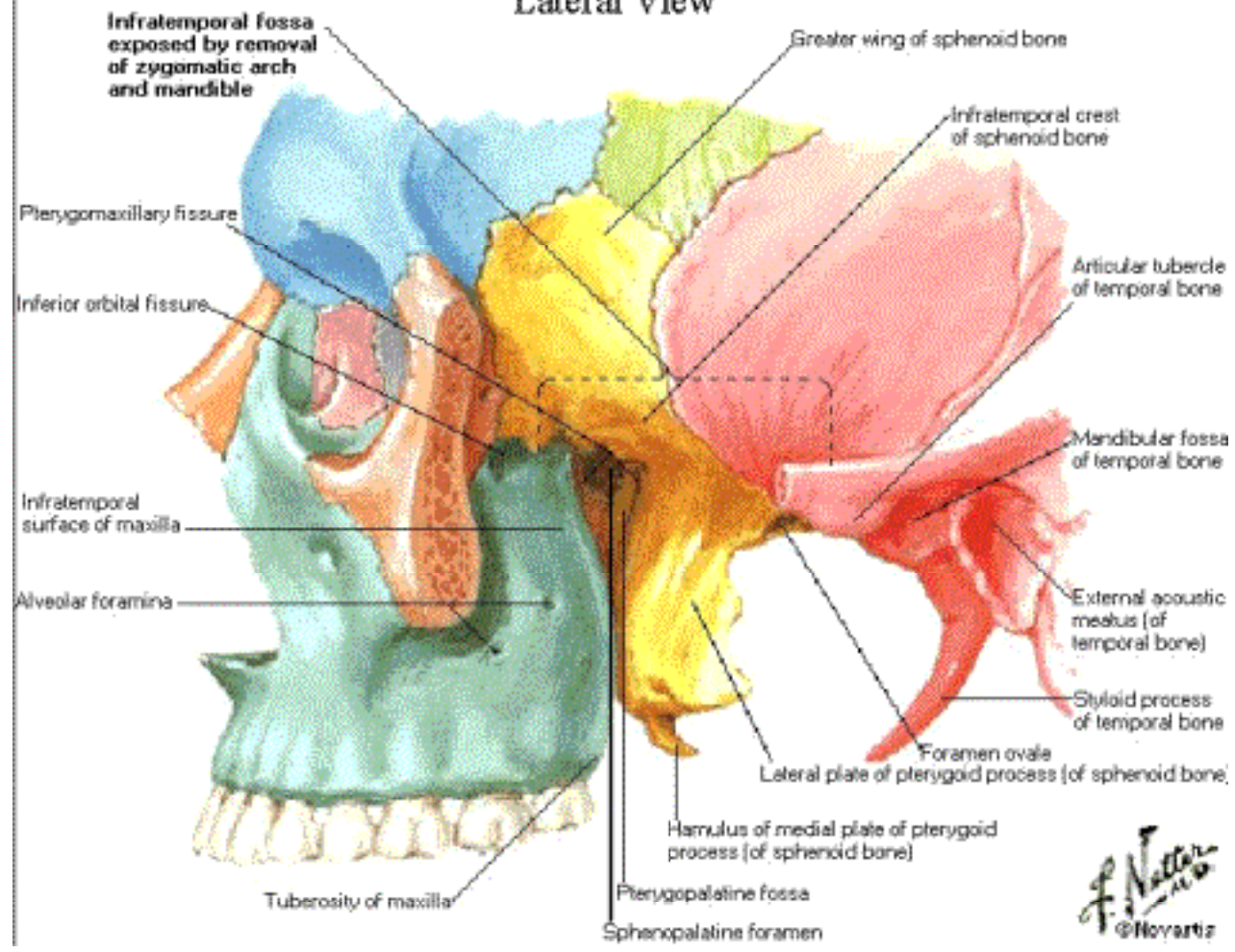
Lateral View



F. Netter M.D.
© Novartis

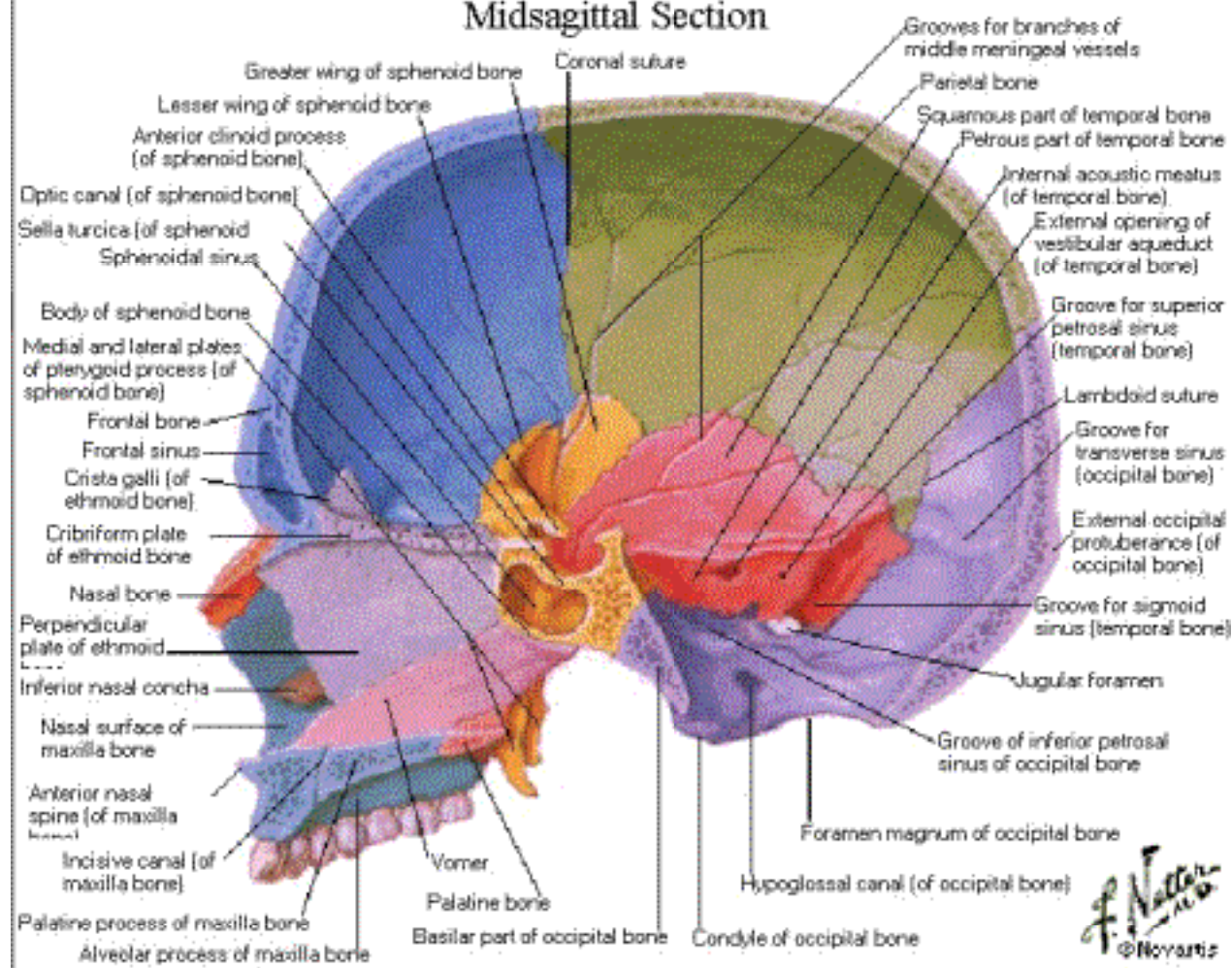
Skull - Infratemporal Fossa Exposed

Lateral View

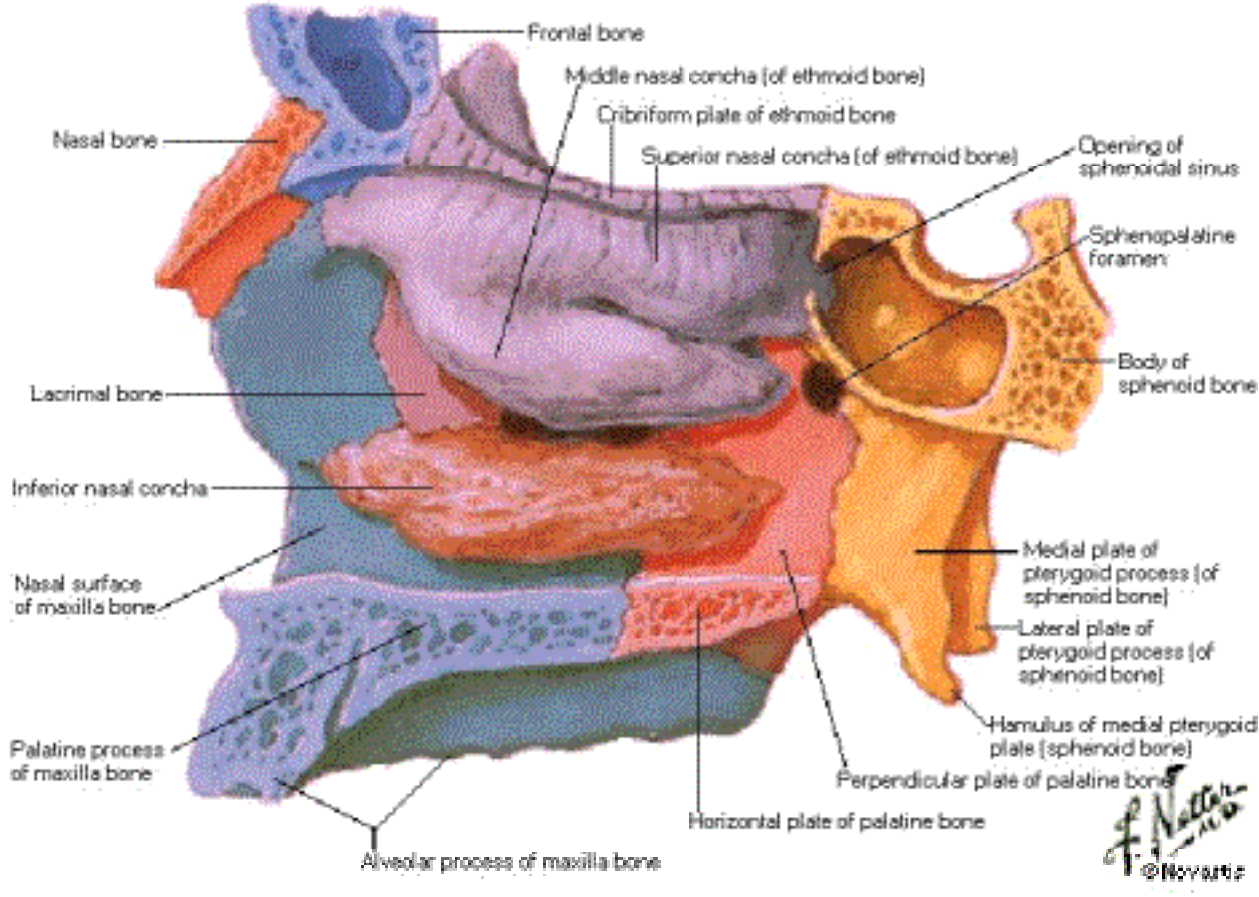


Skull

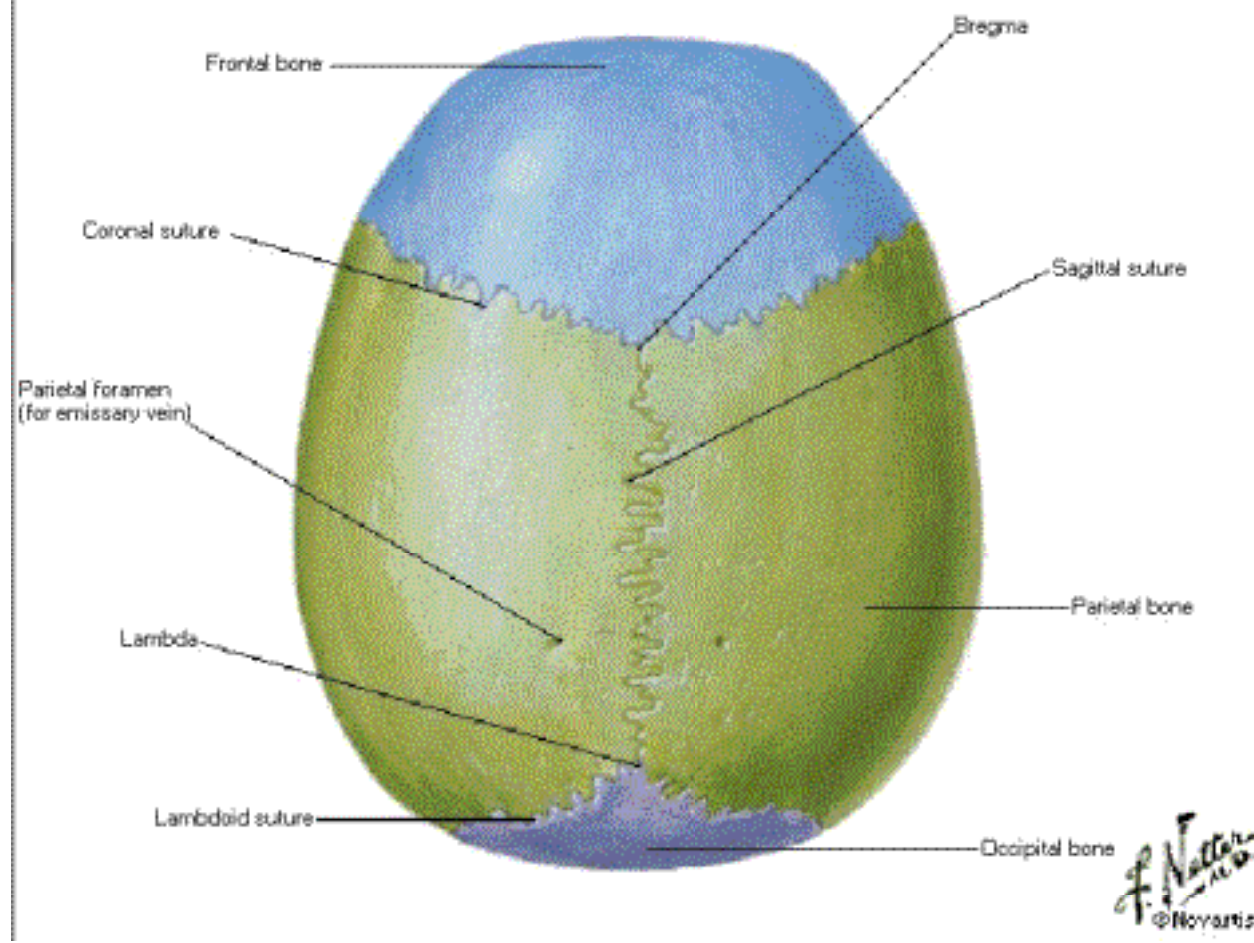
Midsagittal Section



Skull - Nasal Conchae Exposed
Sagittal Section

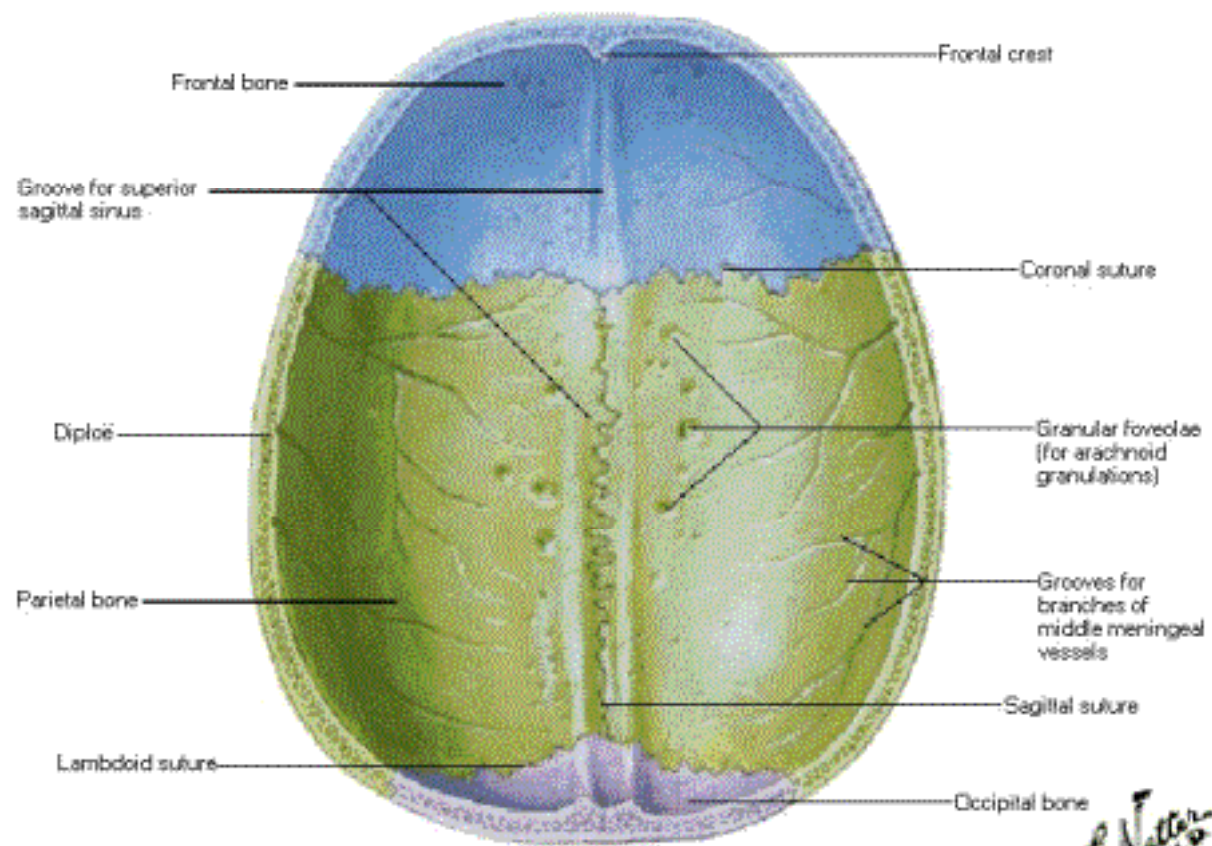


Calvaria Superior View



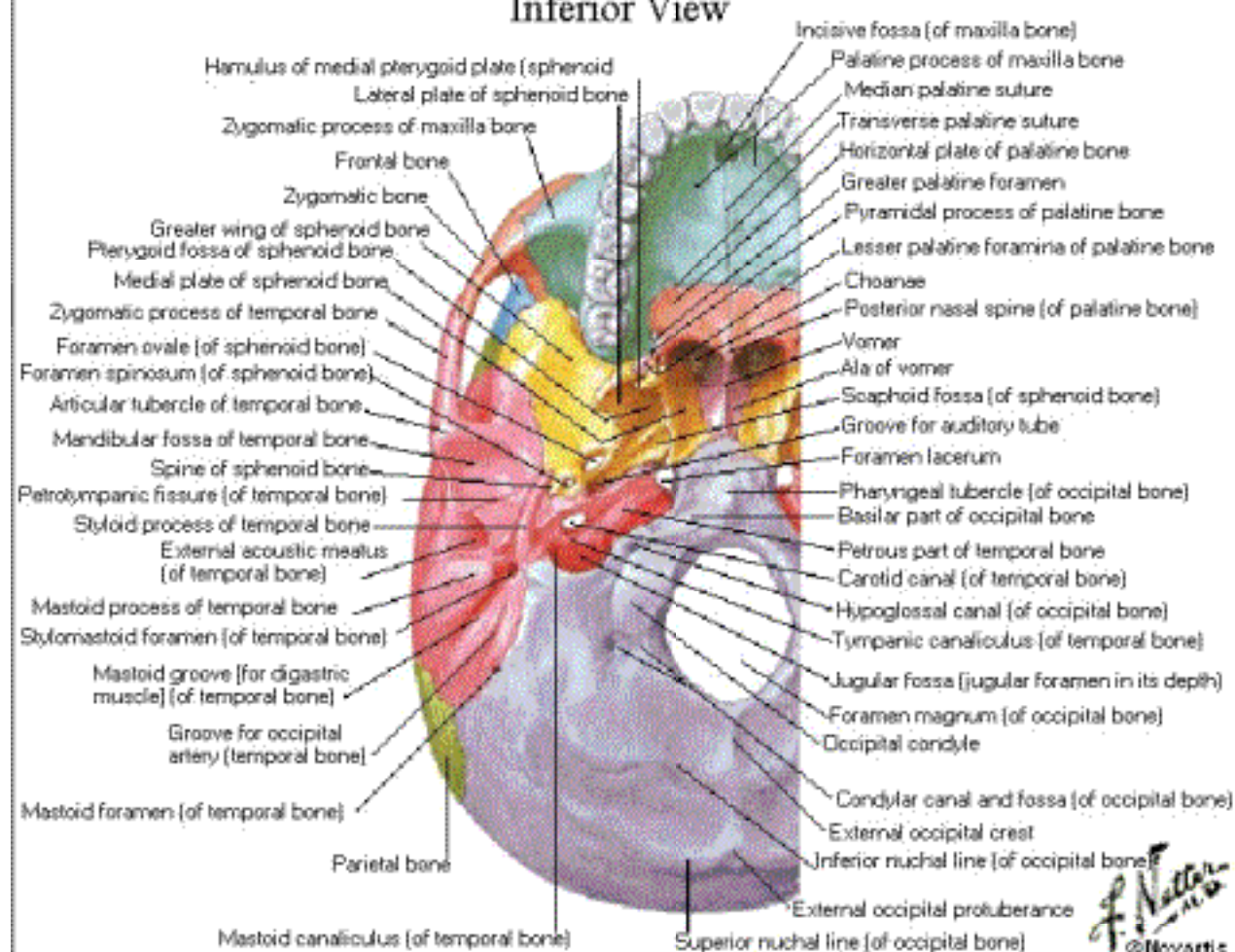
Calvaria

Inferior View



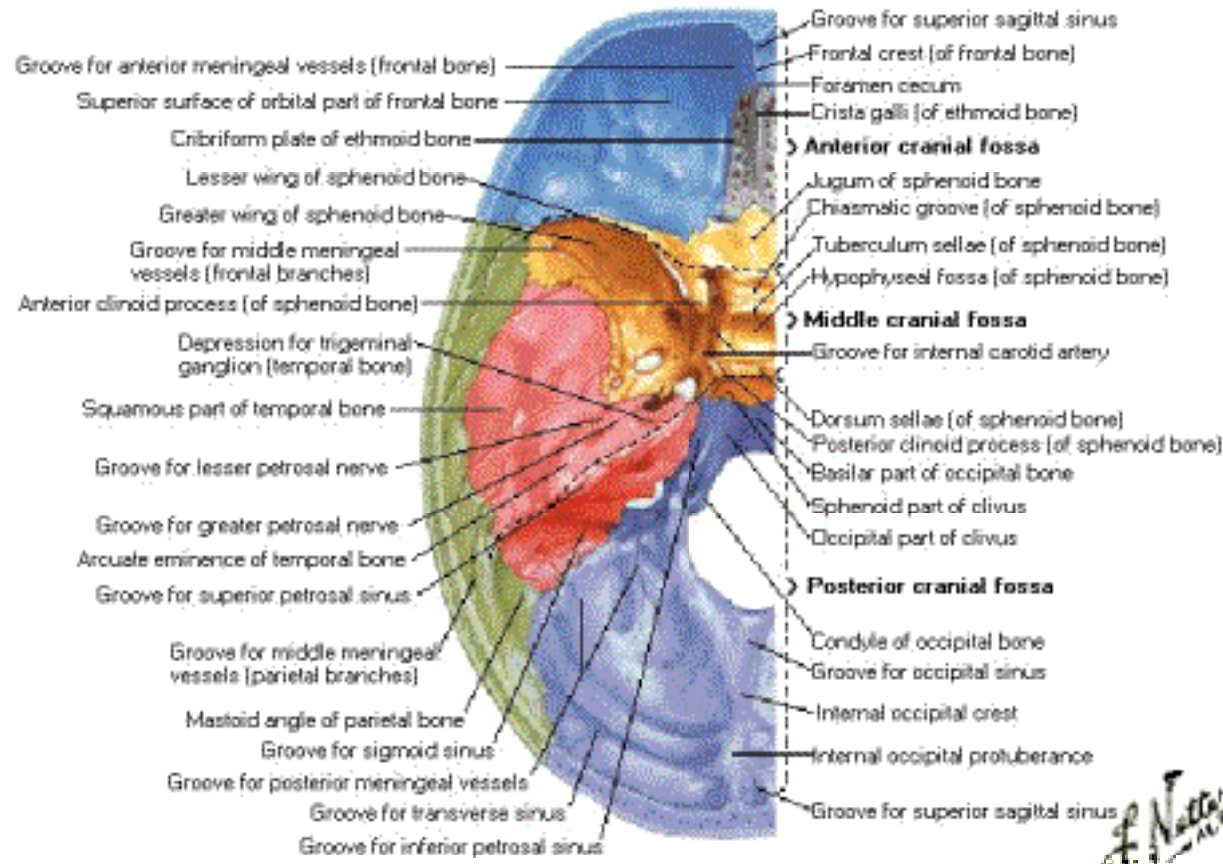
F. Netter M.D.
© Novartis

Cranial Base Inferior View



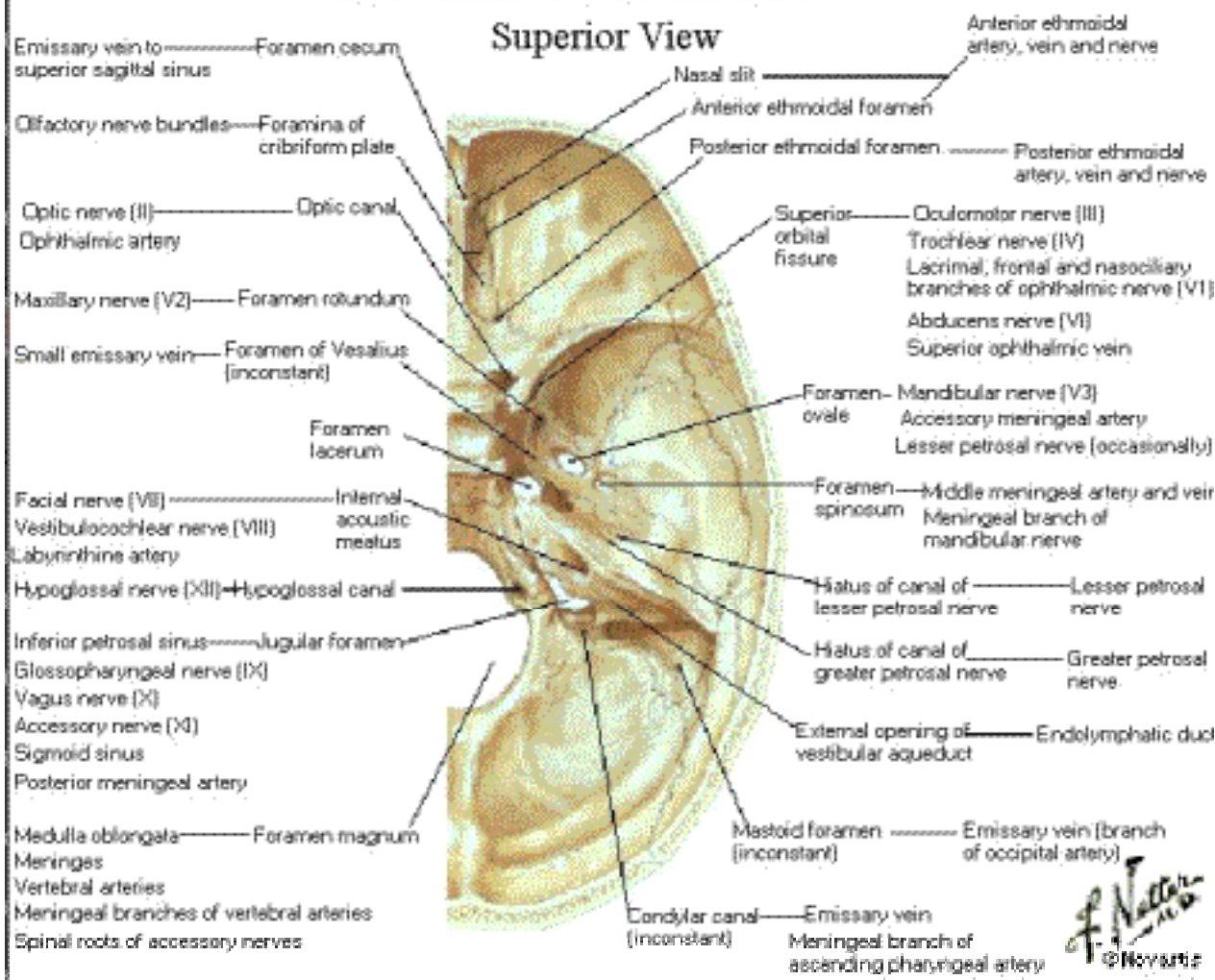
Bones of Cranial Base

Superior View



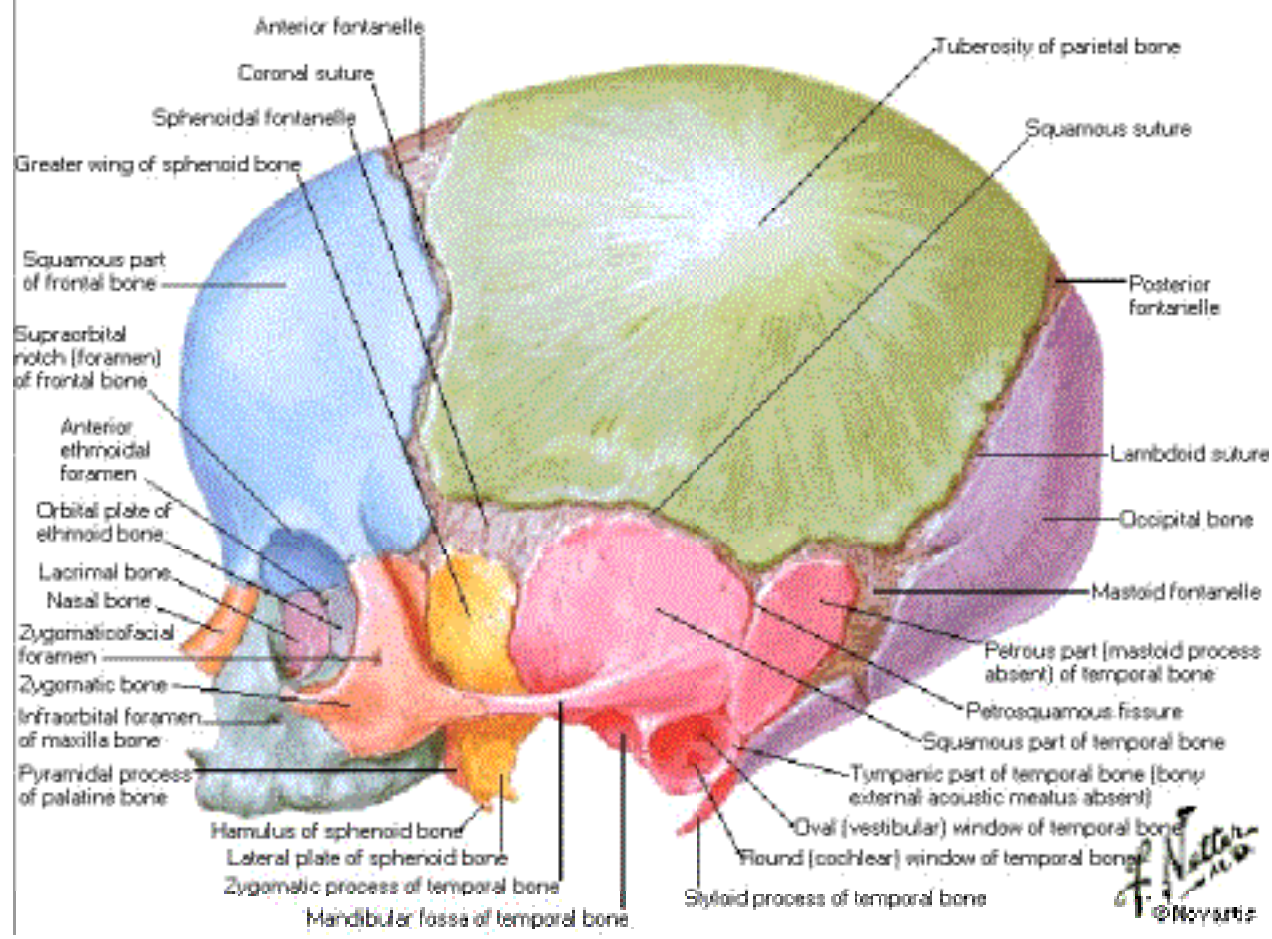
Foramina of Cranial Base

Superior View

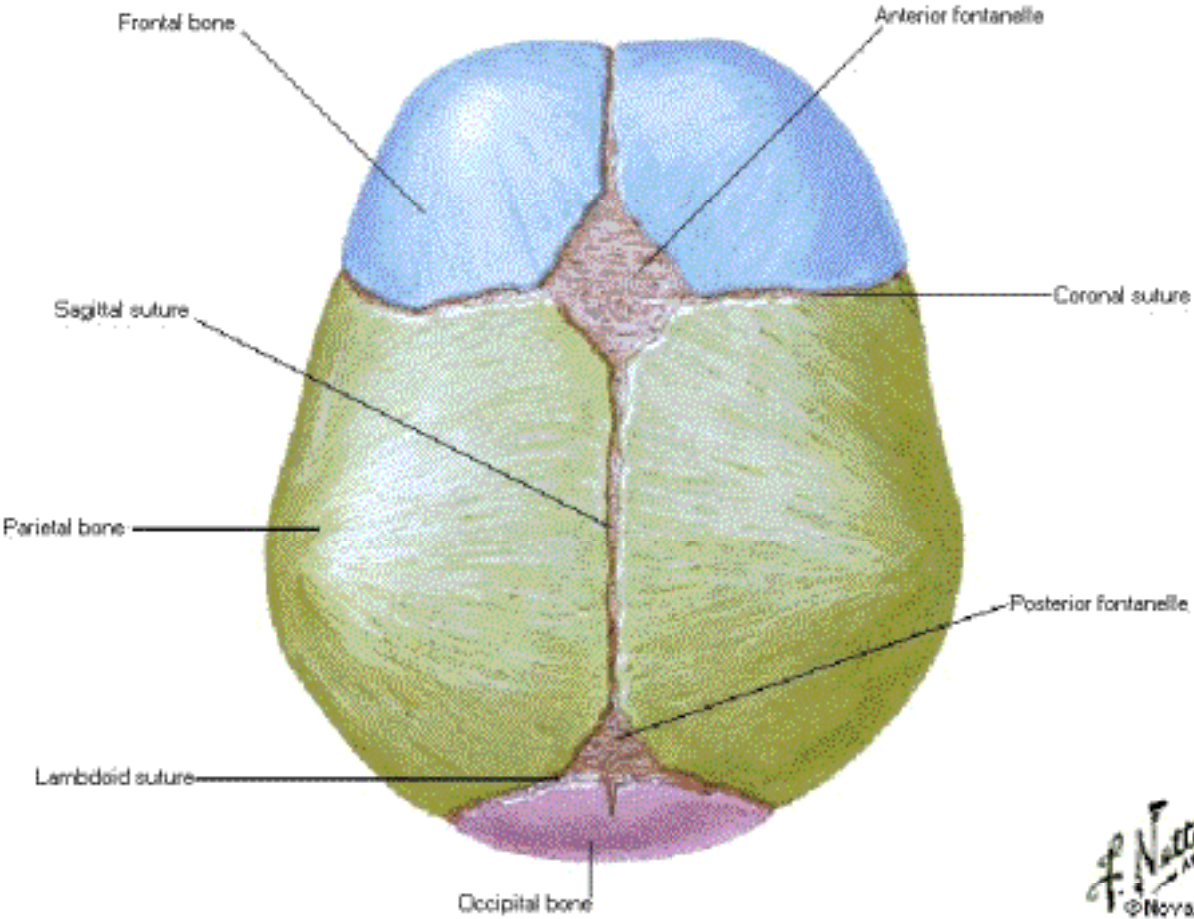


F. Netter M.D.
© 1974

Skull of Newborn Lateral View



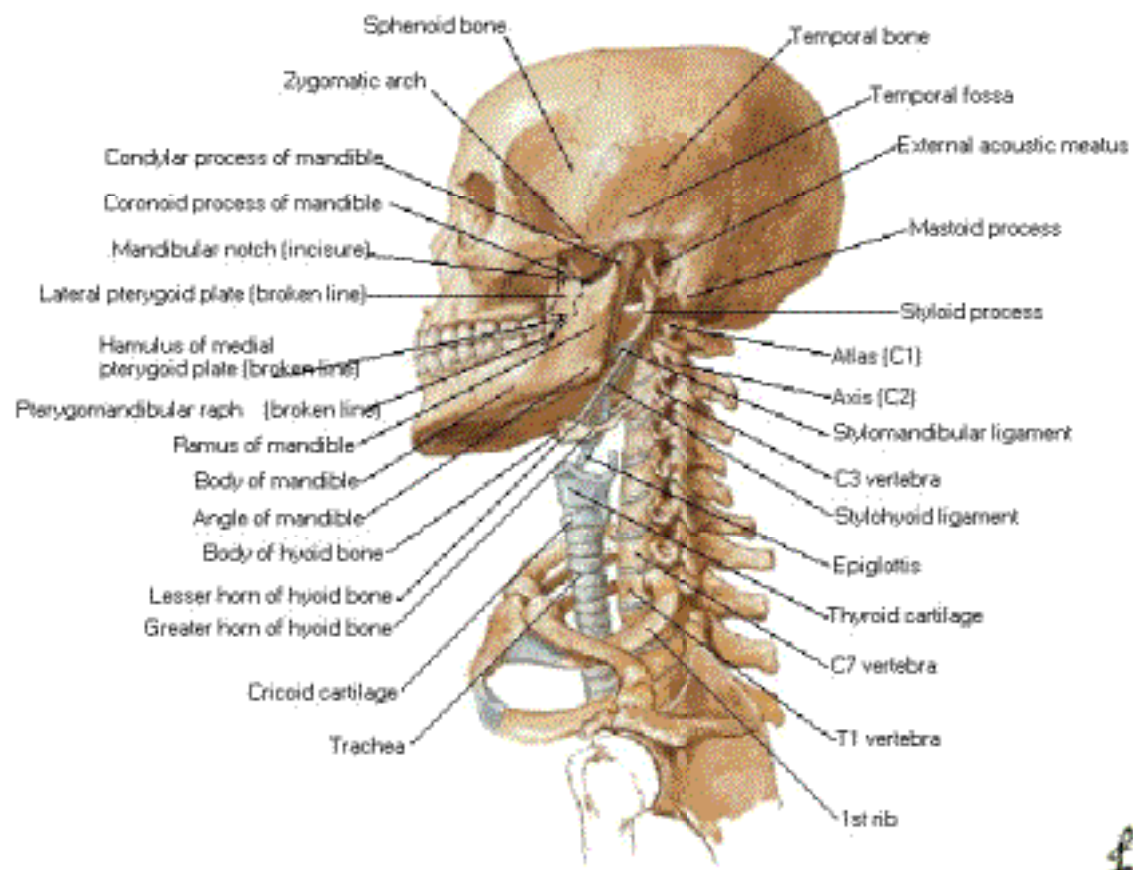
Skull of Newborn
Superior View



F. Netter
M.D.
© Novartis

Bony Framework of Head and Neck

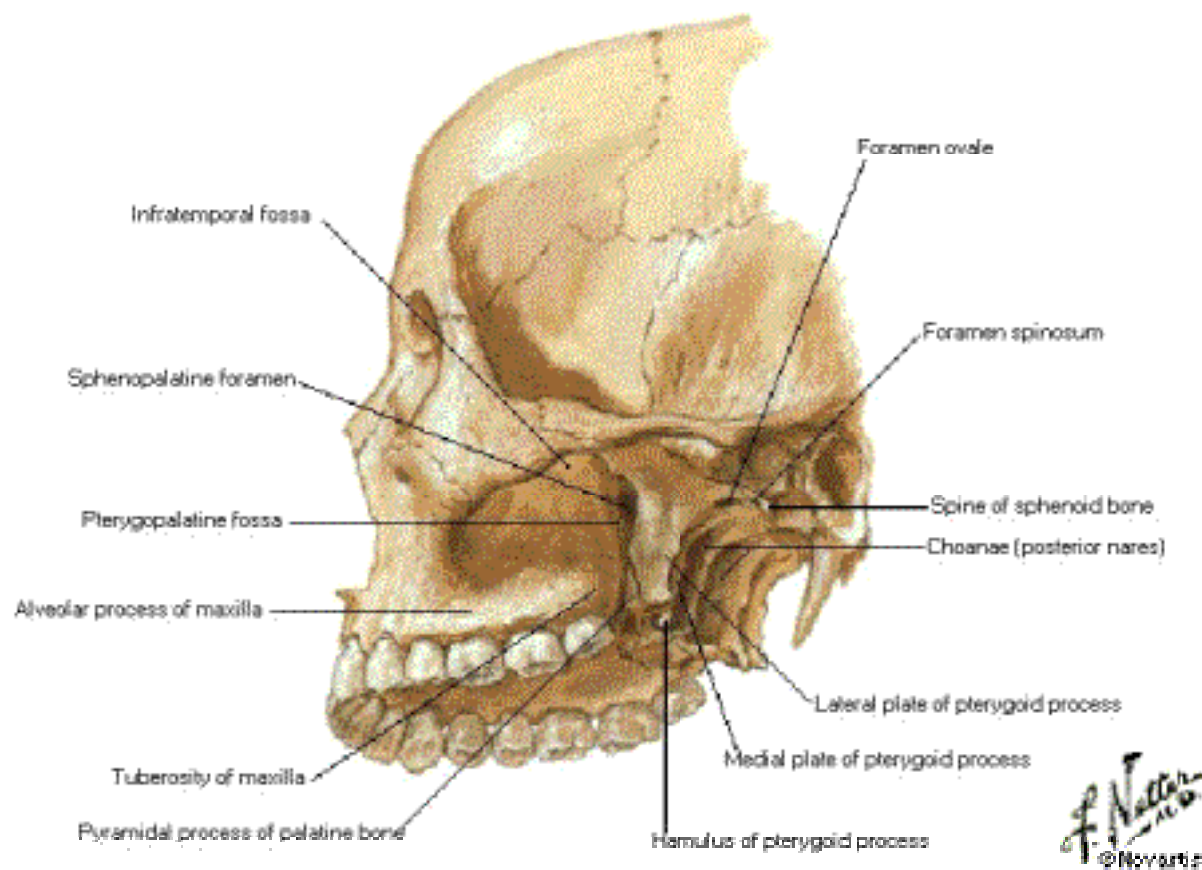
Lateral View



F. Netter M.D.
© 1989

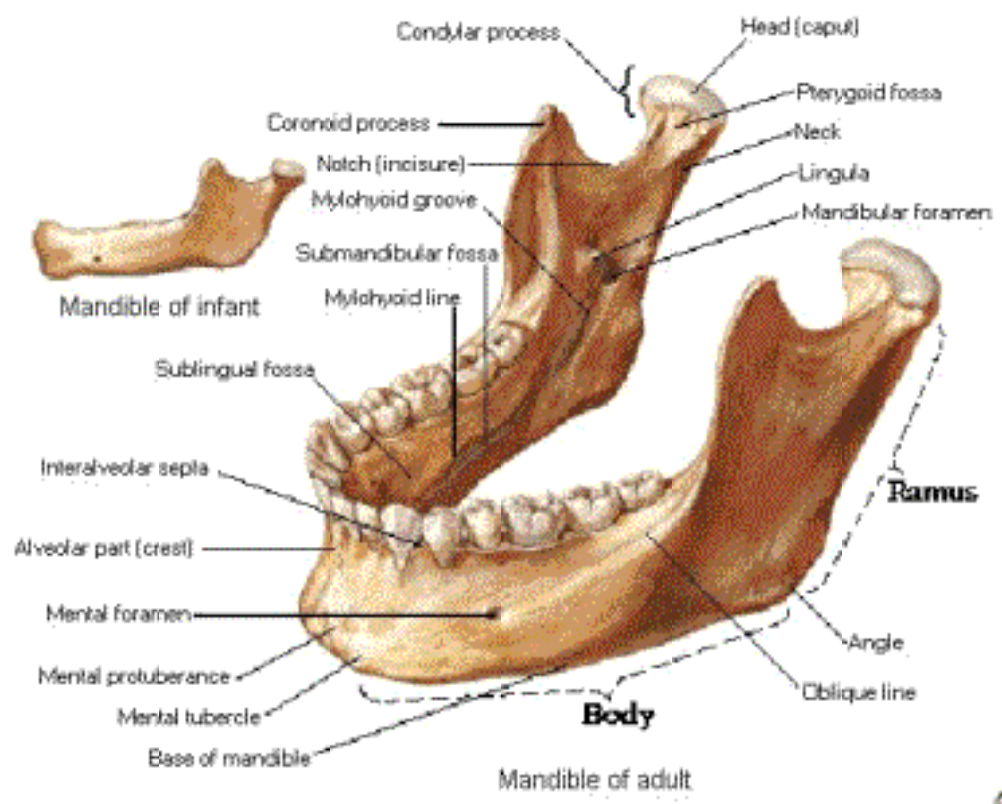
Bony Framework of Head - Mandible Removed

Lateral View



Mandible

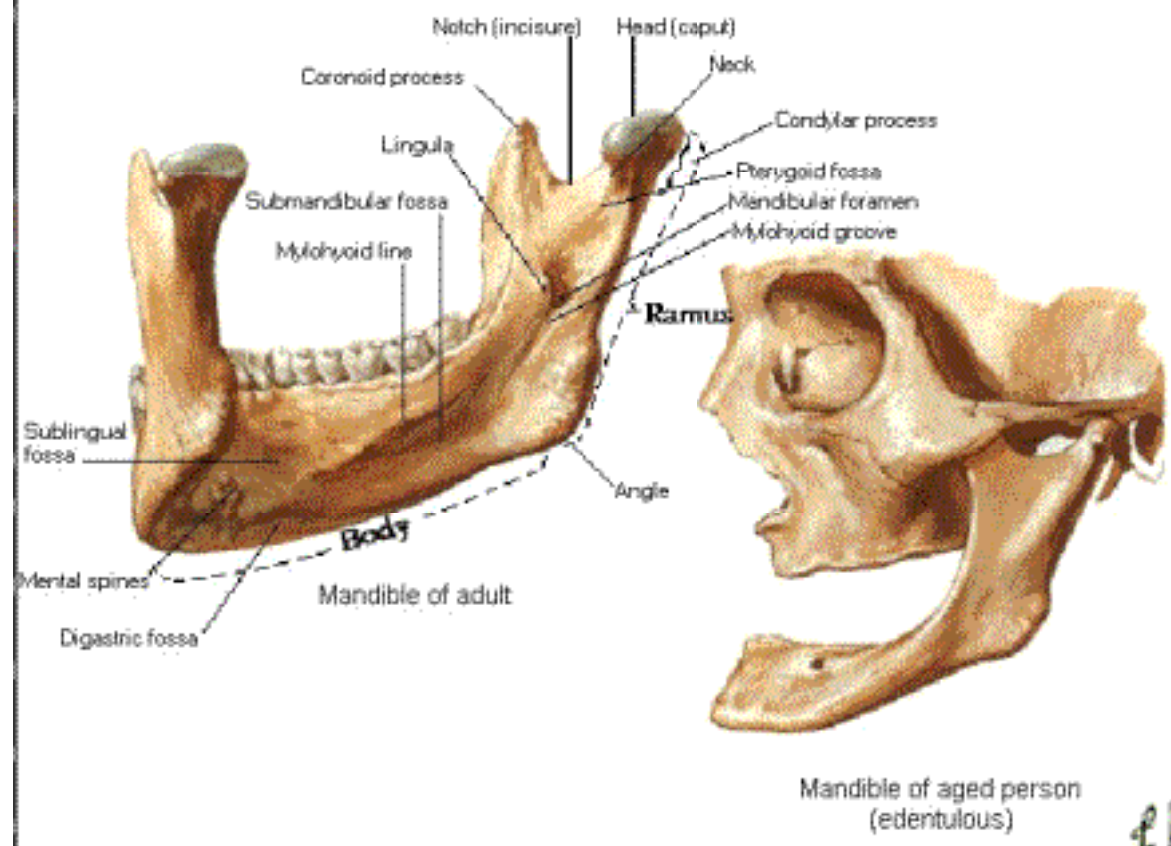
Anterolateral Superior View



F. Netter
© Novartis

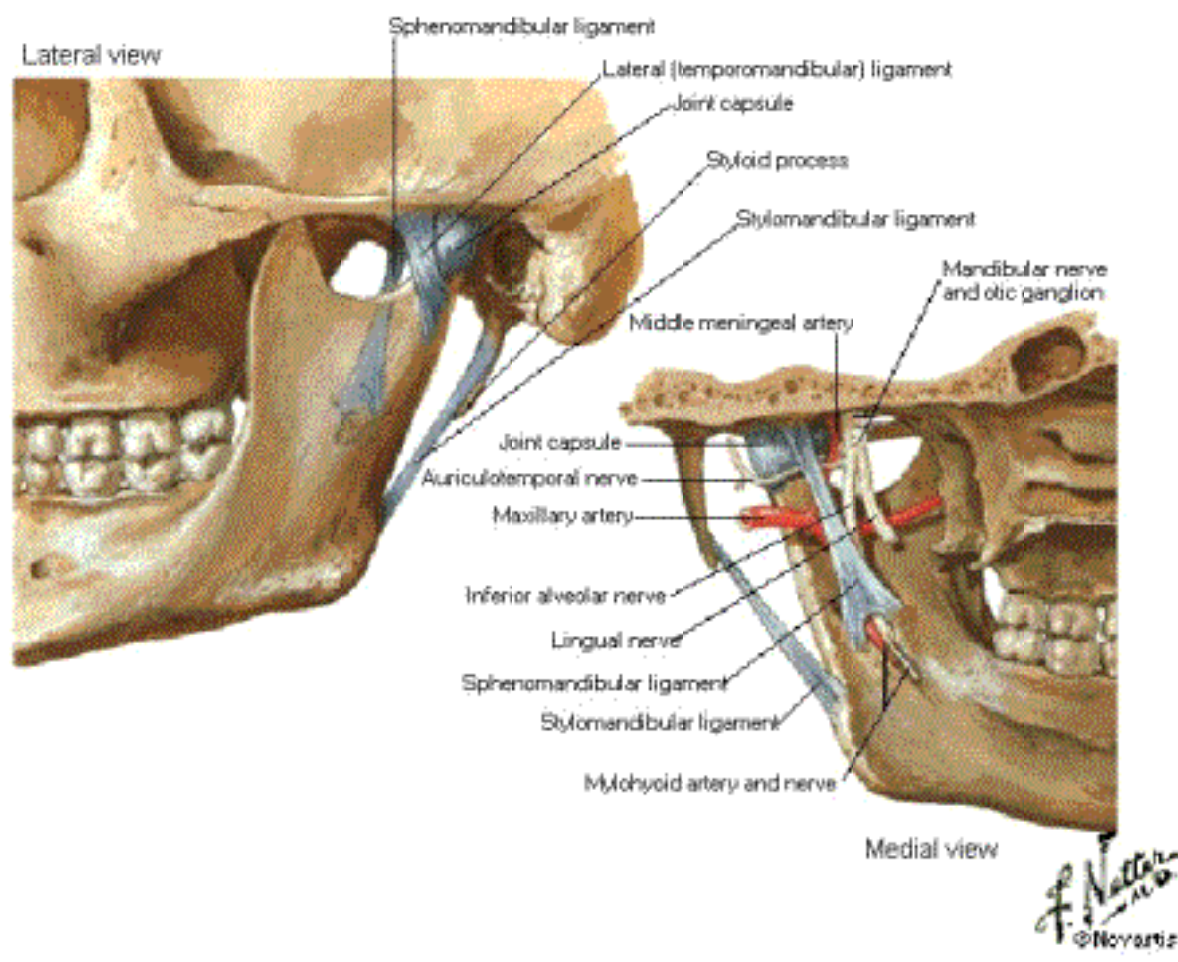
Mandible

Left Posterior View



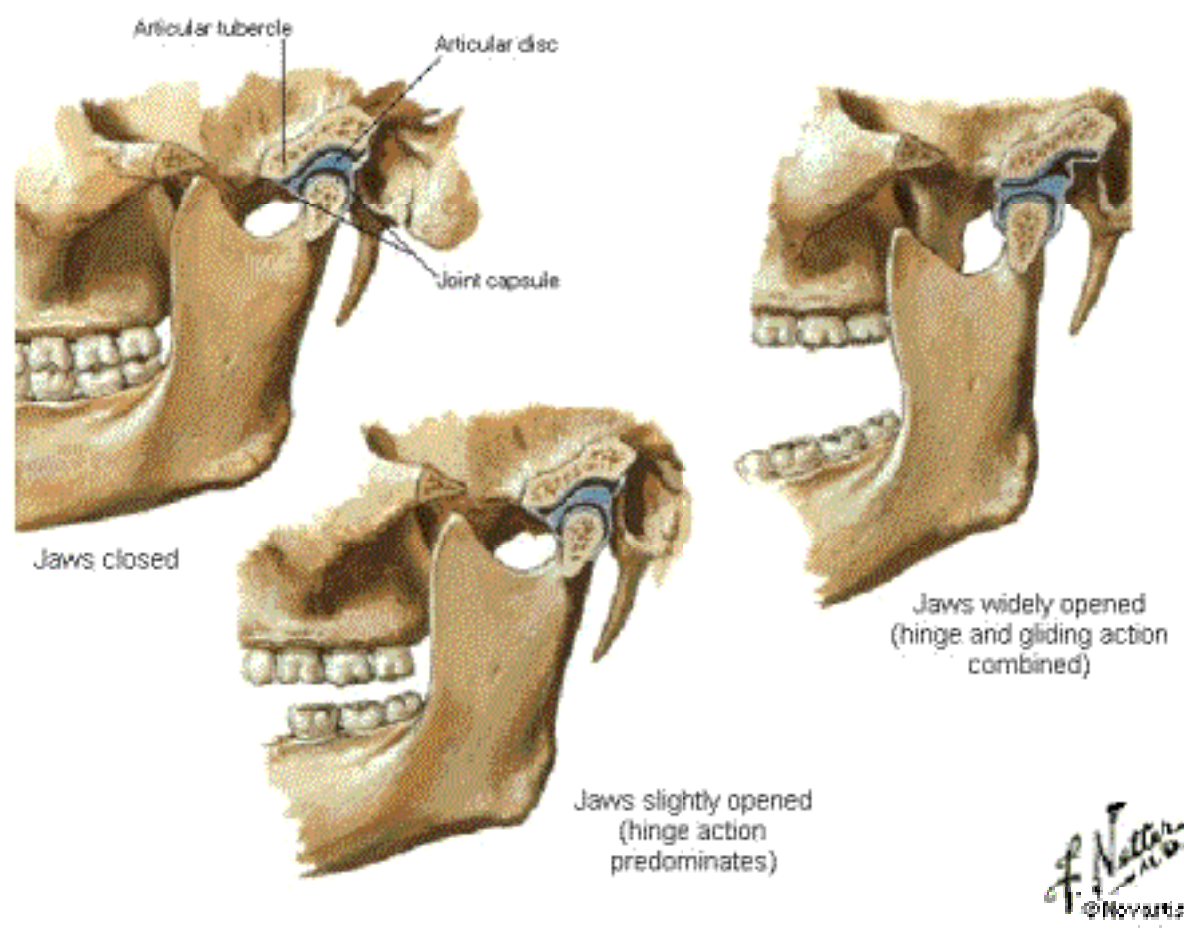
Temporomandibular Joint

Lateral and Medial Views



Temporomandibular Joint

Joint Action



Jaws closed

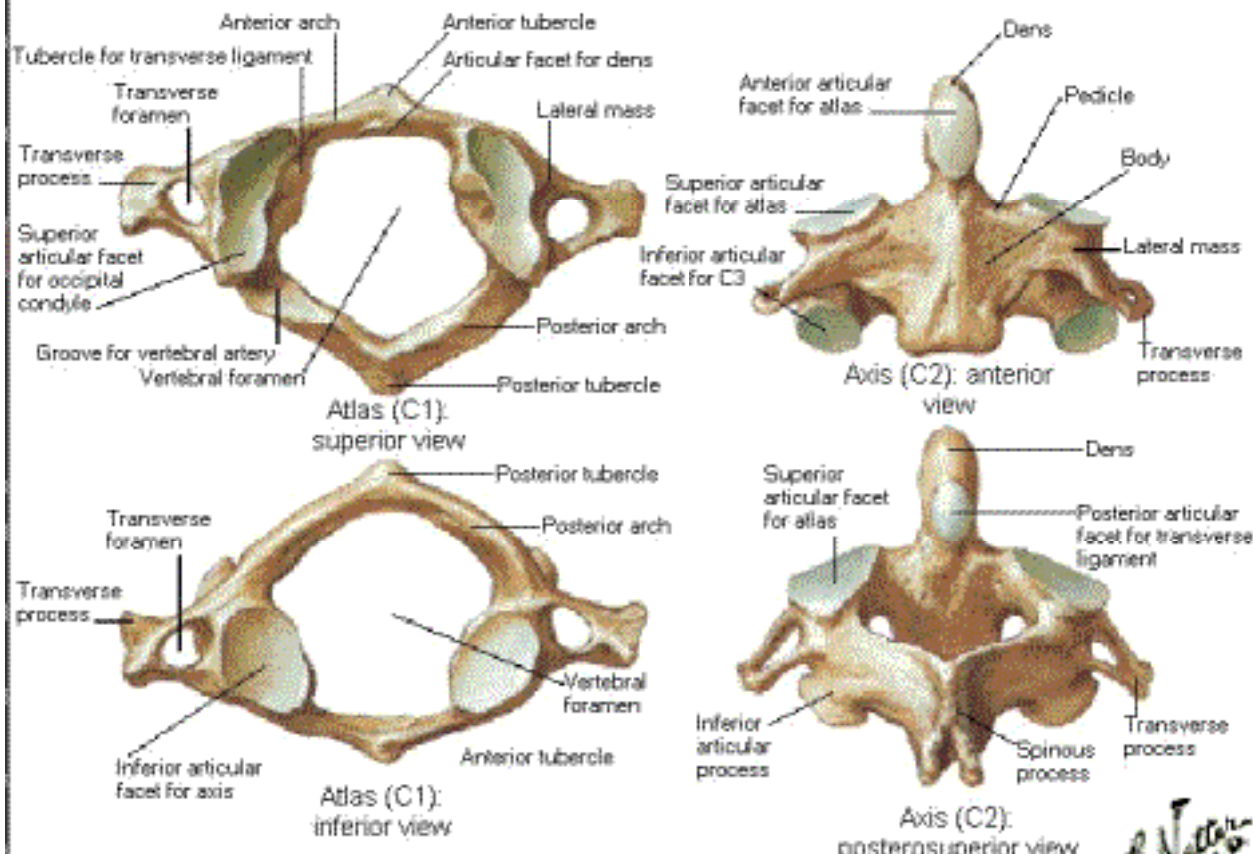
Jaws widely opened
(hinge and gliding action
combined)

Jaws slightly opened
(hinge action
predominates)

F. Netter
M.D.
© 1996 W.B. Saunders

Cervical Vertebrae

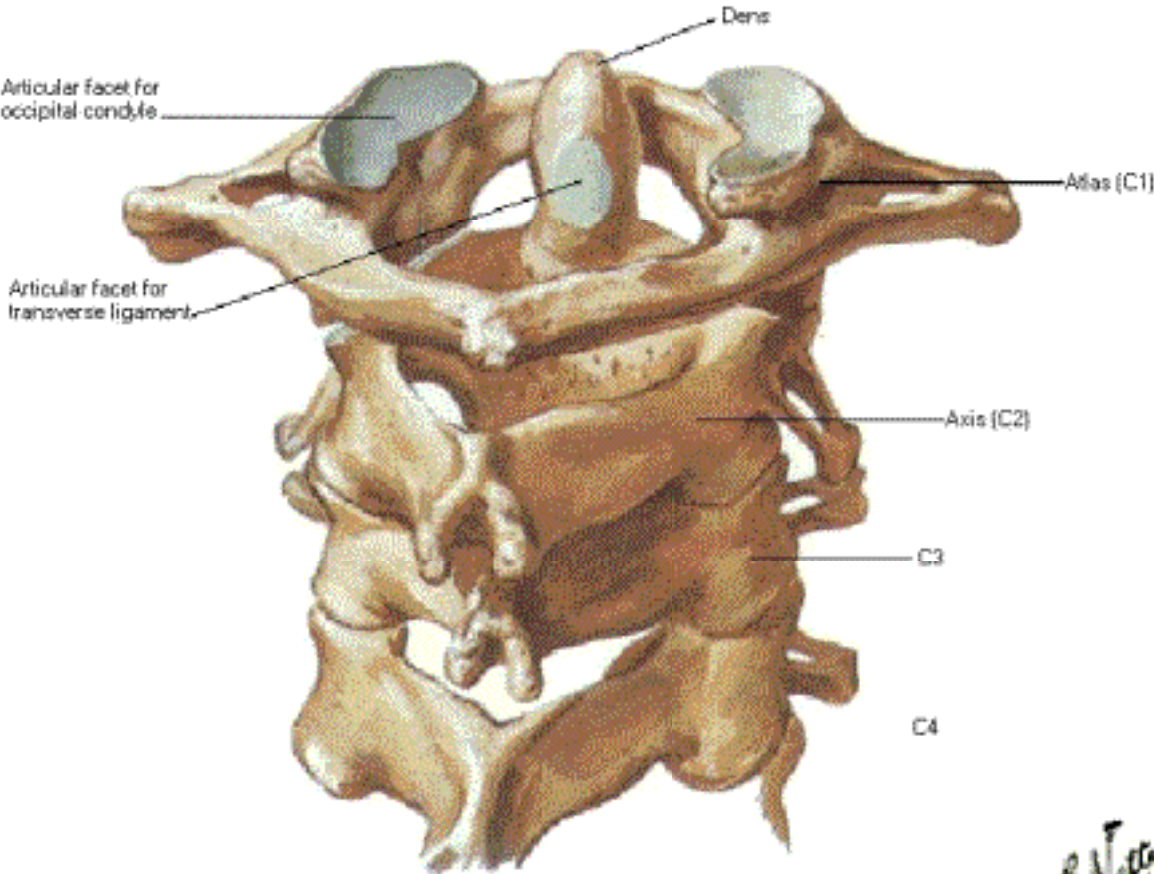
Atlas and Axis



F. Netter M.D.
© 1995

Cervical Vertebrae [C1-C4], Assembled

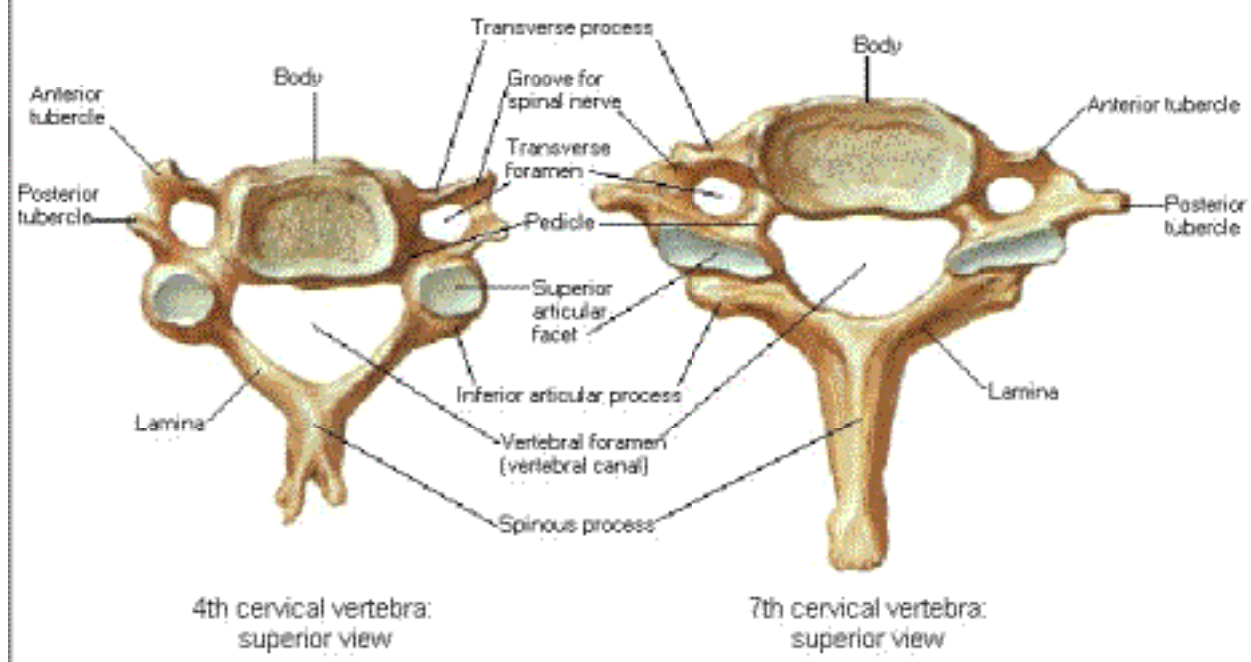
Posterosuperior View



F. Netter
M.D.
© Novartis

Cervical Vertebrae [C4 and C7]

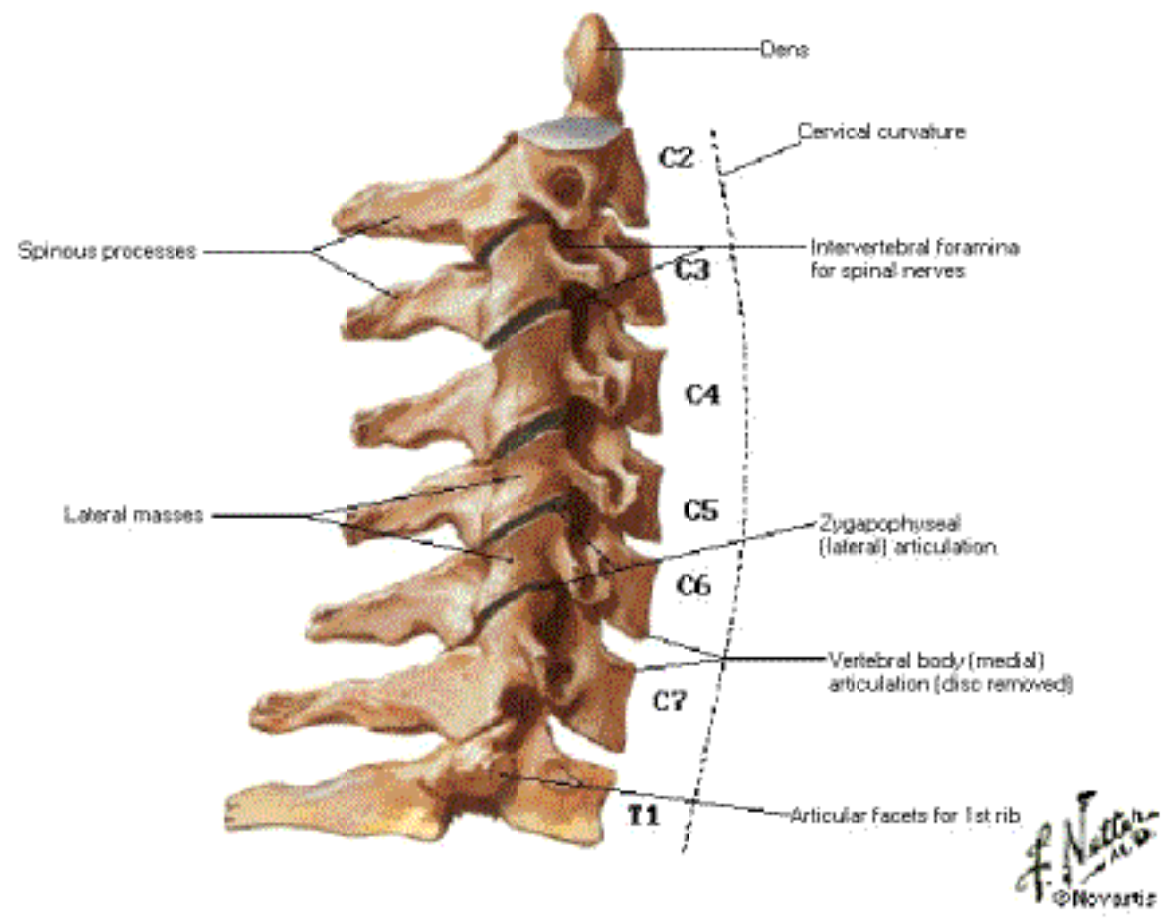
Superior Views



F. Netter M.D.
© Novartis

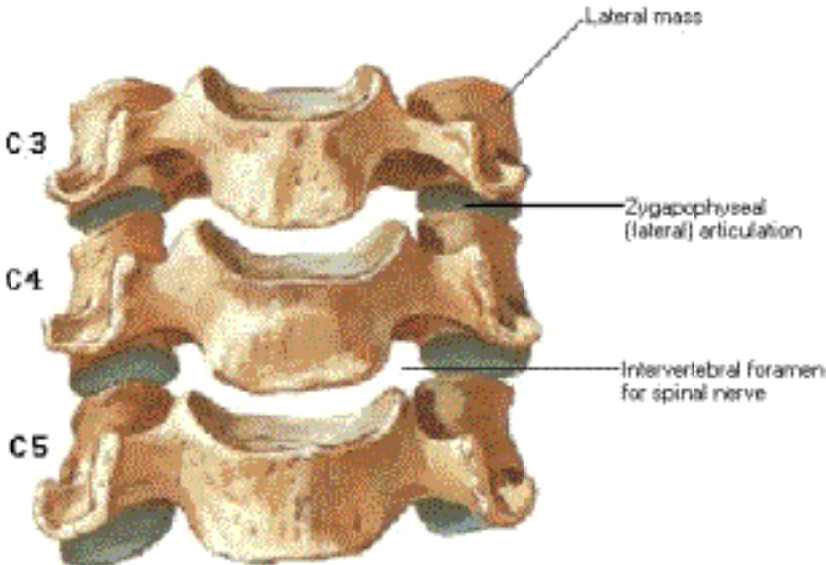
Cervical Vertebrae [C2-T1], Assembled

Right Lateral View



Cervical Vertebrae [C3-C5], Assembled

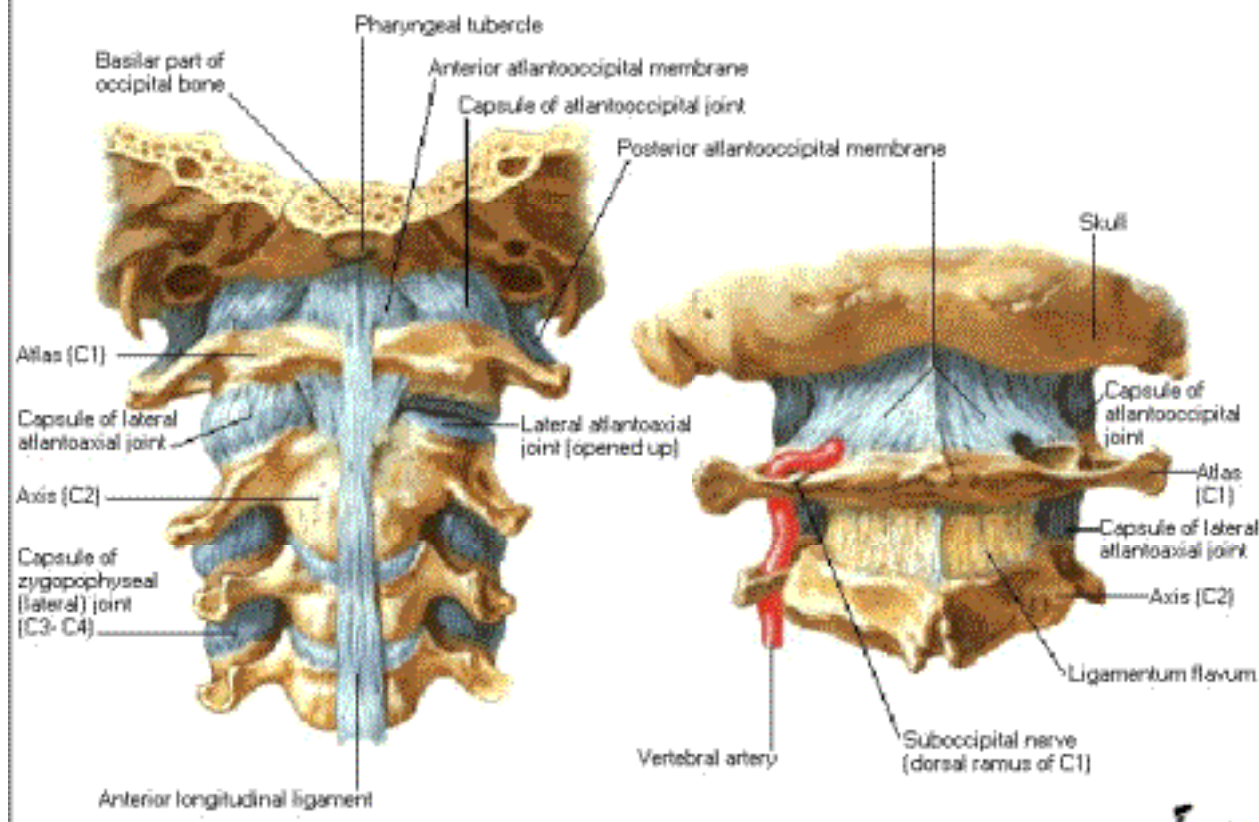
Anterior View



F. Netter M.D.
© Novartis

External Craniocervical Ligaments

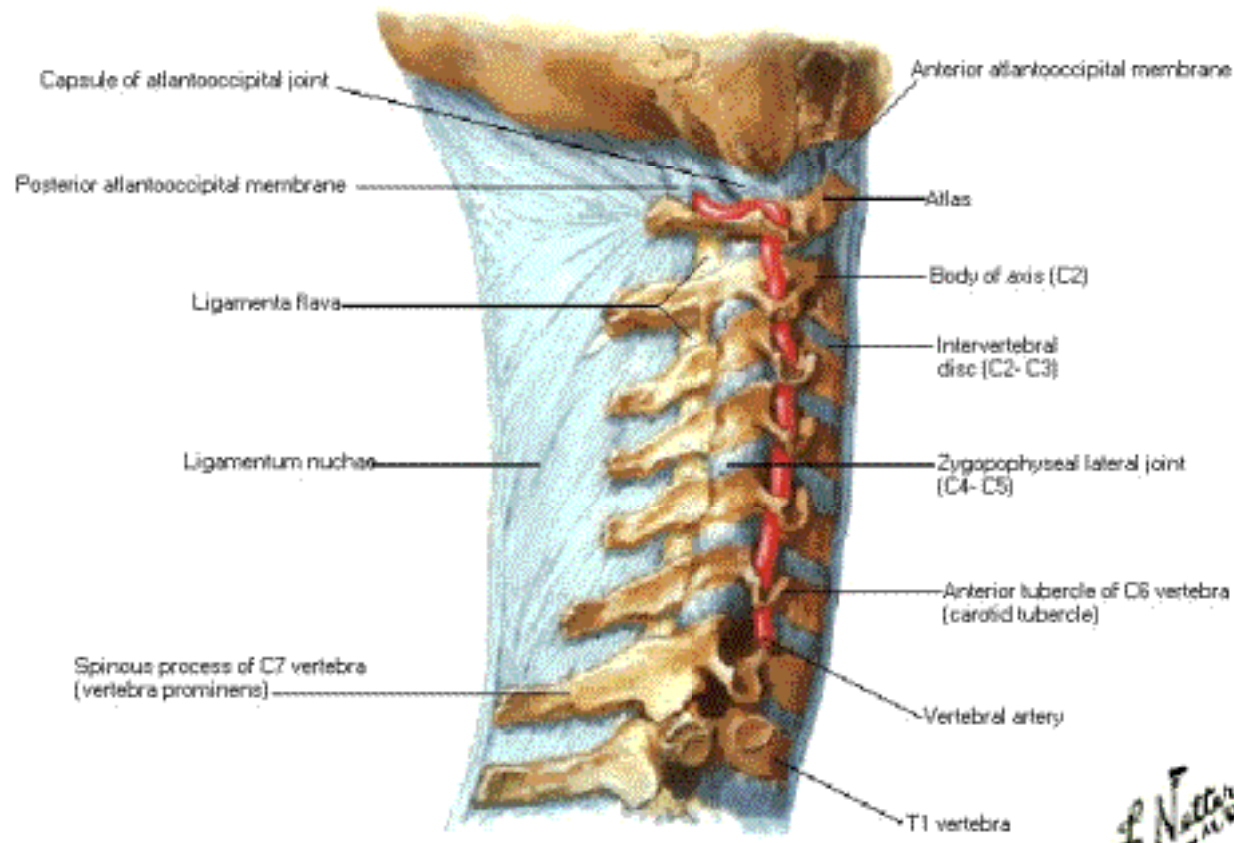
Anterior and Posterior Views



F. Netter
© Novartis

External Craniocervical Ligaments

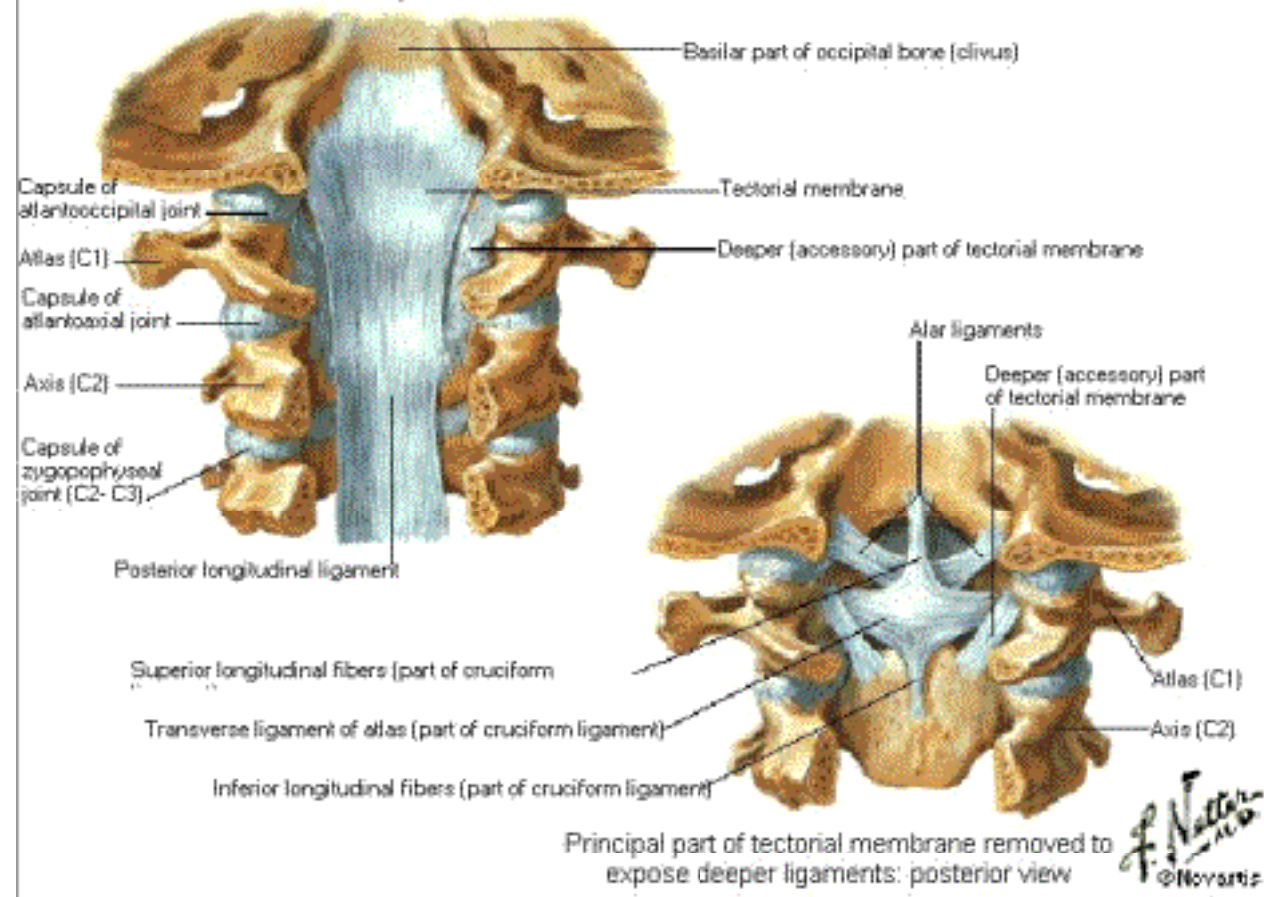
Right Lateral View



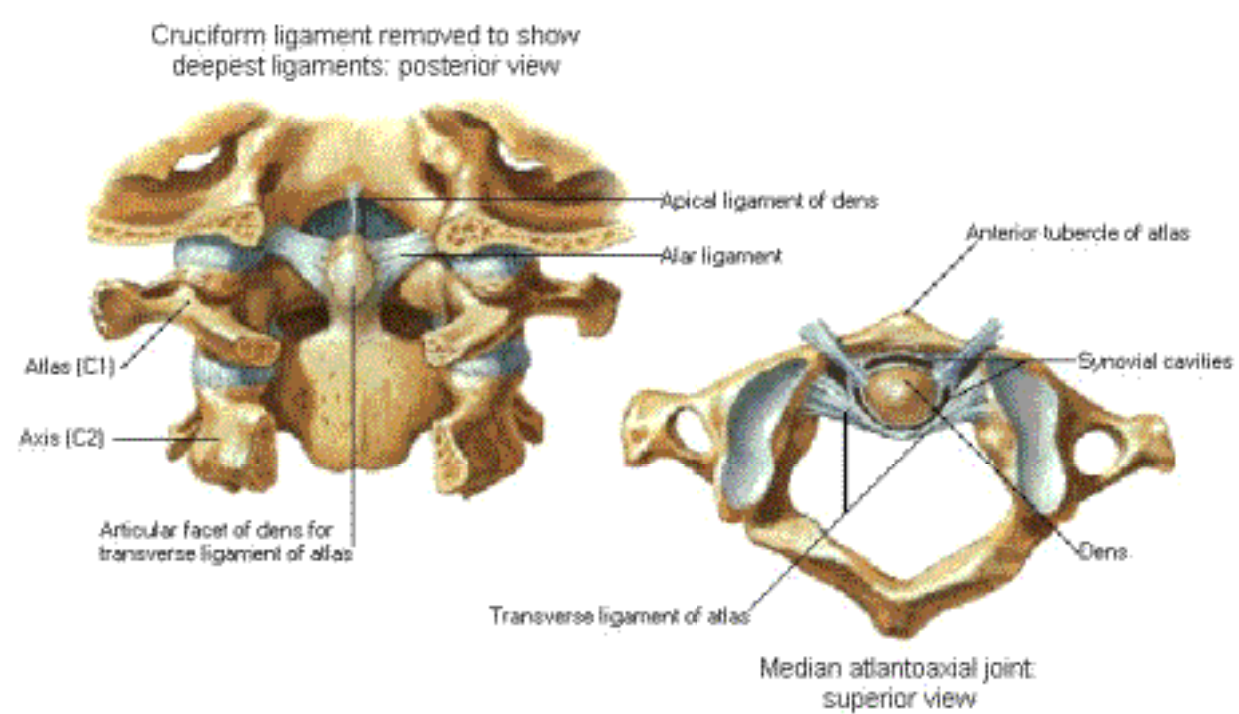
F. Netter
© Novartis

Internal Craniocervical Ligaments

Upper part of vertebral canal with spinous processes and parts of vertebral arches removed to expose ligaments on posterior vertebral bodies: posterior view

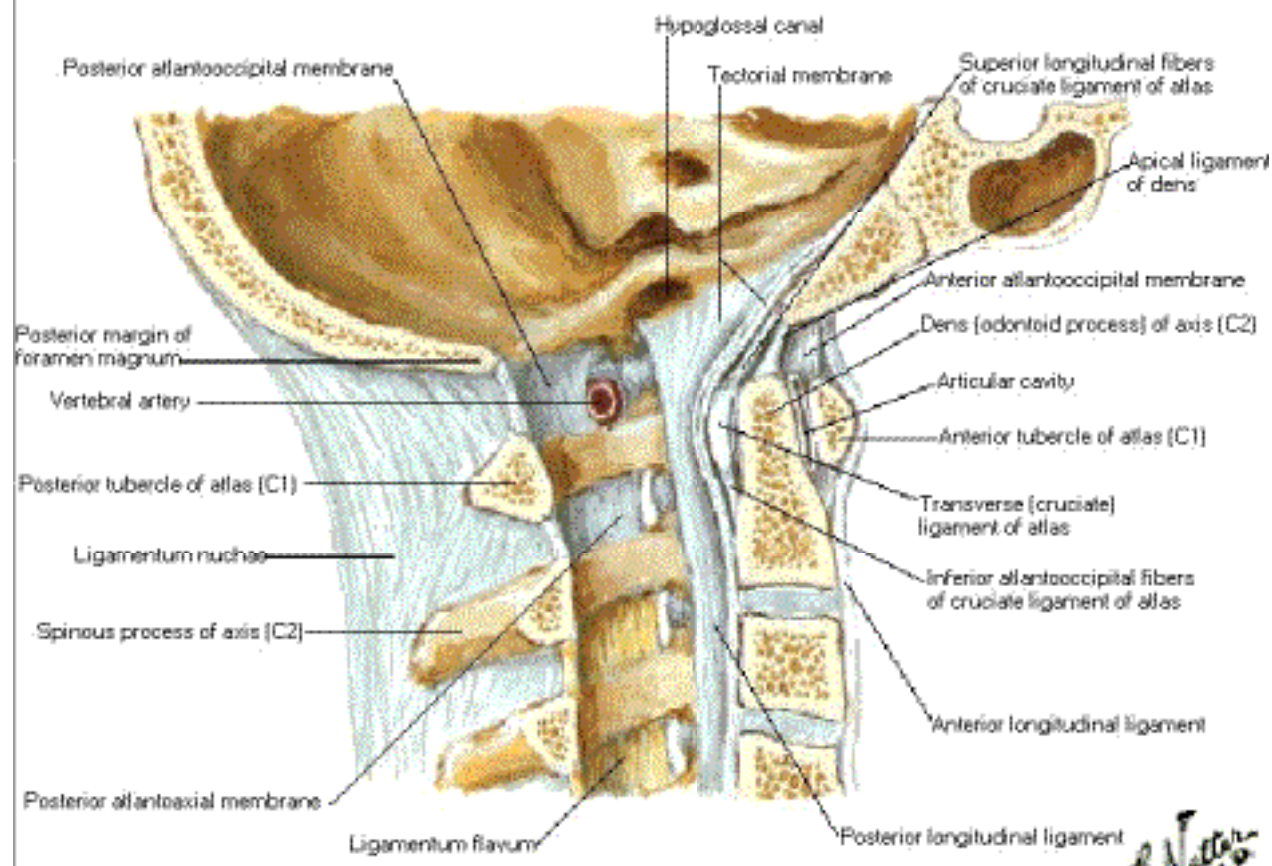


Internal Craniocervical Ligaments [Continued]



F. Netter
© Novartis

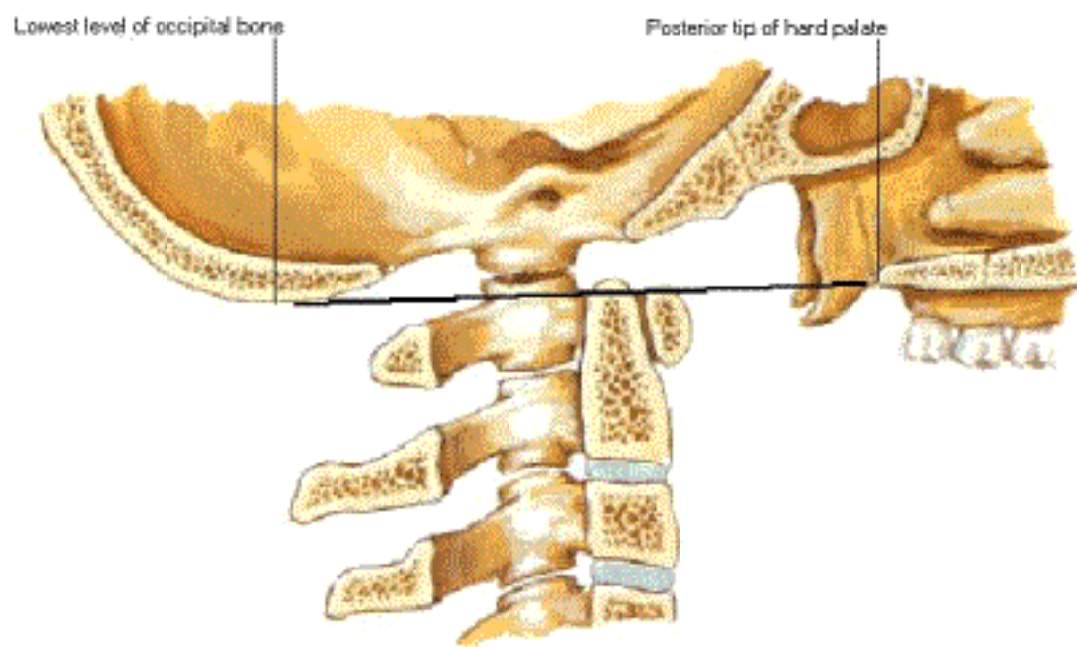
Atlantooccipital Junction



F. Netter M.D.
© 1994

Atlantooccipital Junction

McGregor's Line



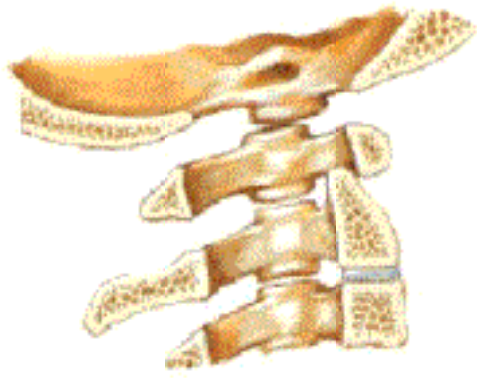McGregor's line, from posterior tip of hard palate to lowest point of occipital bone. Average normal position of odontoid tip is 1.32 mm above this line with standard deviation of plus or minus 2.6 mm as measured on a standard lateral radiograph. Tip > 4.5 mm above line is considered to indicate basilar impression.

F. Netter M.D.
© Novartis

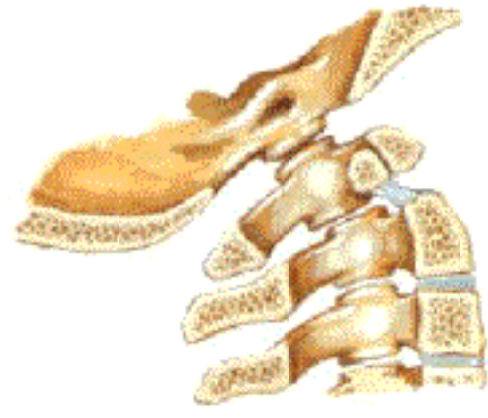Atlantooccipital Junction

Odontoid Abnormalities

Odontoid abnormalities, most often associated with skeletal dysplasias such as Klippel-Feil, Down's or Morquio's syndromes



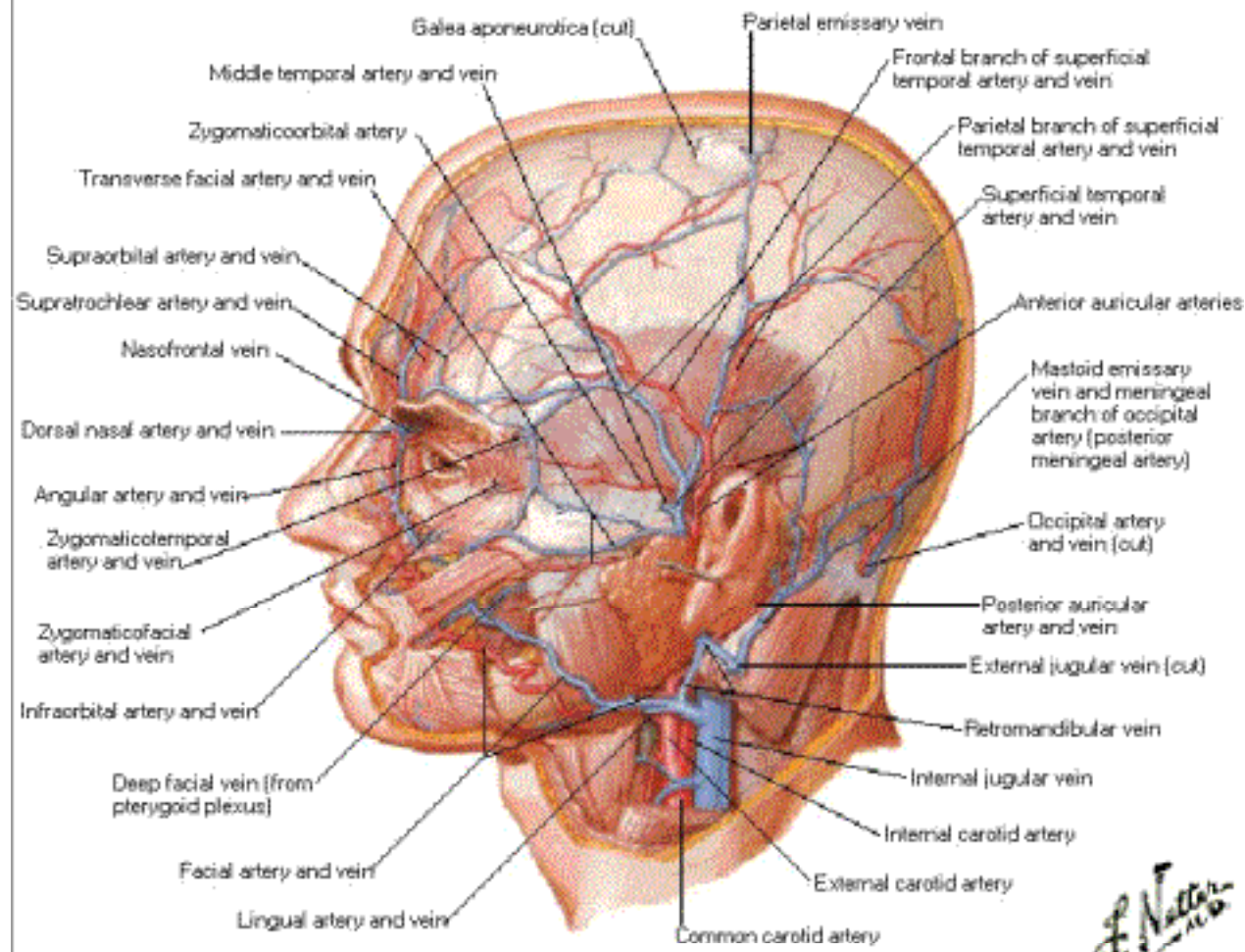
Hypoplastic dens
(odontoid process)



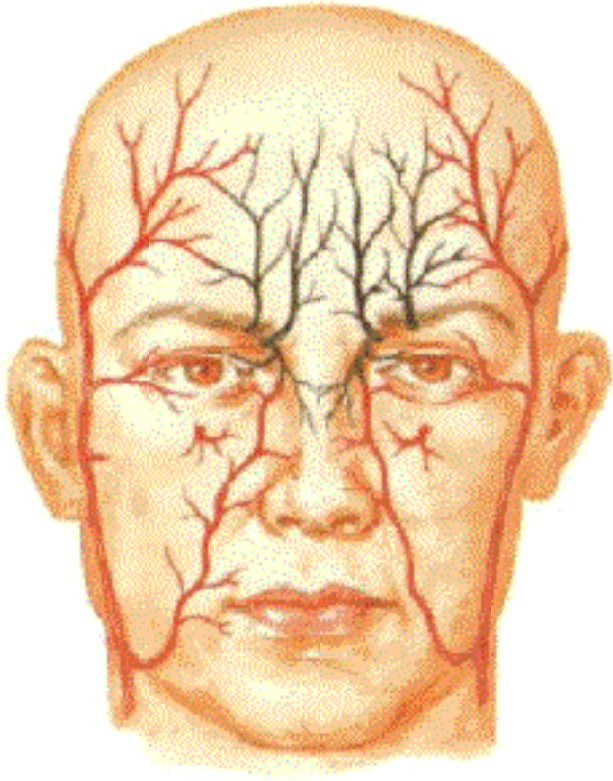
Os odontoideum with fibrous union
and narrowing of vertebral canal
with head in extension

F. Netter M.D.
© Novartis

Superficial Arteries and Veins of Face and Scalp

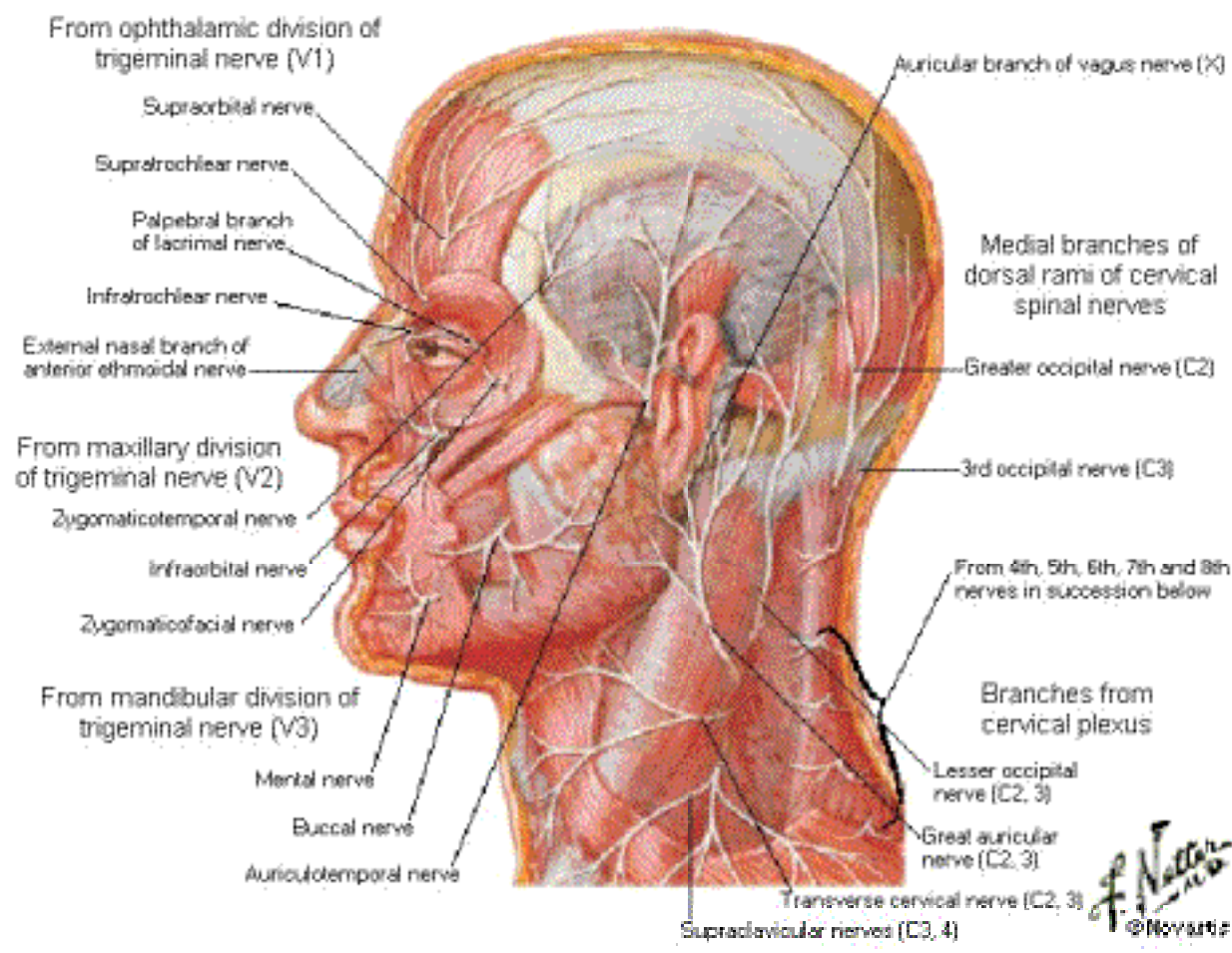


Superficial Face
Sources of Arterial Supply

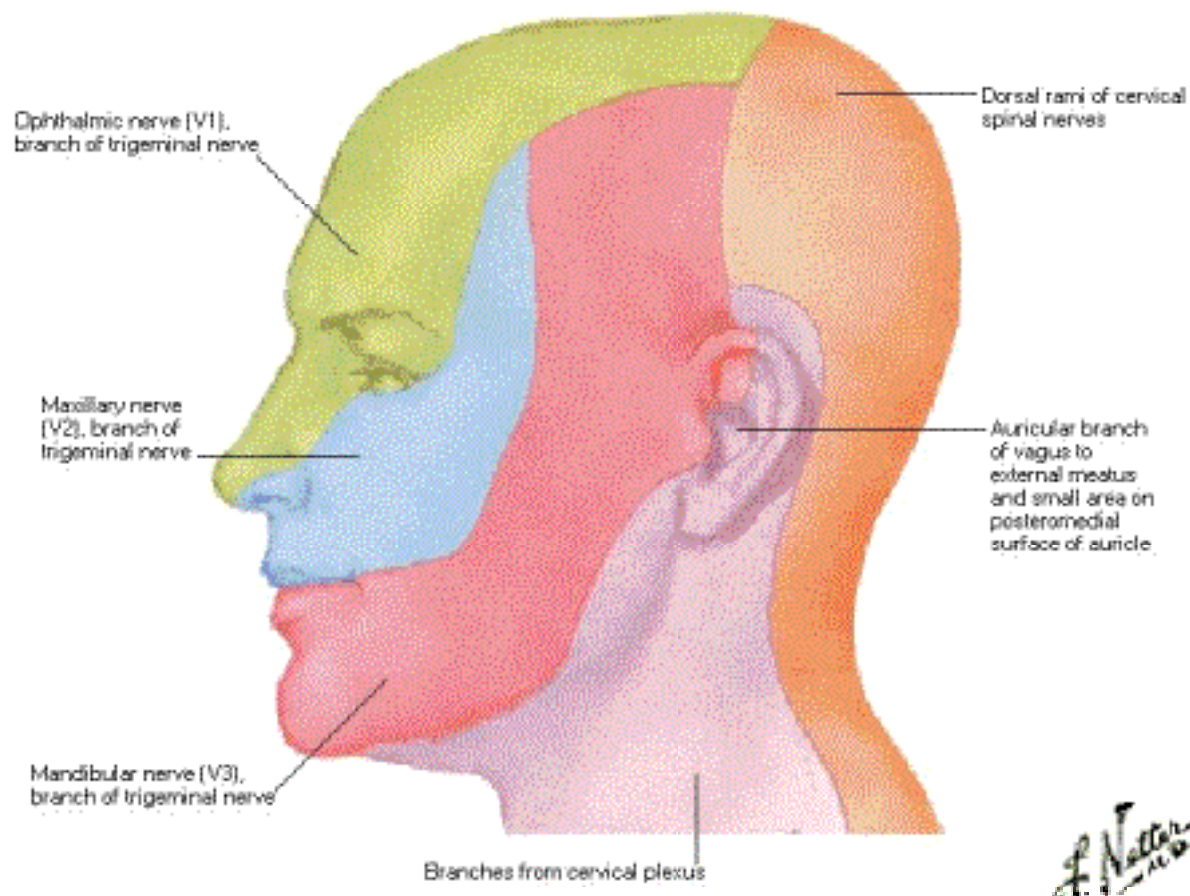


Black: from internal carotid artery (via ophthalmic artery)
Red: from external carotid artery

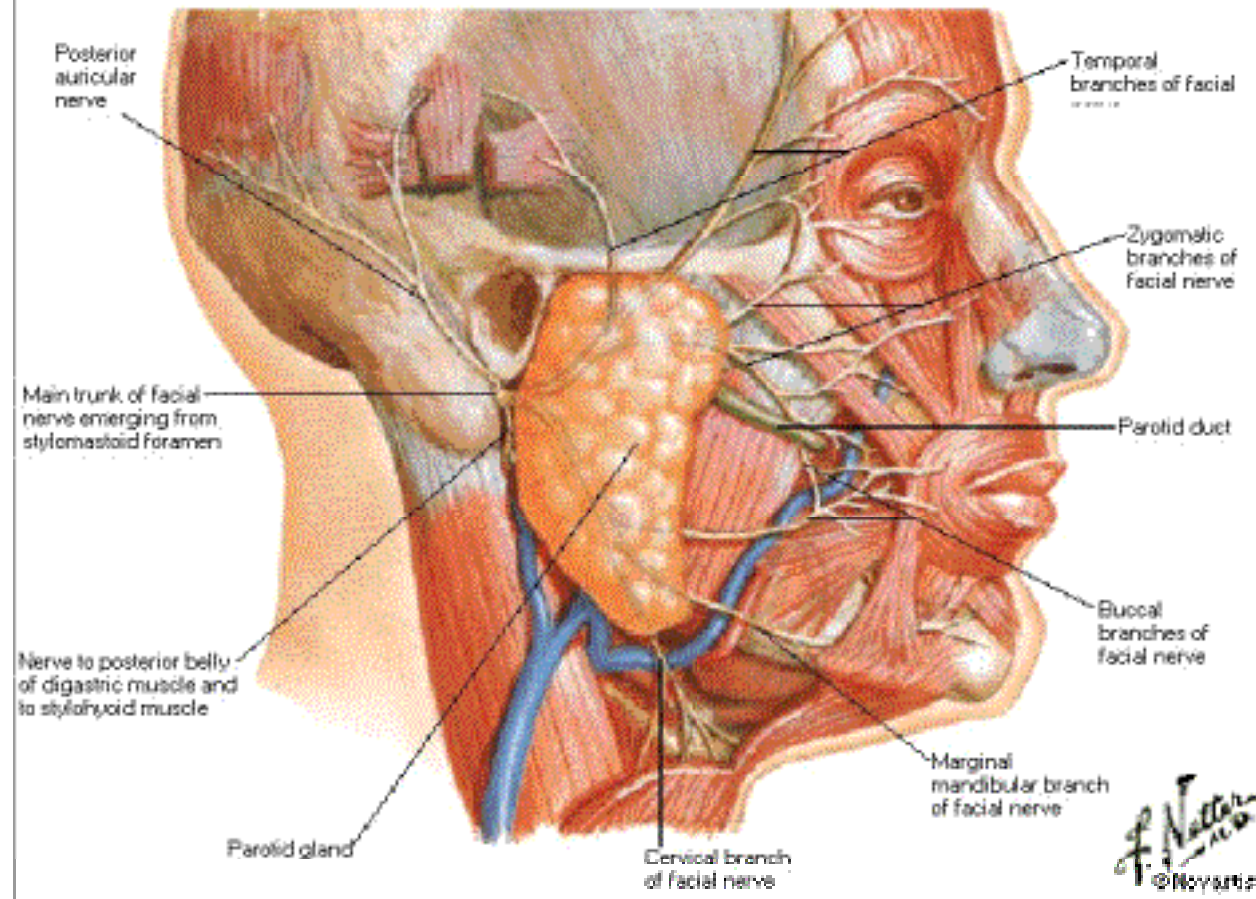
Cutaneous Nerves of Head and Neck



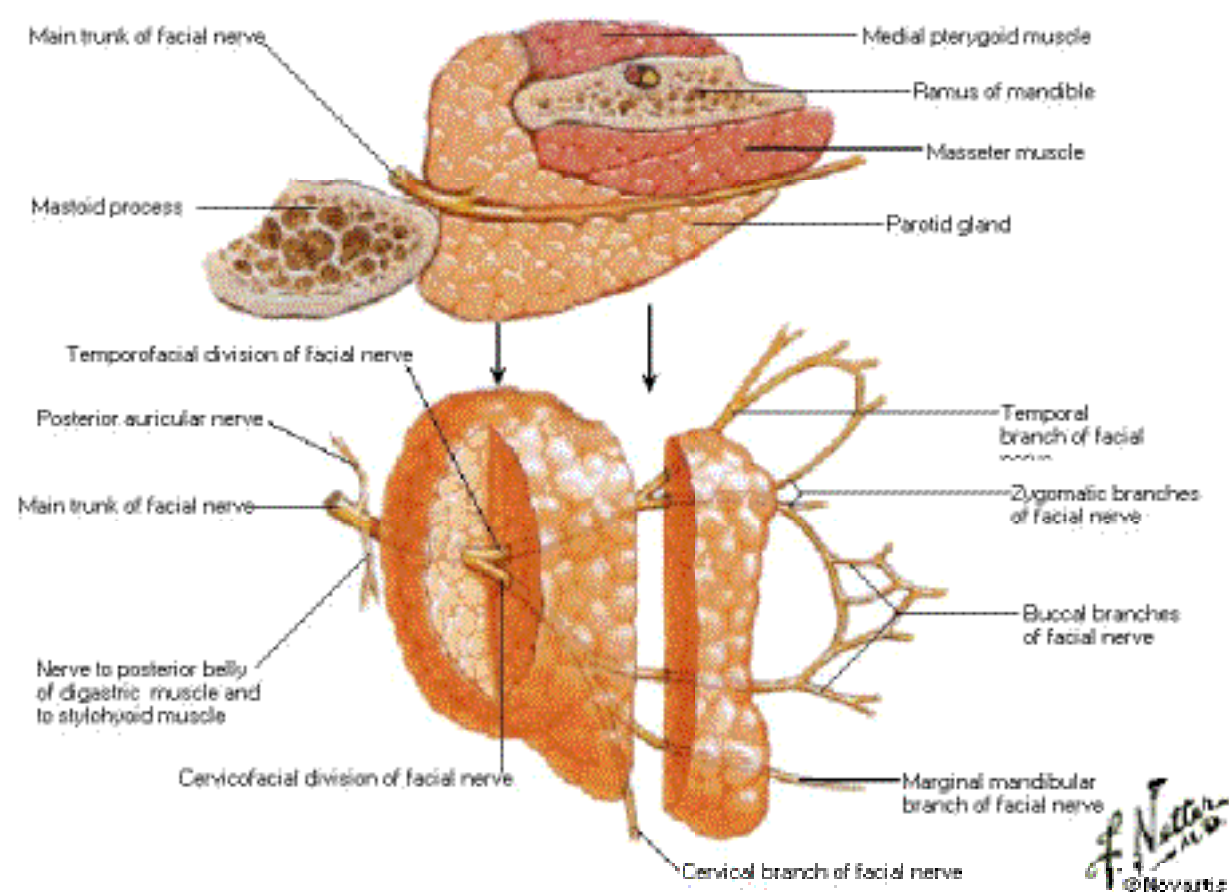
Dermatomes of Head and Neck



Facial Nerve Branches and Parotid Gland in Situ

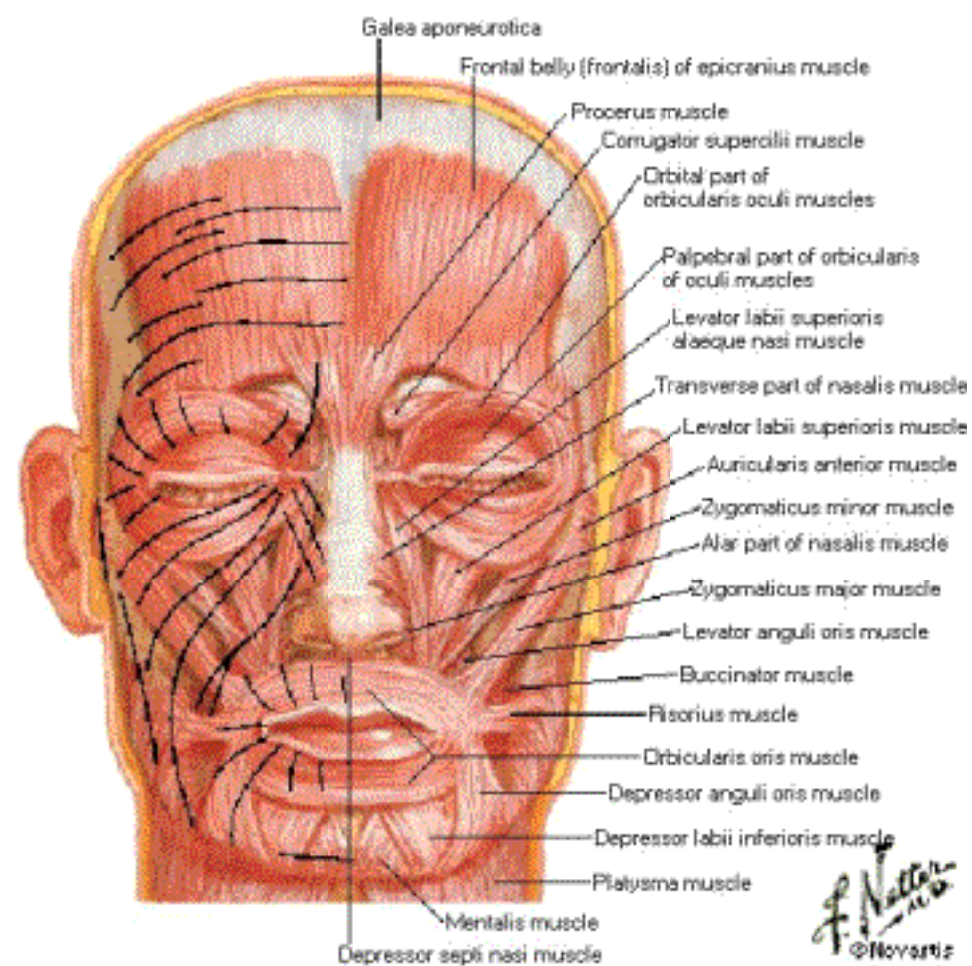


Facial Nerve Branches and Parotid Gland Sectioned

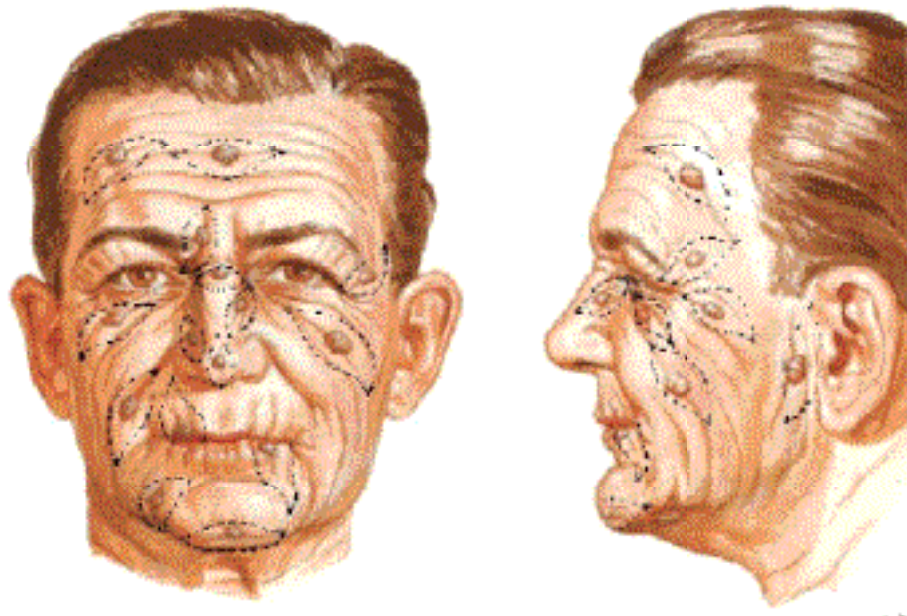


Muscles of Facial Expression

Anterior View



Superficial Face
Course of Wrinkle Lines of Skin

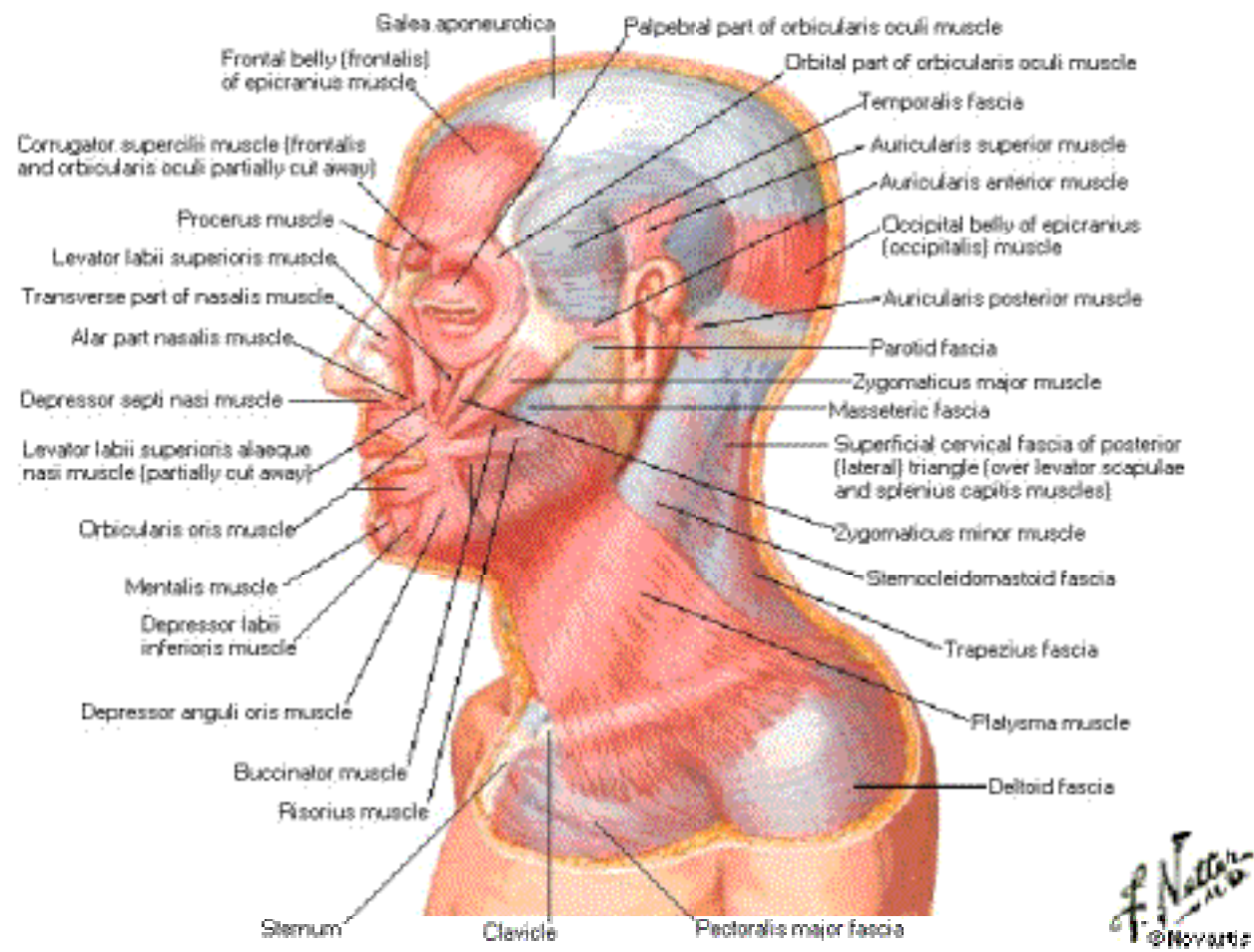


Course of wrinkle lines of skin is transverse to fiber direction of facial muscles. Elliptical incisions for removal of skin tumors conform to direction of wrinkle lines

F. Netter
© 1904

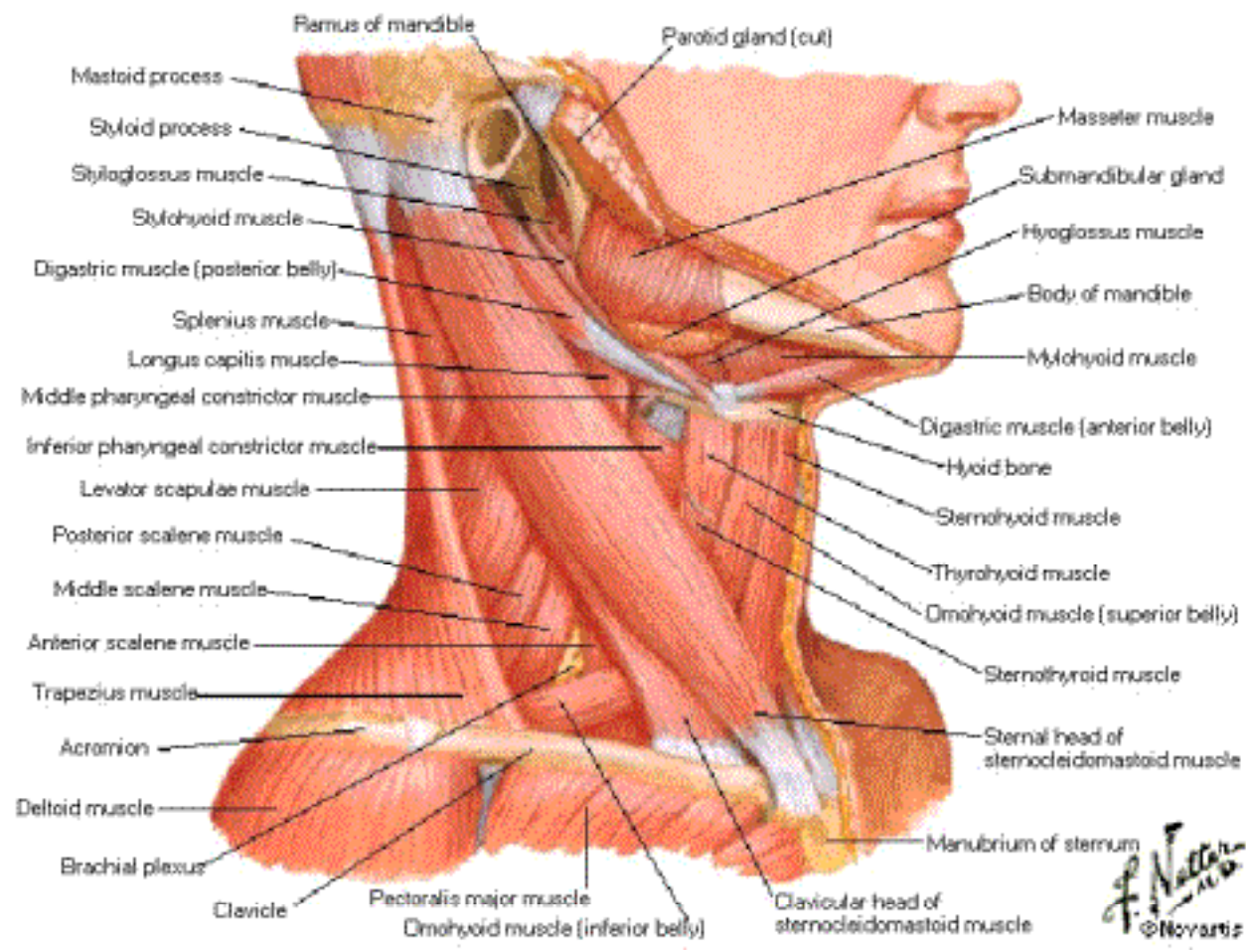
Muscles of Facial Expression

Lateral View



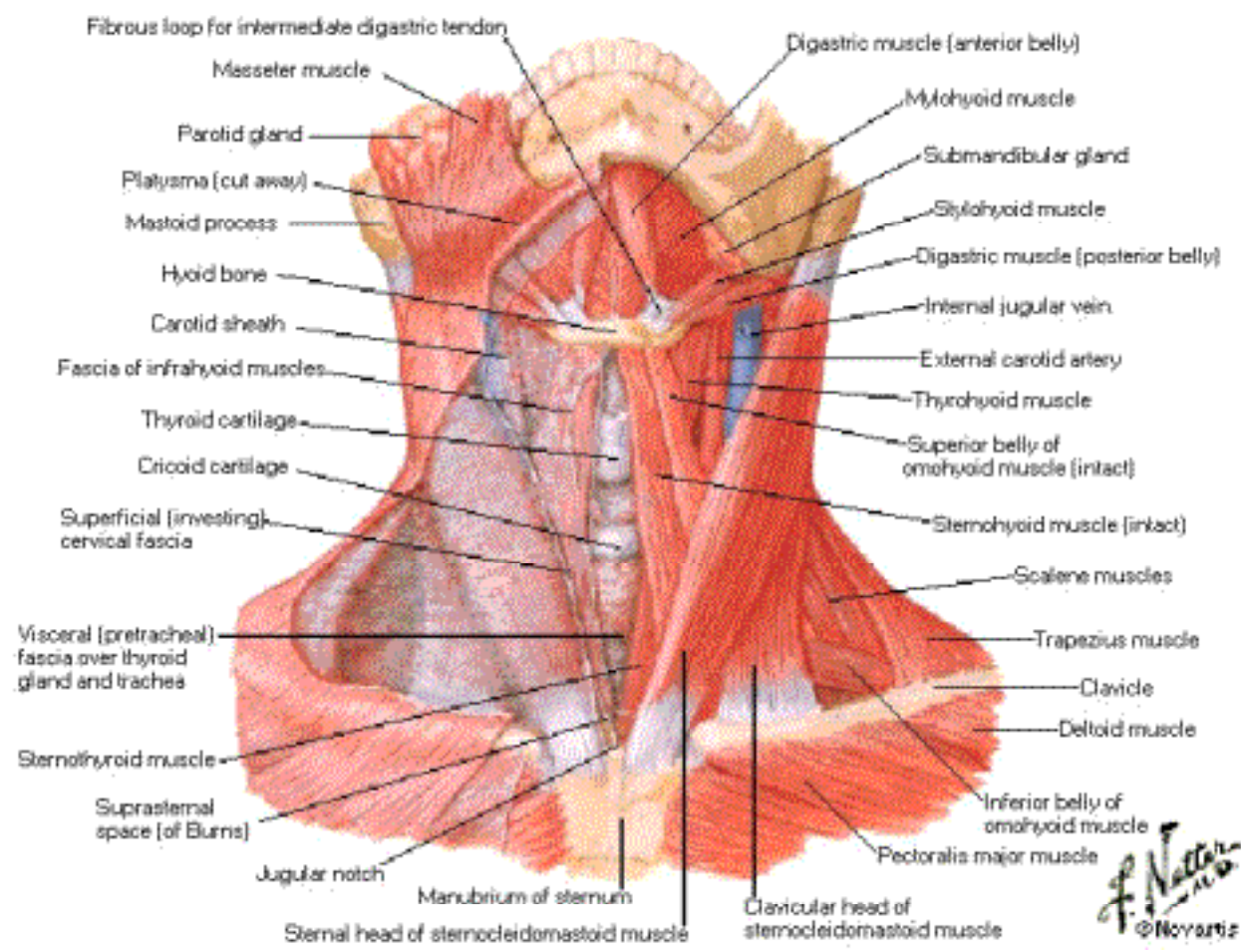
Muscles of Neck

Lateral View

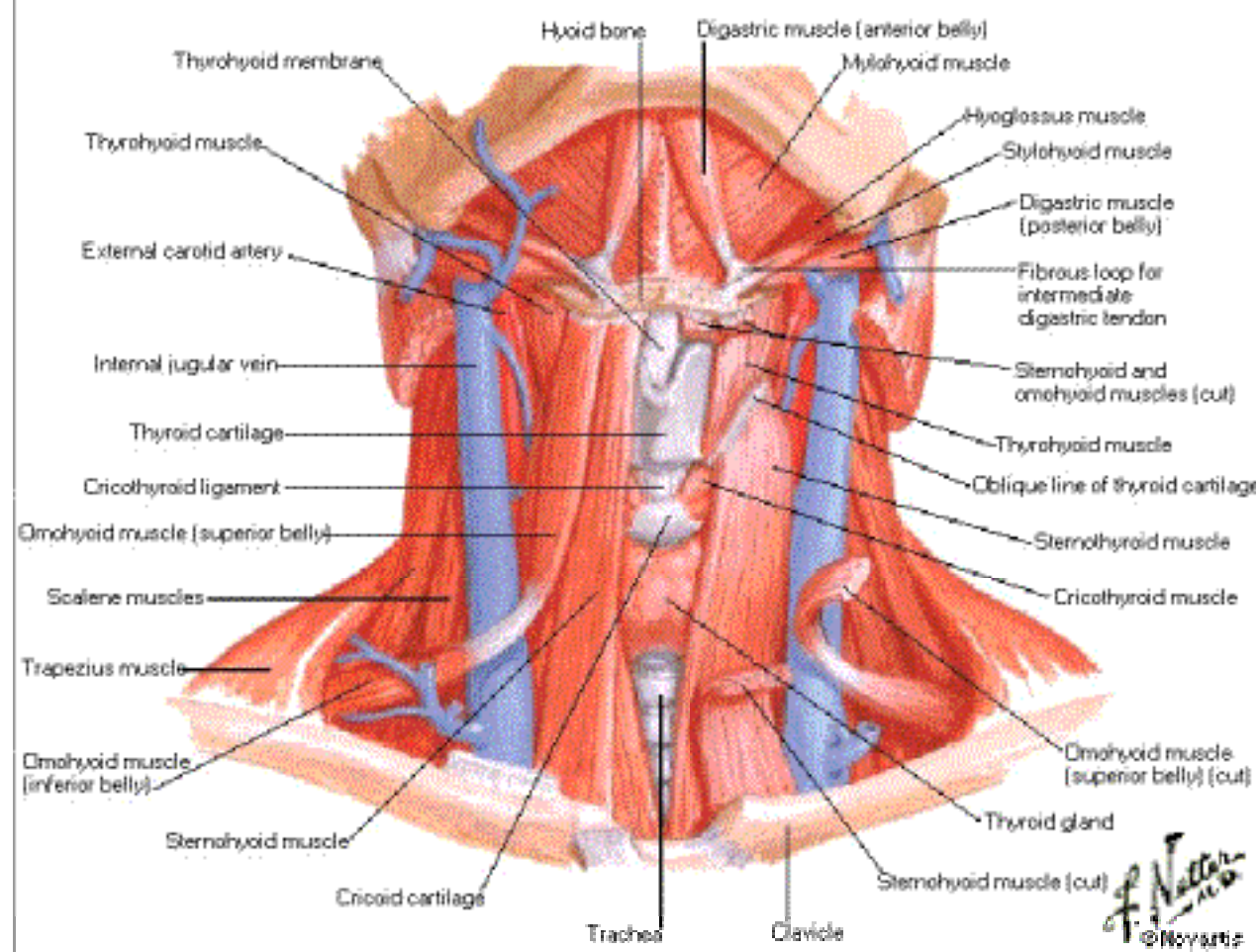


Muscles of Neck

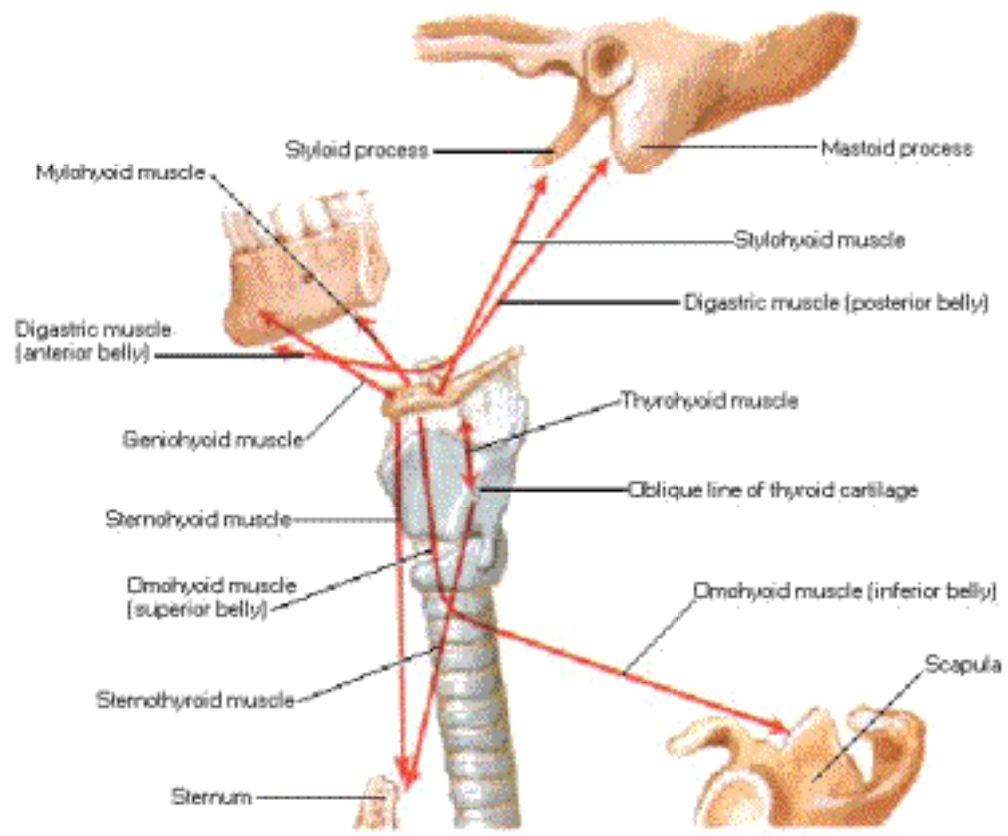
Anterior View



Infrahyoid and Suprahyoid Muscles

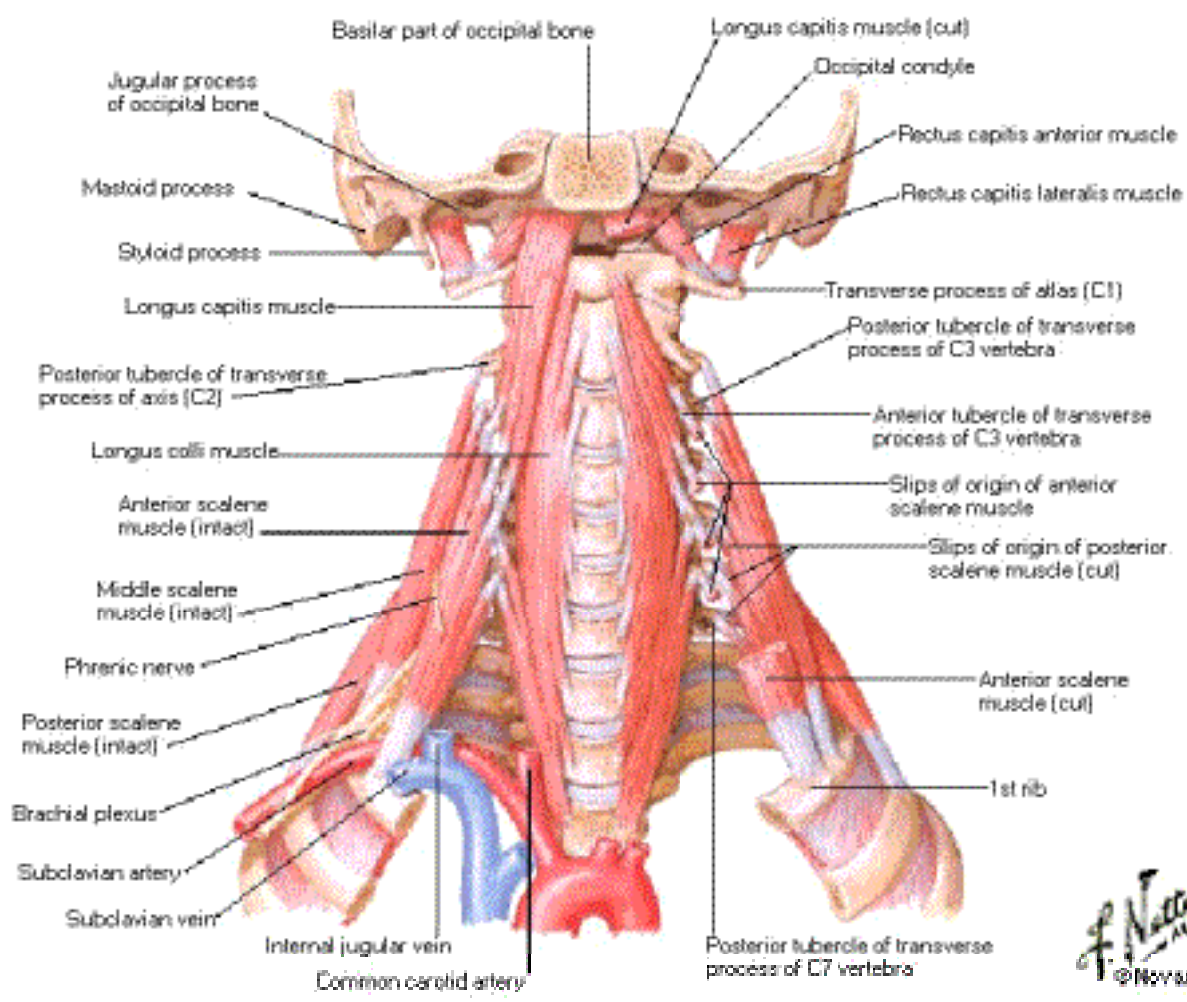


Infrahyoid and Suprahyoid Muscles and their Action Schema

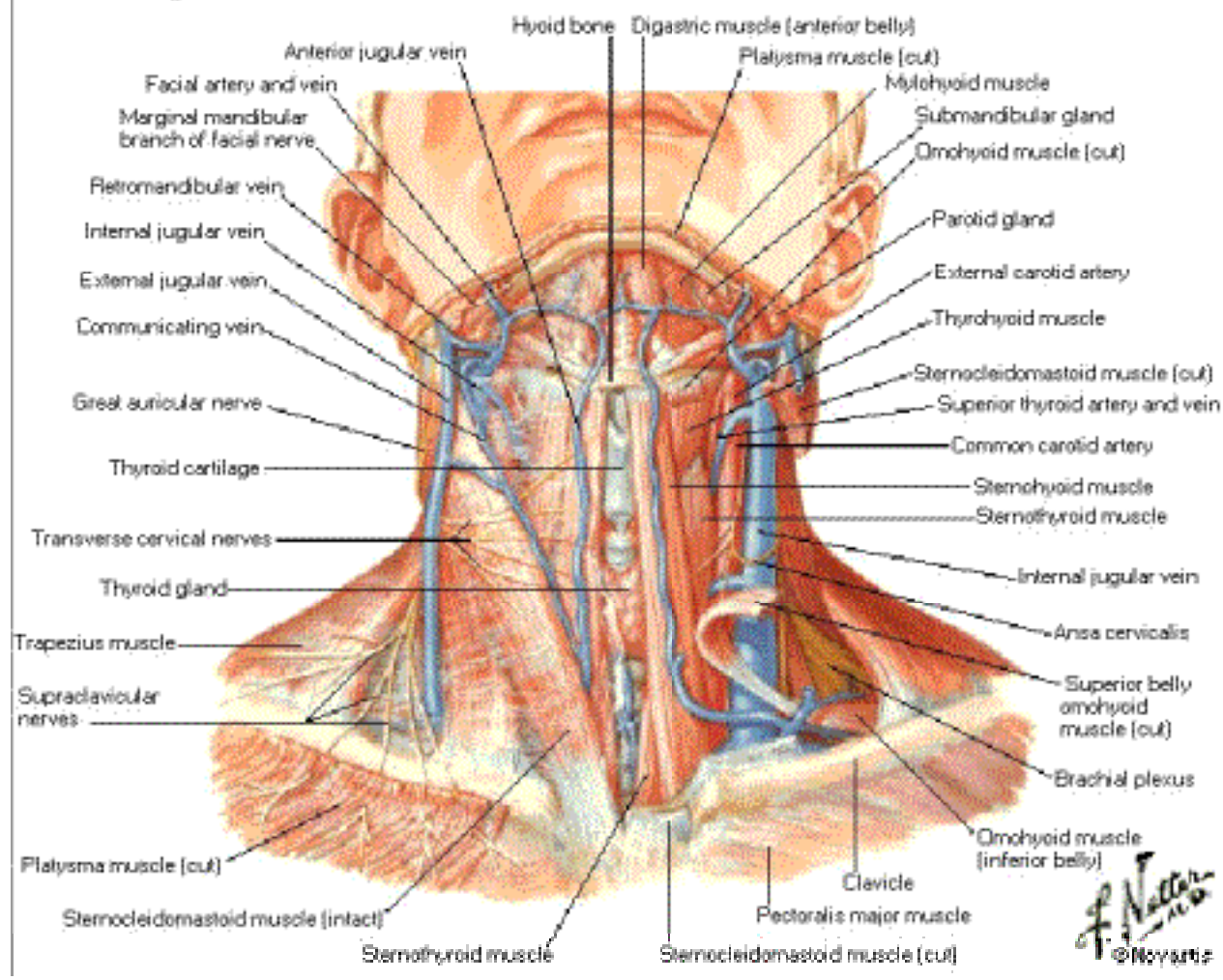


F. Natter
© Novartis

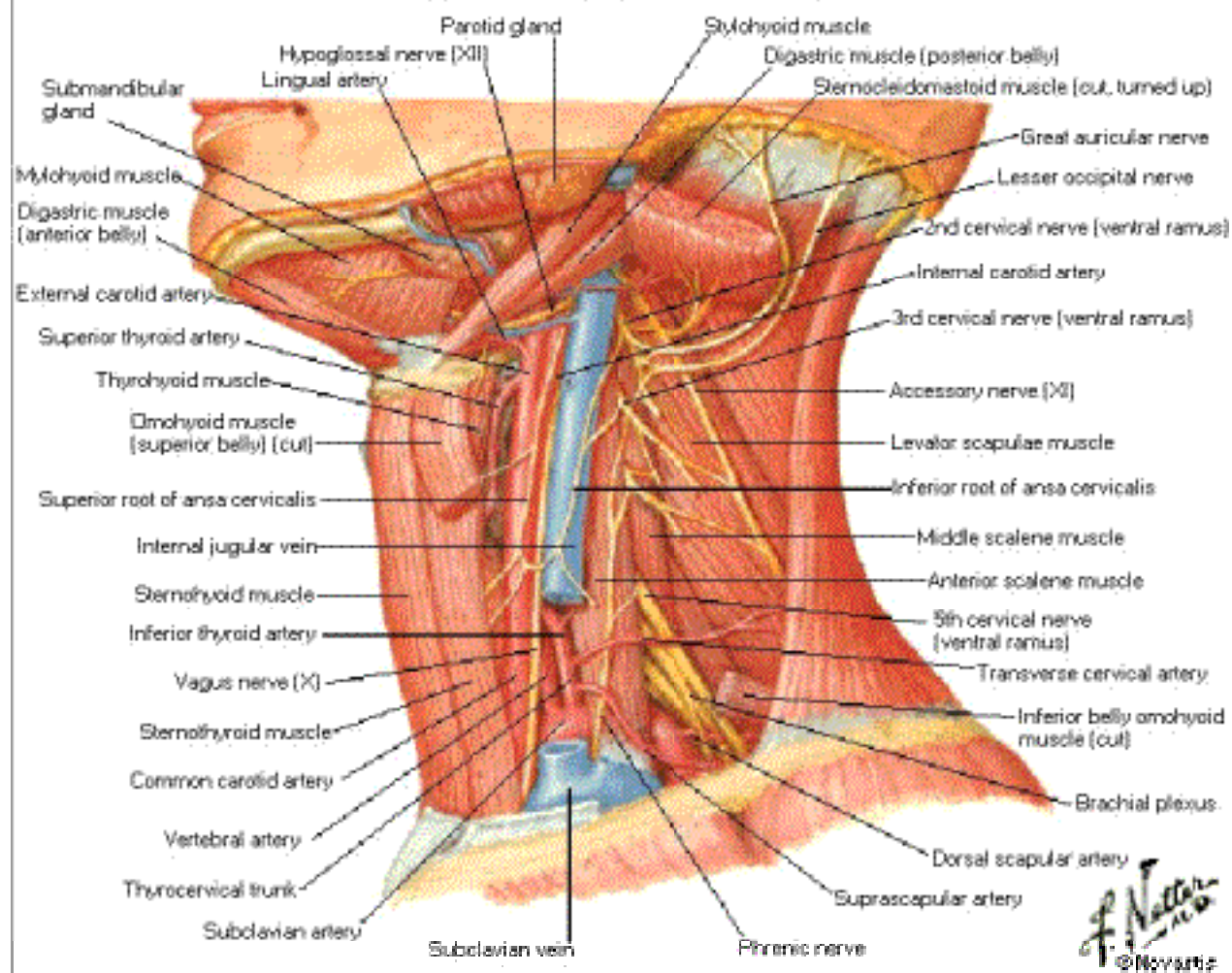
Scalene and Prevertebral Muscles



Superficial Veins and Cutaneous Nerves of Neck



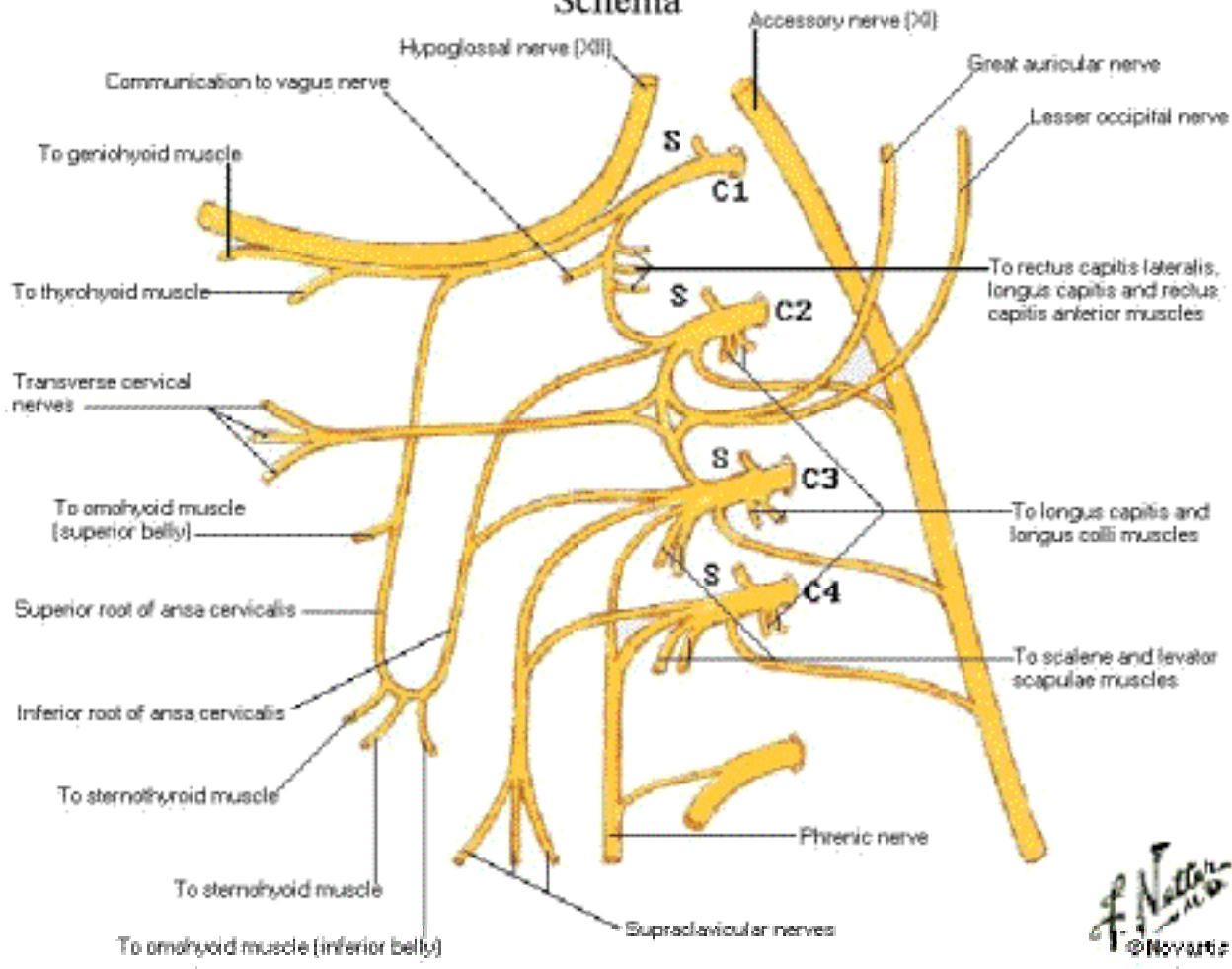
Cervical Plexus in Situ



S = gray ramus to superior sympathetic ganglion

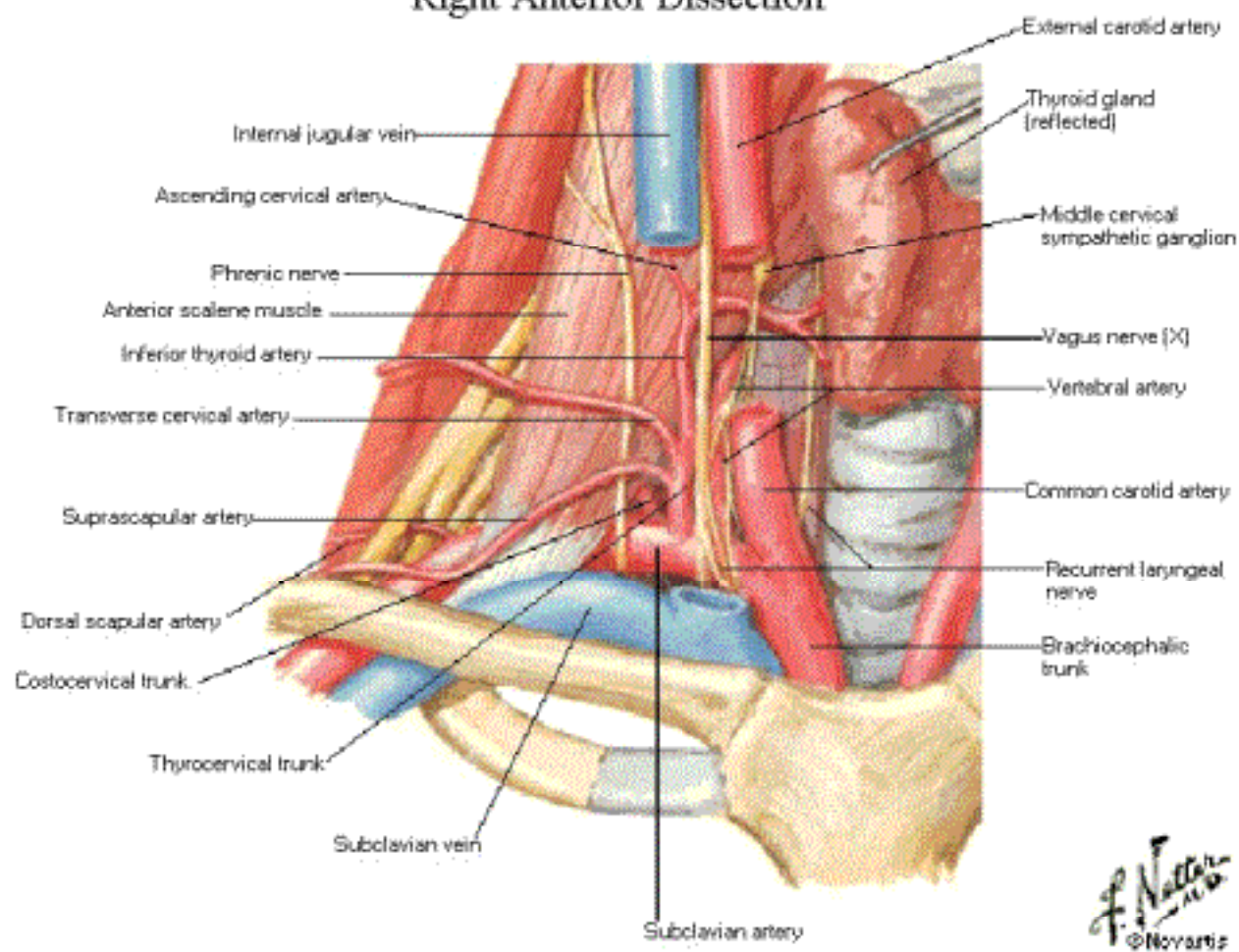
Cervical Plexus

Schema



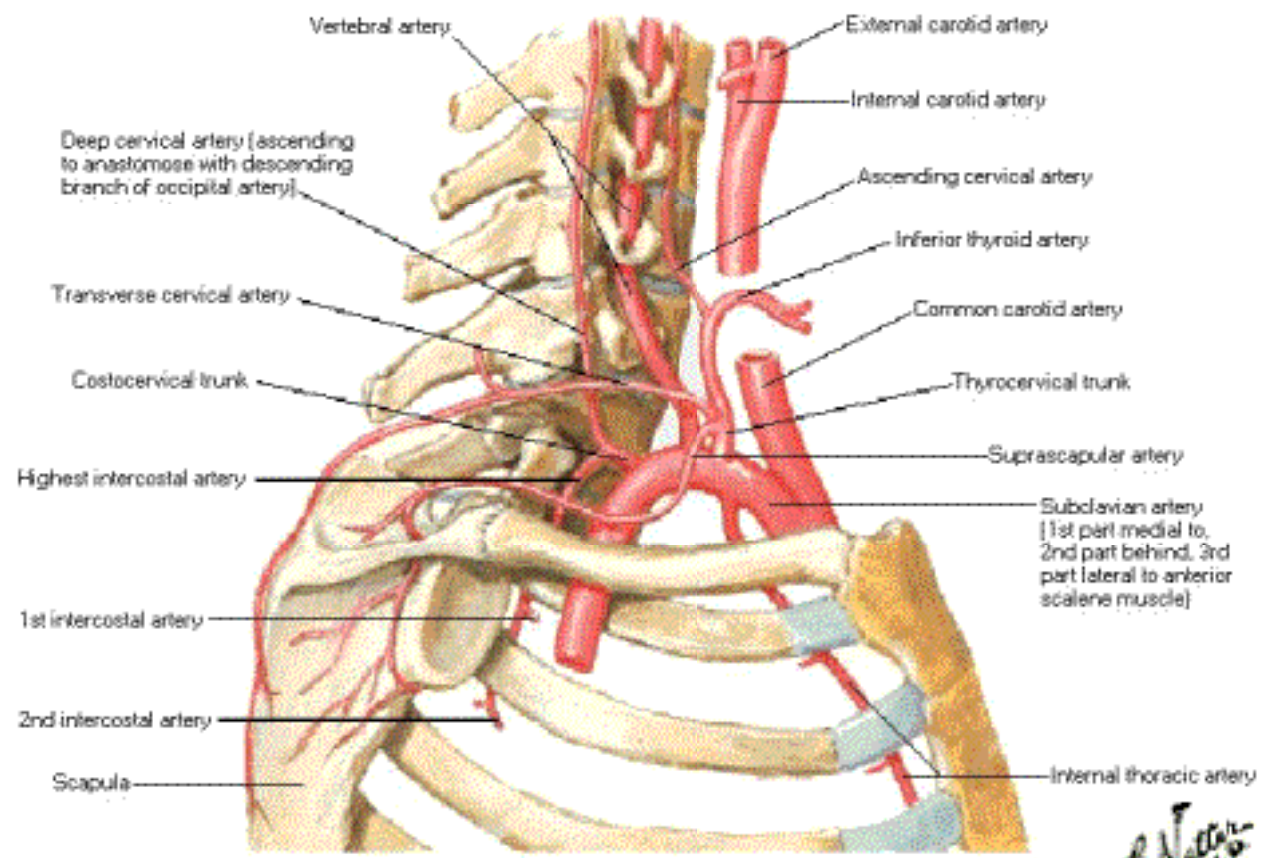
Subclavian Artery

Right Anterior Dissection



Subclavian Artery

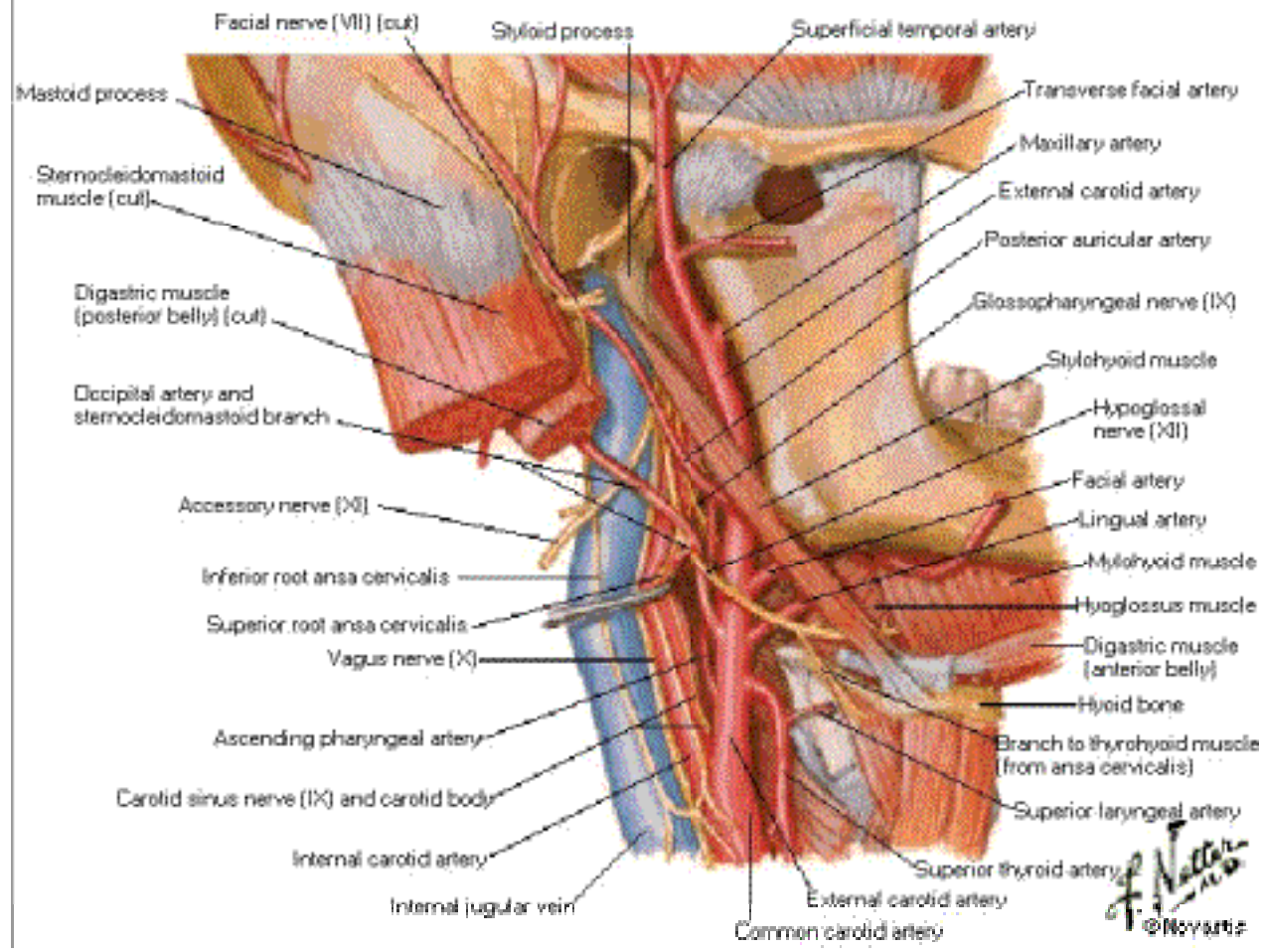
Right Lateral Schematic View



F. Netter
© 1989

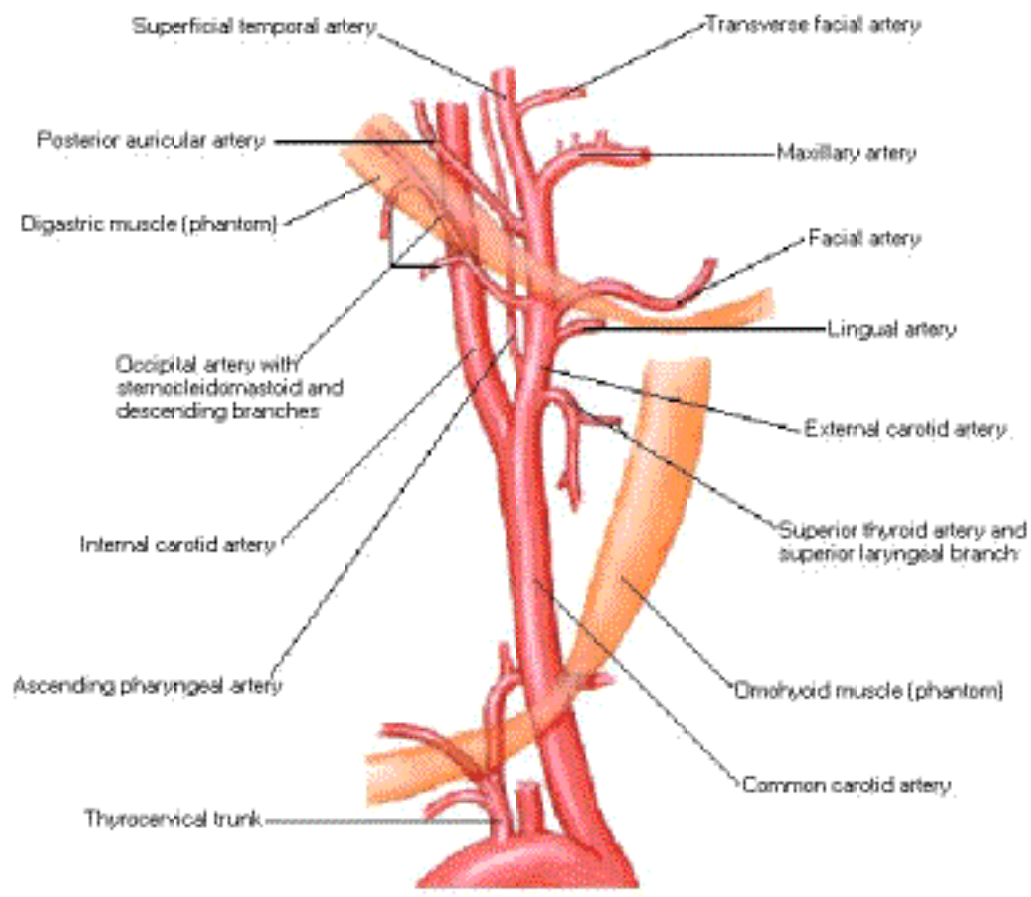
Carotid Arteries - Parotid Fossa

Right Lateral Dissection



External Carotid Artery and Branches

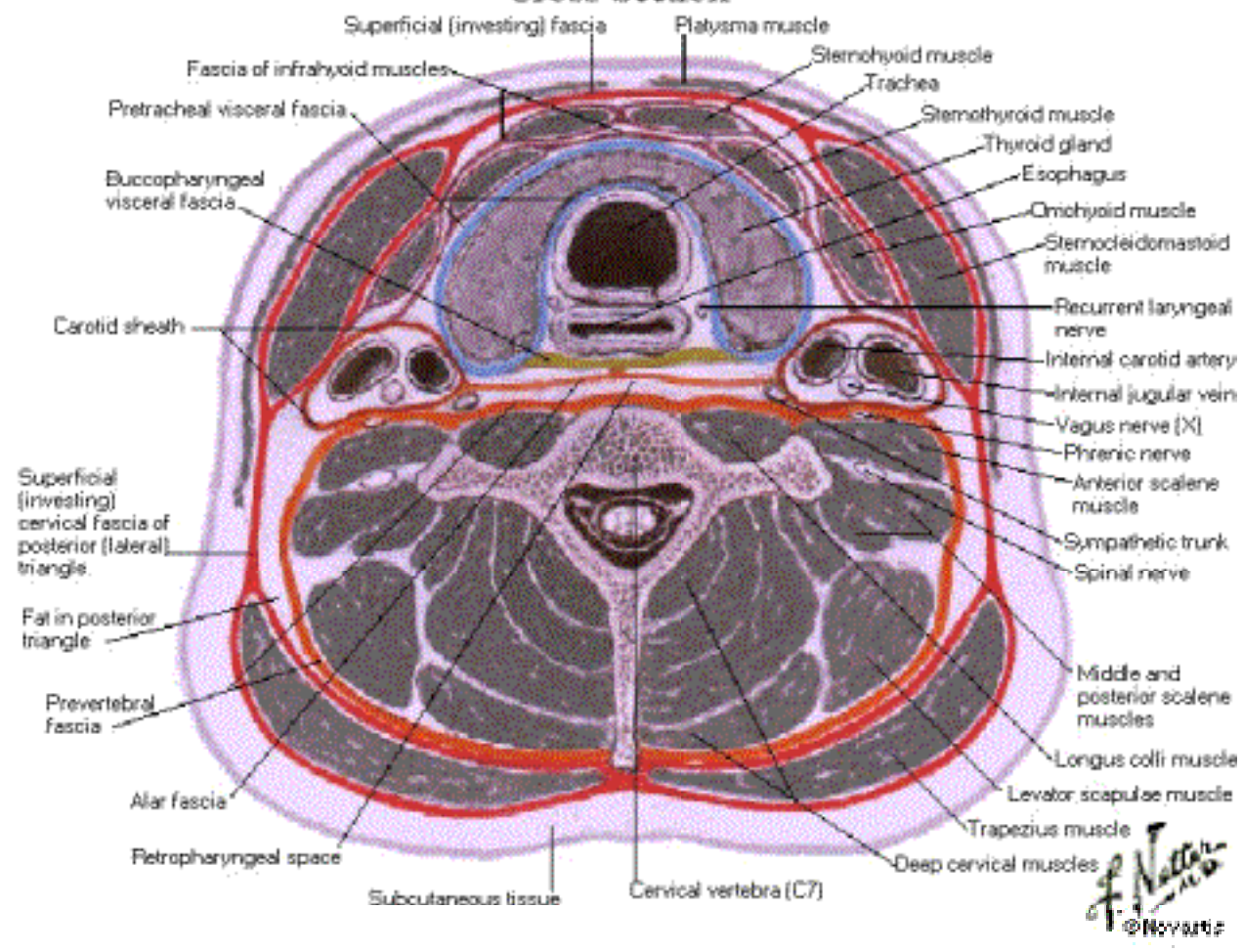
Schema



F. Netter
© Novartis

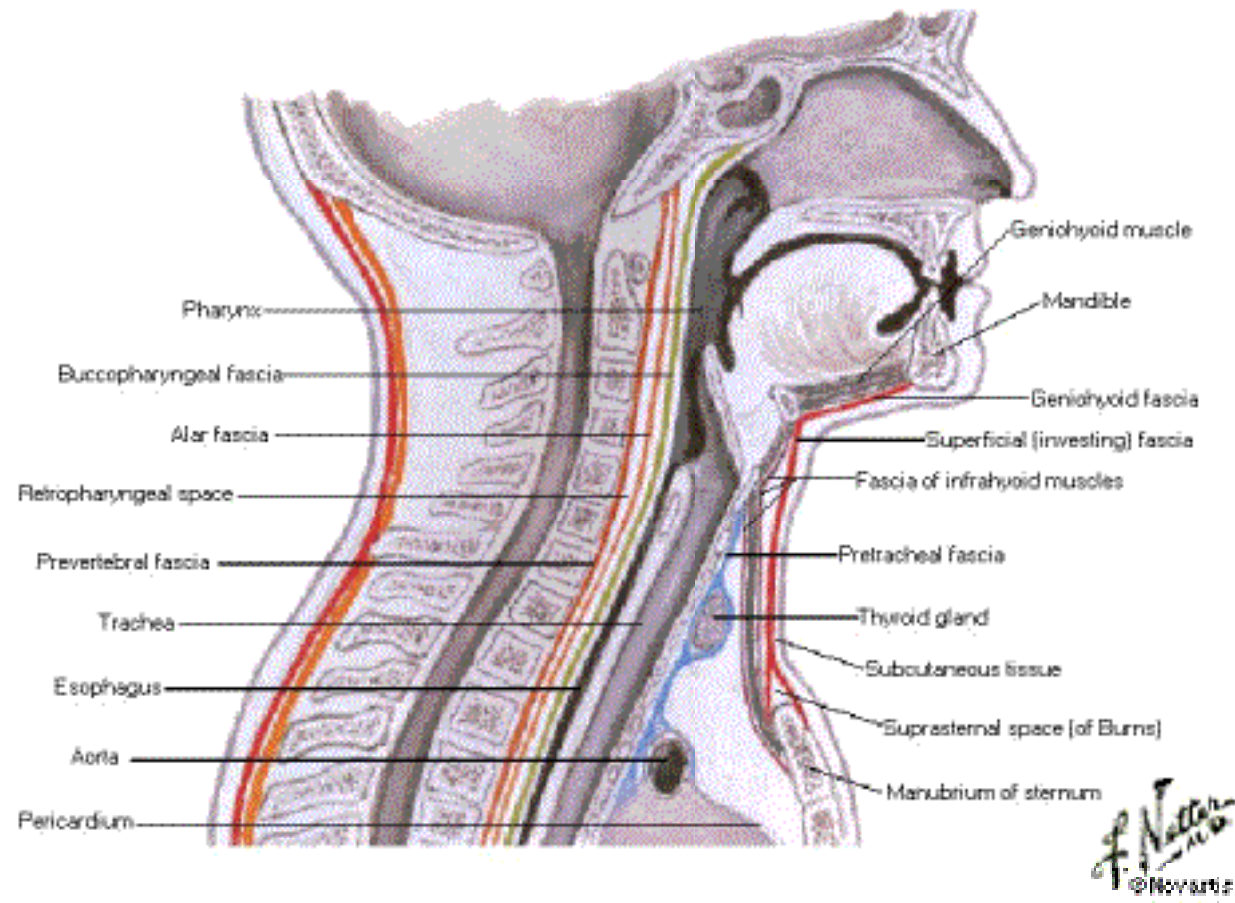
Fascial Layers of Neck

Cross Section



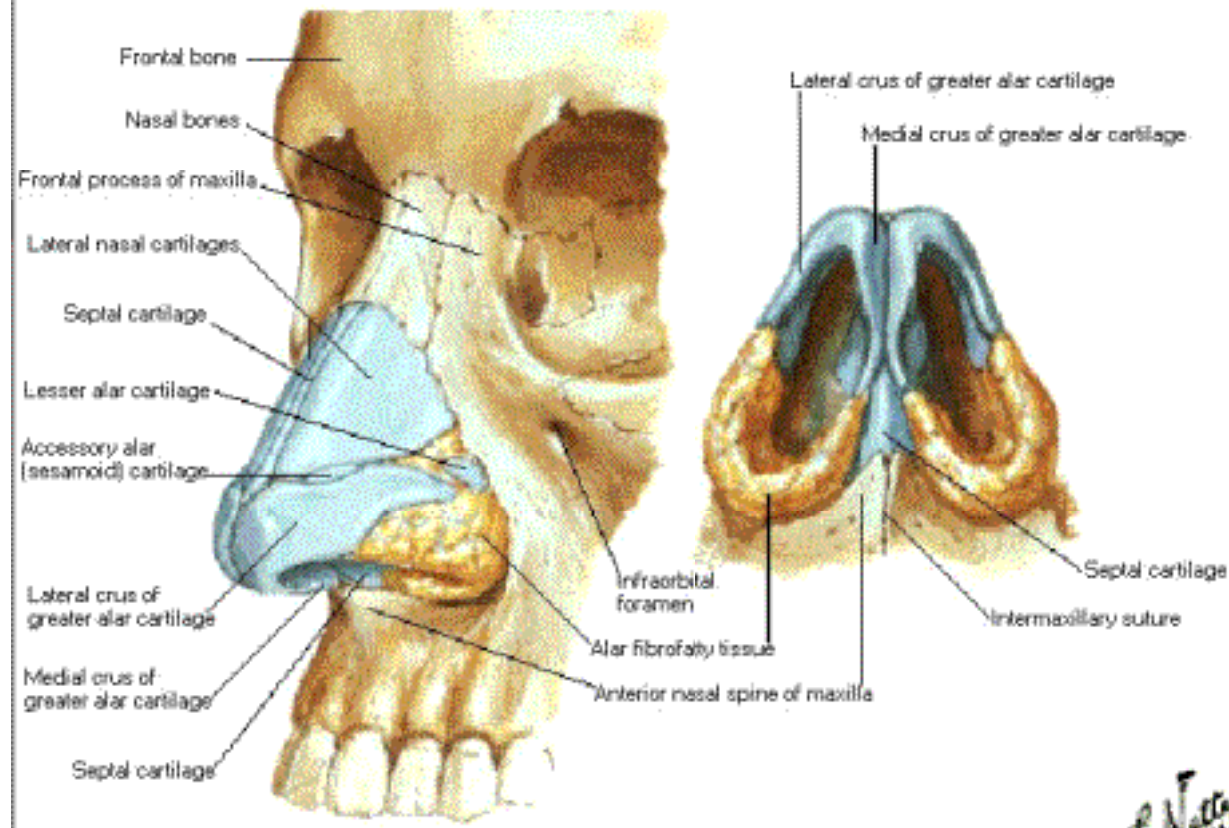
Fascial Layers of Neck

Sagittal Section



External Nose [Skeleton]

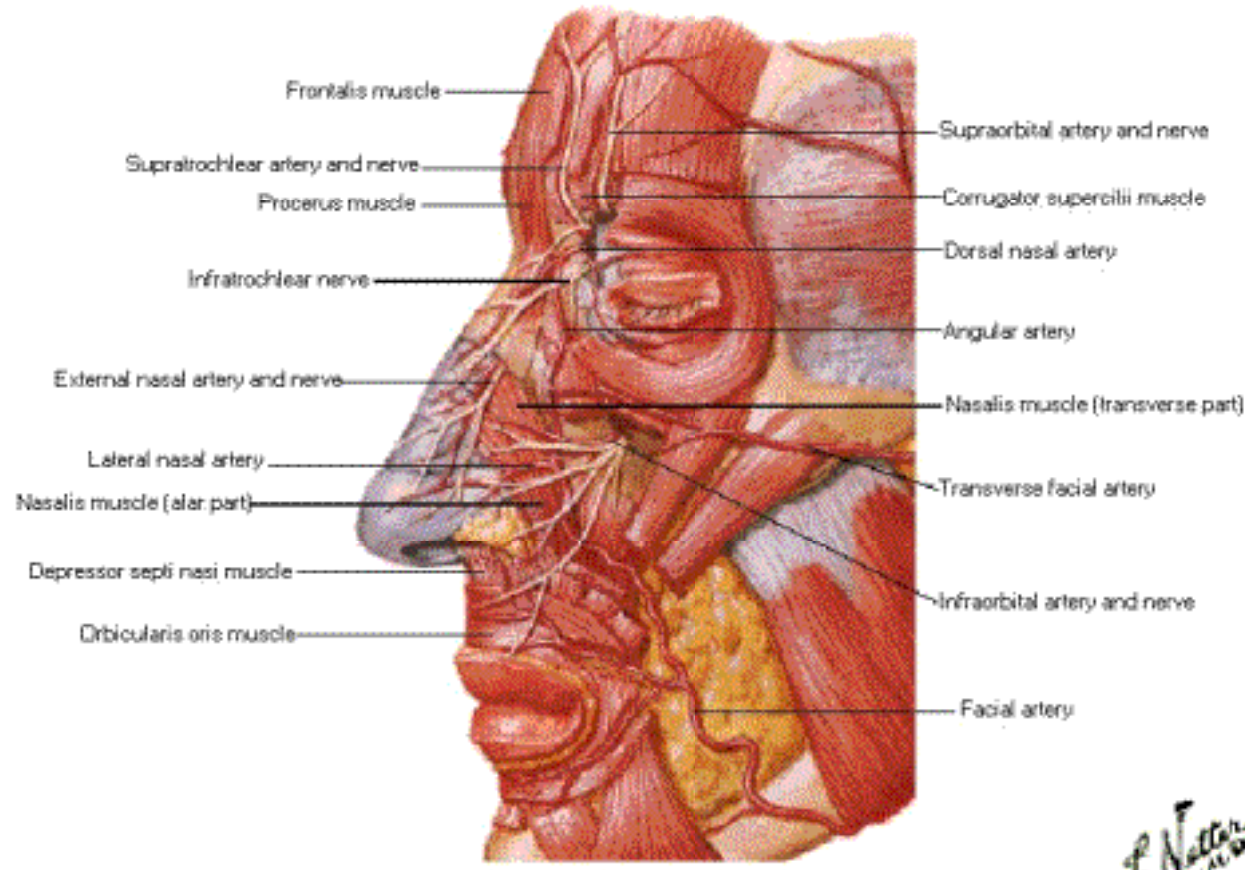
Anterolateral and Inferior Views



F. Netter
© Novartis

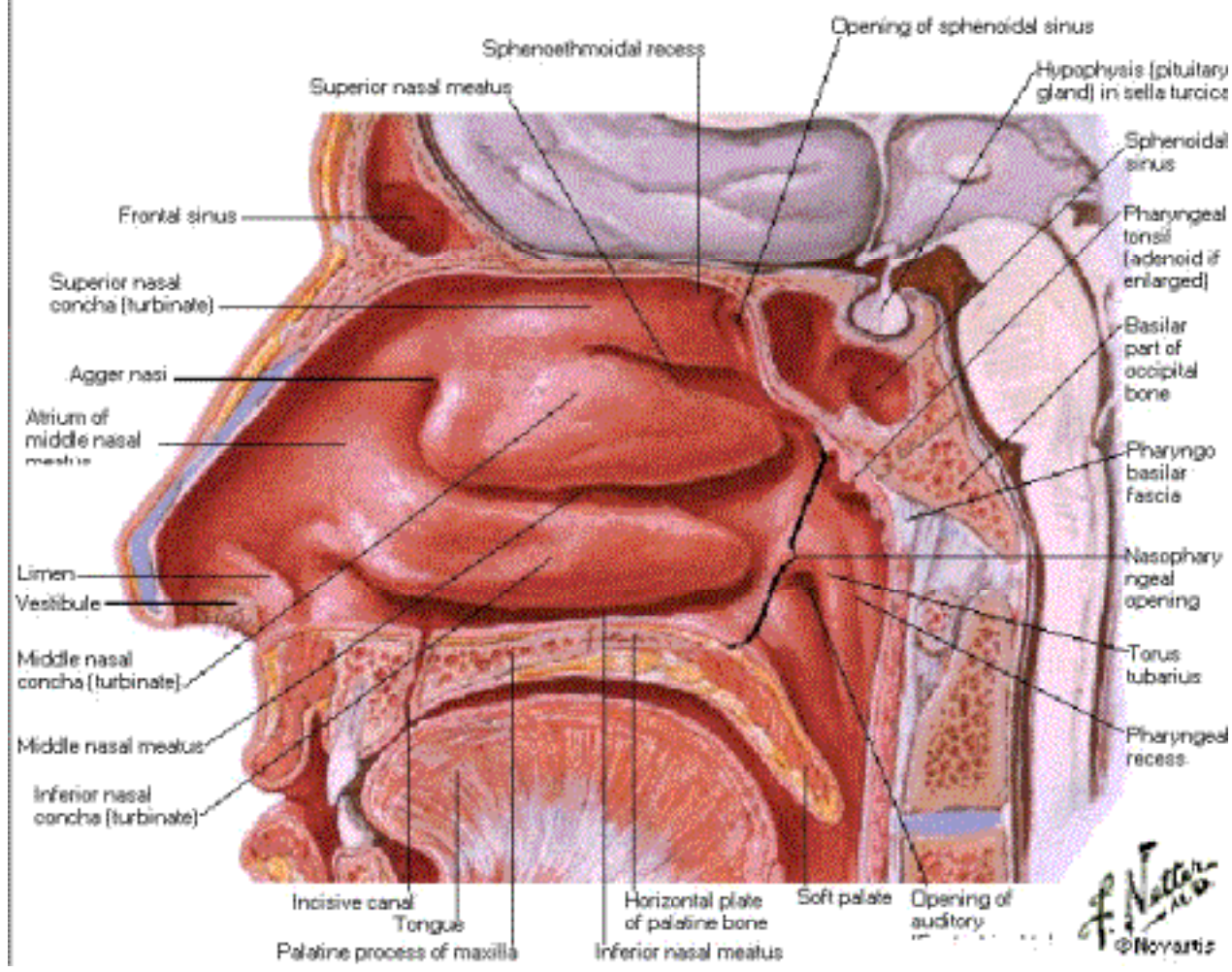
External Nose [Skeleton] in Situ

Lateral View

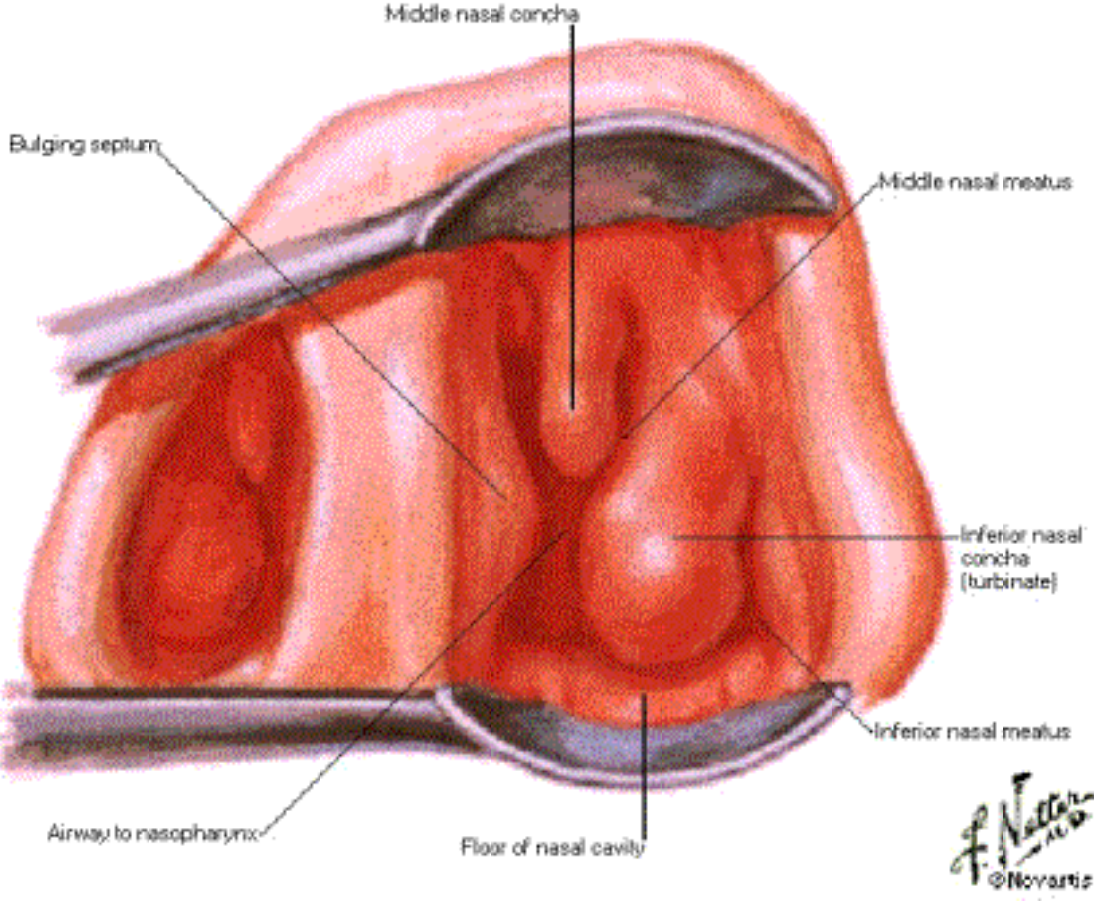


F. Netter M.D.
© Novartis

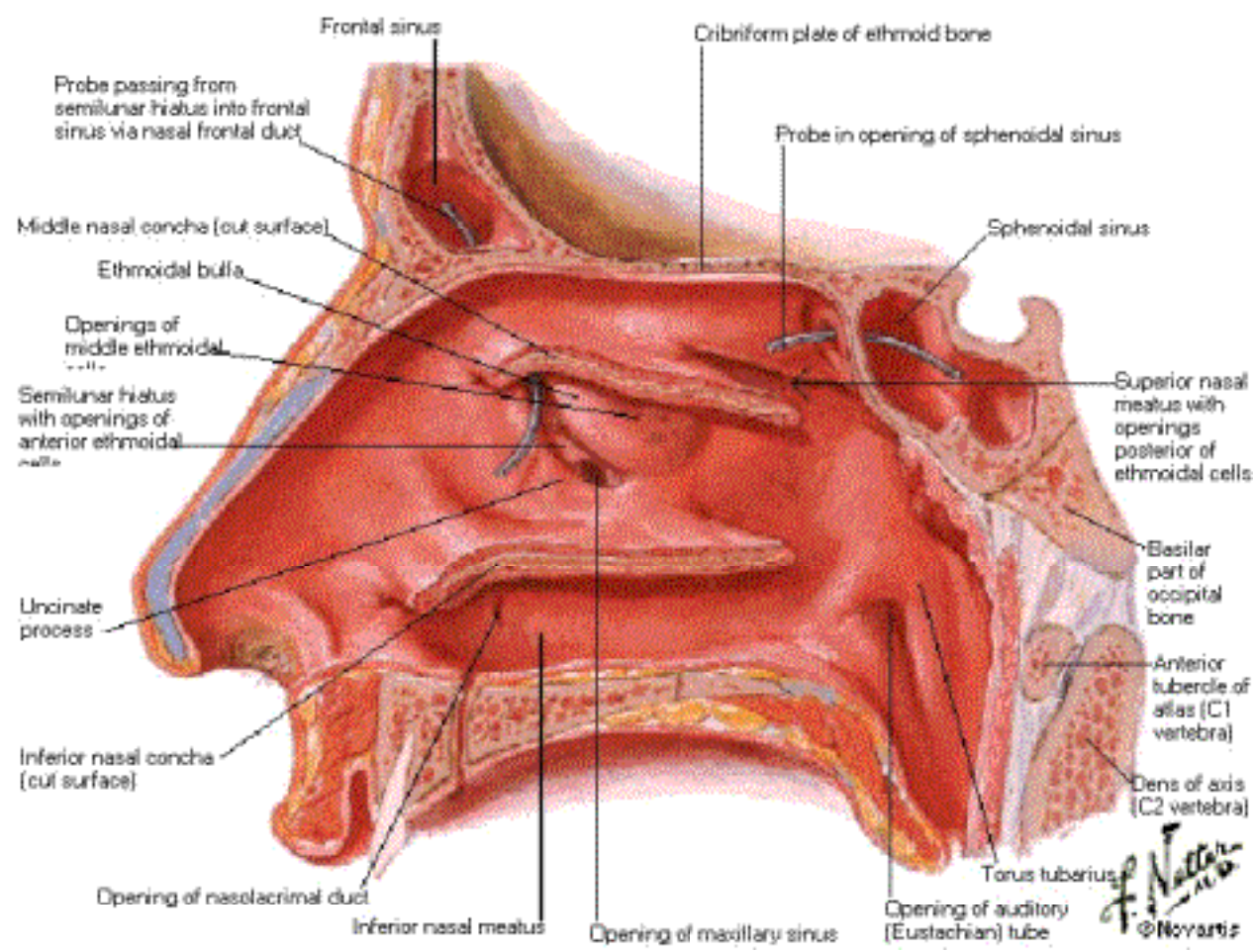
Lateral Nasal Wall



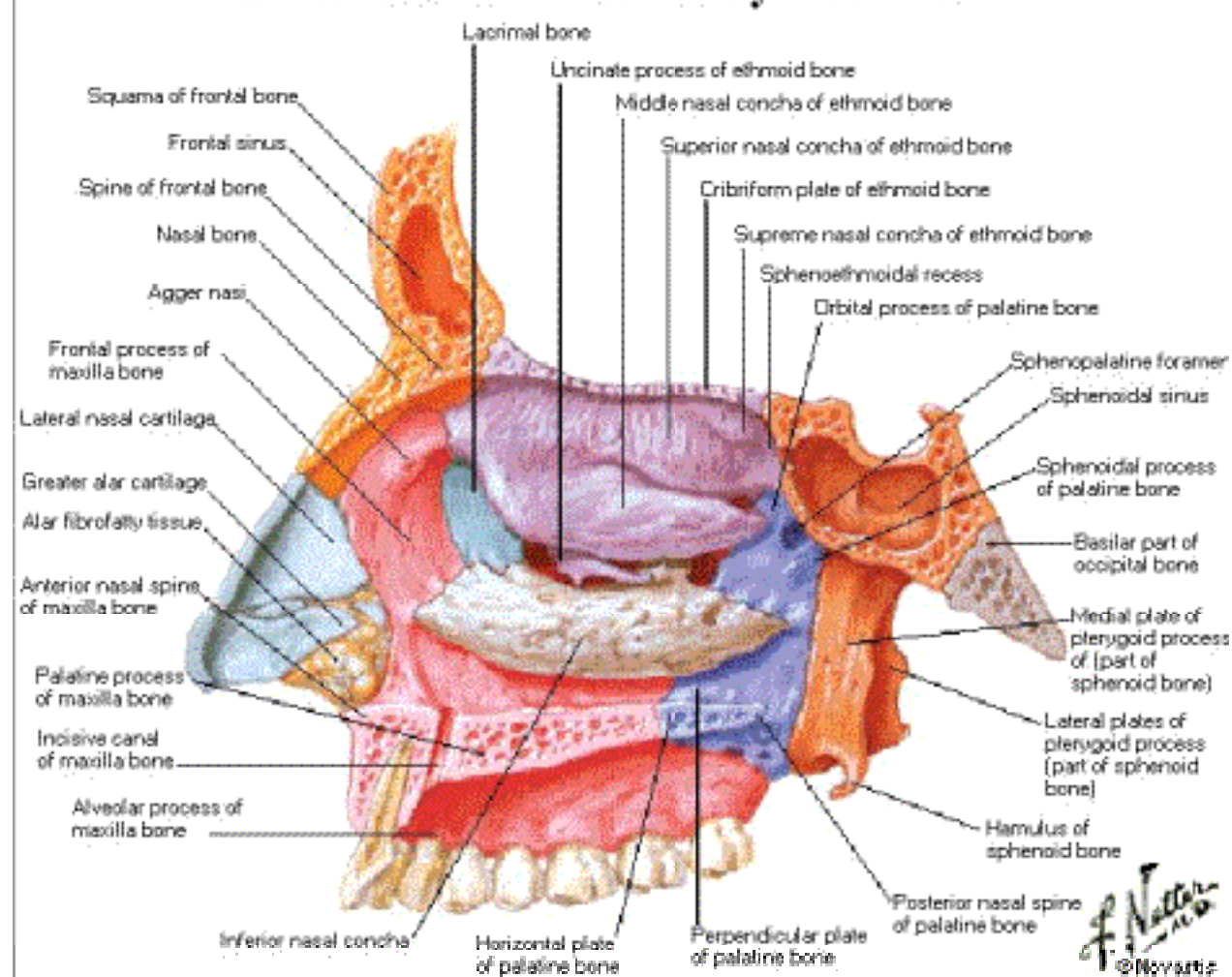
Nasal Cavity
Speculum View



Lateral Nasal Wall - Nasal Conchae Removed

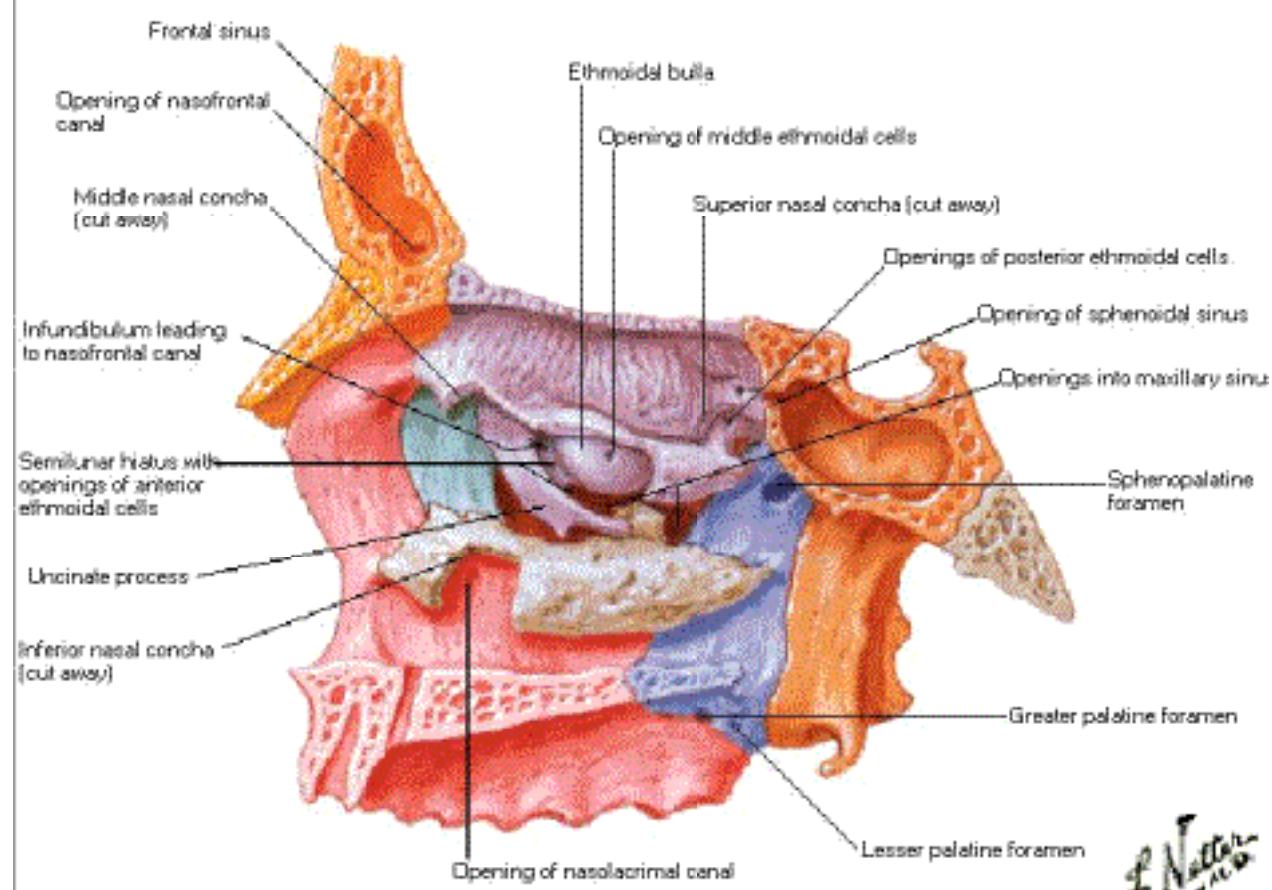


Lateral Nasal Wall - Bony Structure

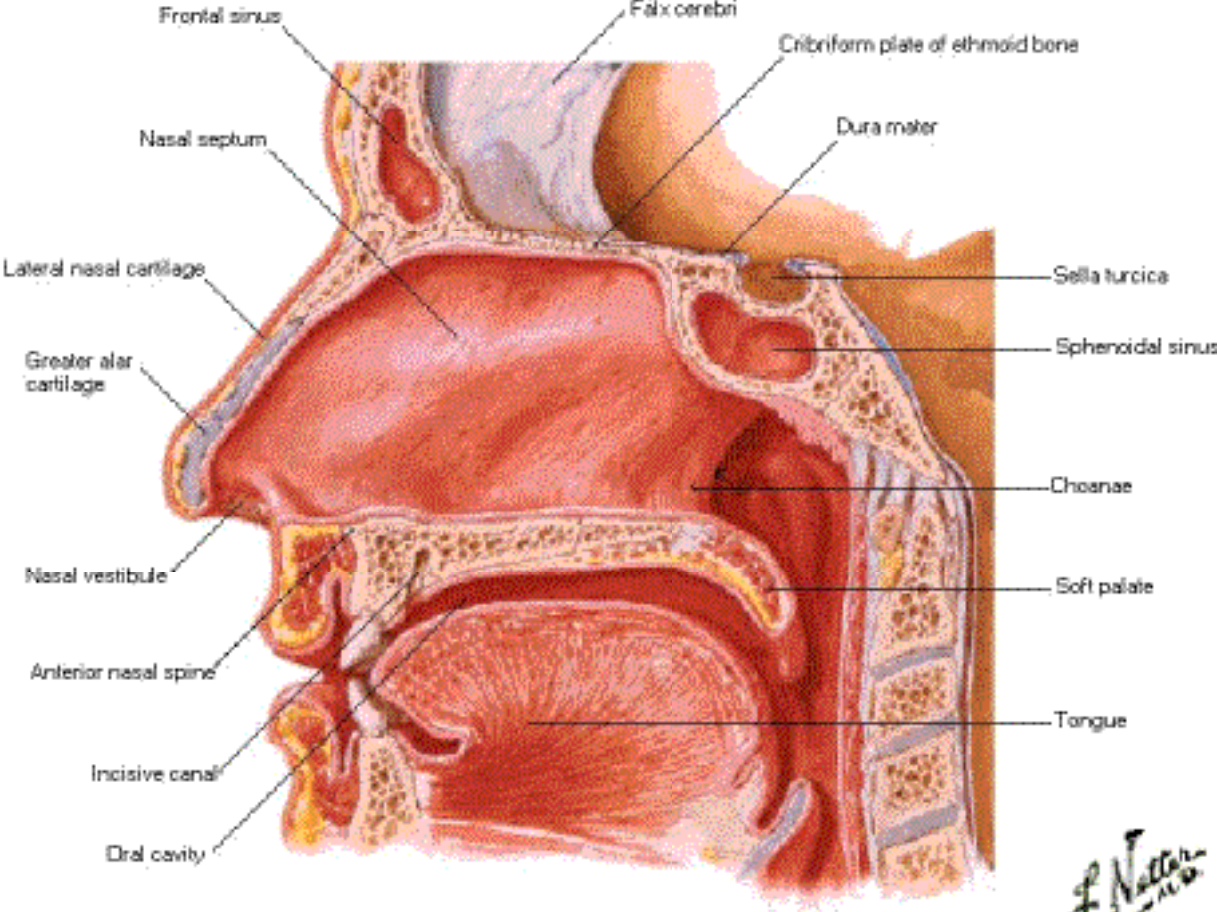


Lateral Nasal Wall - Bony Structure

Nasal Conchae Partly Removed

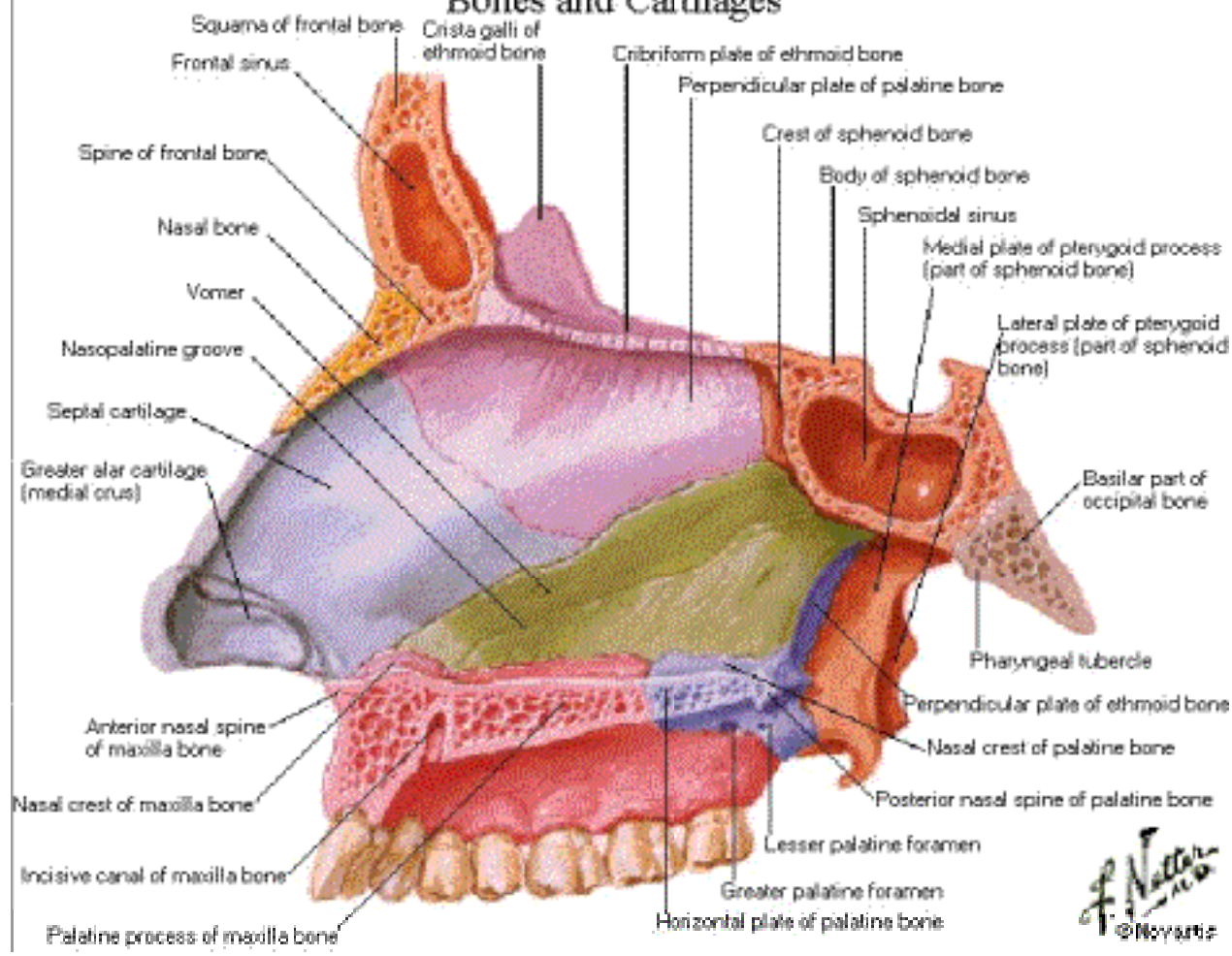


Medial Nasal Wall [Septum]



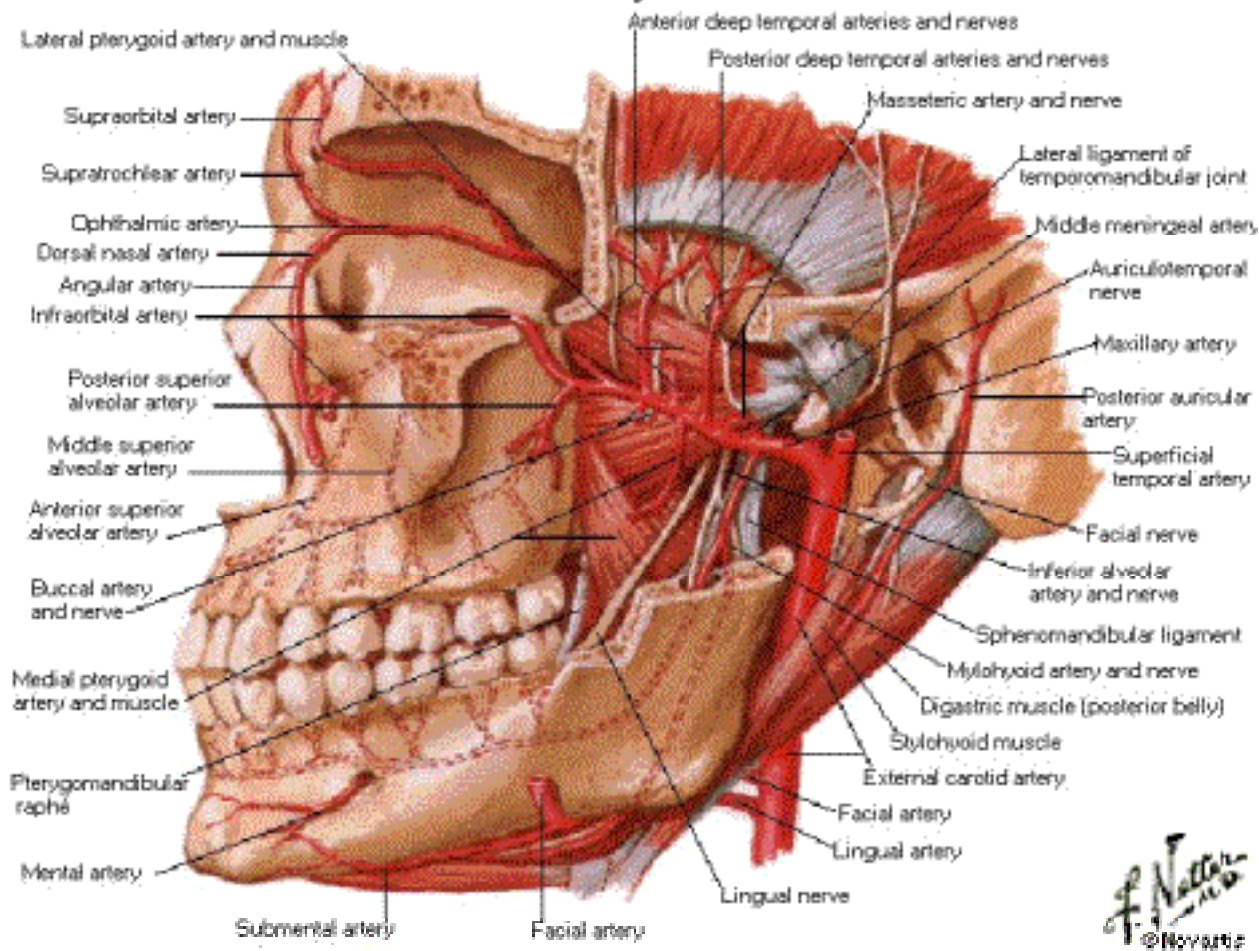
Medial Nasal Wall [Septum]

Bones and Cartilages



Maxillary Artery

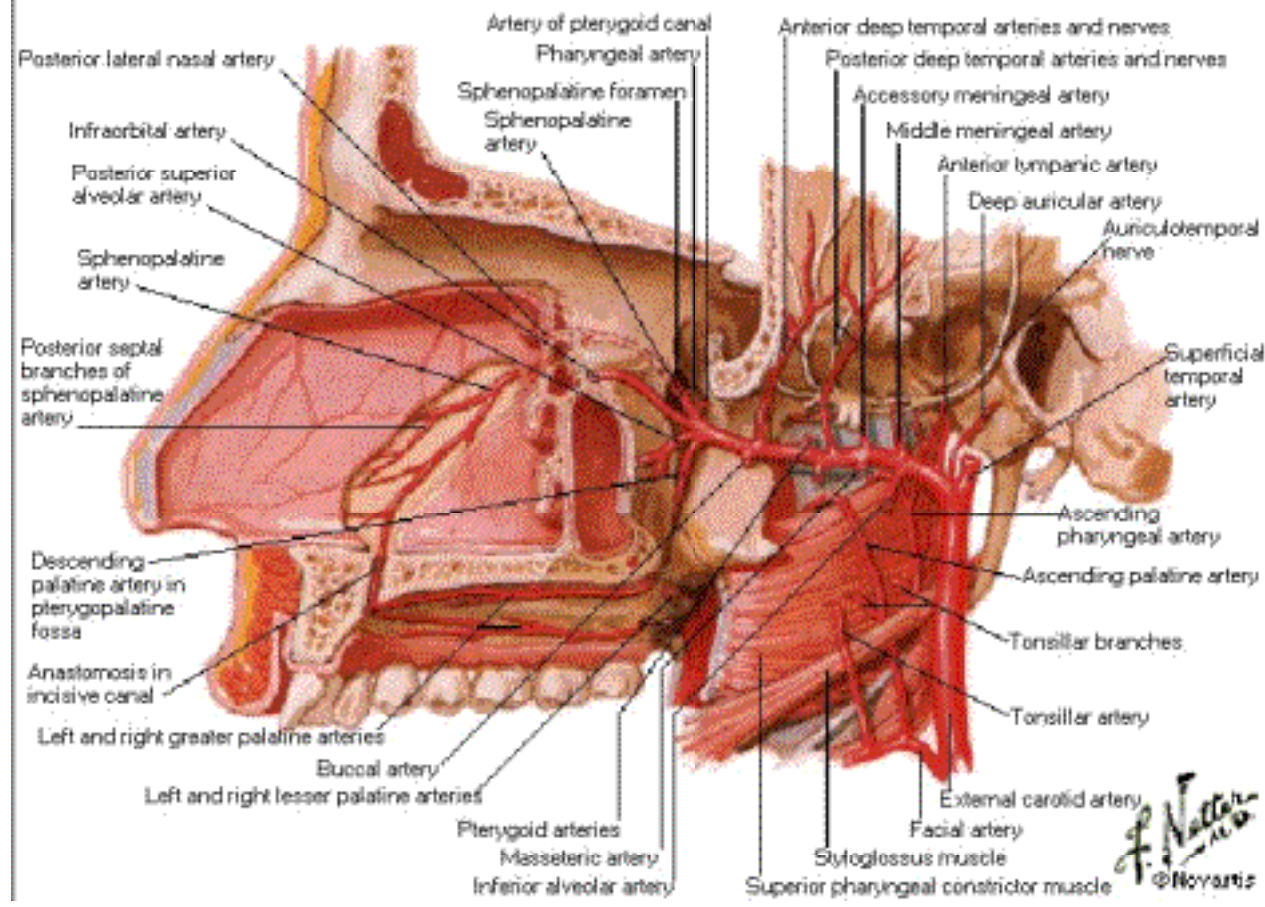
Orbitomaxillary Distribution



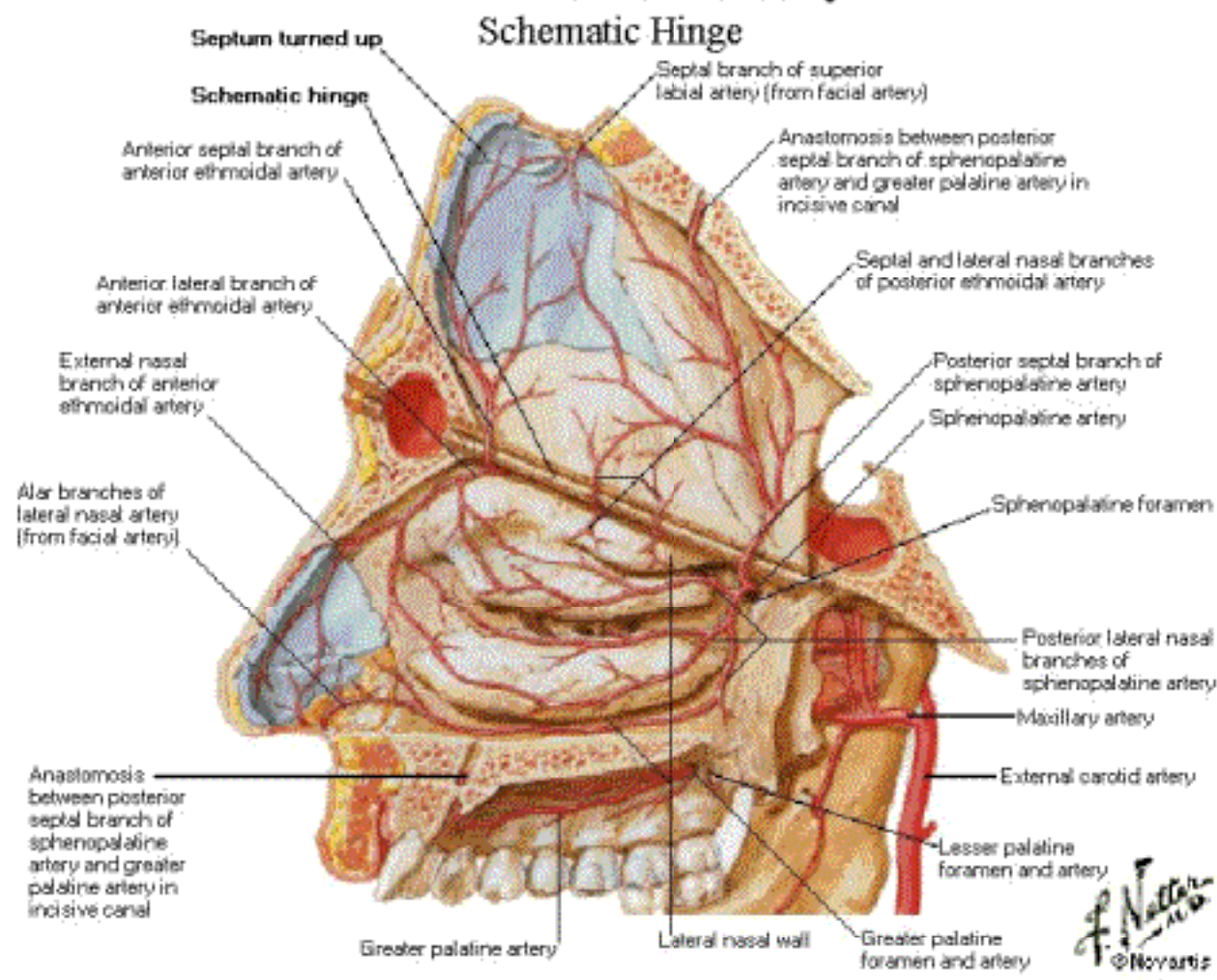
F. Netter
© Novartis

Maxillary Artery

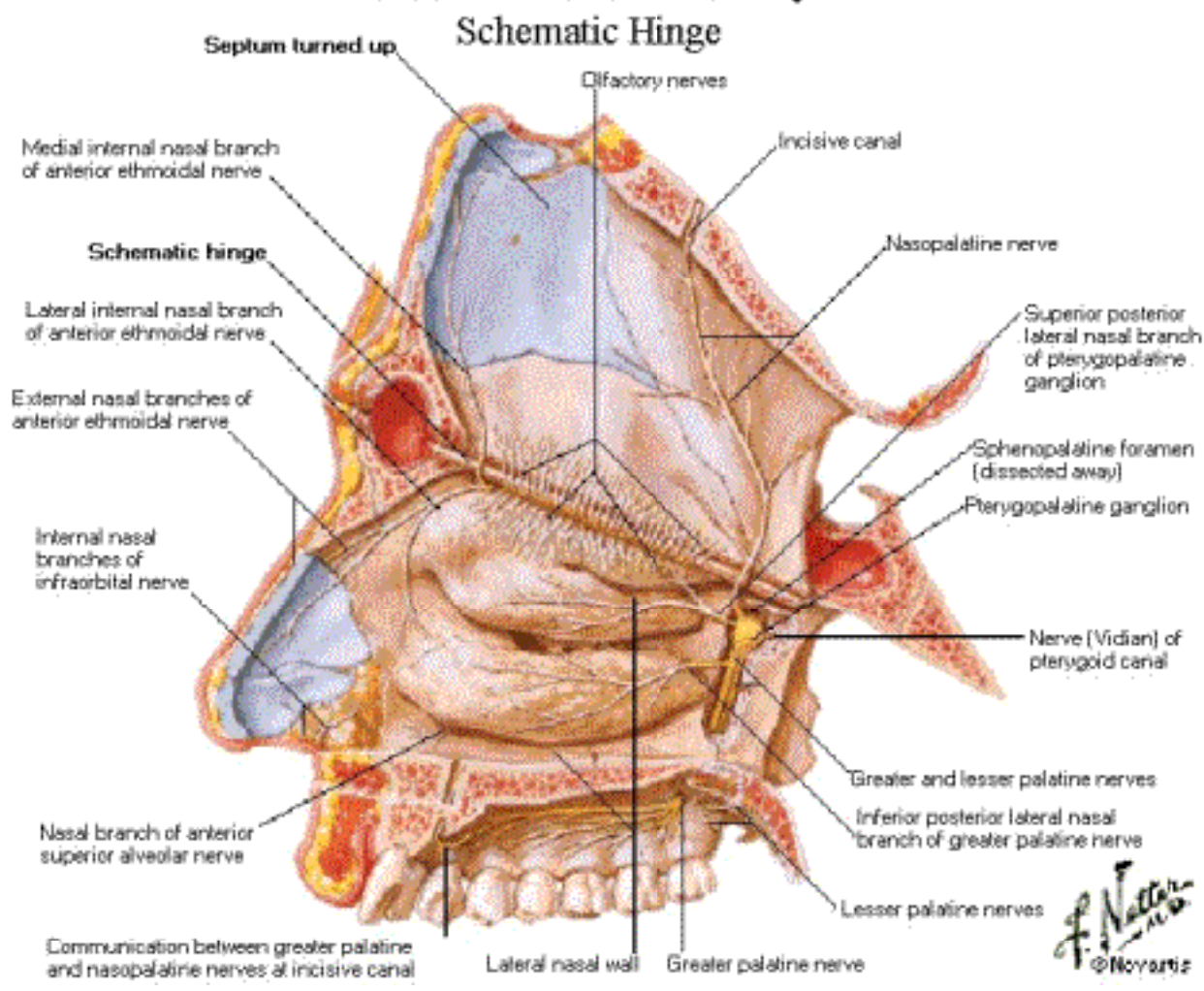
Nasopalatine Distribution



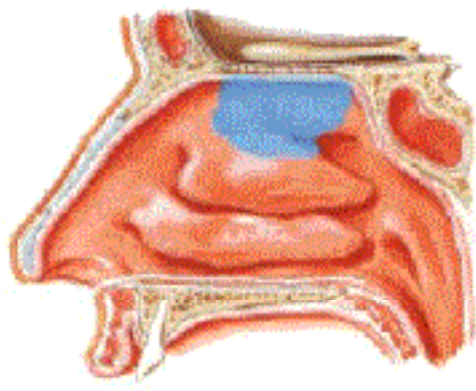
Arteries of Nasal Cavity



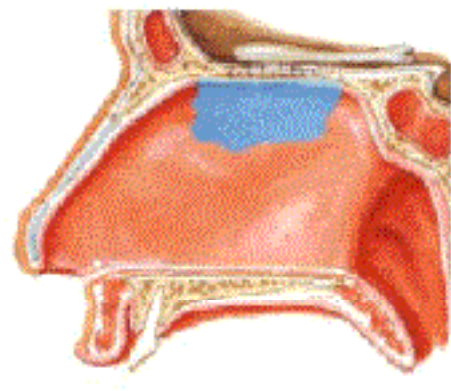
Nerves of Nasal Cavity



Nerves of Nasal Cavity
Distribution of Olfactory Mucosa



Lateral nasal wall



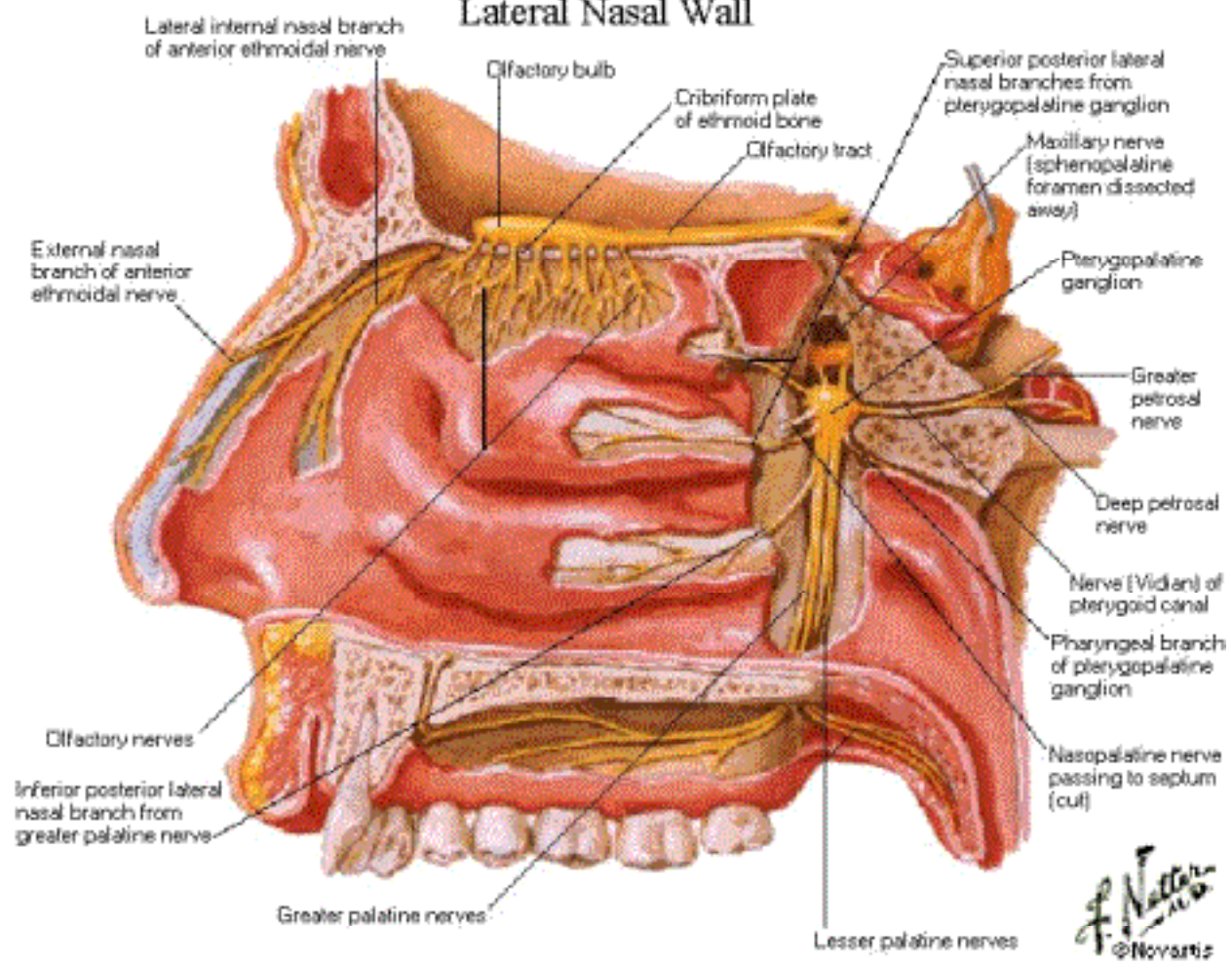
Nasal septum

Note: Distribution of olfactory mucosa is shaded blue.

F. Netter M.D.
© Novartis

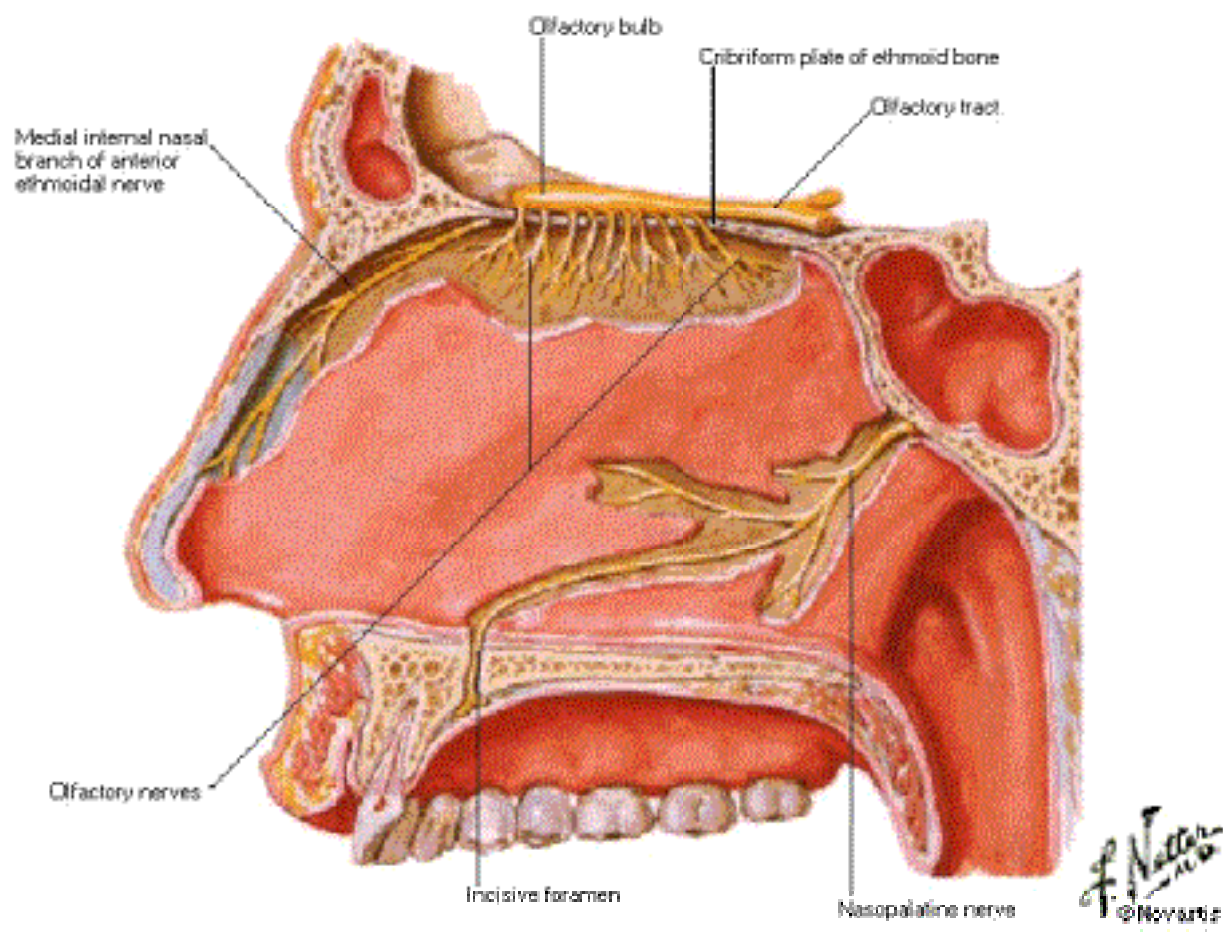
Nerves of Nasal Cavity

Lateral Nasal Wall

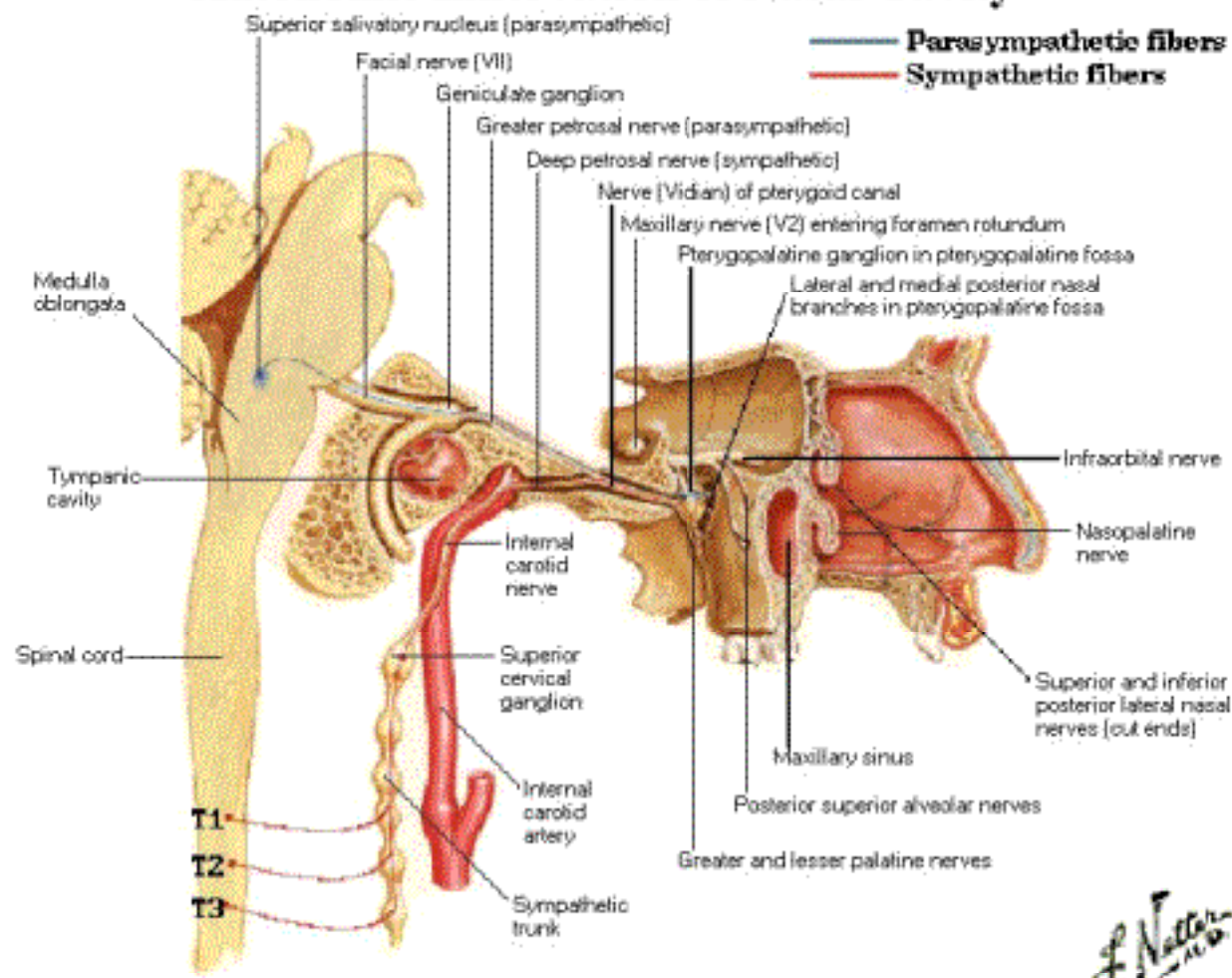


Nerves of Nasal Cavity

Nasal Septum

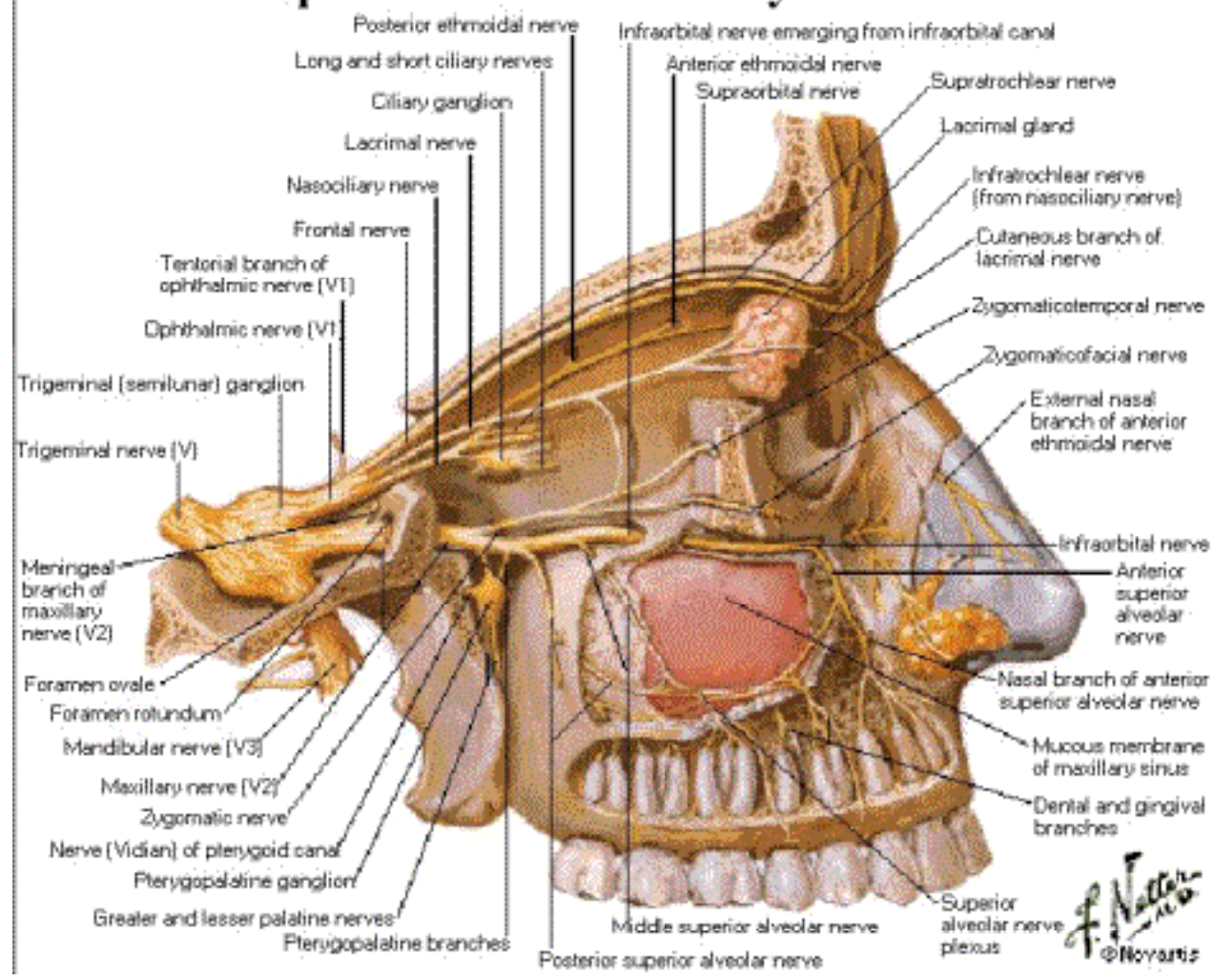


Autonomic Innervation of Nasal Cavity



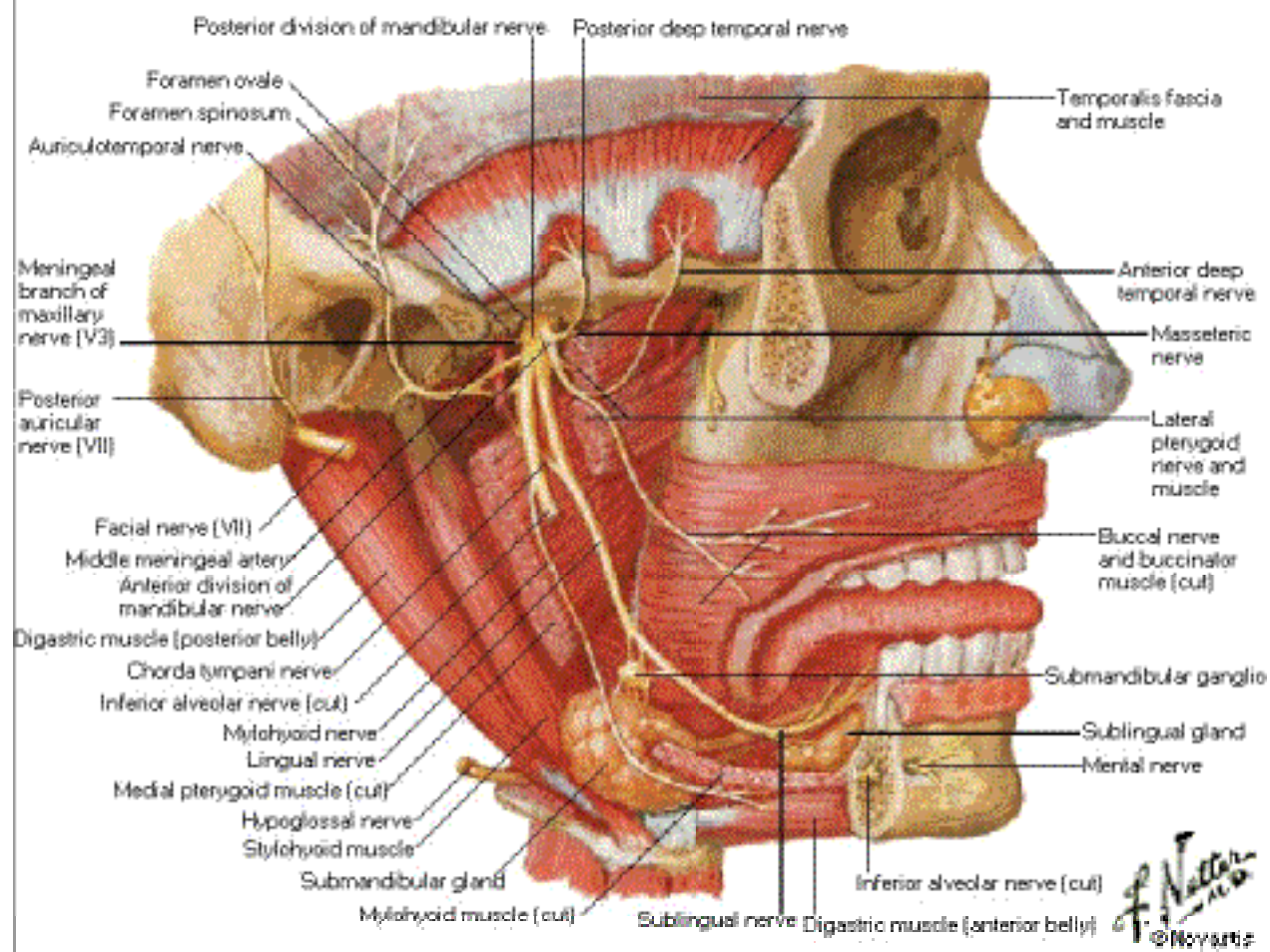
F. Netter M.D.
 © Novartis

Ophthalmic and Maxillary Nerves



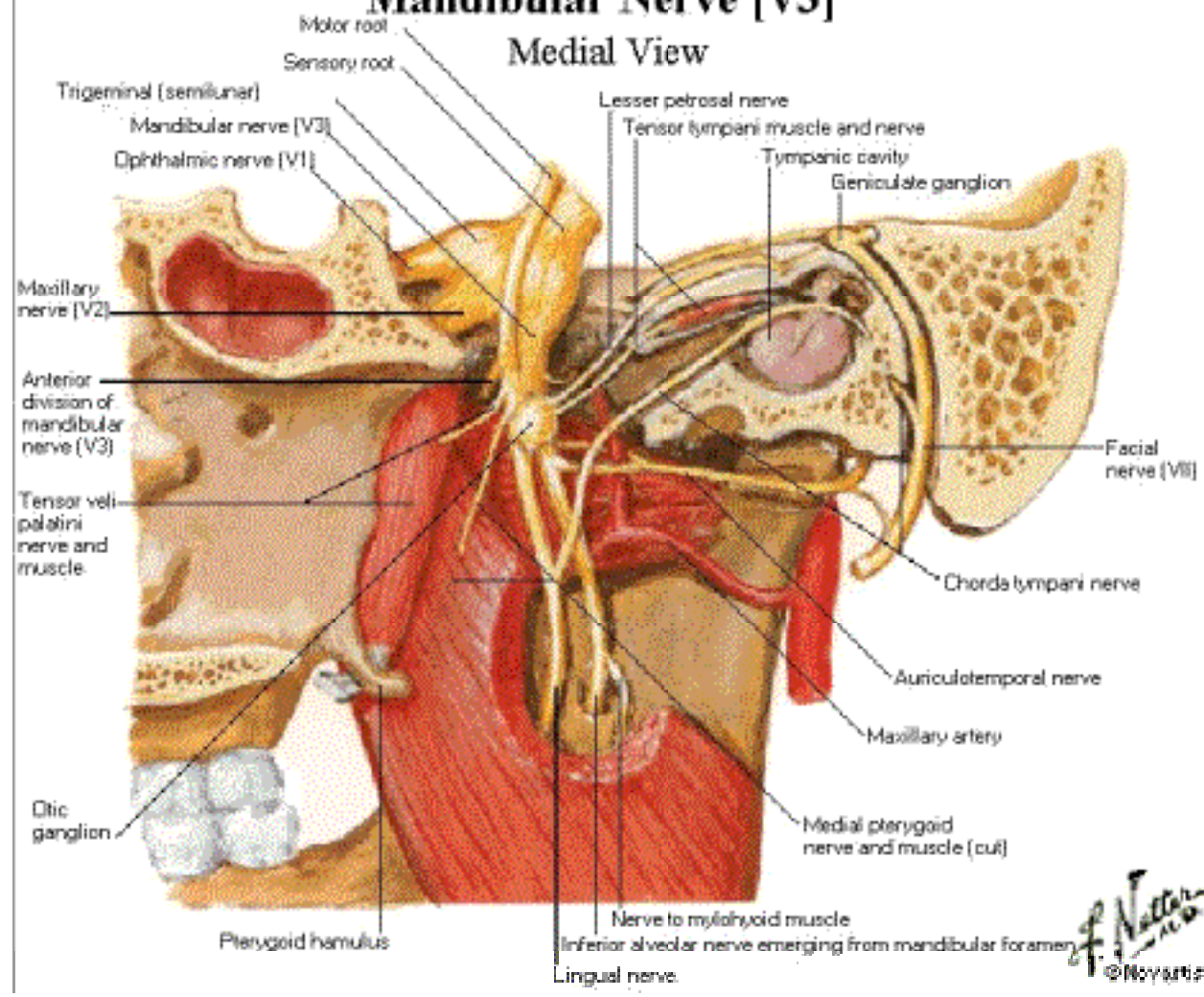
Mandibular Nerve [V3]

Lateral View



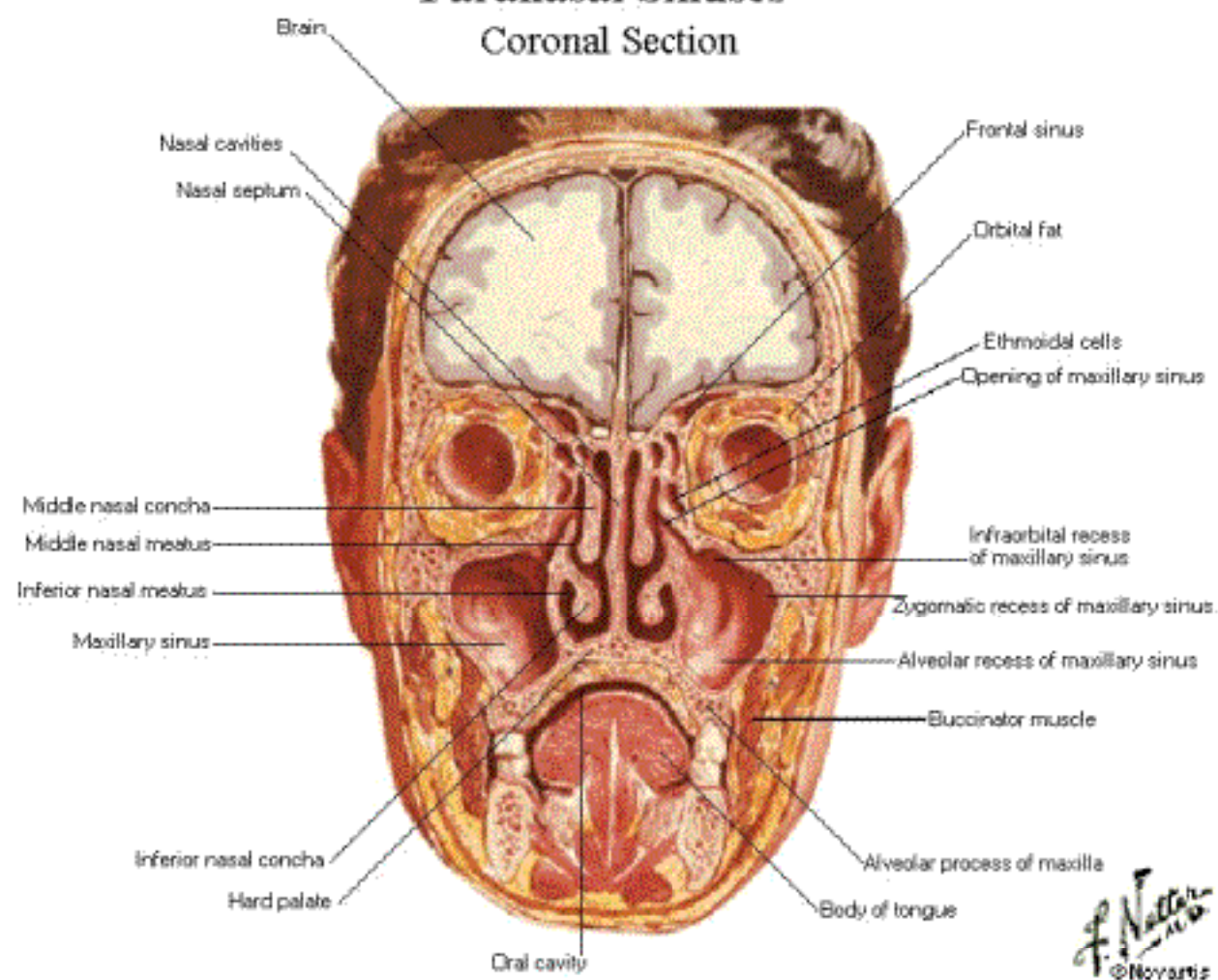
Mandibular Nerve [V3]

Medial View

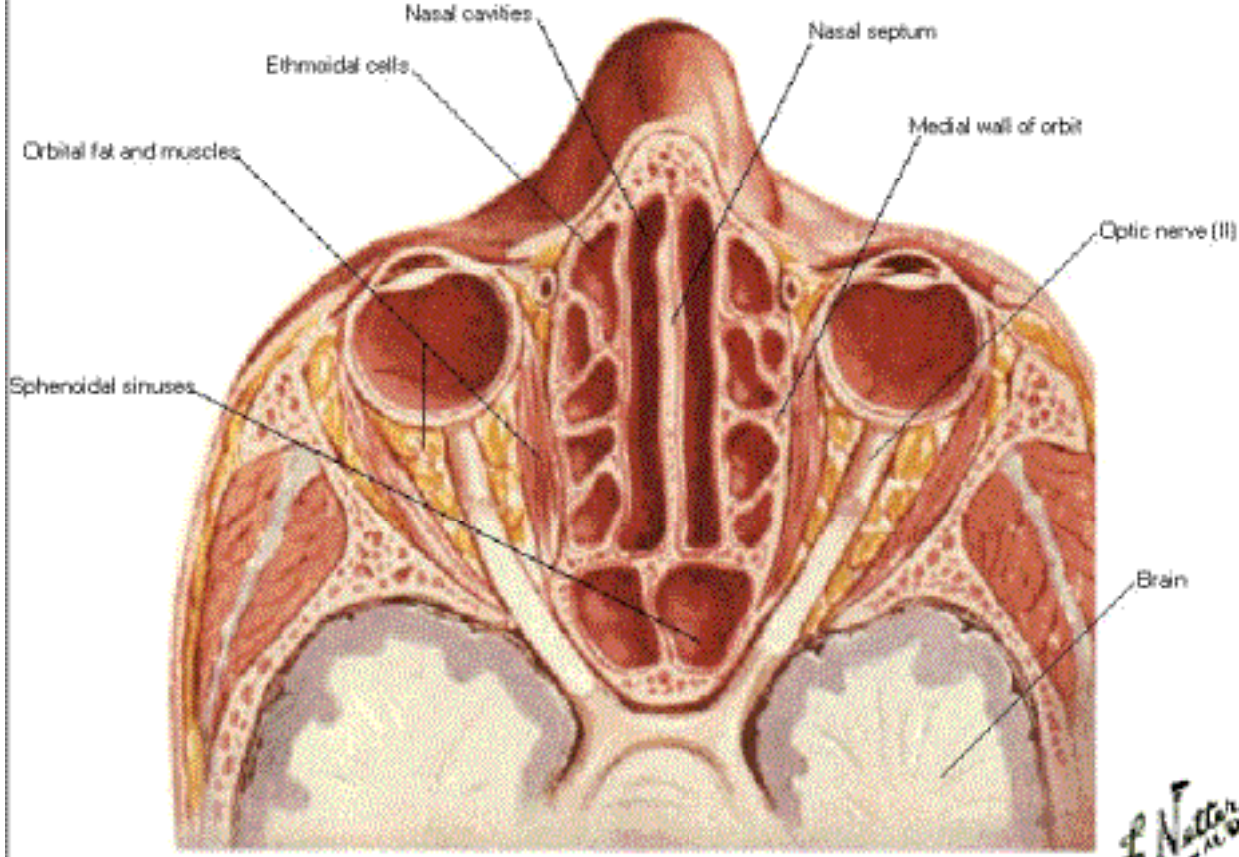


Paranasal Sinuses

Coronal Section



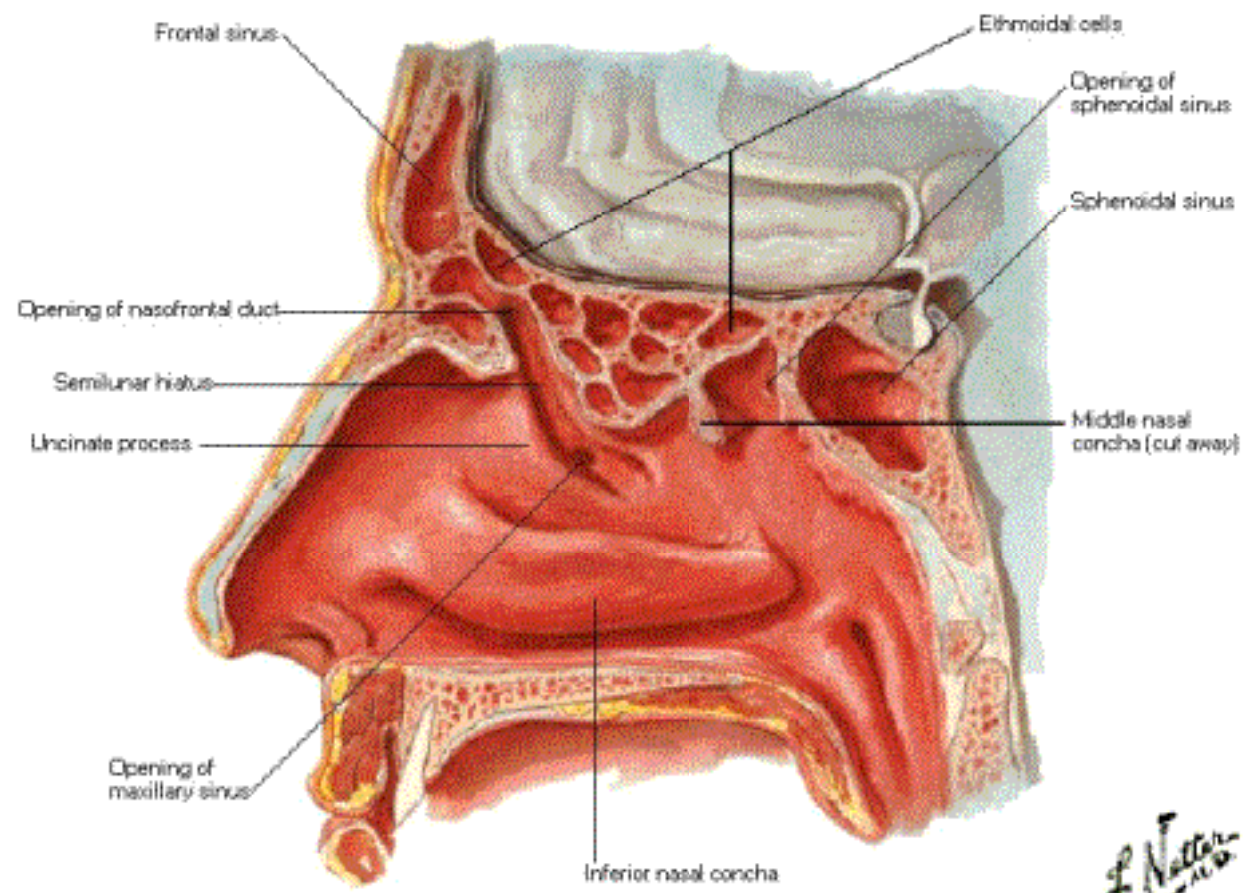
Paranasal Sinuses
Horizontal Section



F. Netter M.D.
© Novartis

Paranasal Sinuses

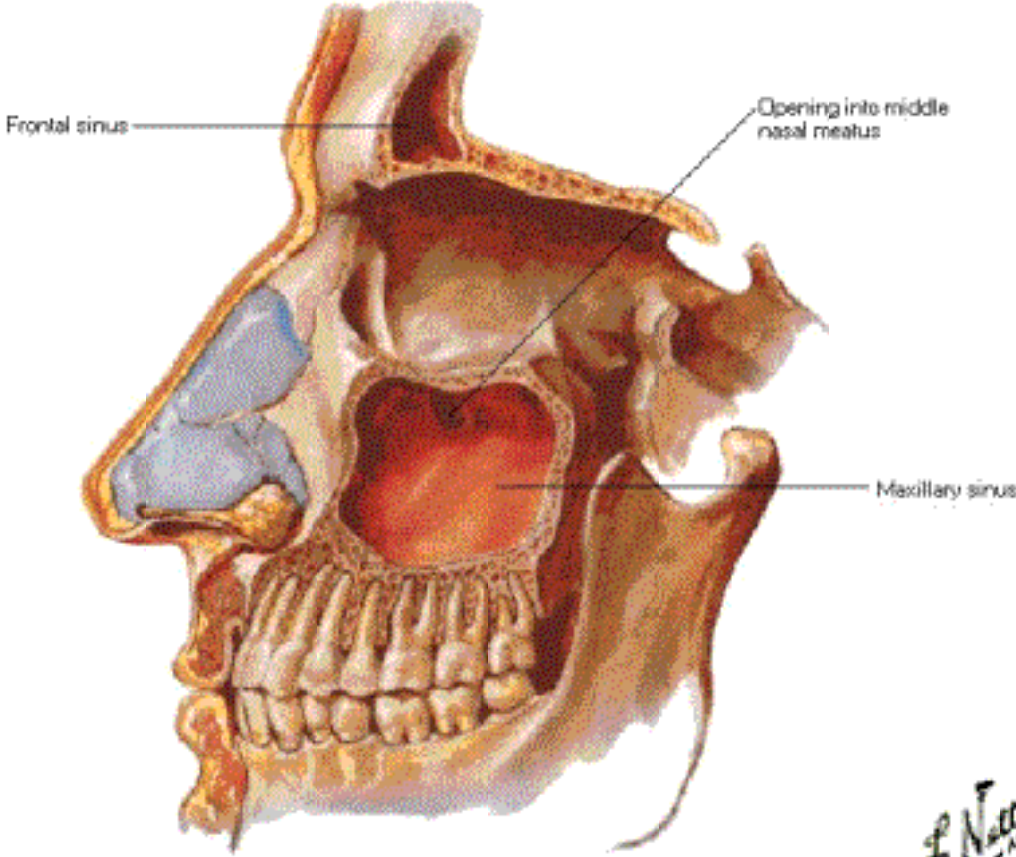
Sagittal Section



F. Netter
© 2010
© Novartis

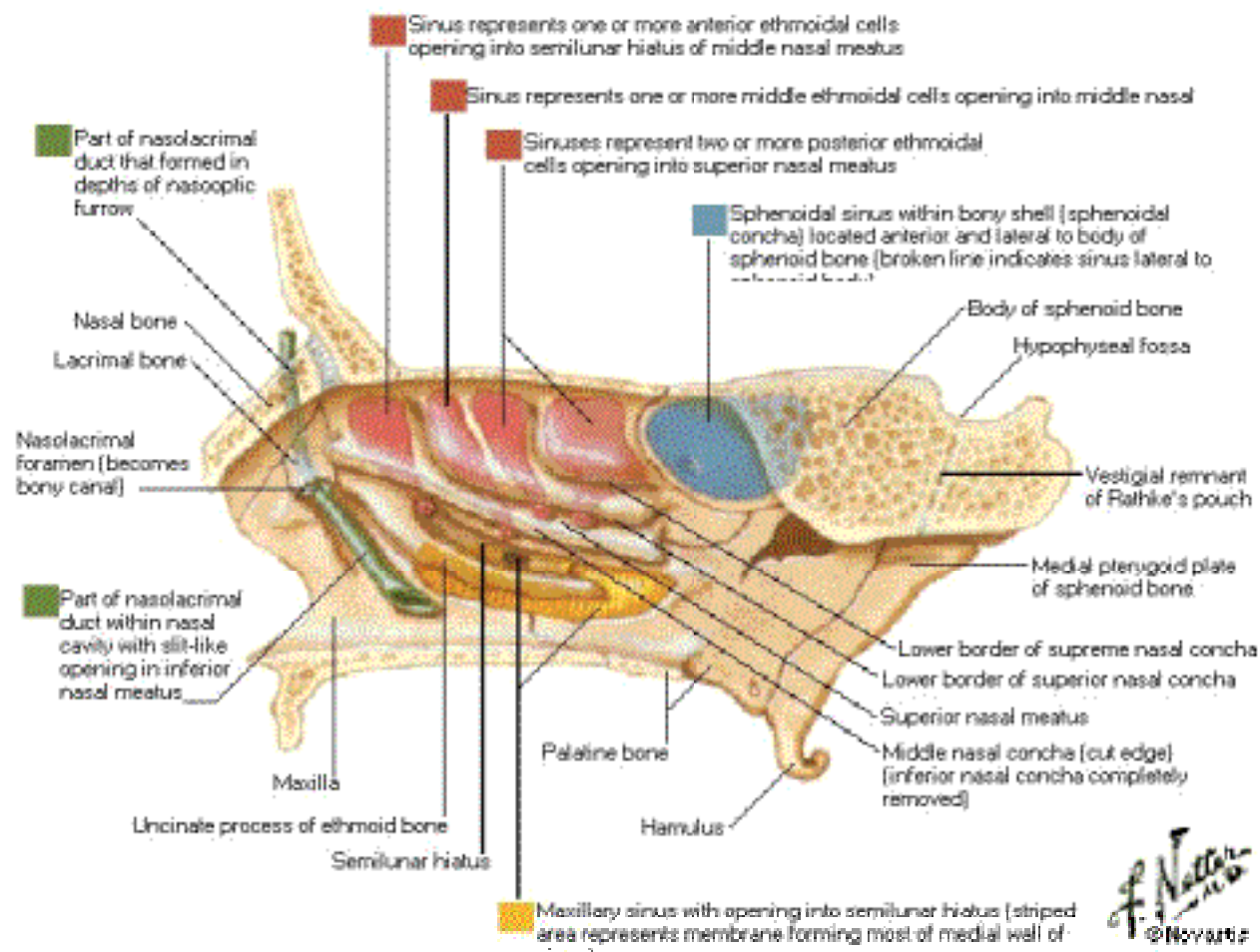
Paranasal Sinuses

Lateral Dissection



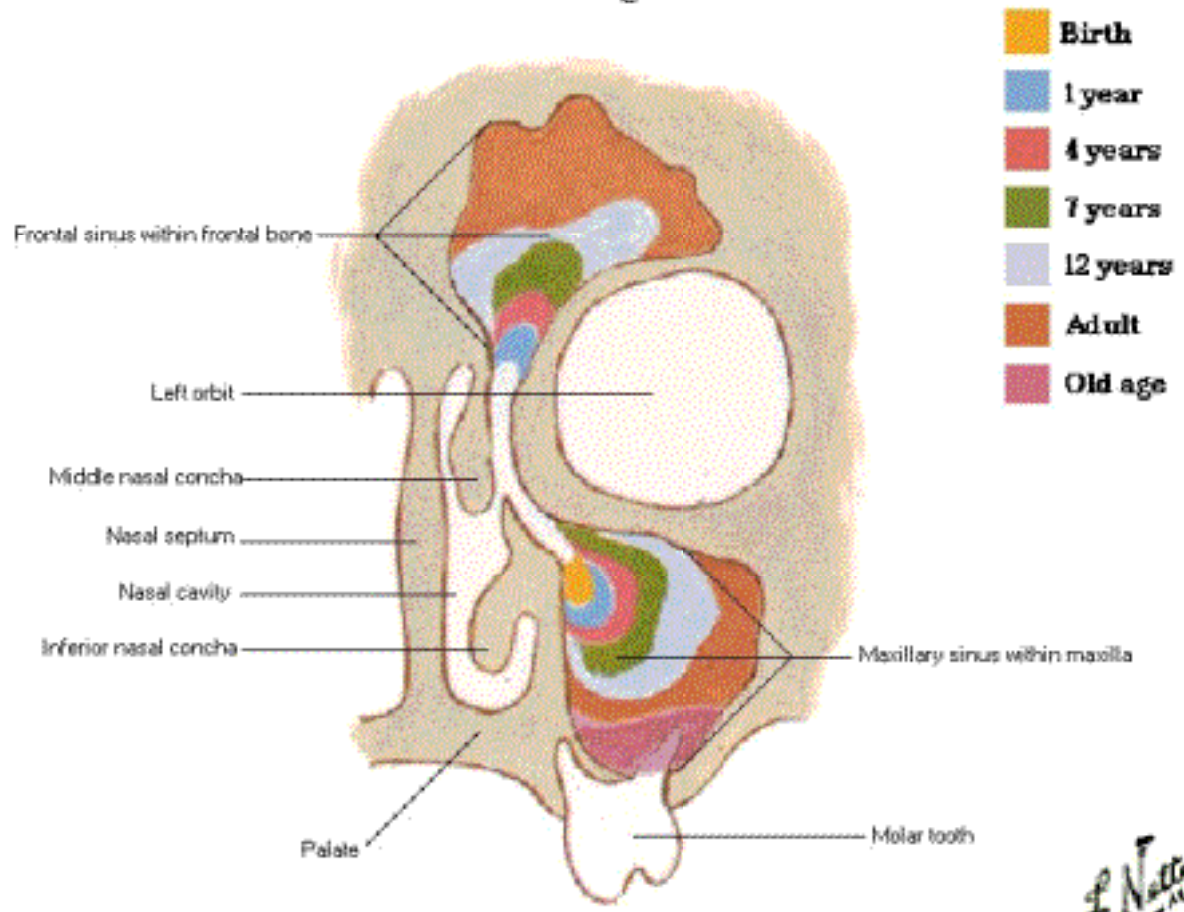
Paranasal Sinuses

At Birth



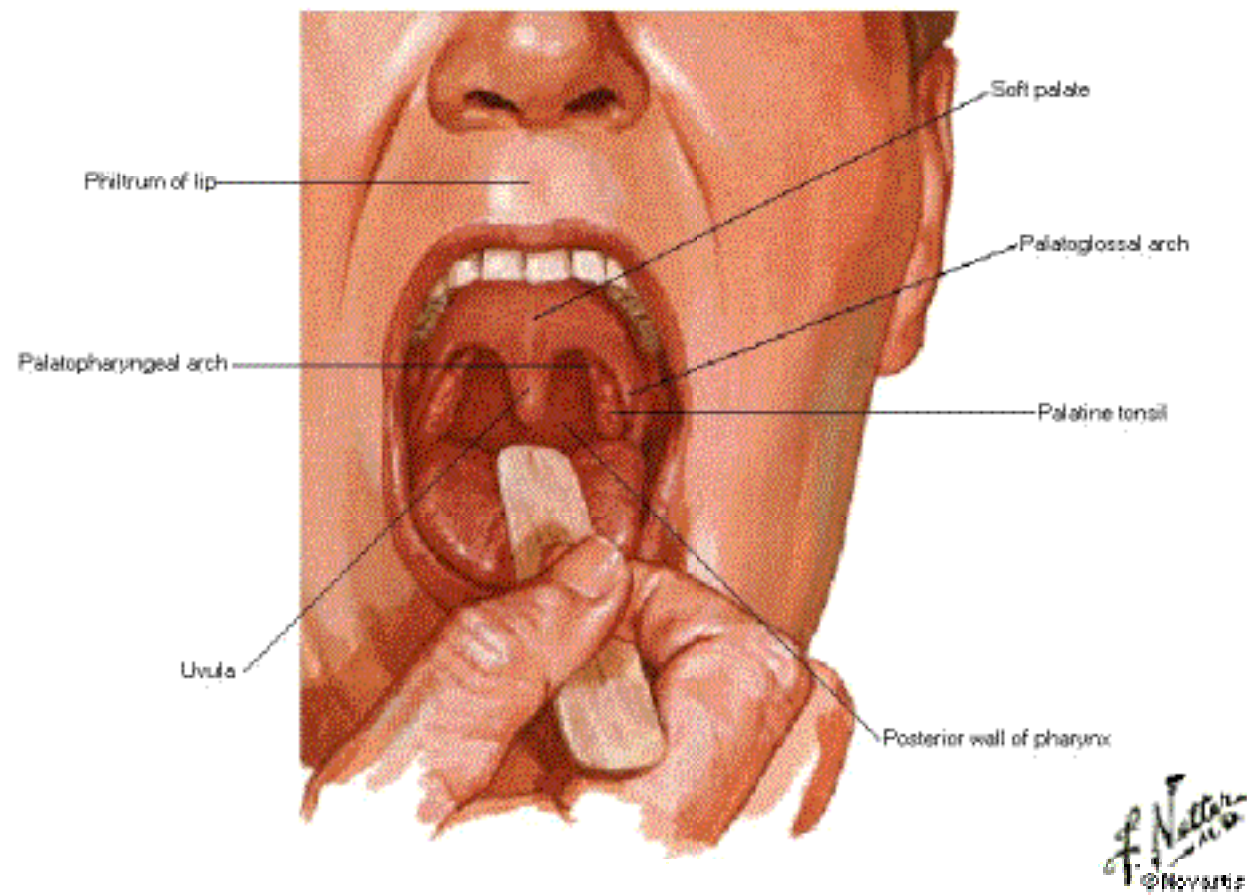
Paranasal Sinuses

Growth throughout Life



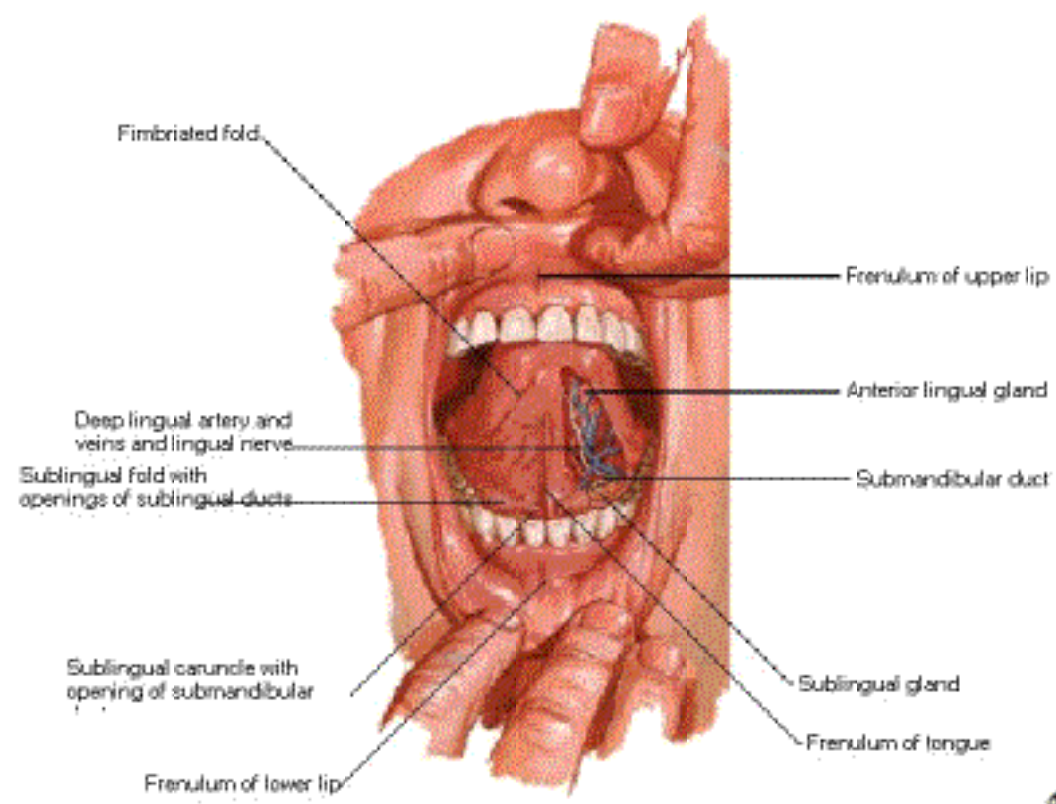
Inspection of Oral Cavity

Dorsum of Tongue and Palate



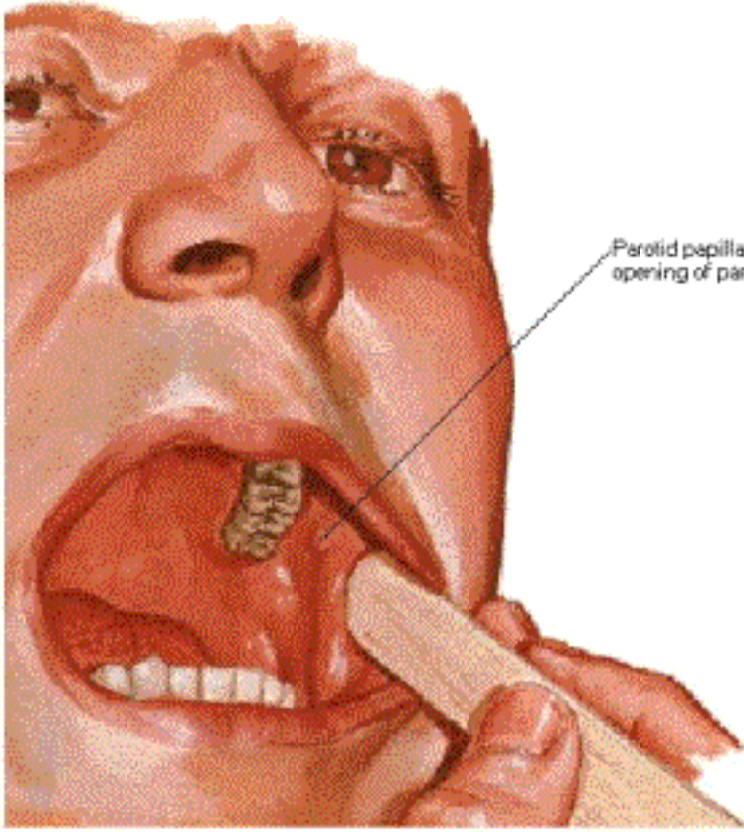
Inspection of Oral Cavity

Sublingual Region - Anterior Vestibule



F. Netter M.D.
© Novartis

Inspection of Oral Cavity
Lateral Oral Vestibule

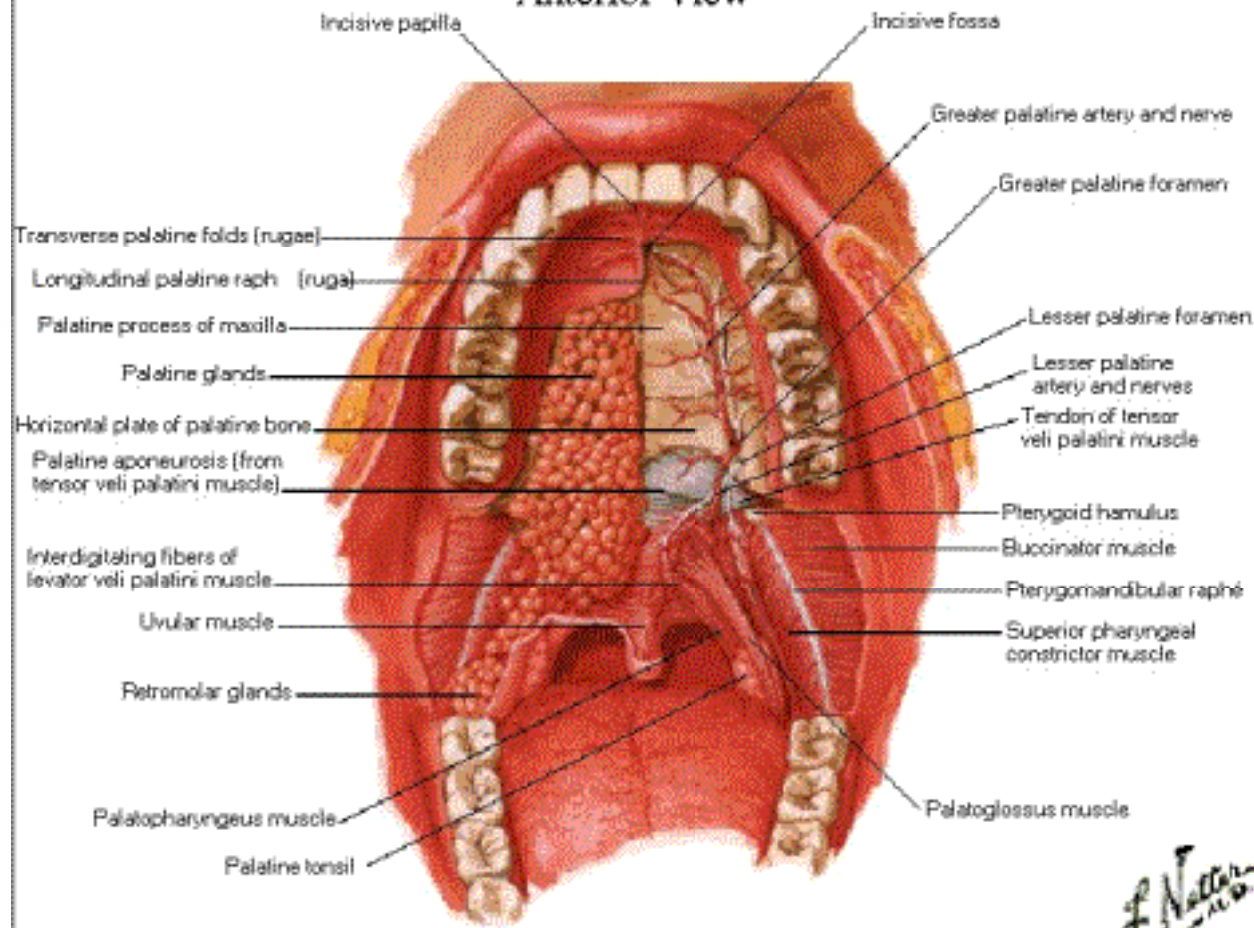


Parotid papilla with opening of parotid duct

F. Netter M.D.
© Novartis

Roof of Mouth - Hard and Soft Palates

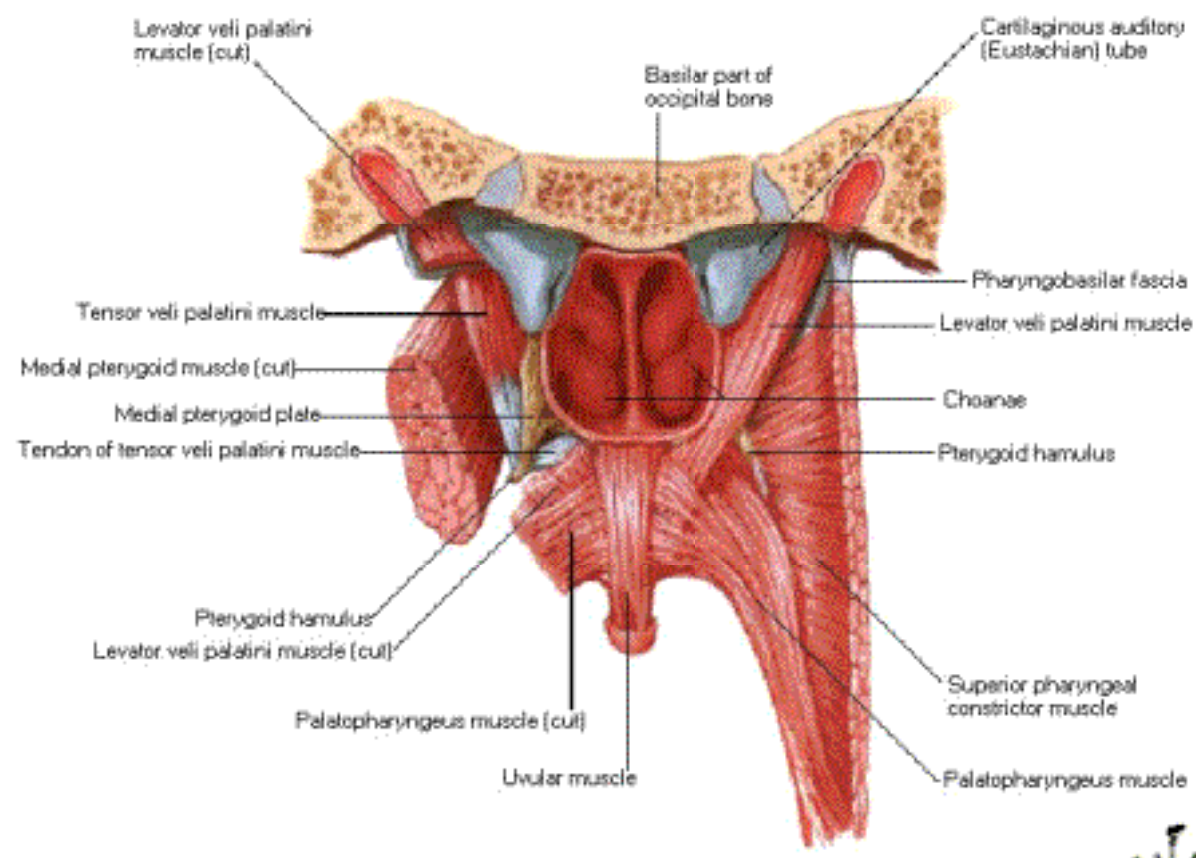
Anterior View



F. Netter M.D.
© 2005

Roof of Mouth - Soft Palate

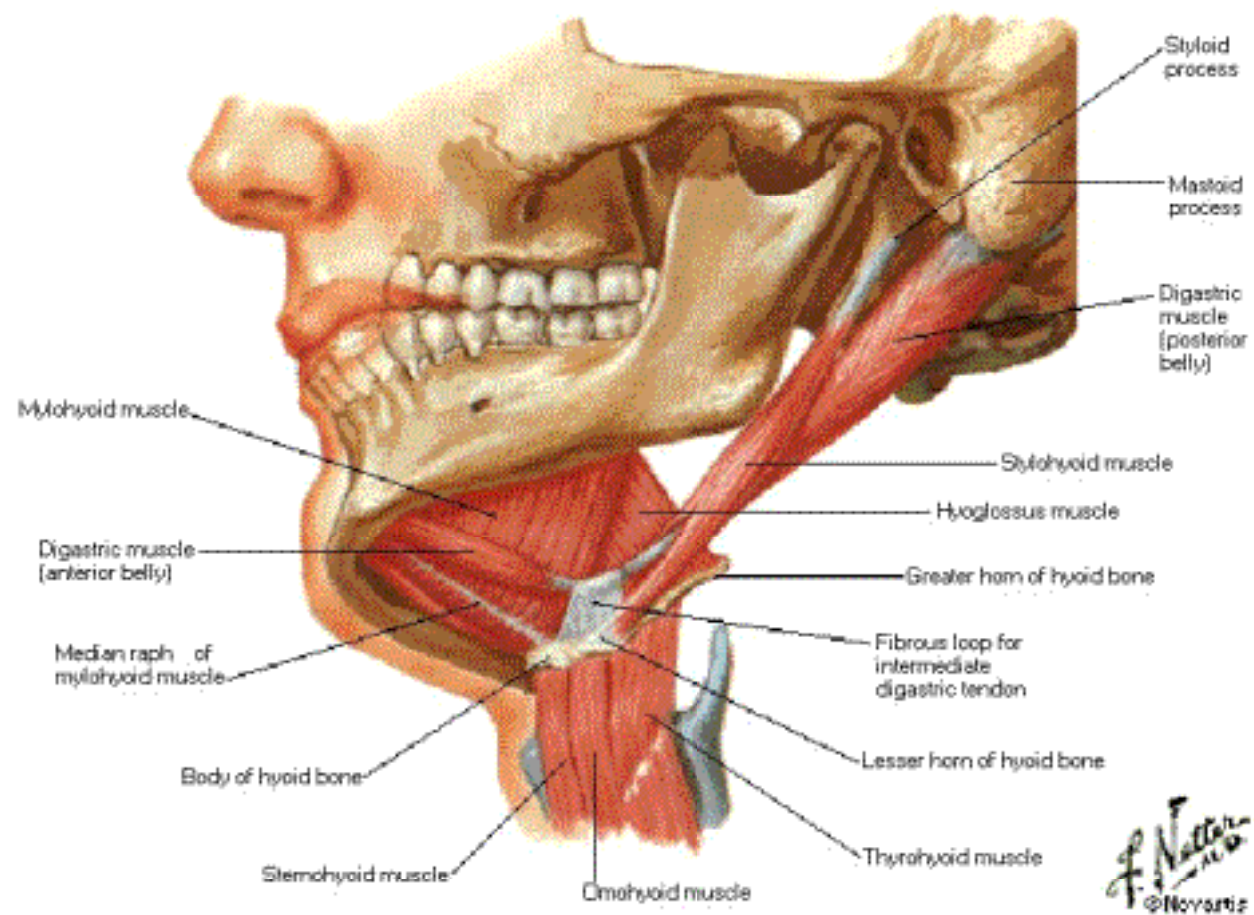
Posterior View



F. Netter
© Novartis

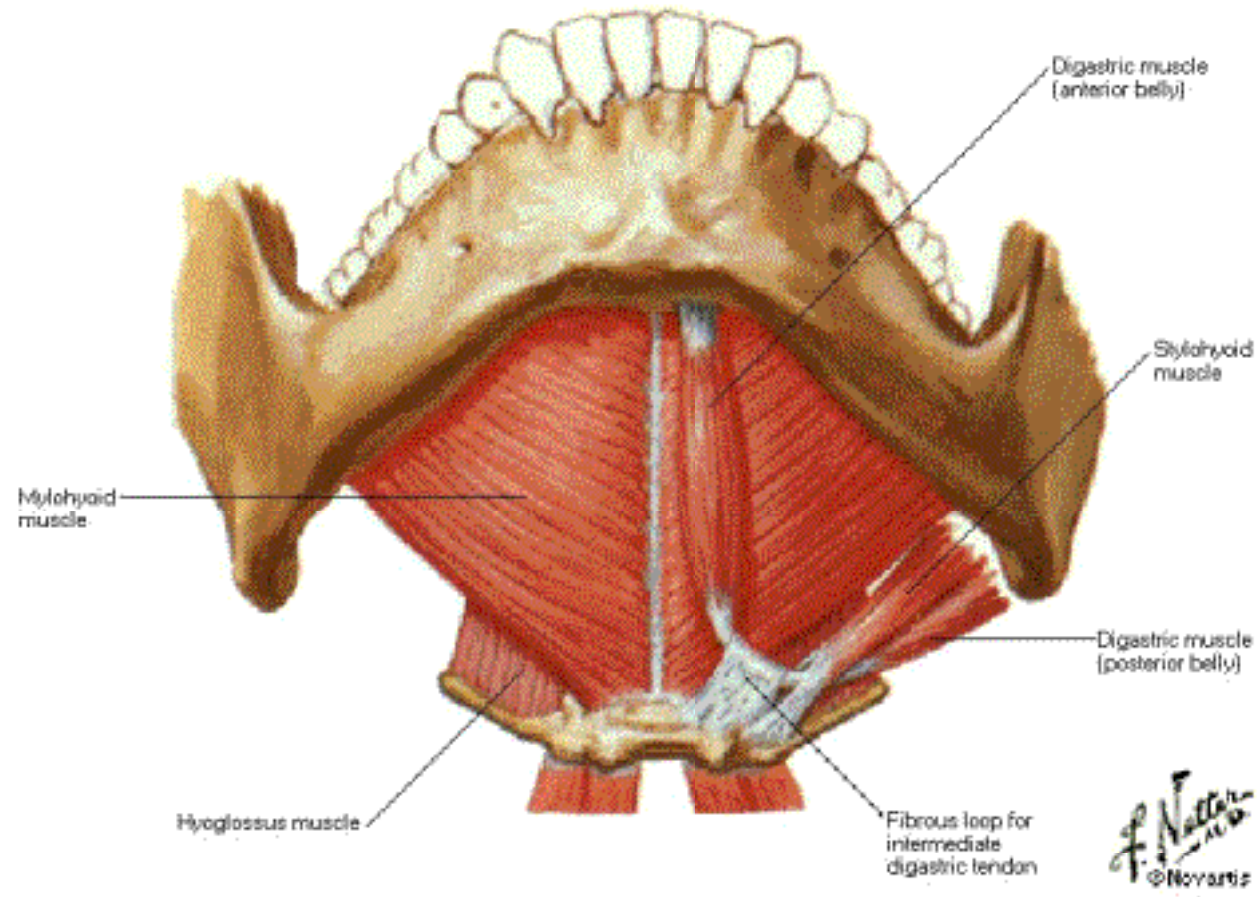
Floor of Mouth - Musculature

Lateral, Slightly Inferior View



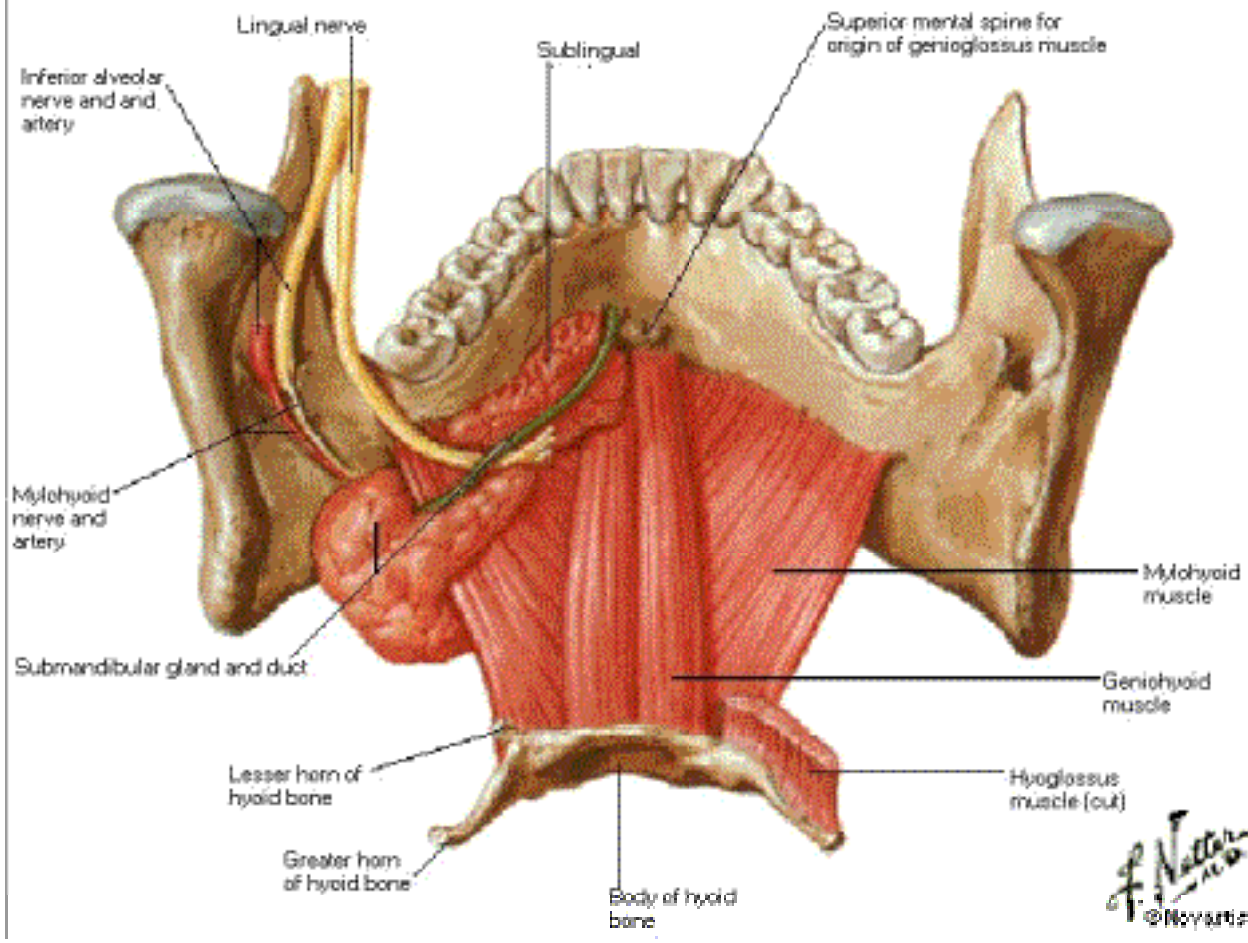
Floor of Mouth - Musculature

Anteroinferior View



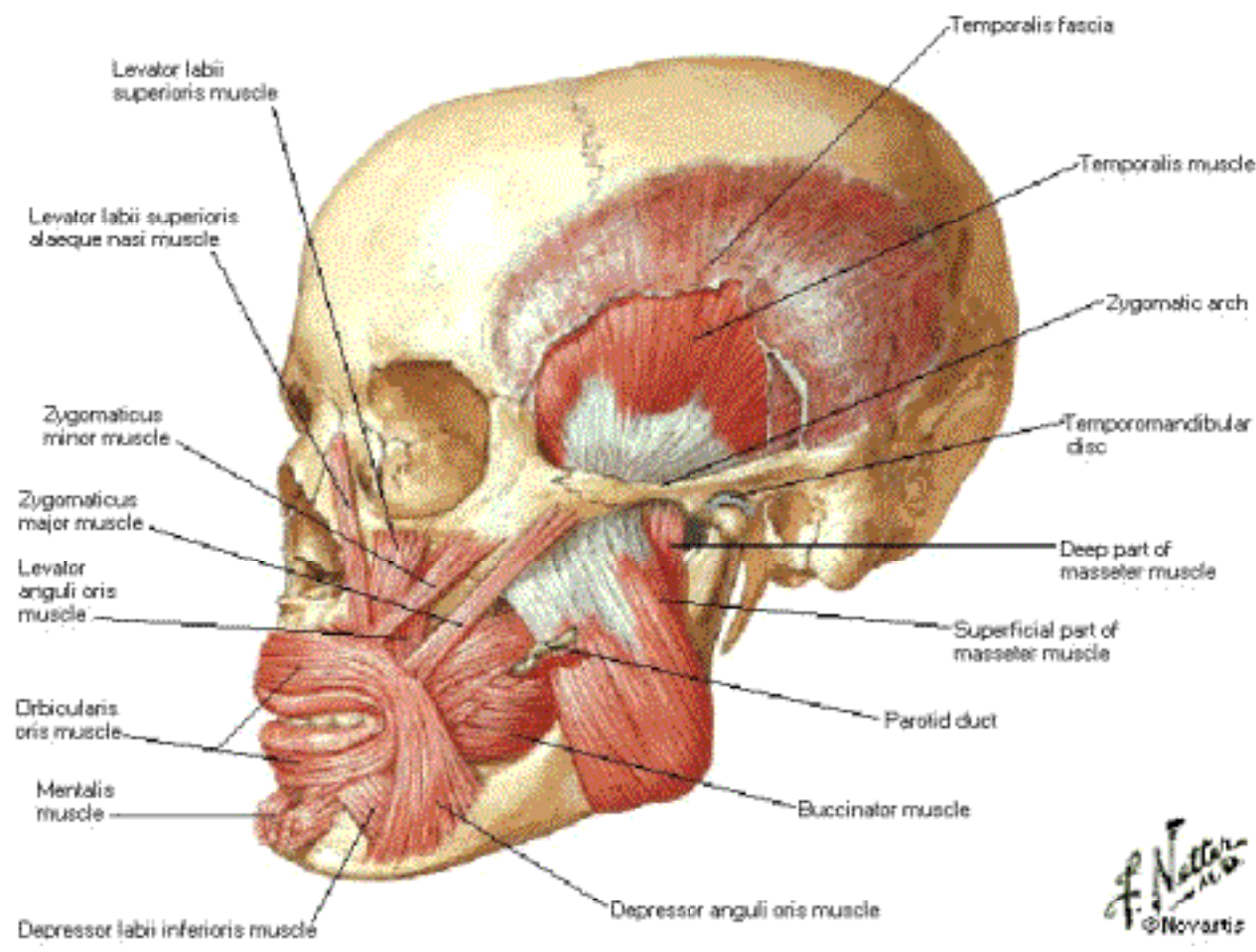
Floor of Mouth - Musculature

Posterosuperior View



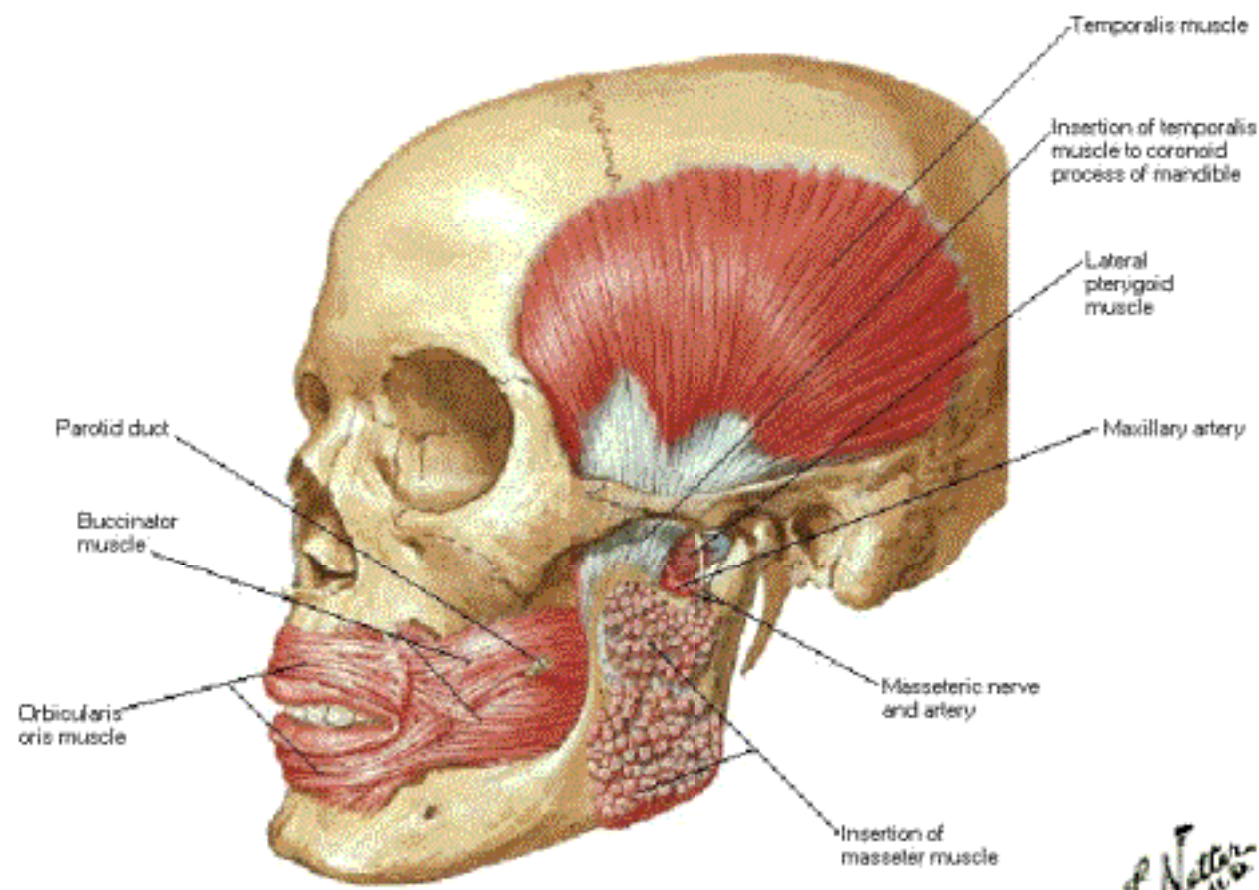
Muscles Involved in Mastication

Lateral View



Muscles Involved in Mastication - Masseter Removed

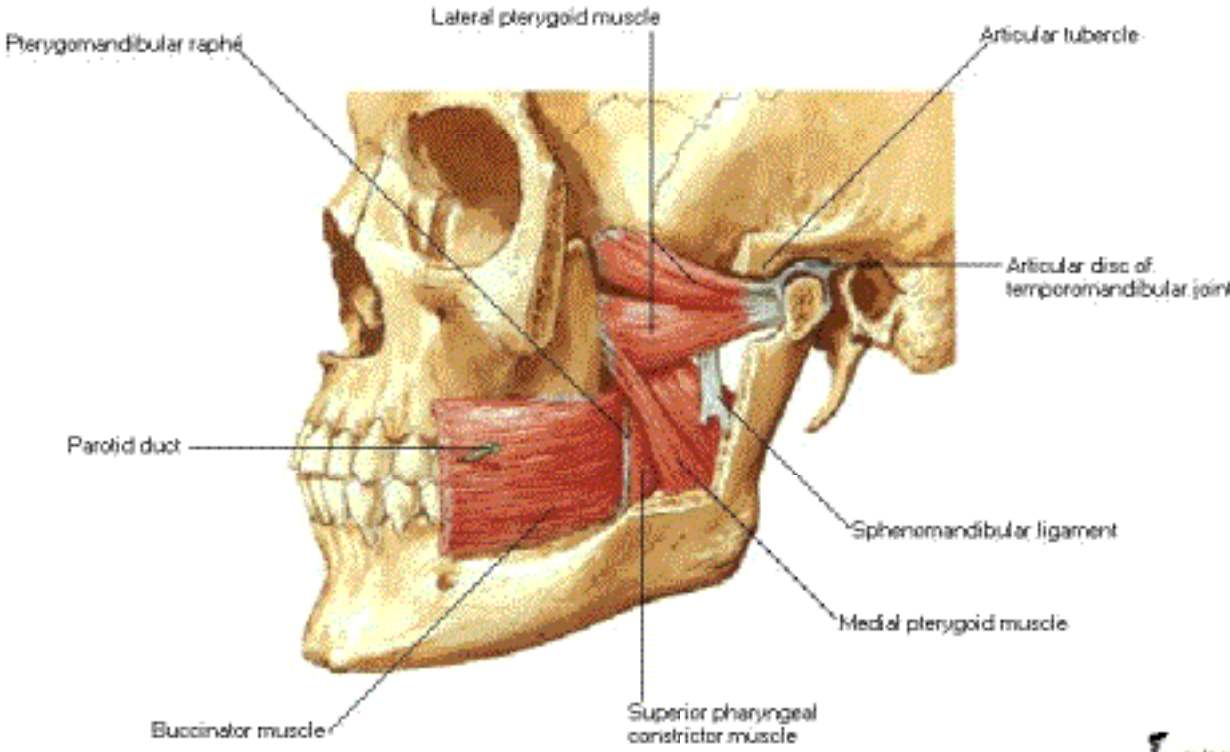
Lateral View



F. Netter M.D.
© Novartis

Muscles Involved in Mastication [Deep]

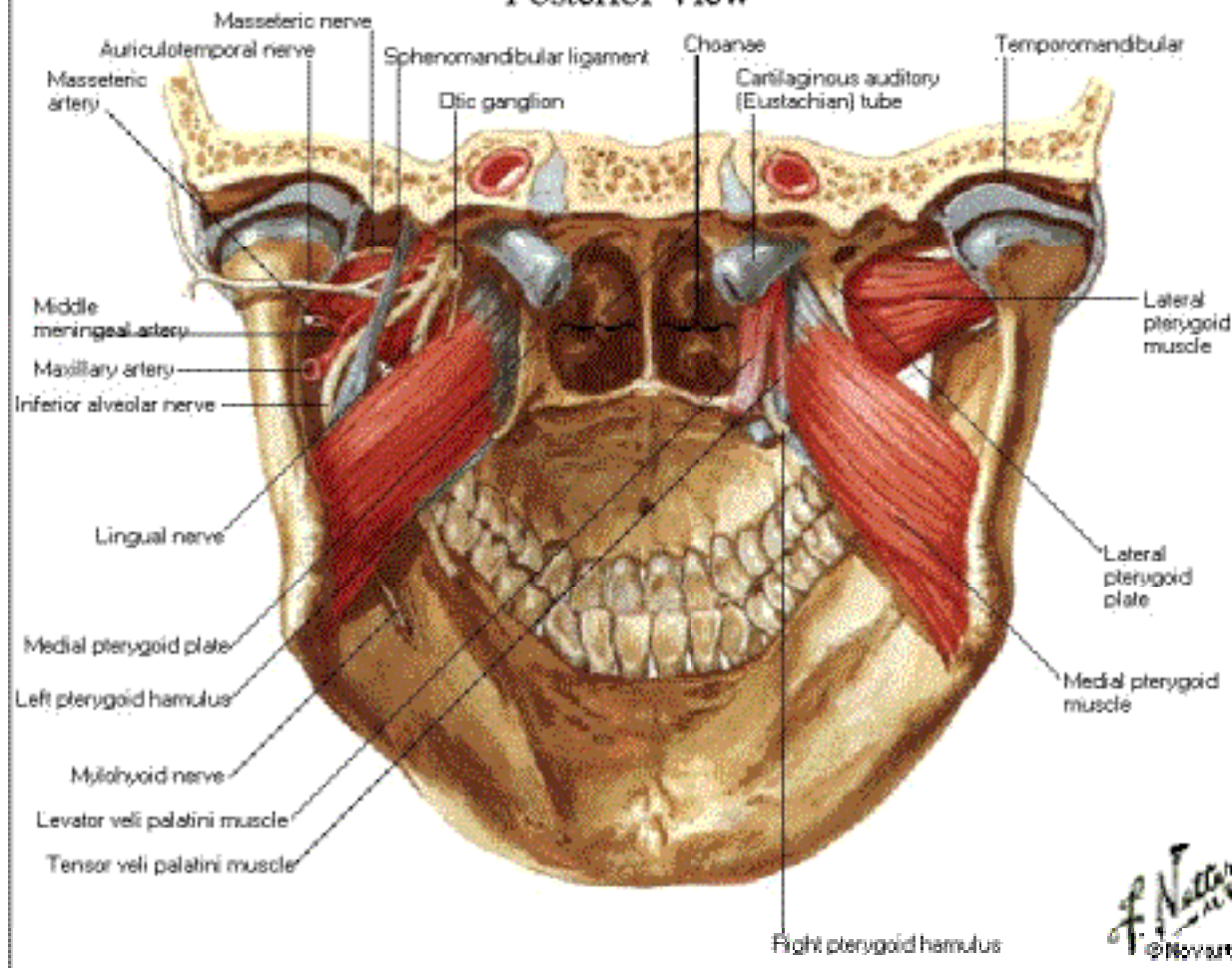
Lateral View



F. Netter M.D.
© 1989

Muscles Involved in Mastication [Deep]

Posterior View

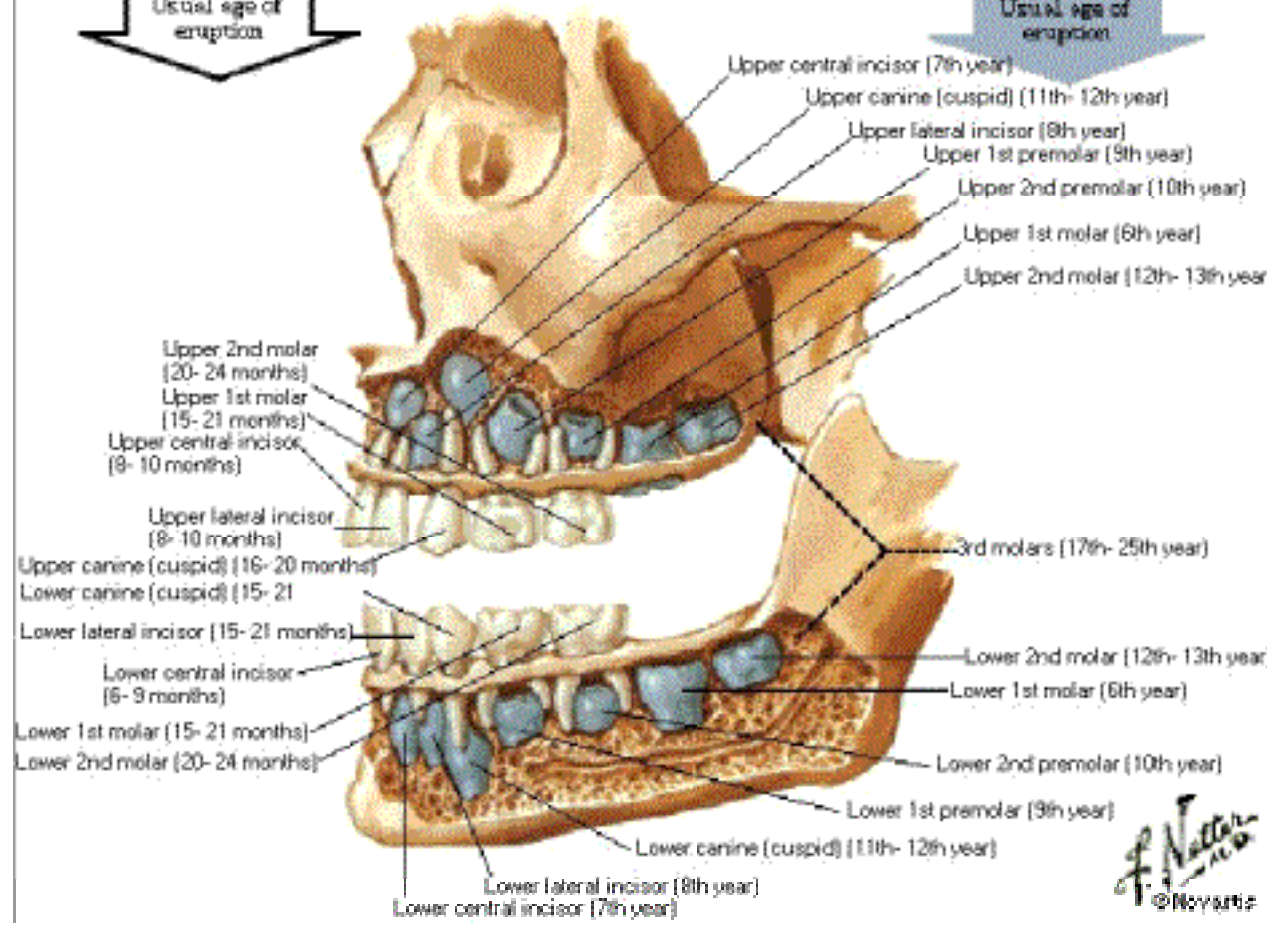


Teeth - Deciduous and Permanent

Age of Eruptions

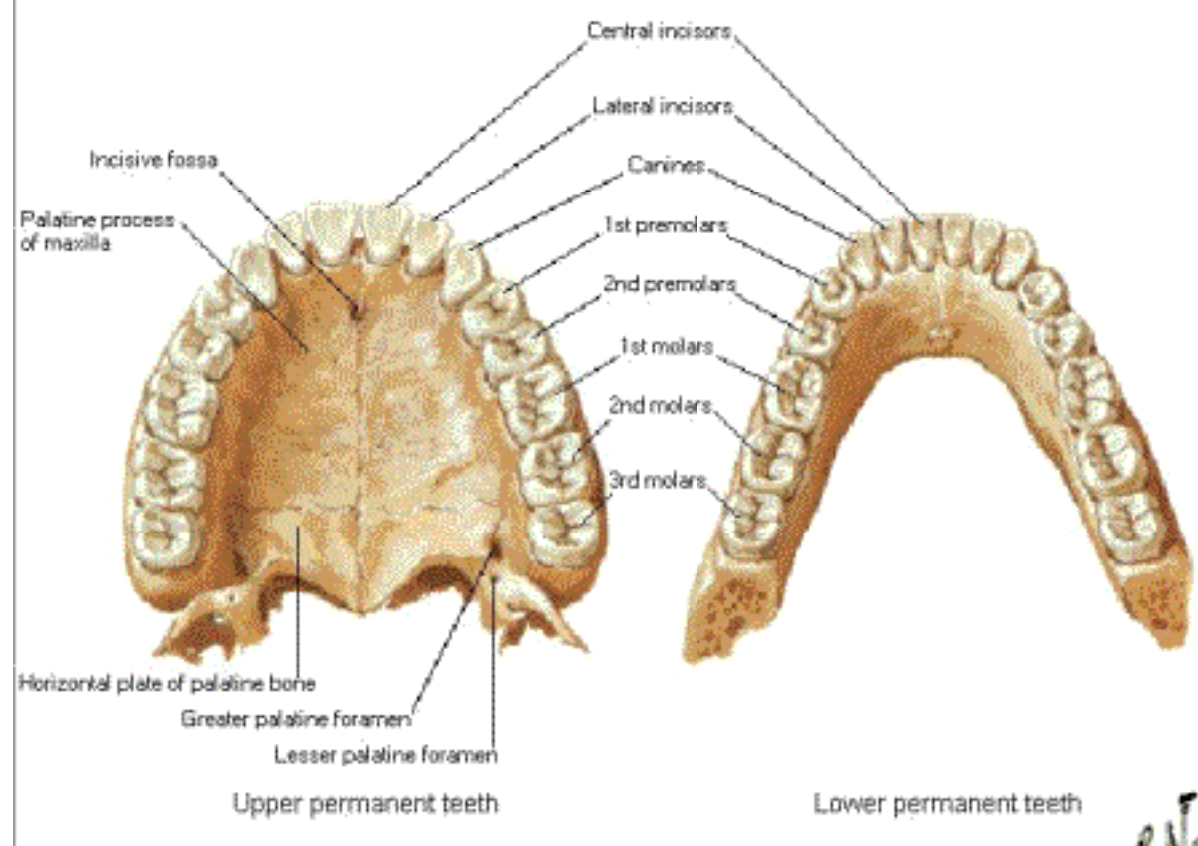
Deciduous
(primary)
Usual age of eruption

Permanent
(colored lines)
Usual age of eruption



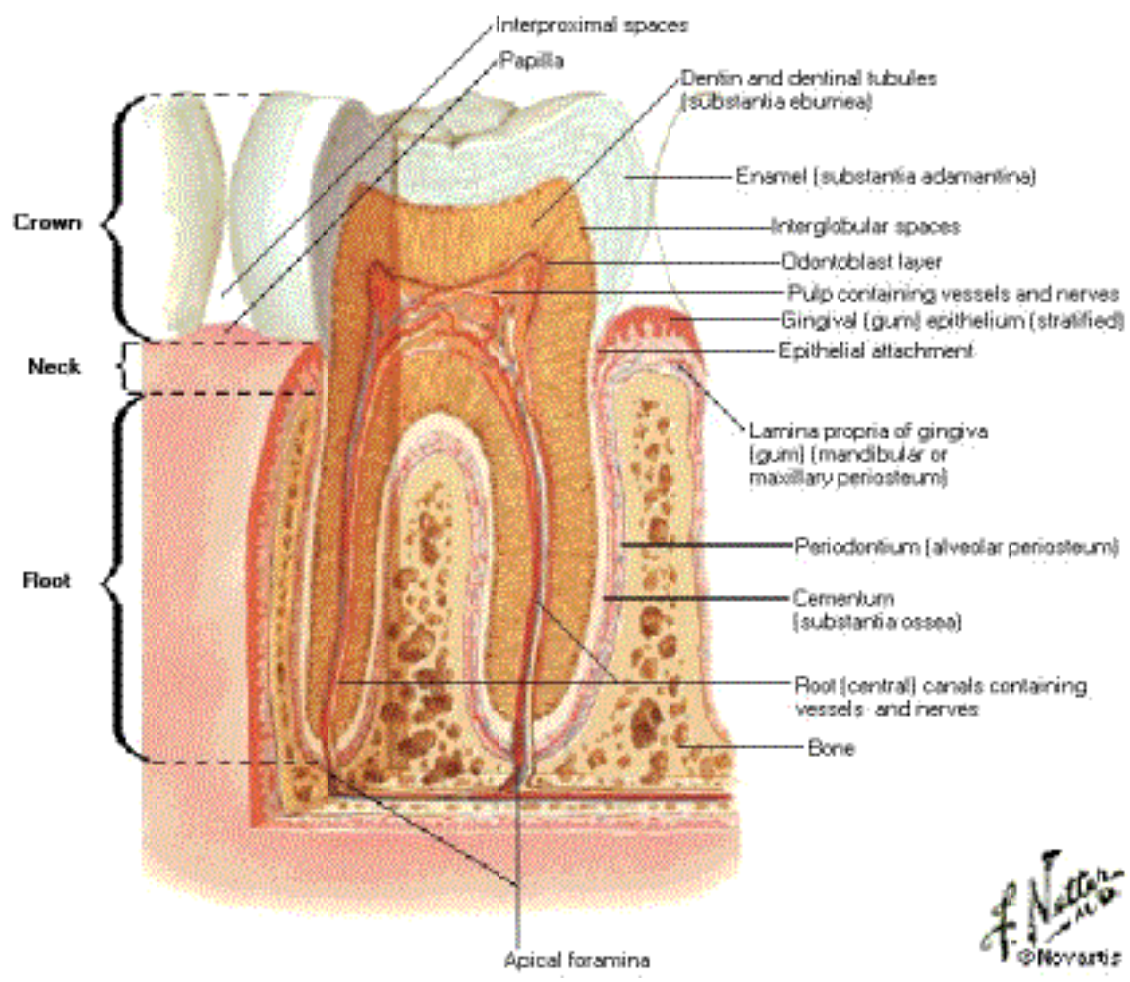
F. Nasser
© 2015

Teeth - Upper and Lower Permanent

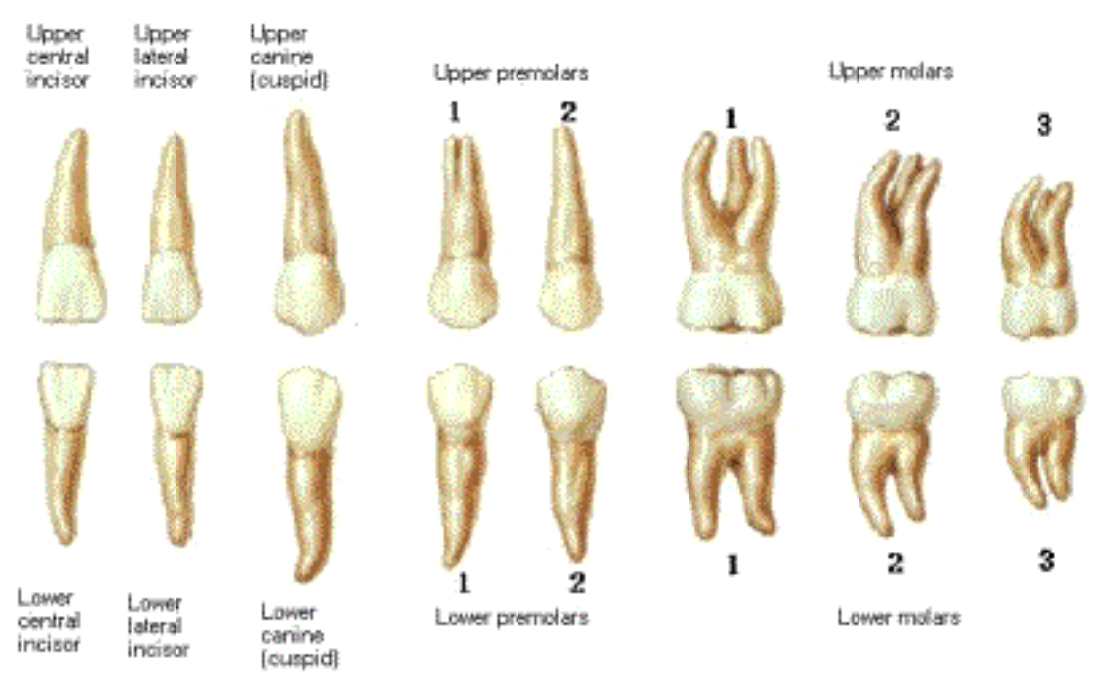


F. Netter
© Novartis

Anatomy of a Tooth



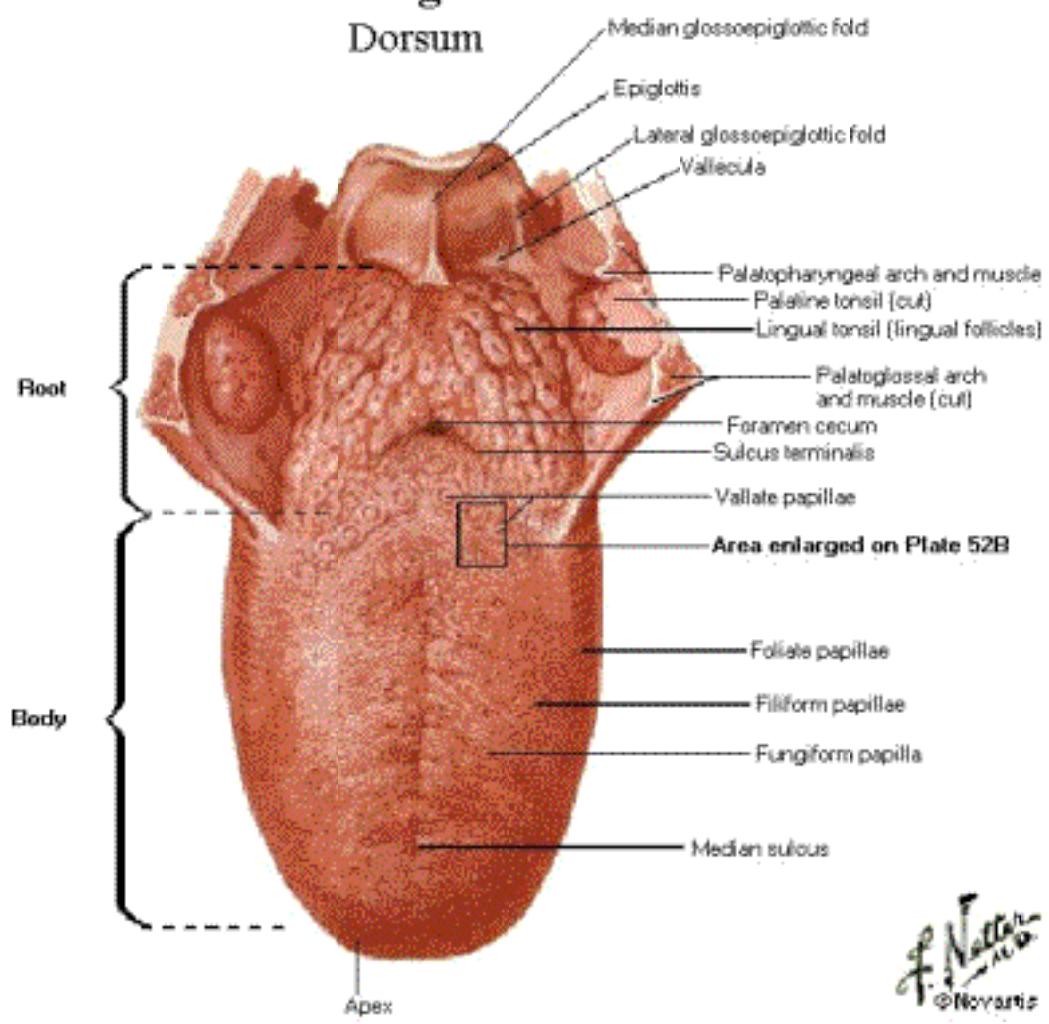
Teeth - Left Upper and Left Lower Permanent Labiobuccal View



F. Netter M.D.
© Elsevier

Tongue

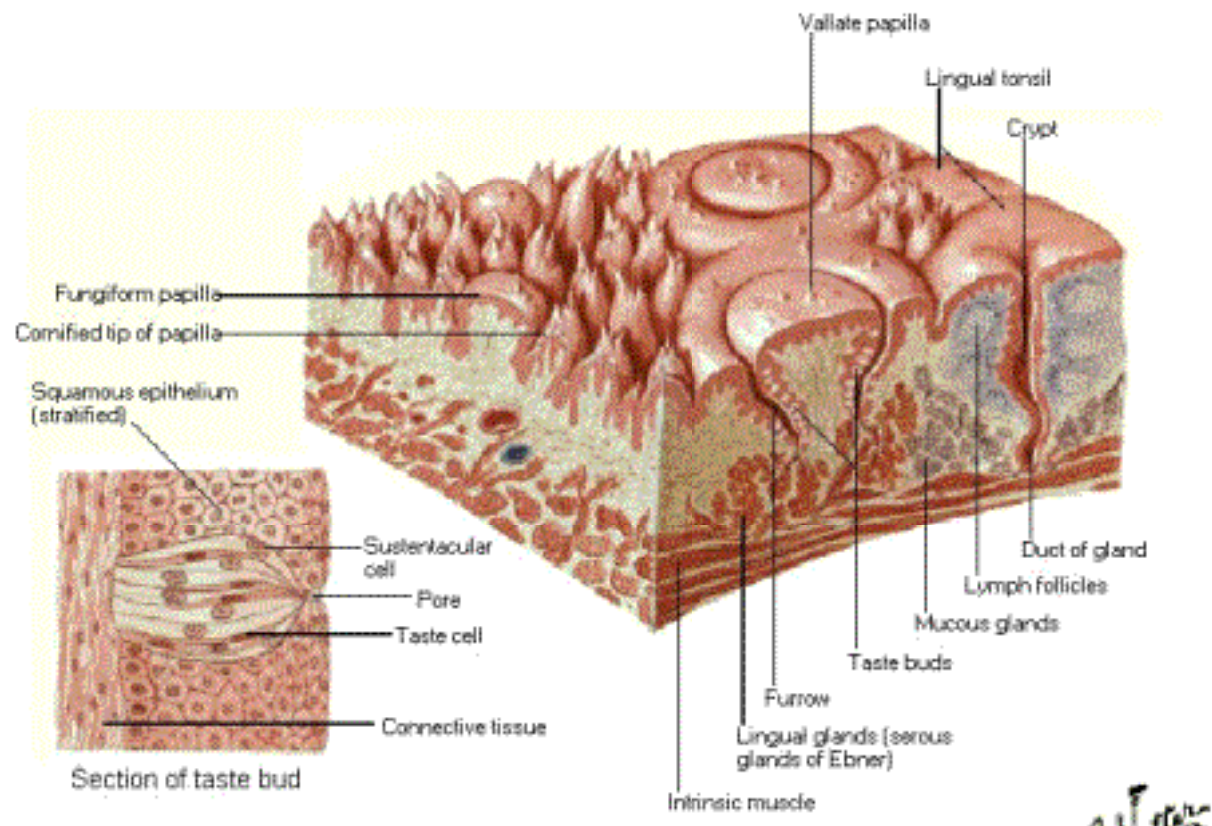
Dorsum



F. Netter
© Novartis

Tongue - Schematic Stereogram

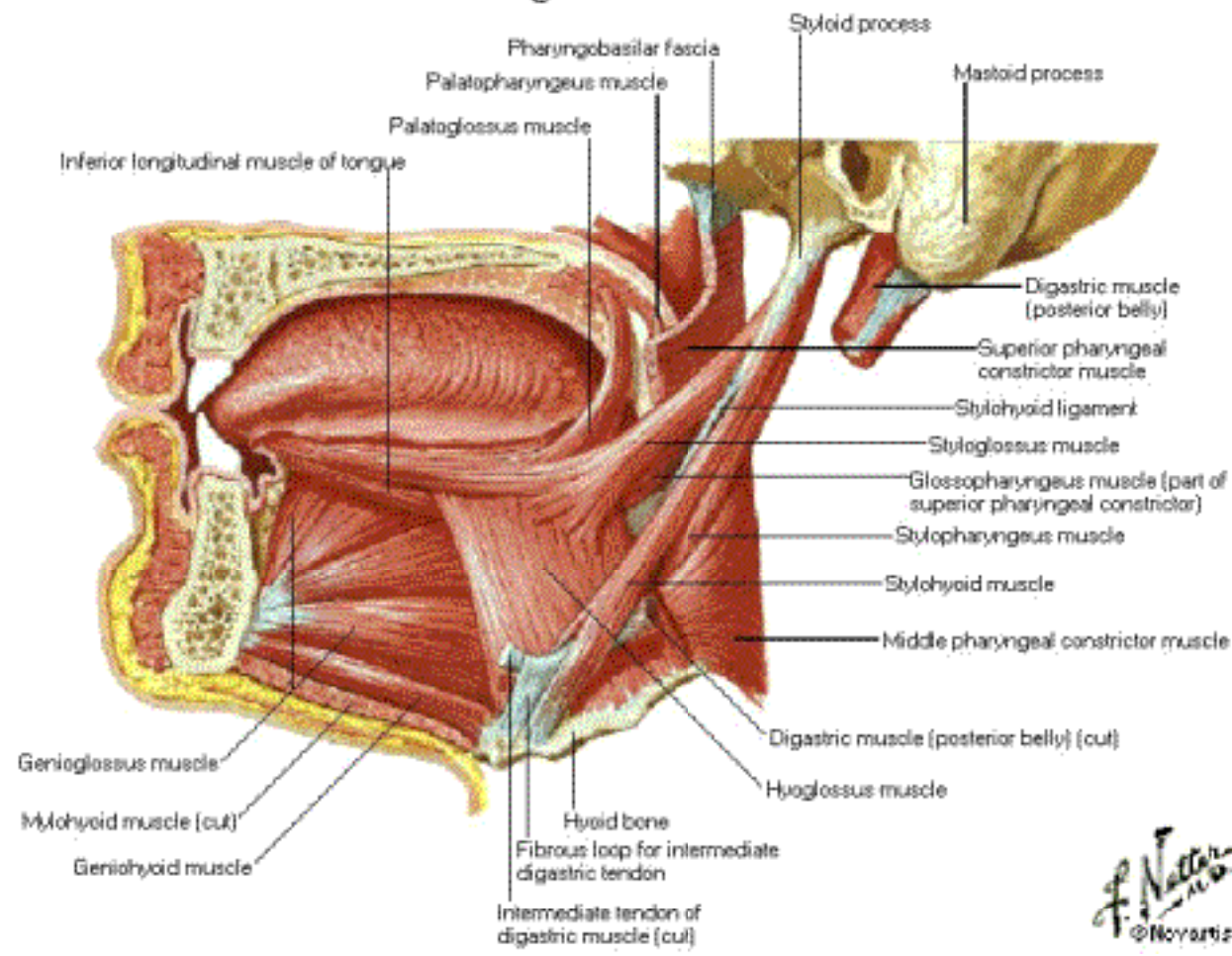
Area Indicated on Plate 52A



F. Netter
© Novartis

Muscles of Tongue

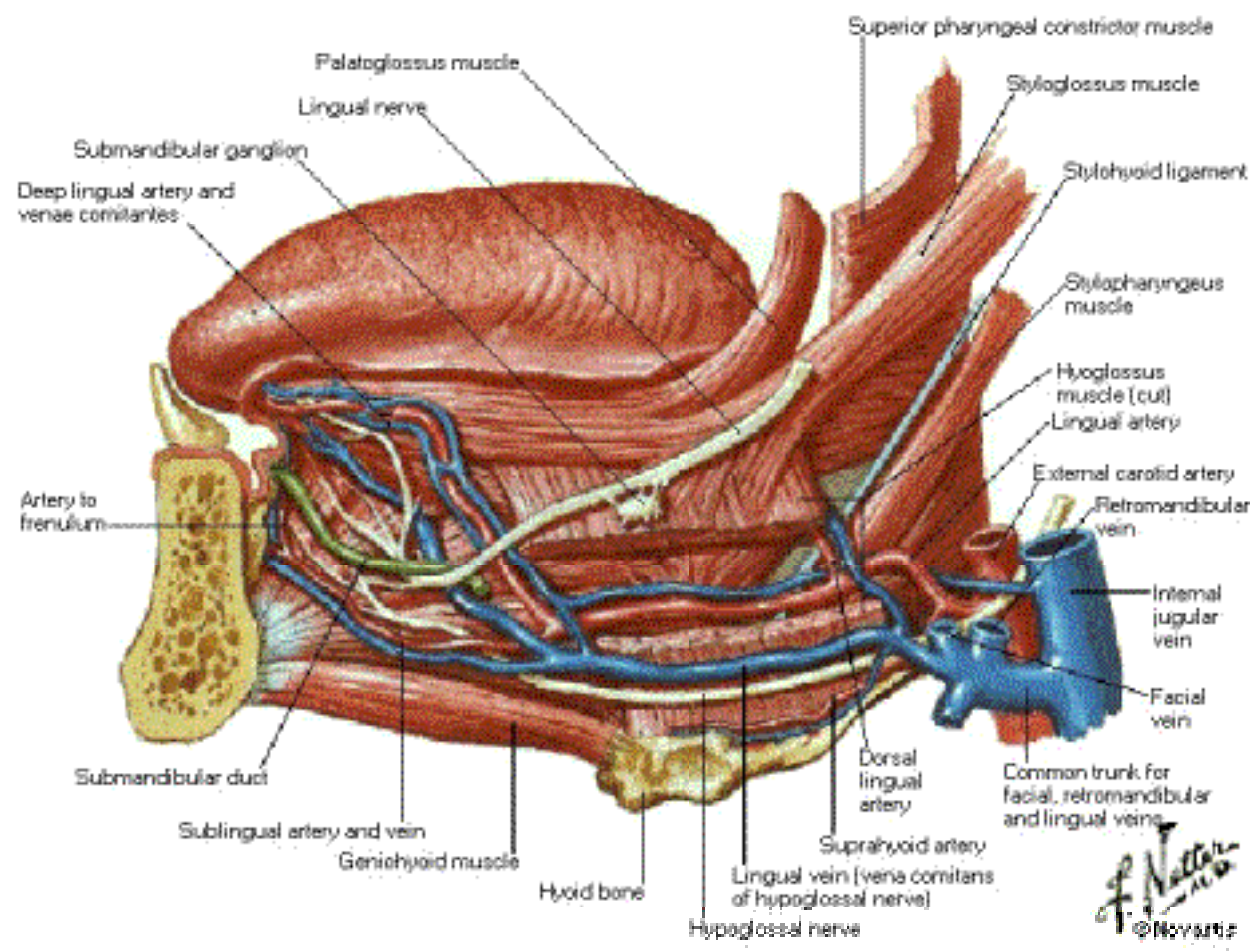
Sagittal Section



F. Netter M.D.
© Novartis

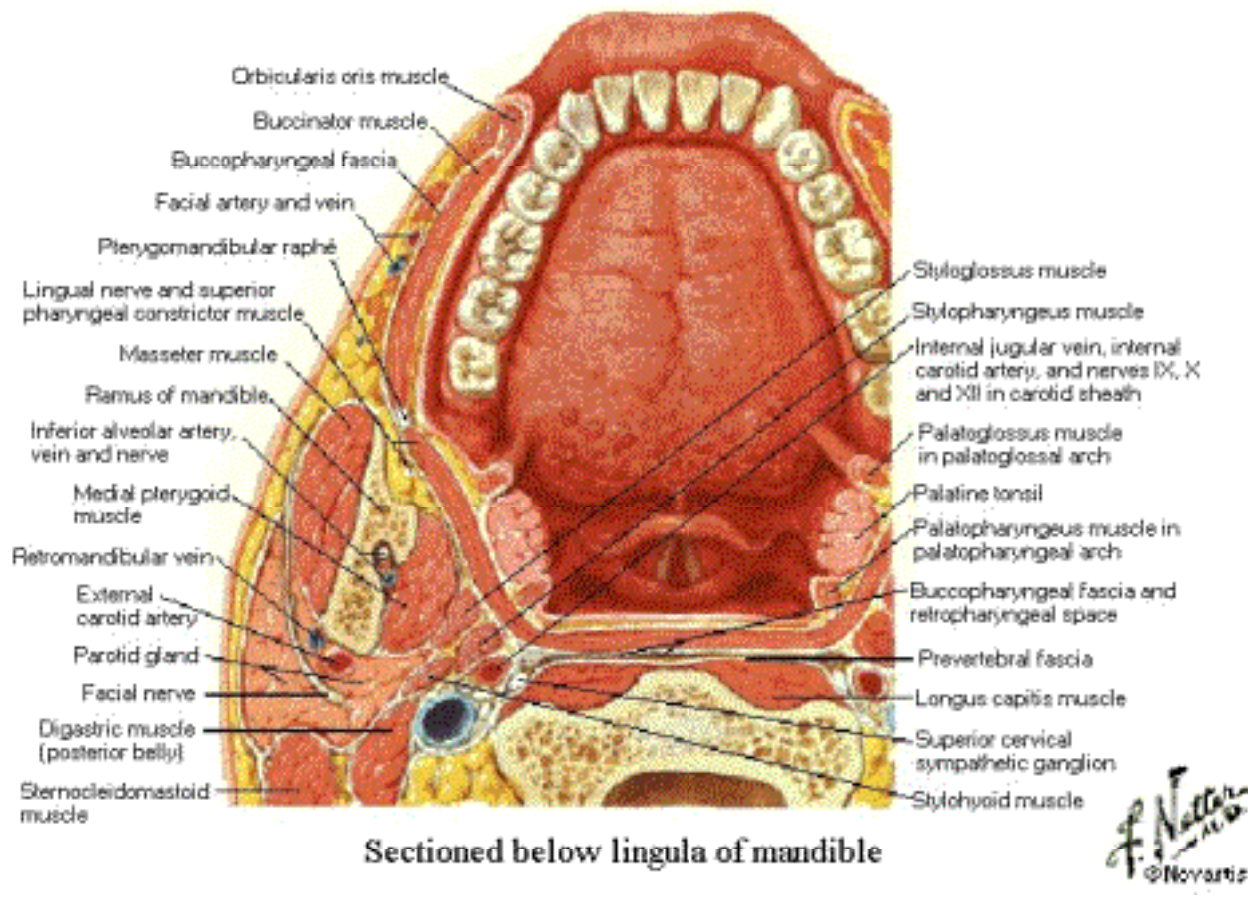
Tongue and Related Structures

Sagittal Section



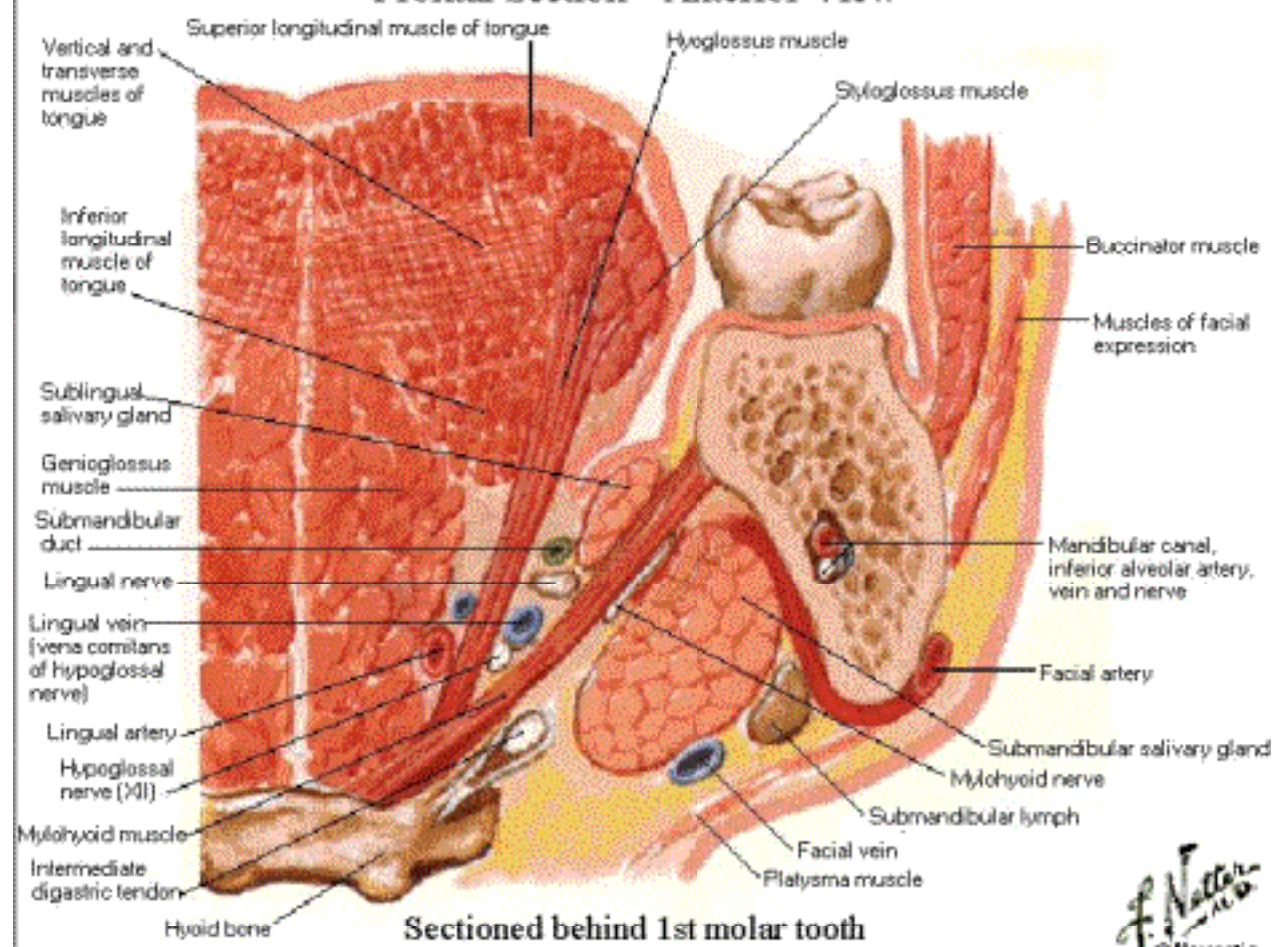
Tongue and Mouth

Horizontal Section - Superior View



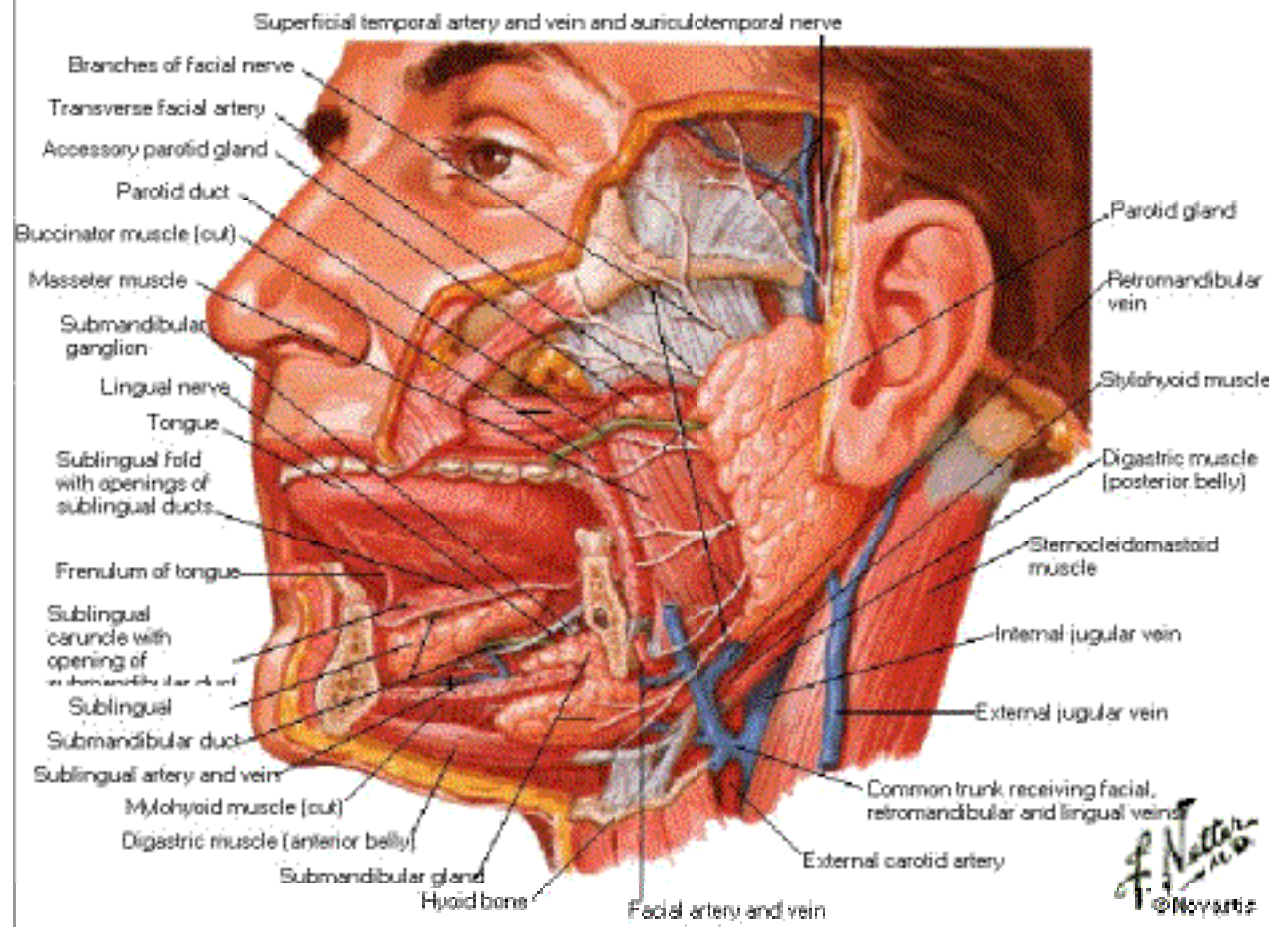
Tongue and Mouth

Frontal Section - Anterior View



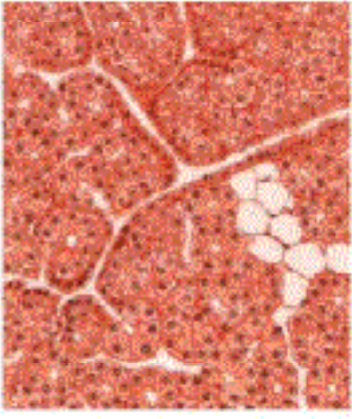
F. Netter M.D.
© Novartis

Salivary Glands Dissection

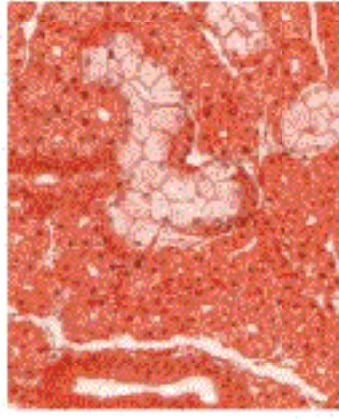


Salivary Glands


Histology



Parotid gland: totally serous



Submandibular gland: mostly serous, partially mucous







Sublingual gland: almost completely mucous

F. Netter
© 2014

Afferent Innervation of Mouth and Pharynx

Anterior View

- Trigeminal nerve (V)** 
- Glossopharyngeal nerve (IX)** 
- Vagus nerve (X)** 
- Facial nerve (VII)** 

Trigeminal (V) (maxillary)

Via superior alveolar nerves

Via pterygopalatine ganglion and greater and lesser palatine nerves

Facial (VII) (nervus intermedius)

Via greater petrosal nerve, pterygopalatine ganglion and greater and lesser palatine nerves

Glossopharyngeal (IX)

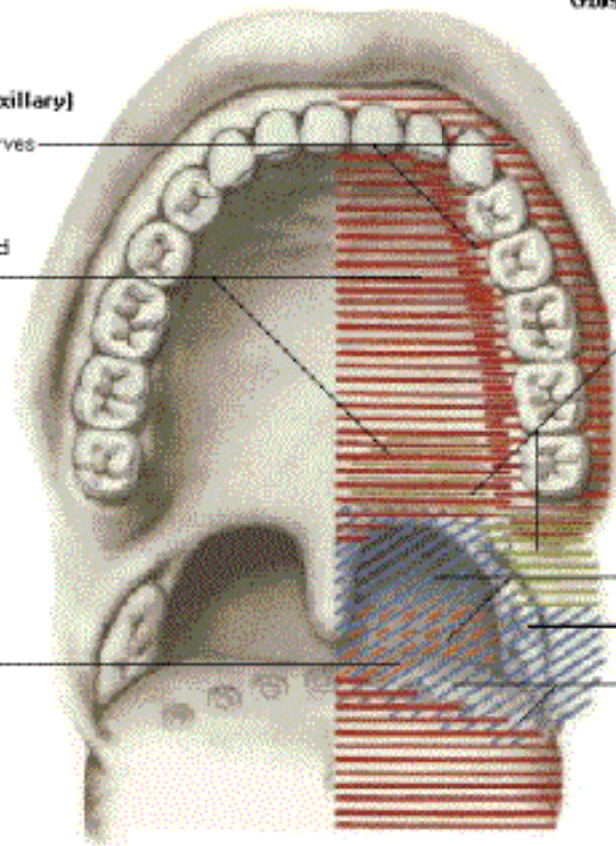
Via pharyngeal plexus

Via tonsillar branches

Taste plus general sensation via lingual branches

Vagus (X)





Via internal branch of superior laryngeal nerve

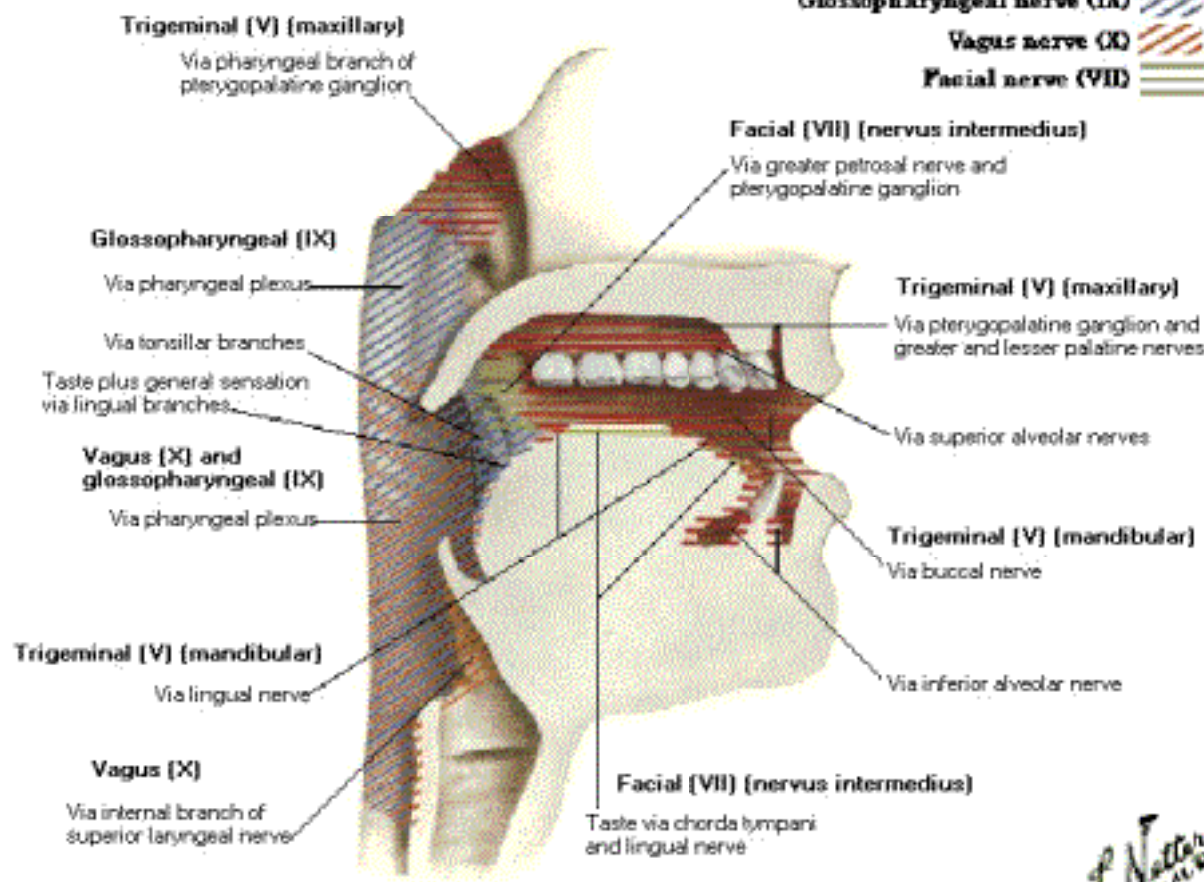


F. Netter M.D.
© 2004 Elsevier

Afferent Innervation of Mouth and Pharynx

Lateral View

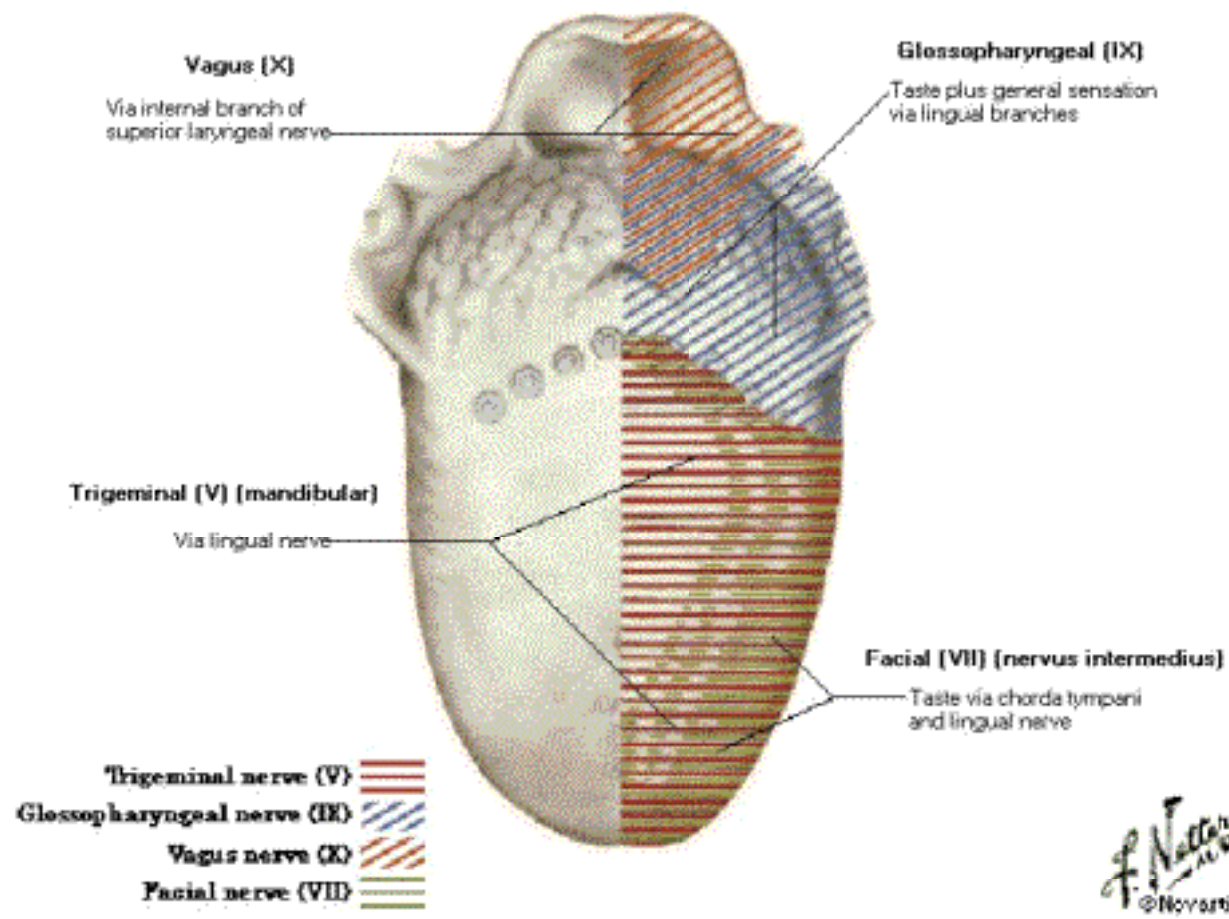
- Trigeminal nerve (V)** 
- Glossopharyngeal nerve (IX)** 
- Vagus nerve (X)** 
- Facial nerve (VII)** 



F. Netter M.D.
© 2005

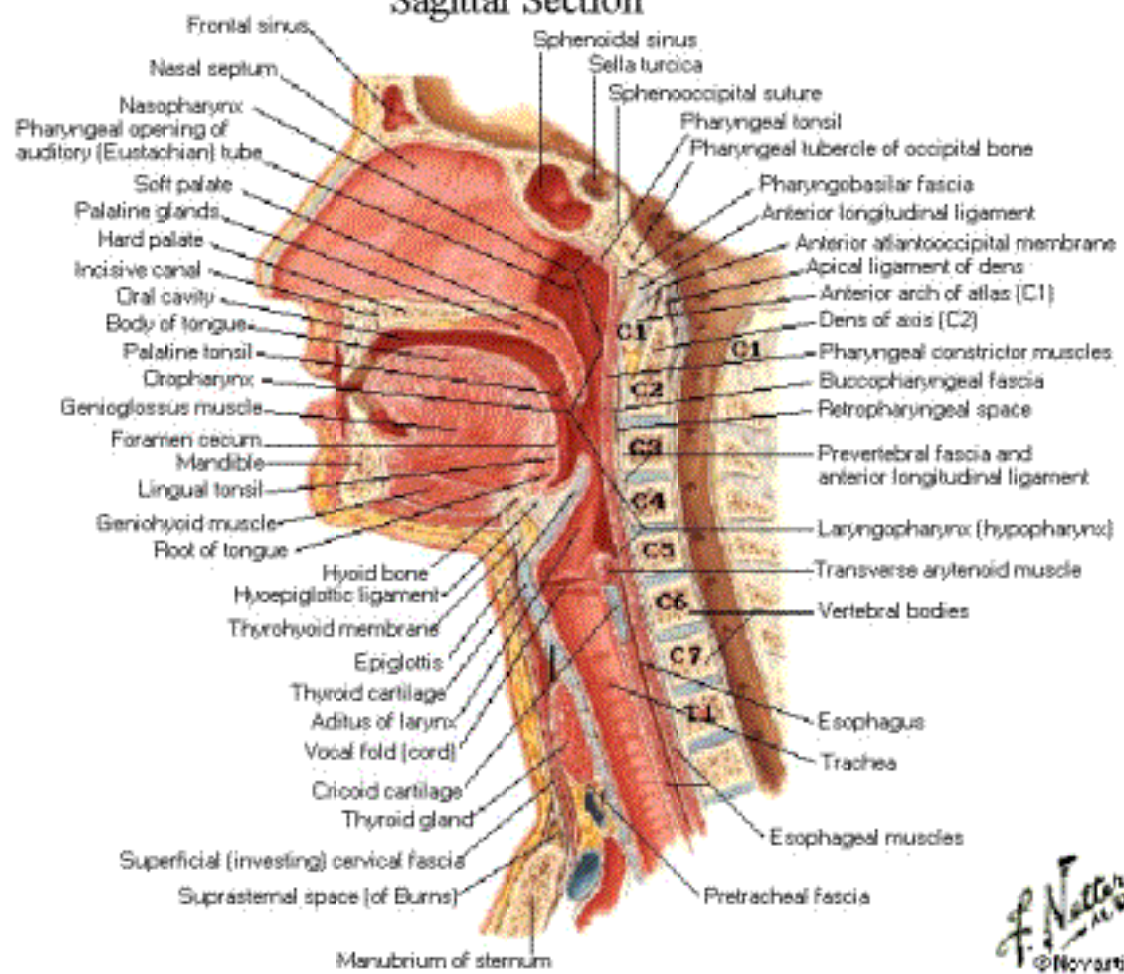
Afferent Innervation of Mouth and Pharynx

Dorsum of Tongue



Pharynx

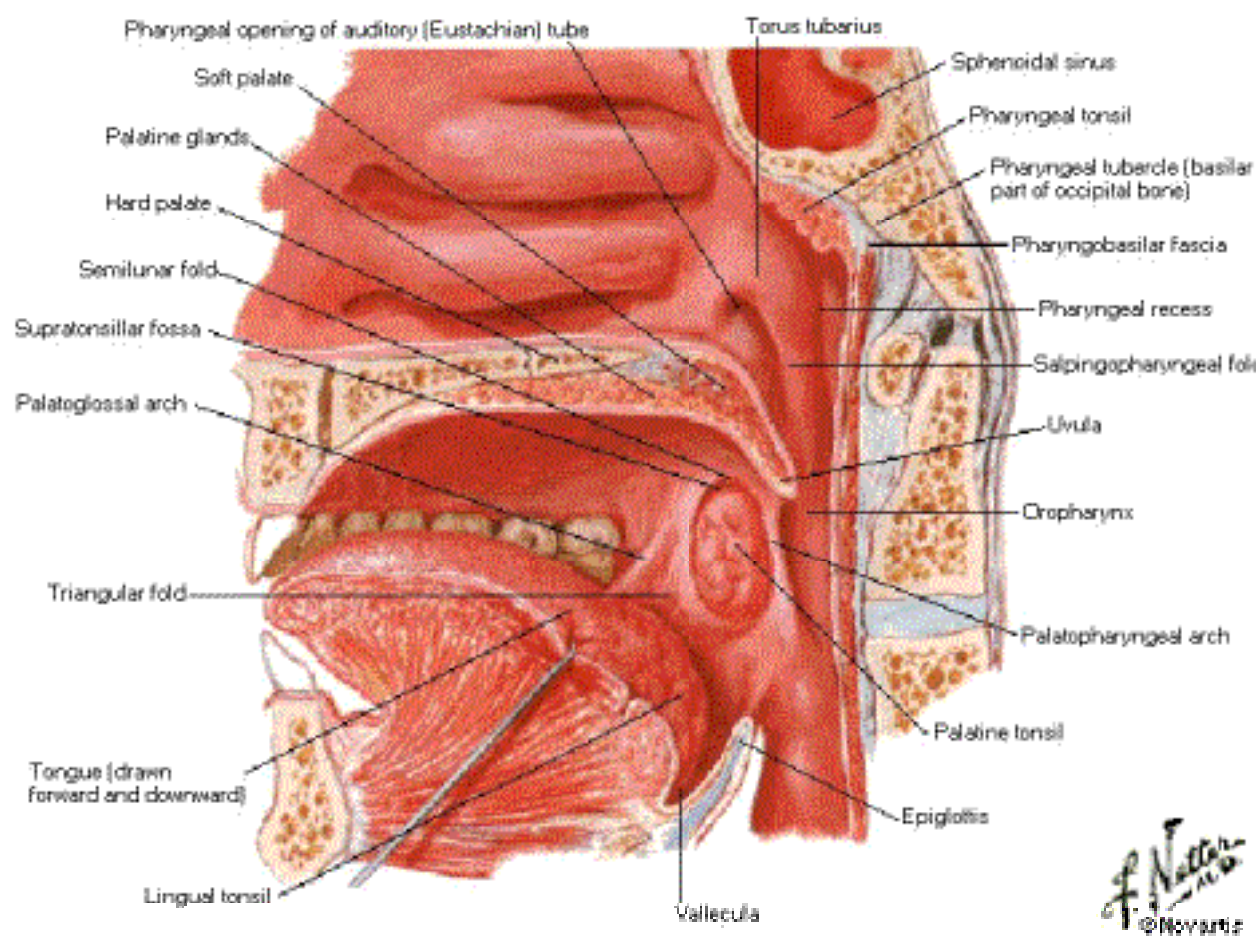
Sagittal Section



F. Netter M.D.
© Novartis

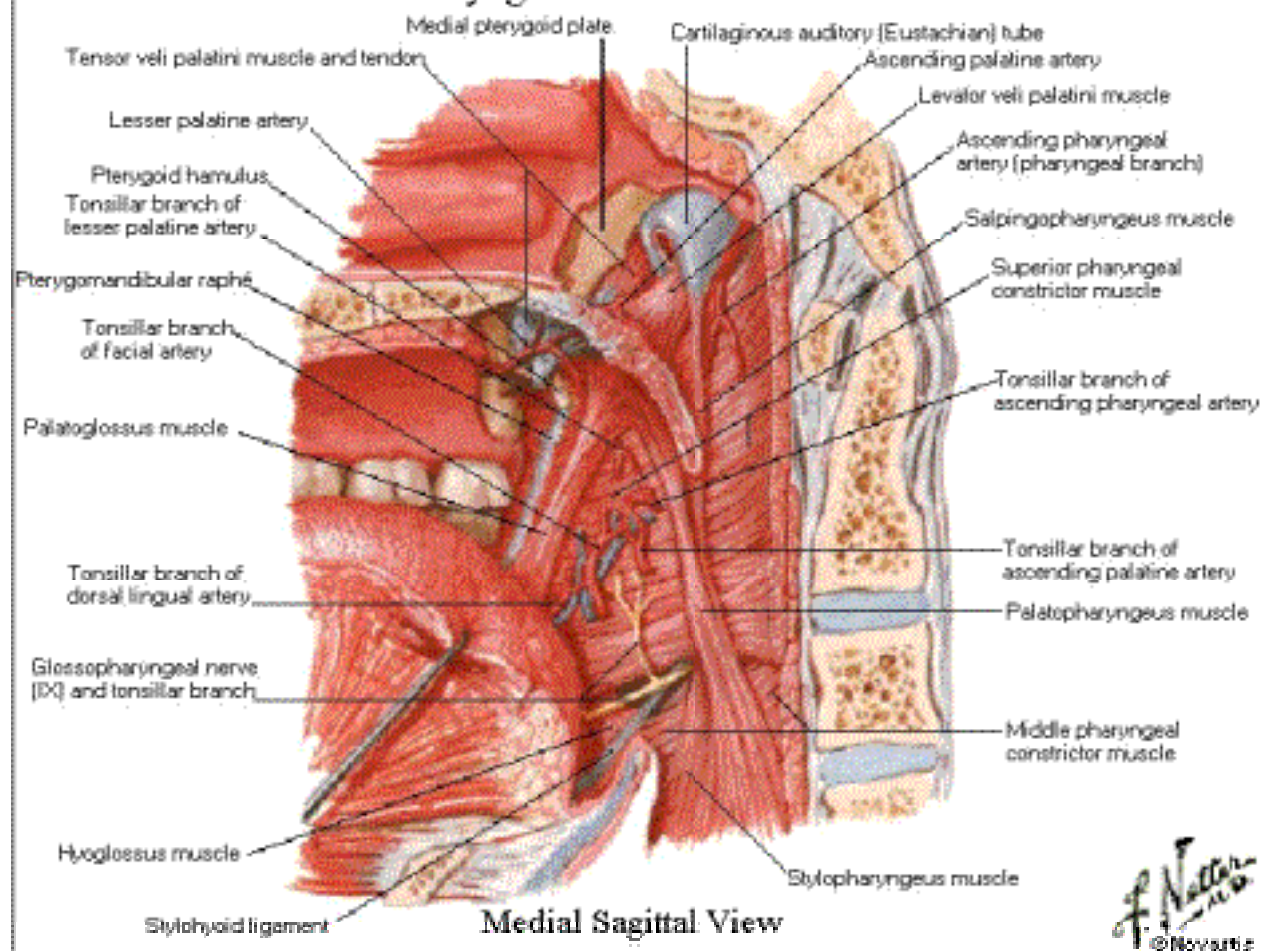
Fauces

Medial Sagittal View



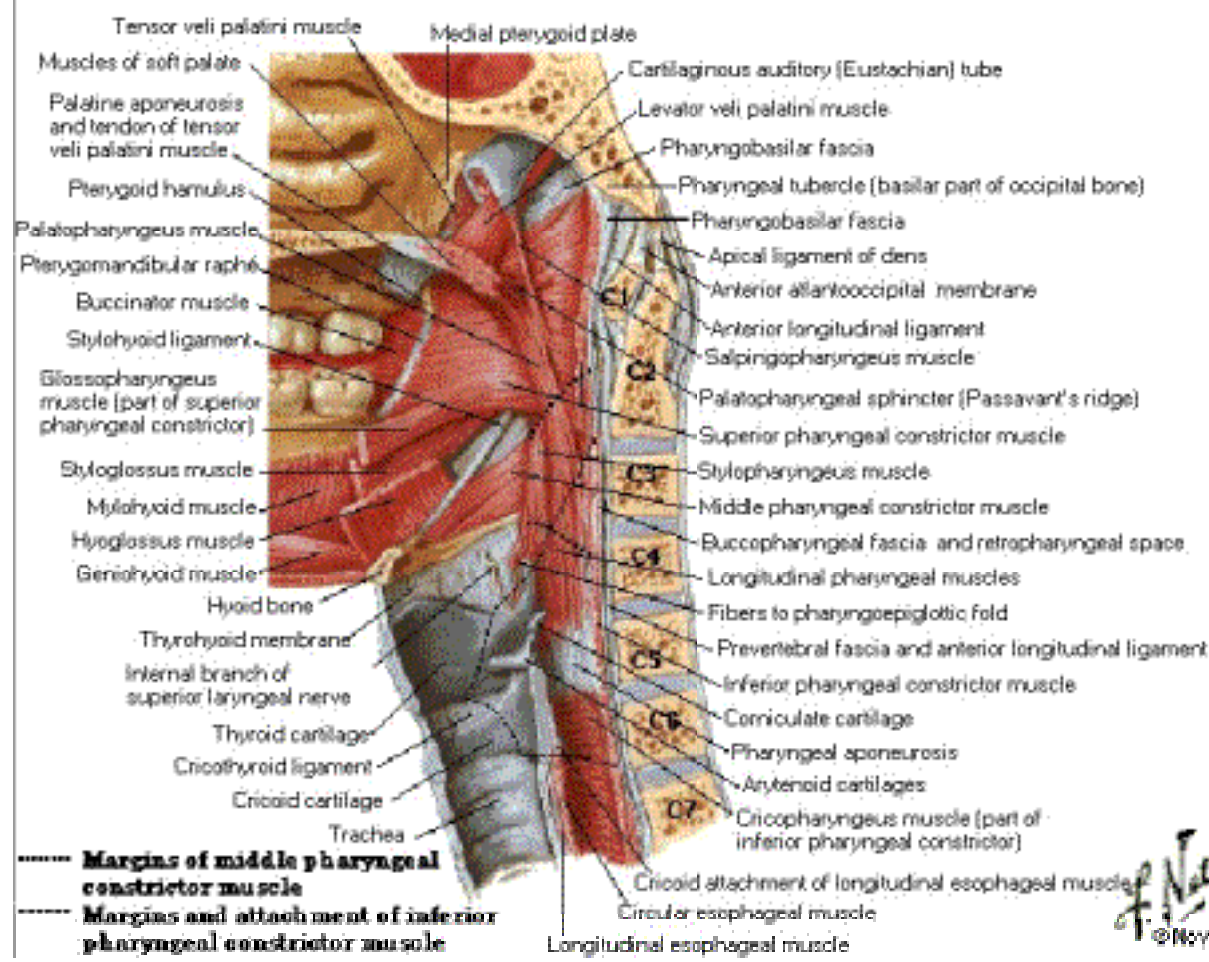
Fauces

Pharyngeal Mucosa Removed



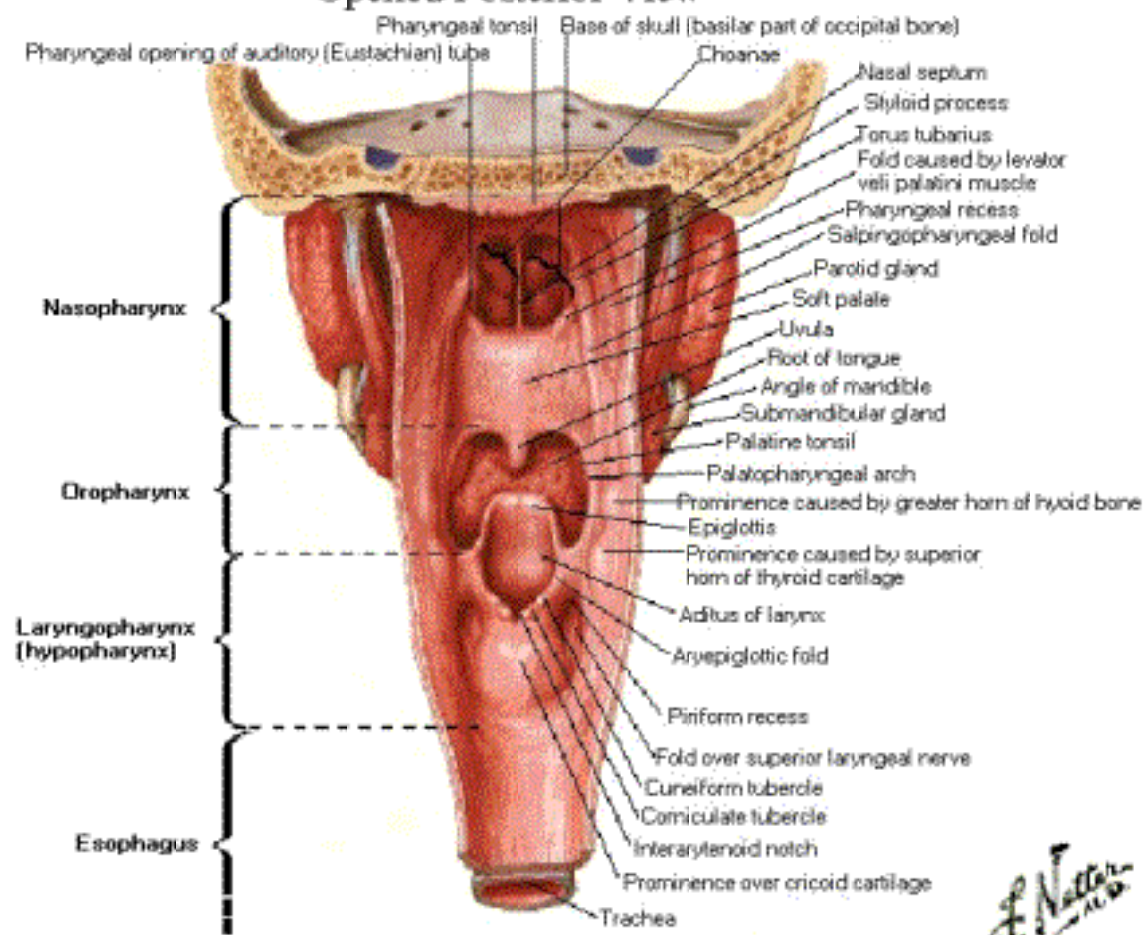
F. Netter M.D.
© 2005

Muscles of Pharynx Sagittal Section



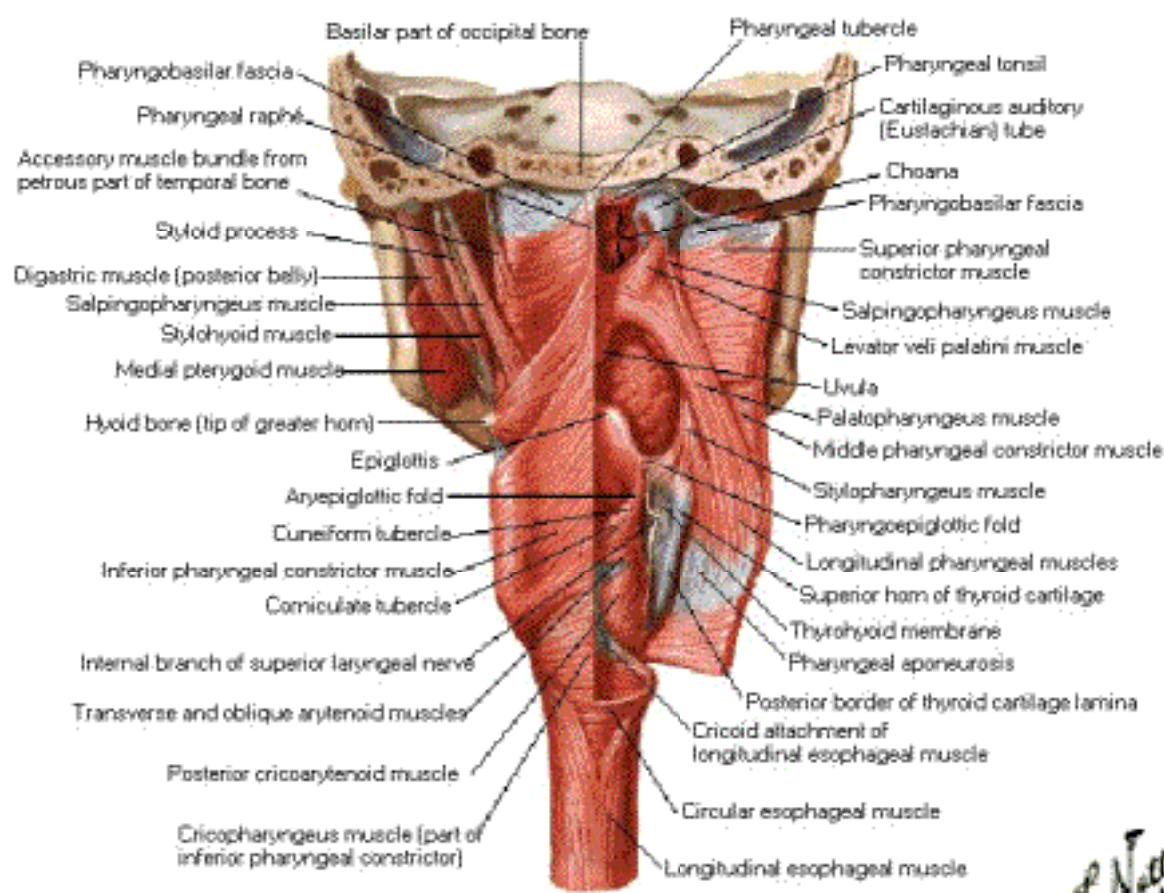
Pharynx

Opened Posterior View



F. Netter M.D.
© Novartis

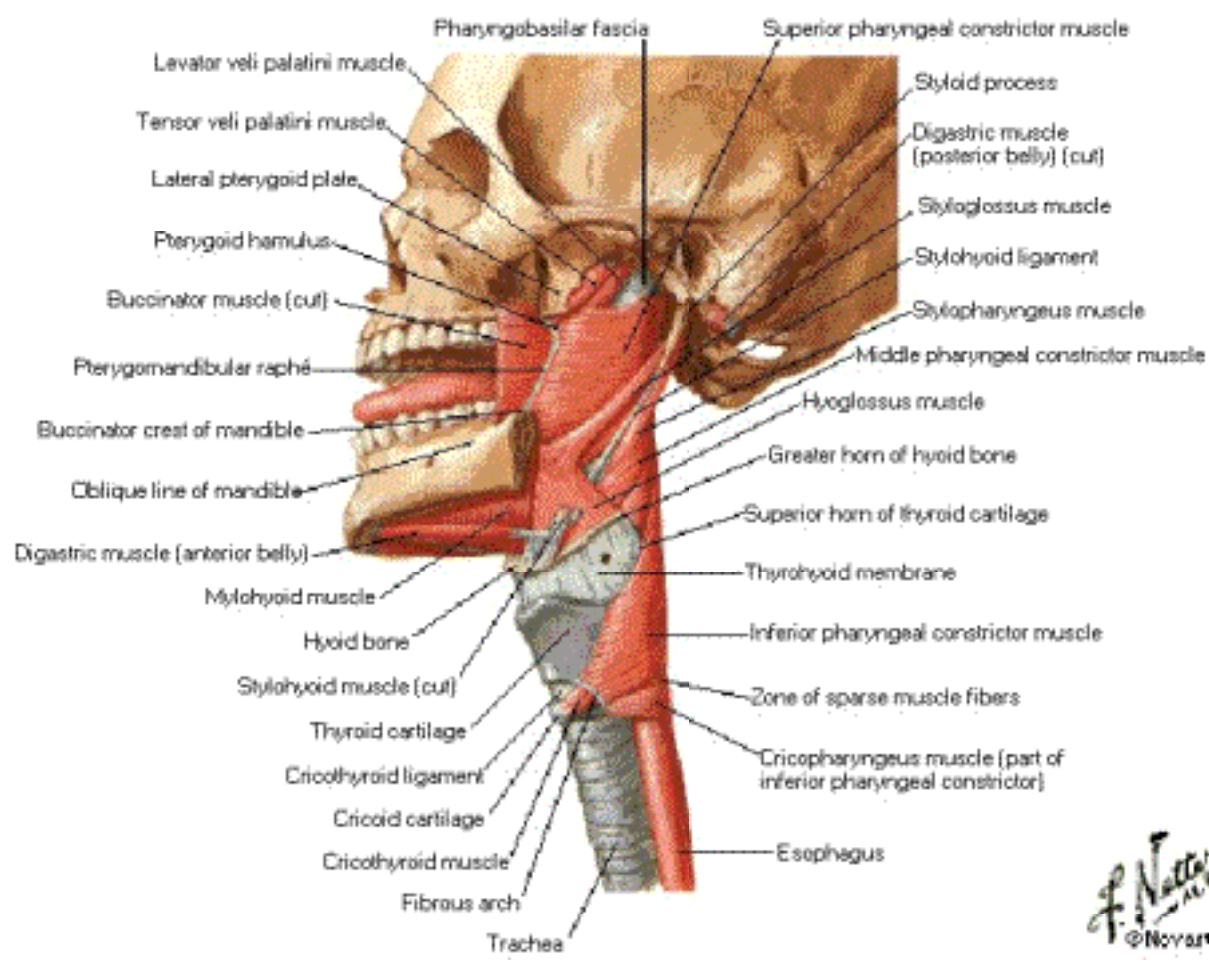
Muscles of Pharynx Partially Opened Posterior View



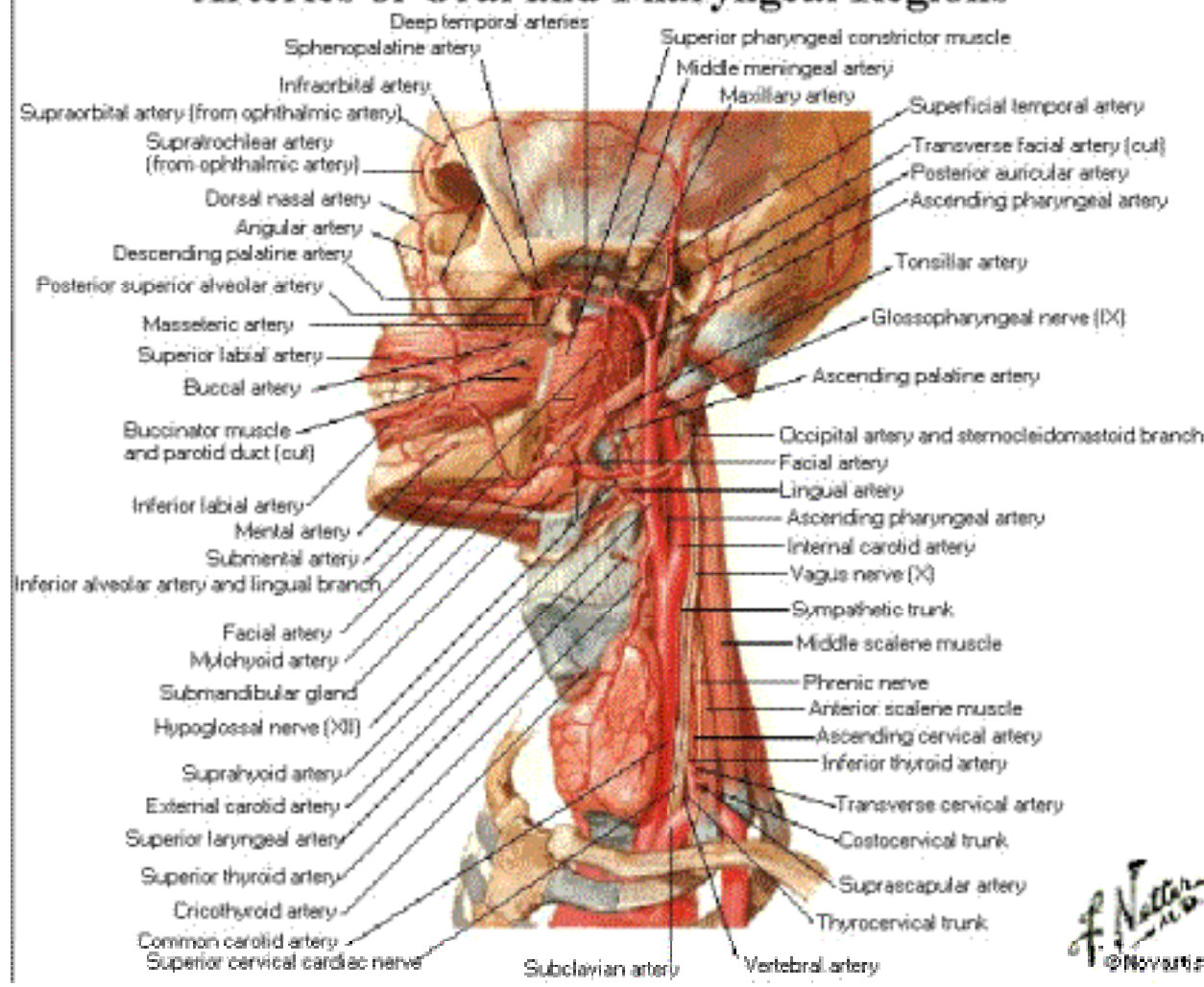
F. Netter M.D.
© 1996

Muscles of Pharynx

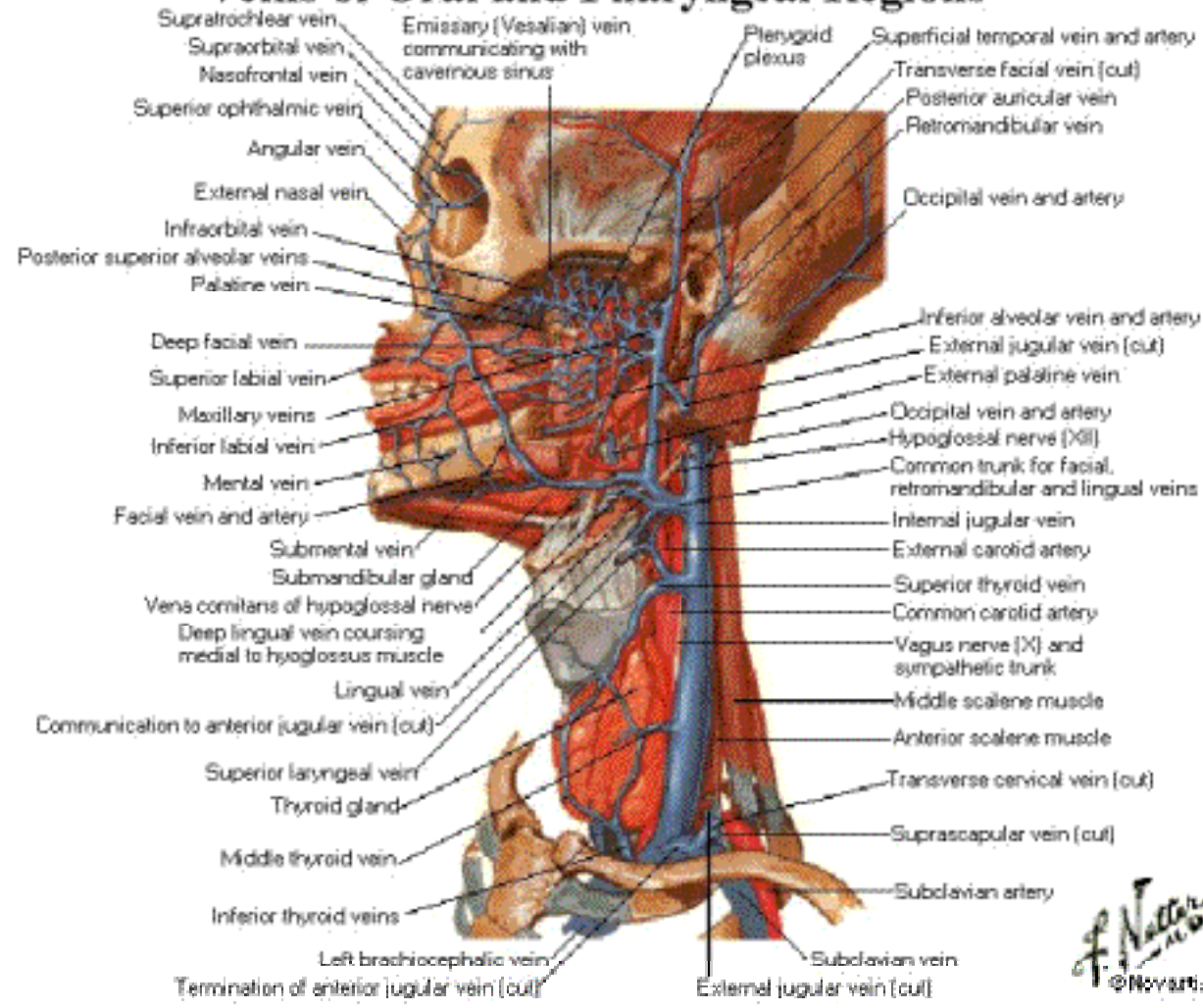
Lateral View



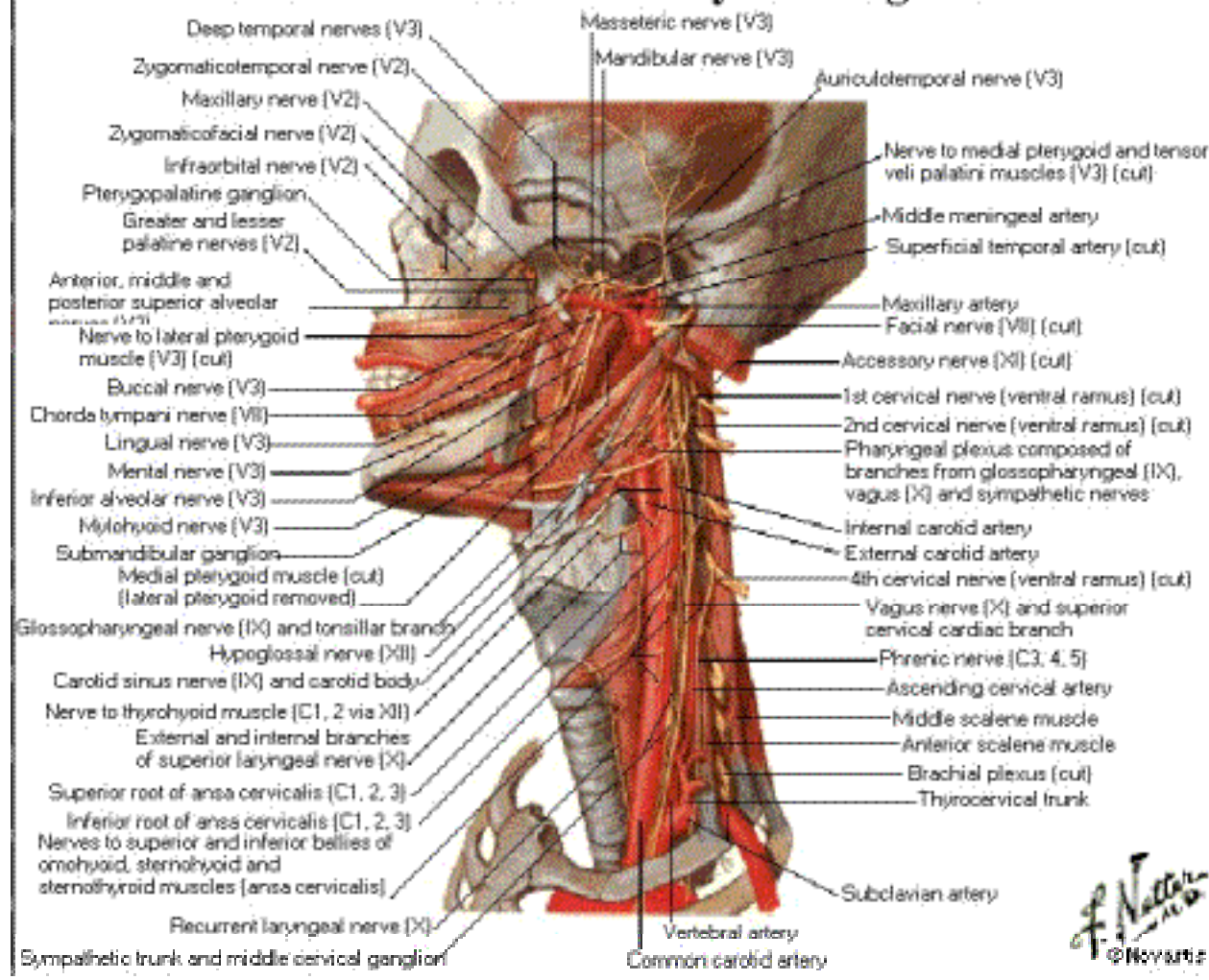
Arteries of Oral and Pharyngeal Regions



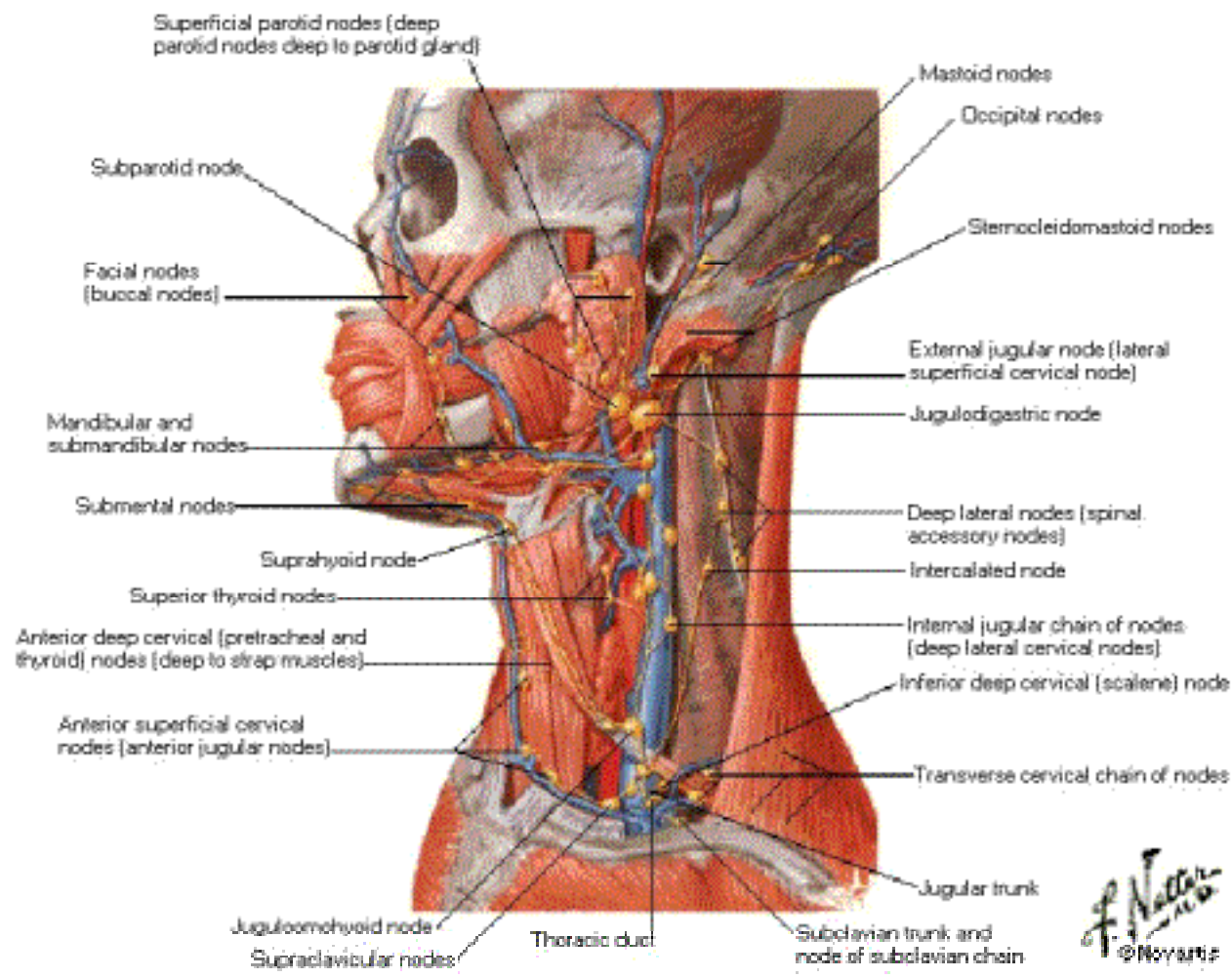
Veins of Oral and Pharyngeal Regions



Nerves of Oral and Pharyngeal Regions

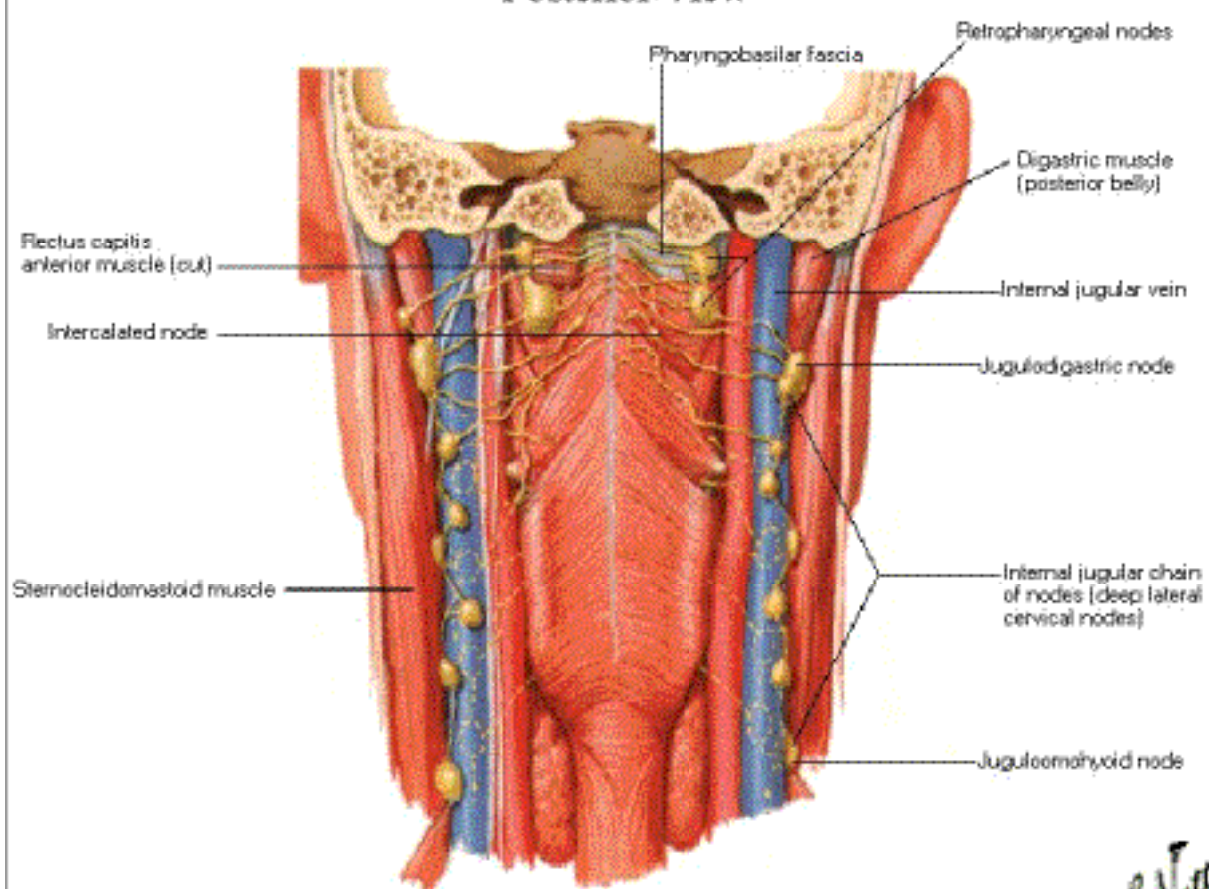


Lymph Vessels and Nodes of Oral and Pharyngeal



Lymphatic Drainage of Pharynx

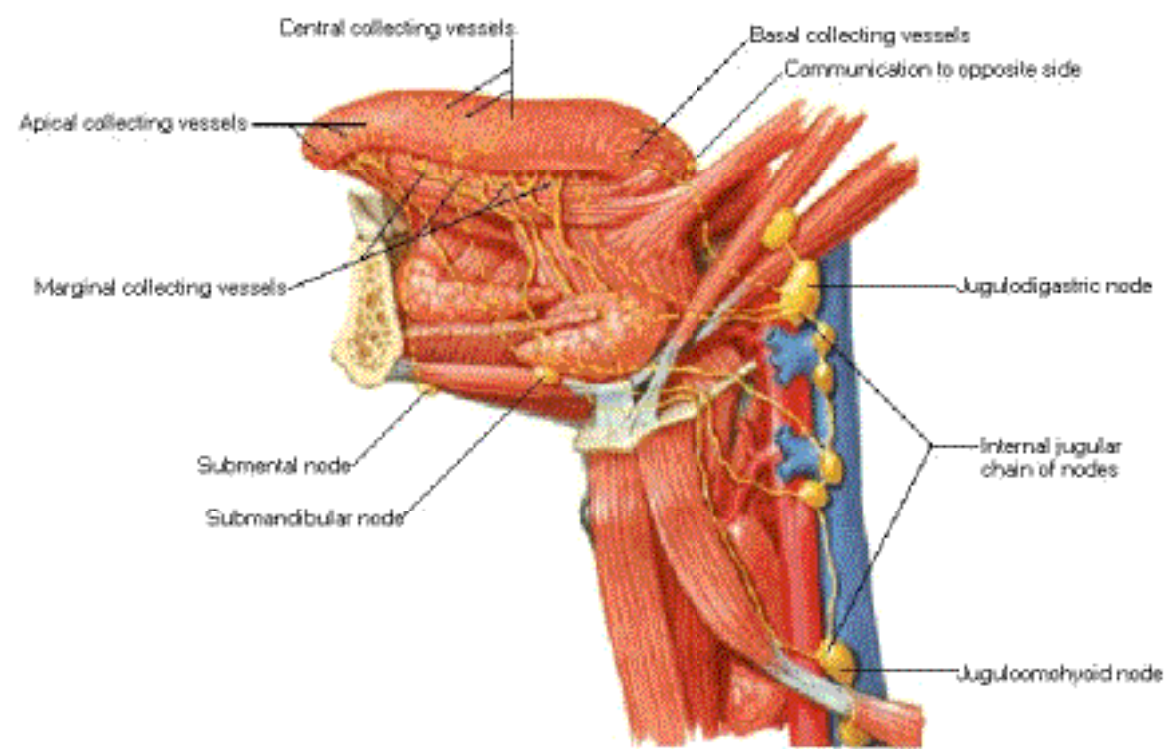
Posterior View



F. Netter M.D.
© 1995

Lymphatic Drainage of Tongue

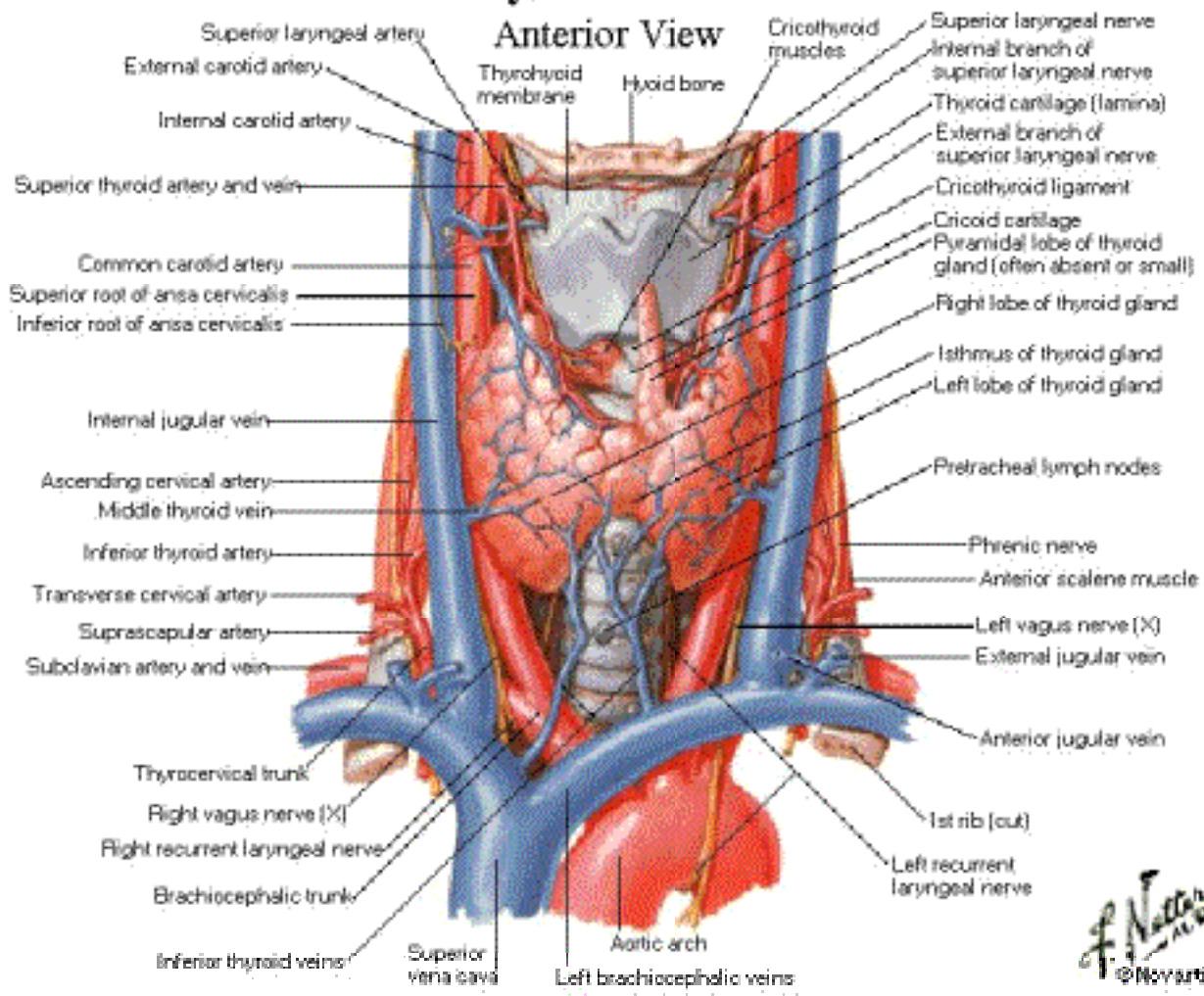
Lateral View



F. Netter M.D.
© 1996

Thyroid Gland

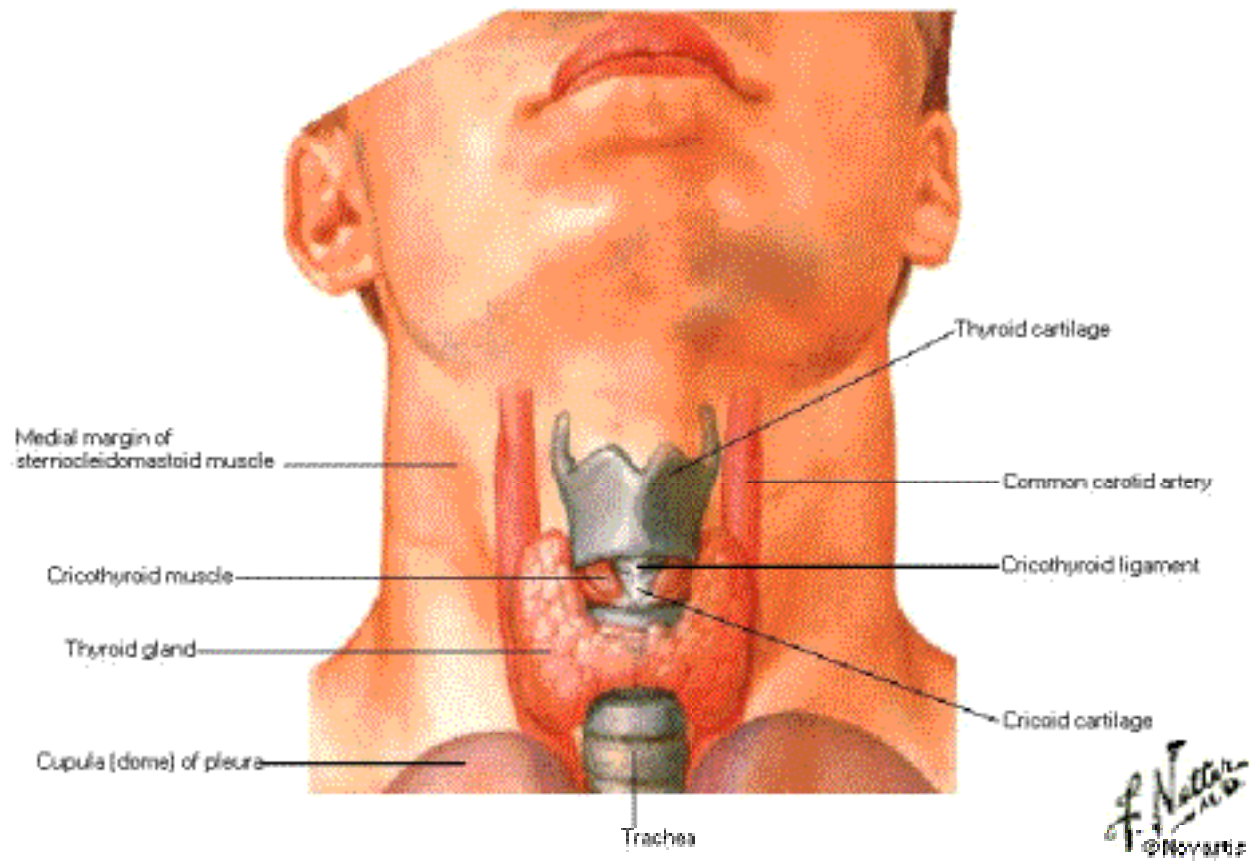
Anterior View



F. Netter M.D.
© 1996

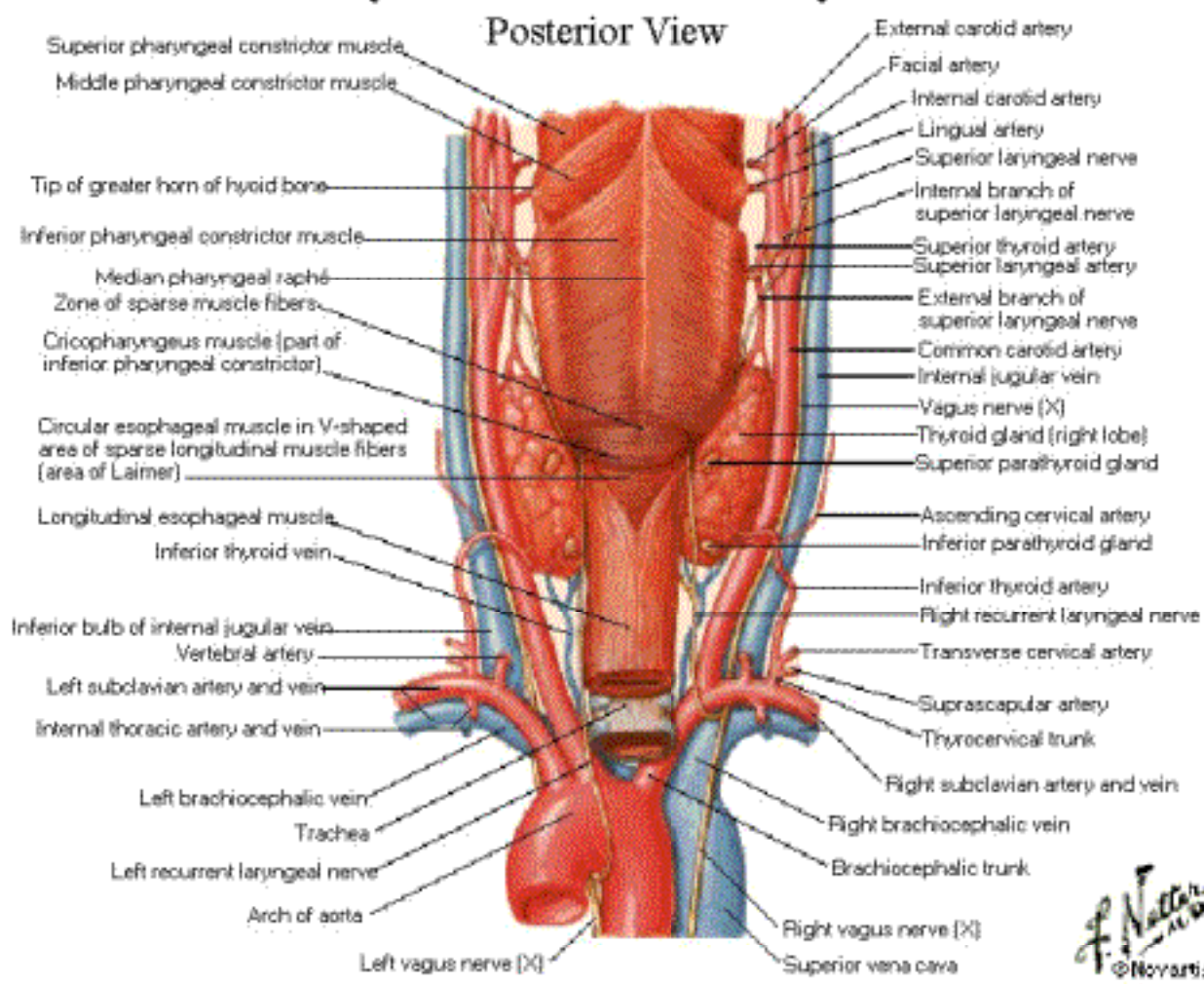
Thyroid Gland in Situ

Anterior View



Thyroid Gland and Pharynx

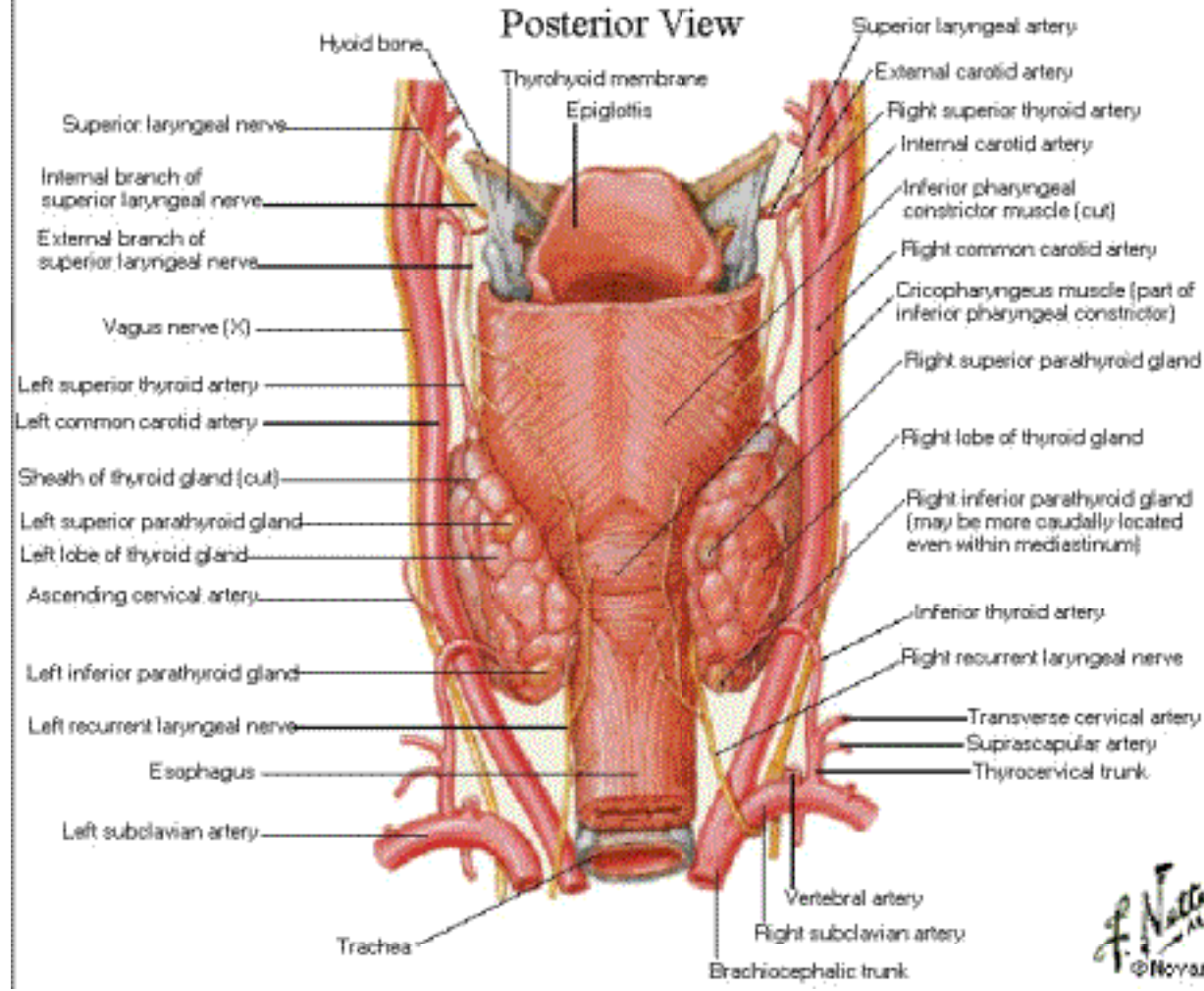
Posterior View



F. Netter M.D.
© Novartis

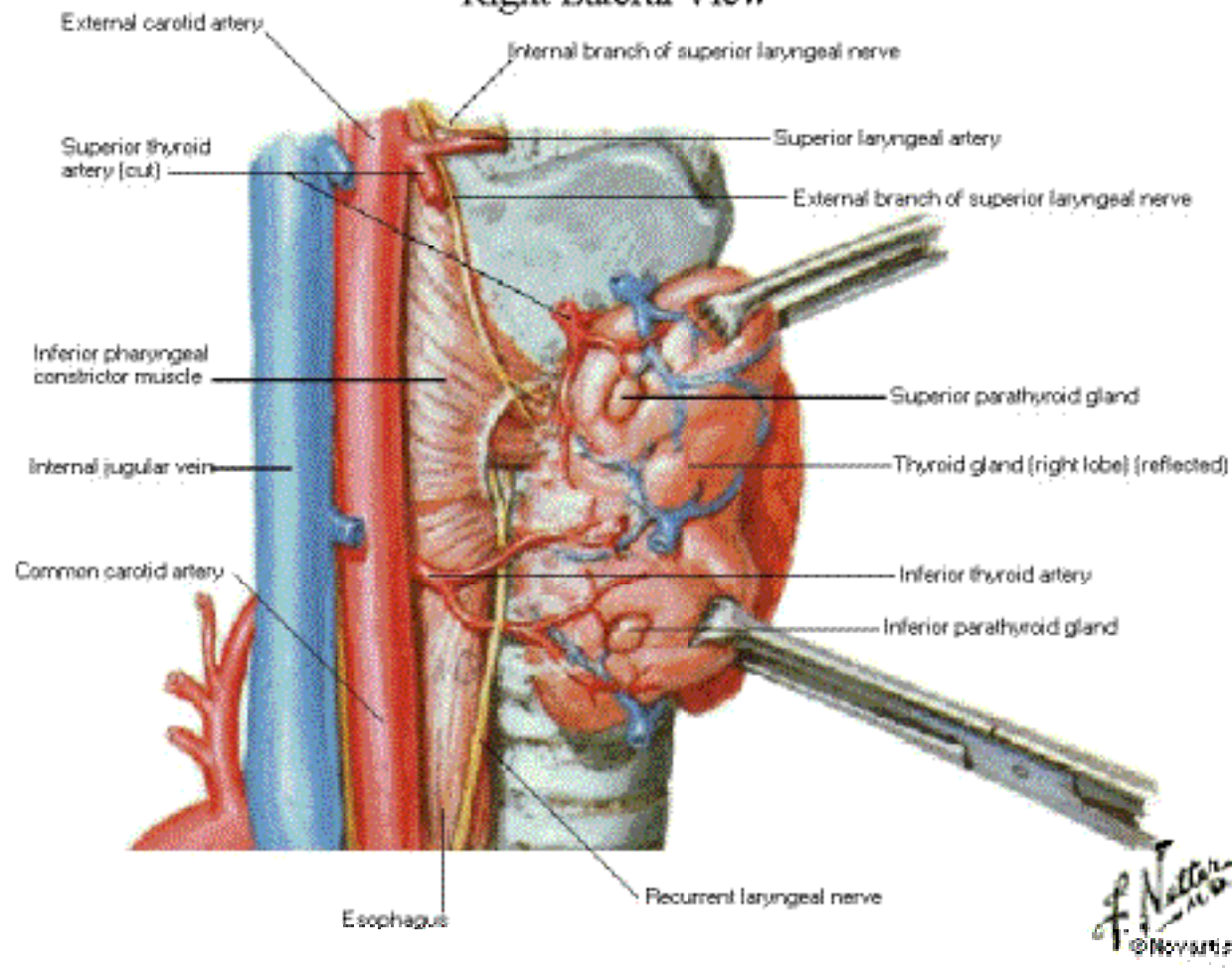
Parathyroid Glands

Posterior View



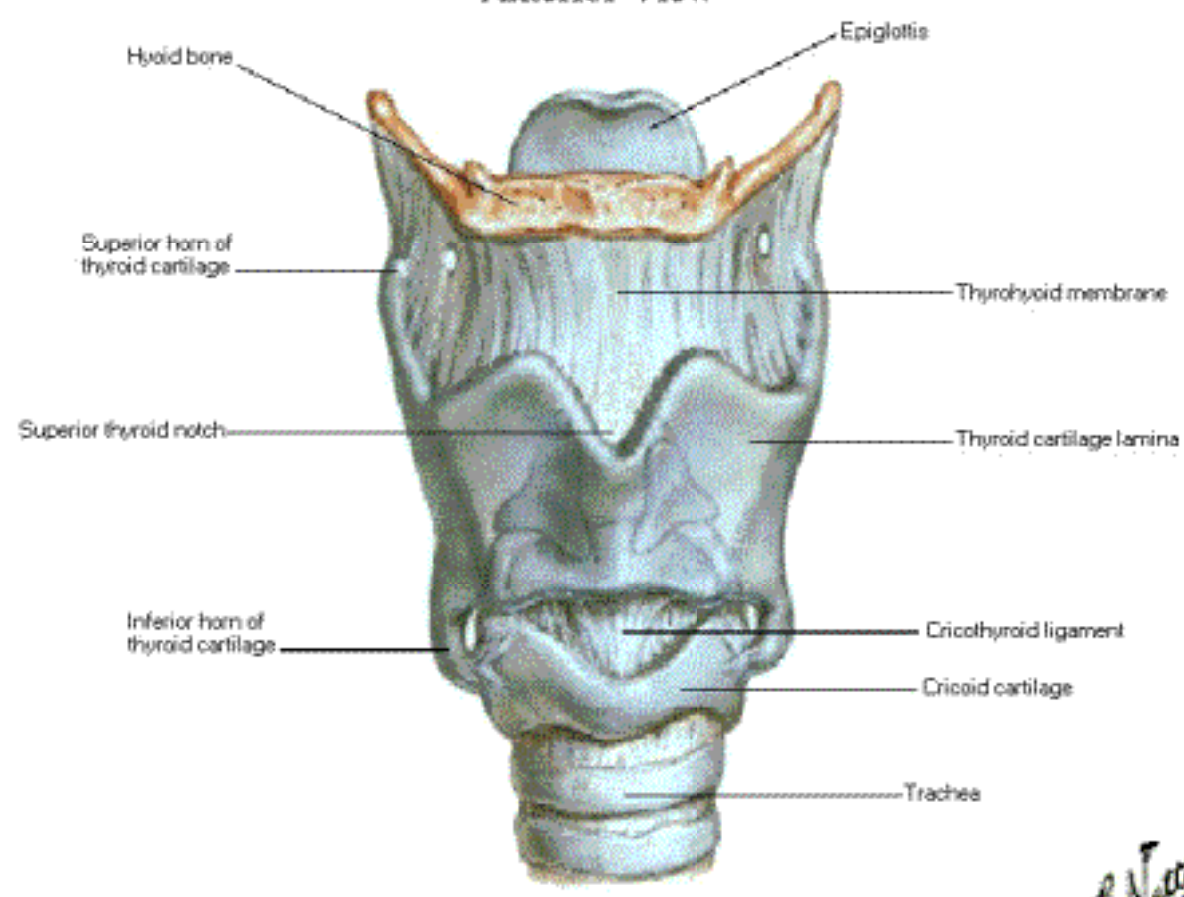
Parathyroid Glands

Right Lateral View



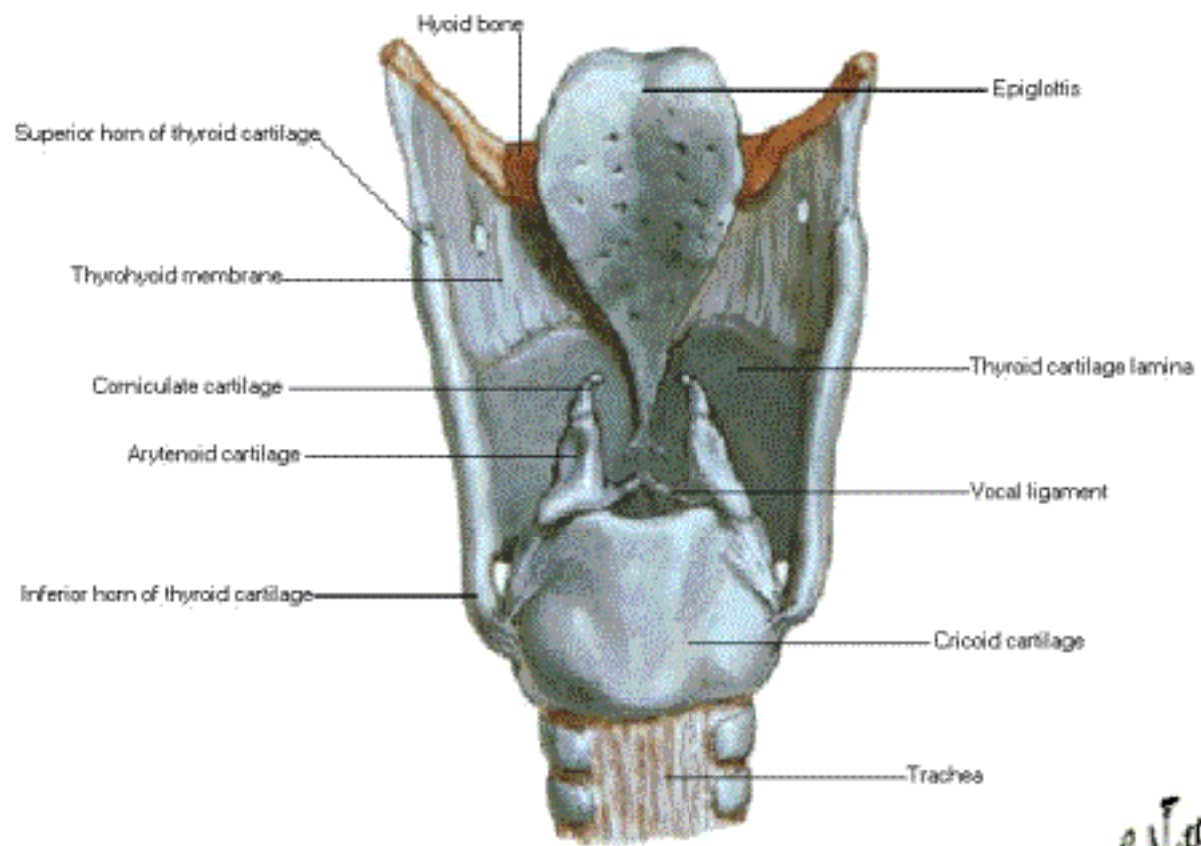
Cartilages of Larynx

Anterior View



F. Netter M.D.
© Novartis

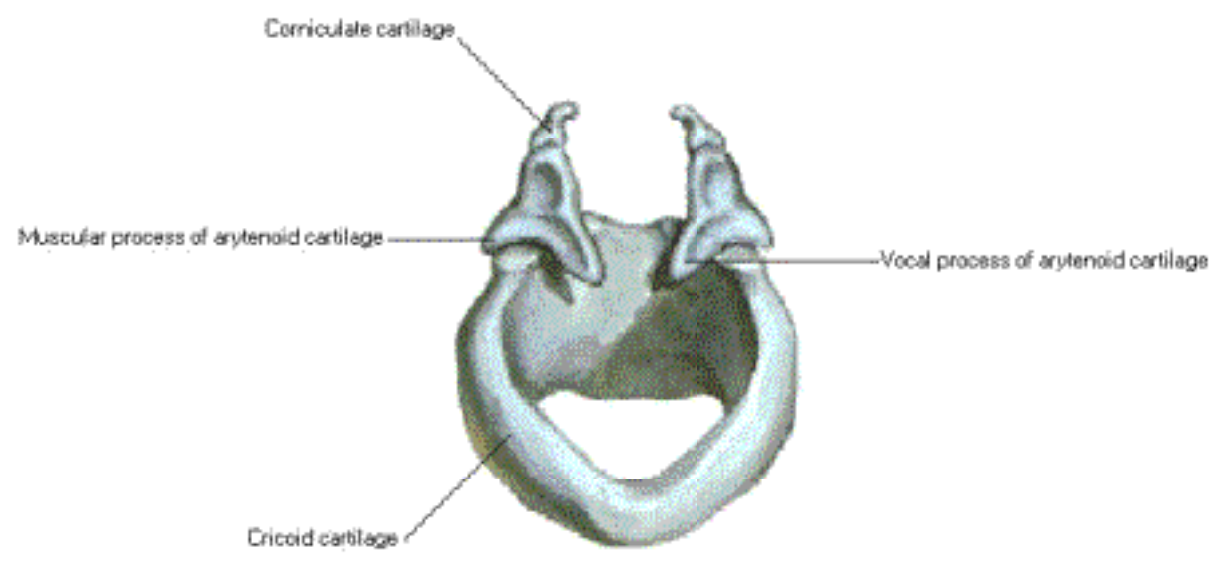
Cartilages of Larynx Posterior View



F. Netter M.D.
© Novartis

Cartilages of Larynx

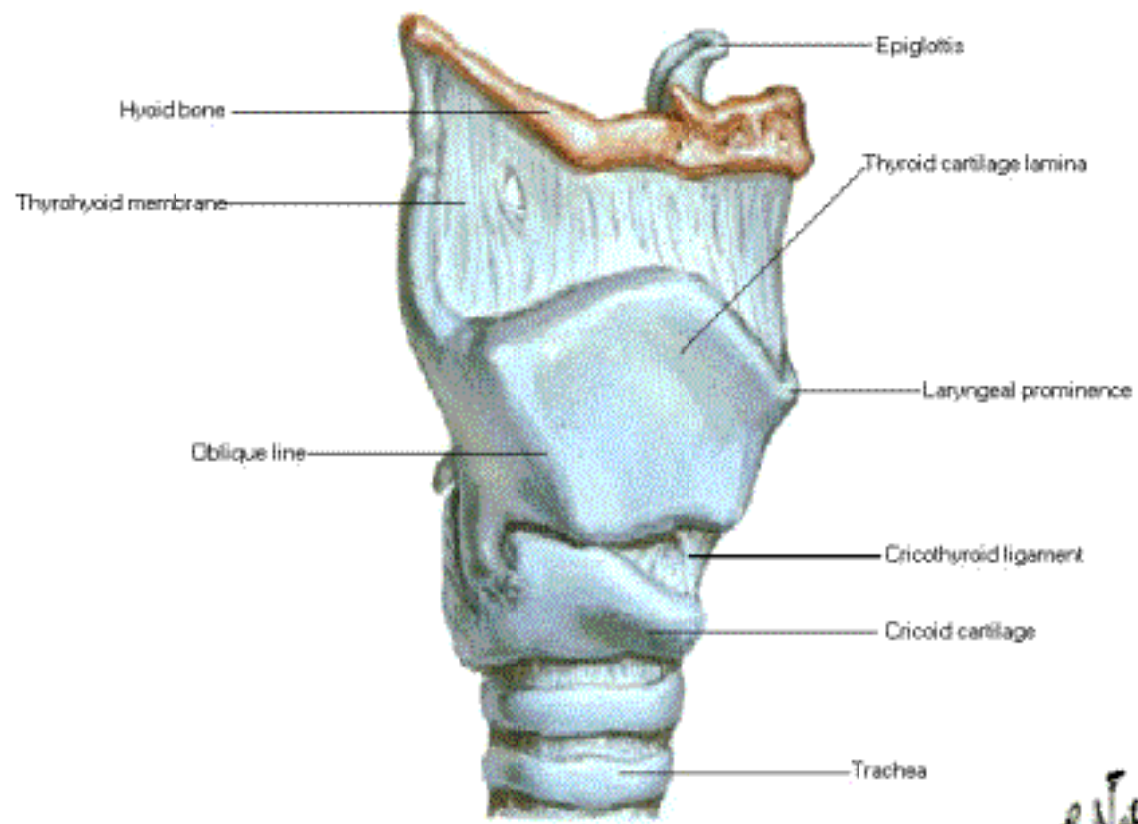
Anterosuperior View



F. Netter M.D.
© Novartis

Cartilages of Larynx

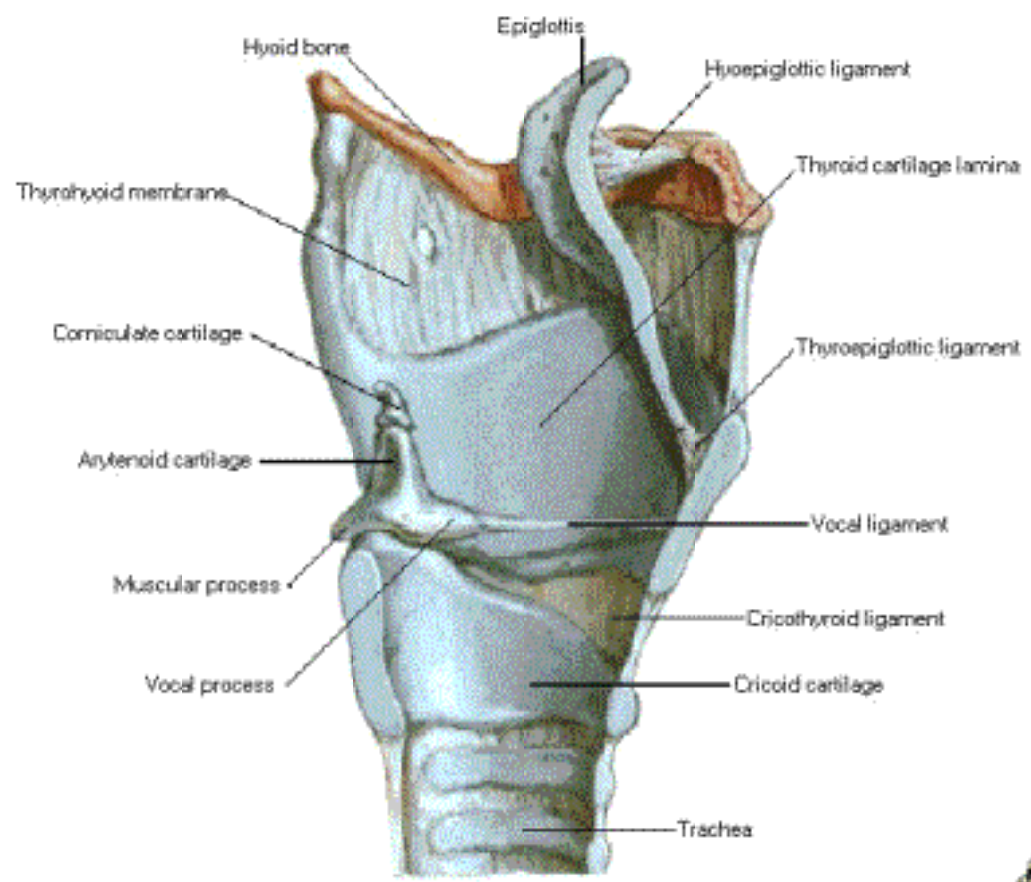
Right Lateral View



F. Netter M.D.
© Novartis

Cartilages of Larynx

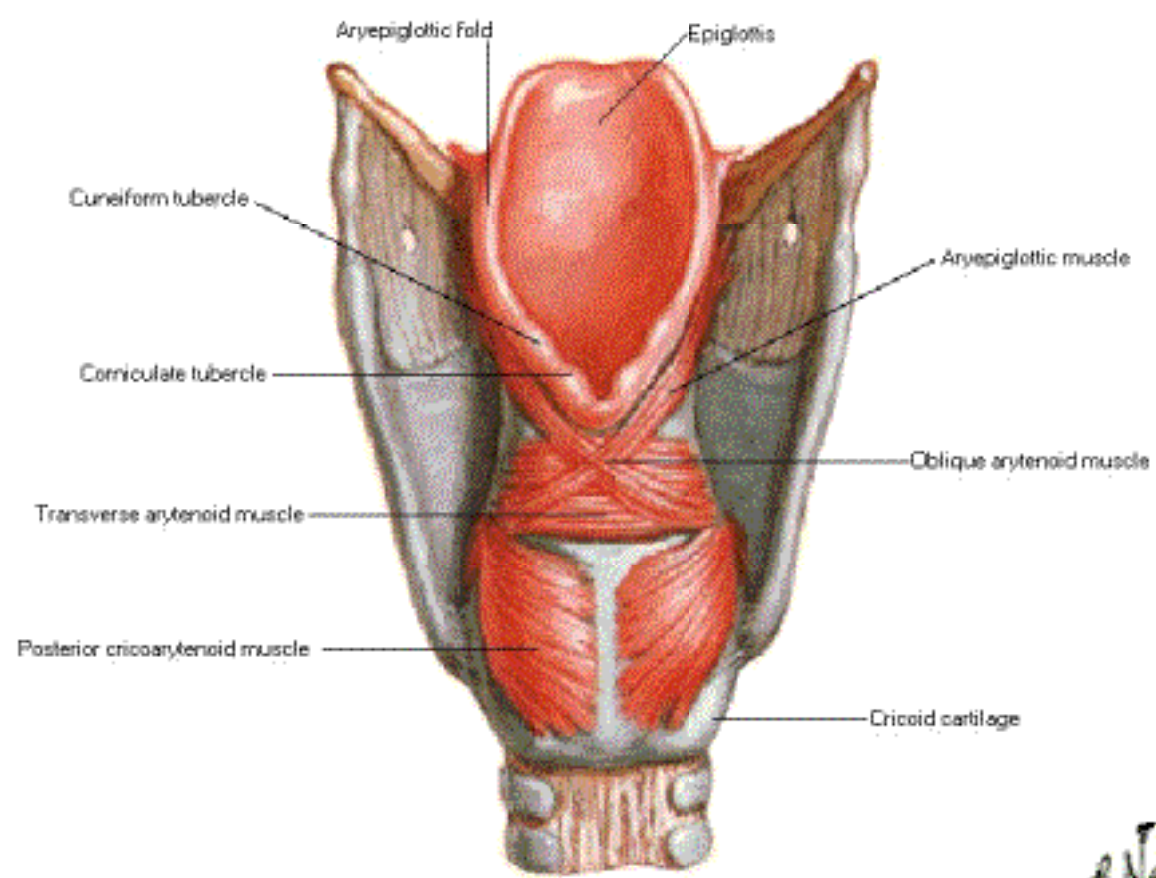
Sagittal Section



F. Netter M.D.
© Novartis

Intrinsic Muscles of Larynx

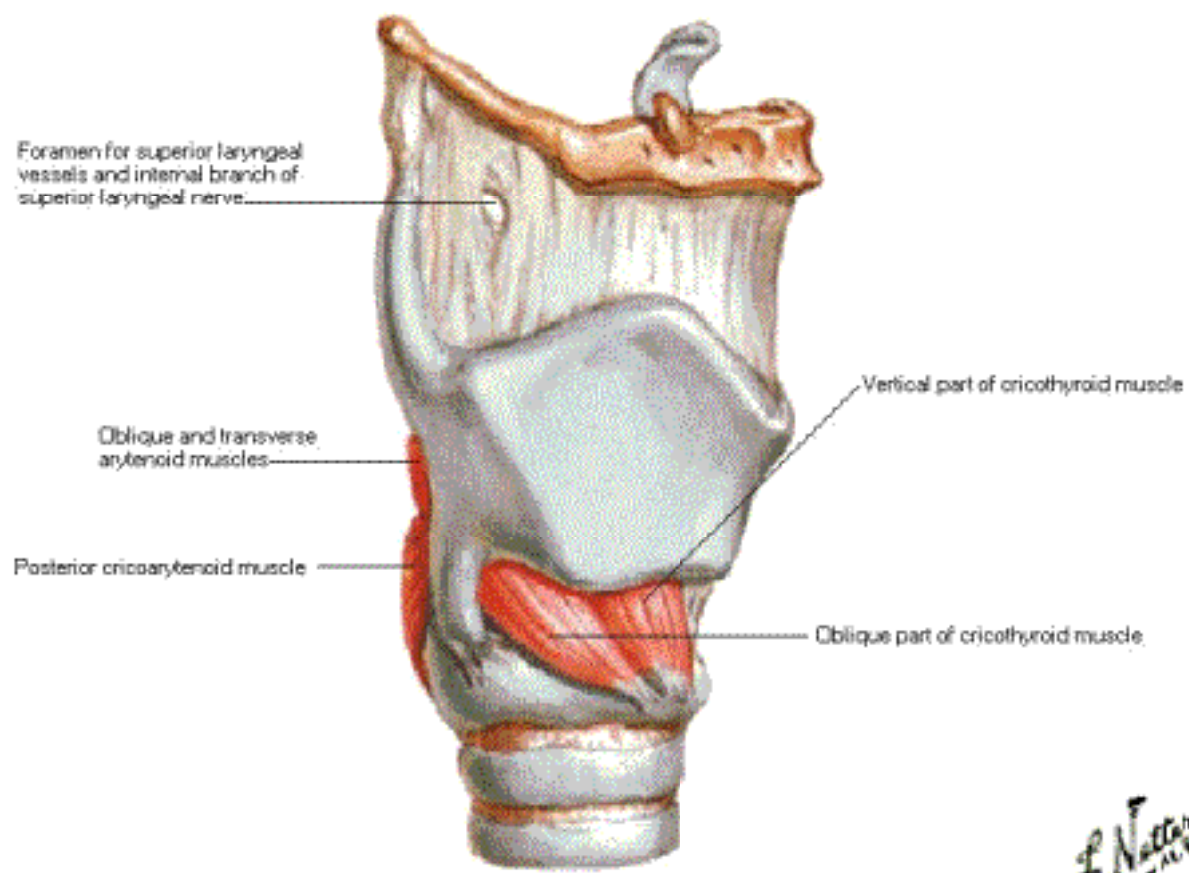
Posterior View



F. Netter
© 1989

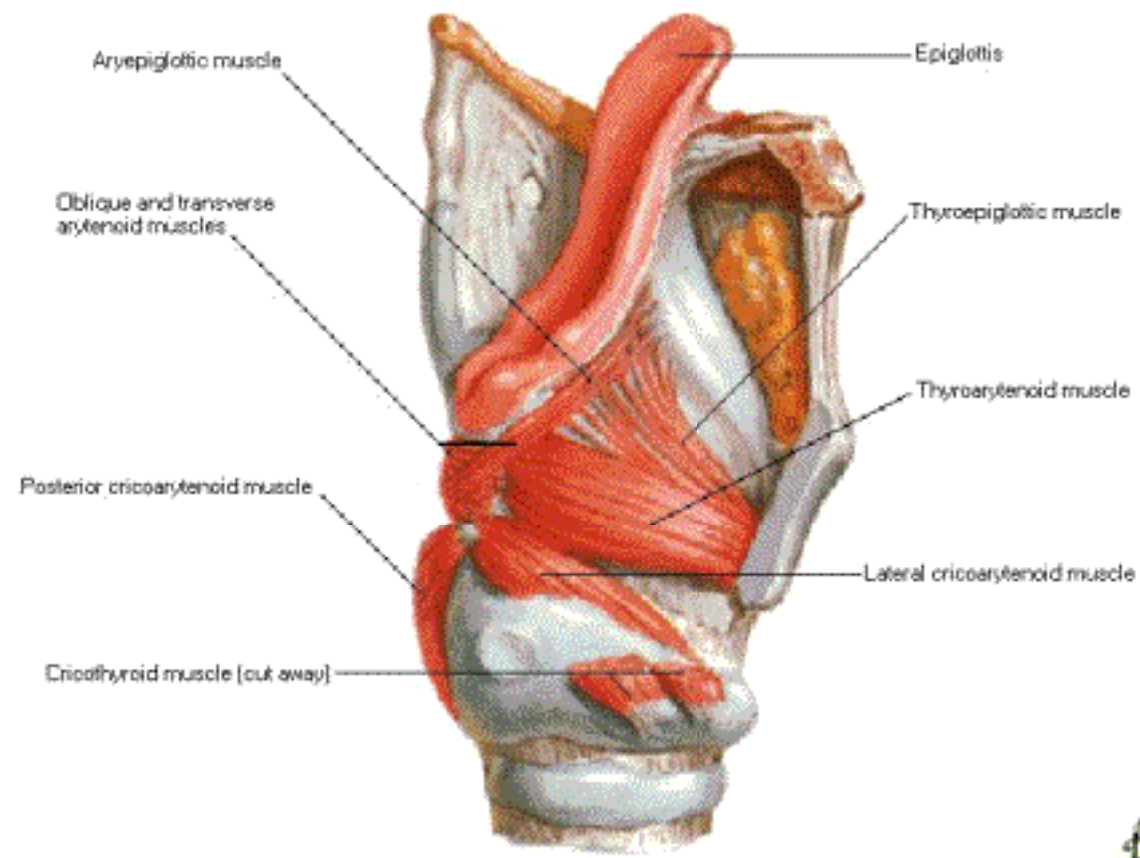
Intrinsic Muscles of Larynx

Right Lateral View



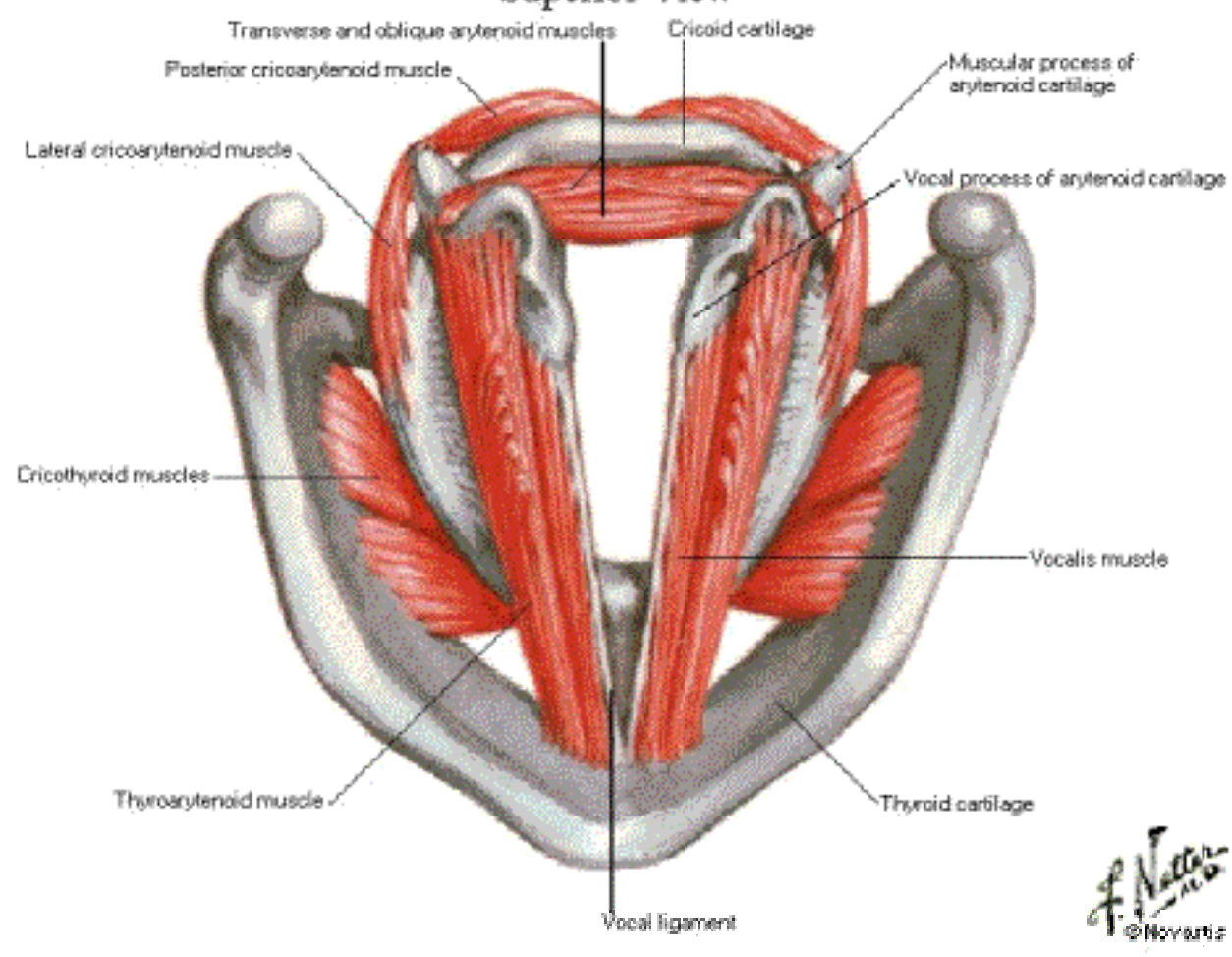
F. Netter M.D.
© Novartis

Intrinsic Muscles of Larynx Lateral Dissection



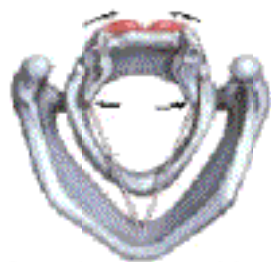
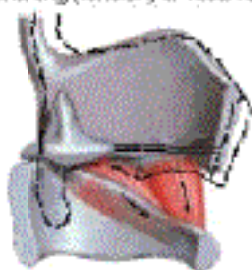
Intrinsic Muscles of Larynx

Superior View

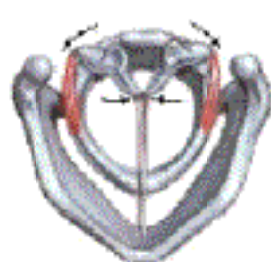


Action of Intrinsic Muscles of Larynx

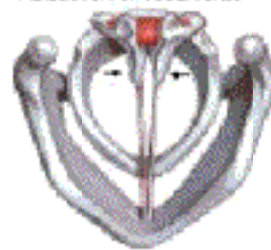Action of cricothyroid muscles:
Lengthening (tension) of vocal folds



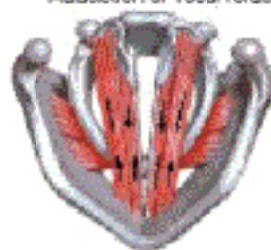Action of posterior cricoarytenoid muscles:
Abduction of vocal folds



Action of lateral cricoarytenoid muscles:
Adduction of vocal folds



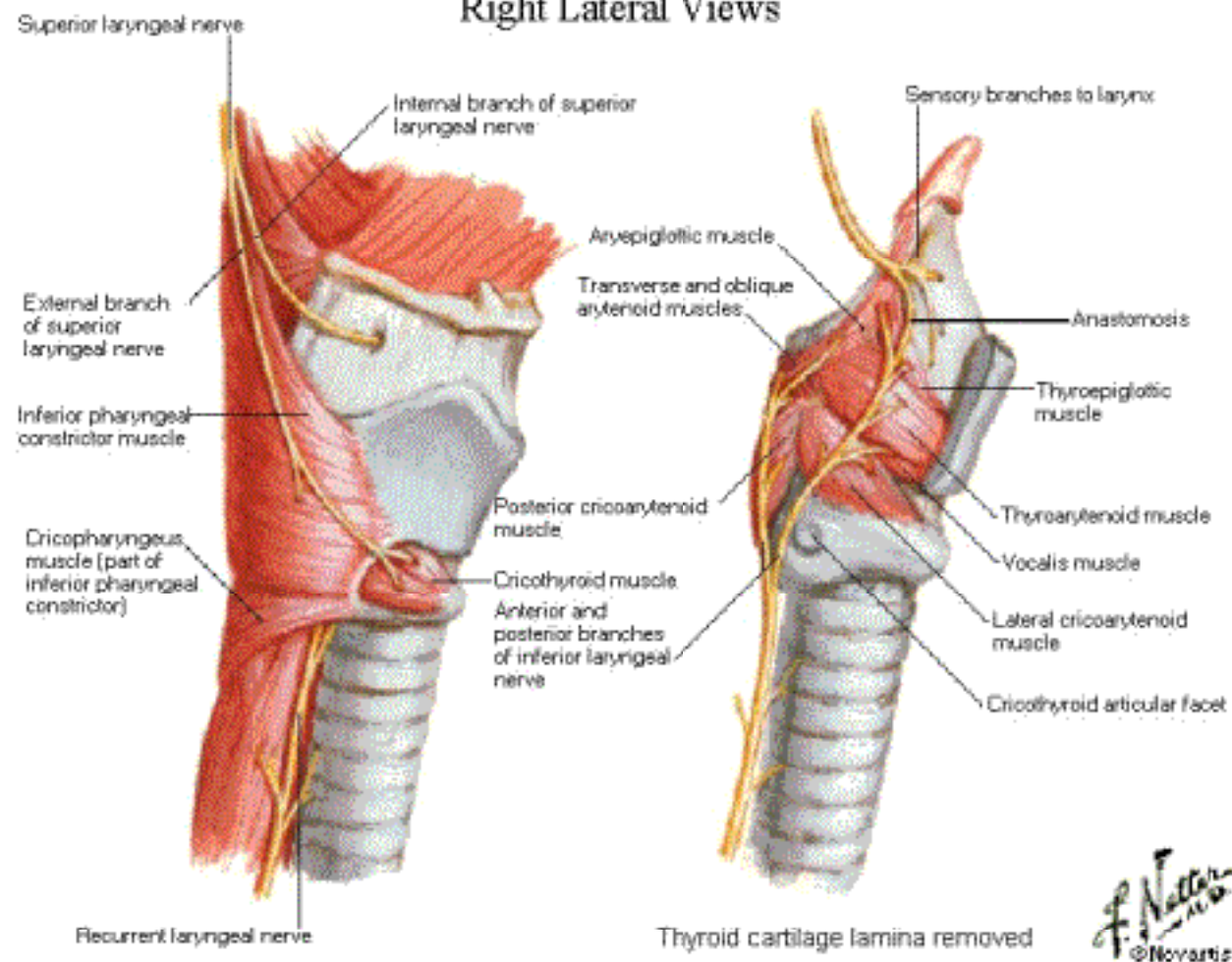
Action of arytenoid muscle:
Adduction of vocal folds



Action of vocalis and thyroarytenoid muscles:
Shortening (relaxation) of vocal folds

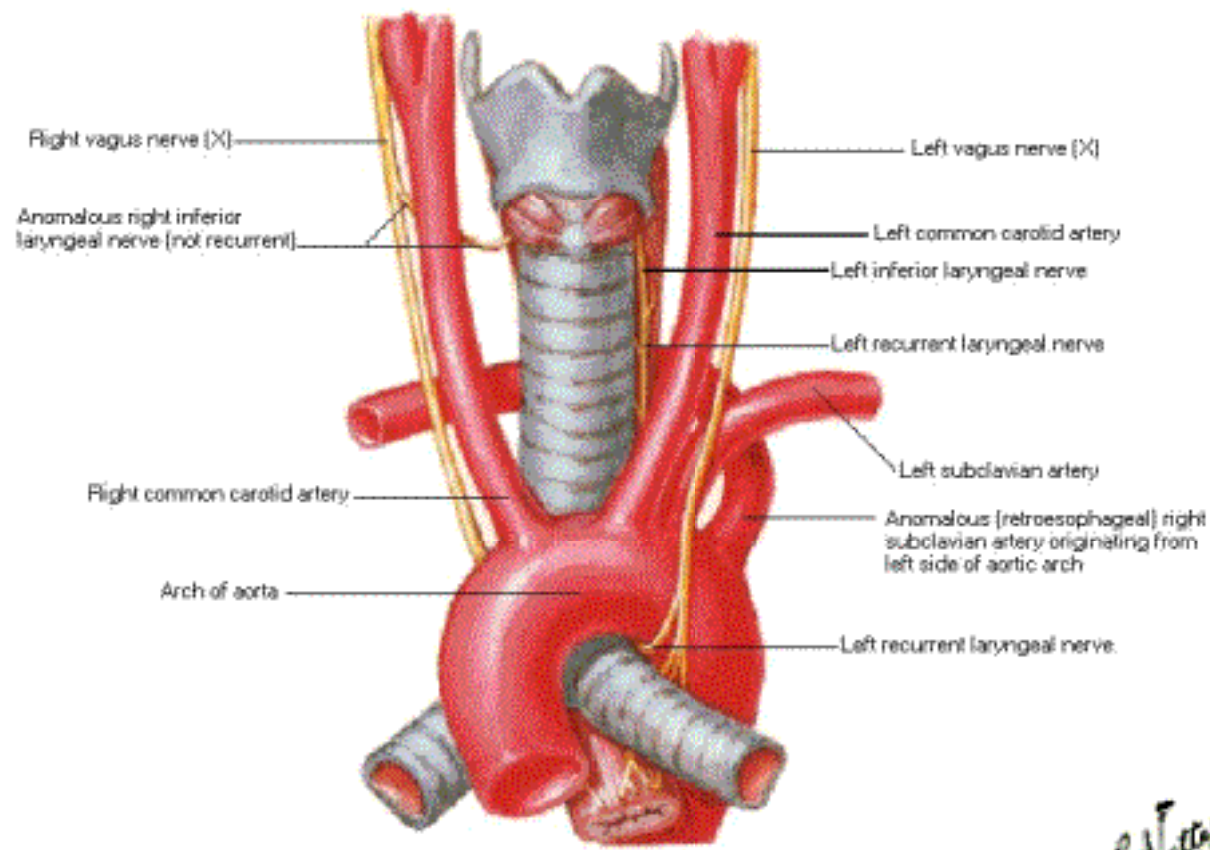
F. Netter
© Novartis

Nerves of Larynx Right Lateral Views



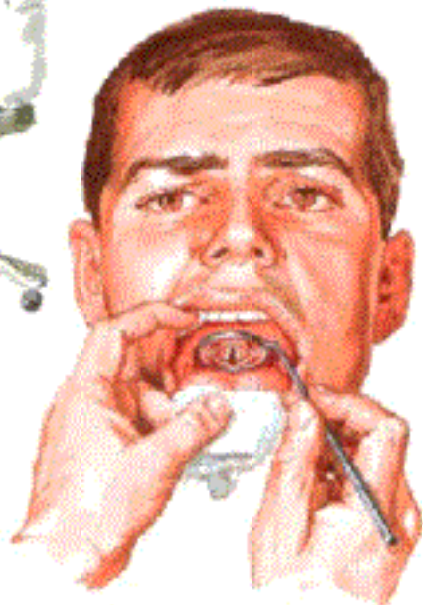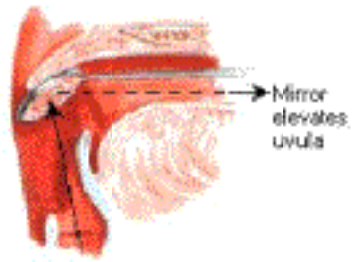
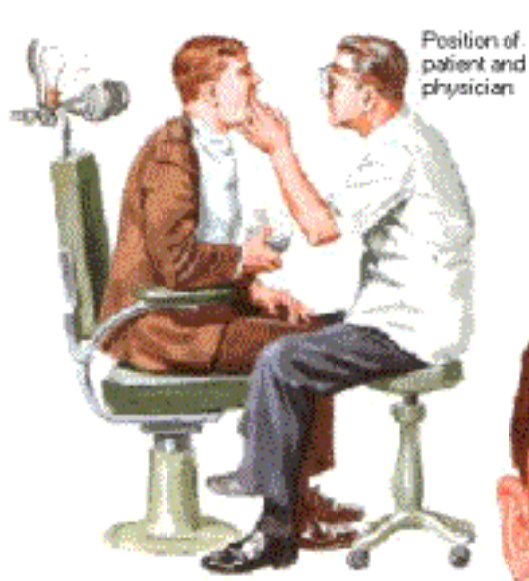Nerves of Larynx

Anterior View



F. Netter M.D.
© Novartis

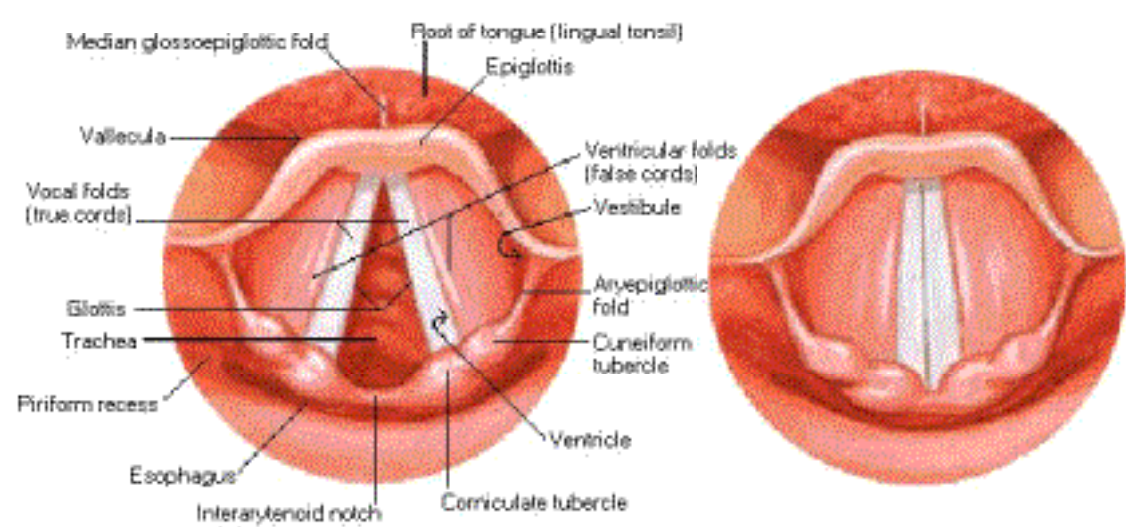
Inspection of Larynx Technique



F. Netter M.D.
©Novartis

Inspection of Larynx

Views during Inspiration and Phonation



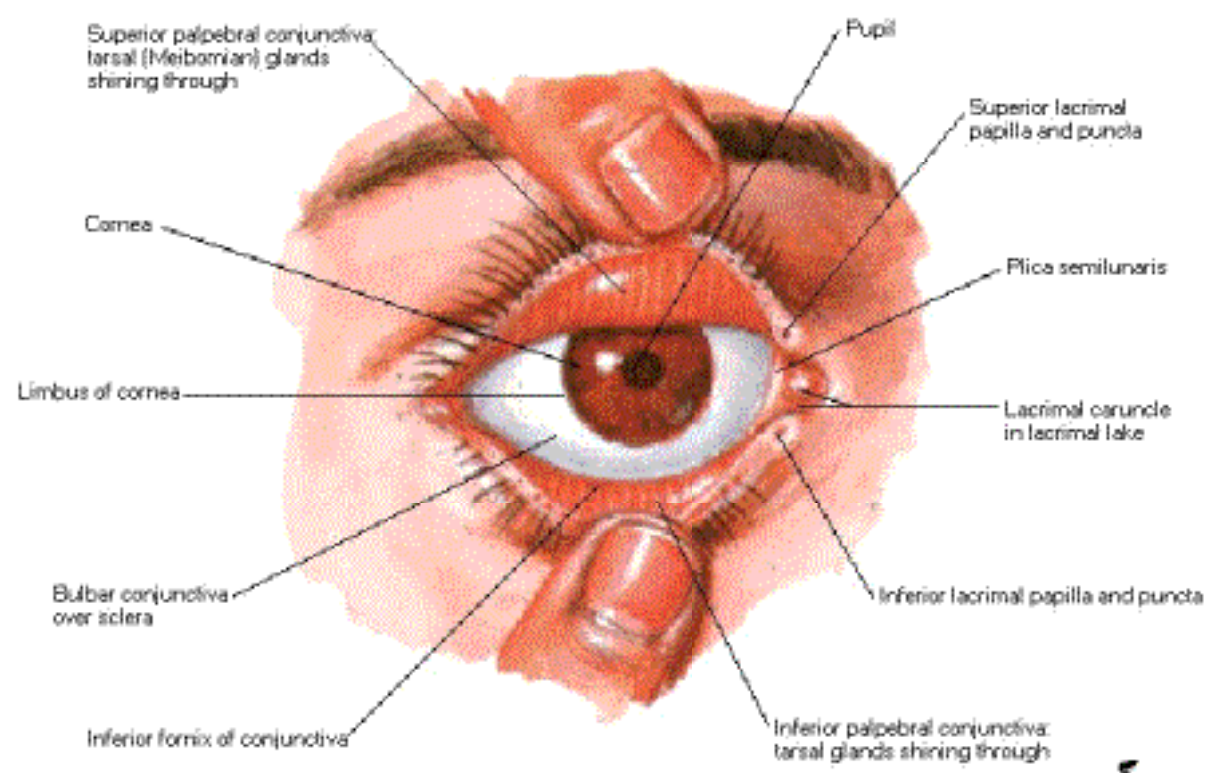
Normal larynx: inspiration

Normal larynx: phonation

F. Netter M.D.
© 1996

Eyelids

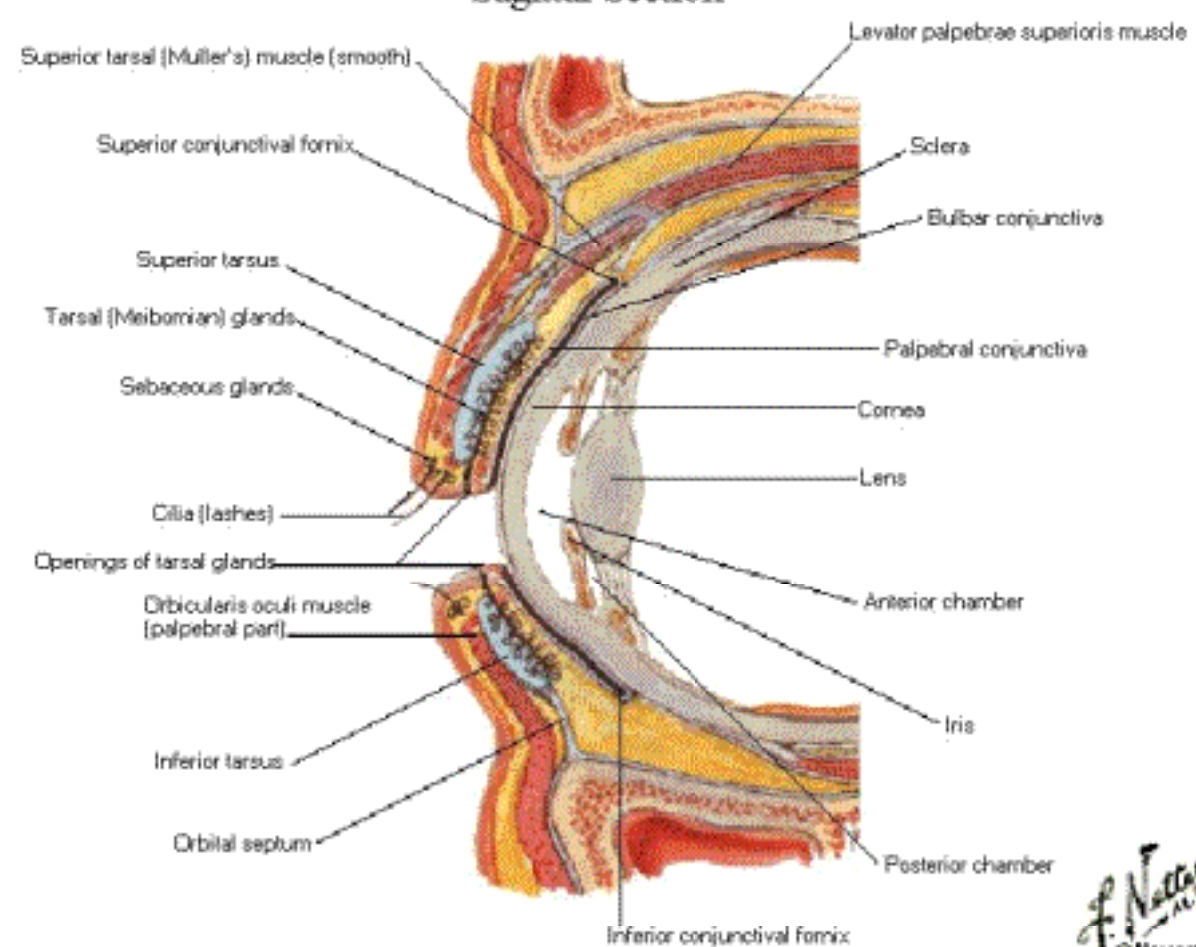
Anterior View



F. Netter
© 1996

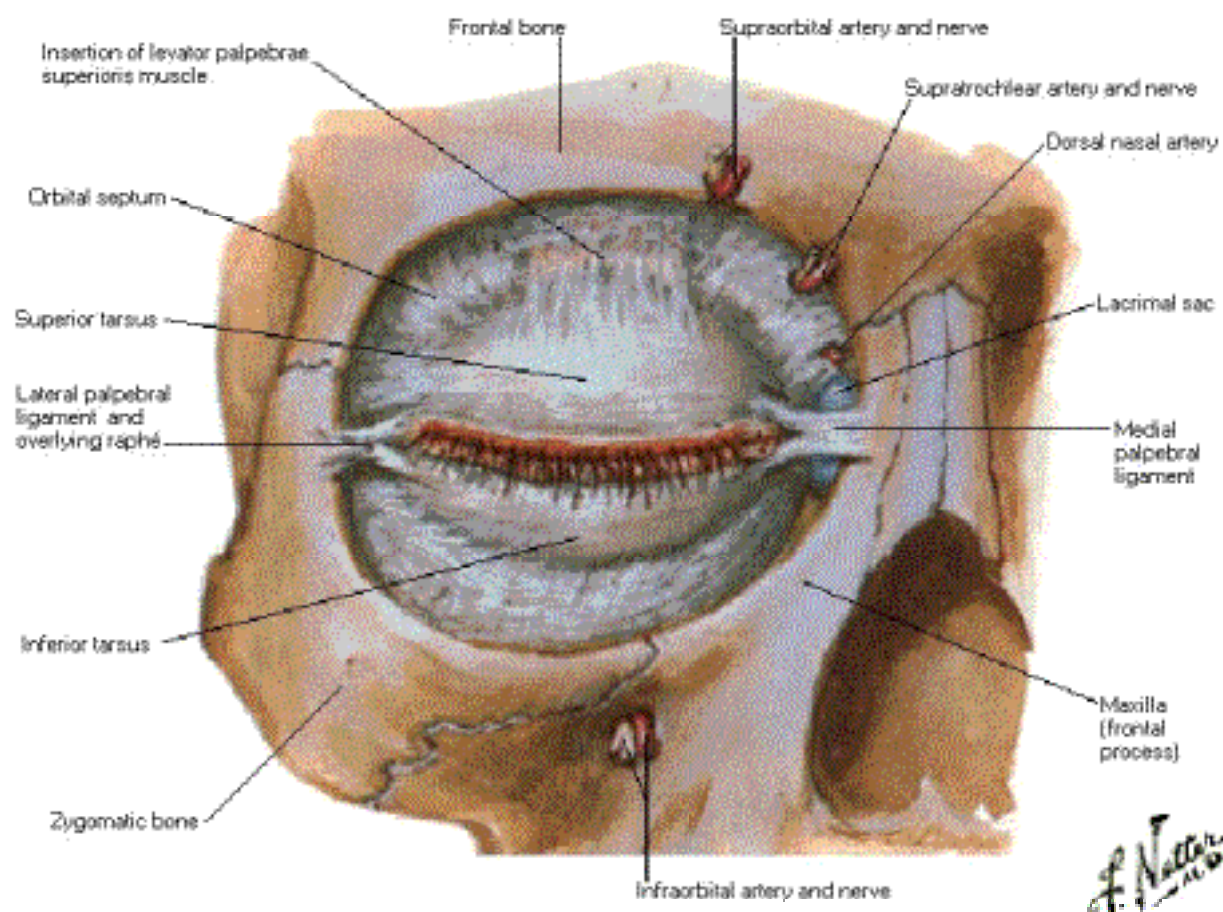
Eyelids and Anterior Orbital Structures

Sagittal Section

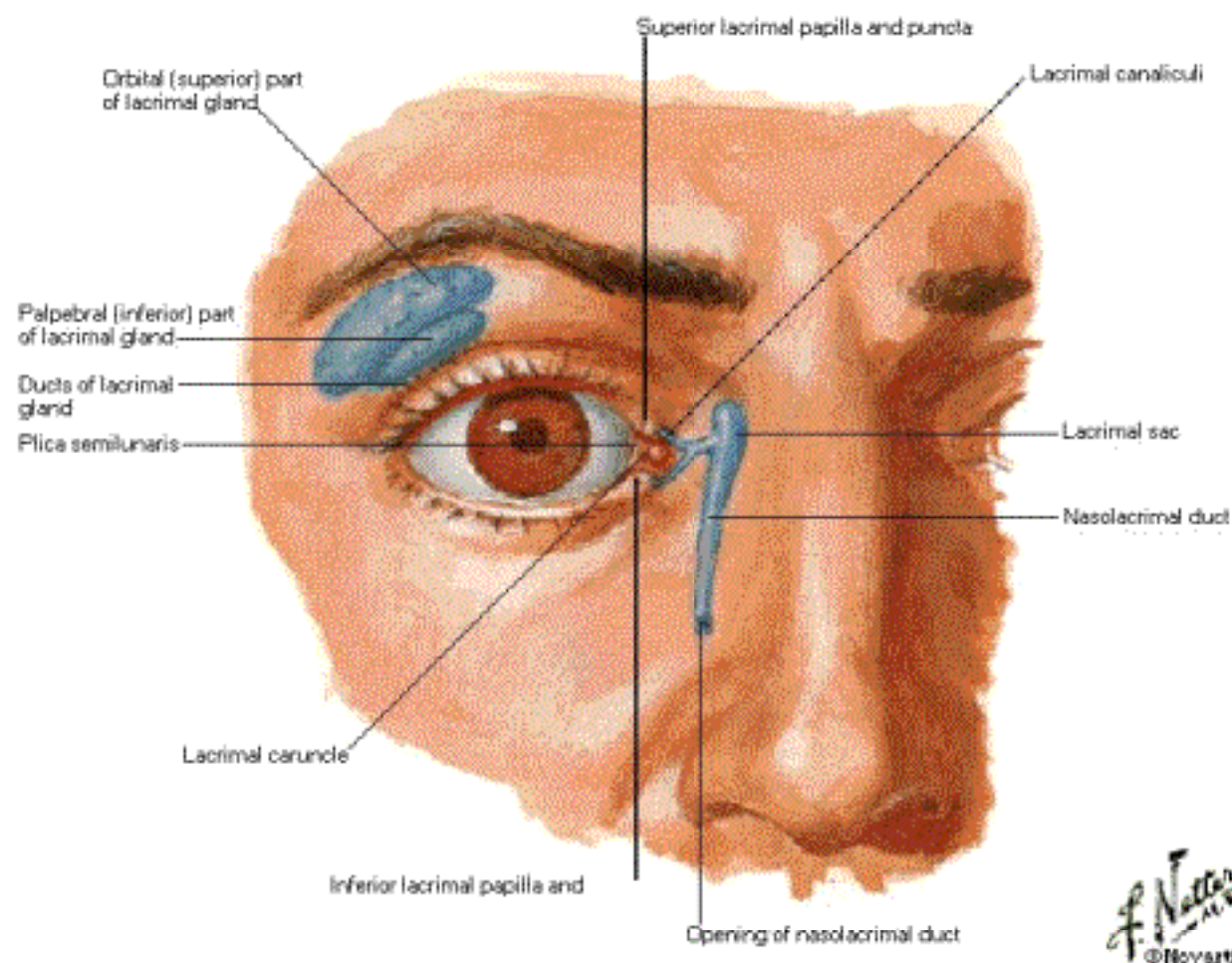


Eyelids - Dissection

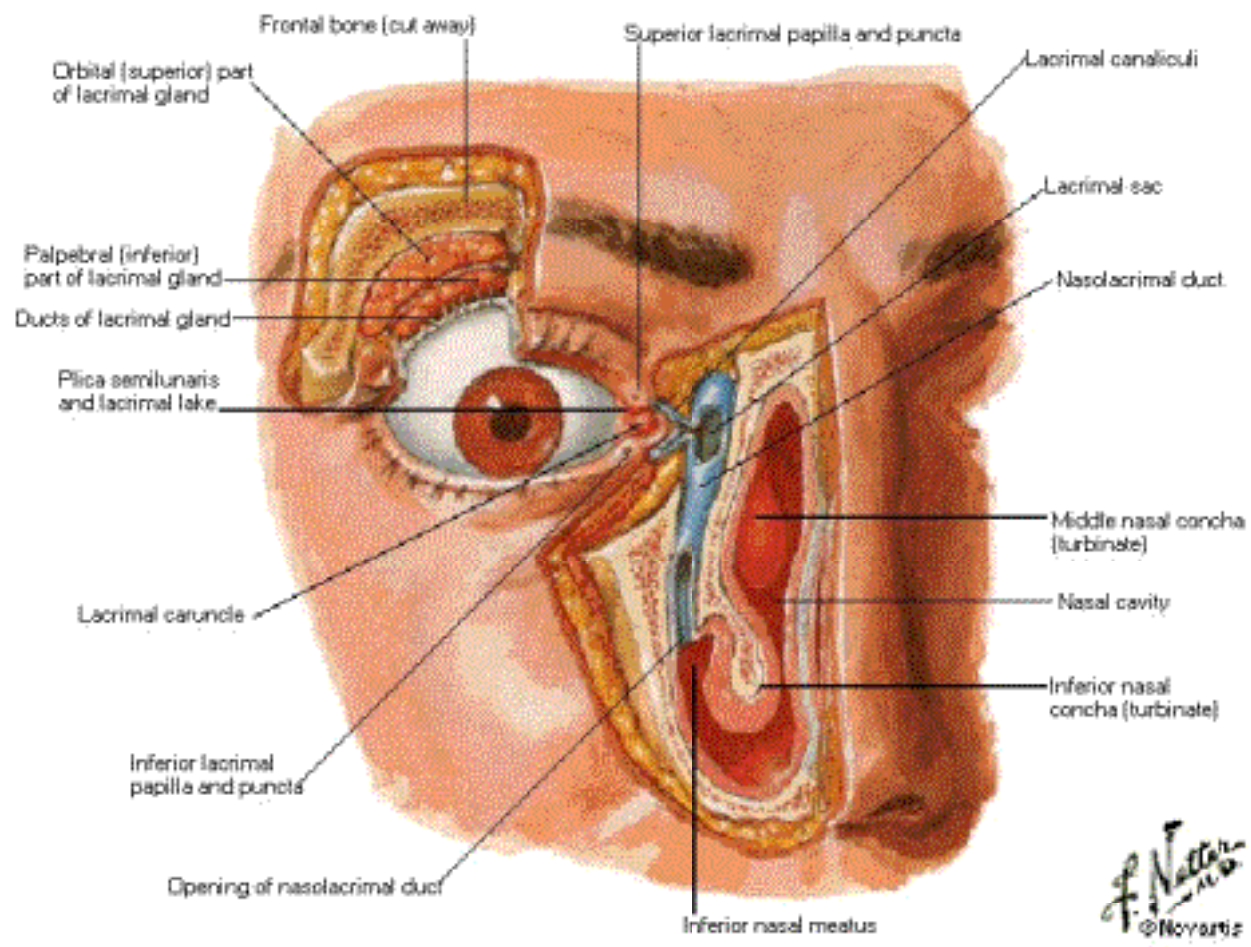
Anterior View



Lacrimal Apparatus in Situ

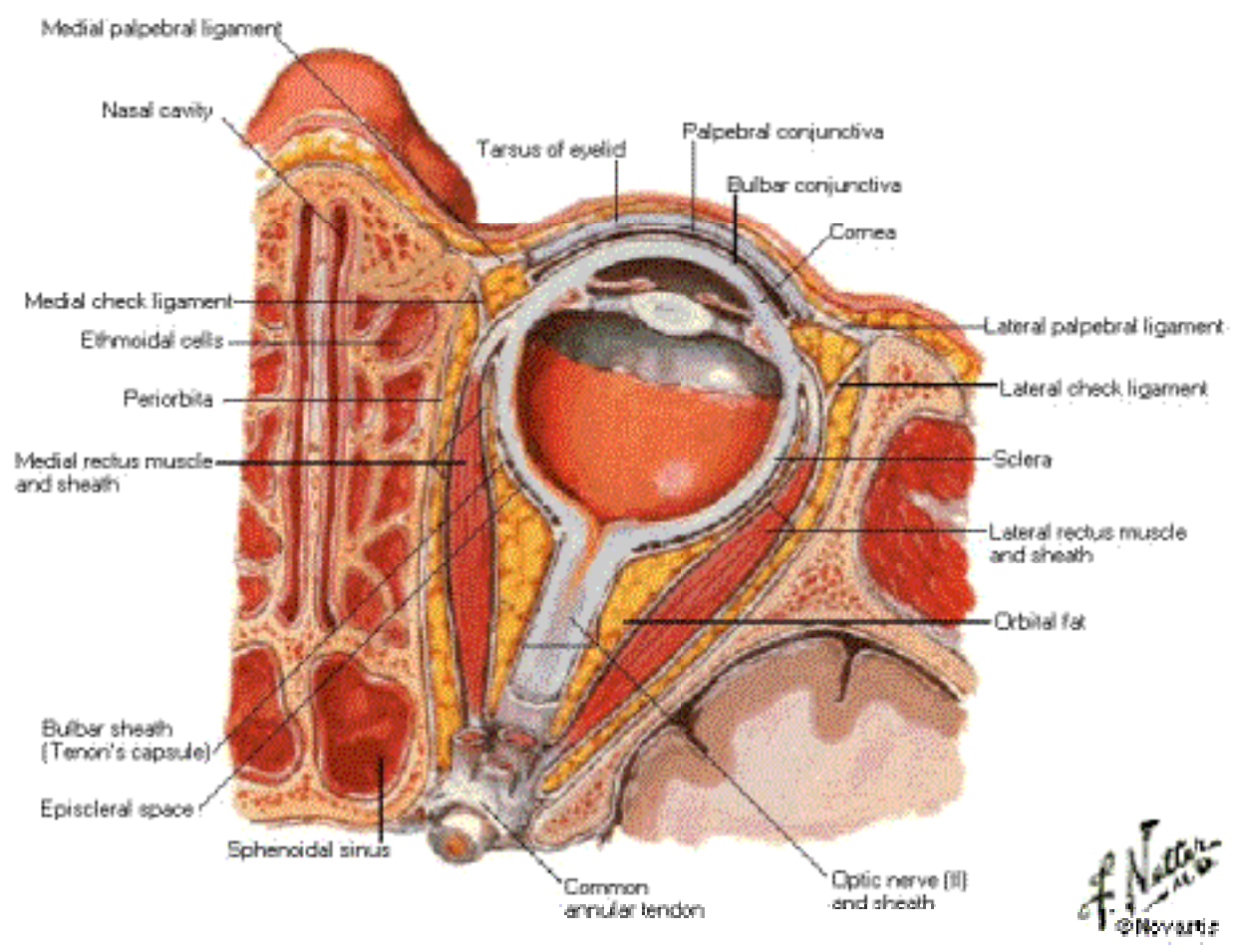


Lacrimal Apparatus Dissection



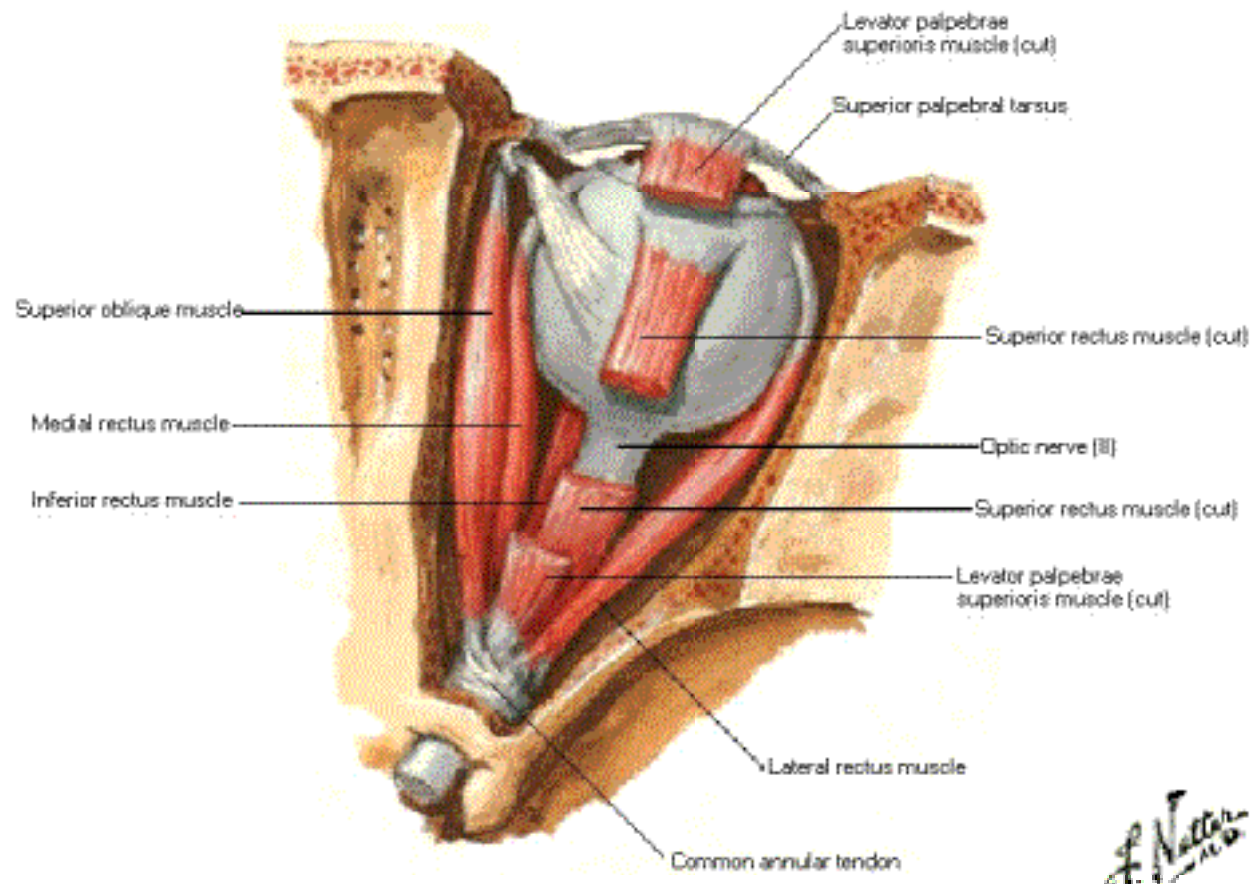
Fascia of Orbit and Eyeball

Horizontal Section



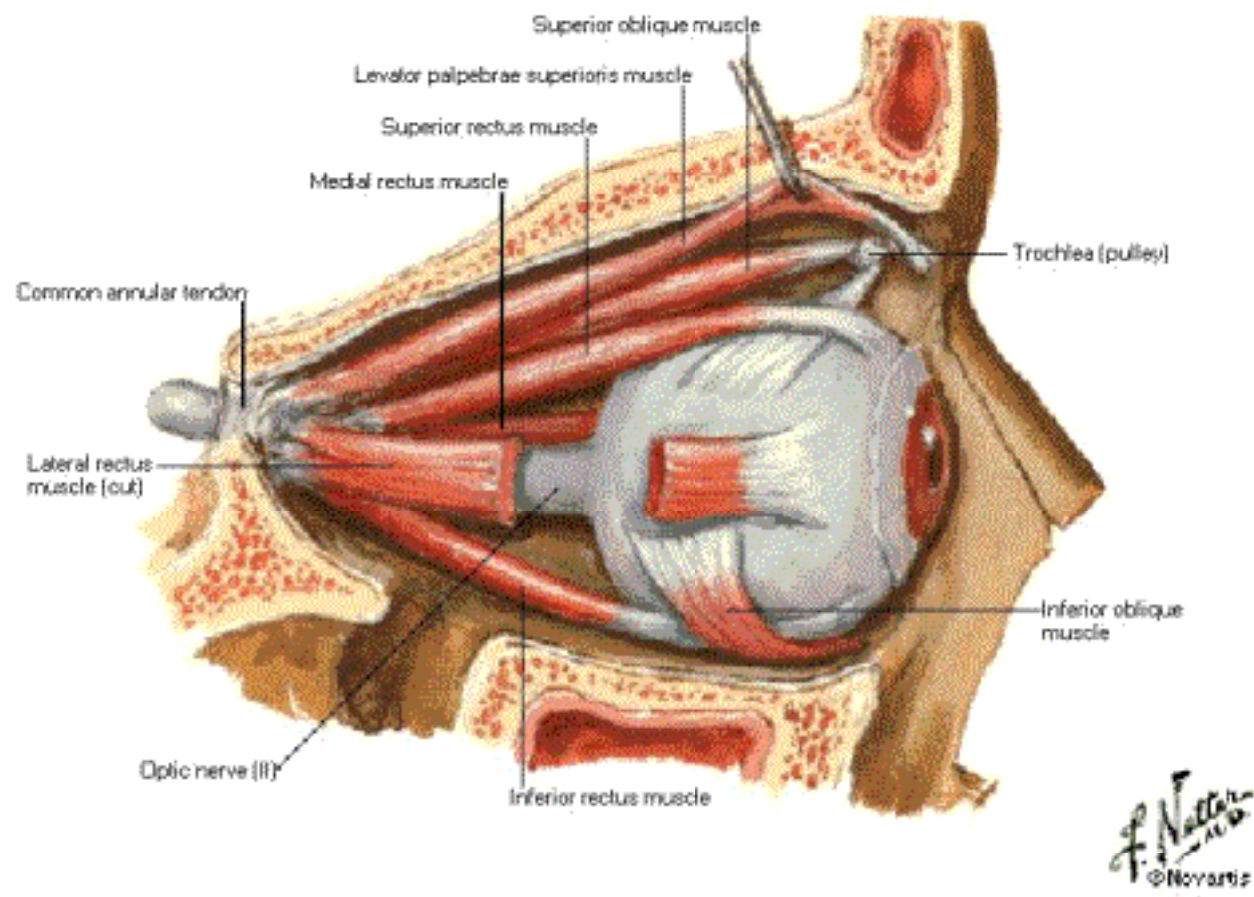
Extrinsic Eye Muscles

Superior View



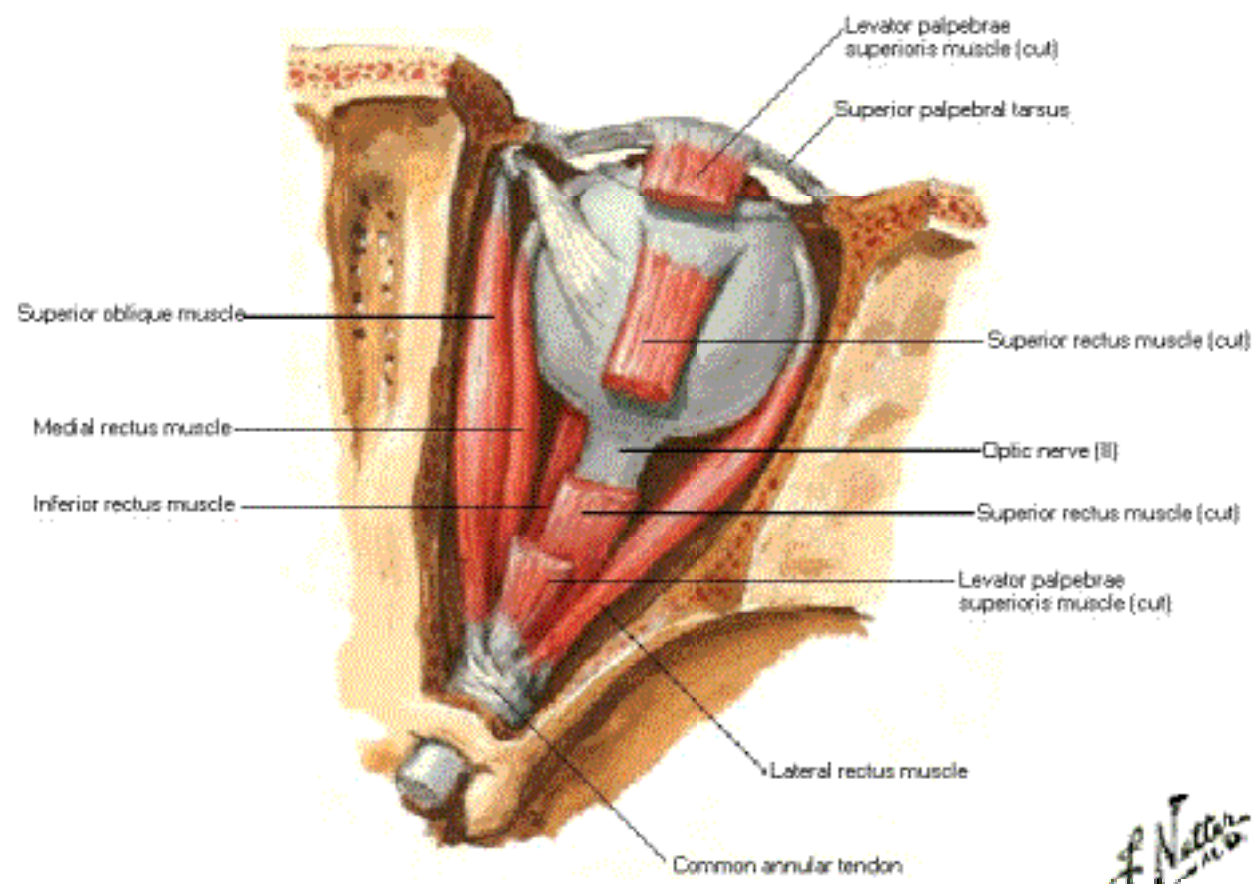
Extrinsic Eye Muscles

Right Lateral View



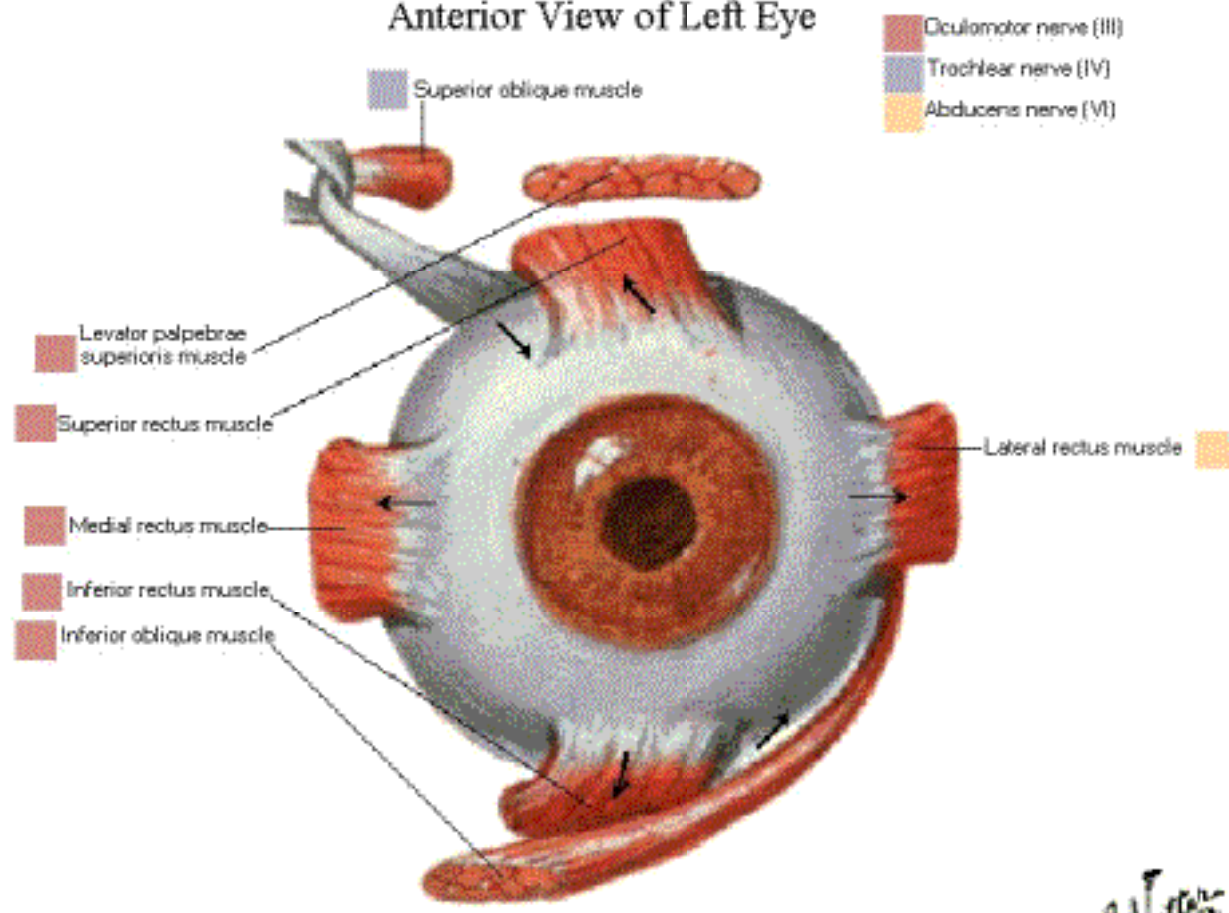
Extrinsic Eye Muscles

Superior View



Extrinsic Eye Muscles - Innervation and Action

Anterior View of Left Eye

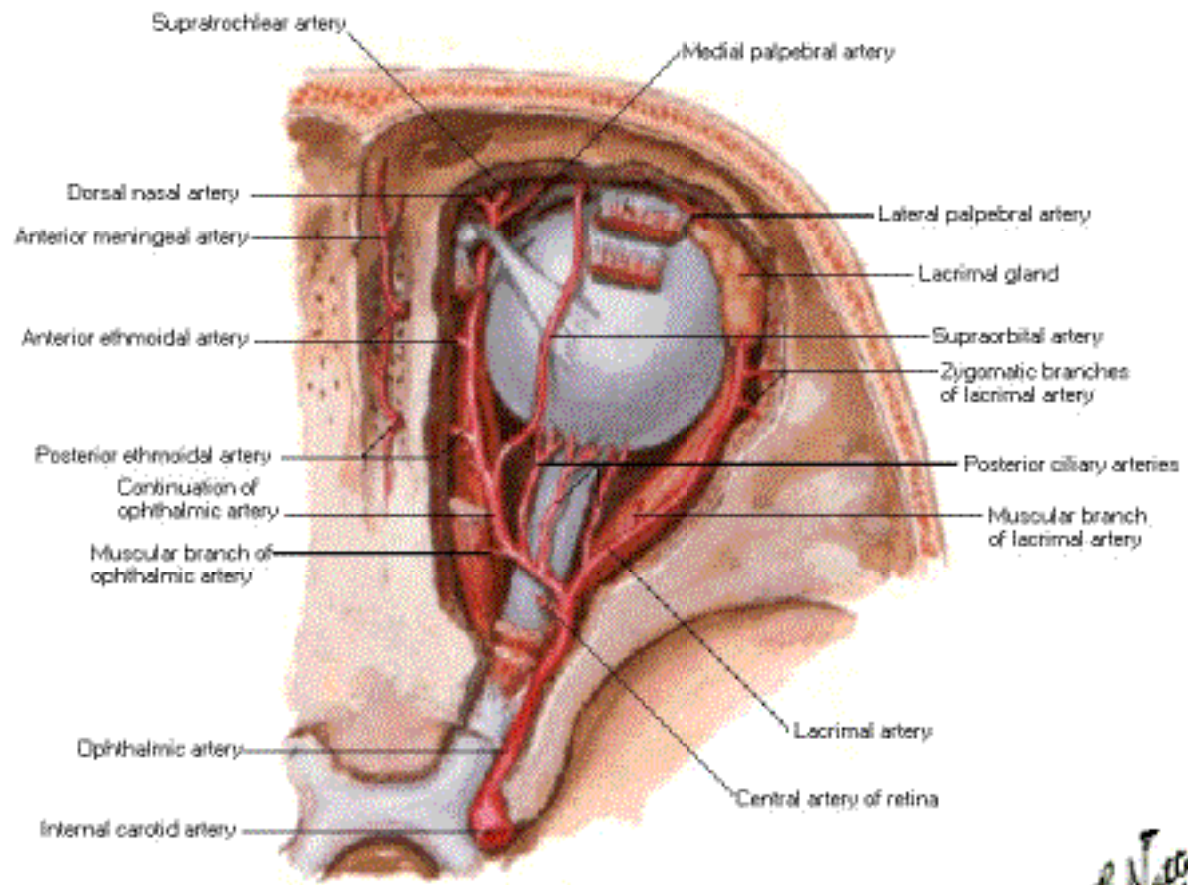


Note: arrows indicate direction of eye movement produced by each muscle

F. Nasser
© November

Arteries and Veins of Orbit and Eyelids

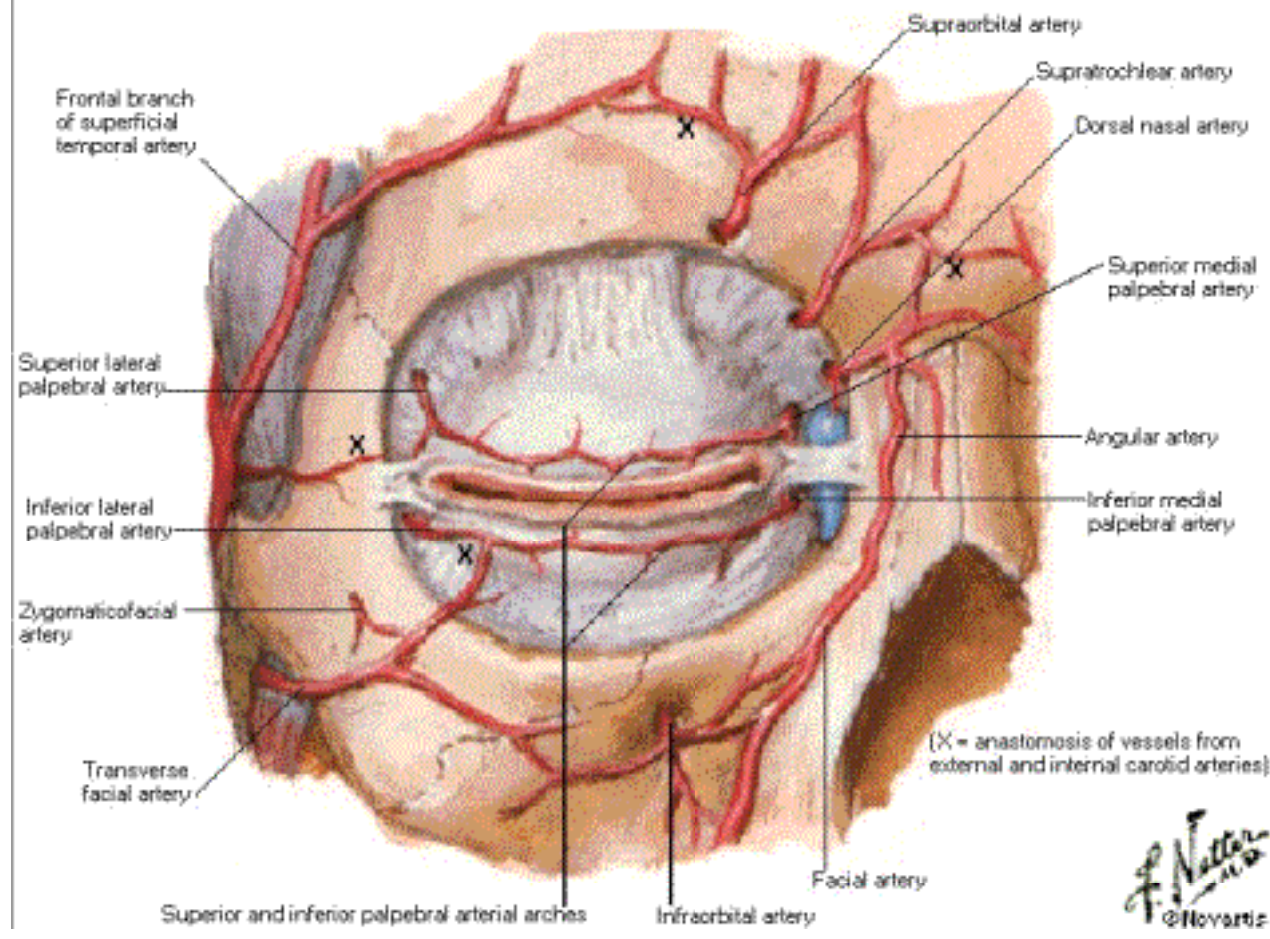
Superior View



F. Netter M.D.
© Novartis

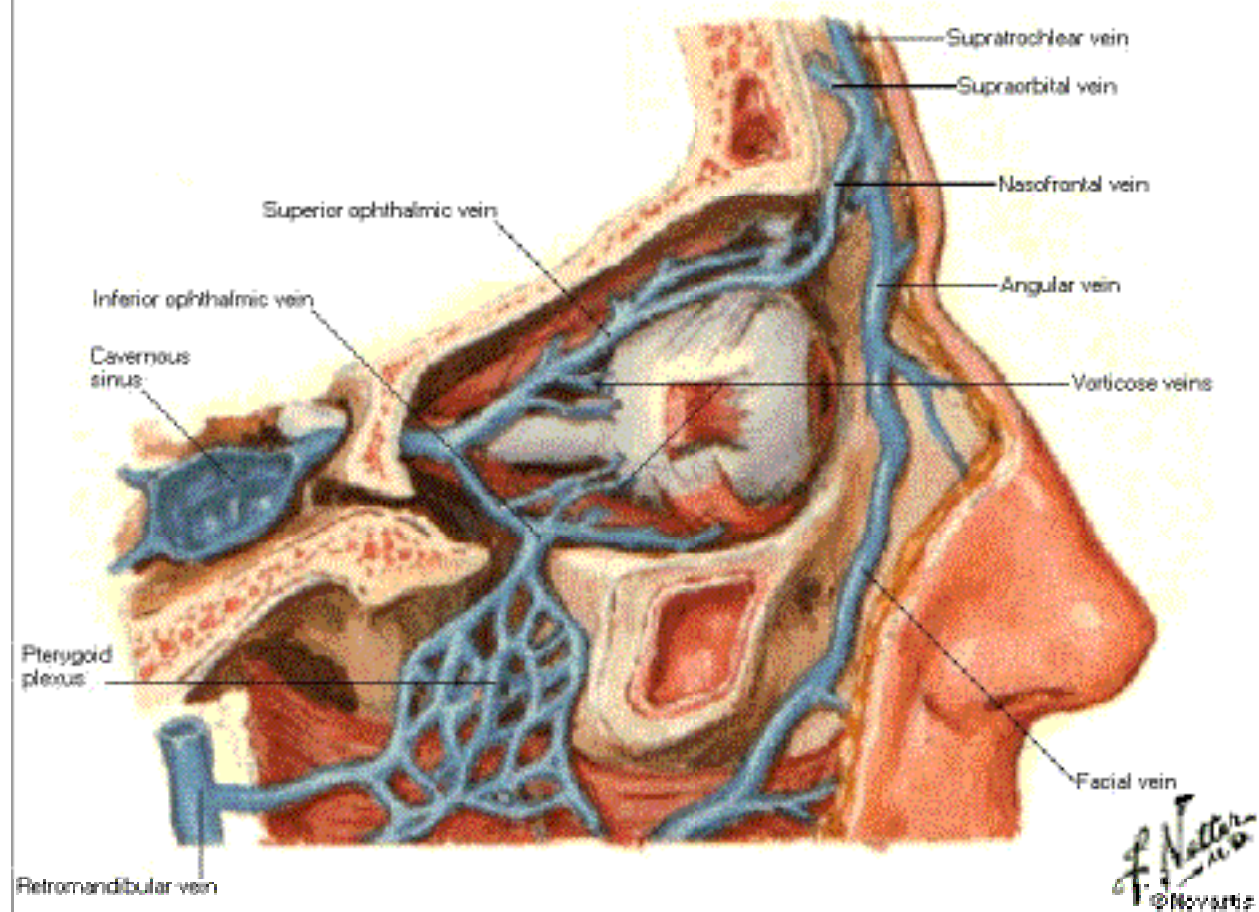
Arteries and Veins of Orbit and Eyelids

Anterior View



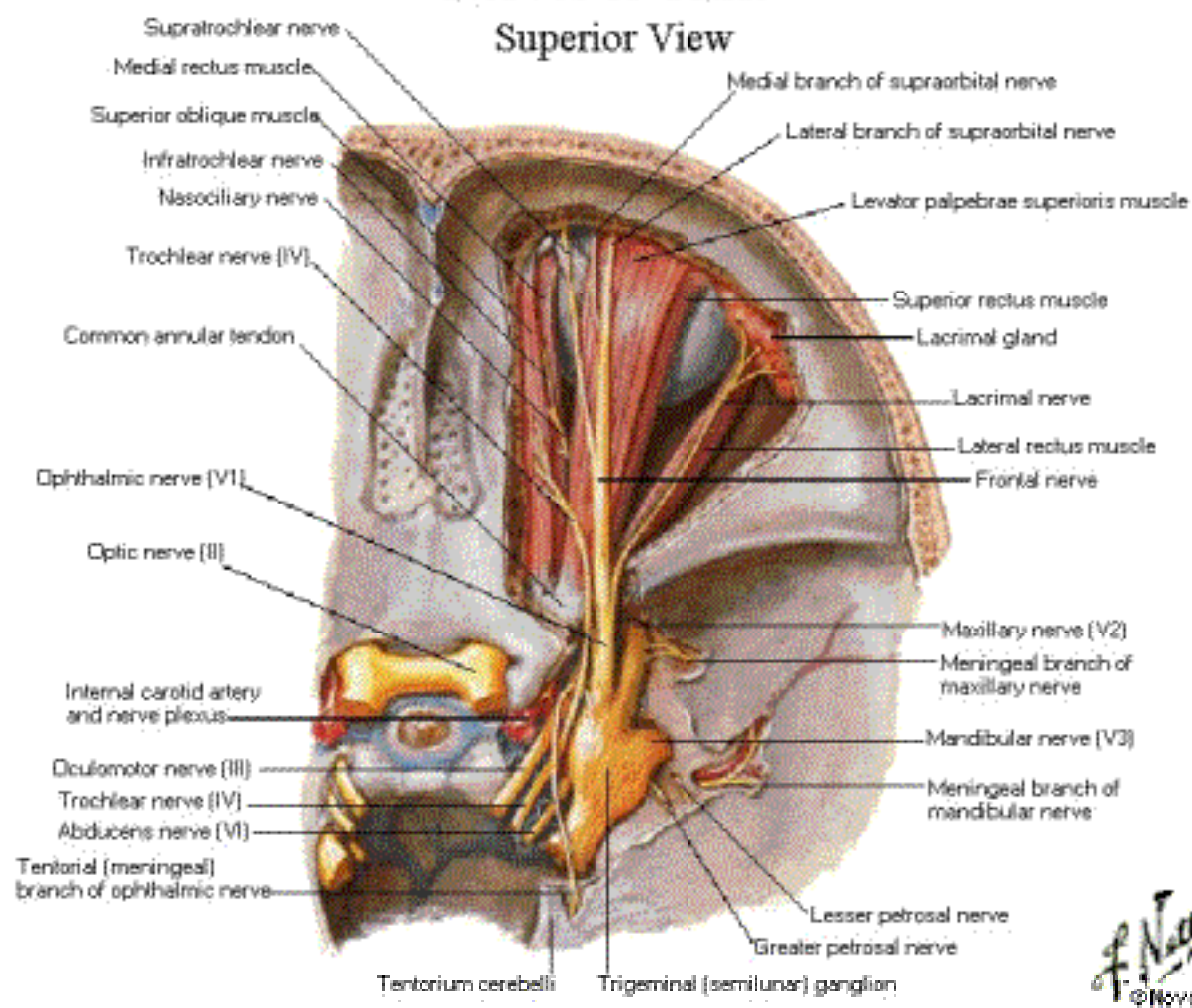
Arteries and Veins of Orbit and Eyelids

Lateral View



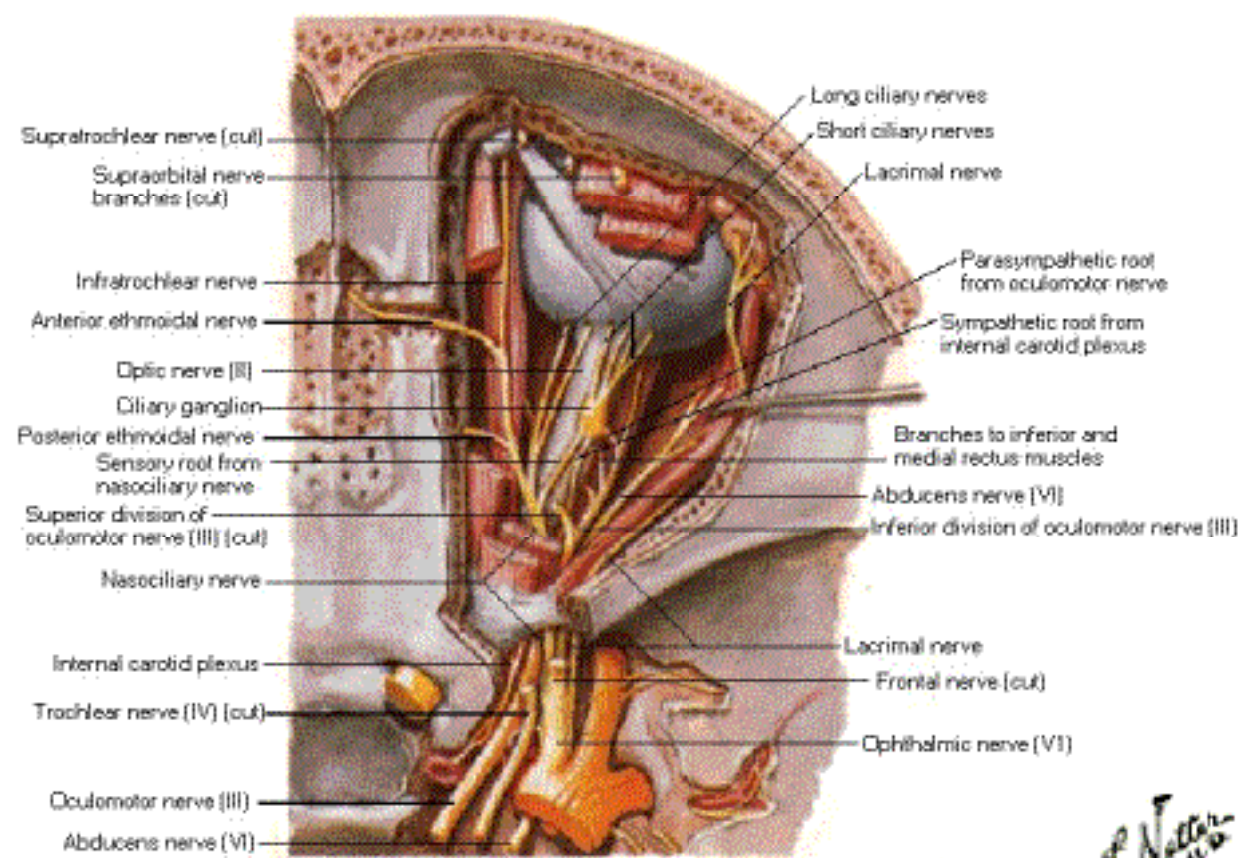
Nerves of Orbit

Superior View



Nerves of Orbit - Muscles Partially Cut Away

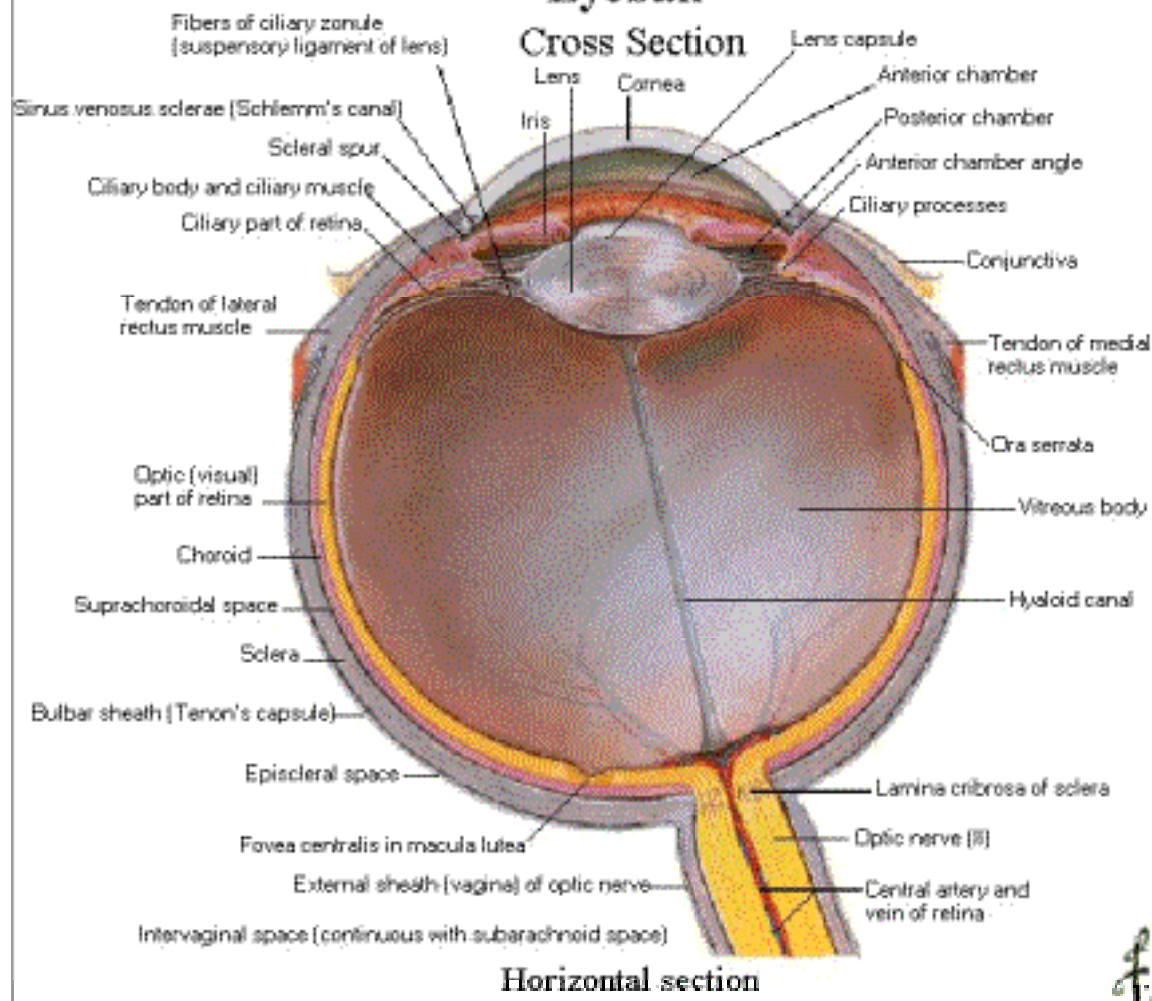
Superior View



F. Netter M.D.
© 1989

Eyeball

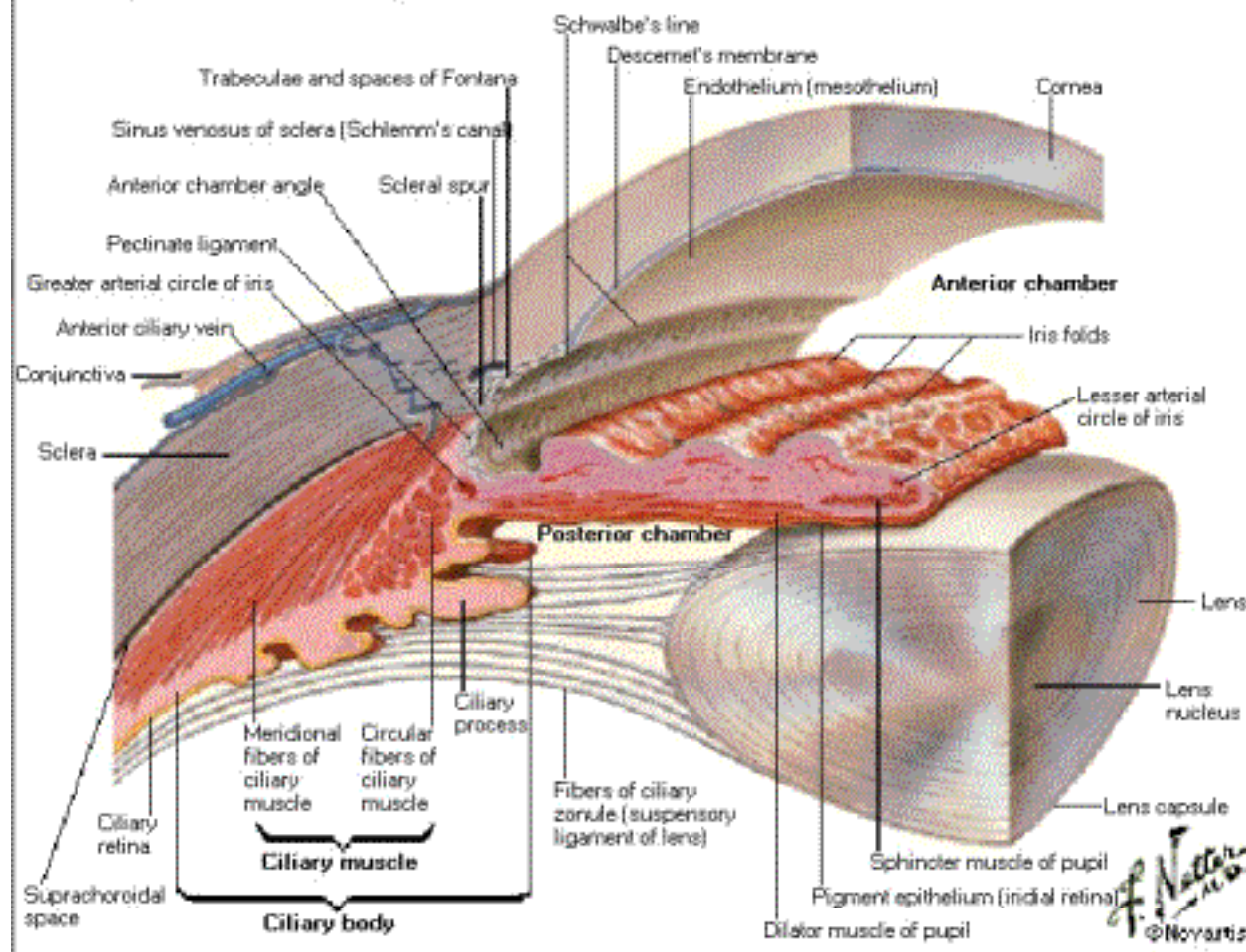
Cross Section



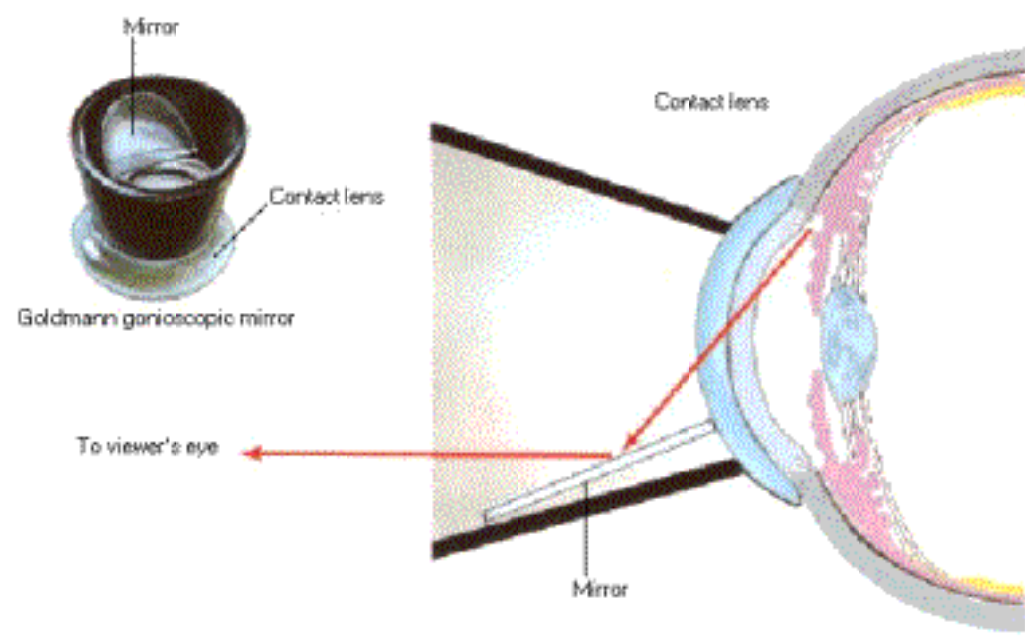
F. Natter
© Novartis

Anterior and Posterior Chambers of Eye

Note: for clarity only single plane of zonular fibers shown; actually fibers surround entire circumference of lens



Anterior Chamber Angle of Eye

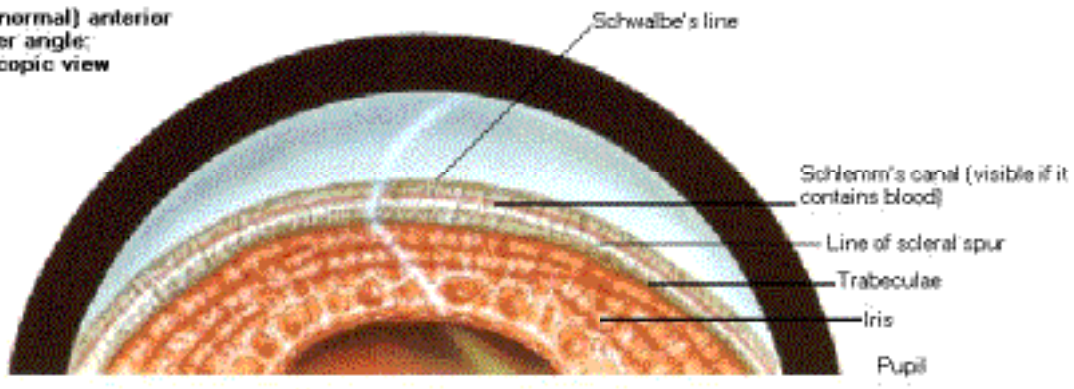


F. N. N. N.
© Novartis

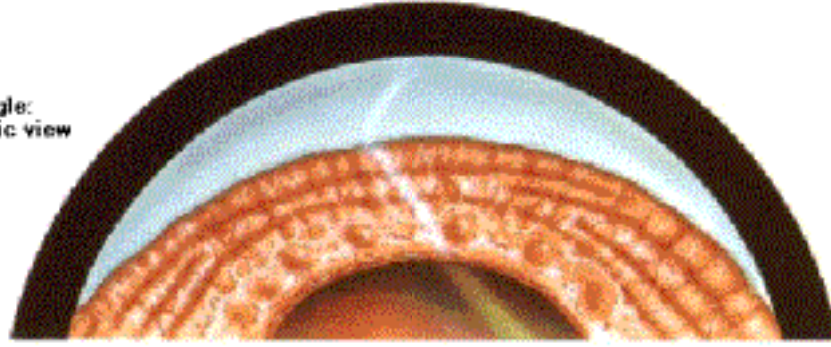
Anterior Chamber Angle of Eye

Gonioscopic Views

Open (normal) anterior chamber angle: gonioscopic view



Closed angle: gonioscopic view

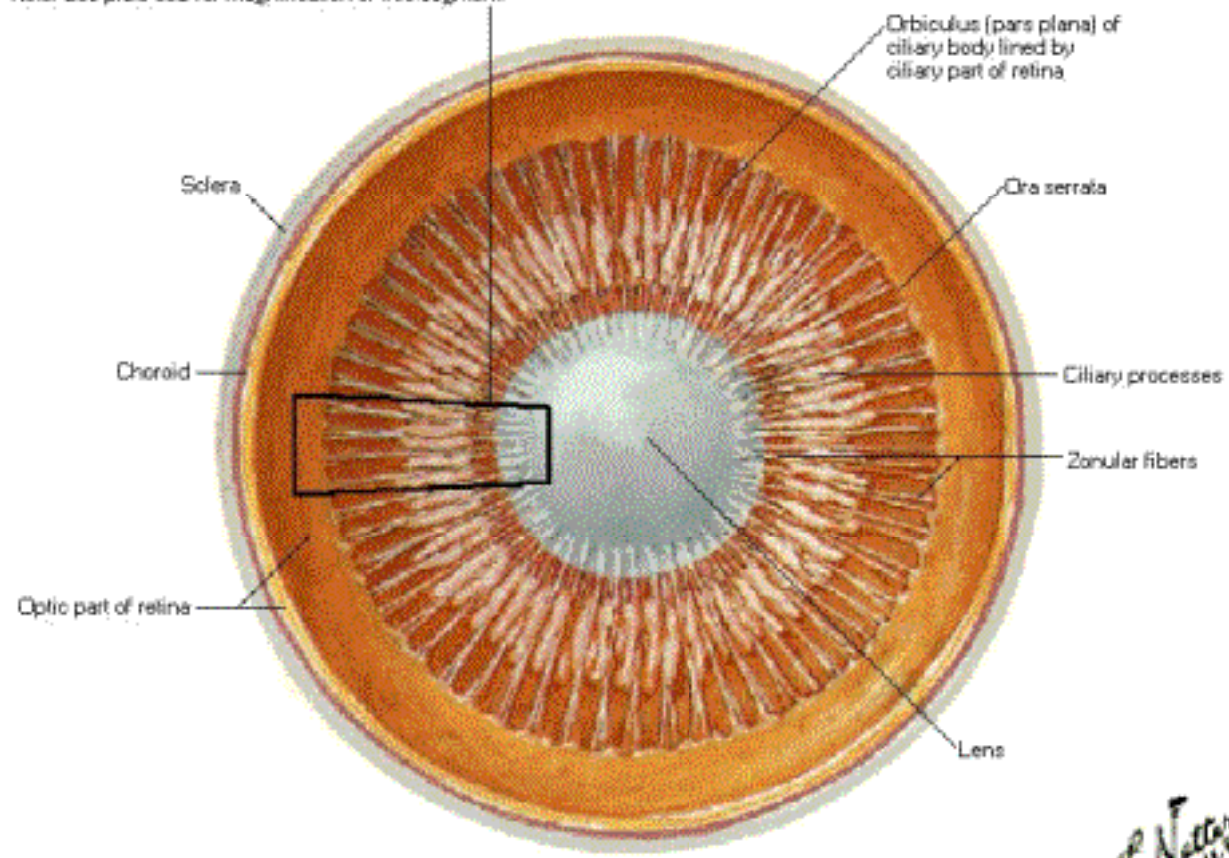


F. Natter
© Novartis

Lens and Supporting Structures

Section in Frontal Plane

Note: See plate 65C for magnification of this segment.

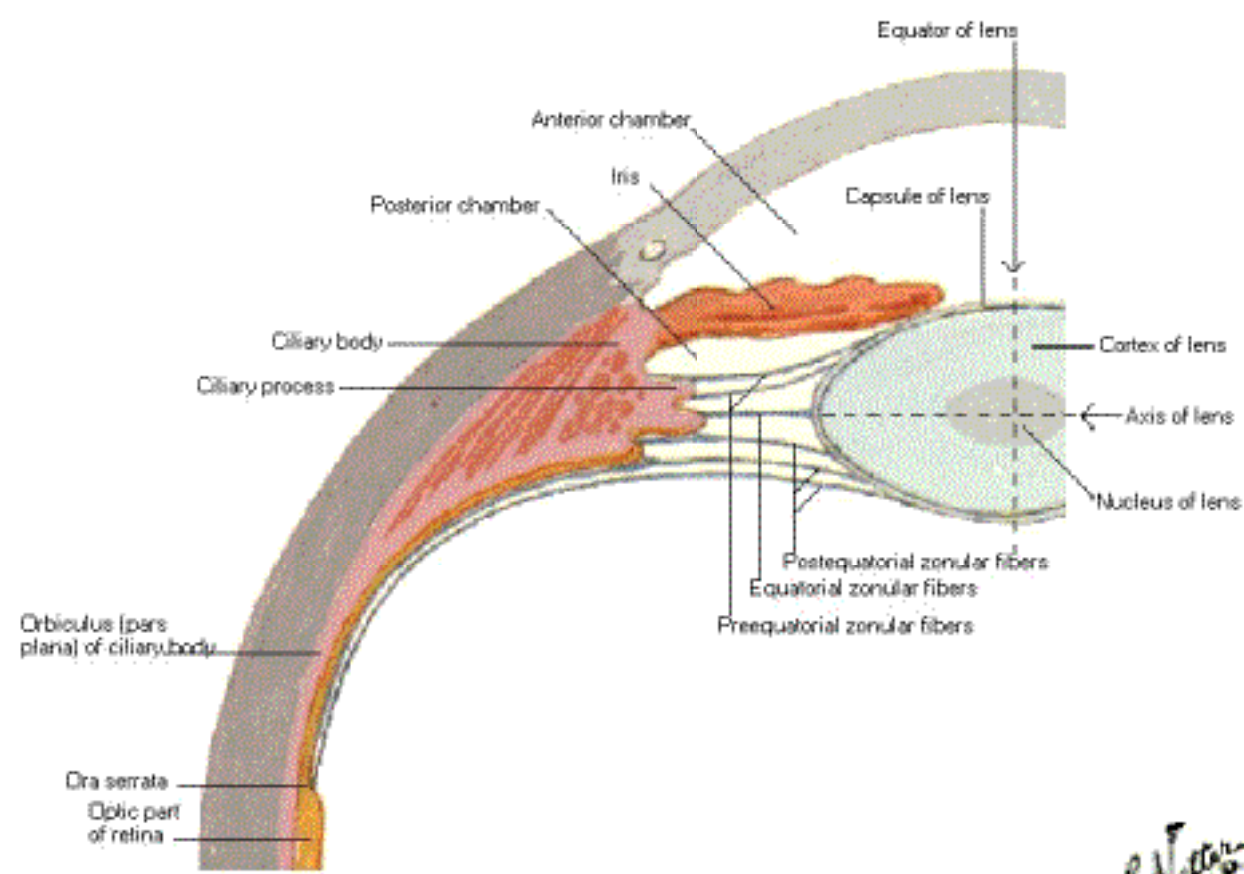


Bulb of eye: anterior segment viewed from behind

F. Netter M.D.
© Novartis

Lens and Supporting Structures

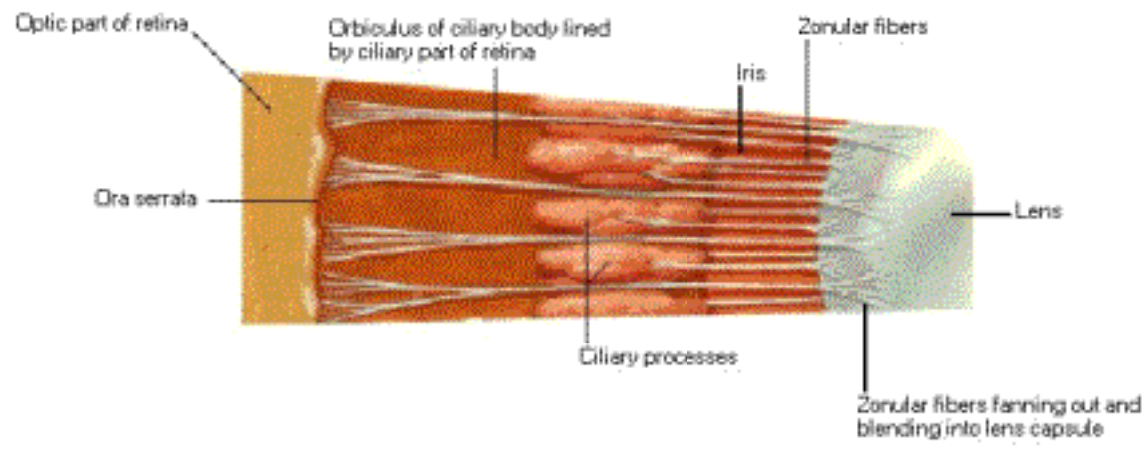
Horizontal Section



F. Netter
© 1996

Lens and Supporting Structures

Segment Outlined in Plate 85A

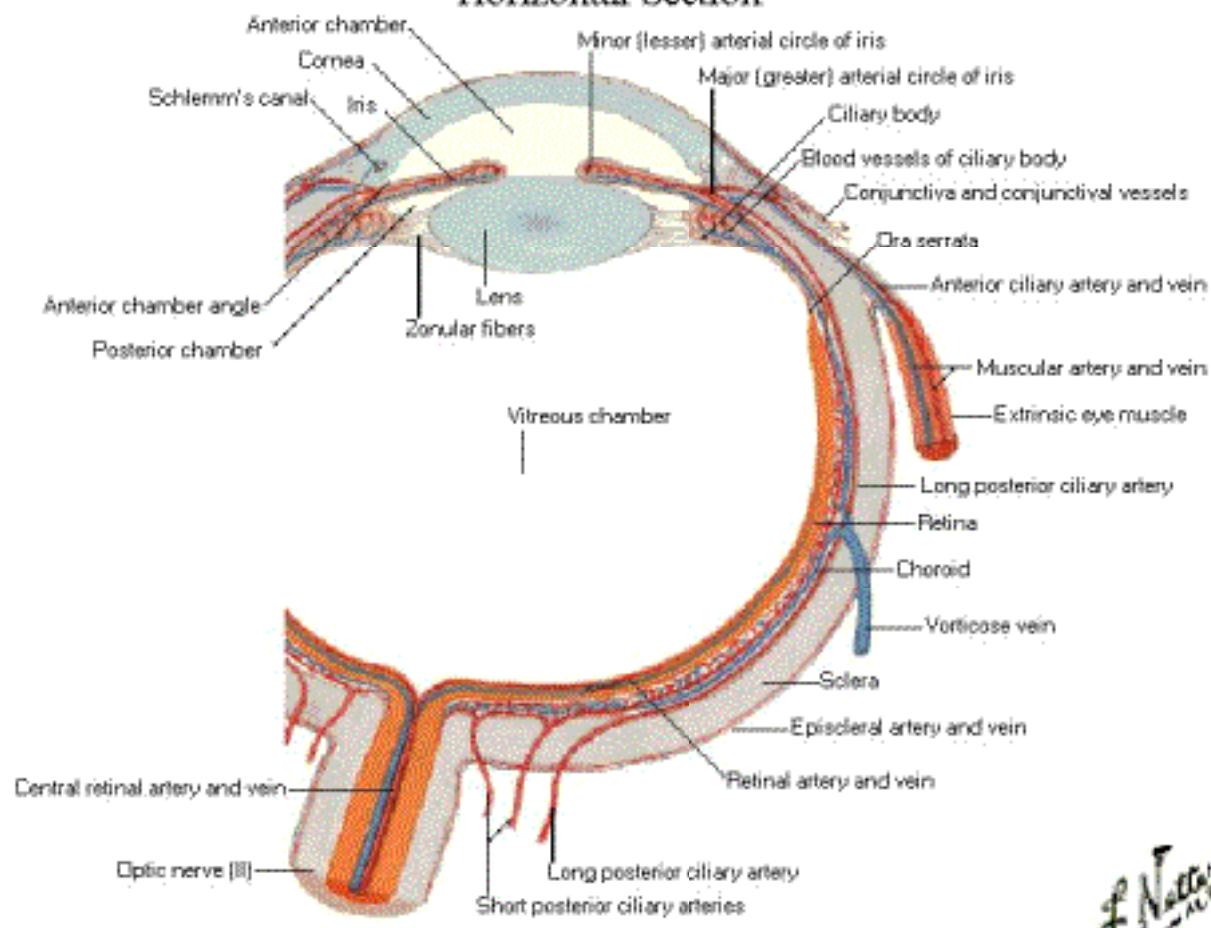


Magnified to ultramicroscopic scale (semischematic)



Intrinsic Arteries and Veins of Eye

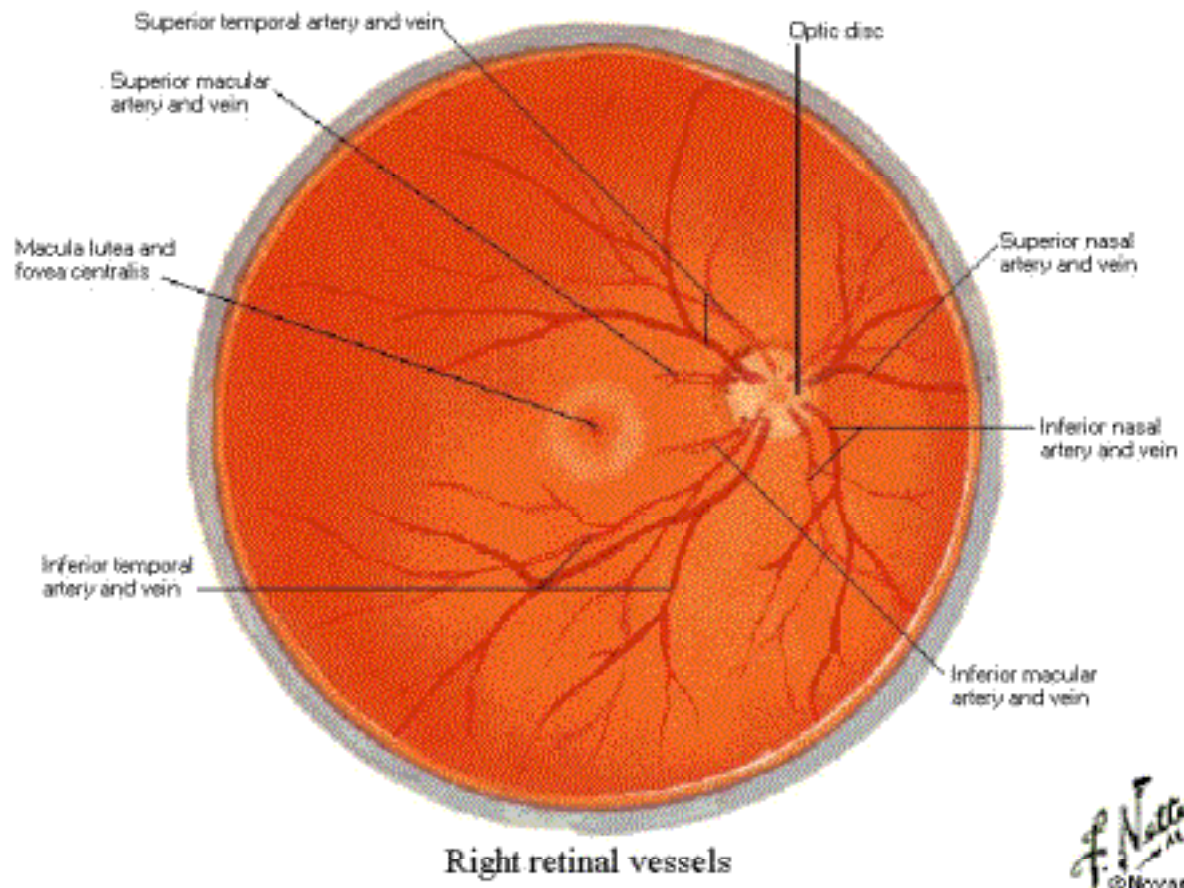
Horizontal Section



F. Netter
© Novartis

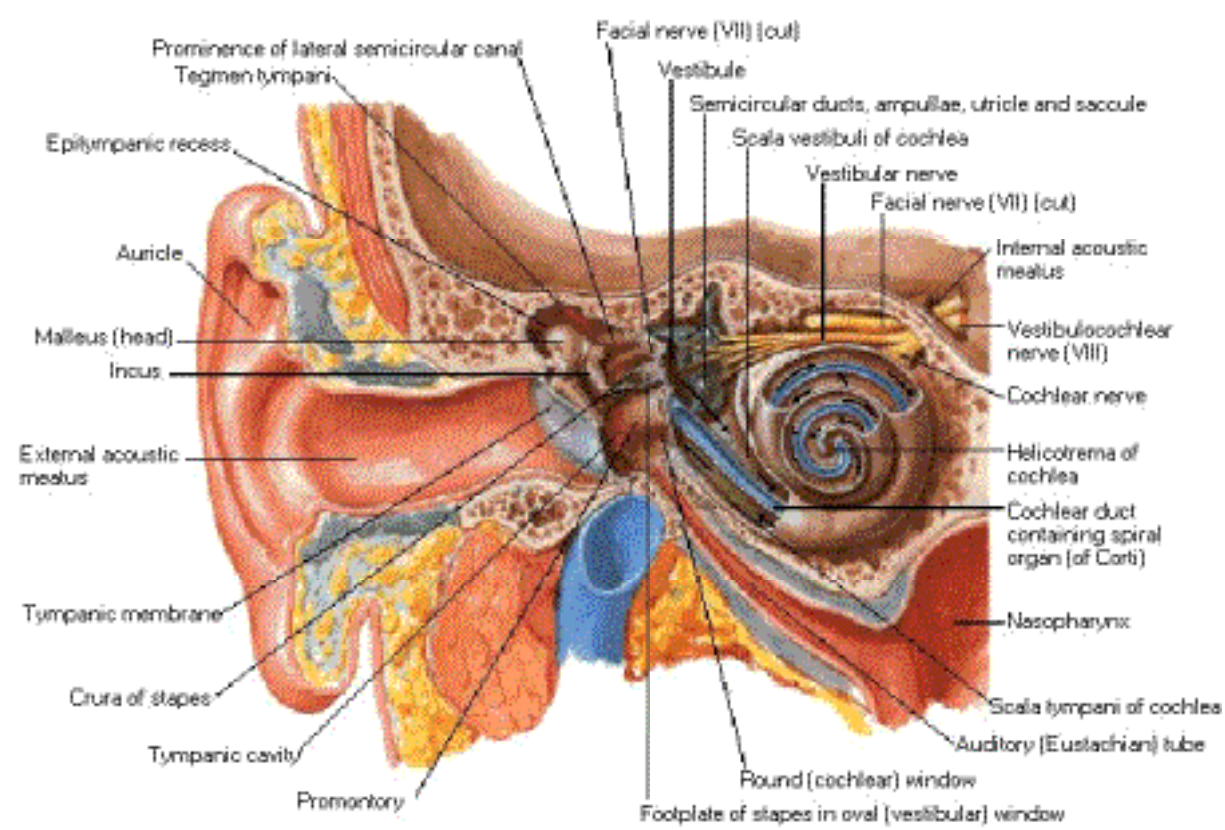
Intrinsic Arteries and Veins of Eye

Ophthalmoscopic View



F. Netter M.D.
© Novartis

Pathway of Sound Reception



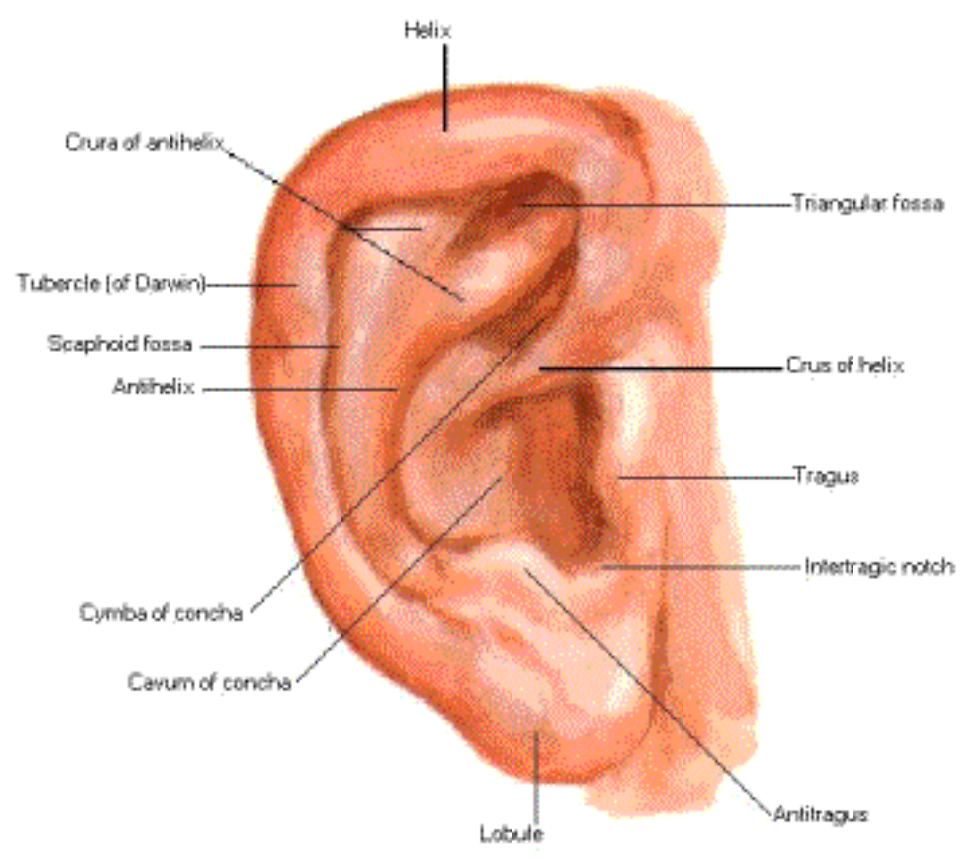
Note: arrows indicate course of sound waves.

Schematic frontal section

F. Netter M.D.
© 1996

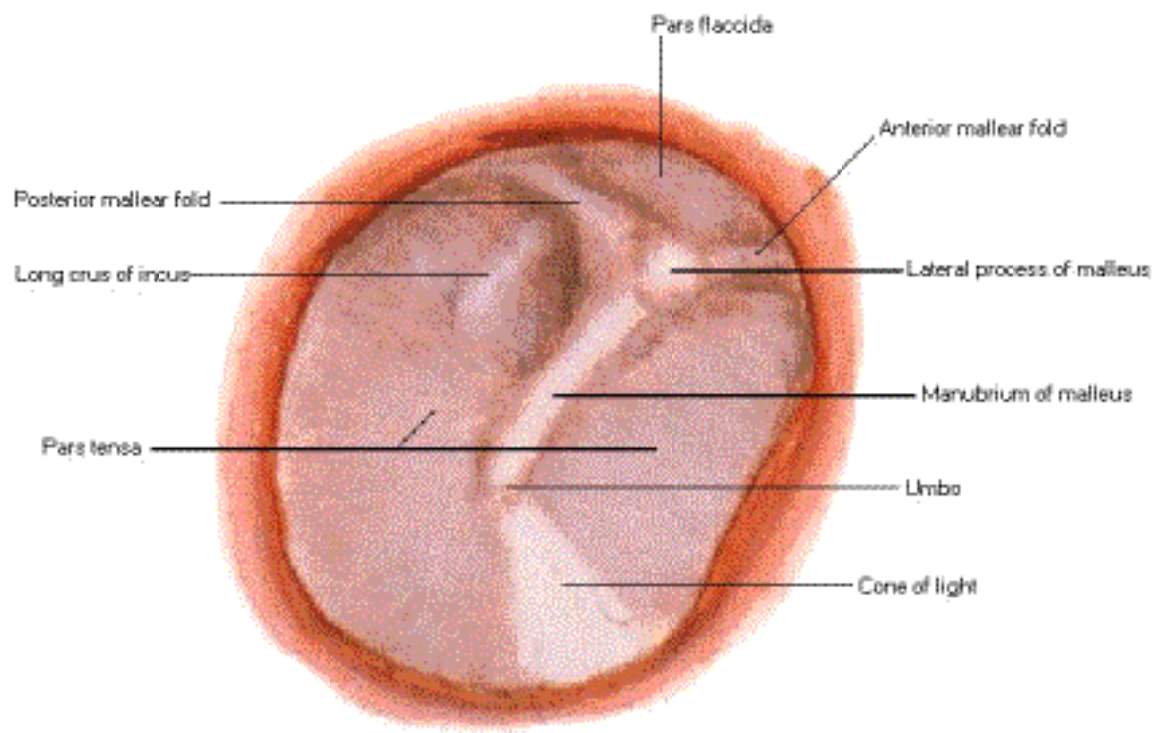
External Ear

Right Auricle



F. Netter M.D.
© Novartis

External Ear
Right Tympanic Membrane

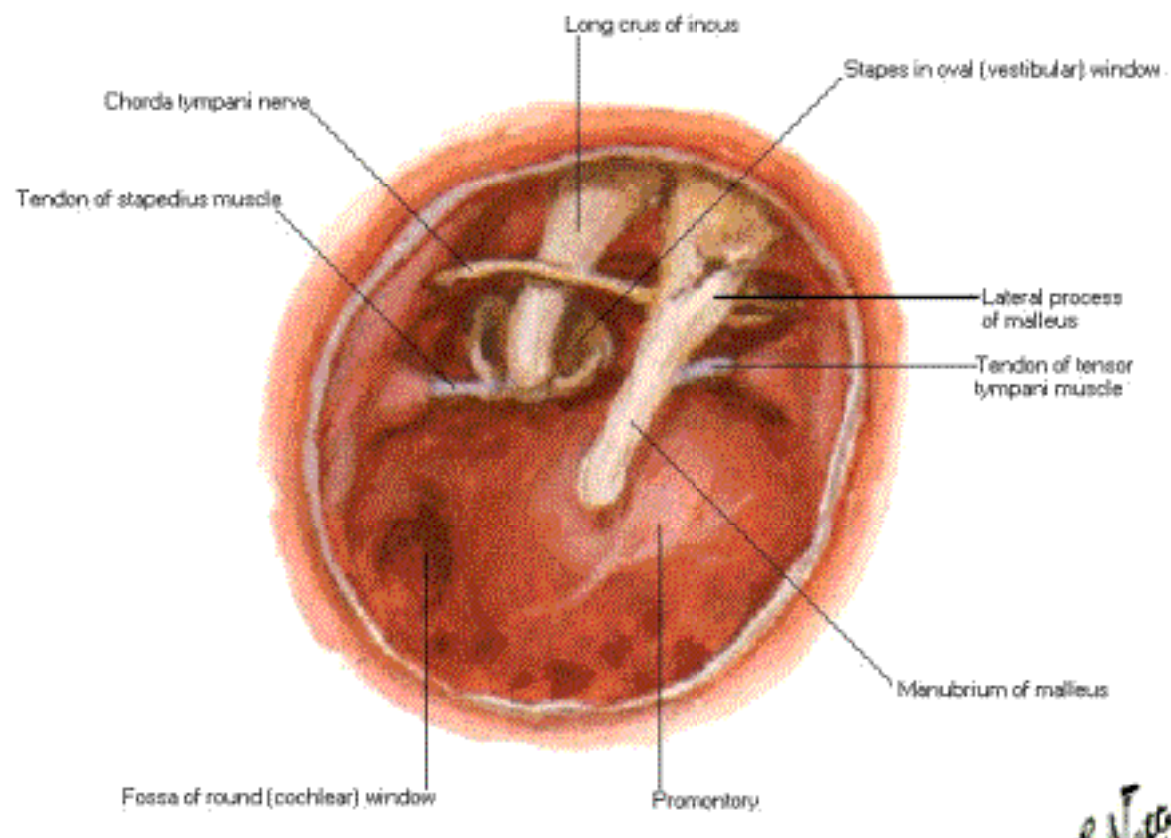


Viewed through speculum



Tympanic Cavity

Viewed from External Acoustic Meatus

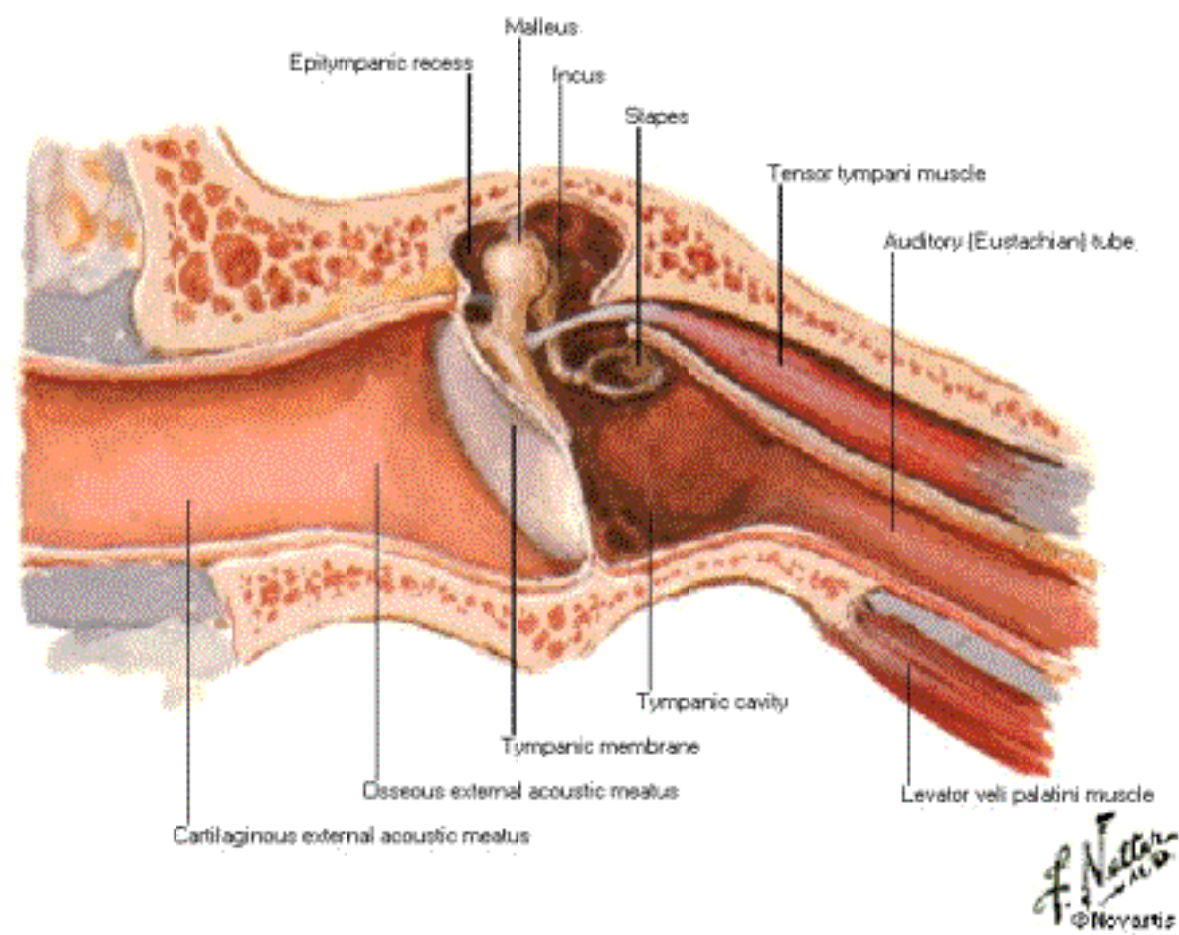


Tympanic Membrane Removed



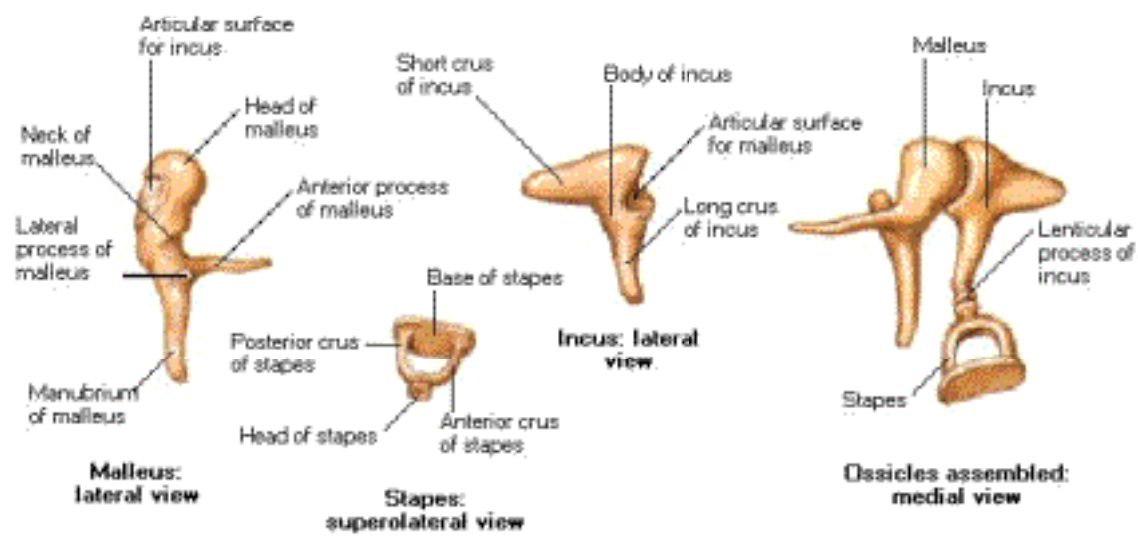
External Ear and Tympanic Cavity

Coronal Oblique Section



Tympanic Cavity

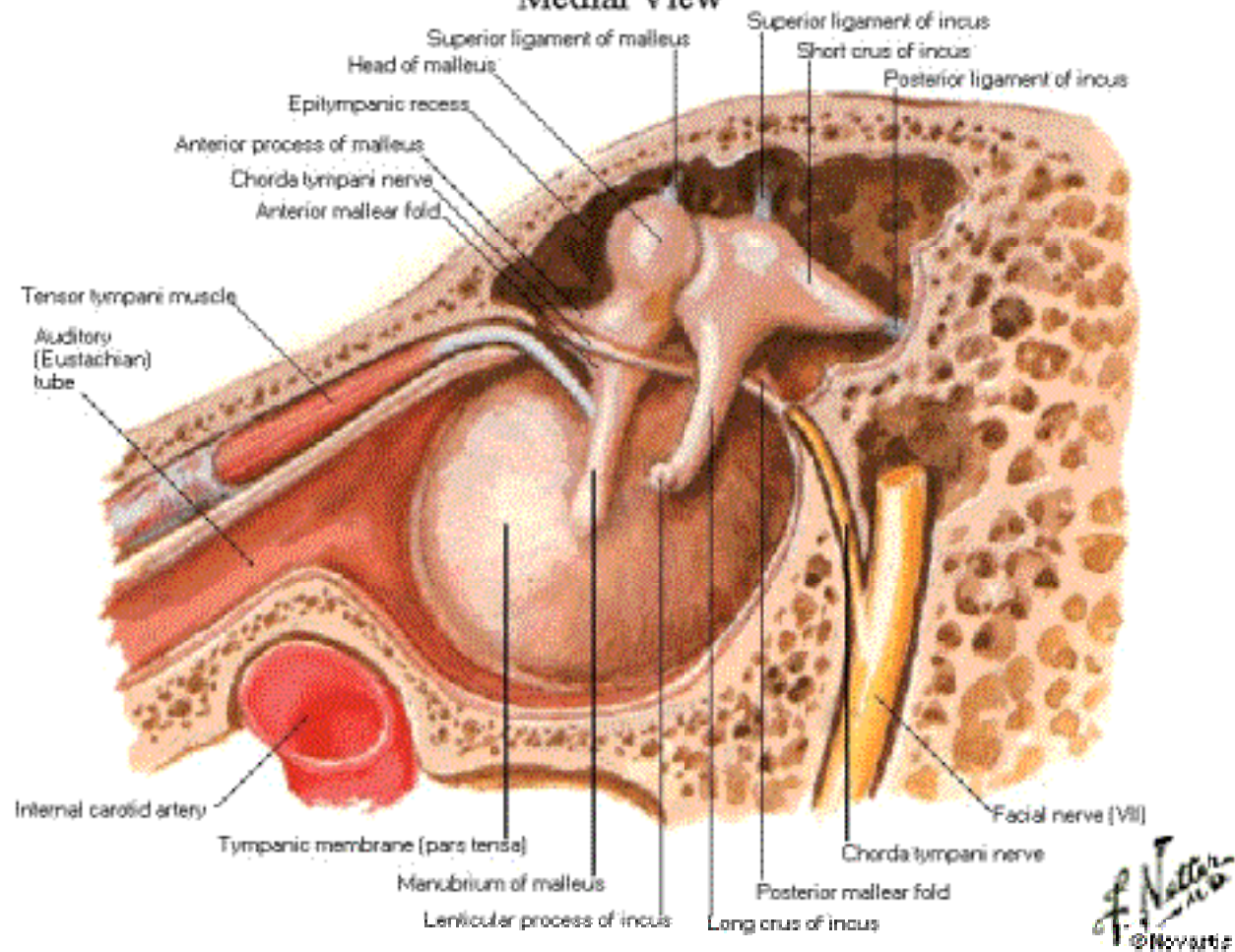
Auditory Ossicles



F. Netter M.D.
© Novartis

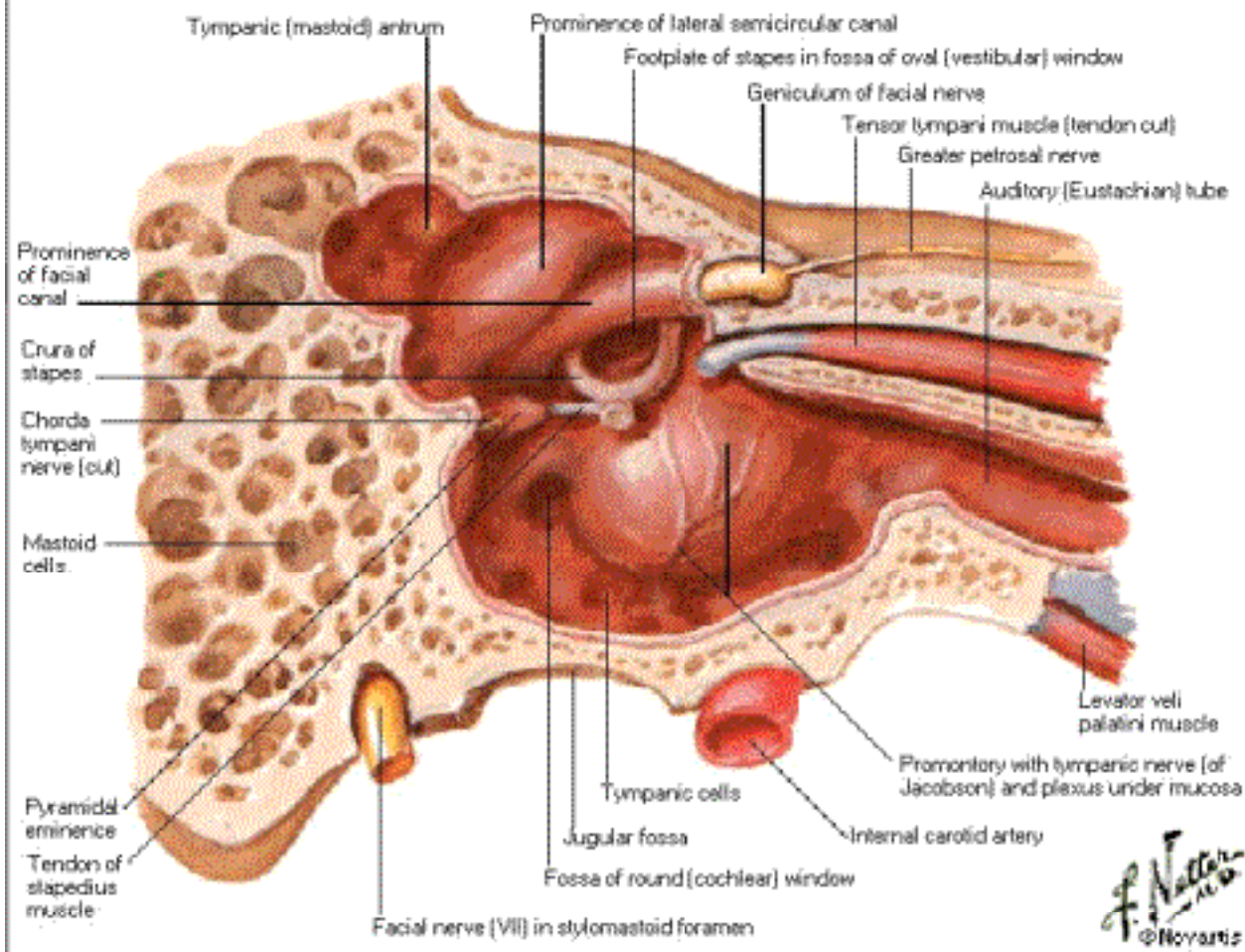
Tympanic Cavity - Lateral Wall

Medial View



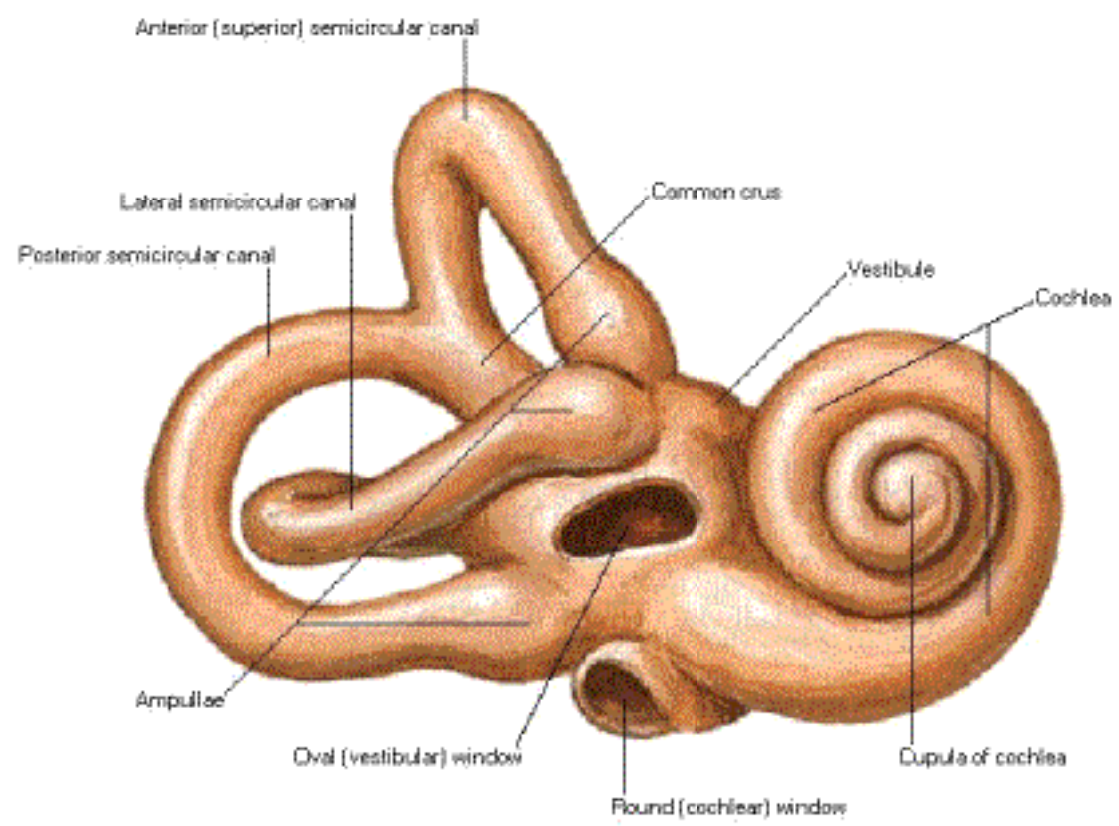
Tympanic Cavity - Medial Wall

Lateral View



Right Osseous Labyrinth

Anterolateral View

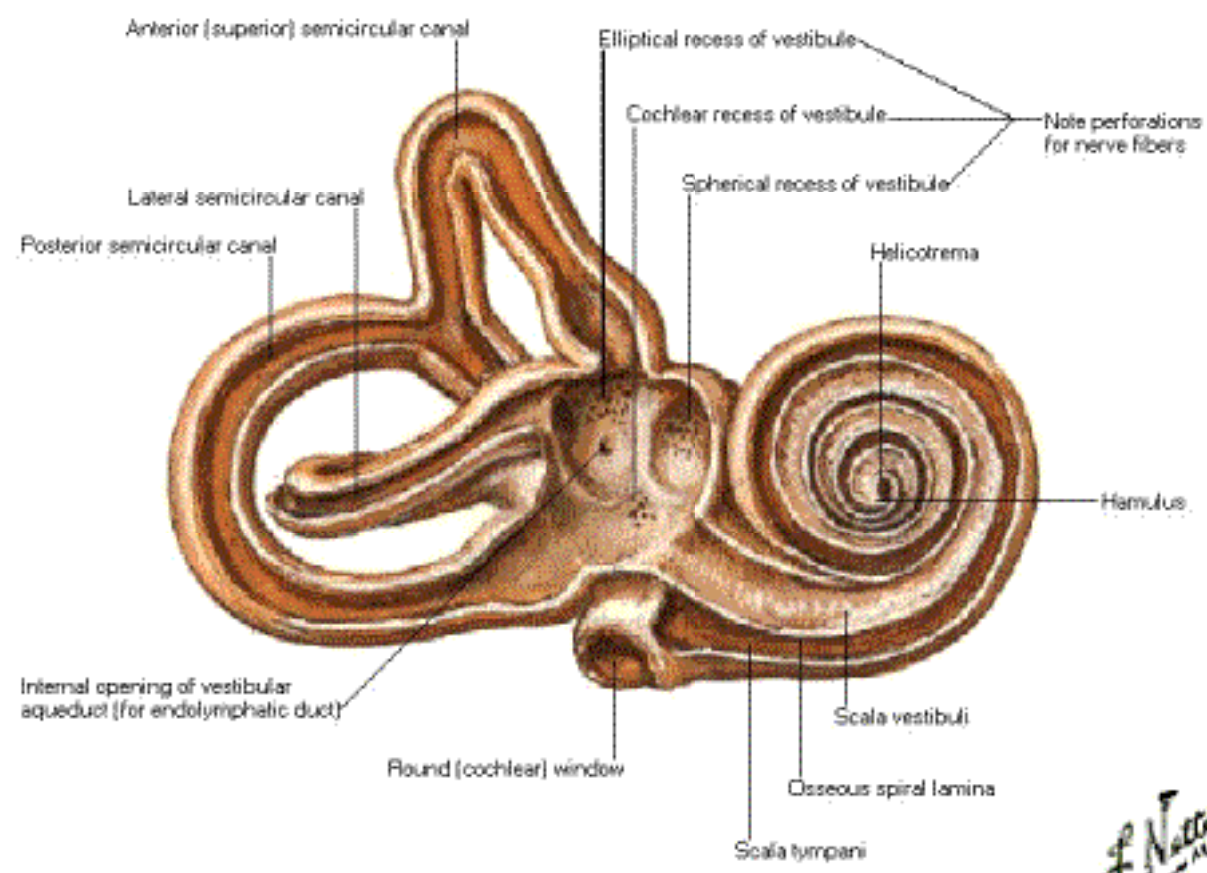


Surrounding cancellous bone removed

F. Netter M.D.
© 1996

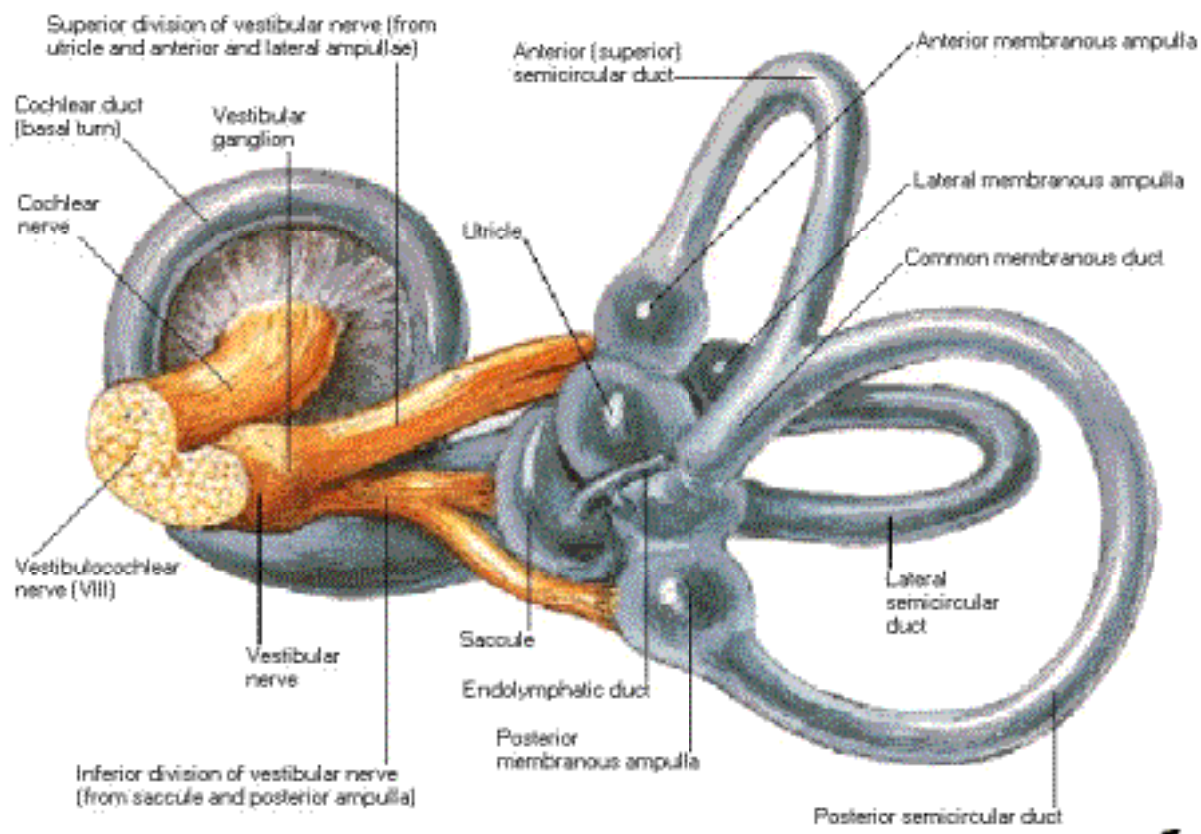
Right Osseous Labyrinth - Dissected

Membranous Labyrinth Removed



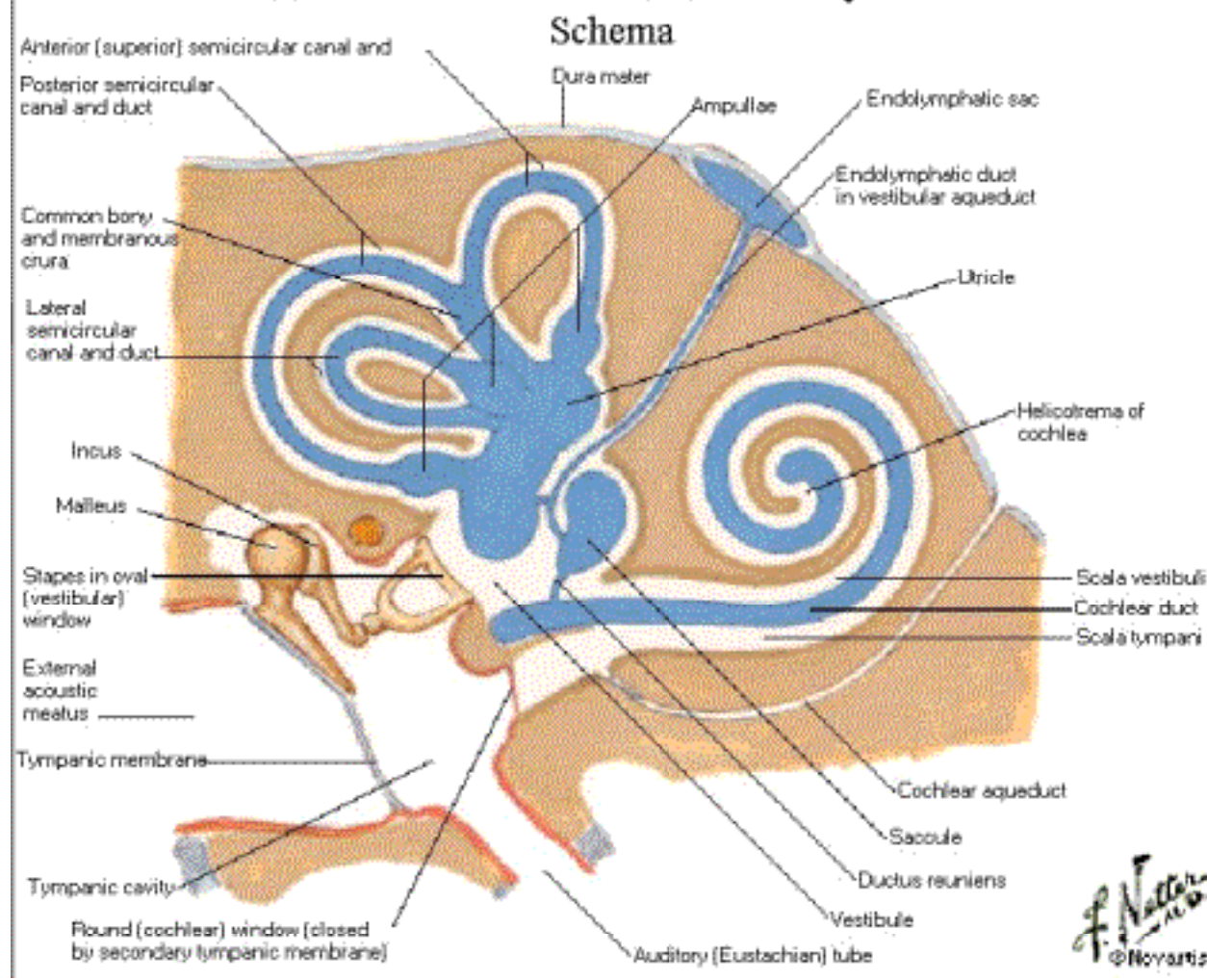
Right Membranous Labyrinth with Nerves

Posteromedial View



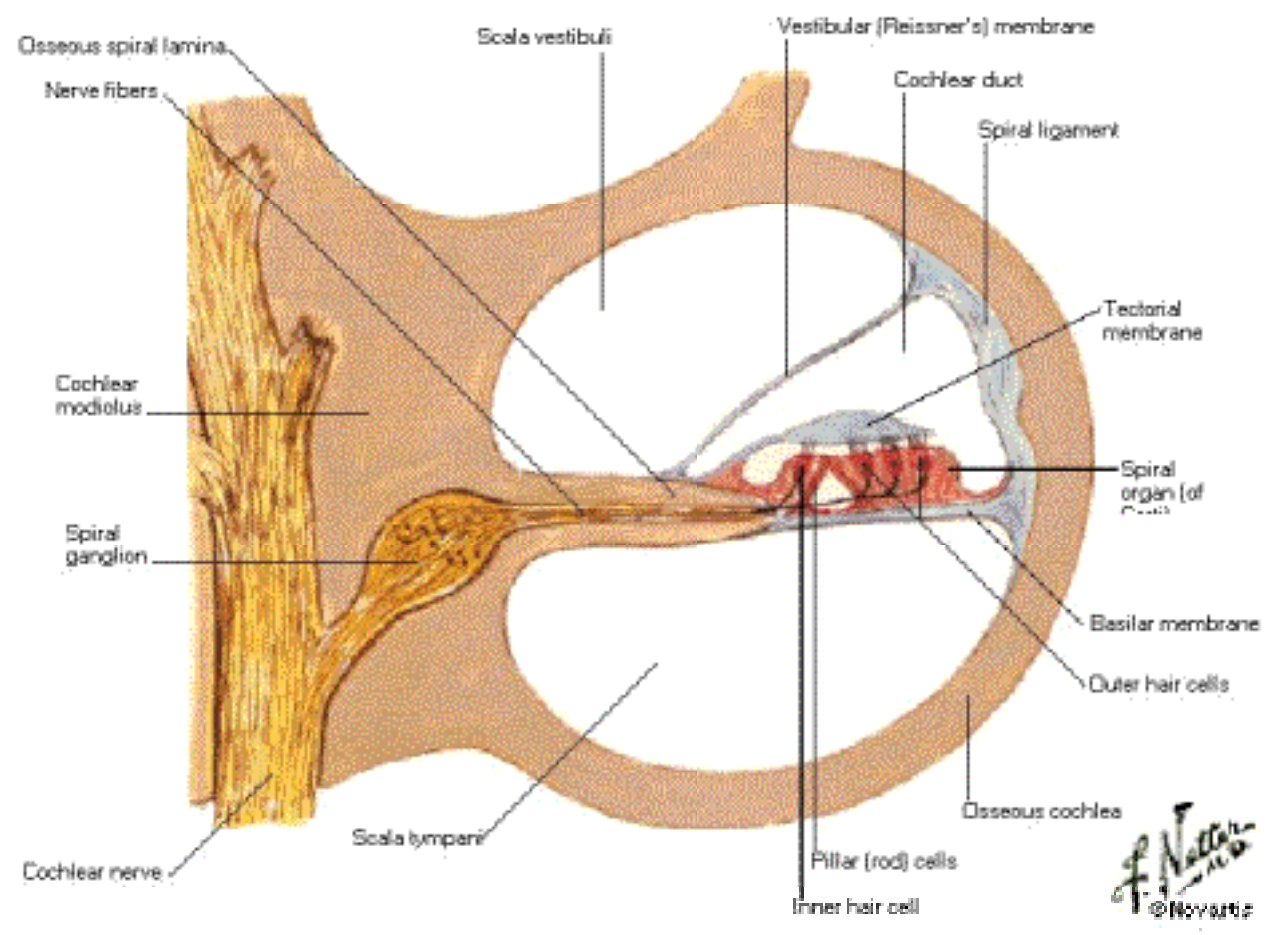
F. Netter
M.D.
© Novartis

Osseous and Membranous Labyrinths



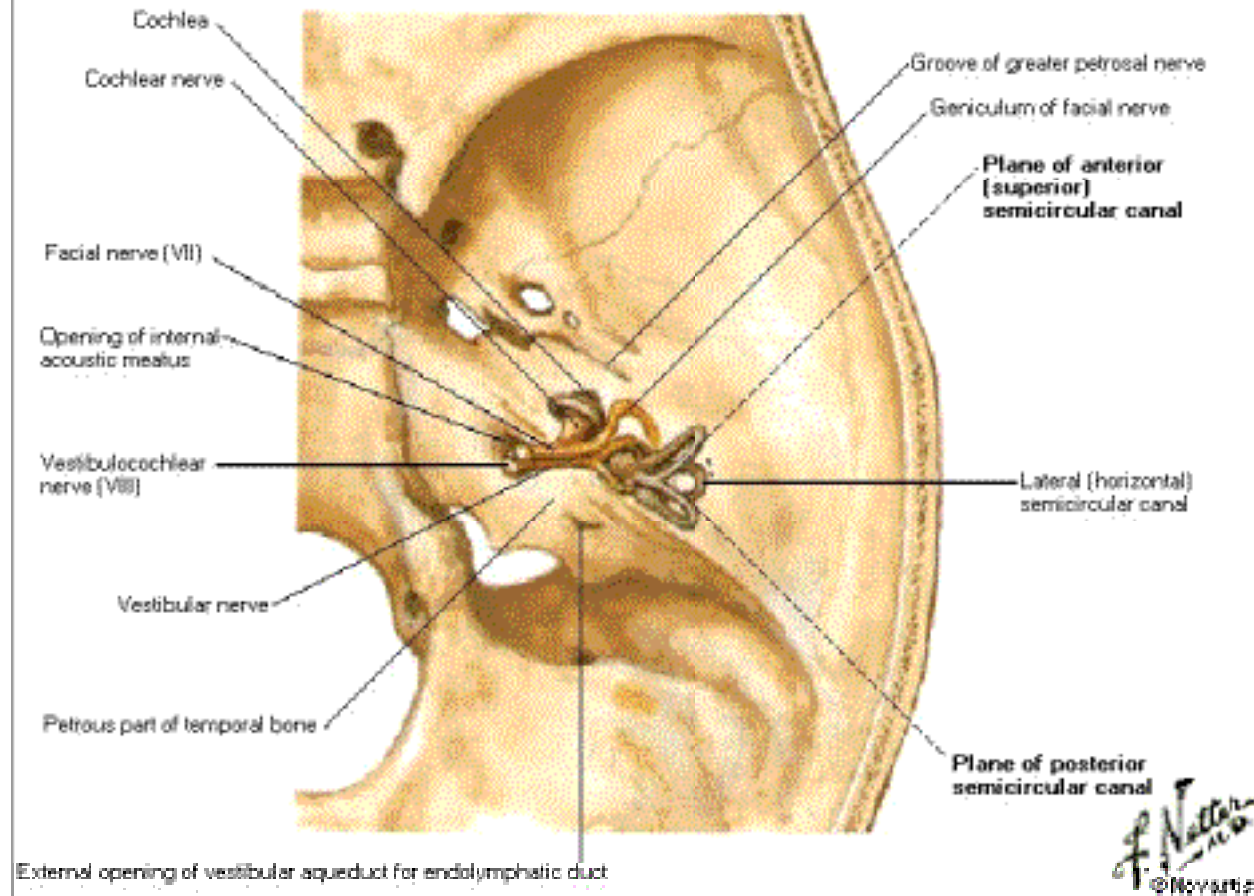
Osseous and Membranous Labyrinths

Section Through Turn of Cochlea



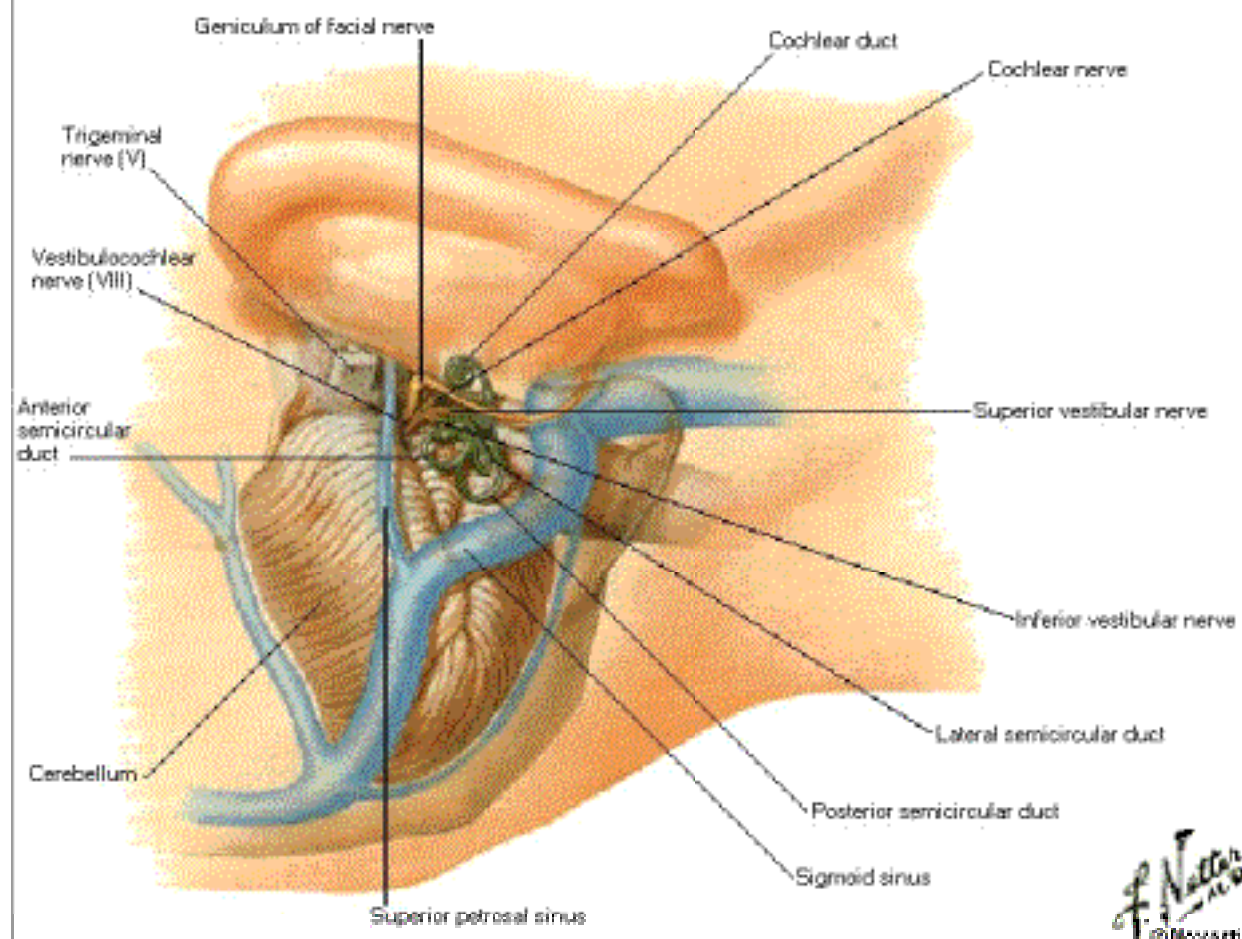
Orientation of Labyrinth in Skull

Superior Projection



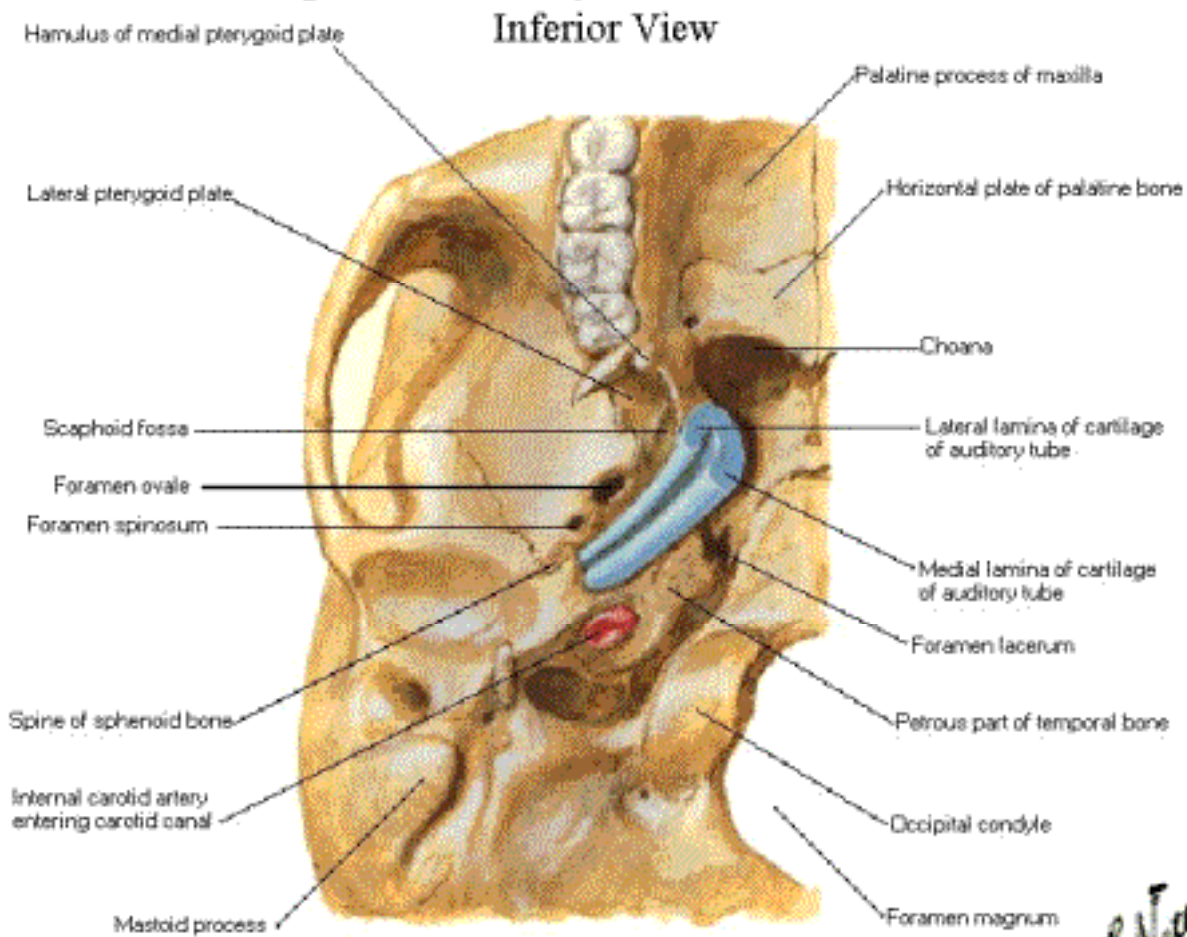
Orientation of Labyrinth in Skull

Lateral Projection



Cartilage of Auditory Tube at Base of Skull

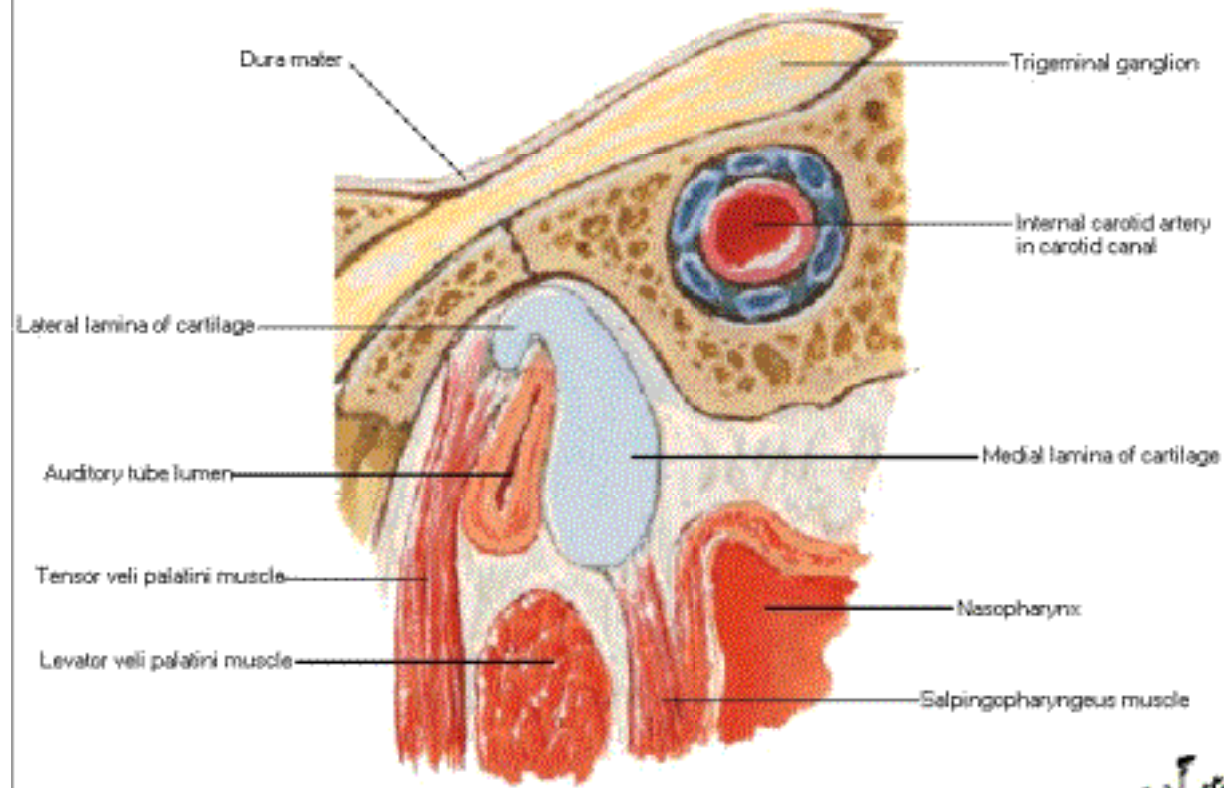
Inferior View



F. Netter
M.D.
© 1989

Auditory Tube - Section through Cartilage

Tube Closed

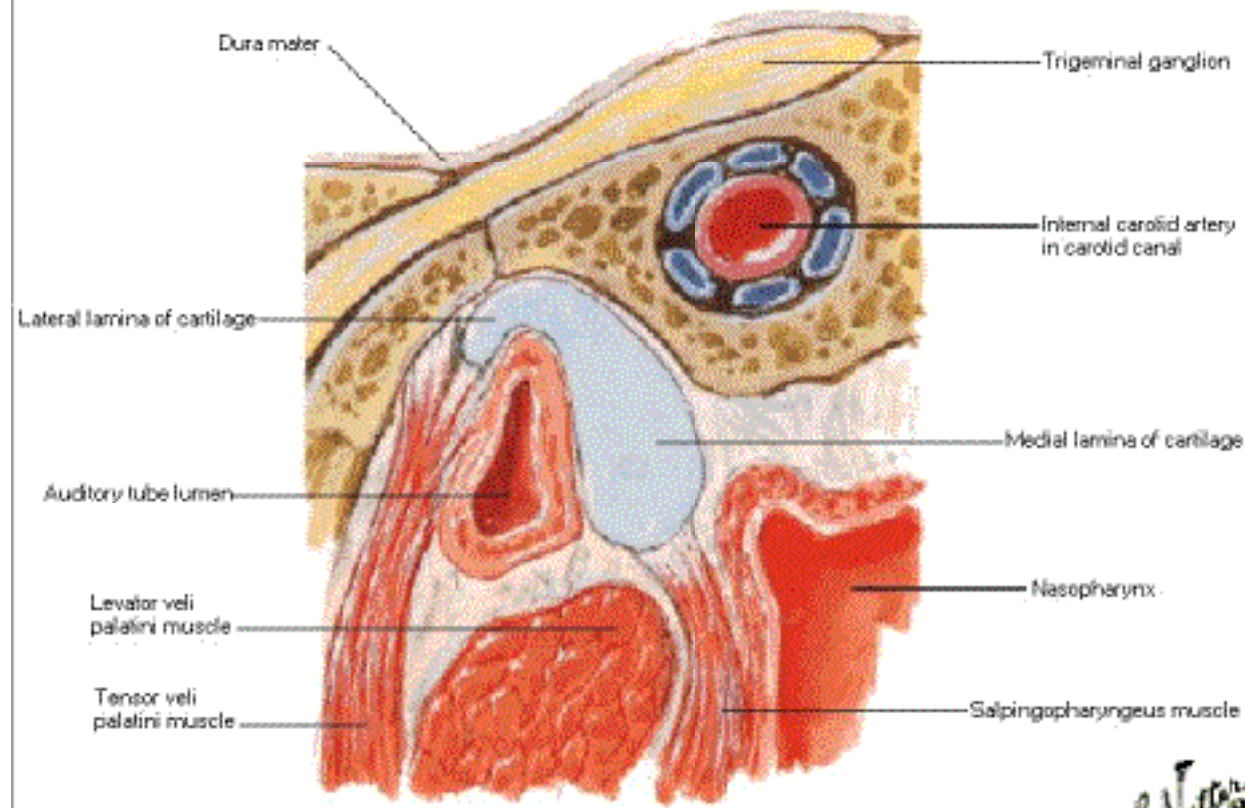


Auditory tube closed by elastic recoil of cartilage, tissue turgidity and tension of salpingopharyngeus muscles

F. Netter M.D.
© Novartis

Auditory Tube - Section through Cartilage

Tube Open

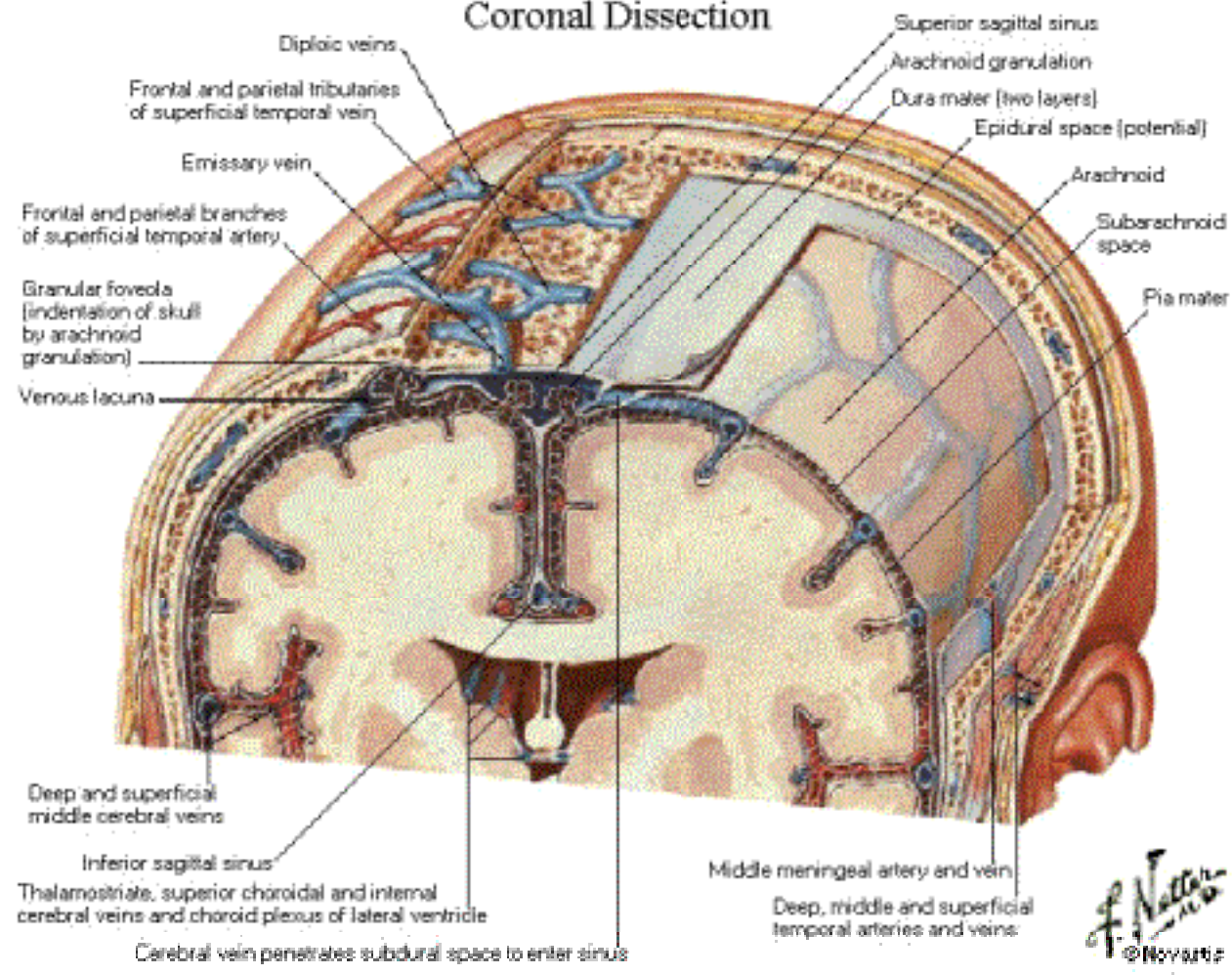


Lumen opened chiefly when attachment of tensor veli palatini muscle pulls wall of tube laterally during swallowing

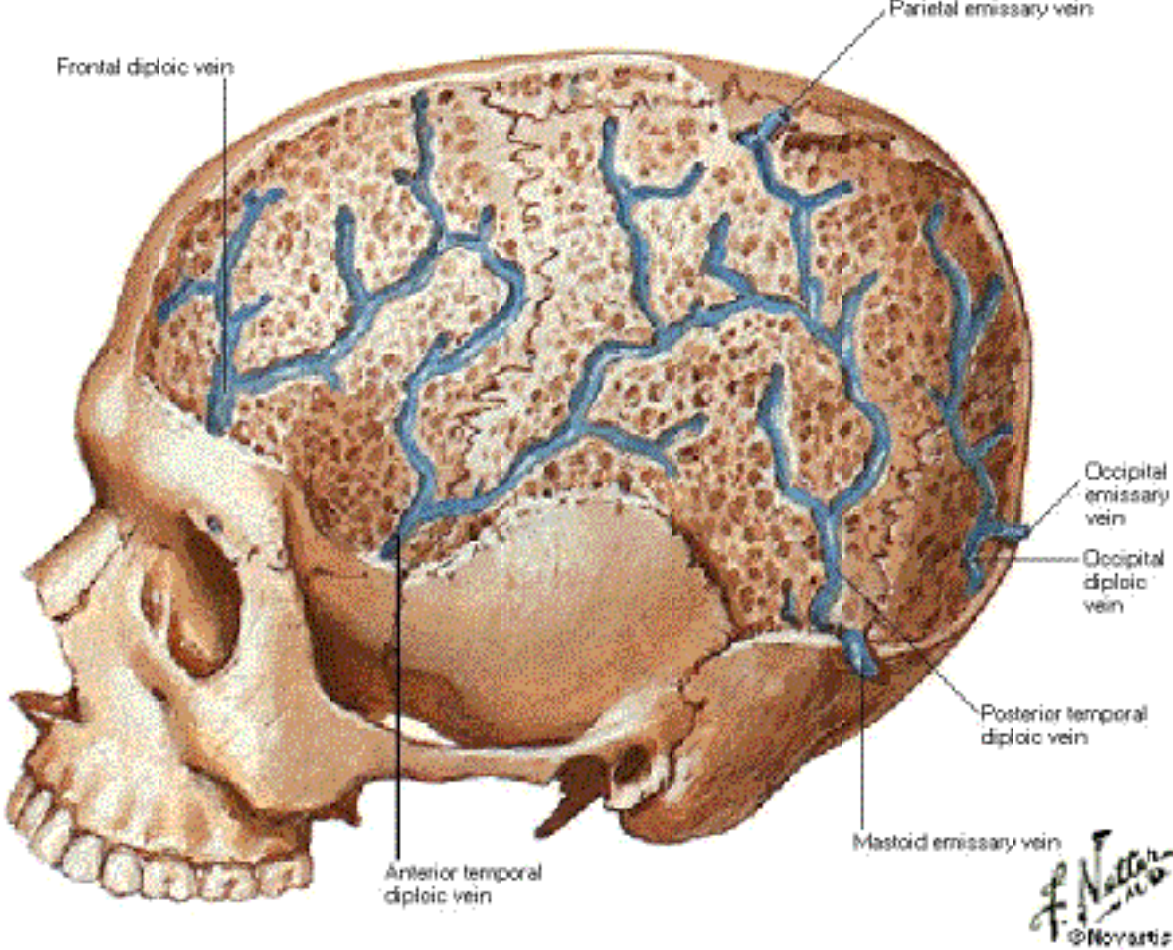
F. Netter M.D.
© 1994

Meninges and Diploic Veins

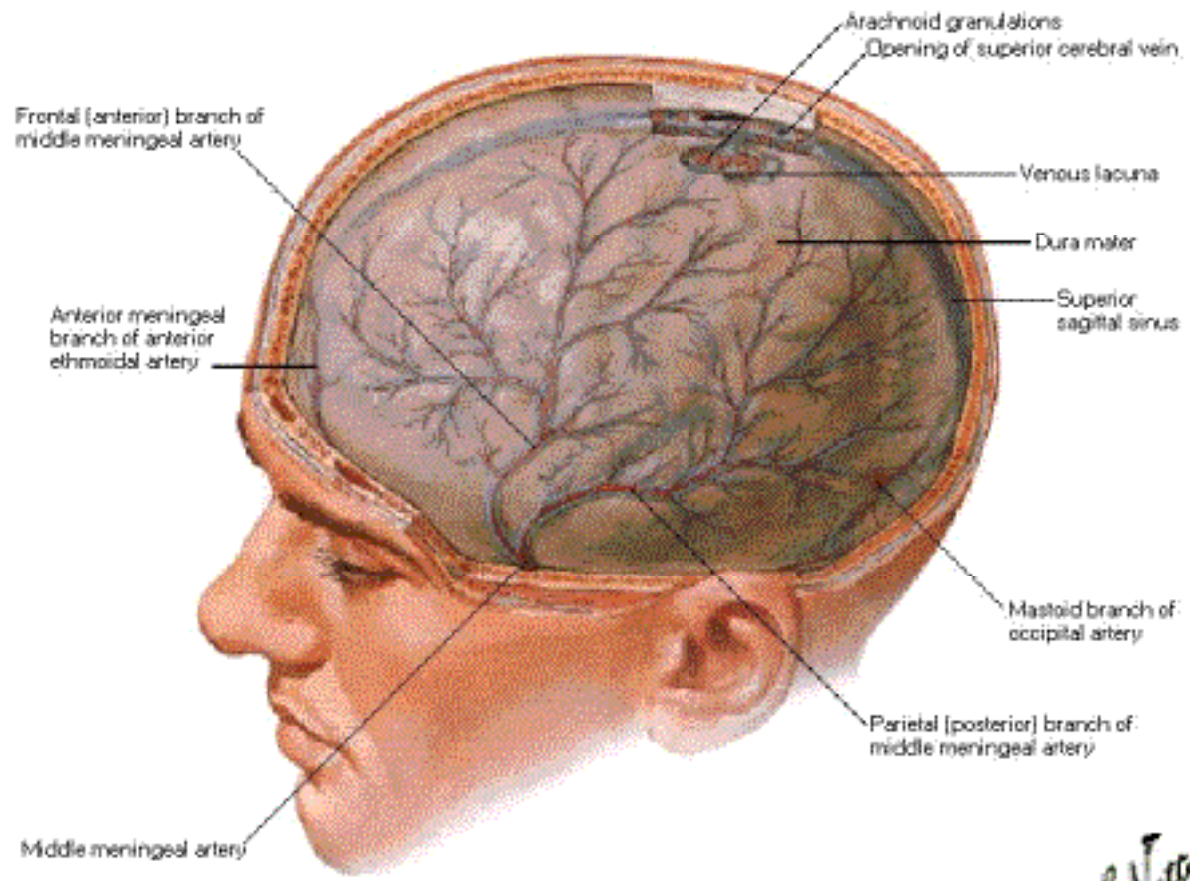
Coronal Dissection



Diploic and Emissary Veins of Skull

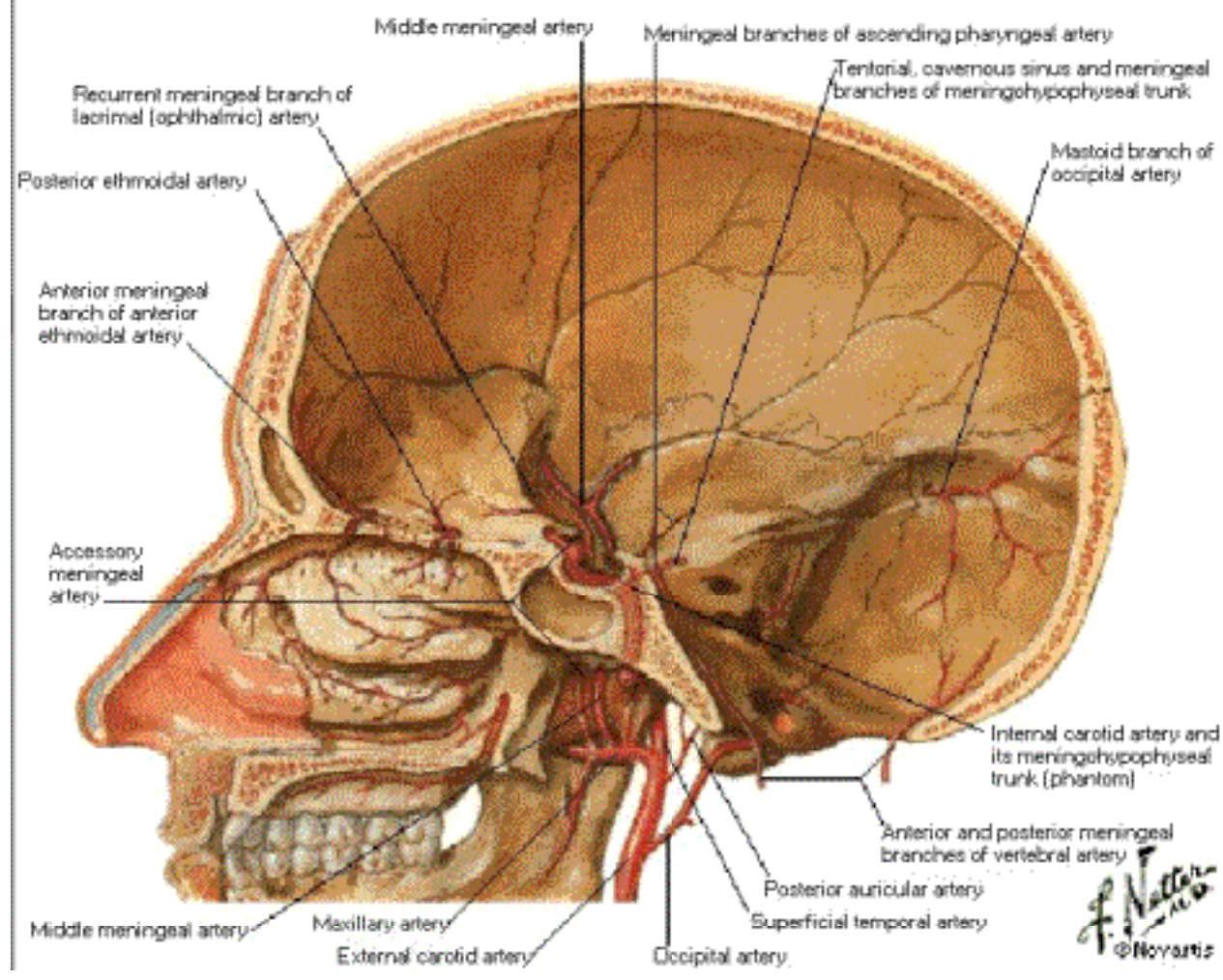


Meningeal Arteries



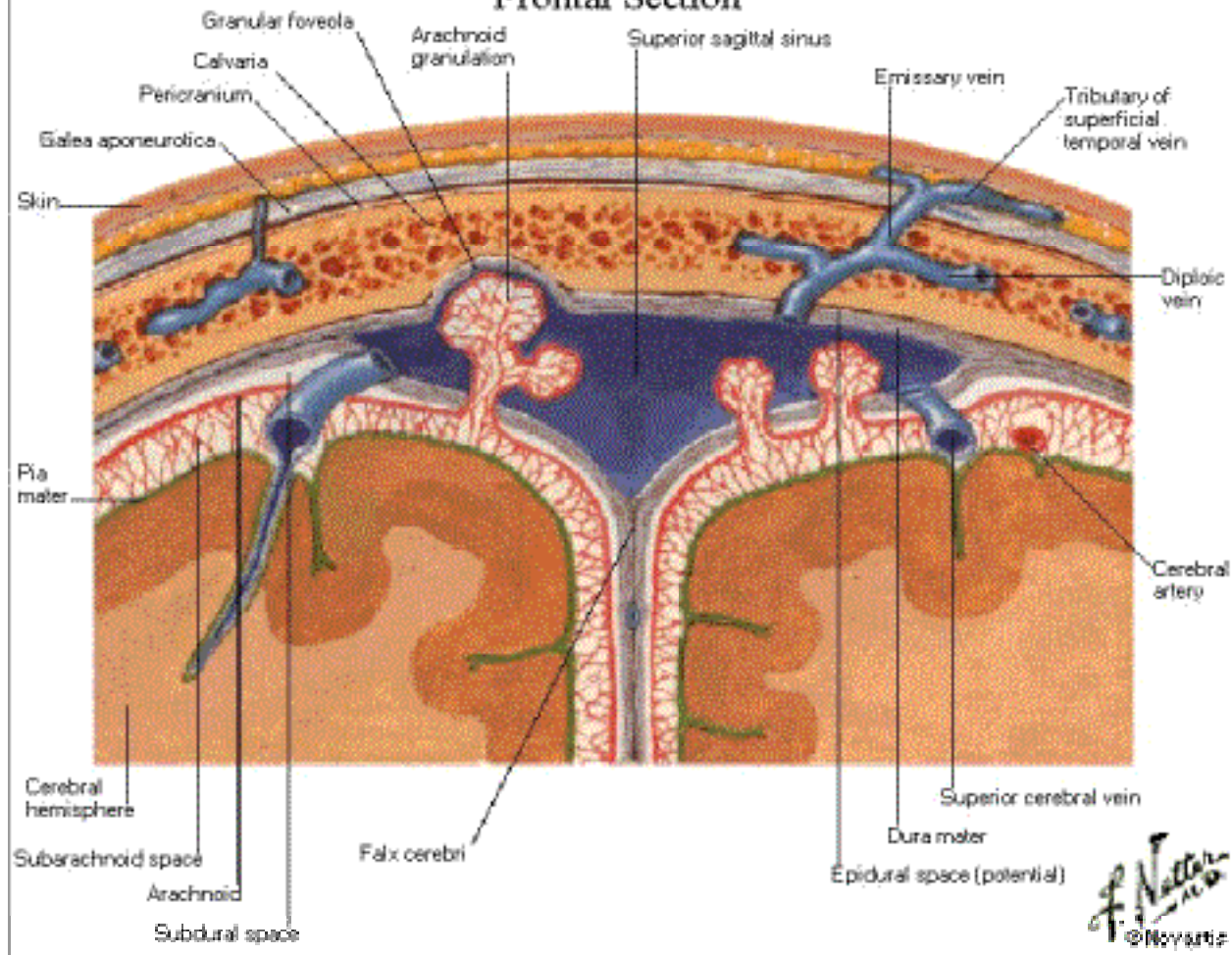
F. Netter M.D.
© Novartis

Meningeal Arteries [Continued]



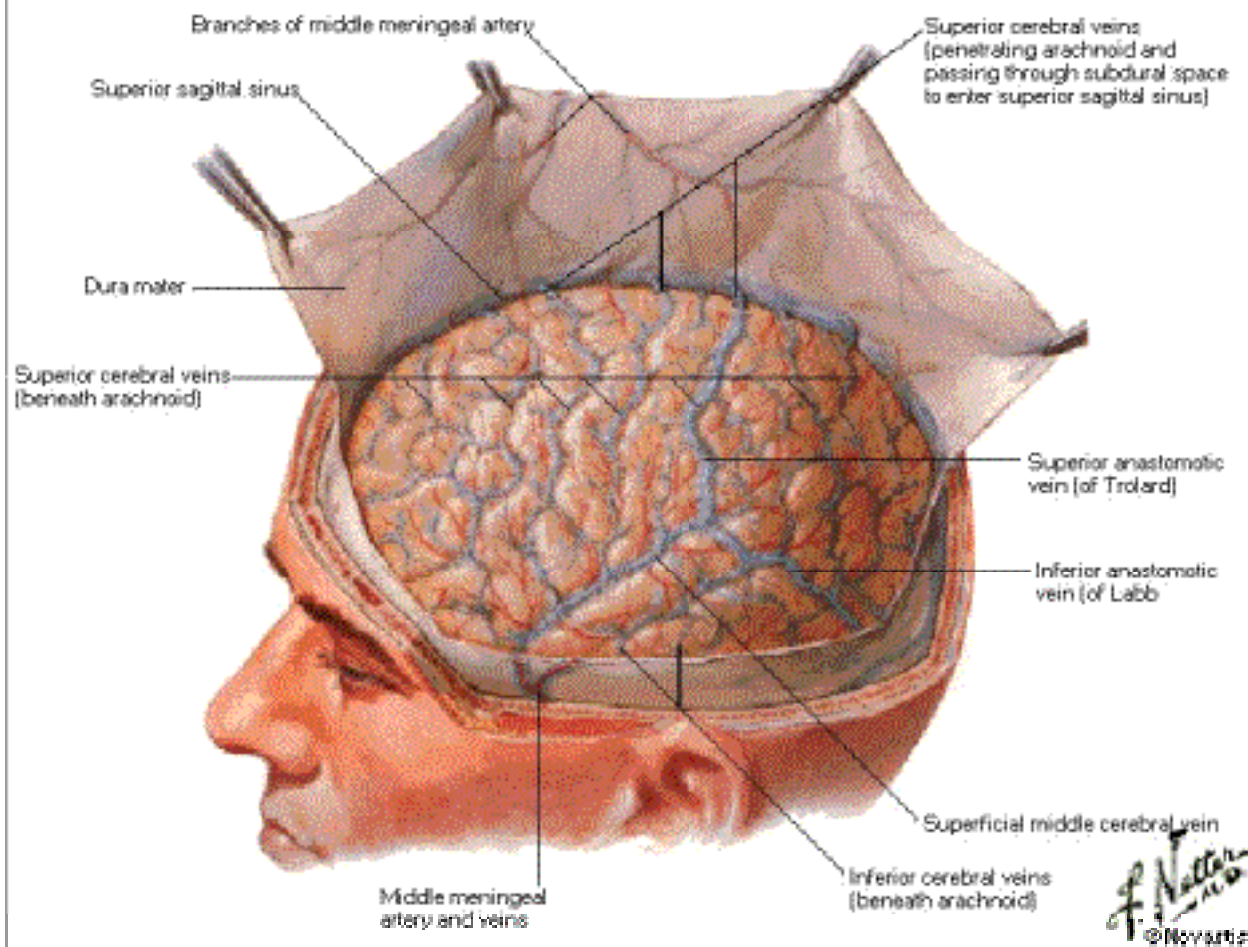
Meninges and Superficial Cerebral Veins

Frontal Section



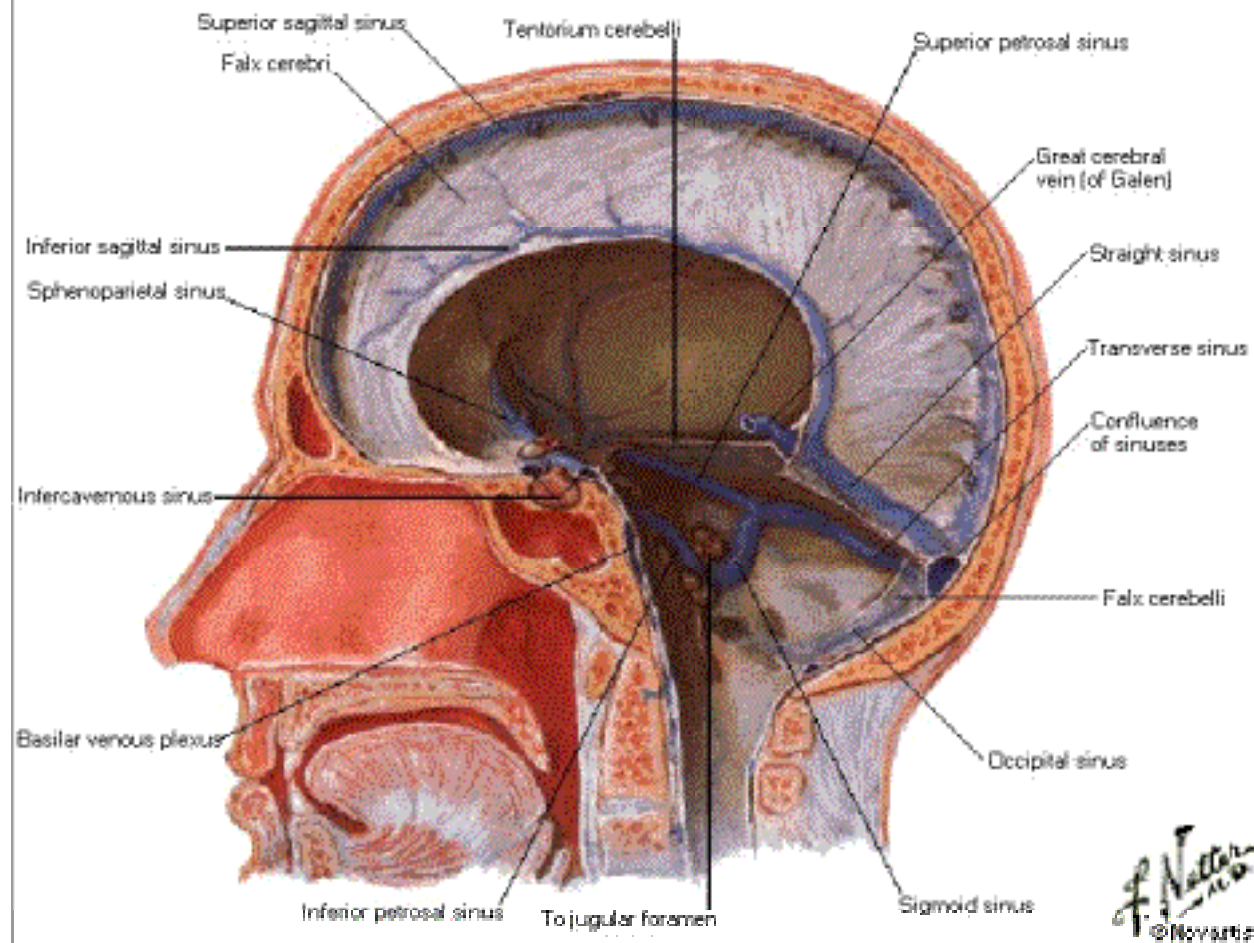
Meninges and Superficial Cerebral Veins

Dura Mater Lifted



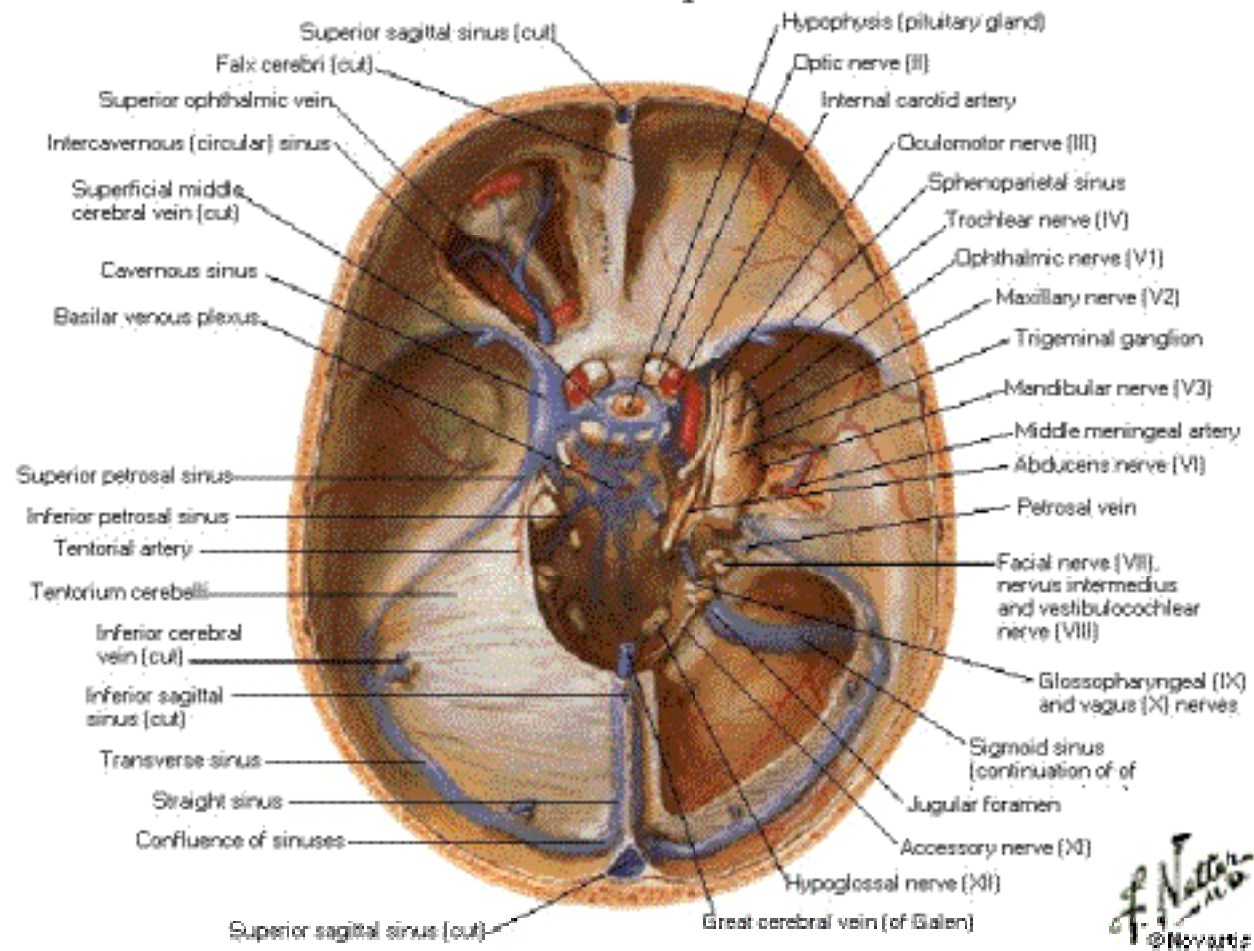
Venous Sinuses of Dura Mater

Sagittal Section



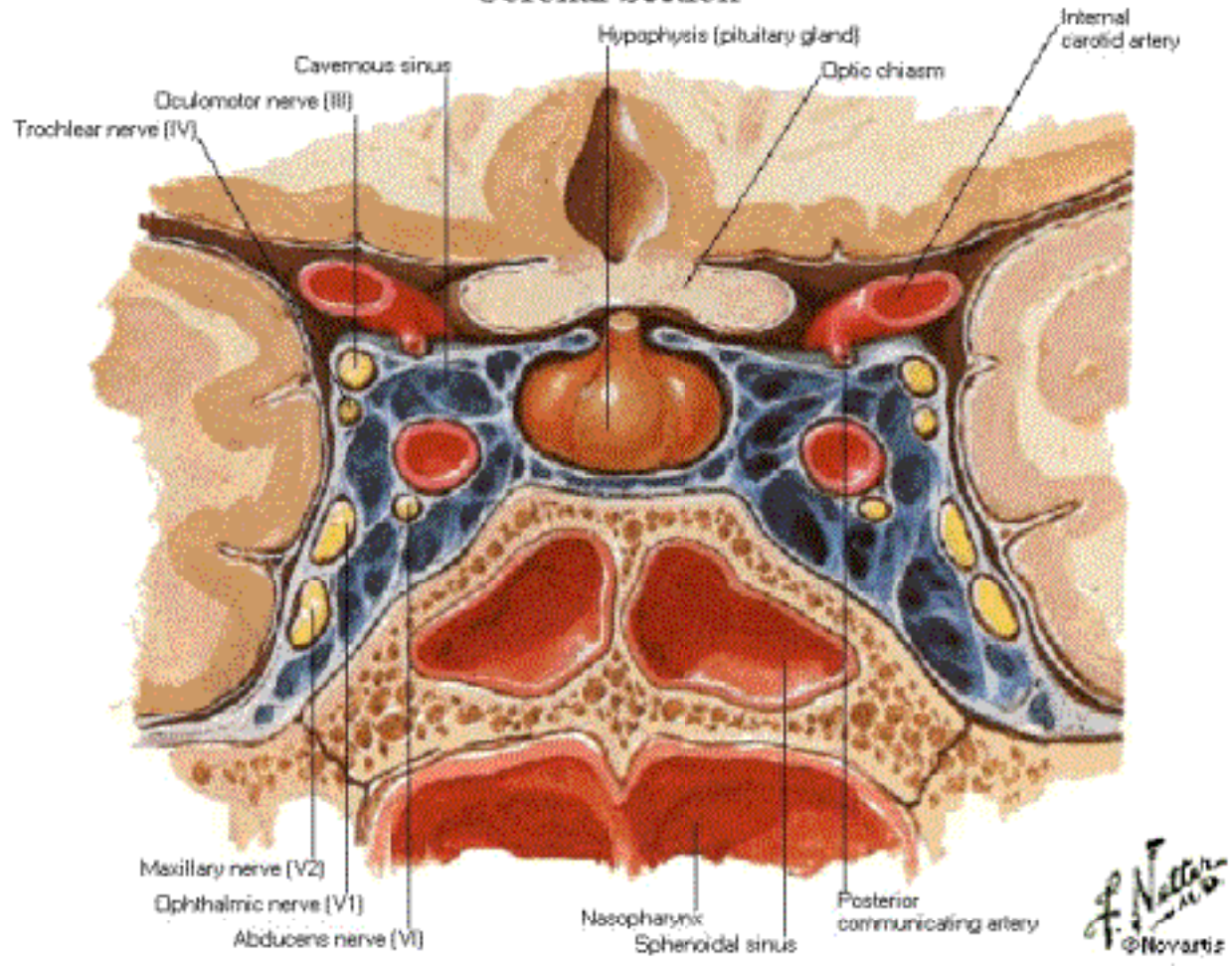
Venous Sinuses of Dura Mater

Cranial Floor - Superior View



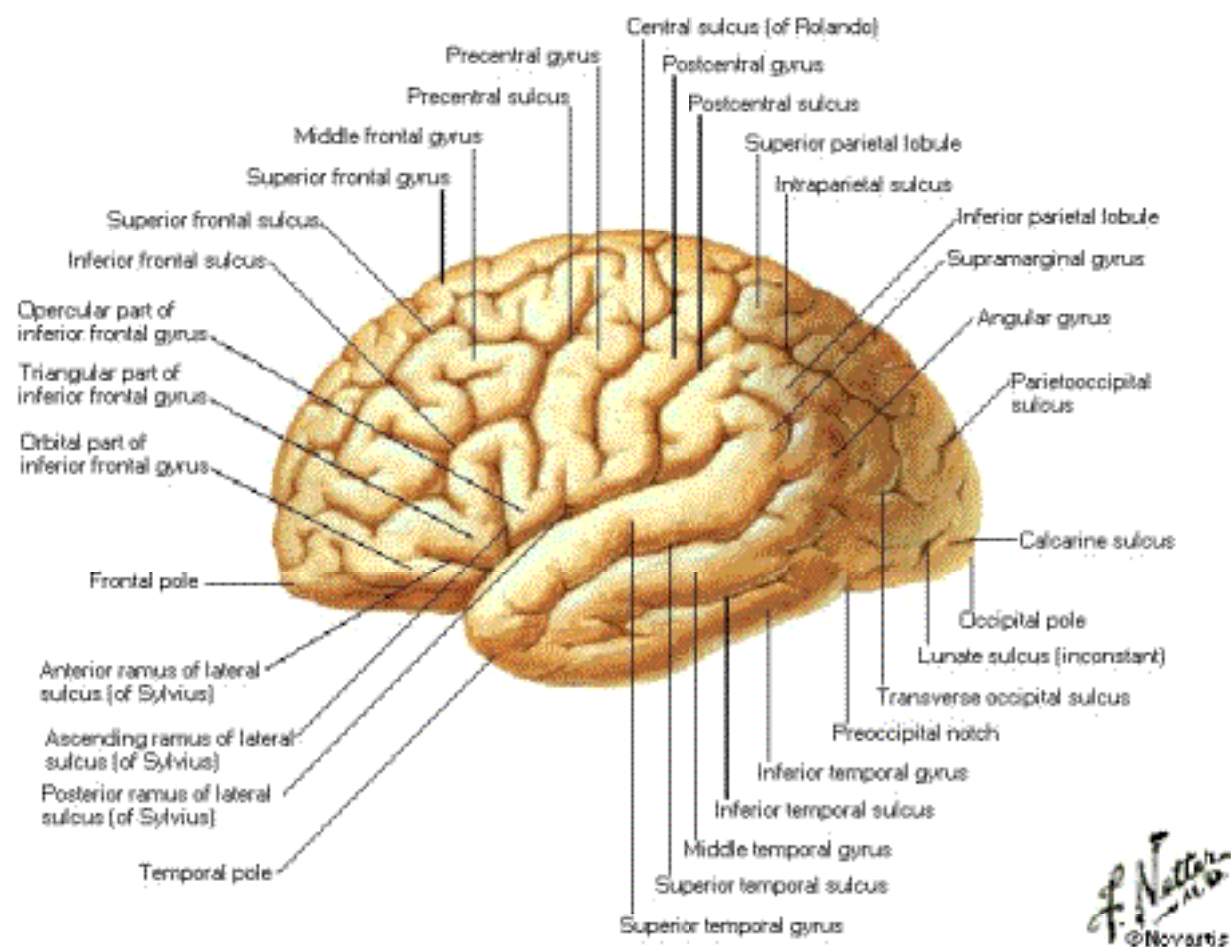
Cavernous Sinus

Coronal Section



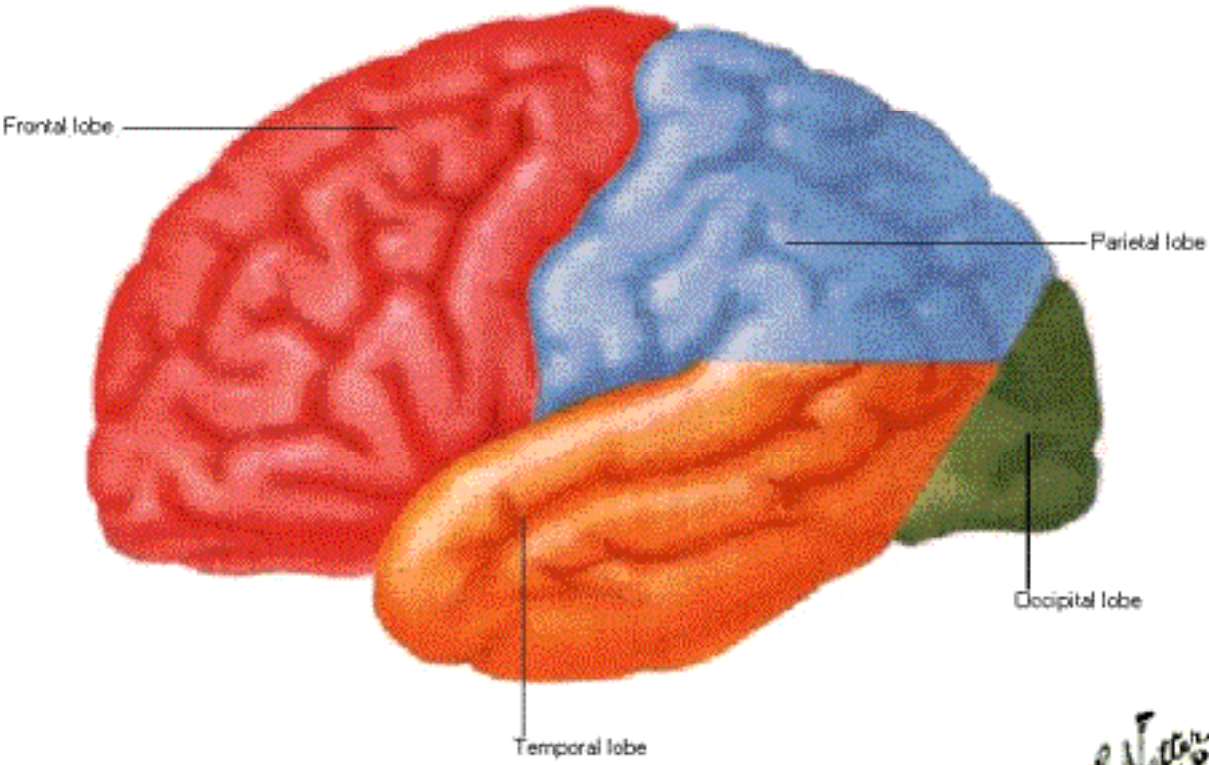
Cerebrum

Lateral View



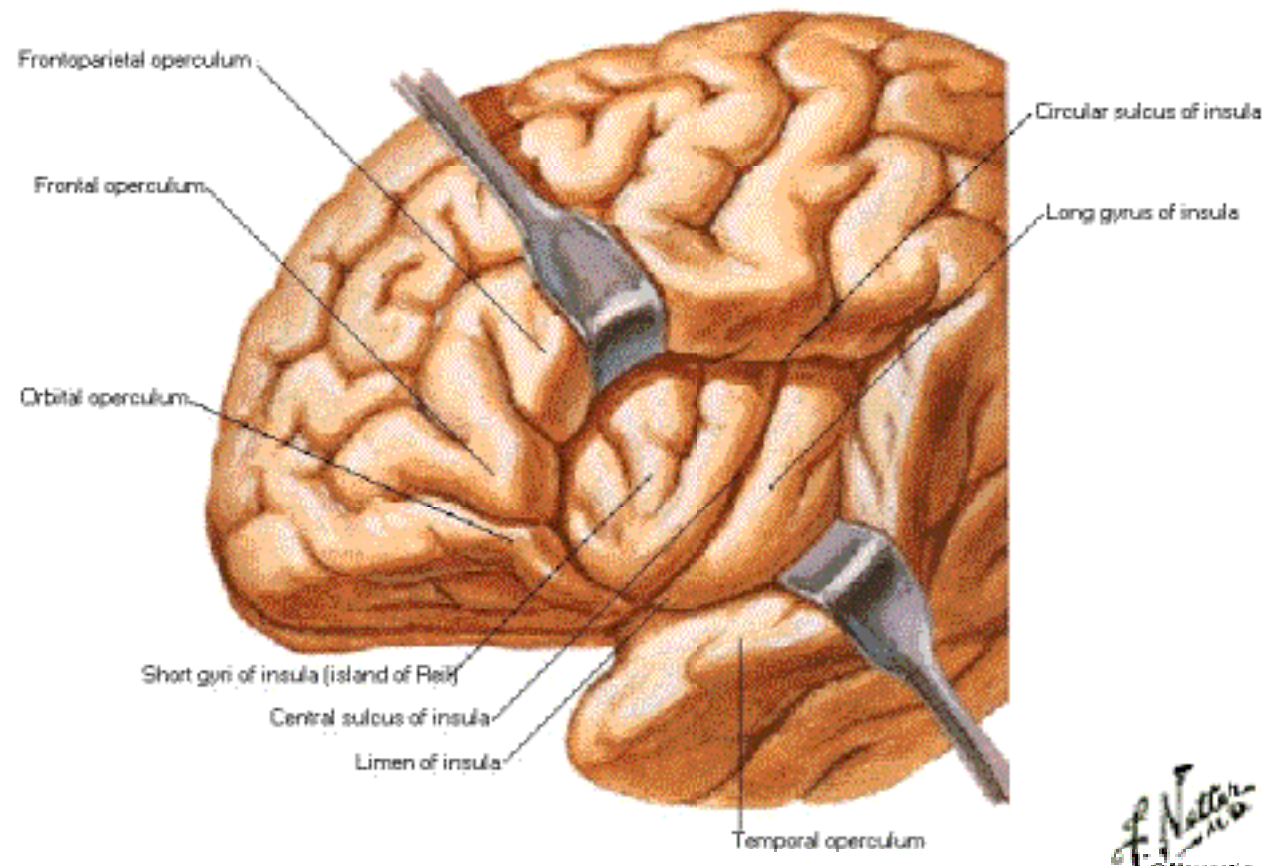
F. Netter M.D.
© Novartis

Cerebrum - Lobes
Lateral View



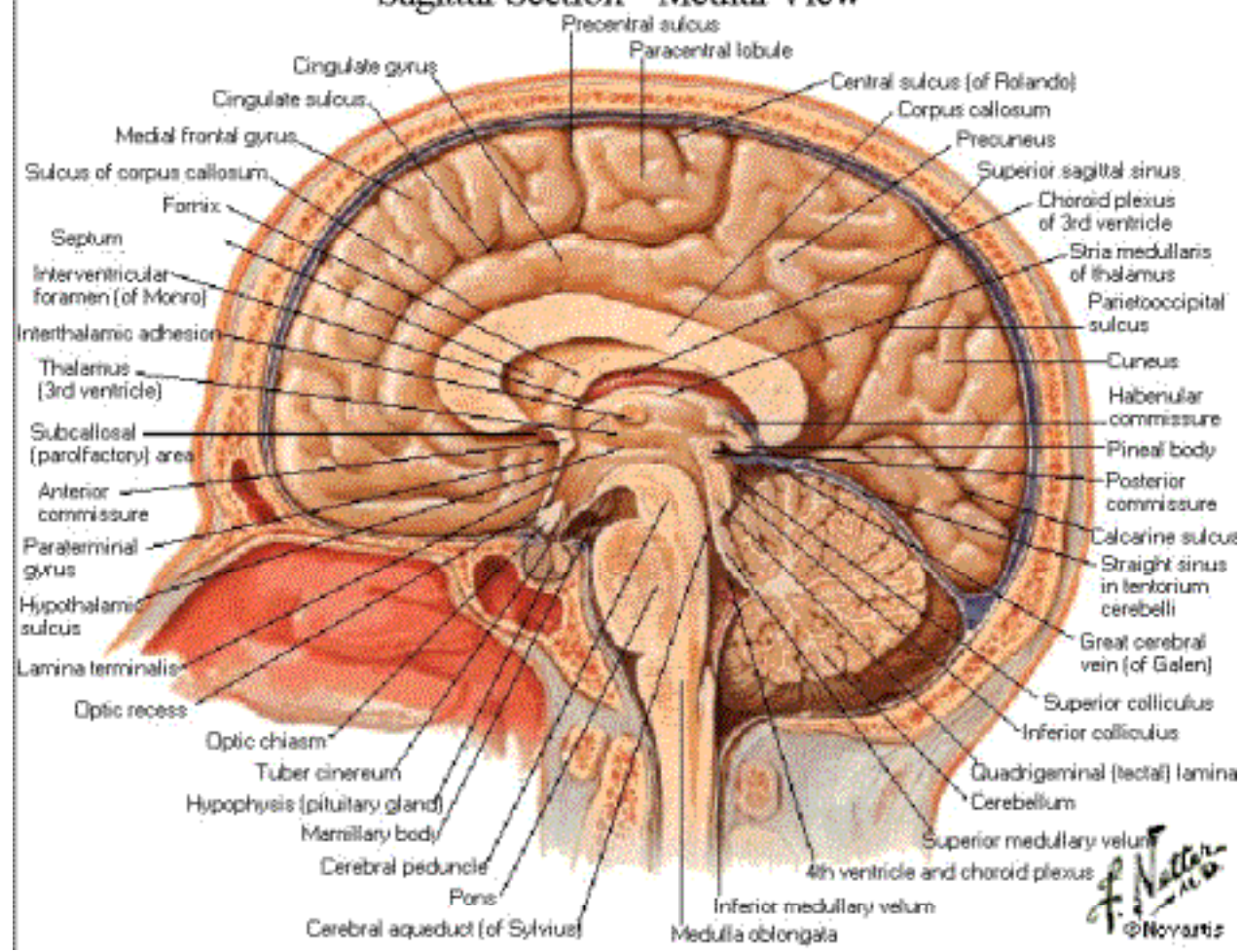
F. Netter M.D.
© Novartis

Cerebrum - Insula [Island of Reil] Lateral View



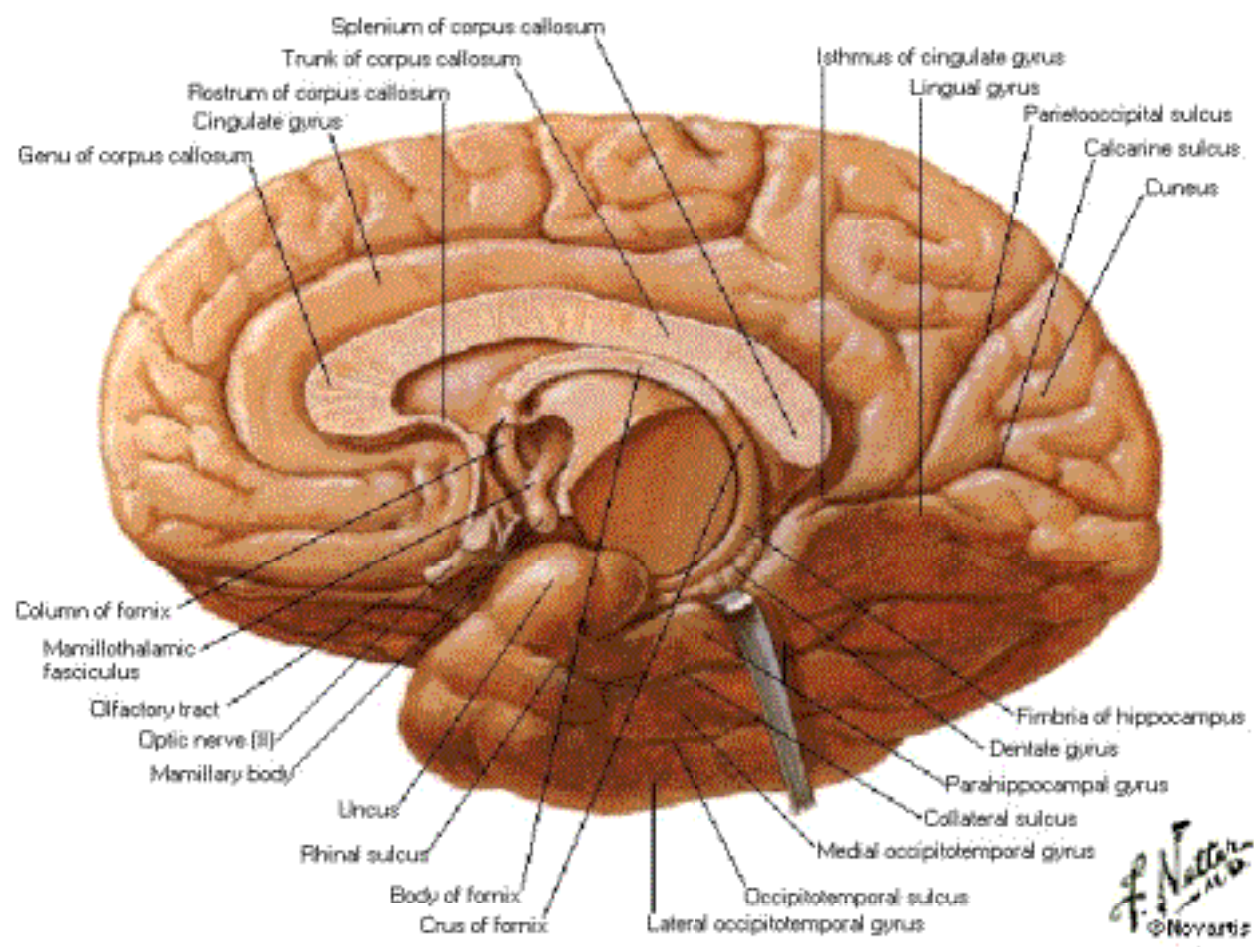
Cerebrum - Brain in Situ

Sagittal Section - Medial View



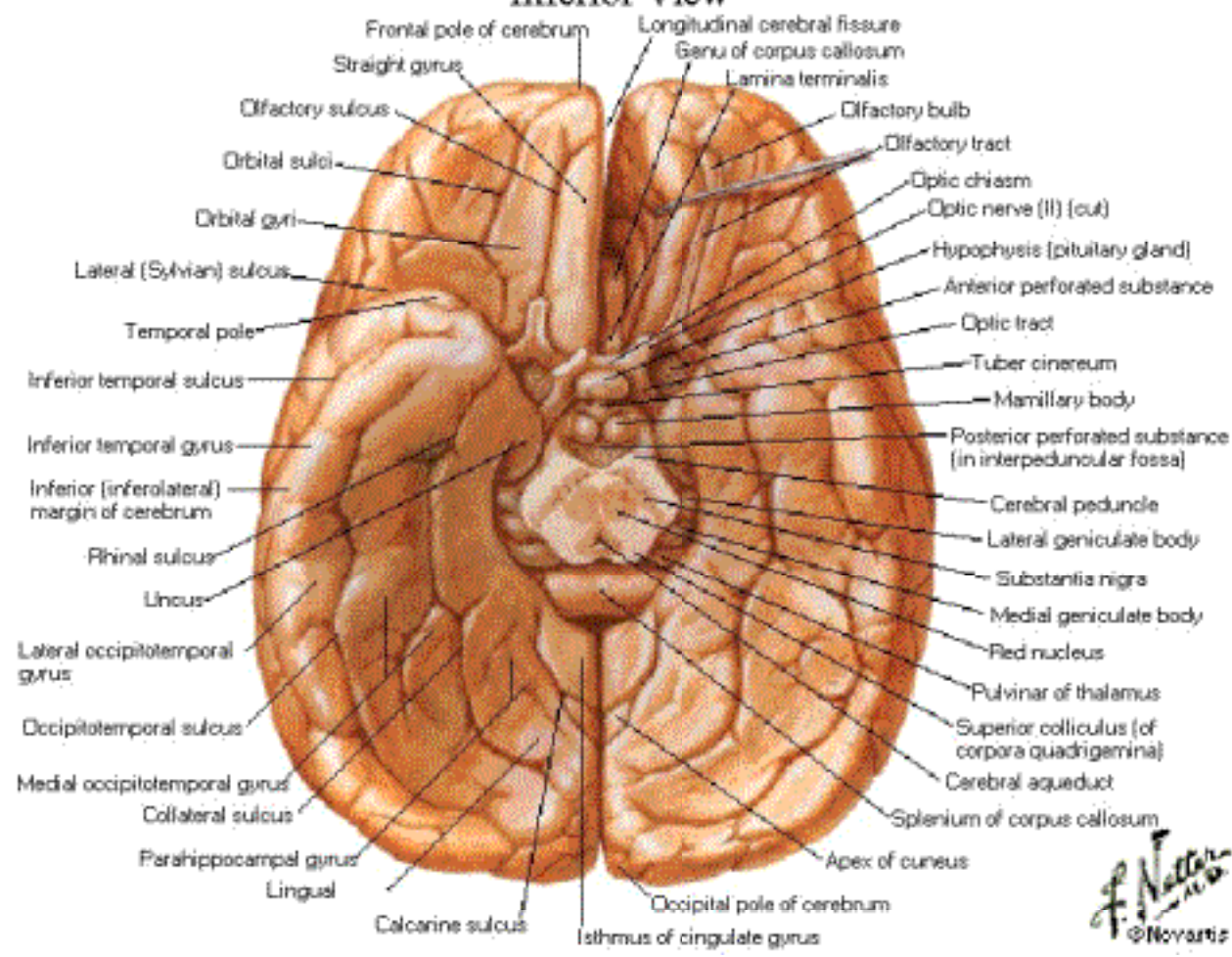
Cerebrum - Hemisphere with Brainstem Excised

Medial View



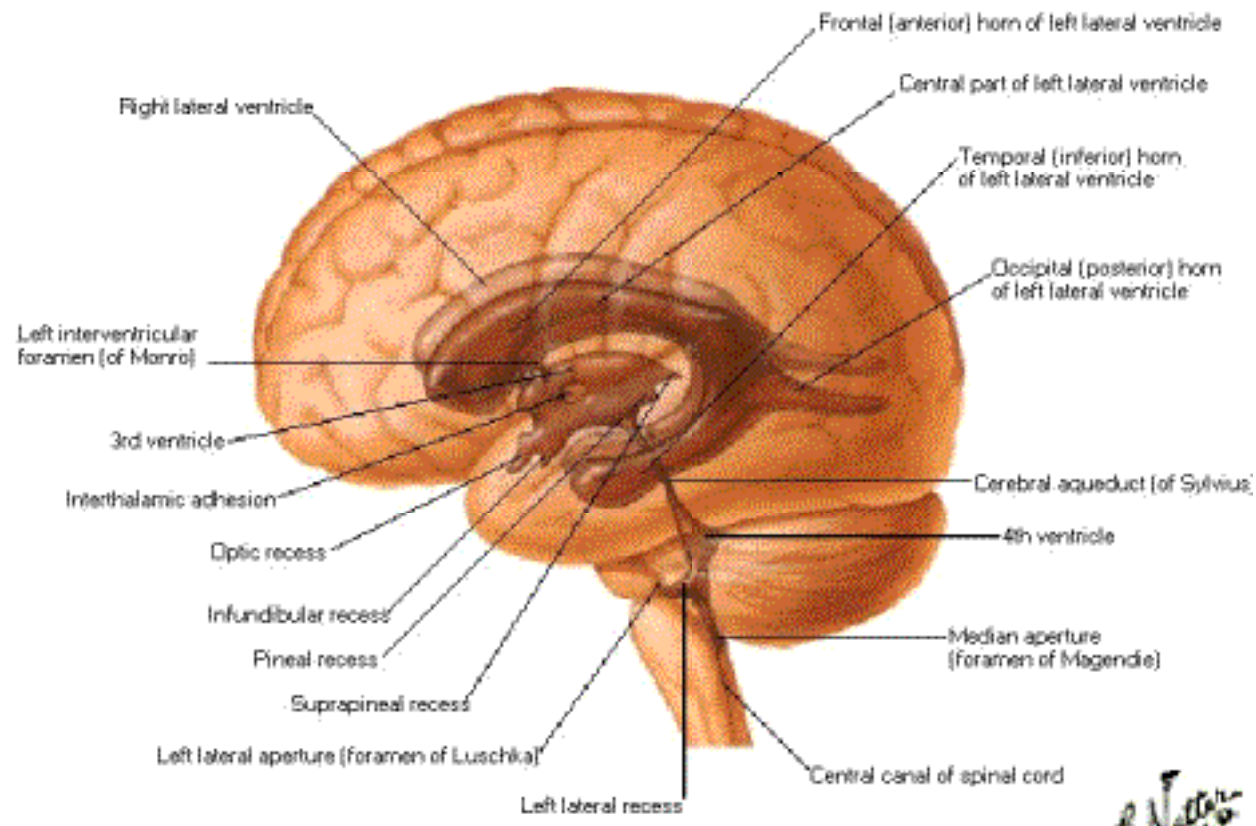
Cerebrum

Inferior View



Ventricles of Brain

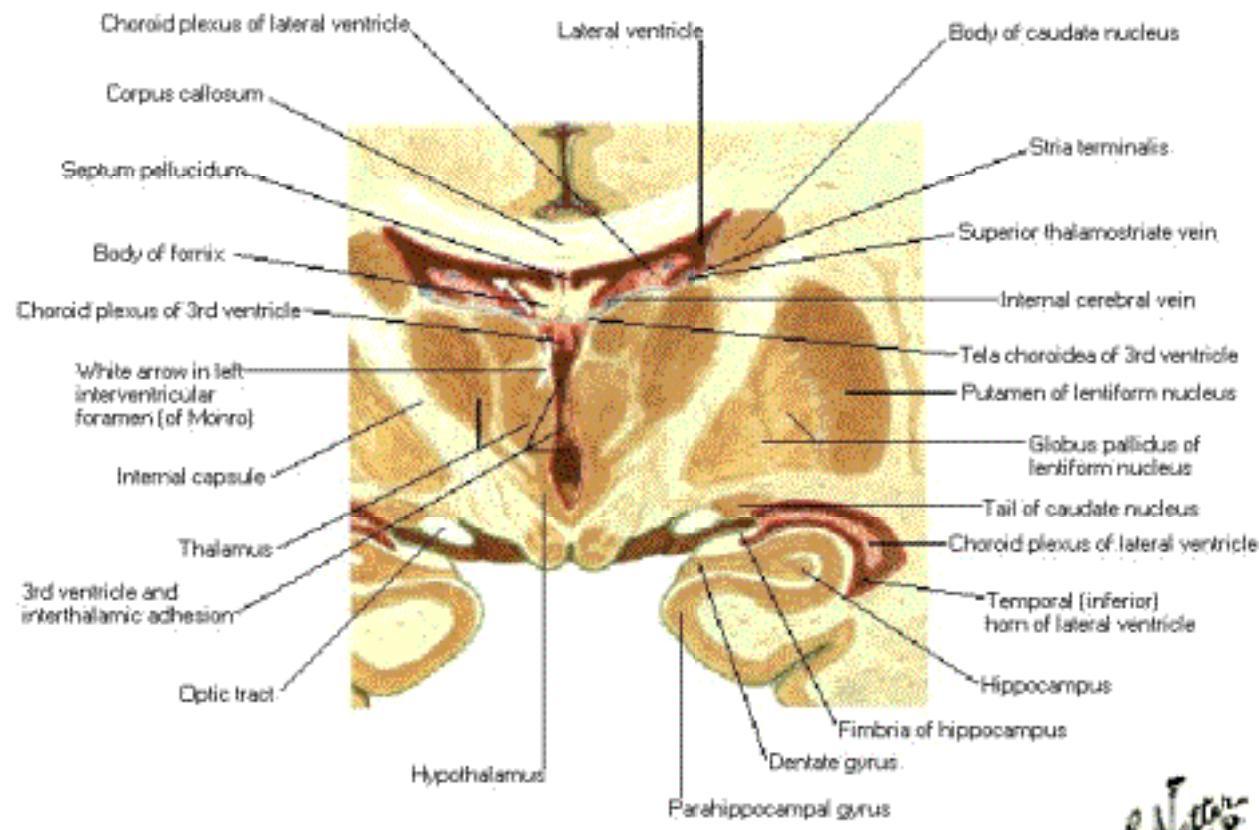
Left Lateral Phantom View



F. Netter M.D.
© 2005

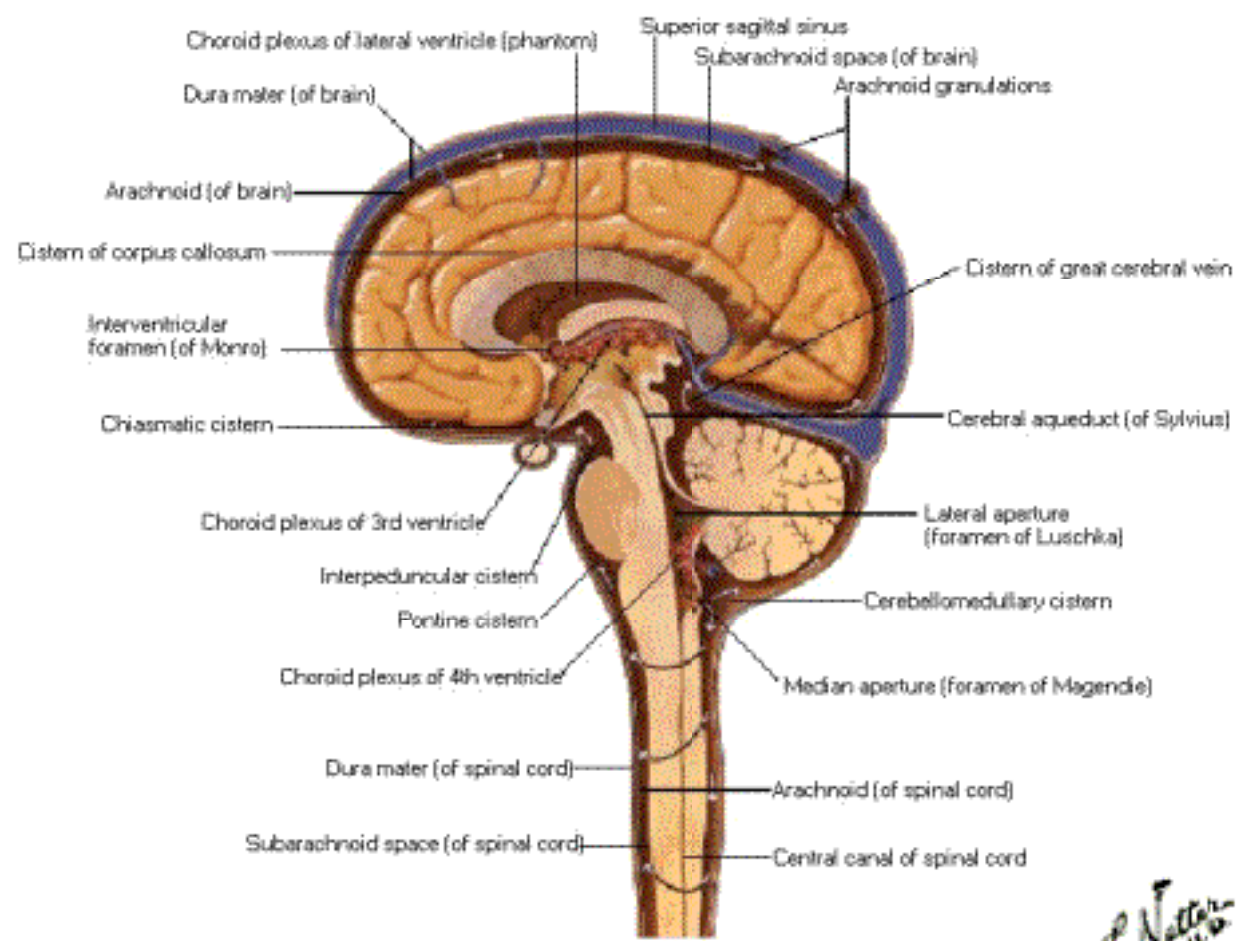
Ventricles of Brain

Coronal Section - Posterior View



F. Netter M.D.
© Novartis

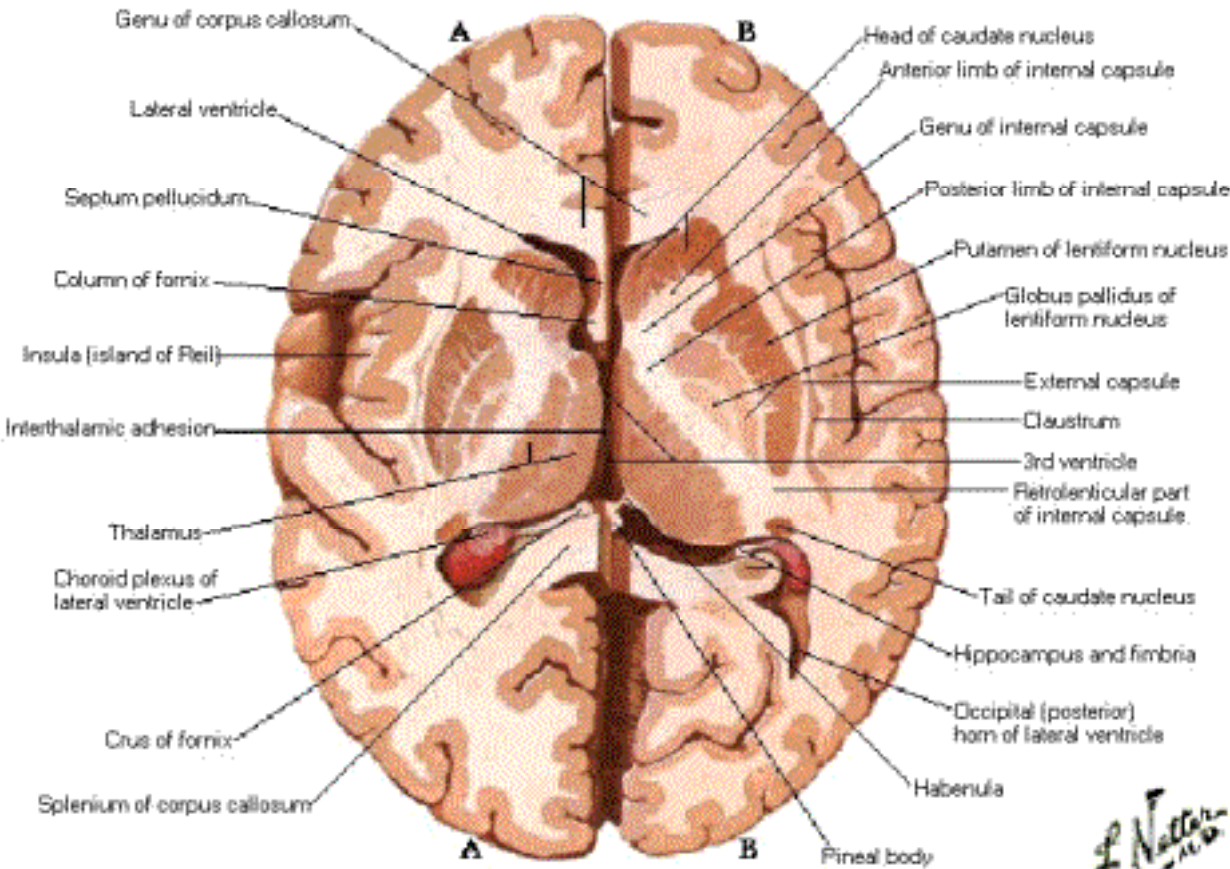
Circulation of Cerebrospinal Fluid



F. Netter M.D.
© Novartis

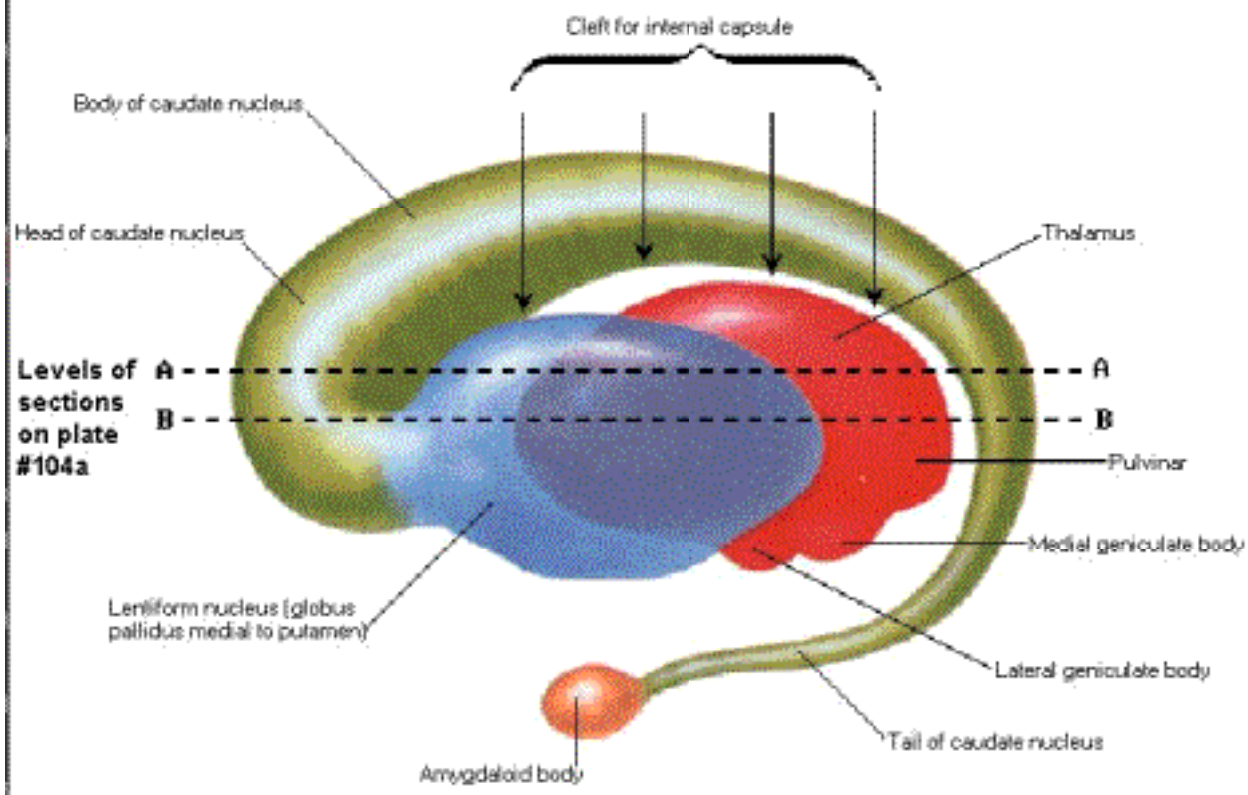
Basal Ganglia

Horizontal Sections through Cerebrum



Basal Ganglia - Schema

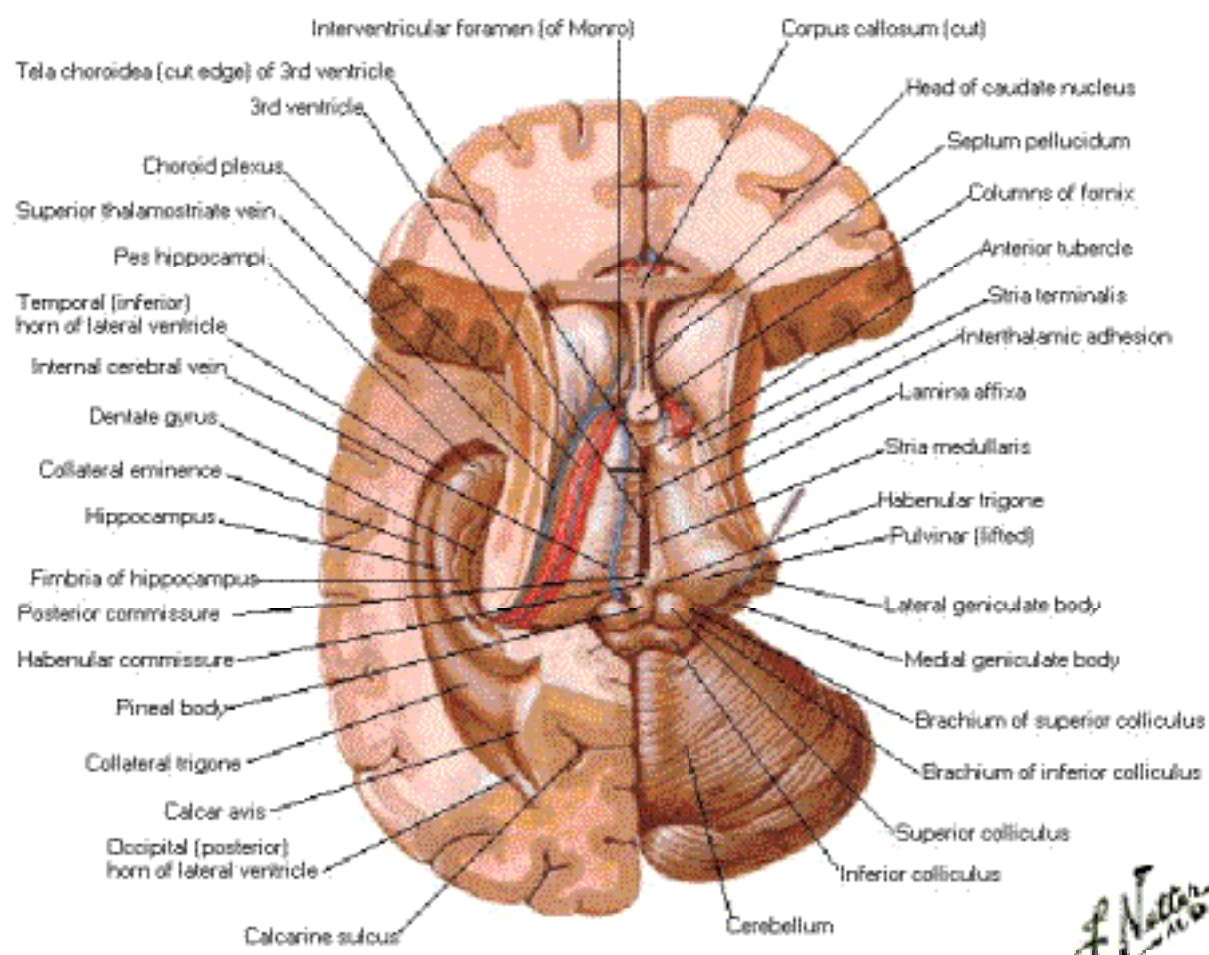
Left Lateral View



Interrelationship of thalamus, lentiform nucleus, caudate nucleus and amygdaloid body

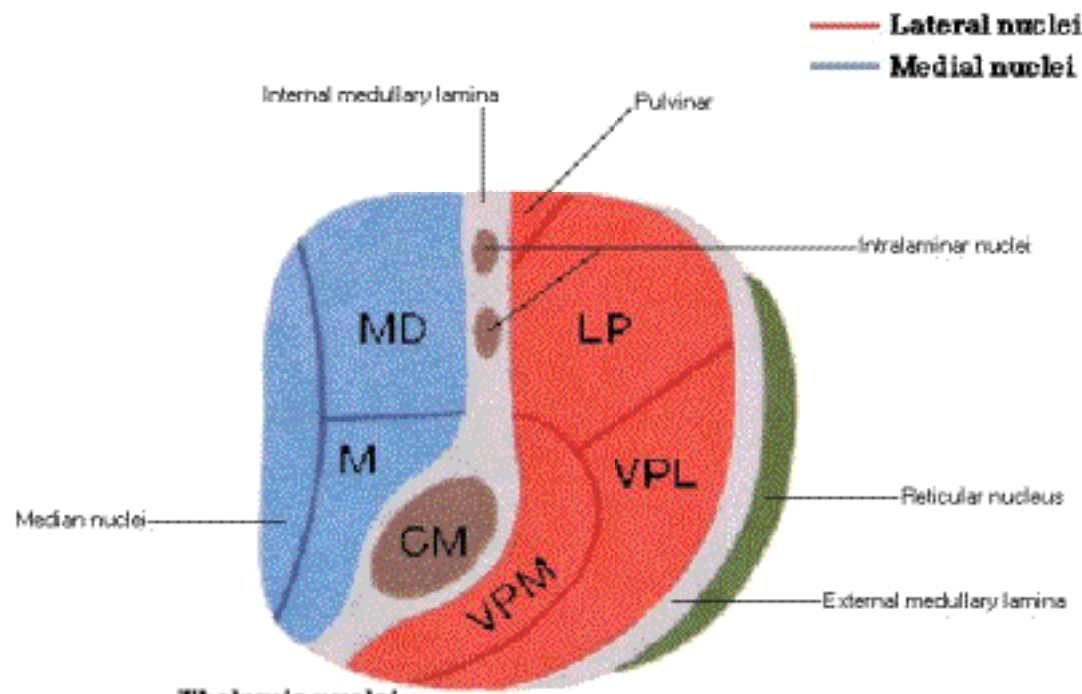
F. Netter M.D.
© 1975

Thalamus



Thalamus

Schematic Section



Thalamic nuclei

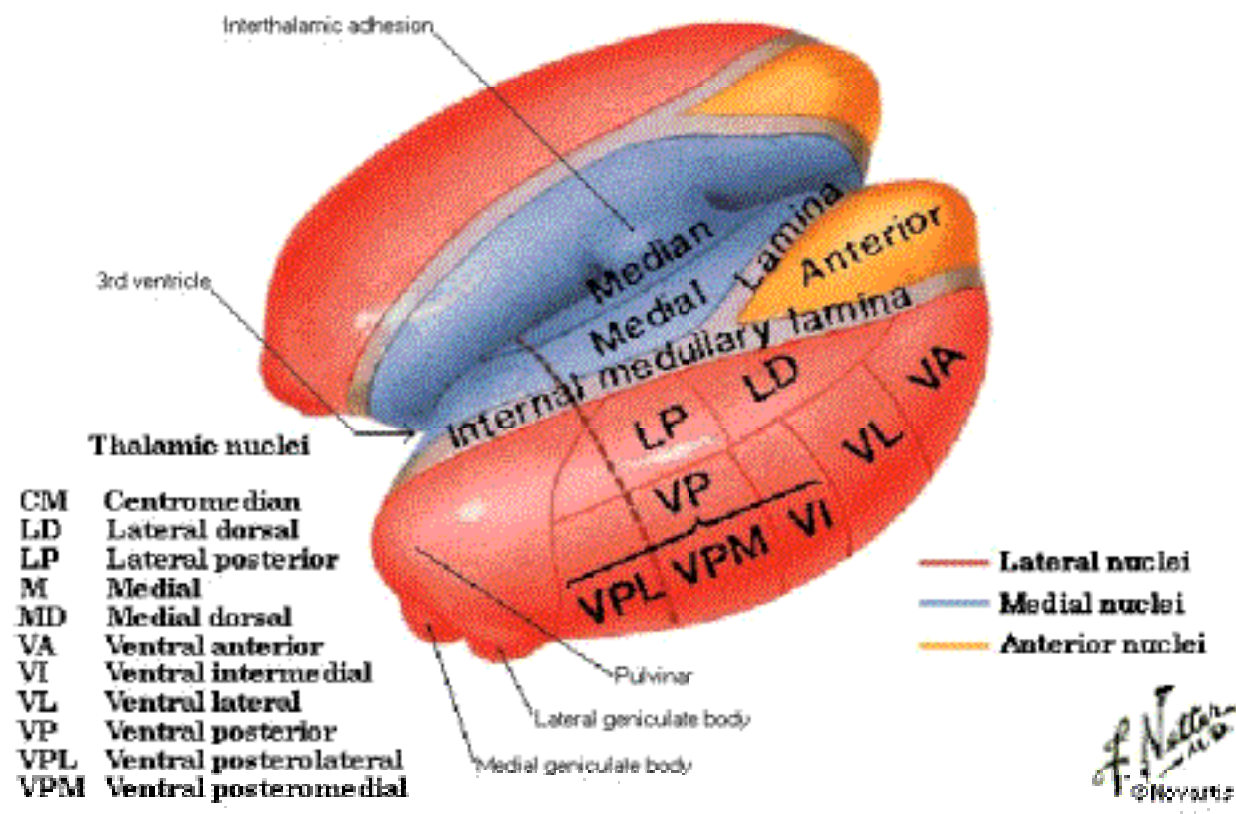
CM	Centromedian	VA	Ventral anterior
LD	Lateral dorsal	VI	Ventral intermediate
LP	Lateral posterior	VL	Ventral lateral
M	Medial	VP	Ventral posterior
MD	Medial dorsal	VPL	Ventral posterolateral
		VPM	Ventral posteromedial

Schematic section through thalamus (at level of broken line shown in plate #105C)

F. Netter M.D.
© 1989

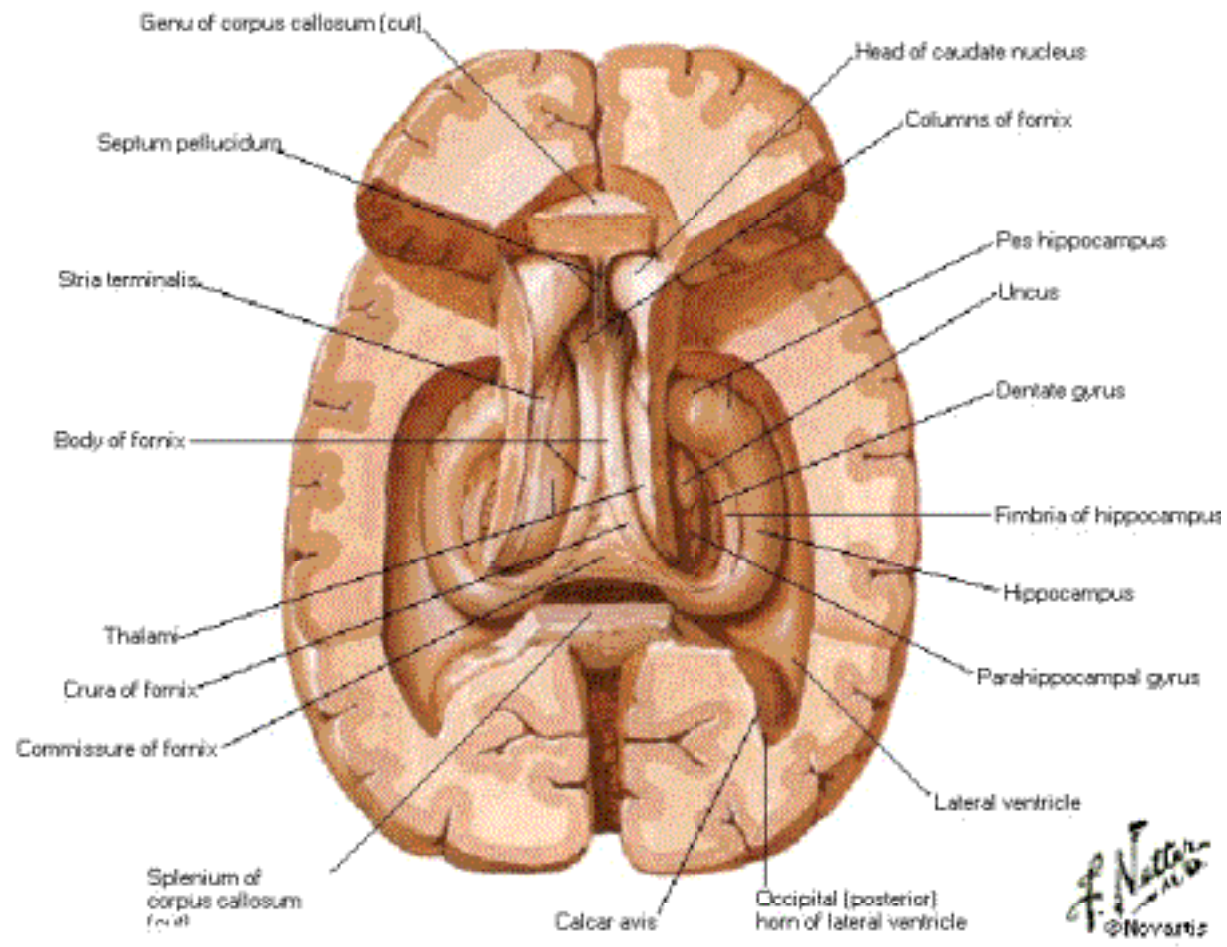
Thalamus

Schematic Representation of Thalamus



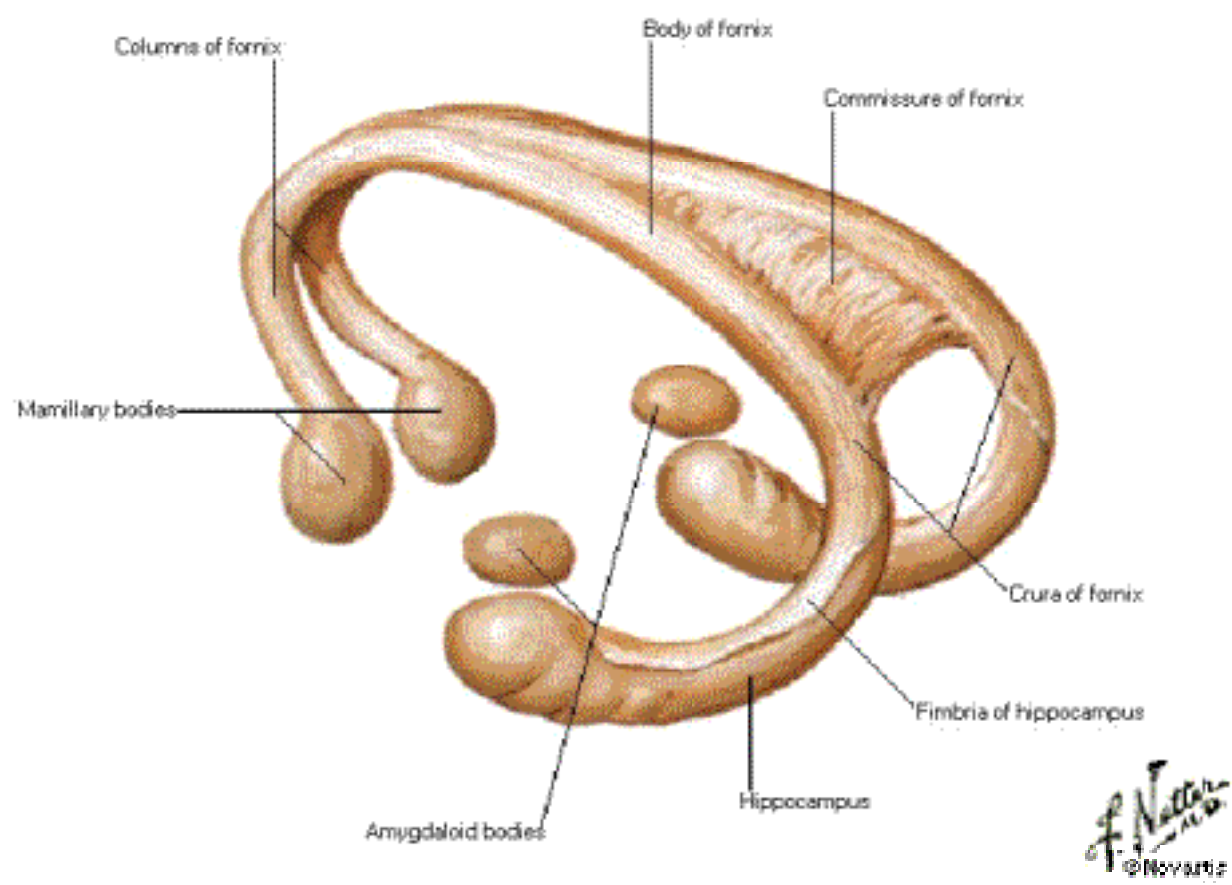
Hippocampus and Fornix

Superior Dissection



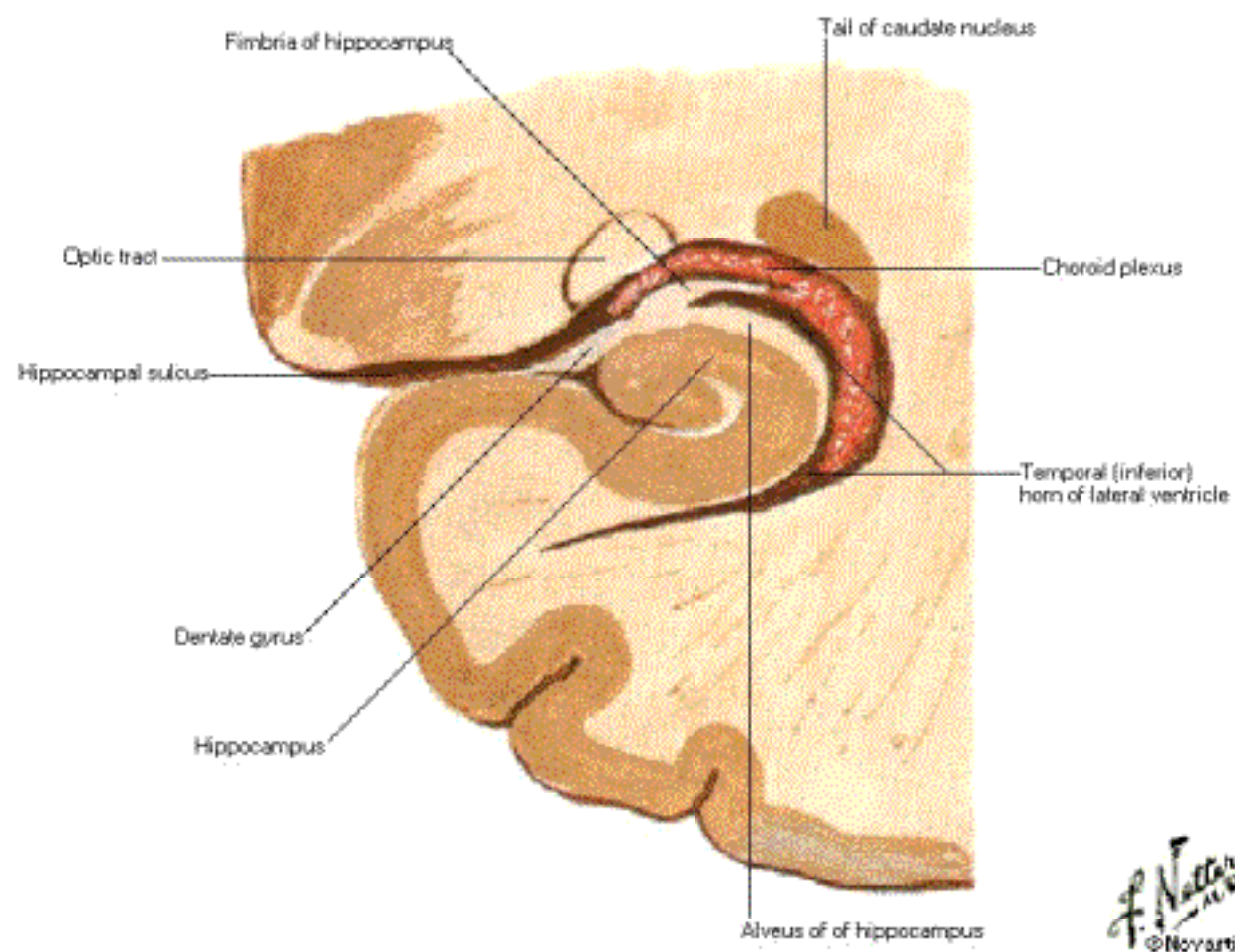
Hippocampus and Fornix

Schema of Fornix



Hippocampus and Fornix

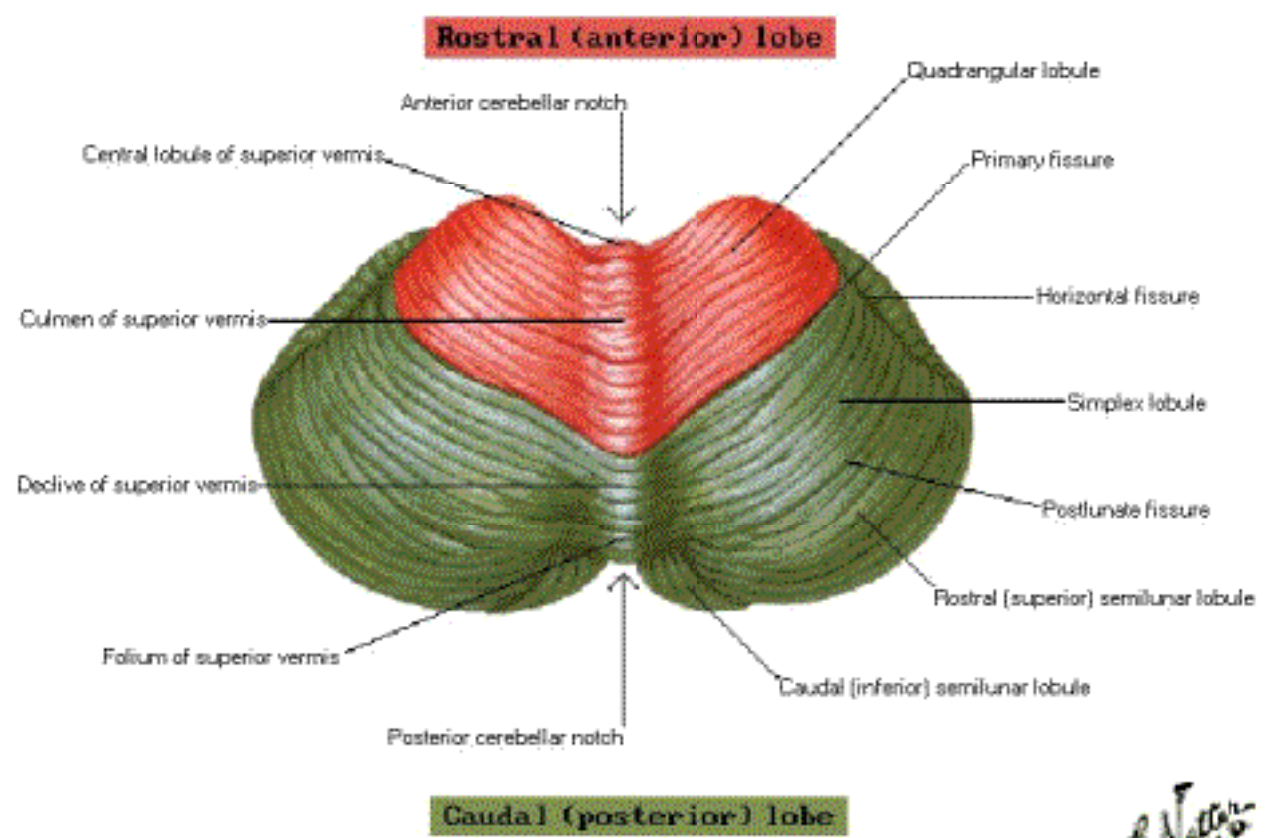
Coronal Section - Posterior View



F. Netter
© Novartis

Cerebellum

Superior Surface



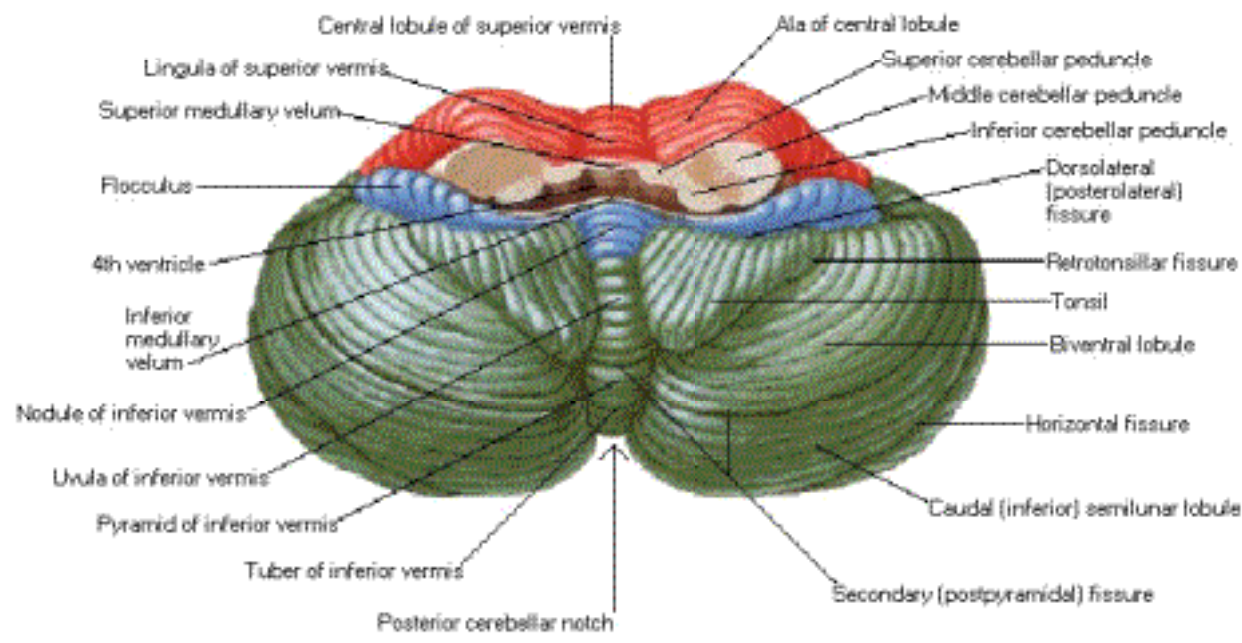
F. N. N. N.
© Novartis

Cerebellum

Inferior Surface

Rostral (anterior) lobe

Flocculonodular lobe

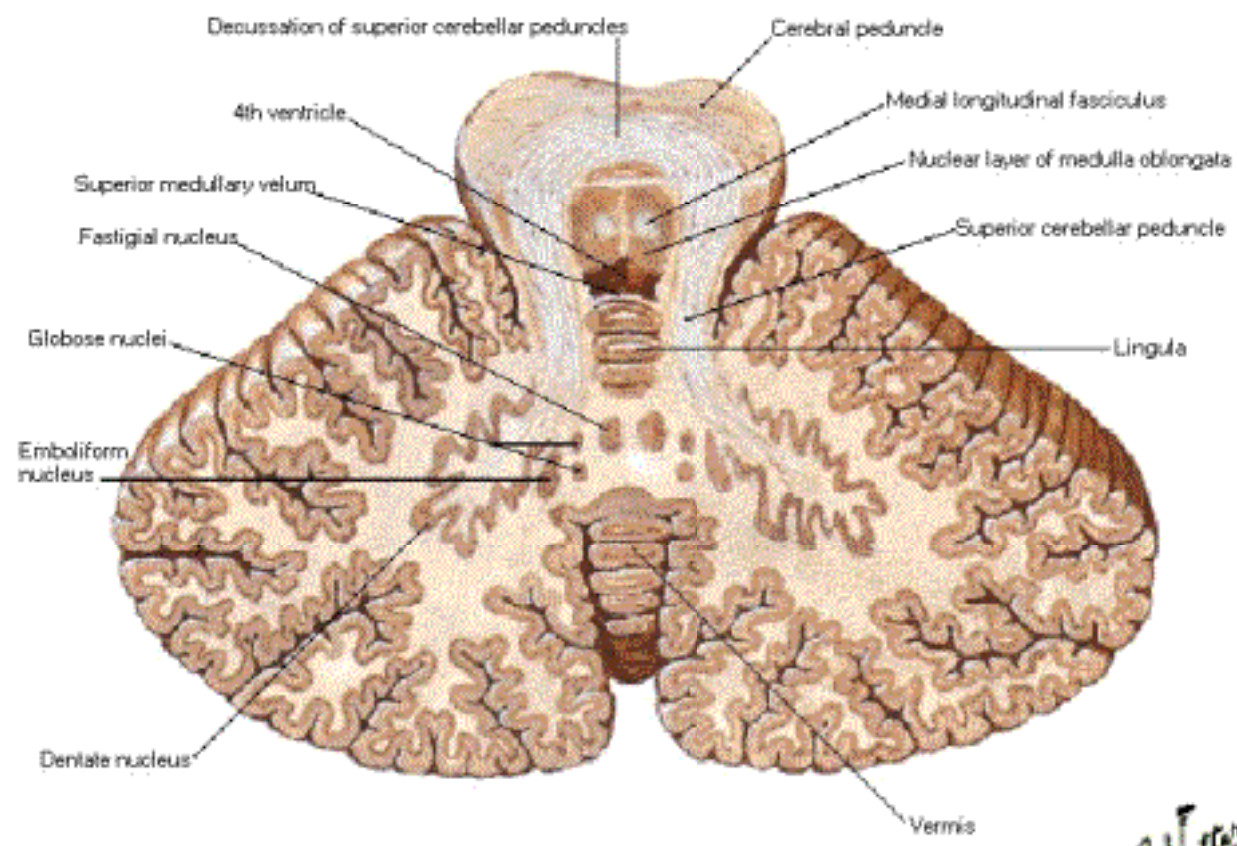


Caudal (posterior) lobe

F. Netter M.D.
© Novartis

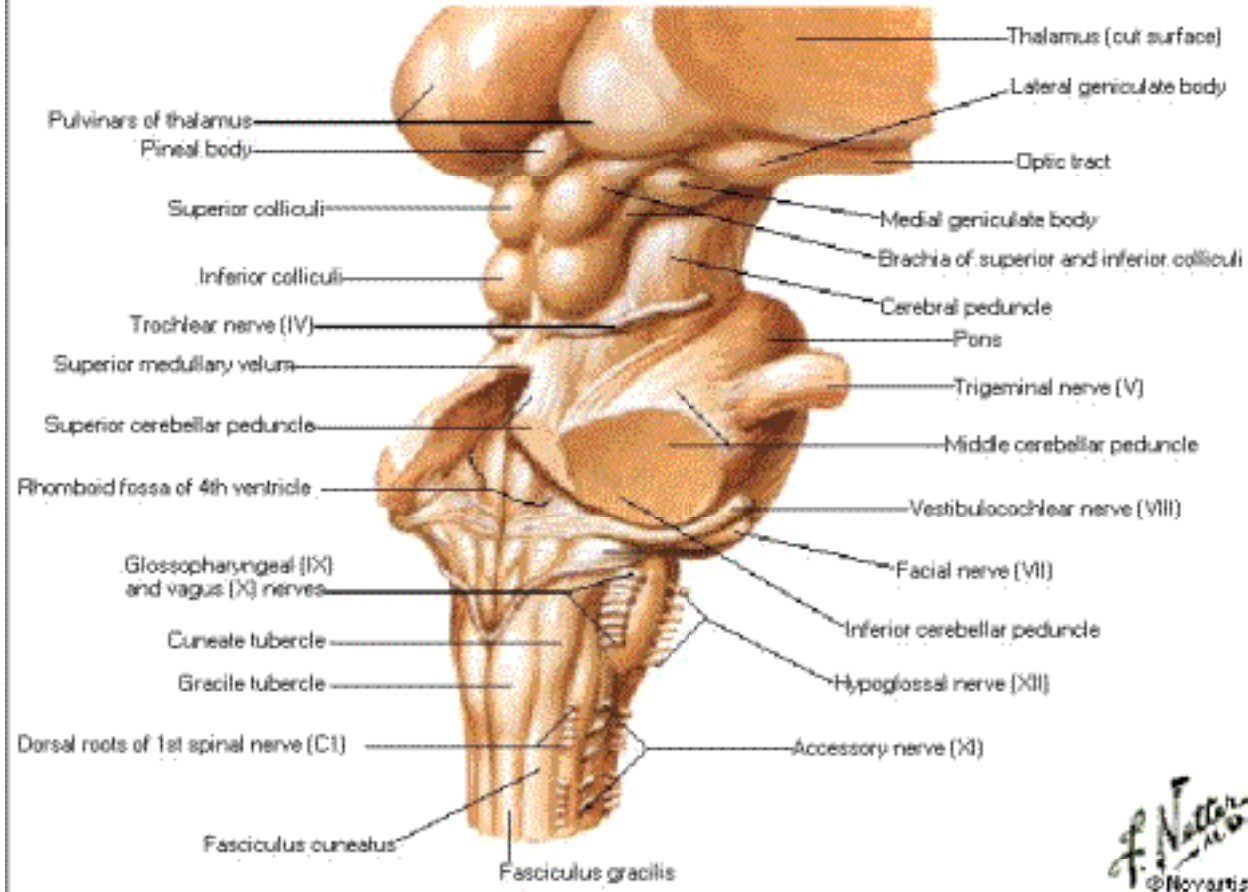
Cerebellum

Section in Plane of Superior Cerebellar Peduncle



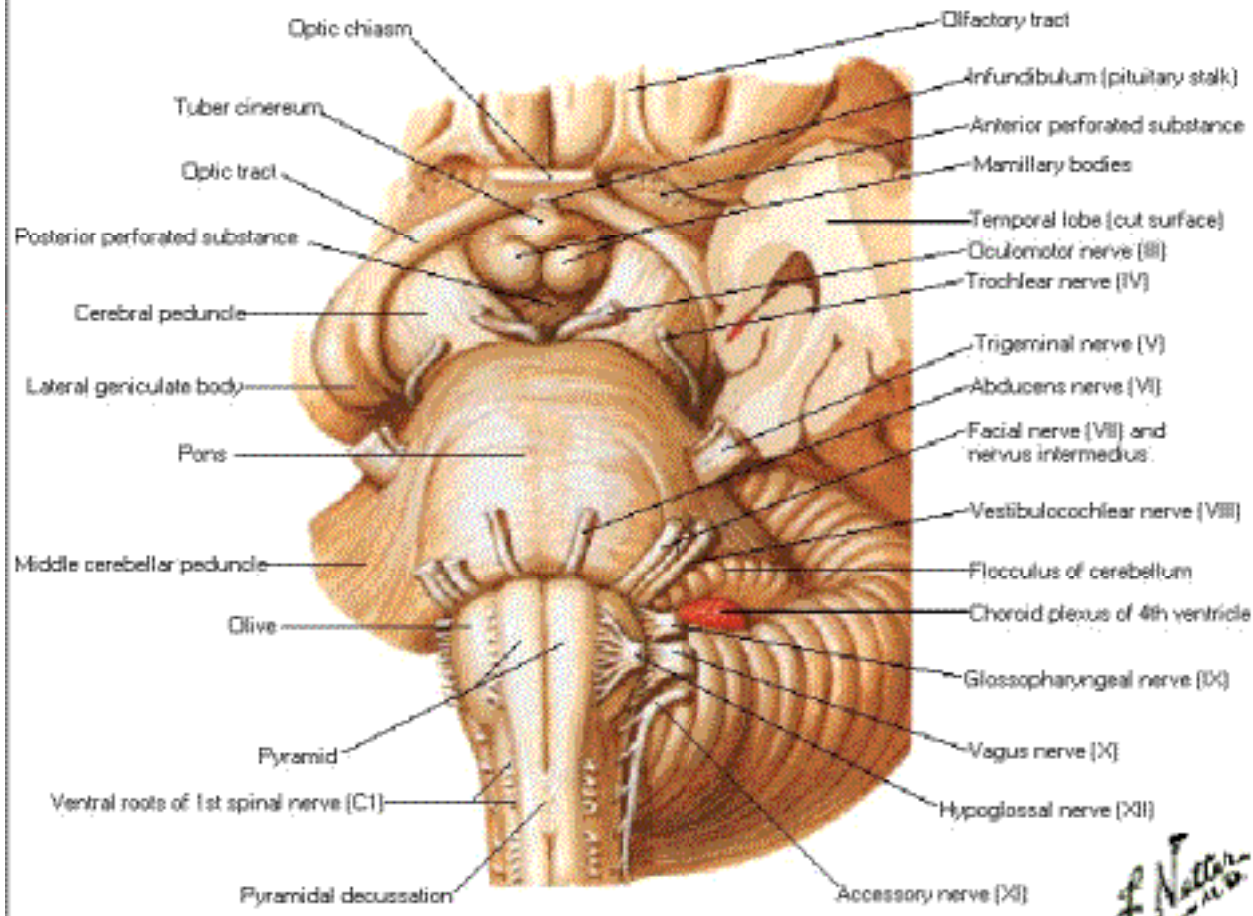
F. Netter
© Novartis

Brainstem Posterolateral View



F. Netter M.D.
© Novartis

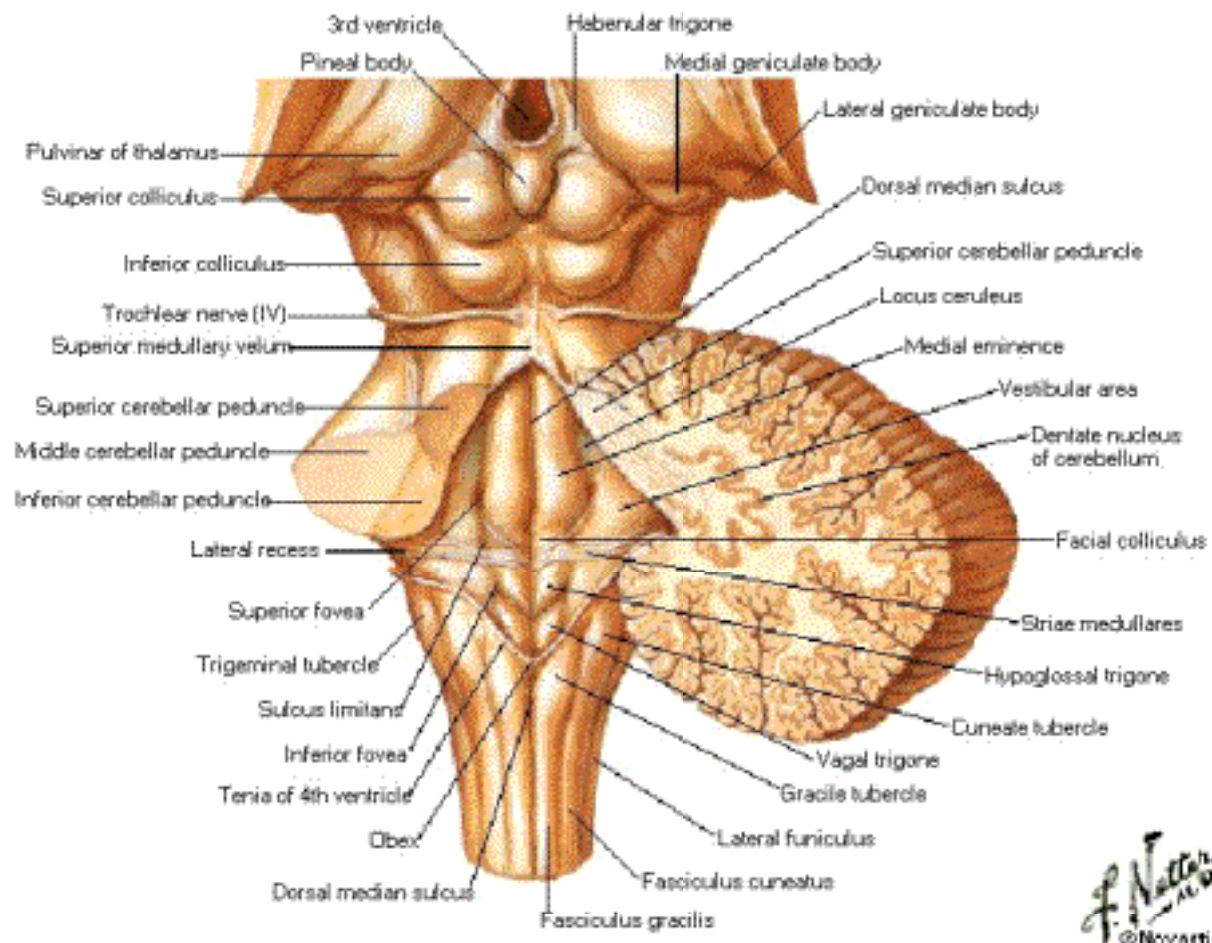
Brainstem Anterioinferior View



F. Netter M.D.
© 1996

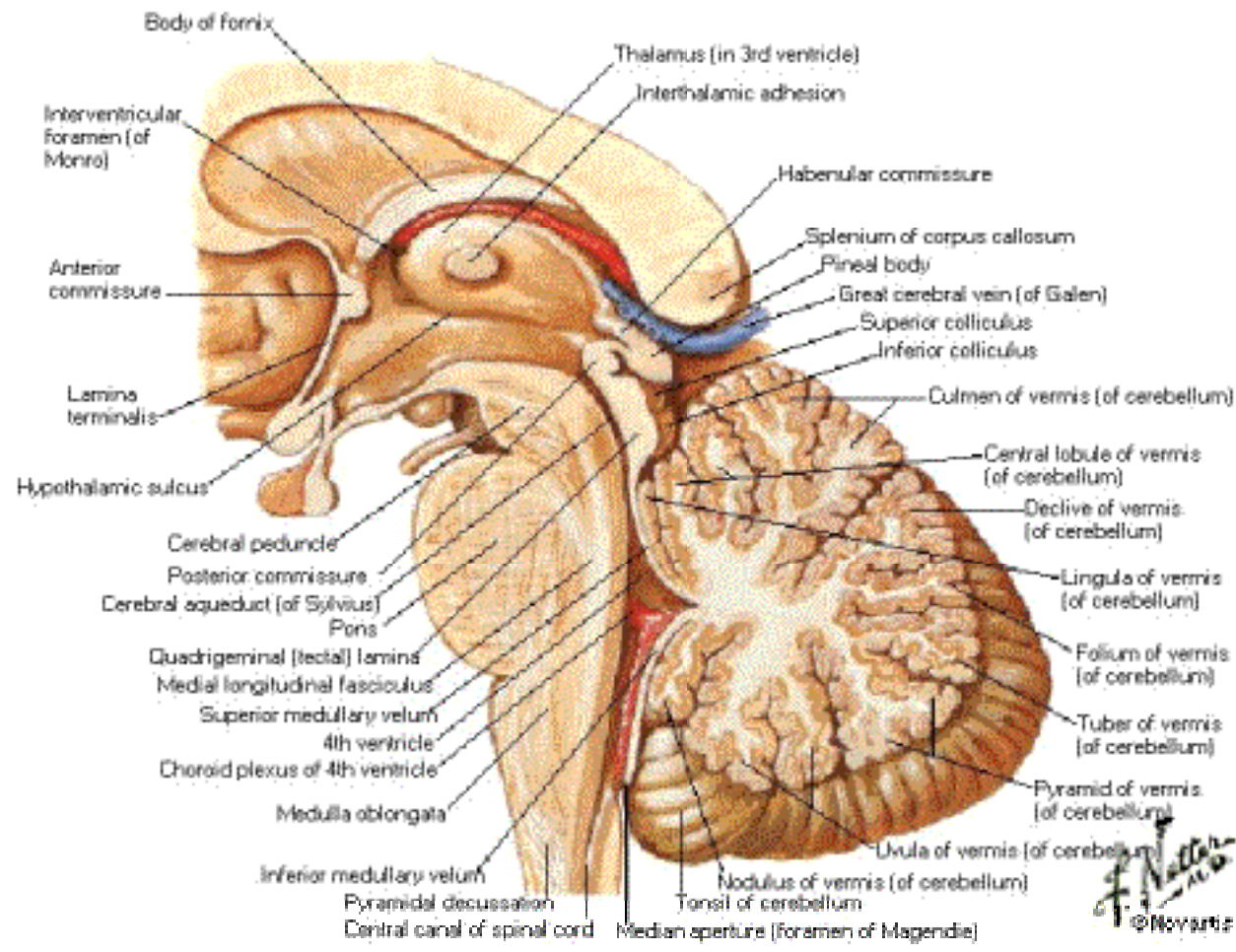
Fourth Ventricle and Cerebellum

Posterior View



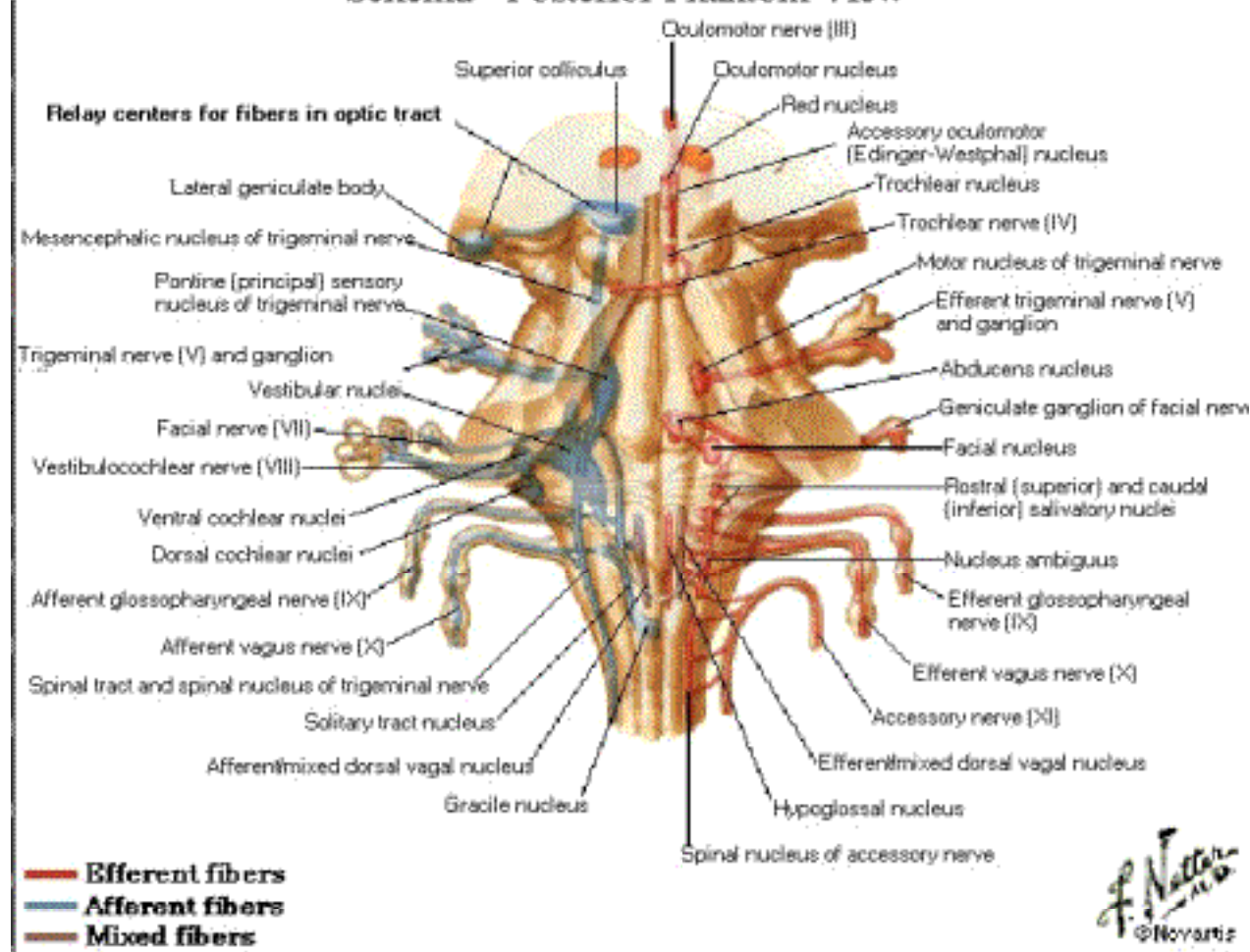
Fourth Ventricle and Cerebellum

Median Sagittal Section



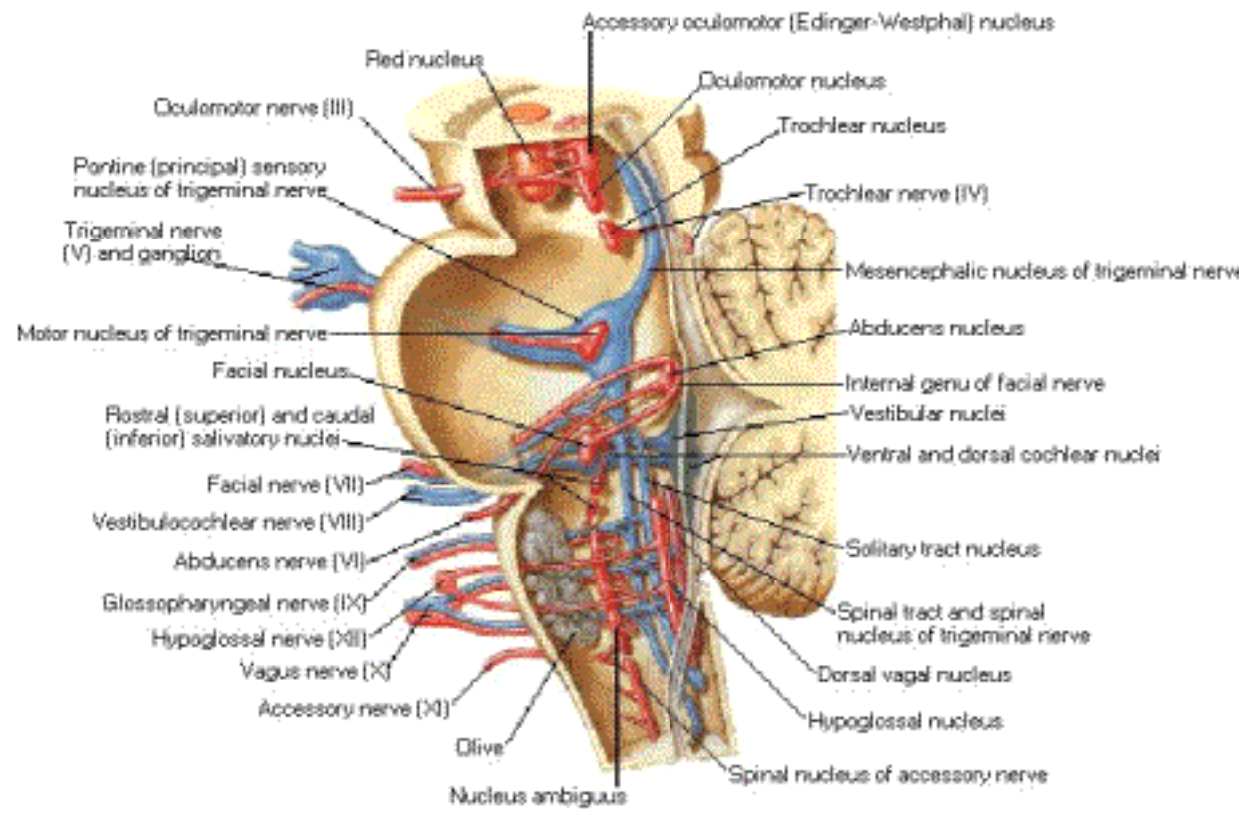
Cranial Nerve Nuclei in Brainstem

Schema - Posterior Phantom View



Cranial Nerve Nuclei in Brainstem

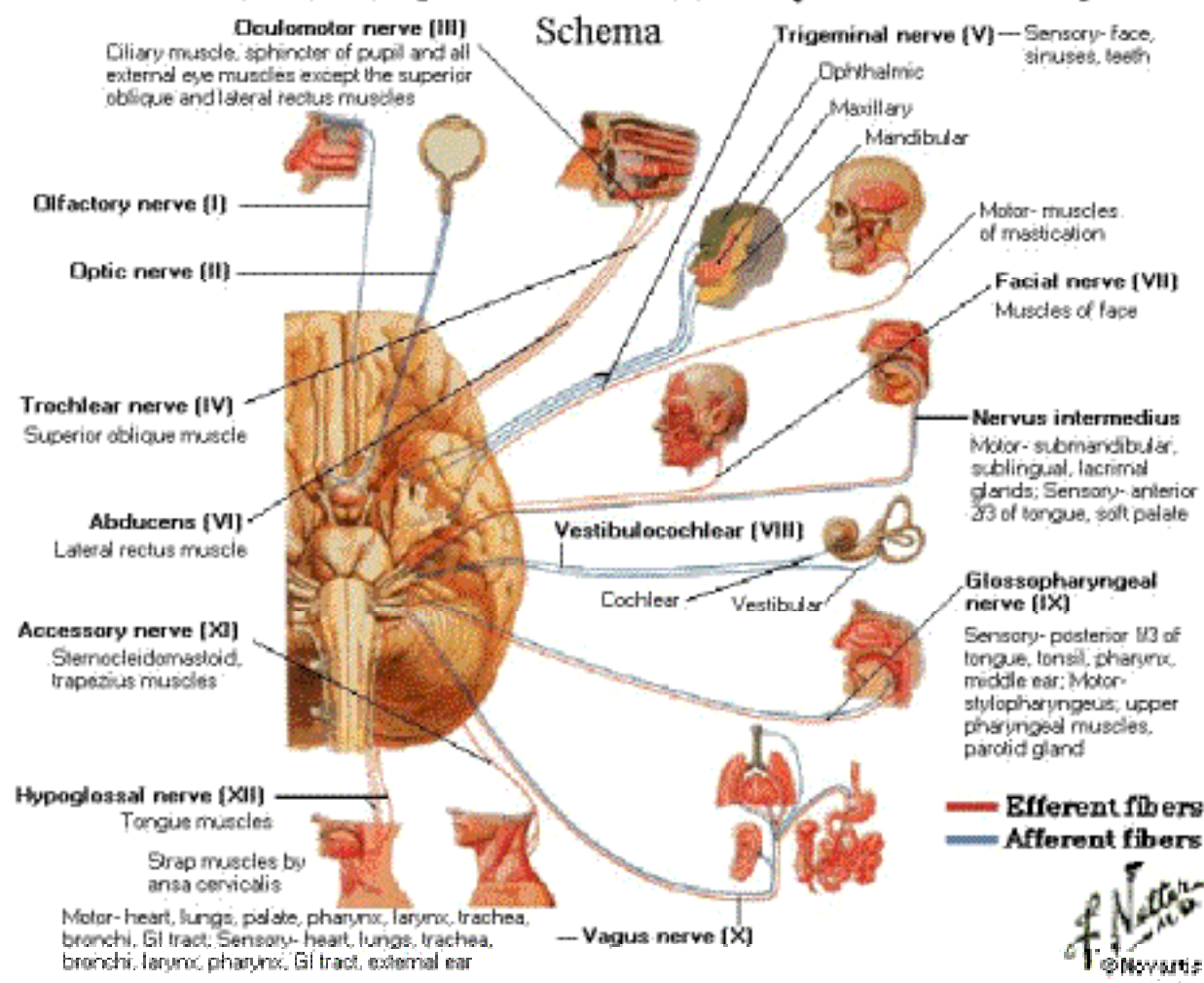
Schema - Medial Dissection



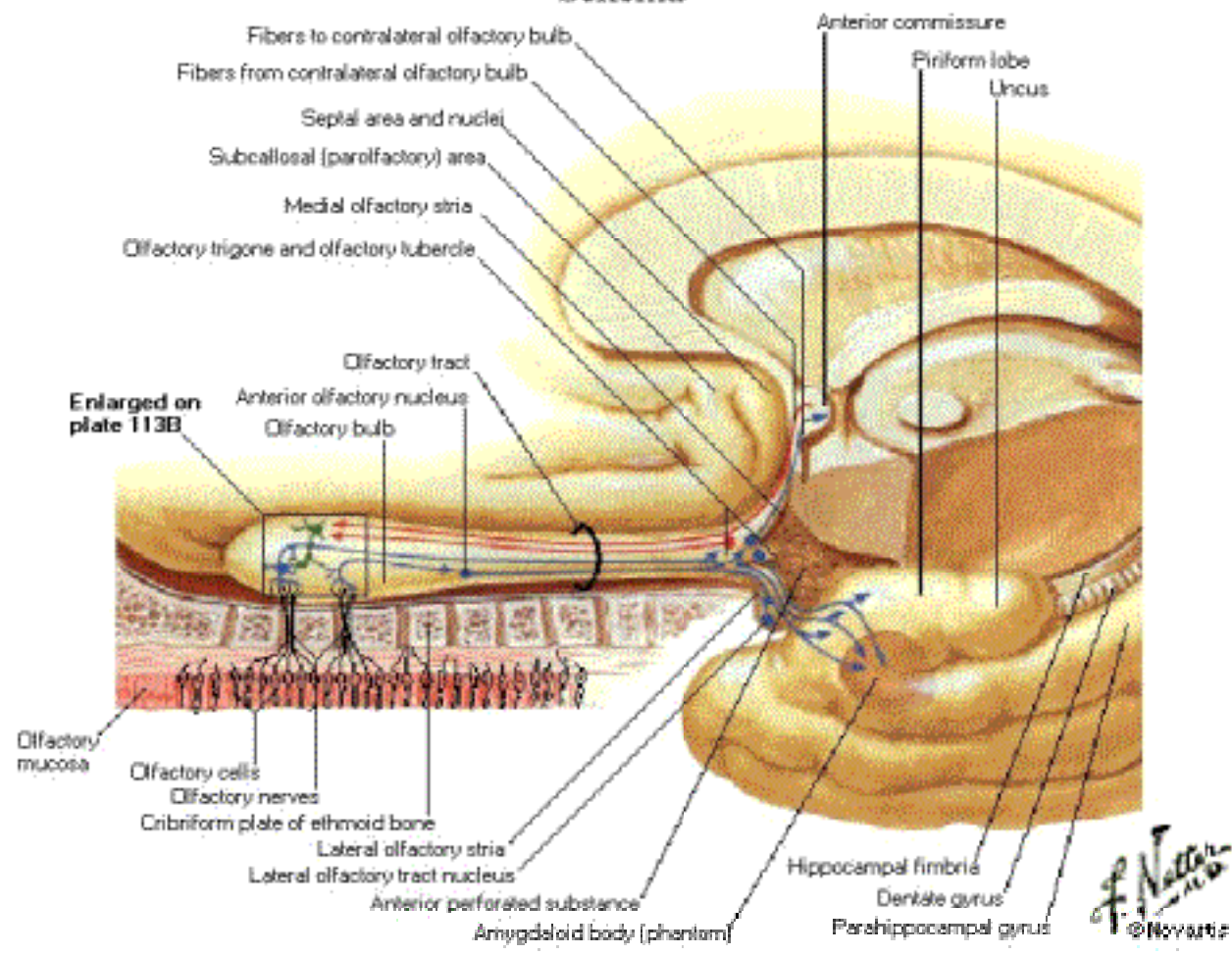
- Efferent fibers
- Afferent fibers
- Mixed fibers

F. N. N. N.
© Novartis

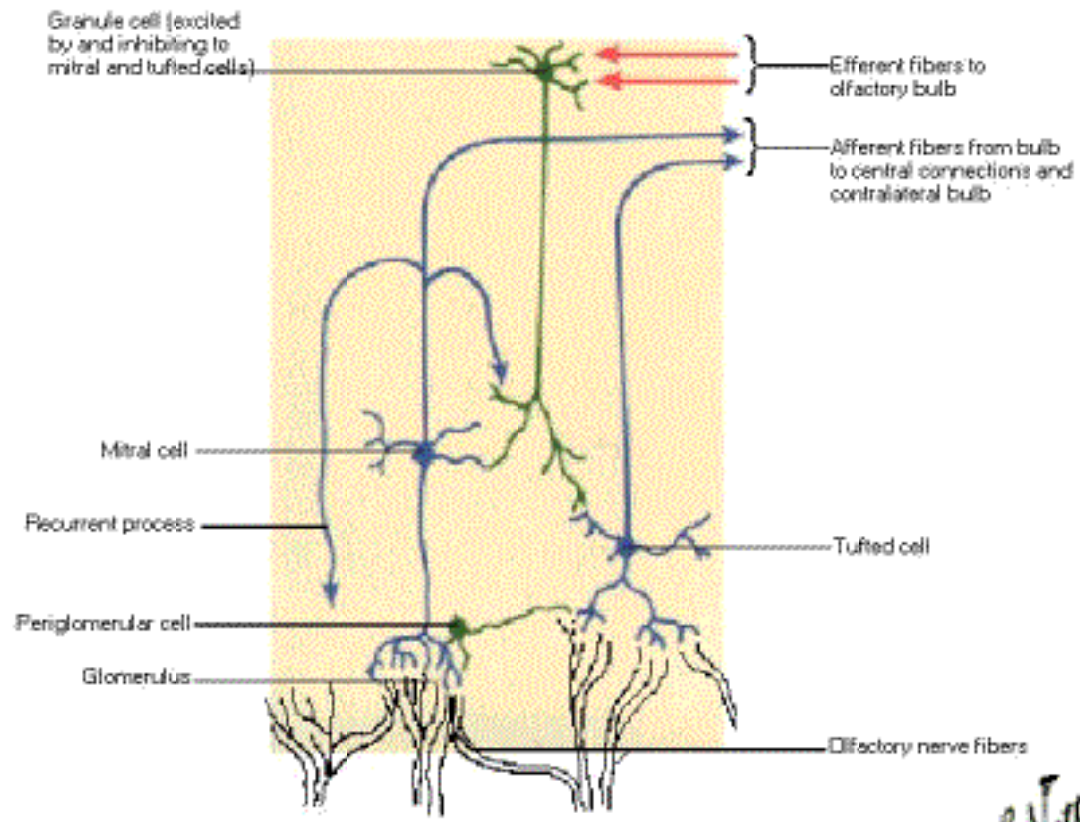
Cranial Nerves [Motor and Sensory Distribution]



Olfactory Nerve Schema



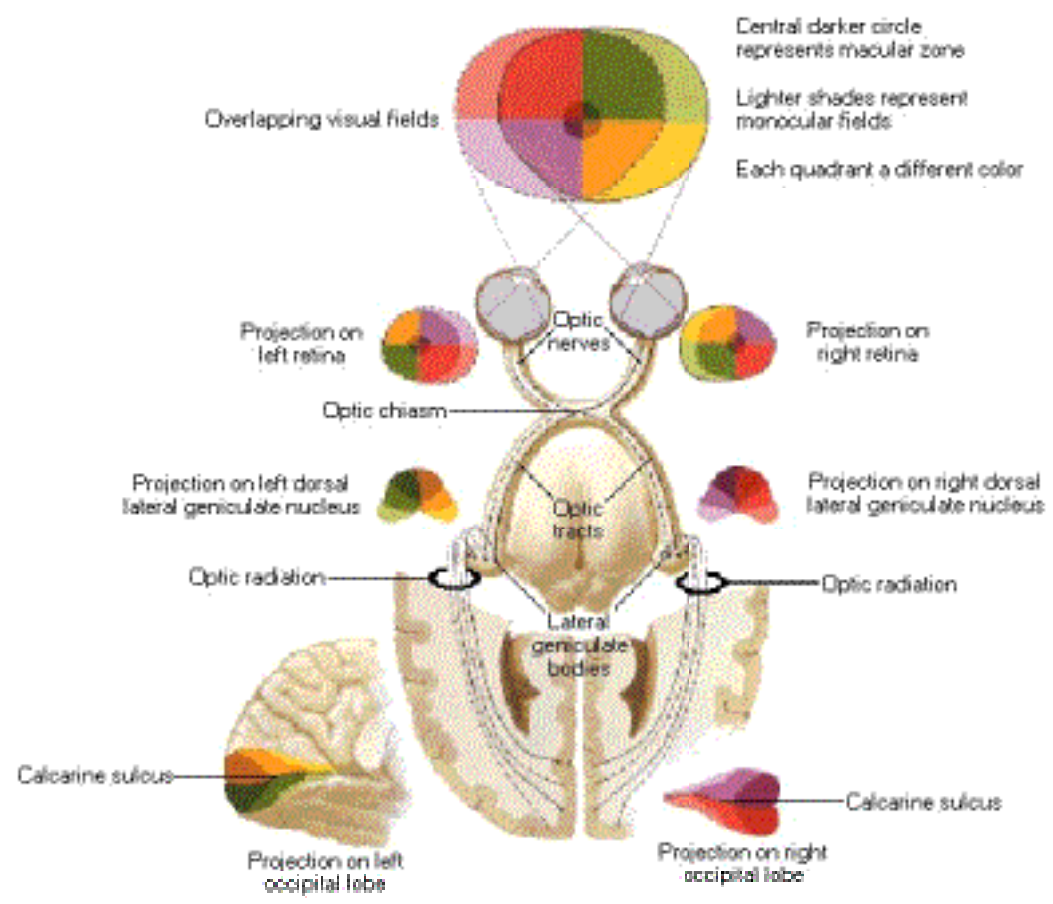
Olfactory Nerve - Olfactory Bulb Cells Schema



Schema of outlined area on plate 113A

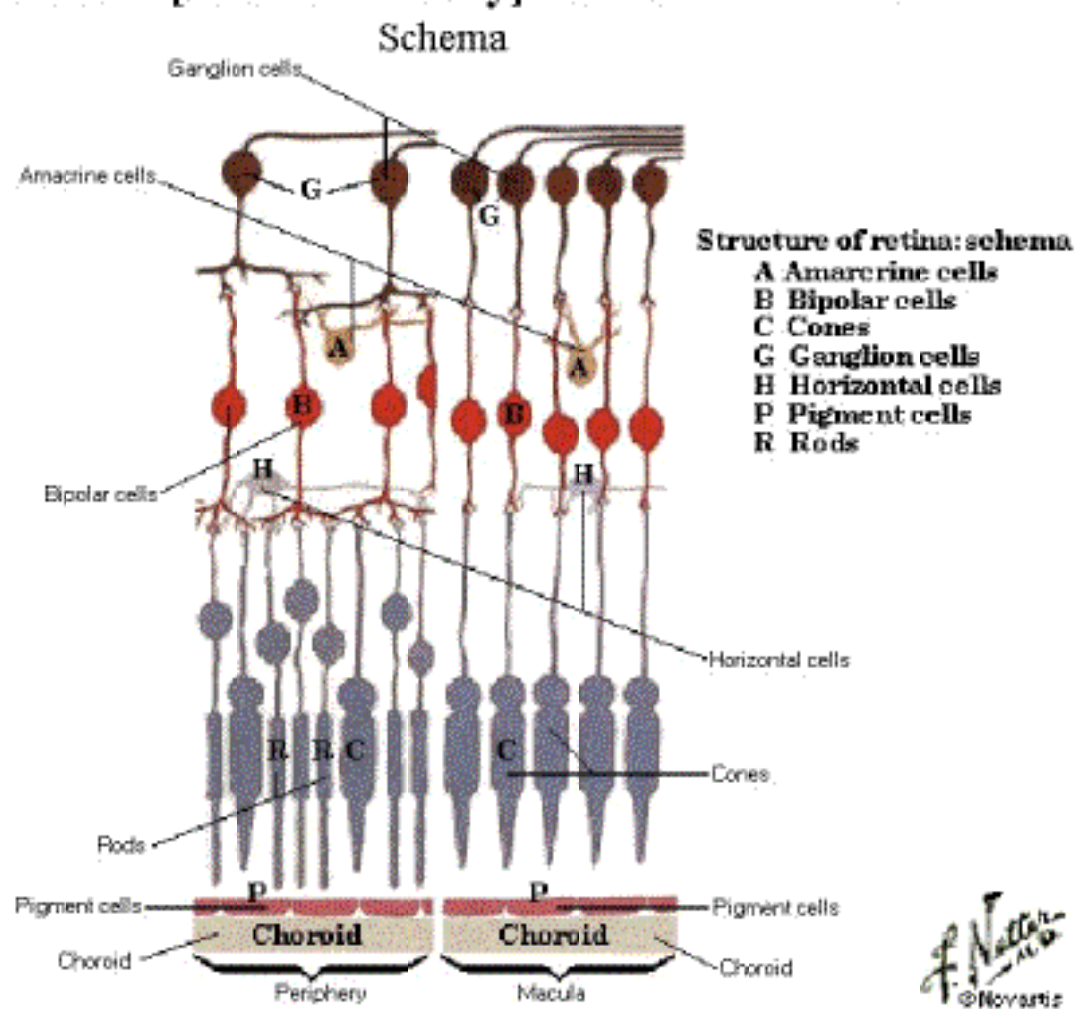
F. Natter
© Novartis

Optic Nerve [Visual Pathway] Schema



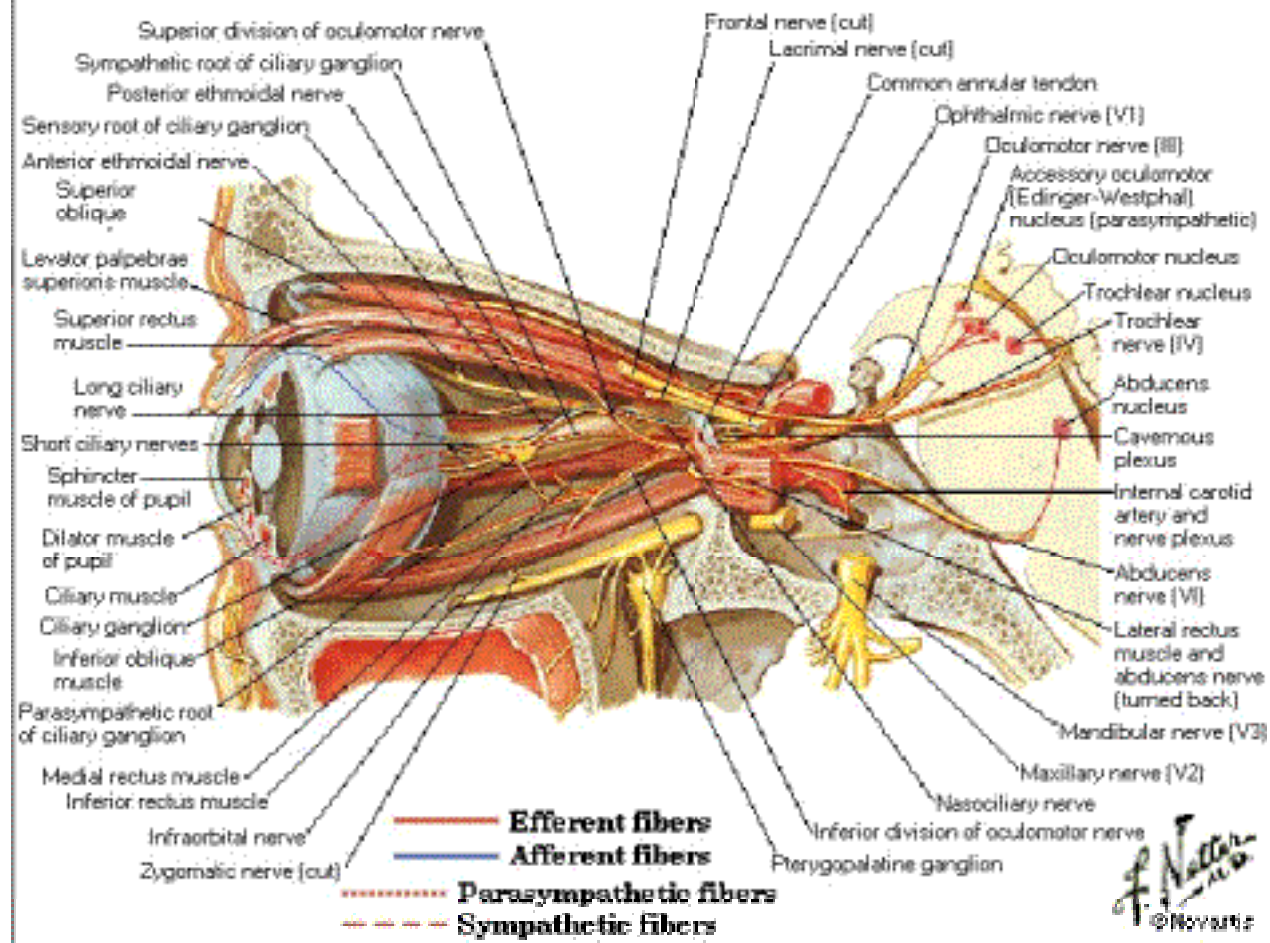
F. Netter M.D.
© Novartis

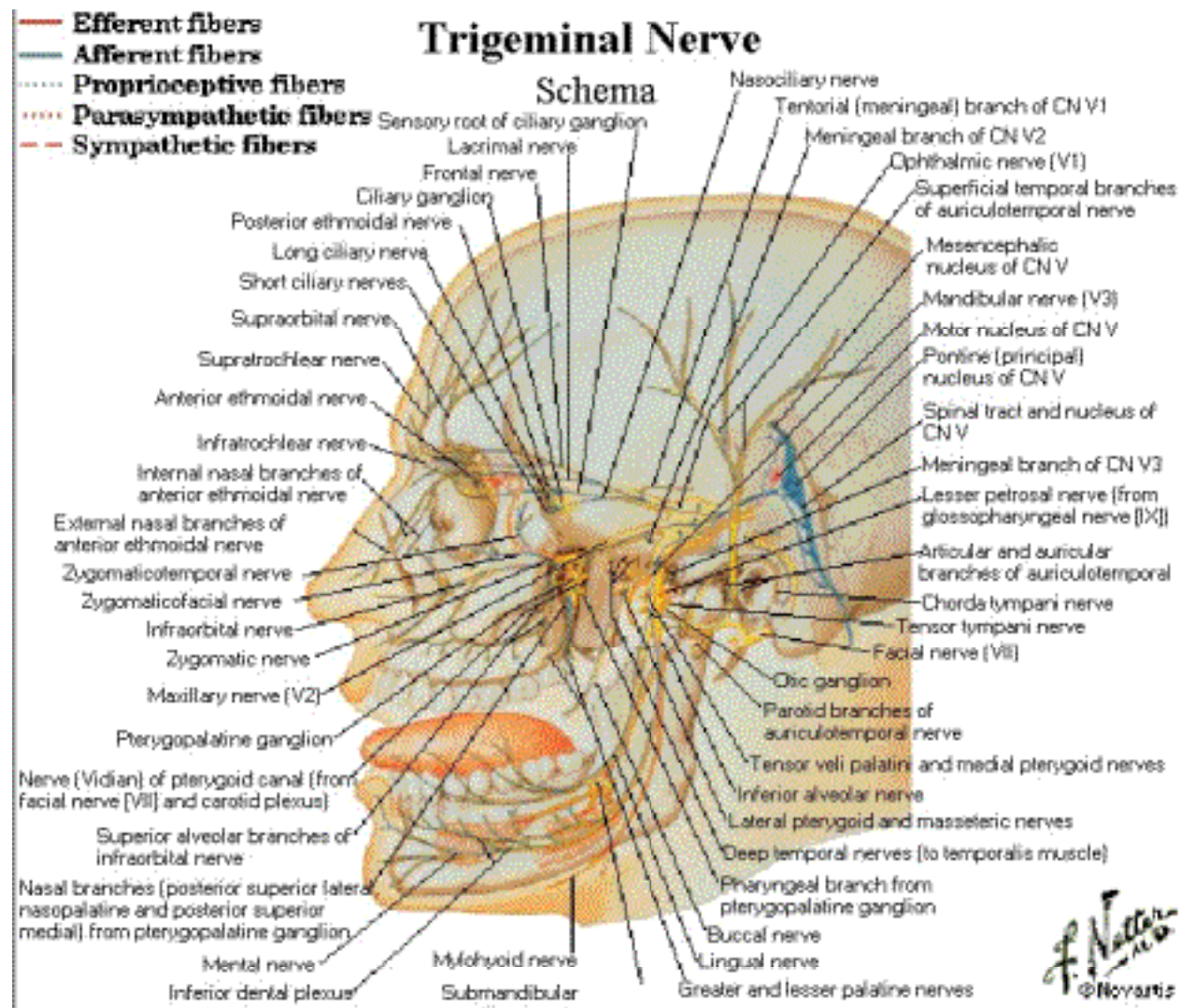
Optic Nerve [Visual Pathway] - Structure of Retina

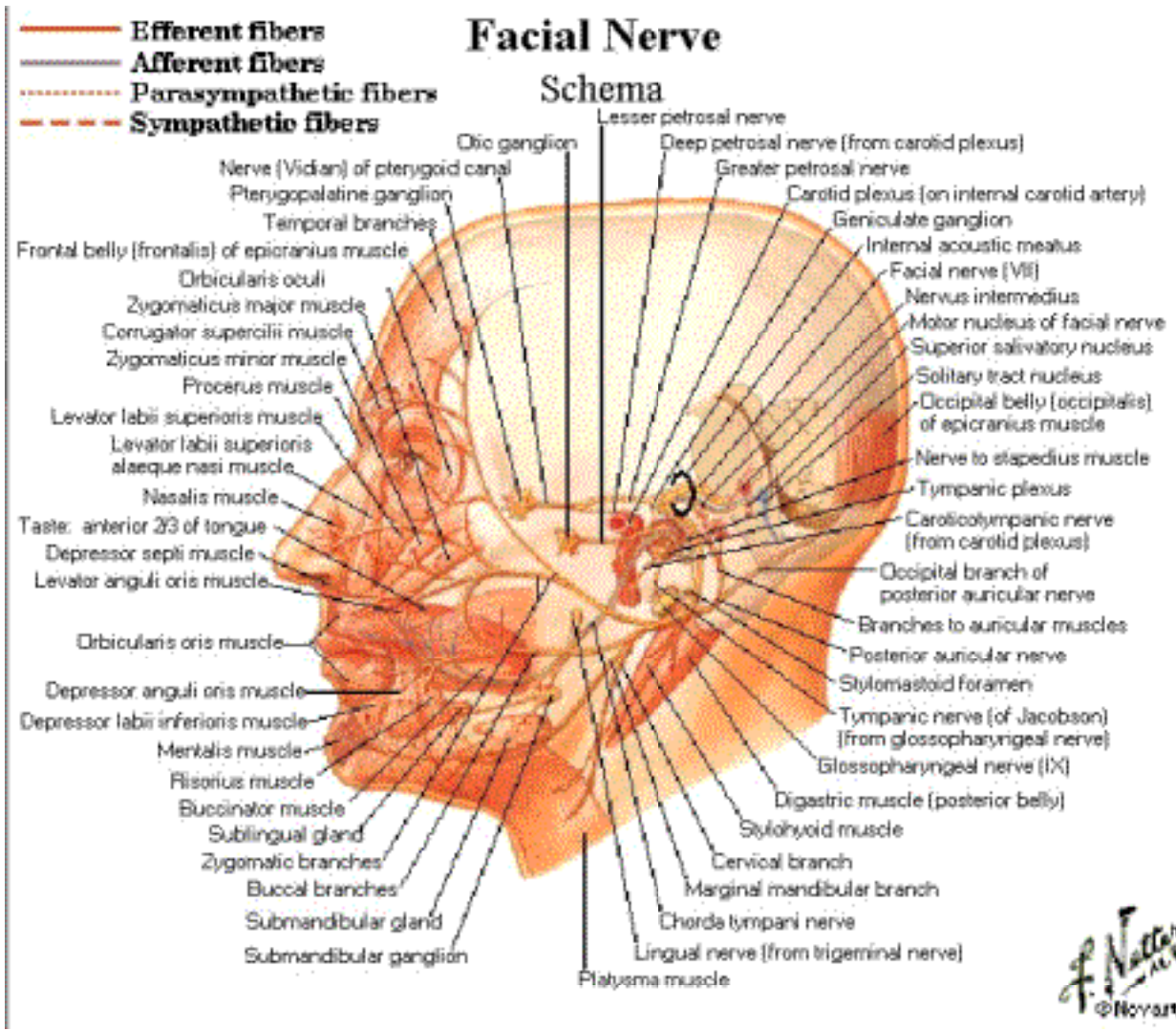


Oculomotor, Trochlear and Abducens Nerves

Schema

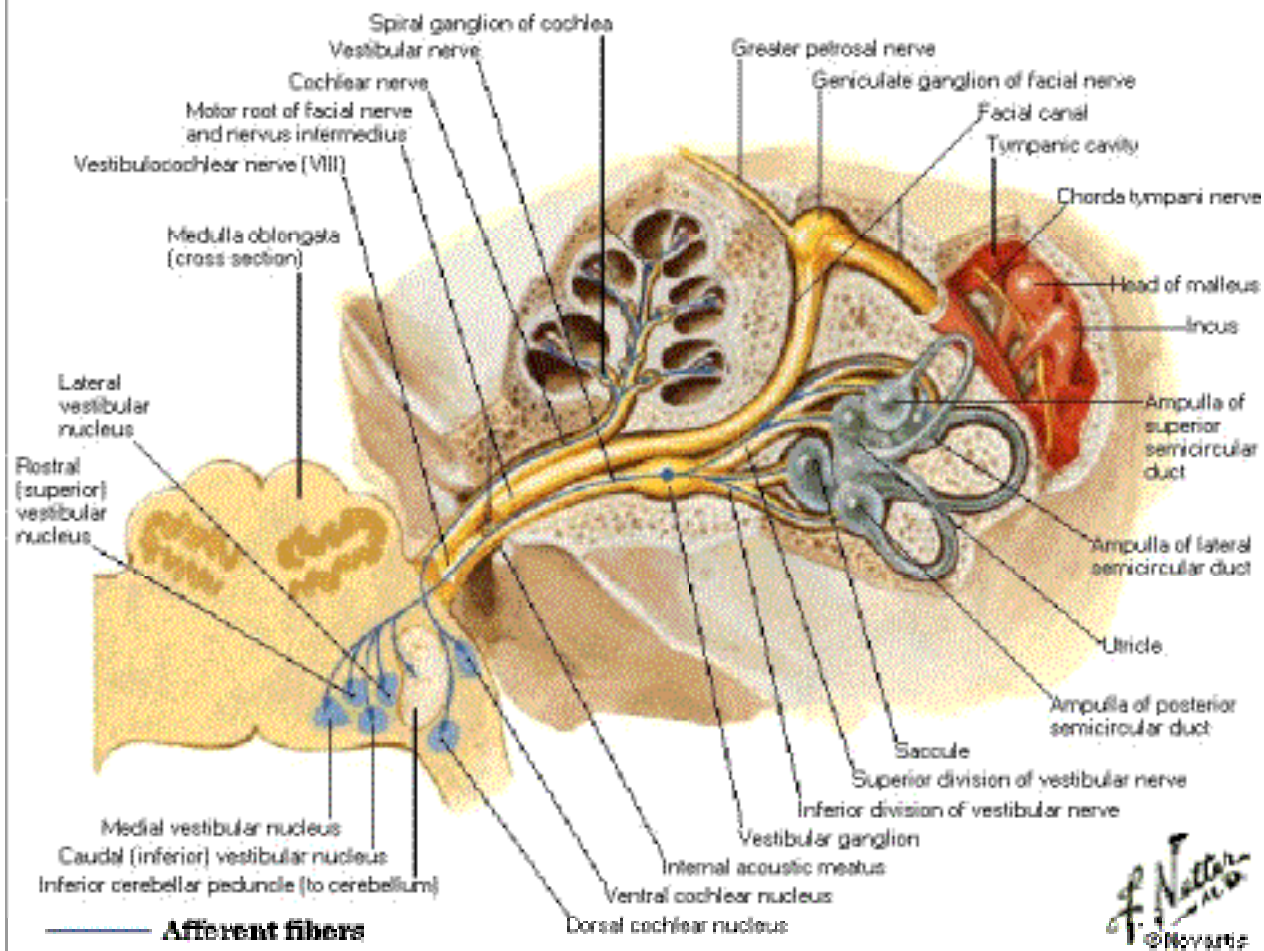






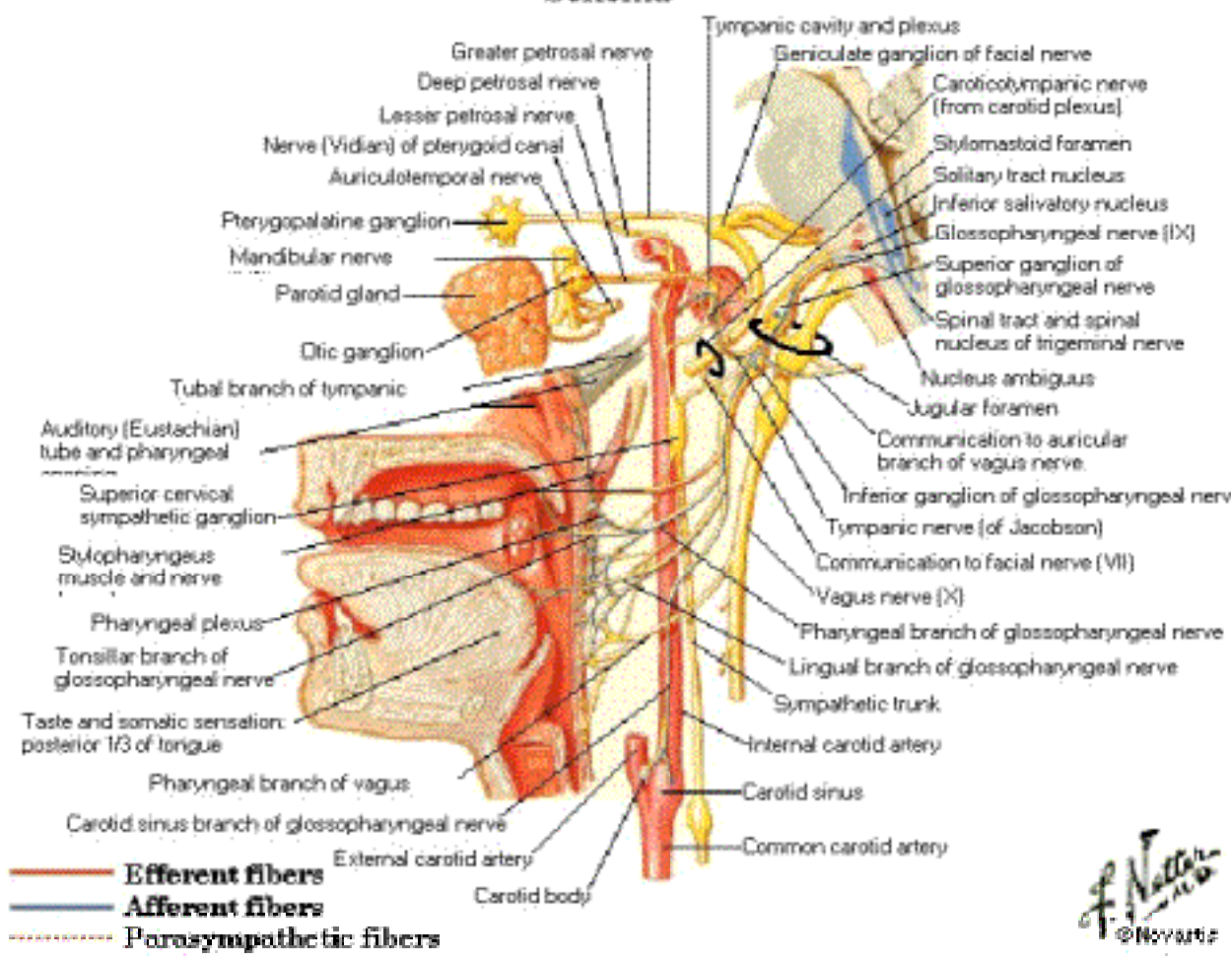
Vestibulocochlear Nerve

Schema



Glossopharyngeal Nerve

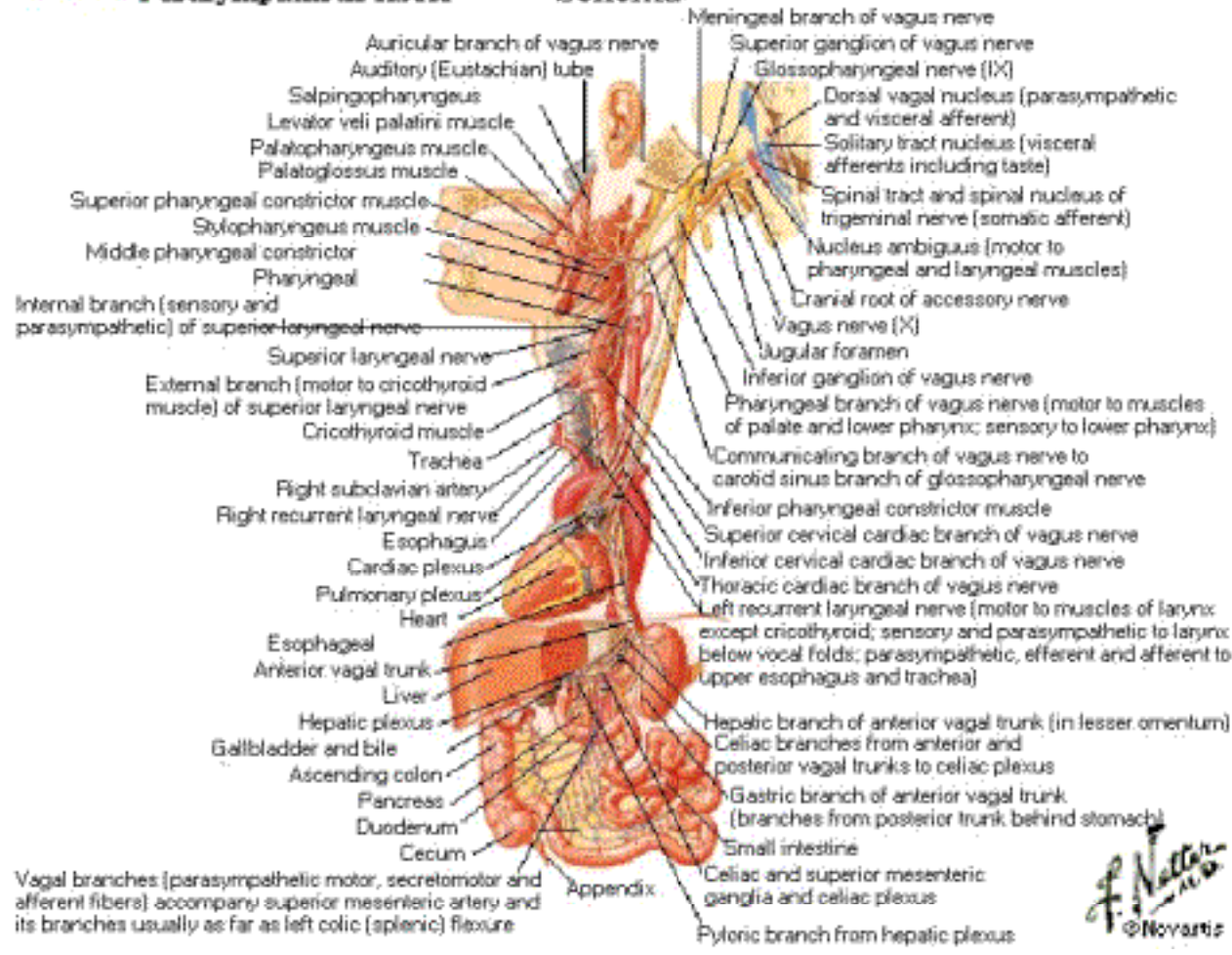
Schema



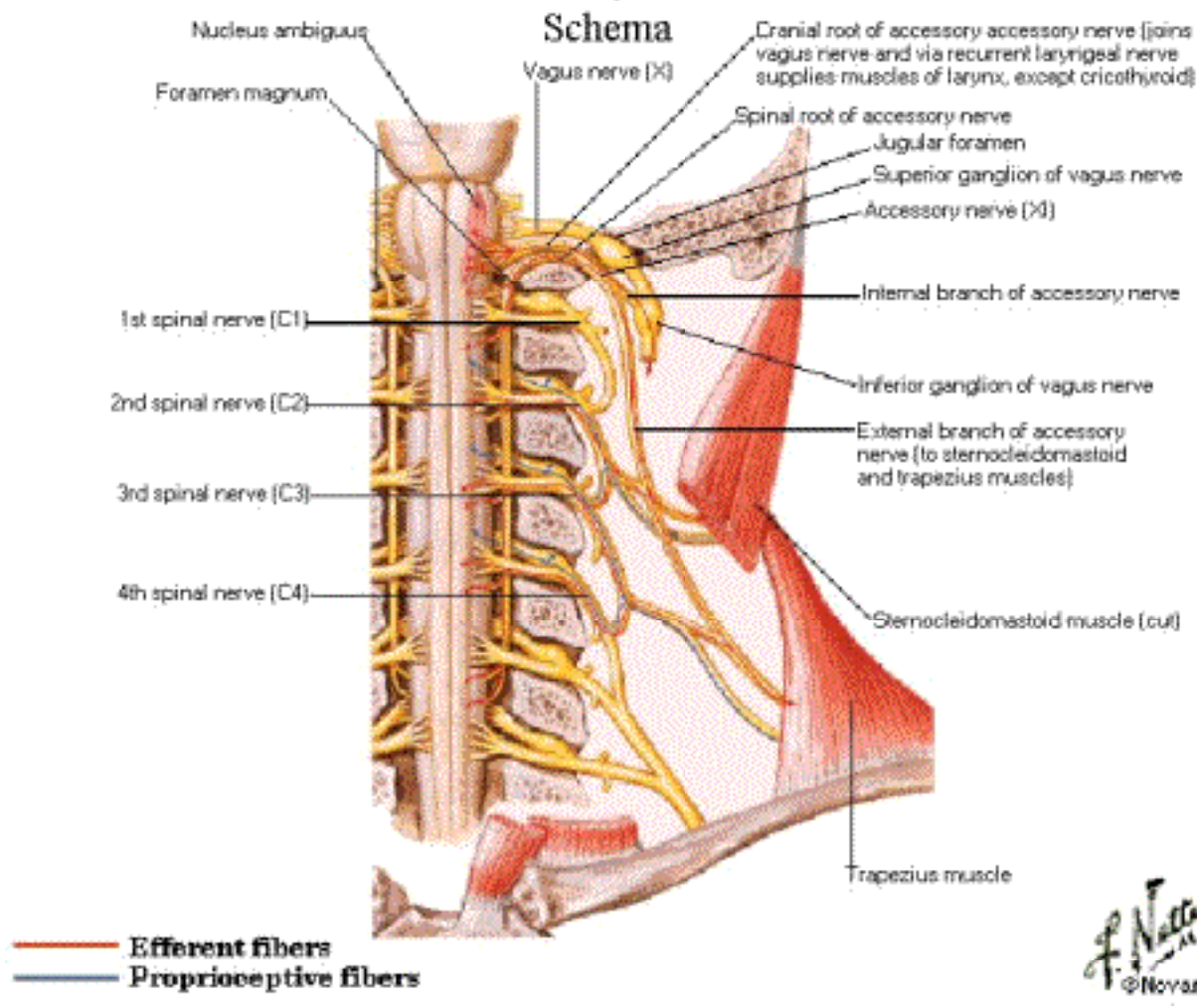
F. N. N. N.
 © Novartis

- Efferent fibers
- Afferent fibers
- - - - - Parasympathetic fibers

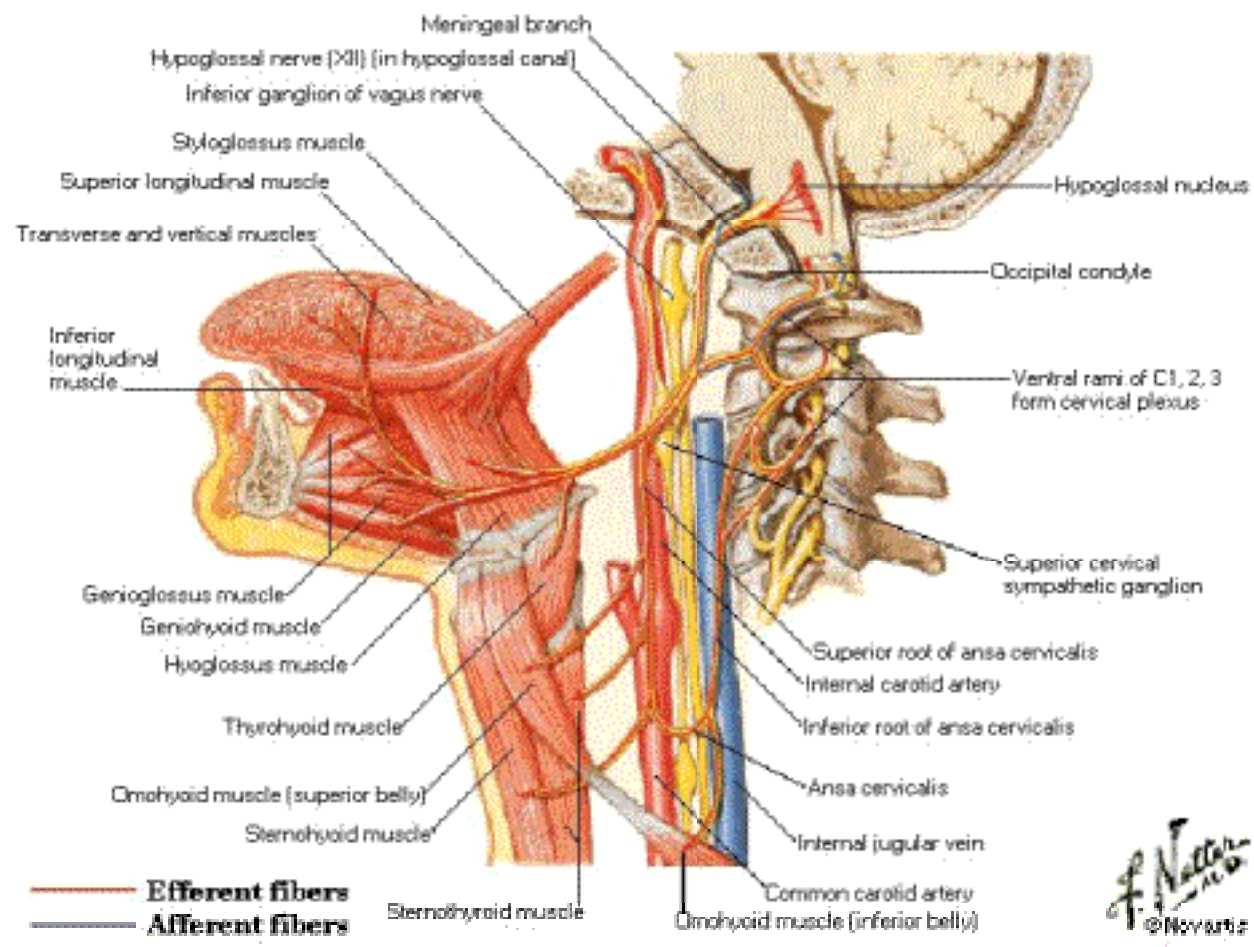
Vagus Nerve Schema



Accessory Nerve

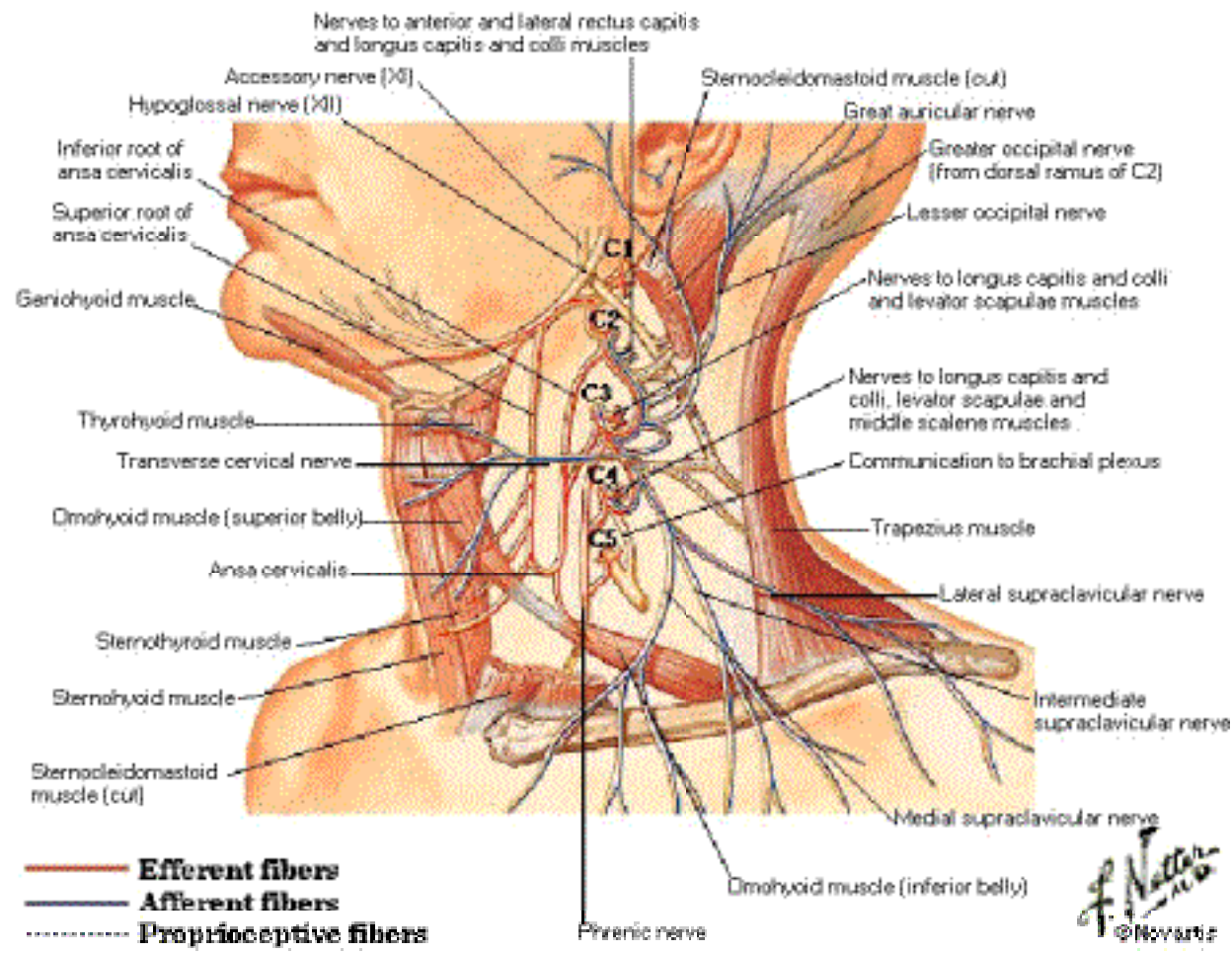


Hypoglossal Nerve Schema

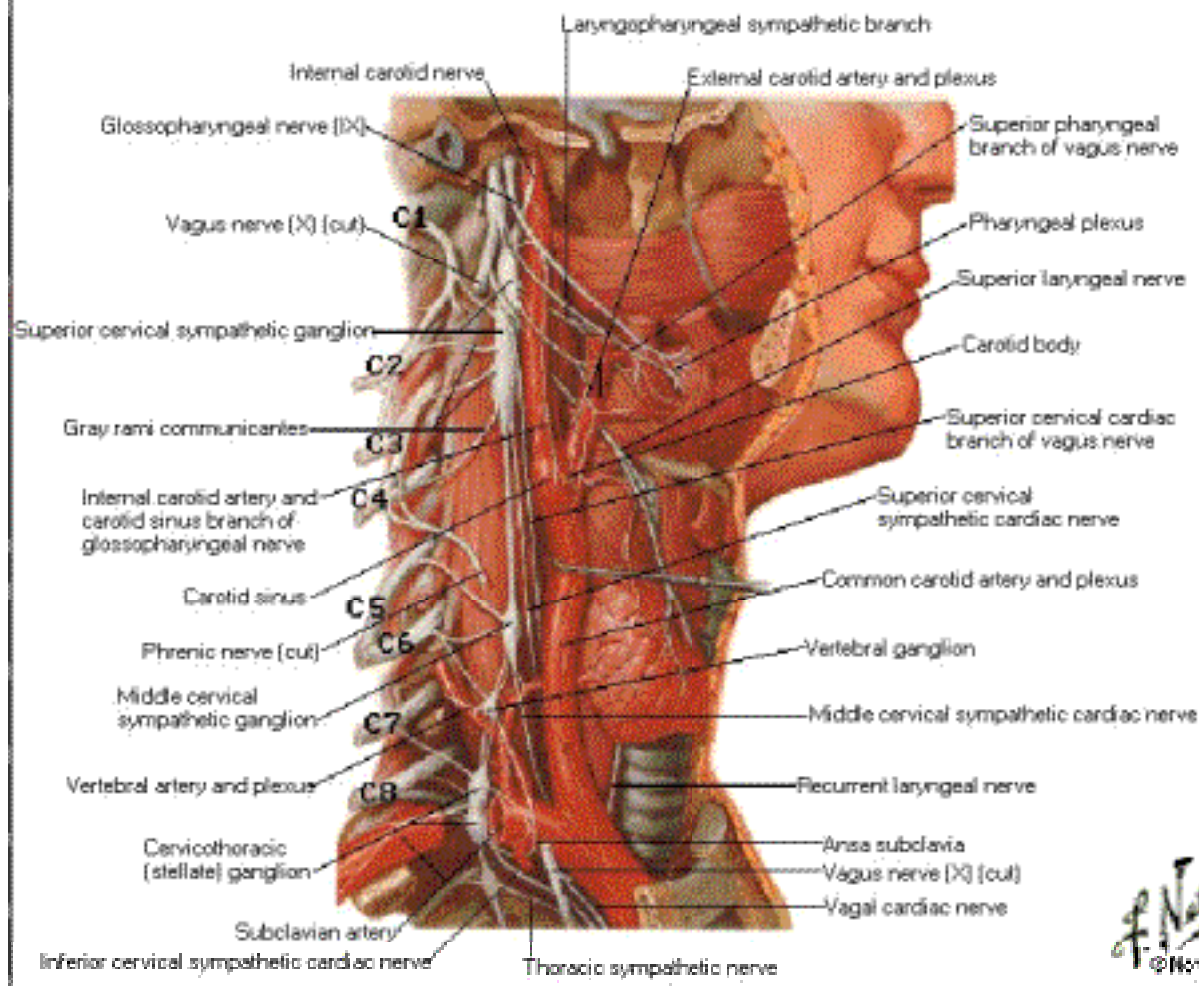


Cervical Plexus

Schema

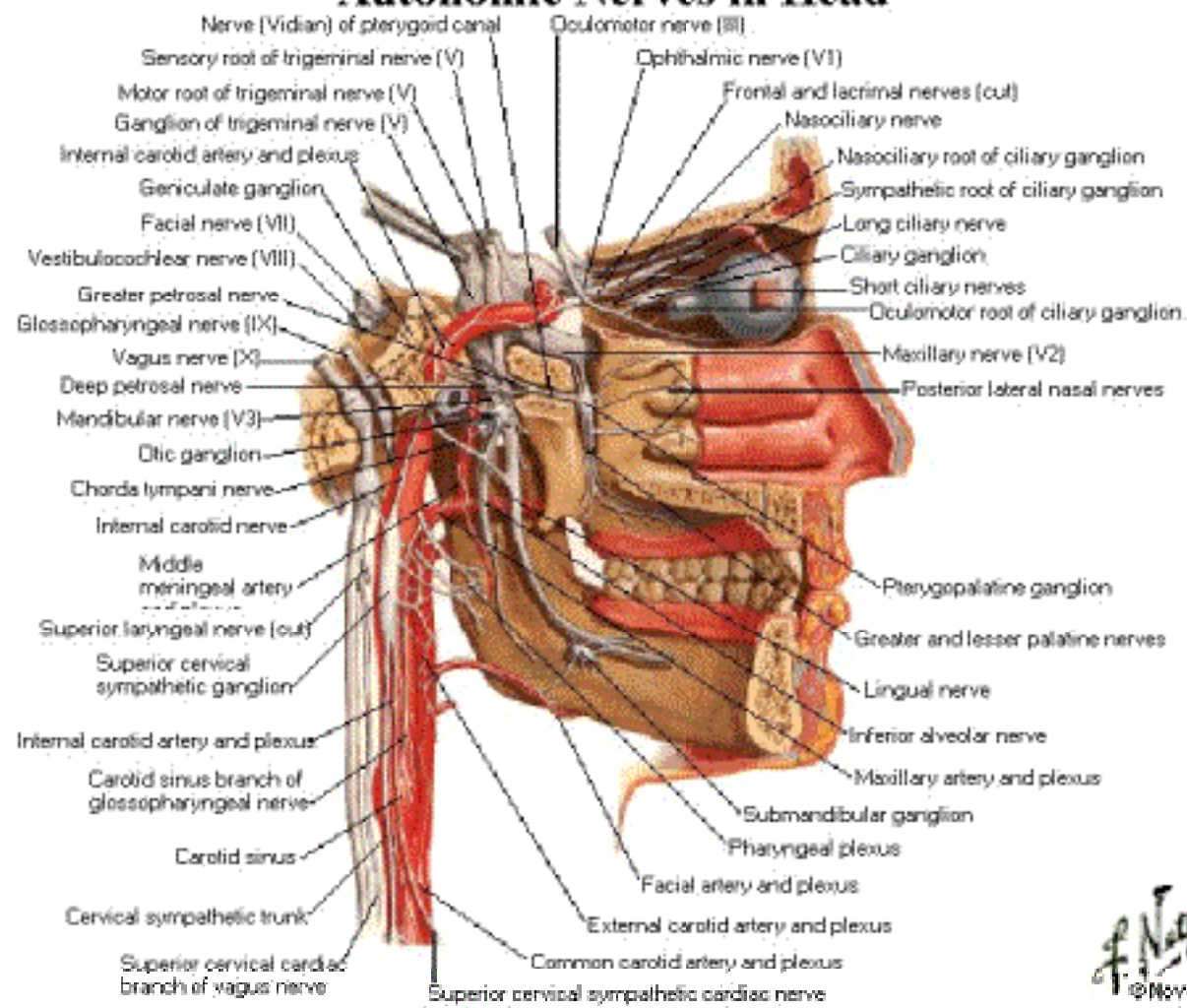


Autonomic Nerves in Neck



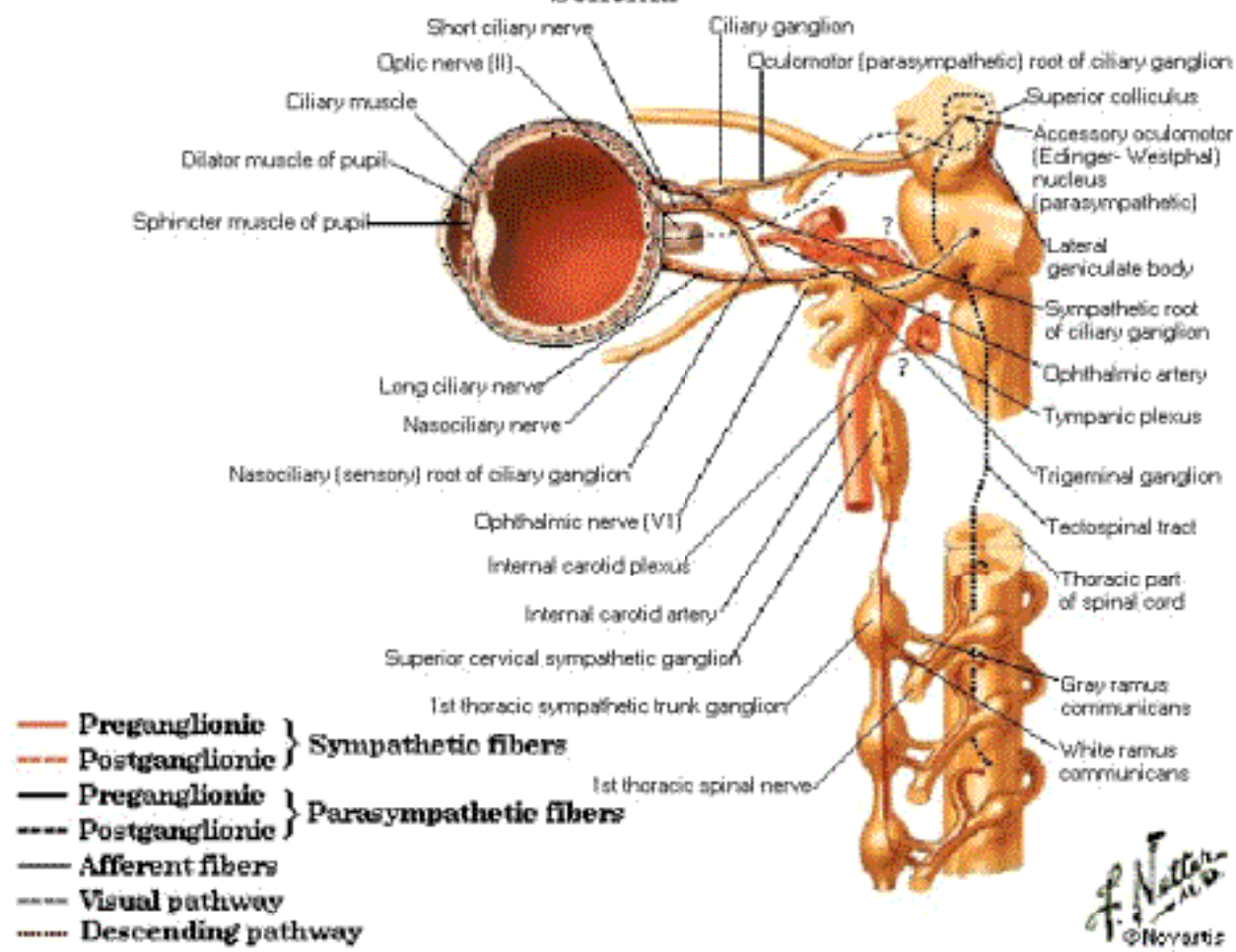
F. Netter M.D.
© 1996

Autonomic Nerves in Head



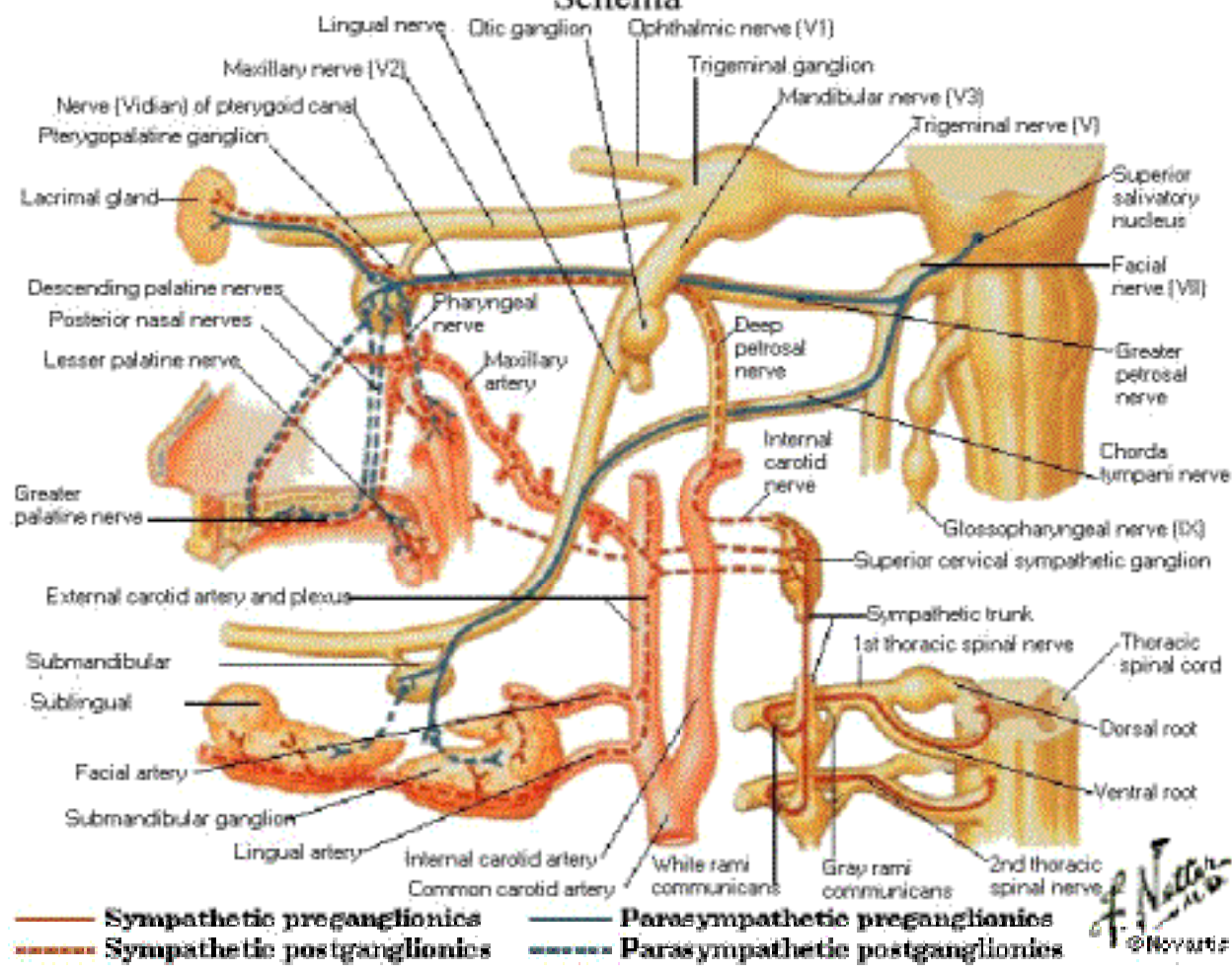
F. Netter
 © 1956

Ciliary Ganglion Schema



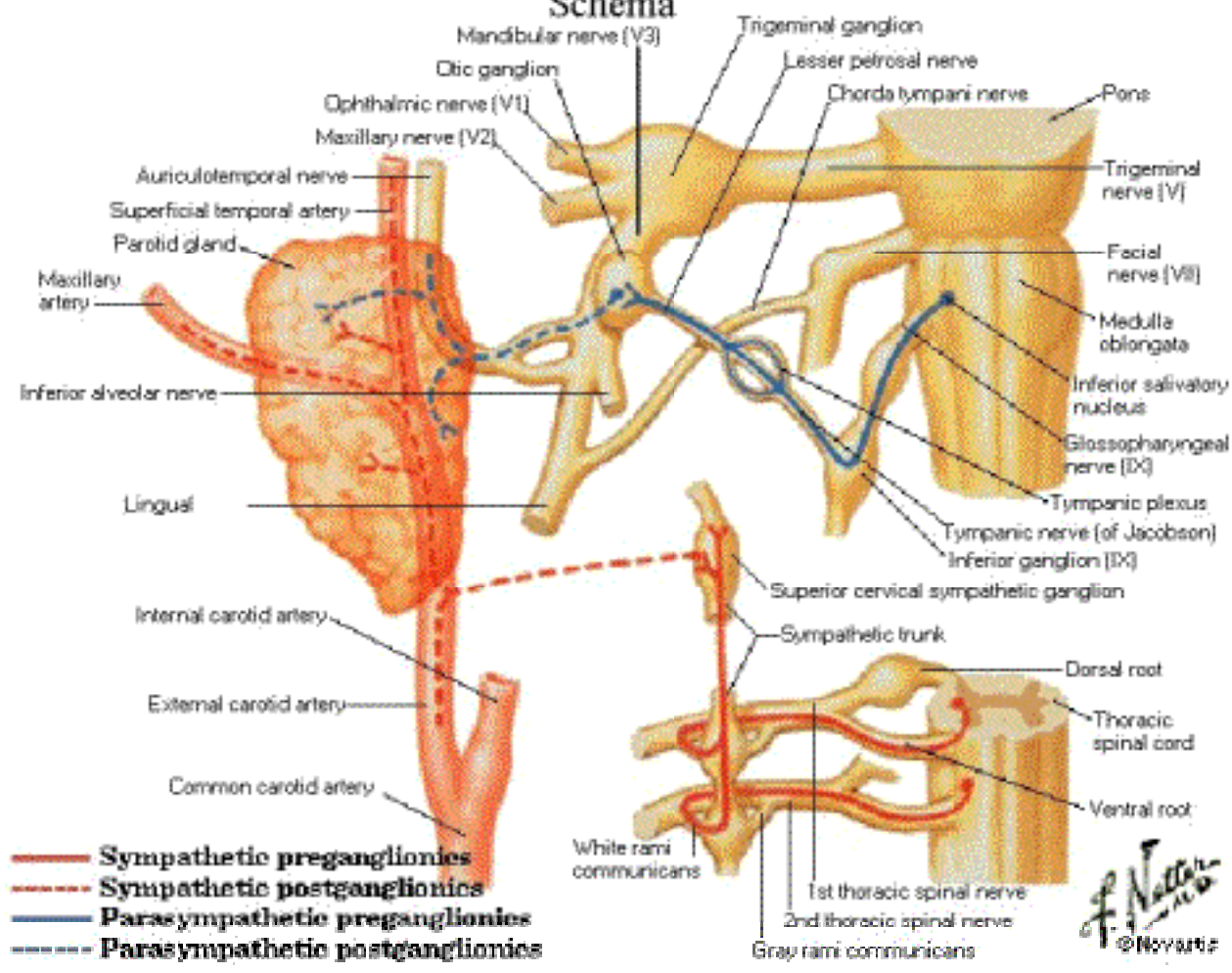
Pterygopalatine and Submandibular Ganglia

Schema



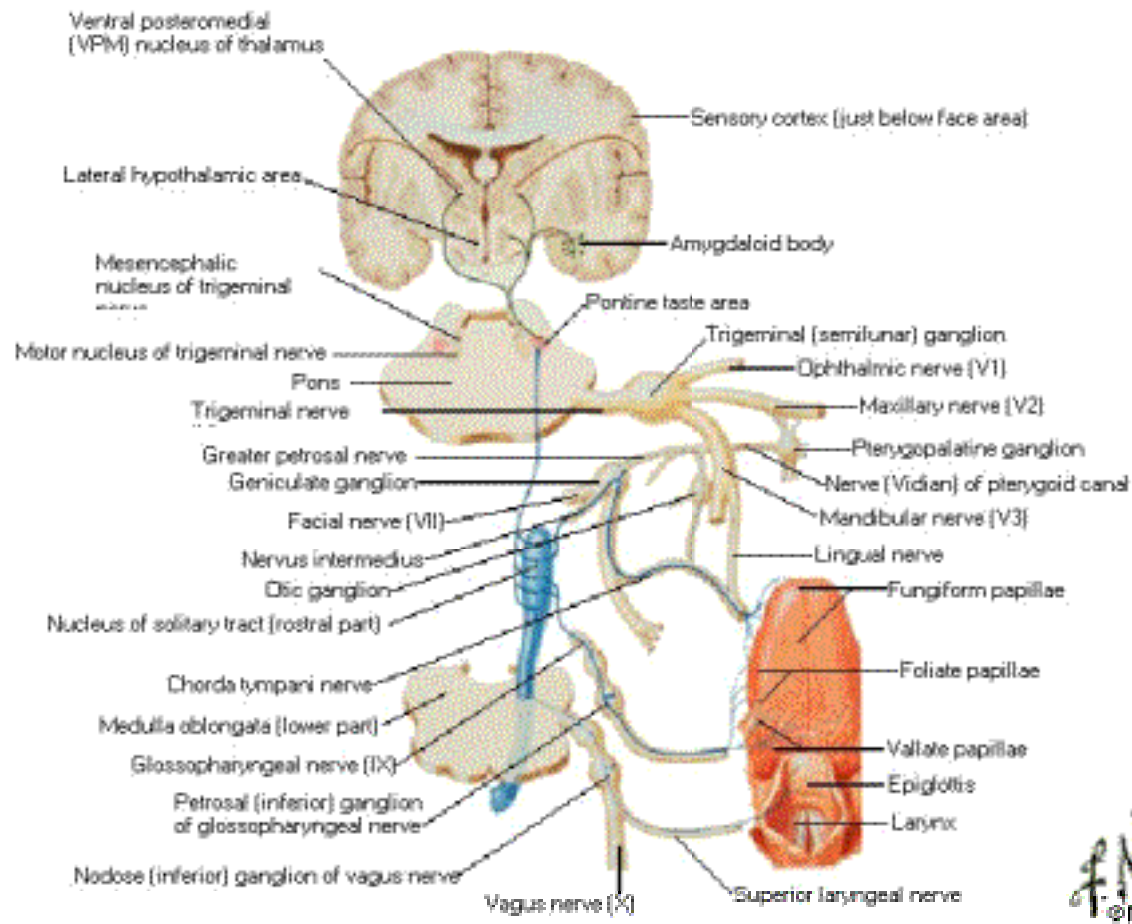
Otic Ganglion

Schema



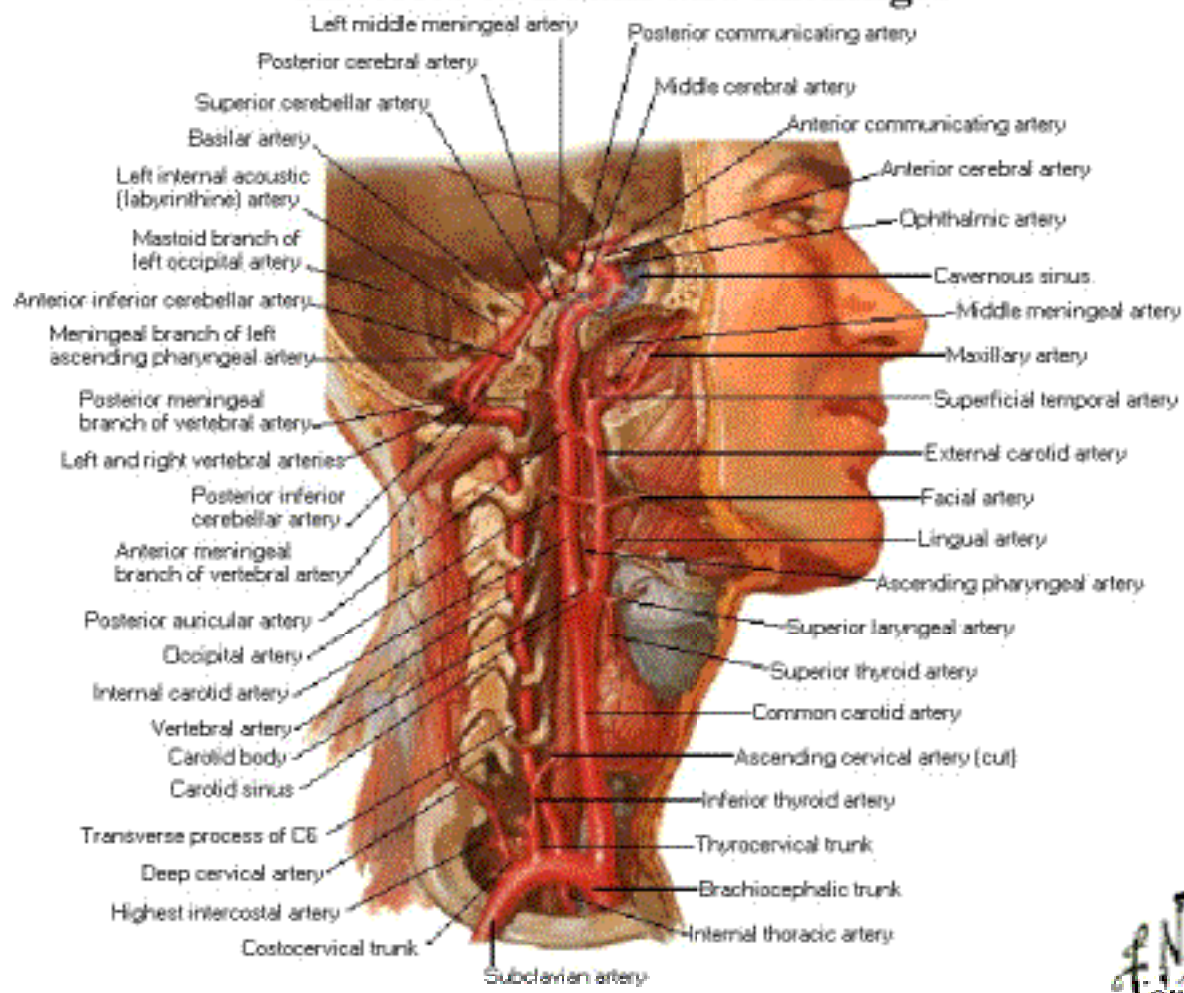
Taste Pathways Schema

— Usual pathway
- - - Accessory pathway



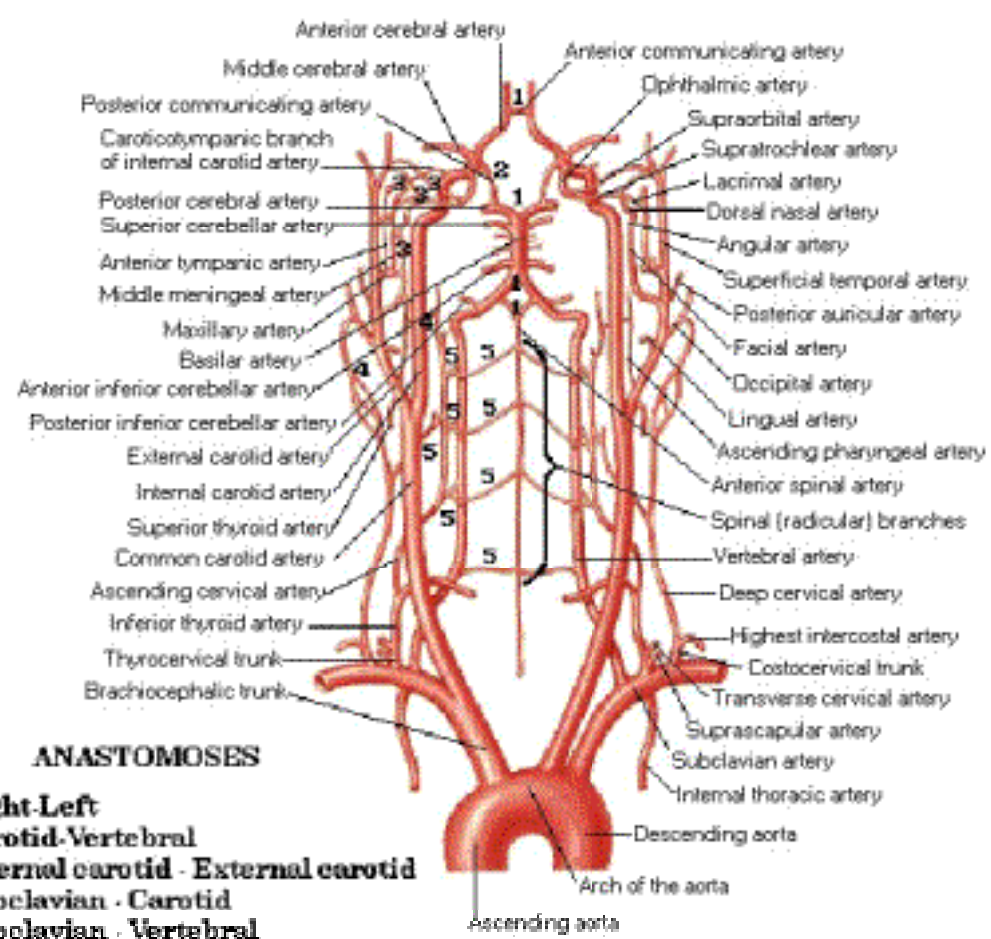
F. Netter M.D.
© 2007 Netter

Arteries to Brain and Meninges



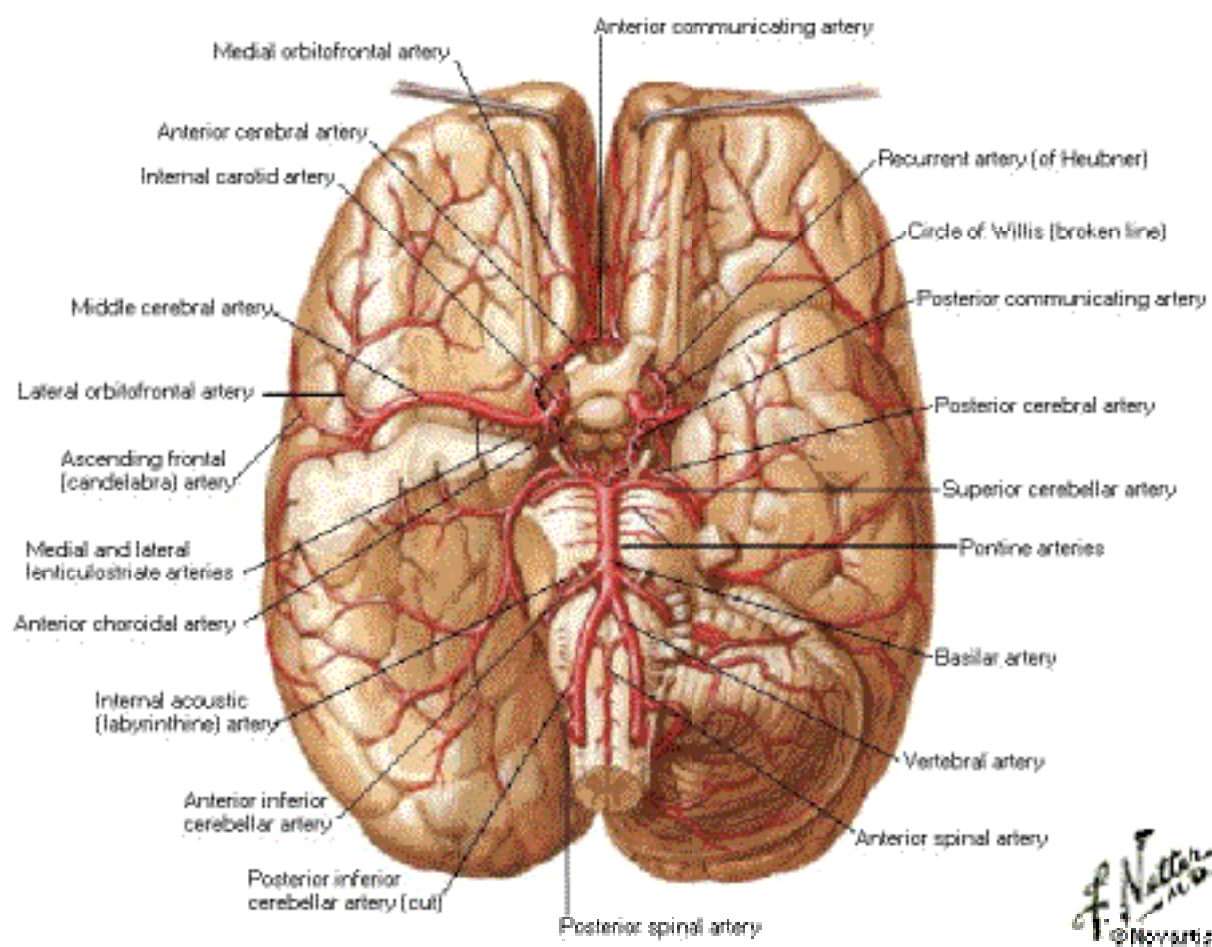
F. Netter
M.D.
© Novartis

Arteries to Brain Schema



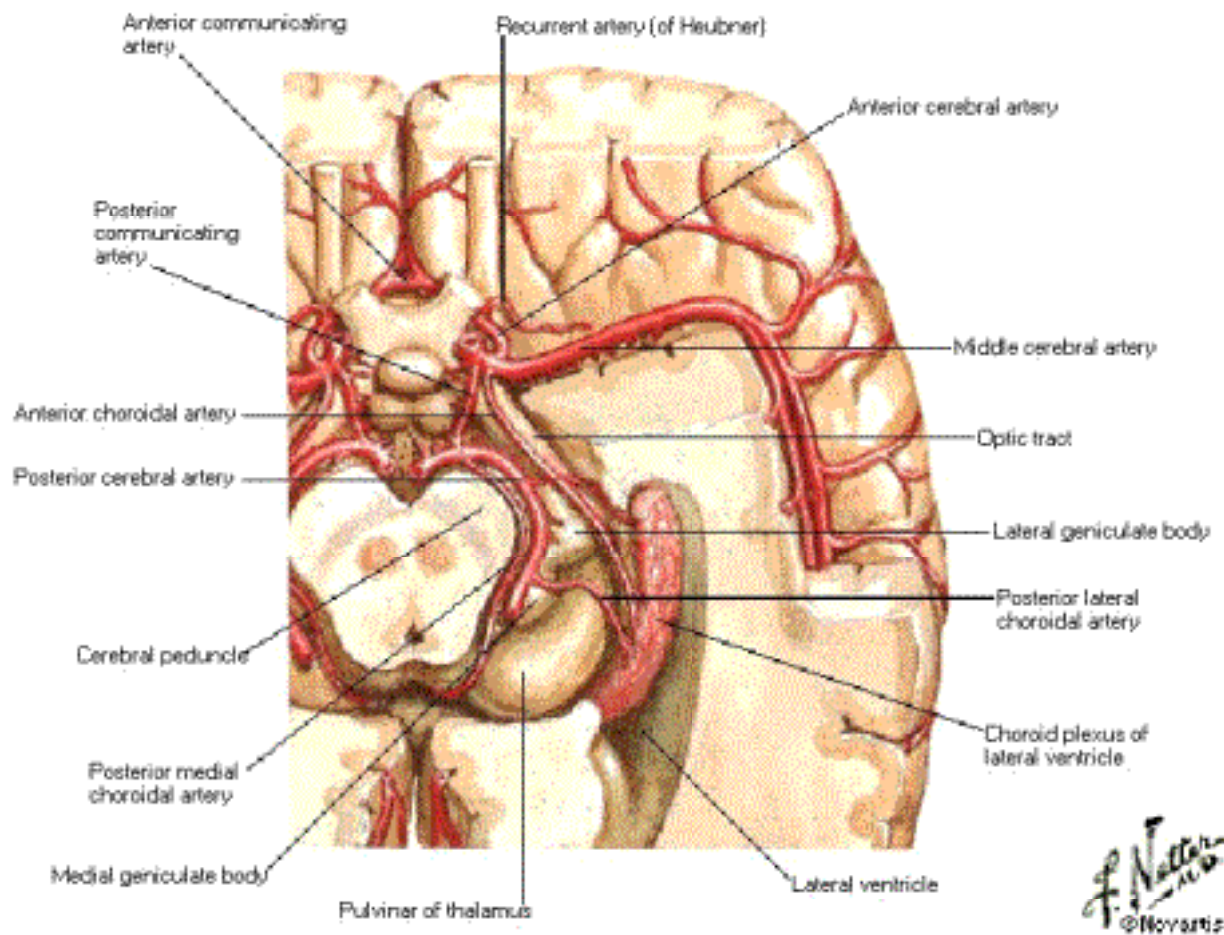
Arteries of Brain

Inferior View



Arteries of Brain [Continued]

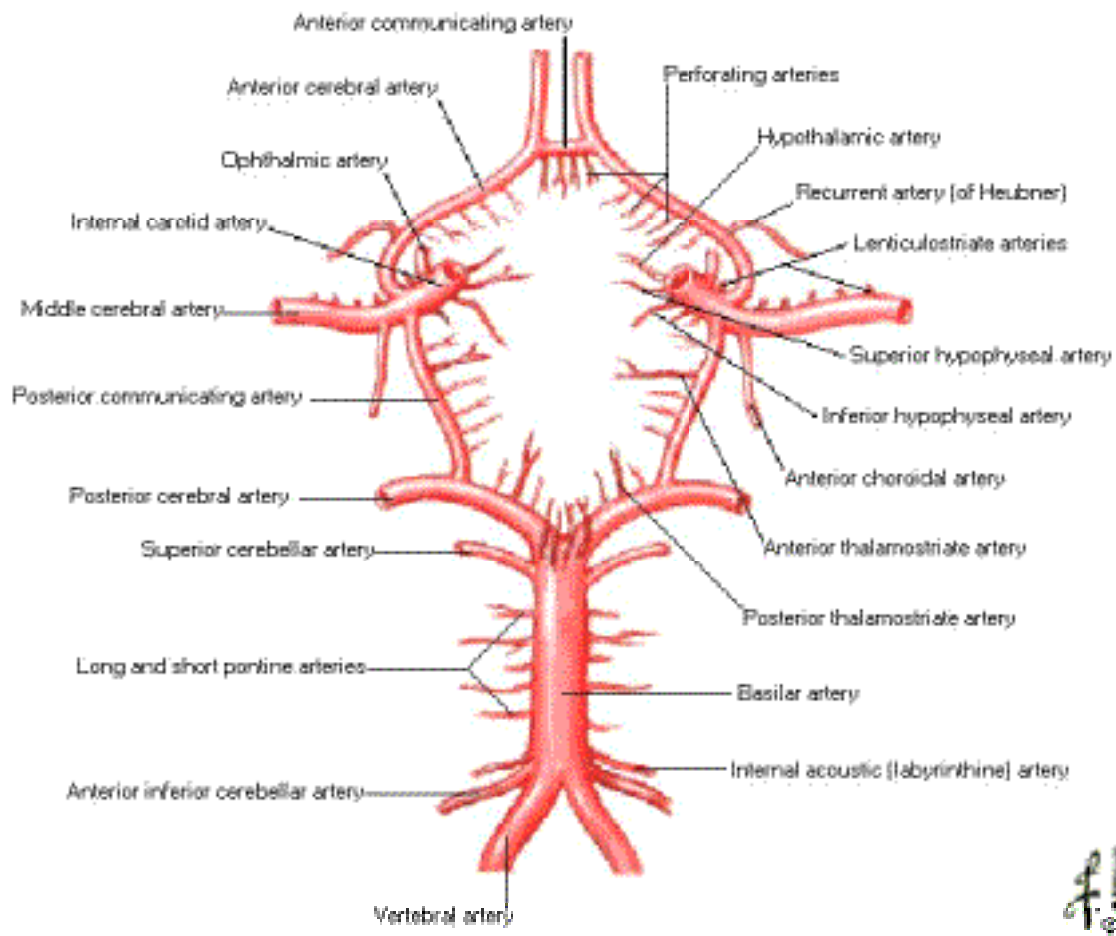
Inferior View



F. Netter M.D.
© Novartis

Circle of Willis - Vessels Dissected Out

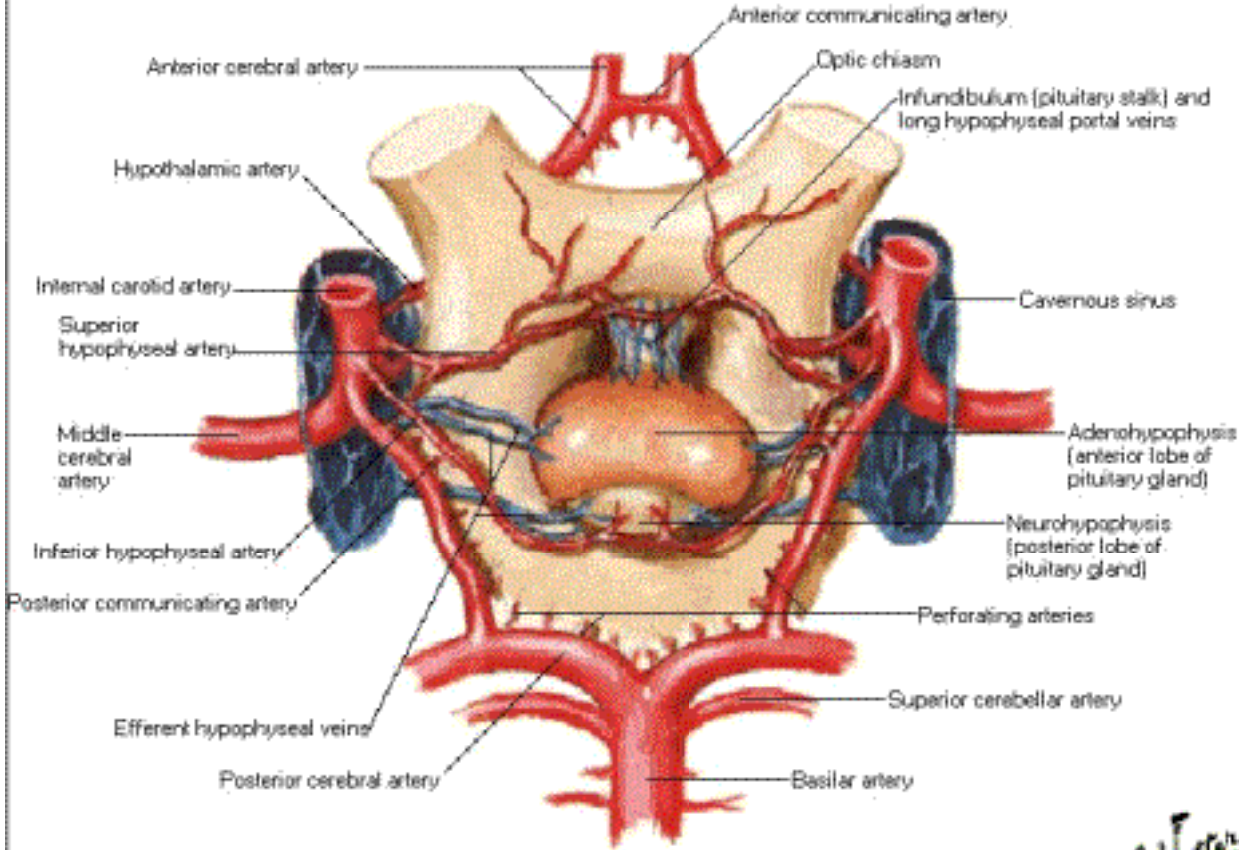
Inferior View



F. Netter M.D.
© 1996

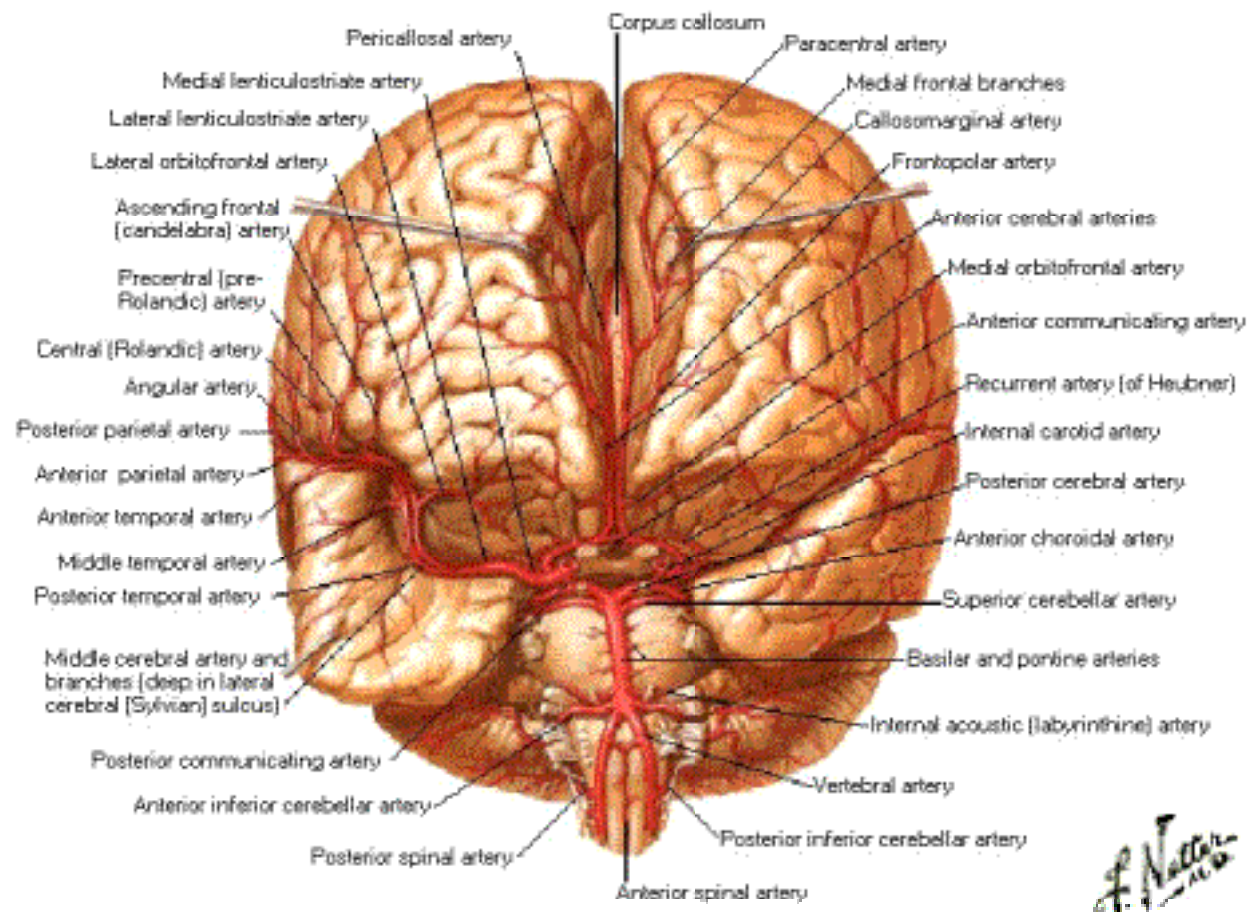
Circle of Willis - Vessels in Situ

Inferior View

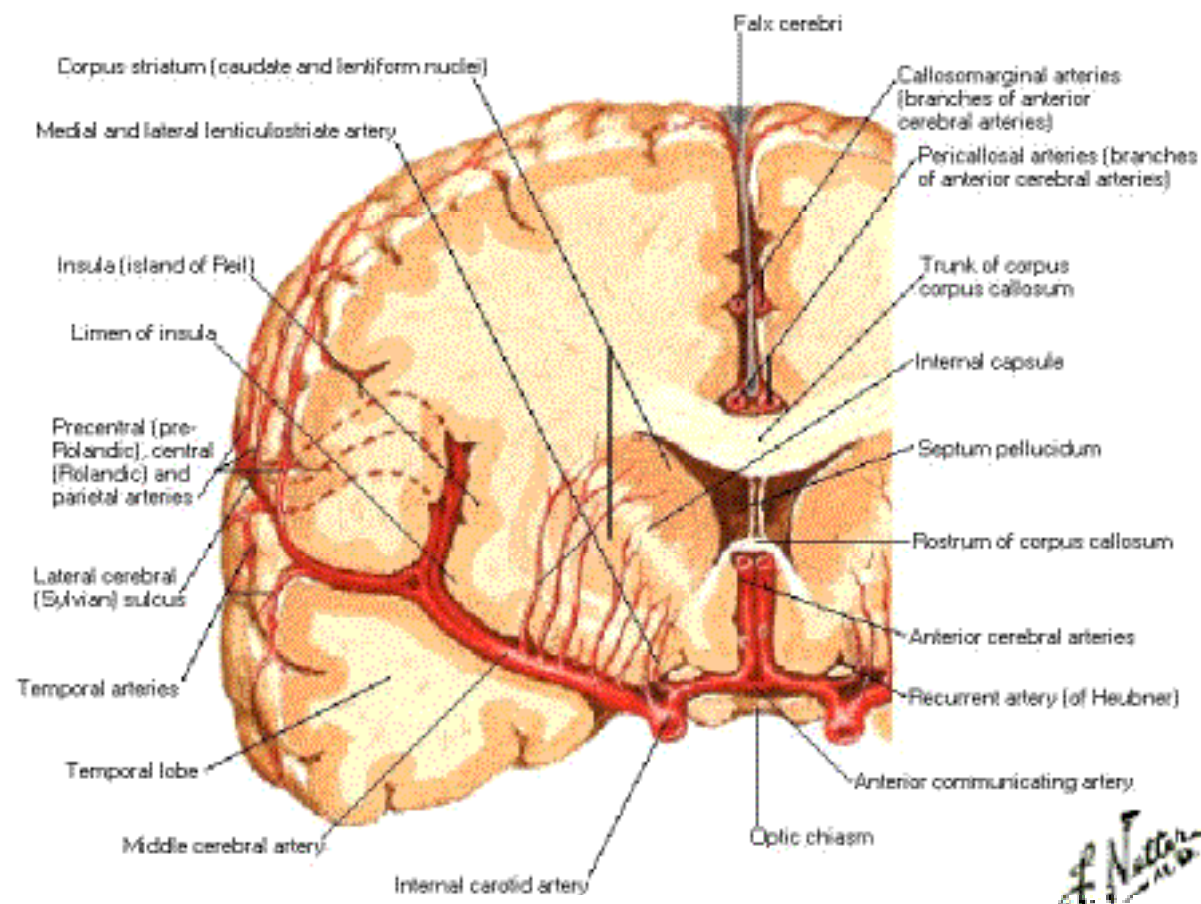


F. Netter
© Novartis

Arteries of Brain Frontal View

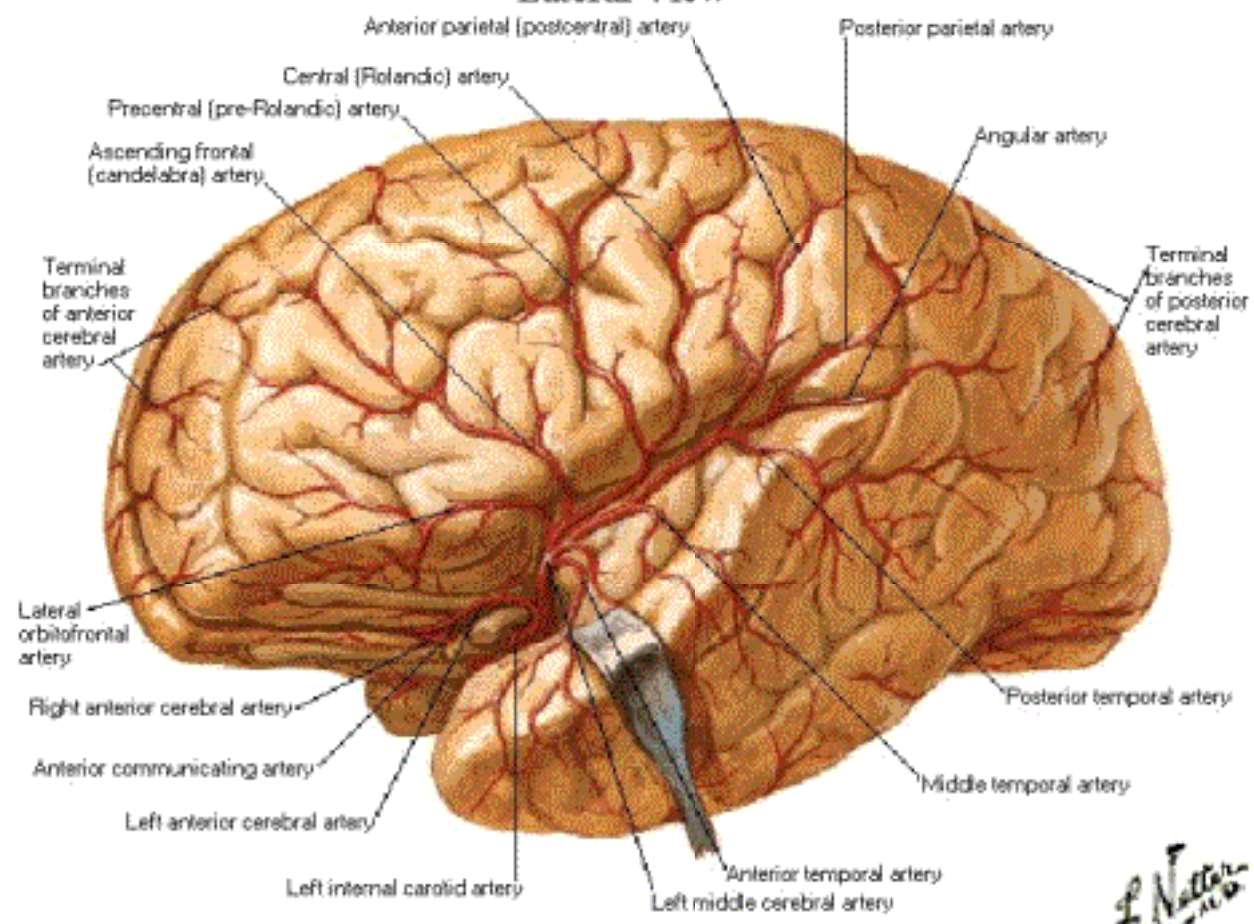


Arteries of Brain Frontal Section



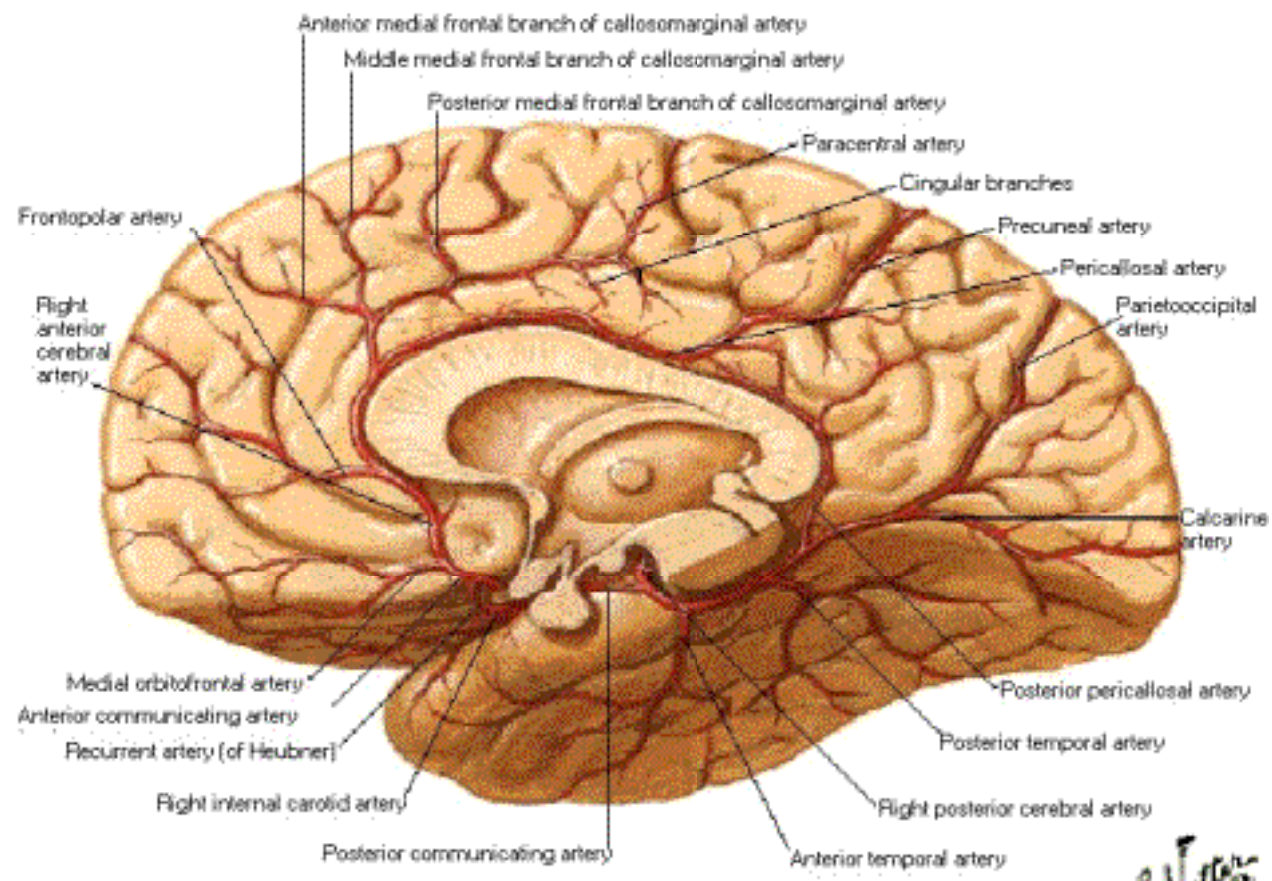
Arteries of Brain

Lateral View



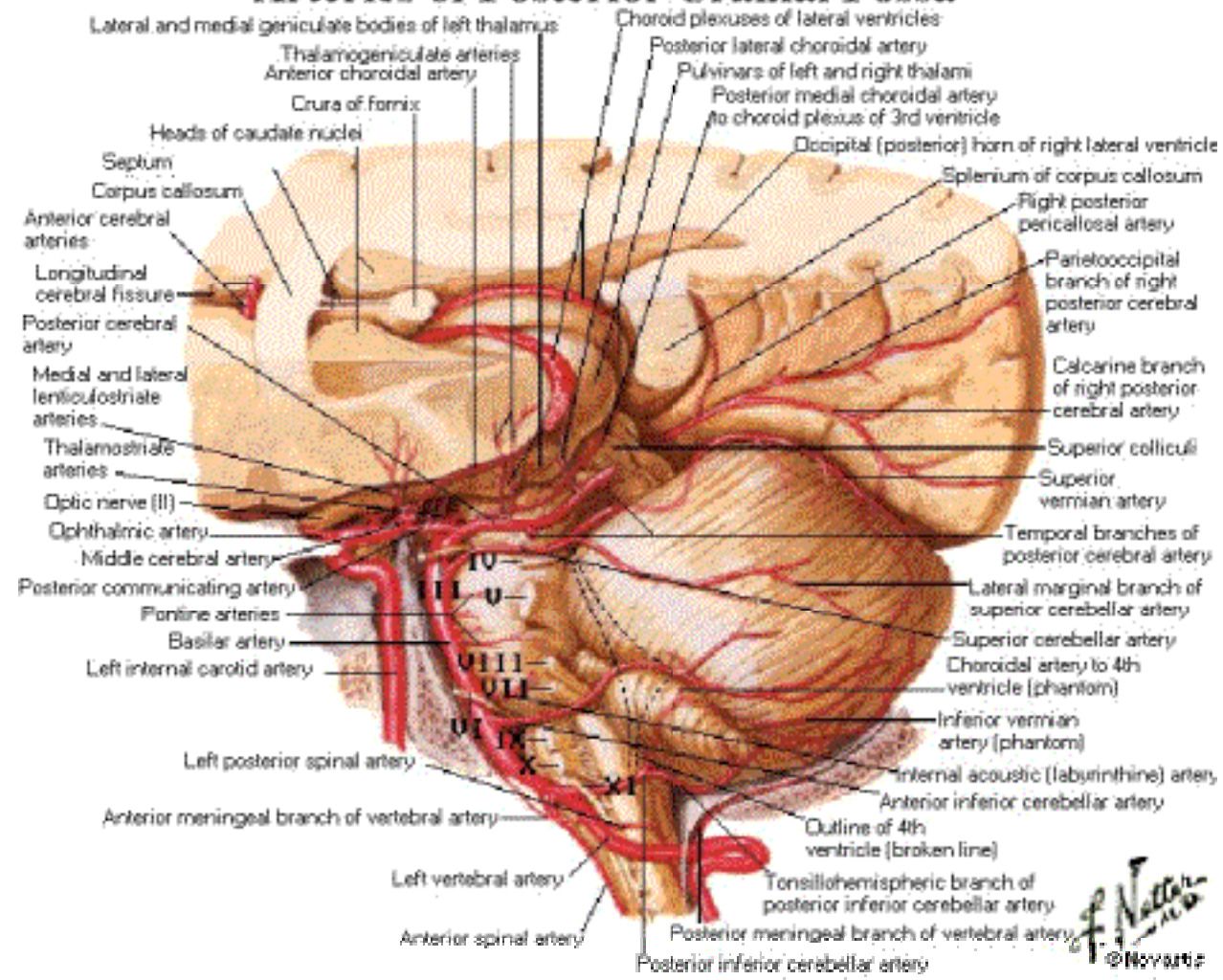
Arteries of Brain

Medial View



F. Netter
© Novartis

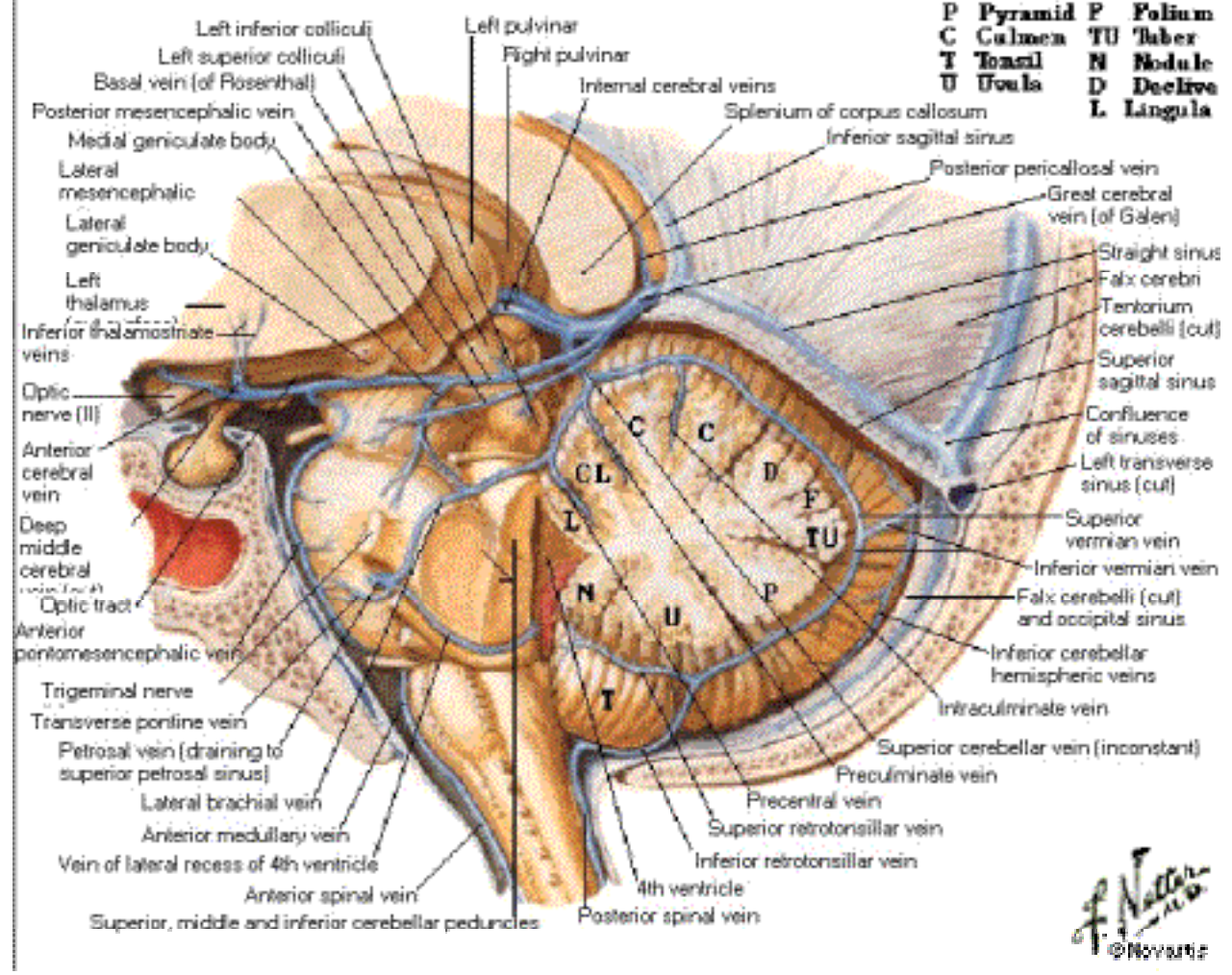
Arteries of Posterior Cranial Fossa



Veins of Posterior Cranial Fossa

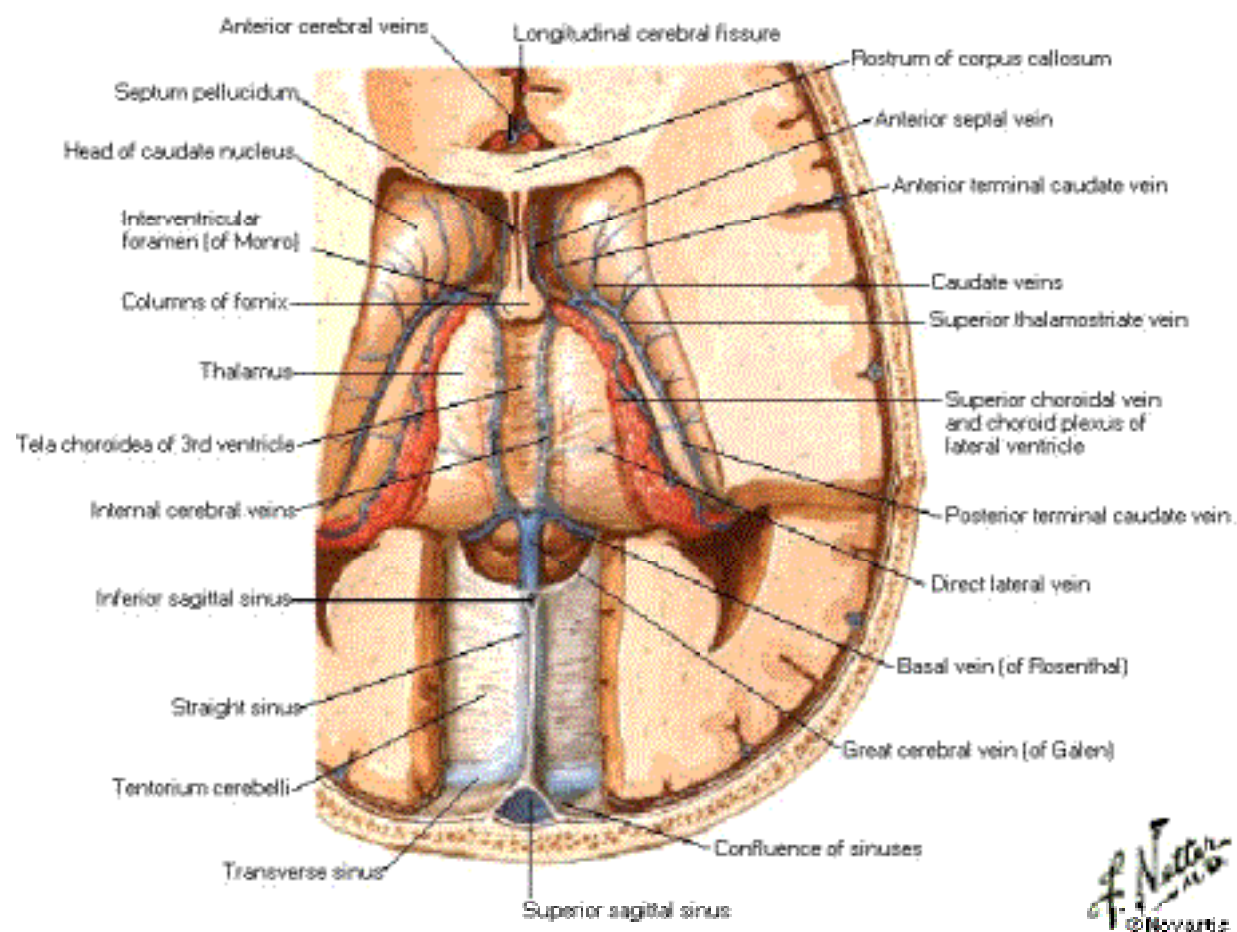
Parts of cerebellum

- CL Central lobule
- P Pyramid P Folium
- C Culmen TU Tuber
- T Tonsil N Nodule
- U Uvula D Declive
- L Lingula



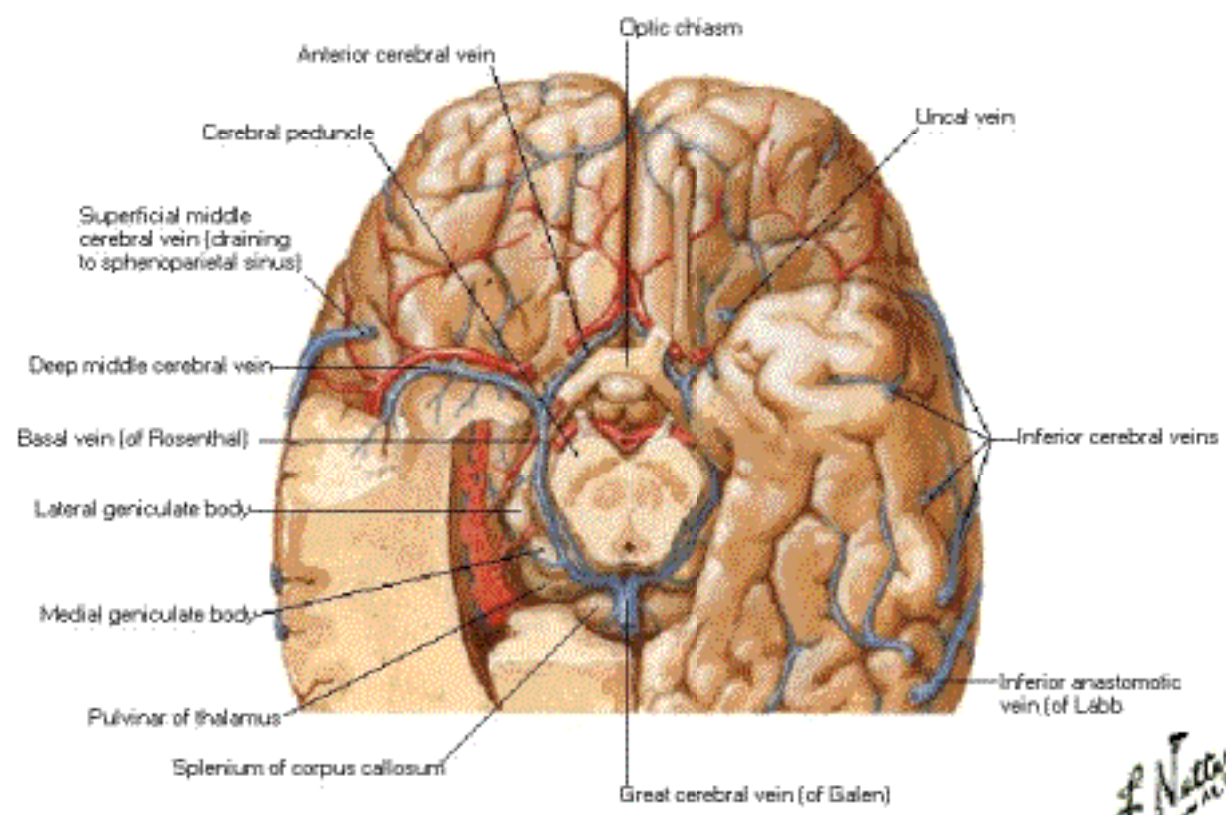
Deep Veins of Brain - Dissection

Superior View

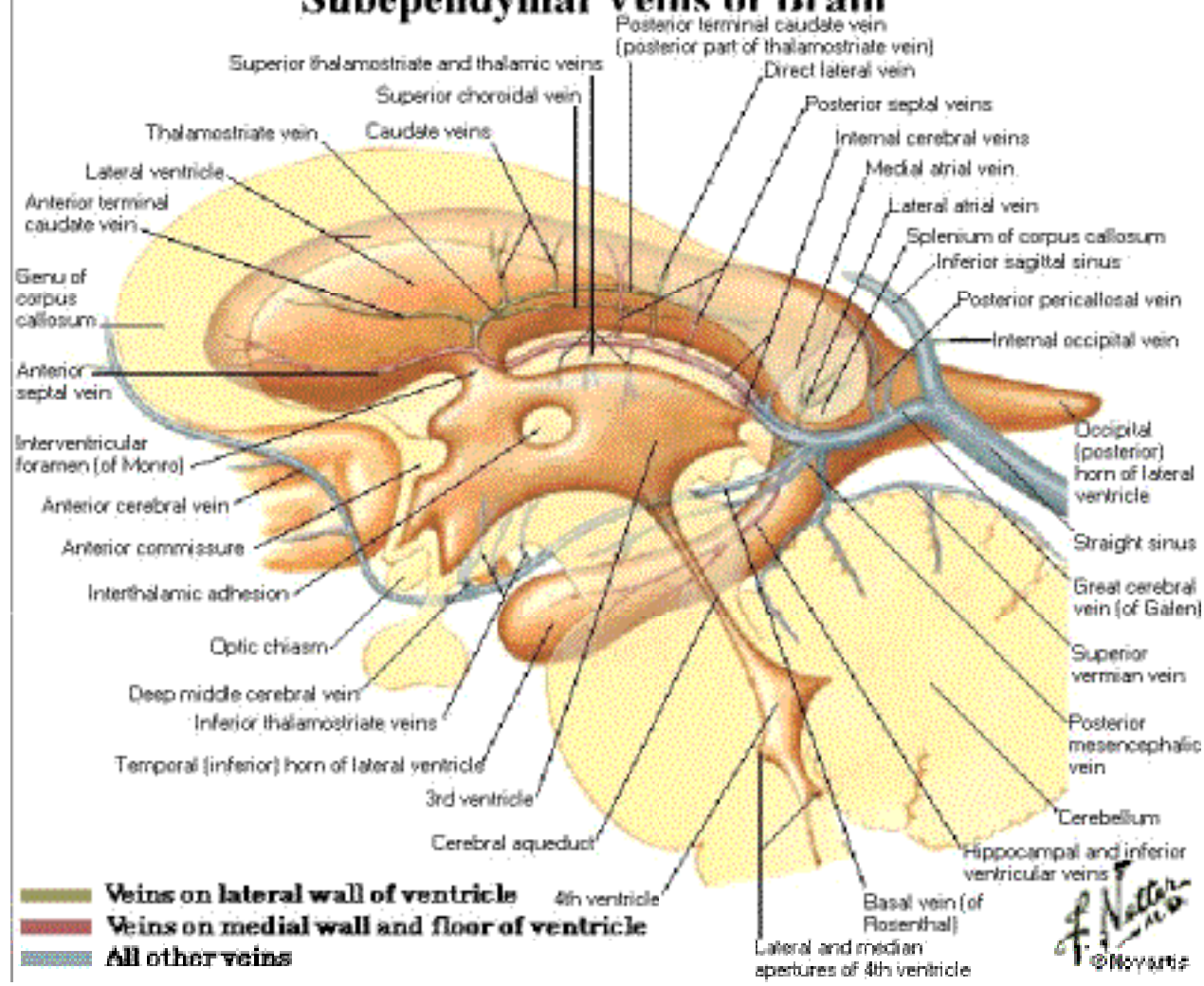


Deep Veins of Brain - Dissection

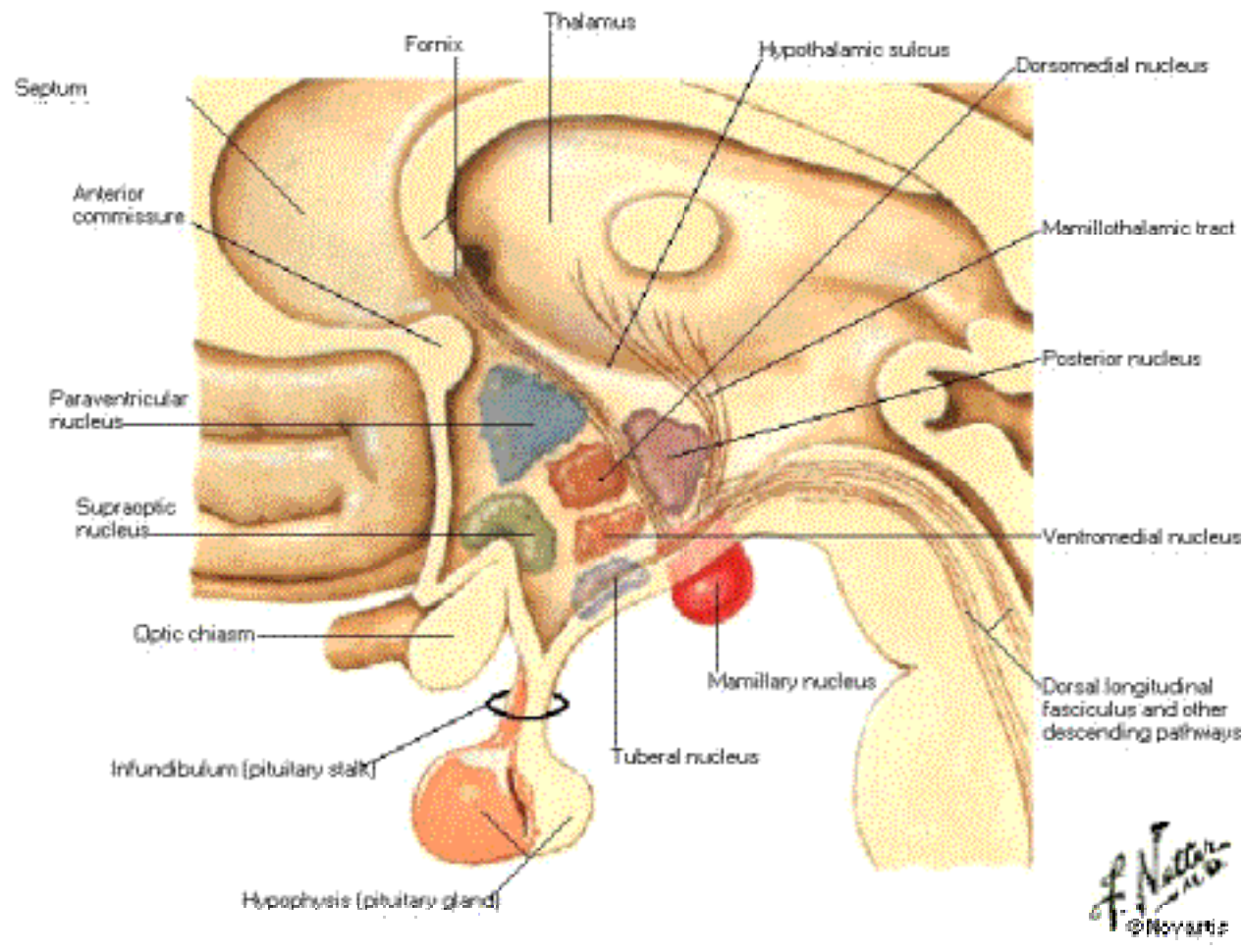
Inferior View



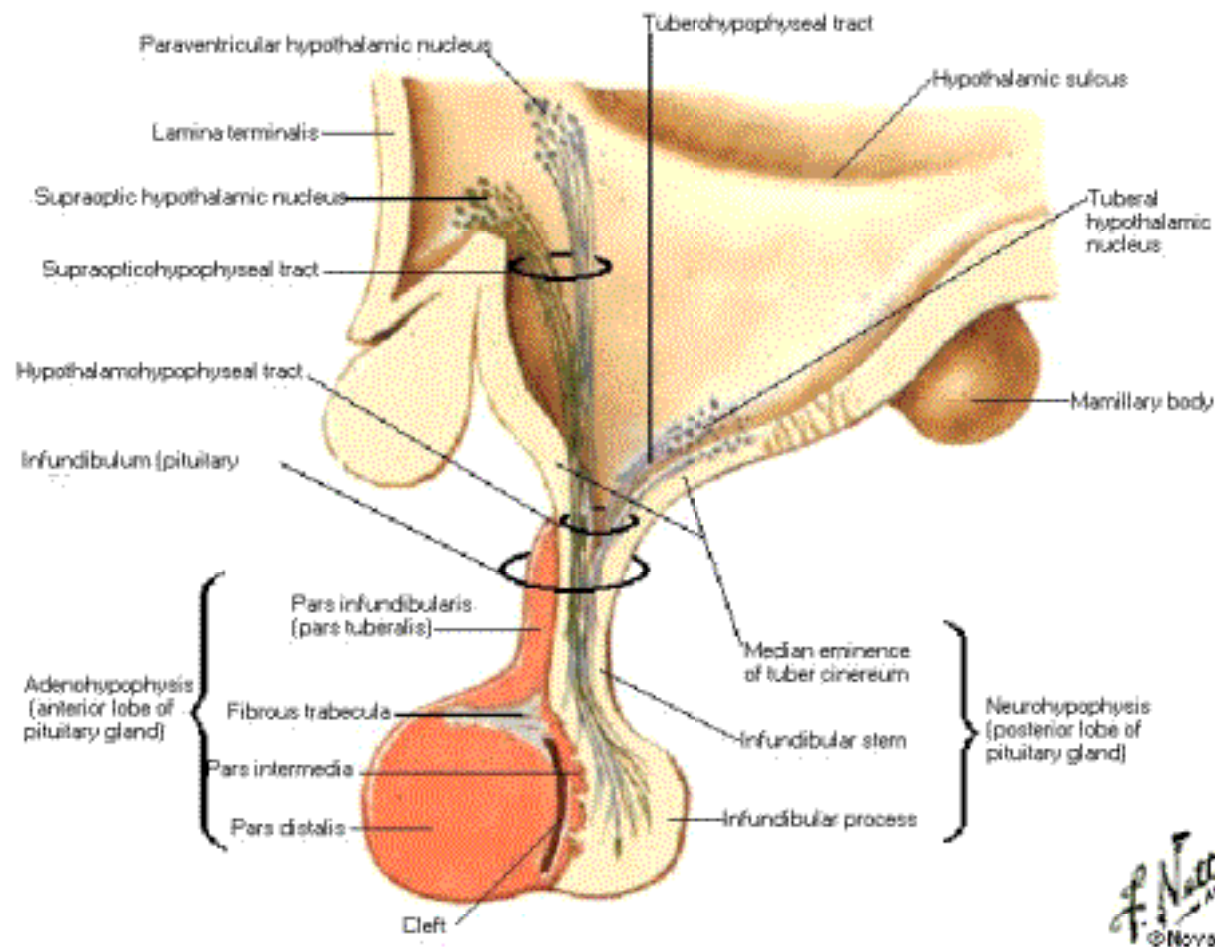
Subependymal Veins of Brain



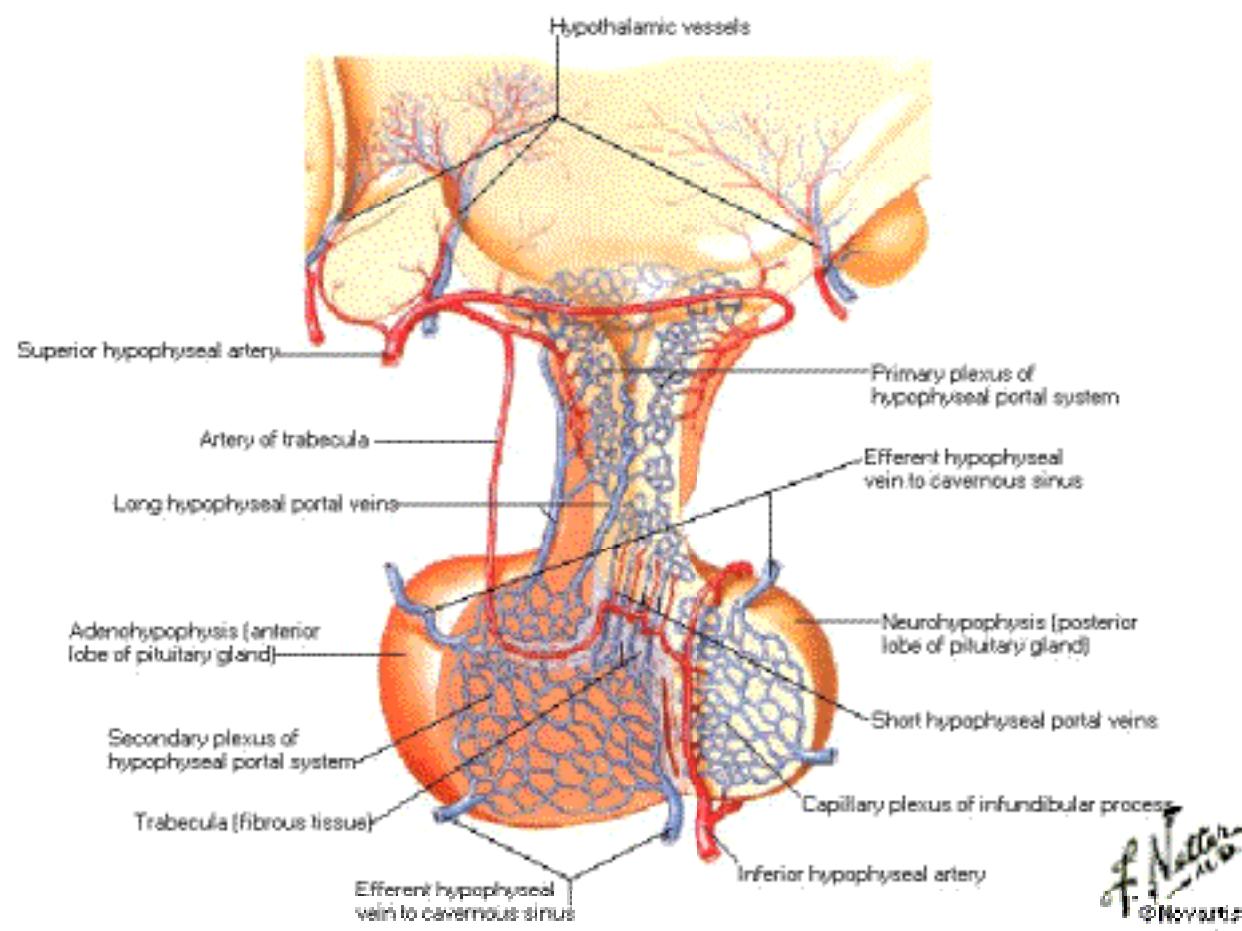
Hypothalamus - Principal Nuclei



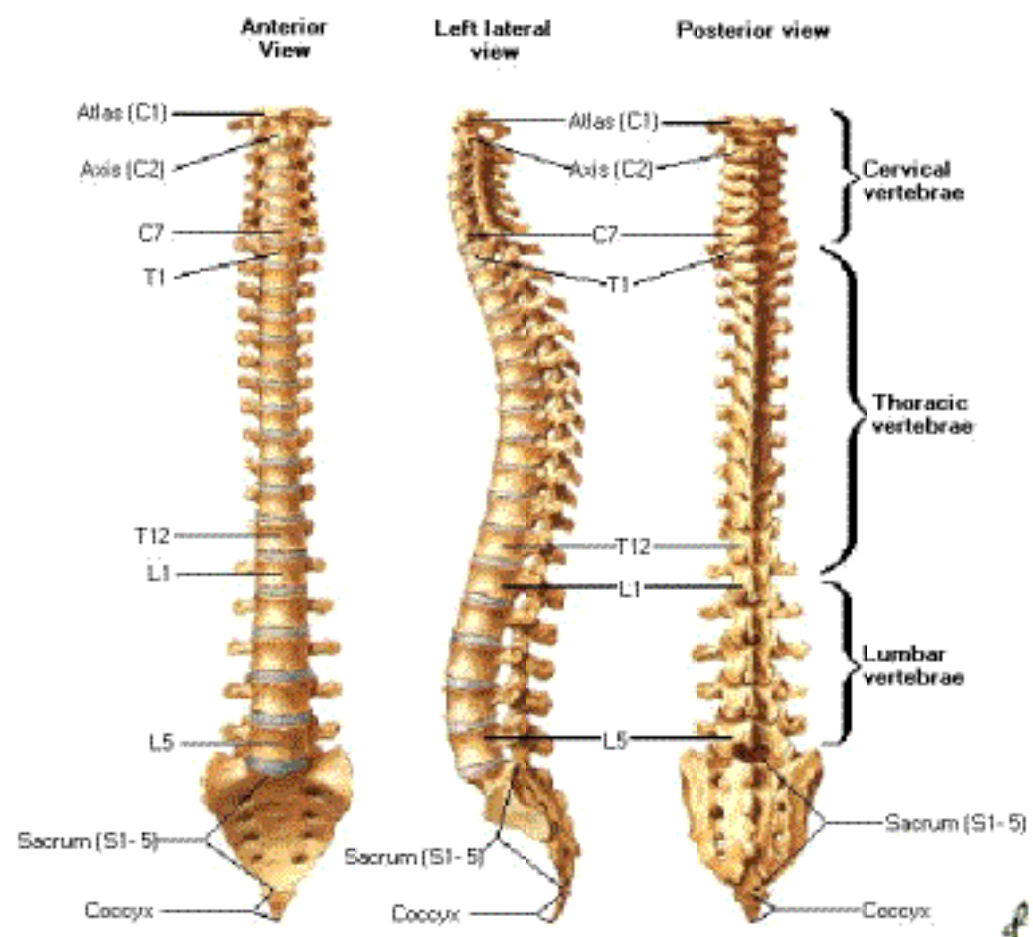
Adenohypophysis and Neurohypophysis



Arteries and Veins of Hypothalamus and Hypophysis



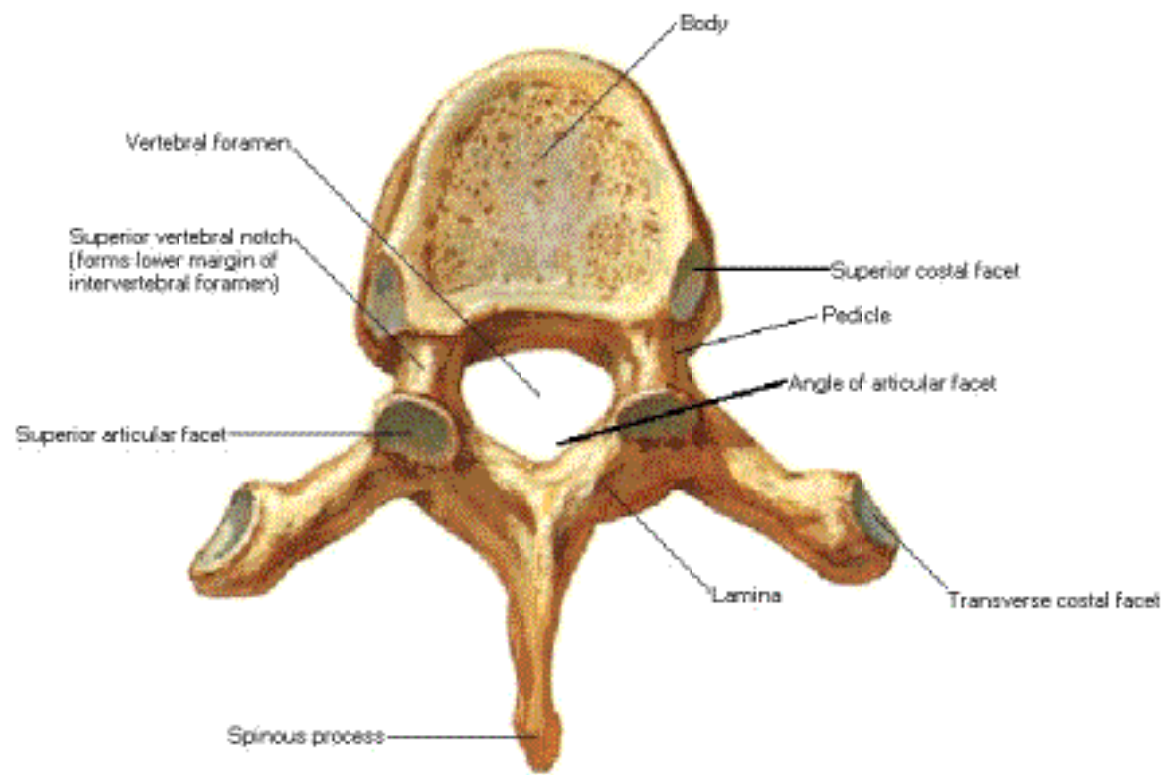
Vertebral Column



F. Netter M.D.
© Novartis

Thoracic Vertebrae [T6]

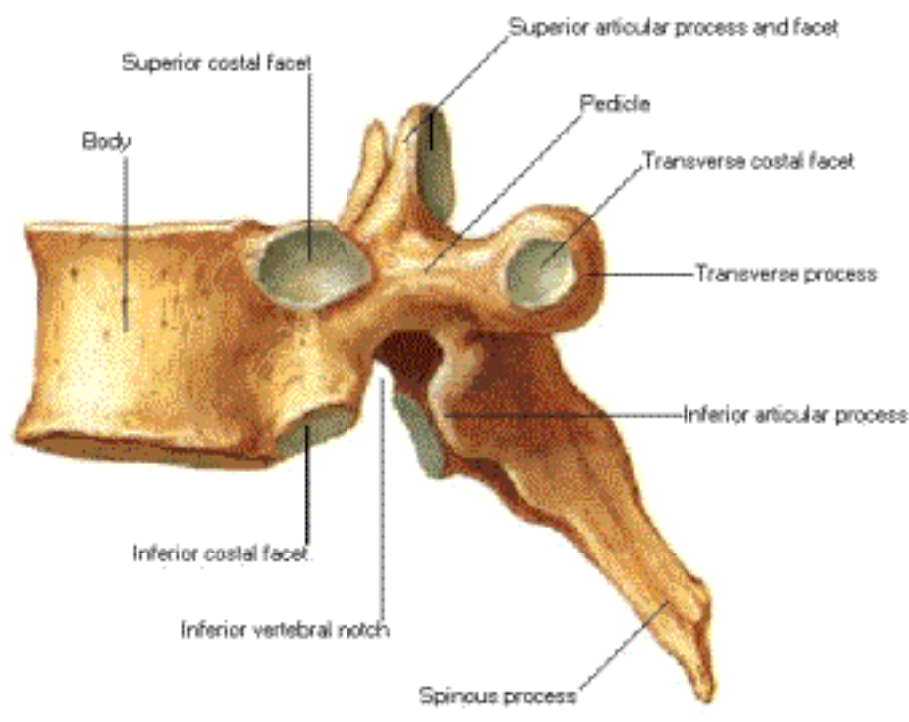
Superior View



F. Netter M.D.
© Netter

Thoracic Vertebrae [T6]

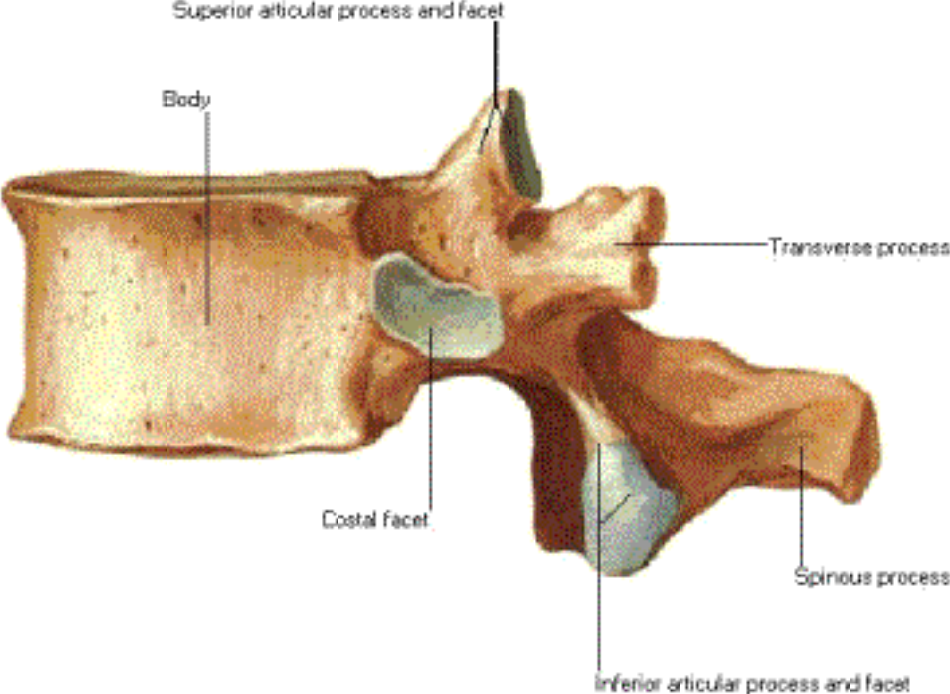
Lateral View



F. Netter M.D.
© Netter

Thoracic Vertebrae [T12]

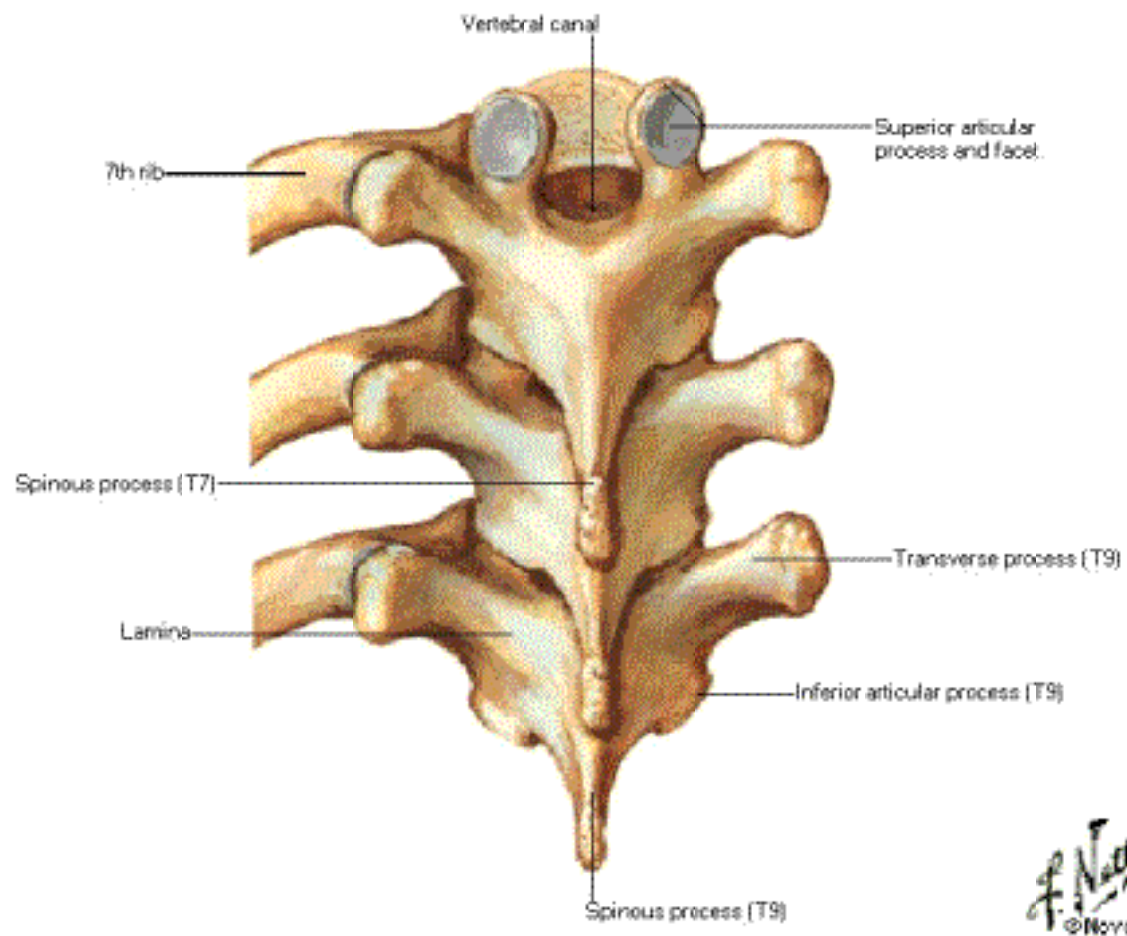
Lateral View



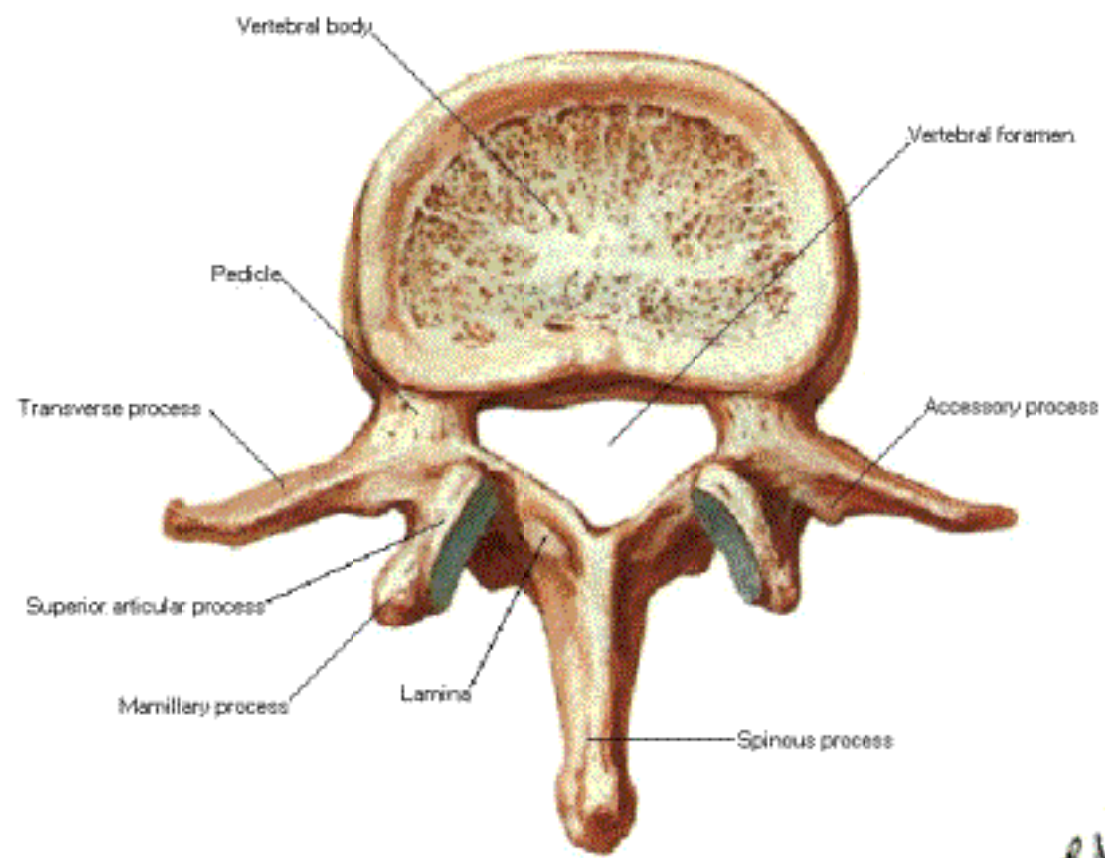
F. Netter M.D.
© Novartis

Thoracic Vertebrae [T7-T9] - Assembled

Posterior View



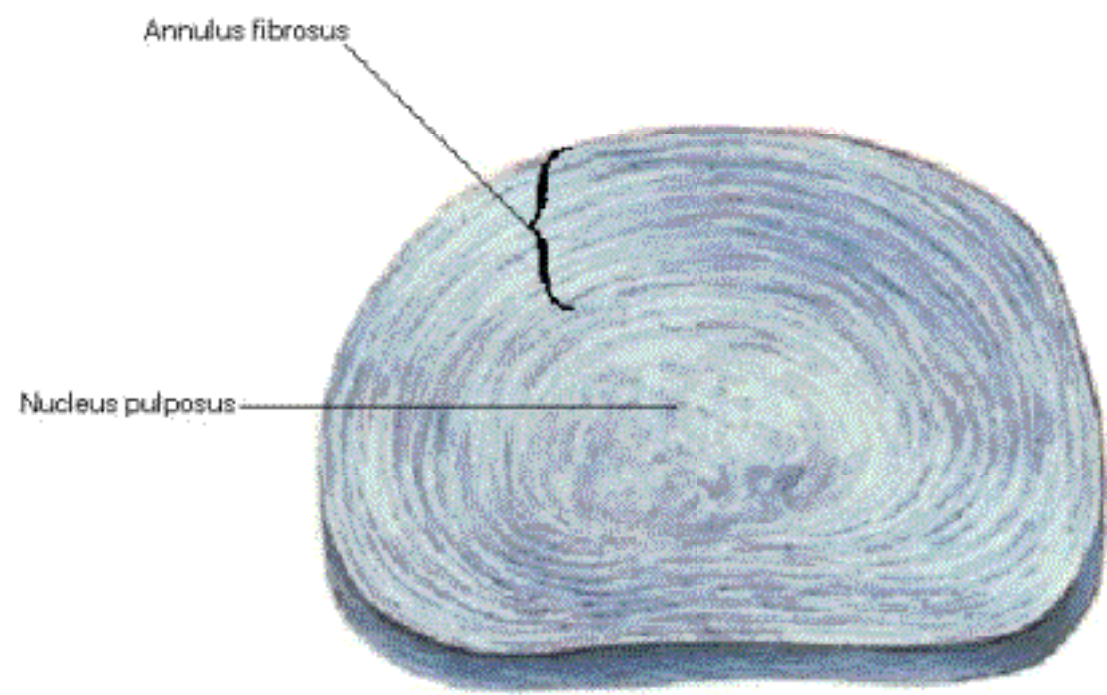
Lumbar Vertebrae [L2] Superior View



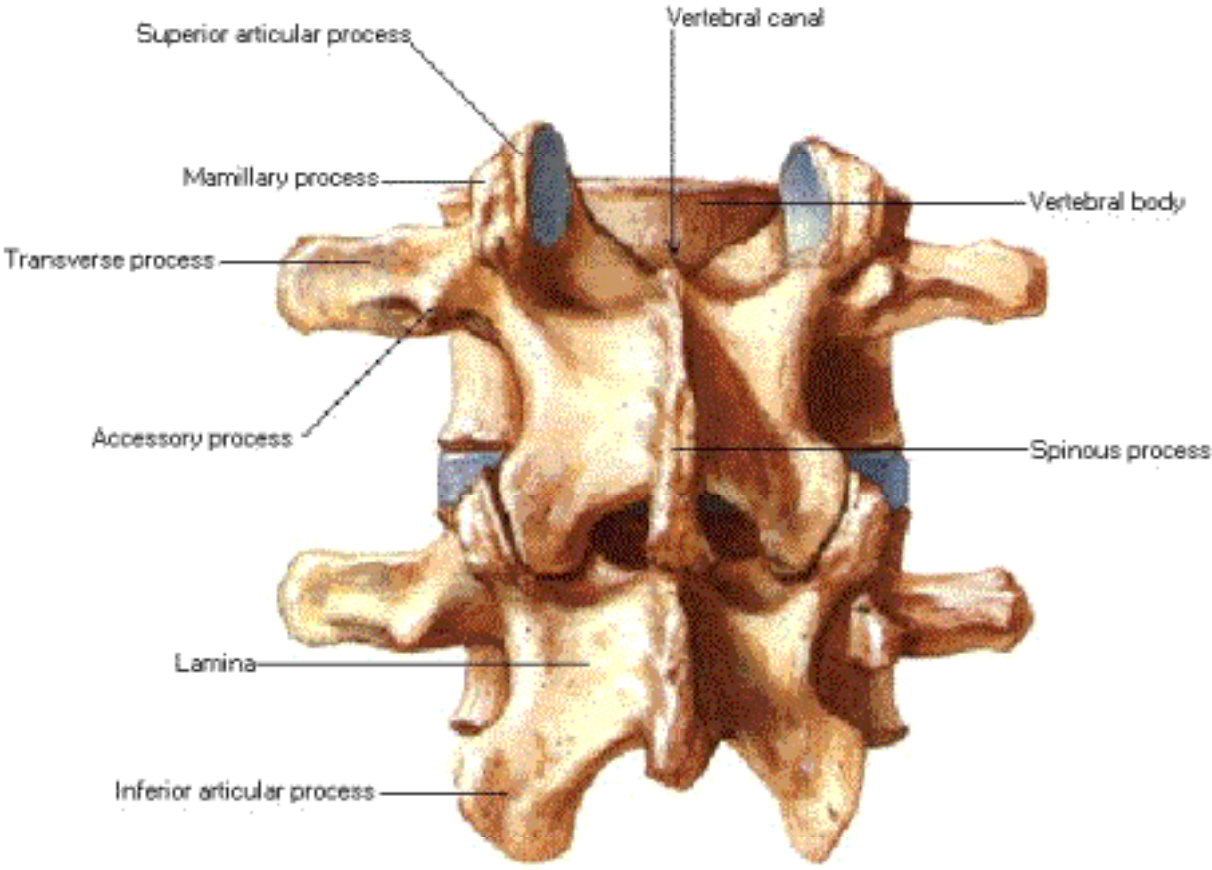
F. Netter M.D.
© Novartis

Lumbar Vertebrae

Intervertebral Disc

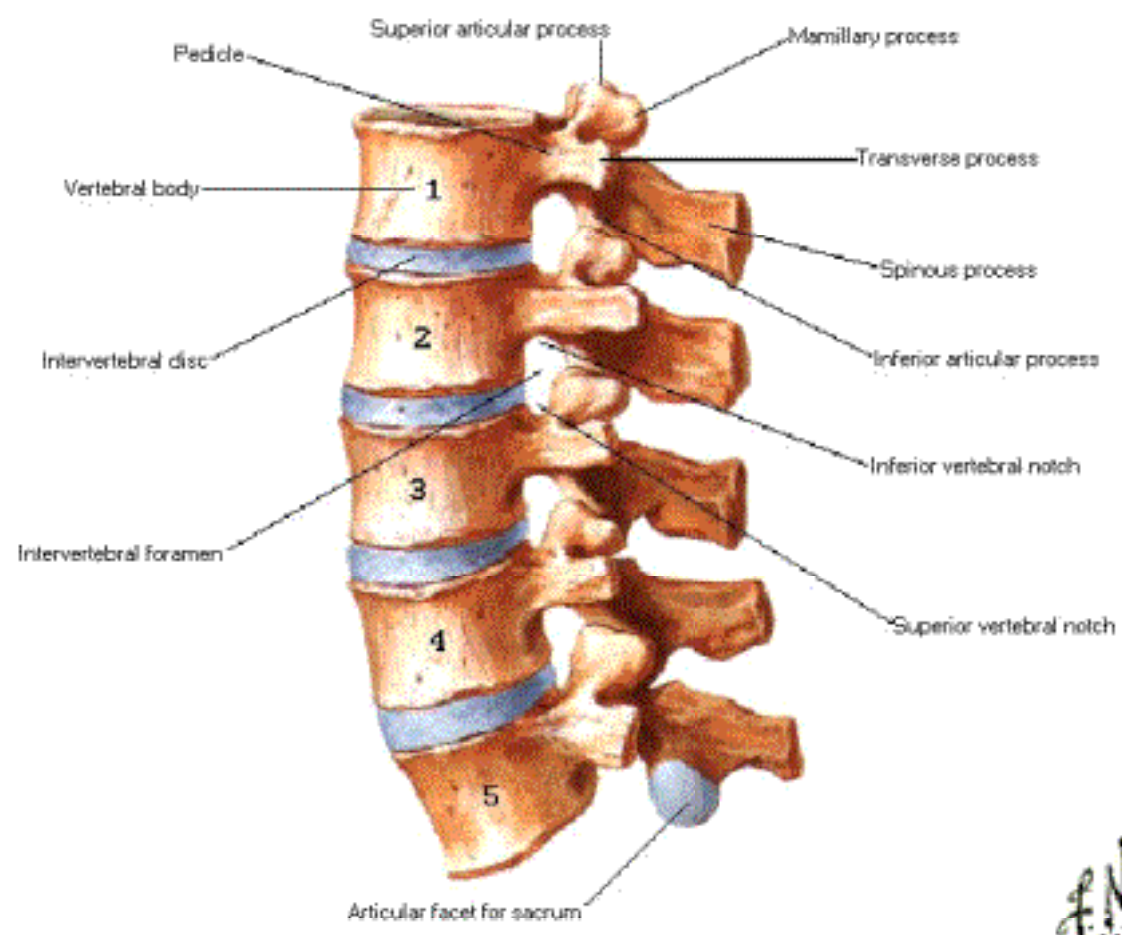


Lumbar Vertebrae [L3-L4] - Assembled
Posterior View



Lumbar Vertebrae [L1-L5] - Assembled

Left Lateral View

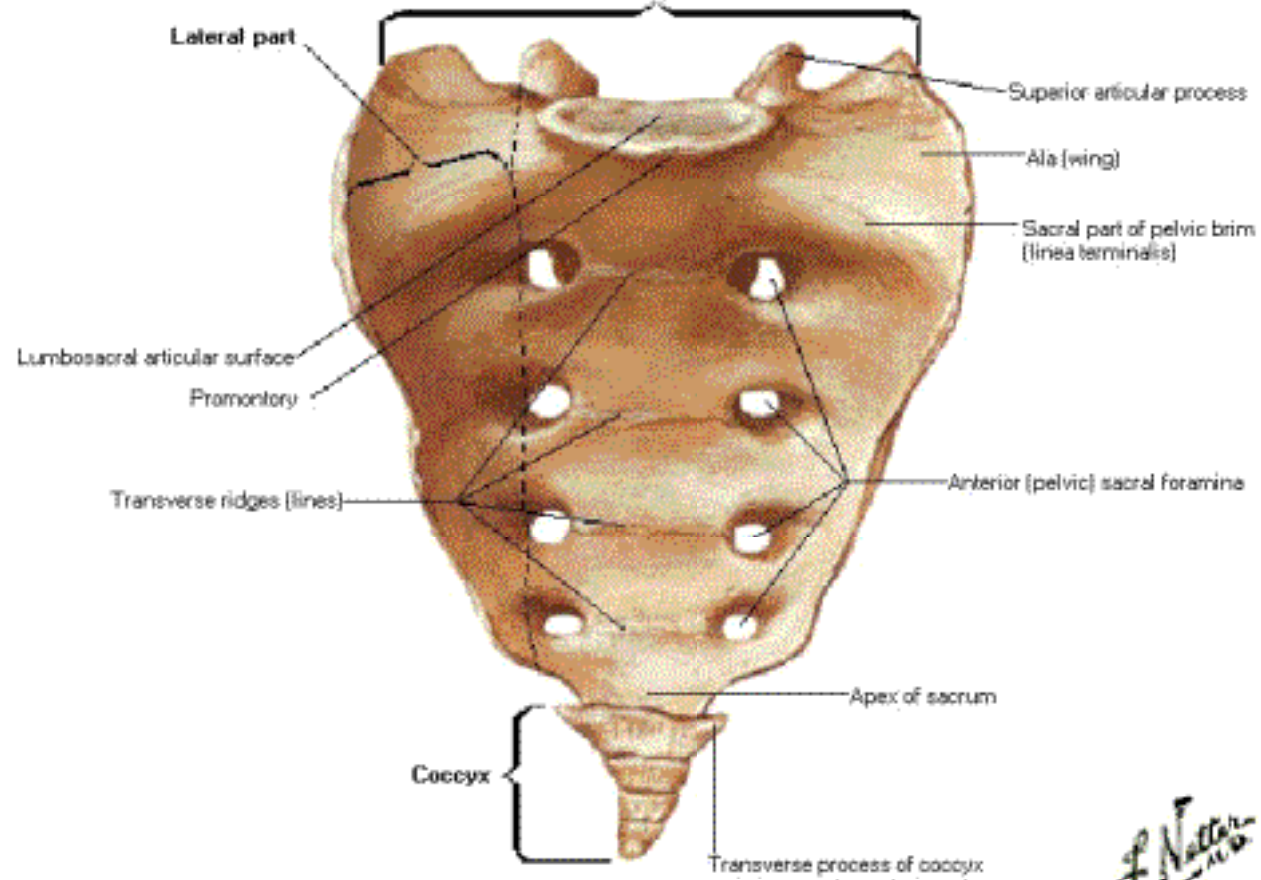


F. Netter M.D.
© Novartis

Sacrum and Coccyx

Pelvic Surface

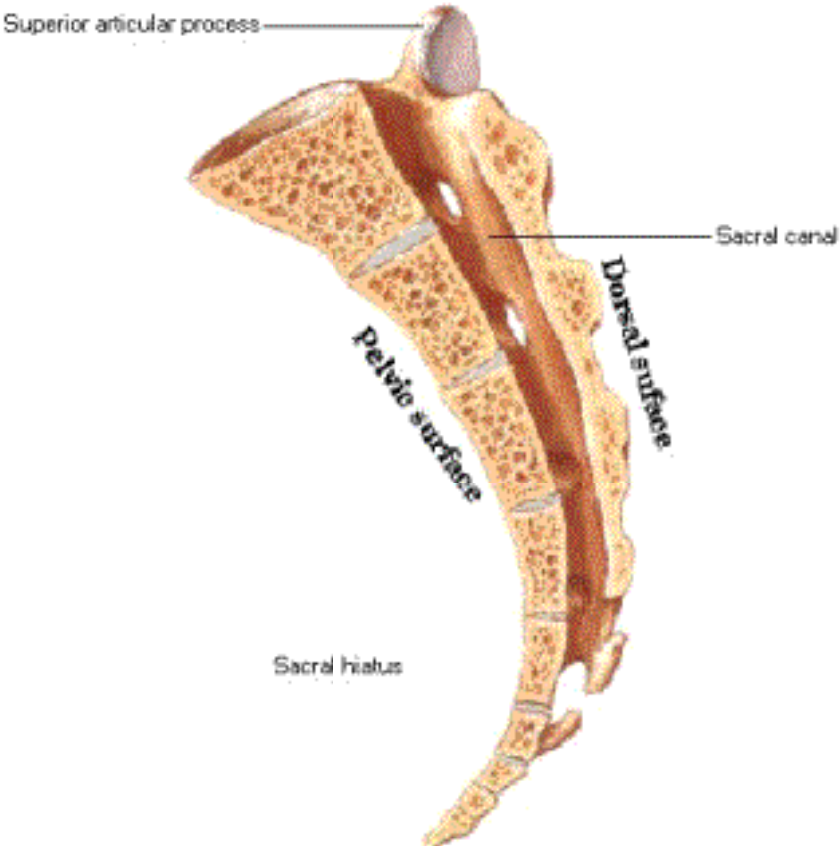
Base of Sacrum



F. Netter
© Novartis

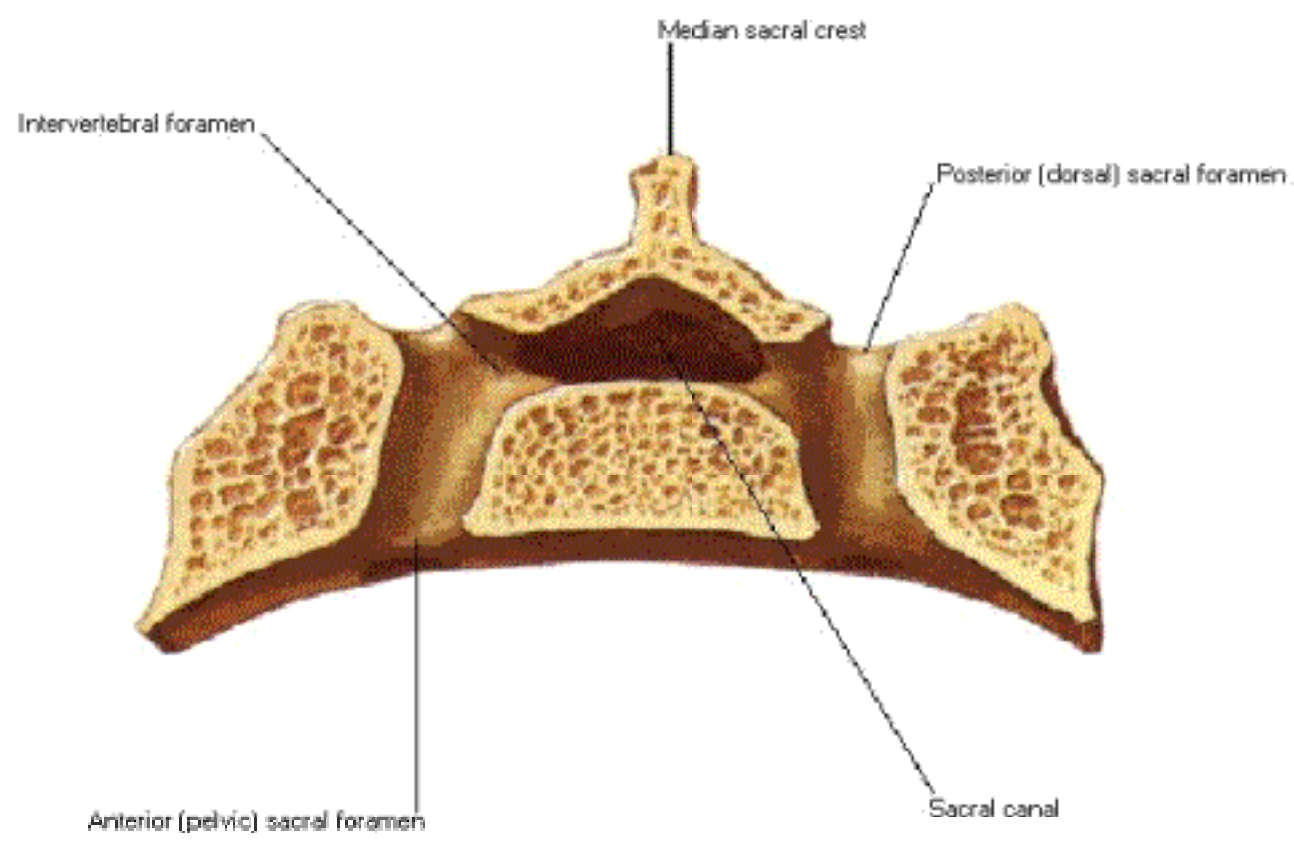
Sacrum and Coccyx

Median Sagittal Section



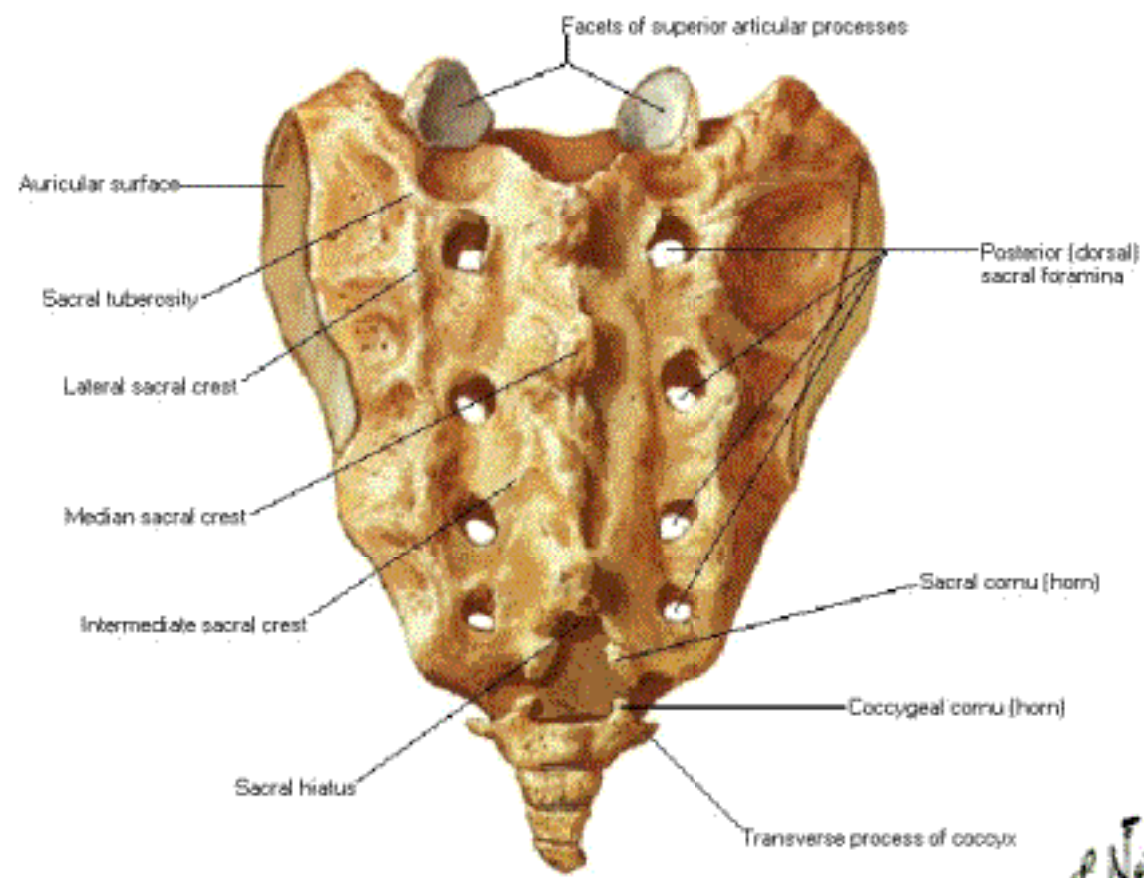
Sacrum

Transverse Section through S1 Foramina



Sacrum and Coccyx

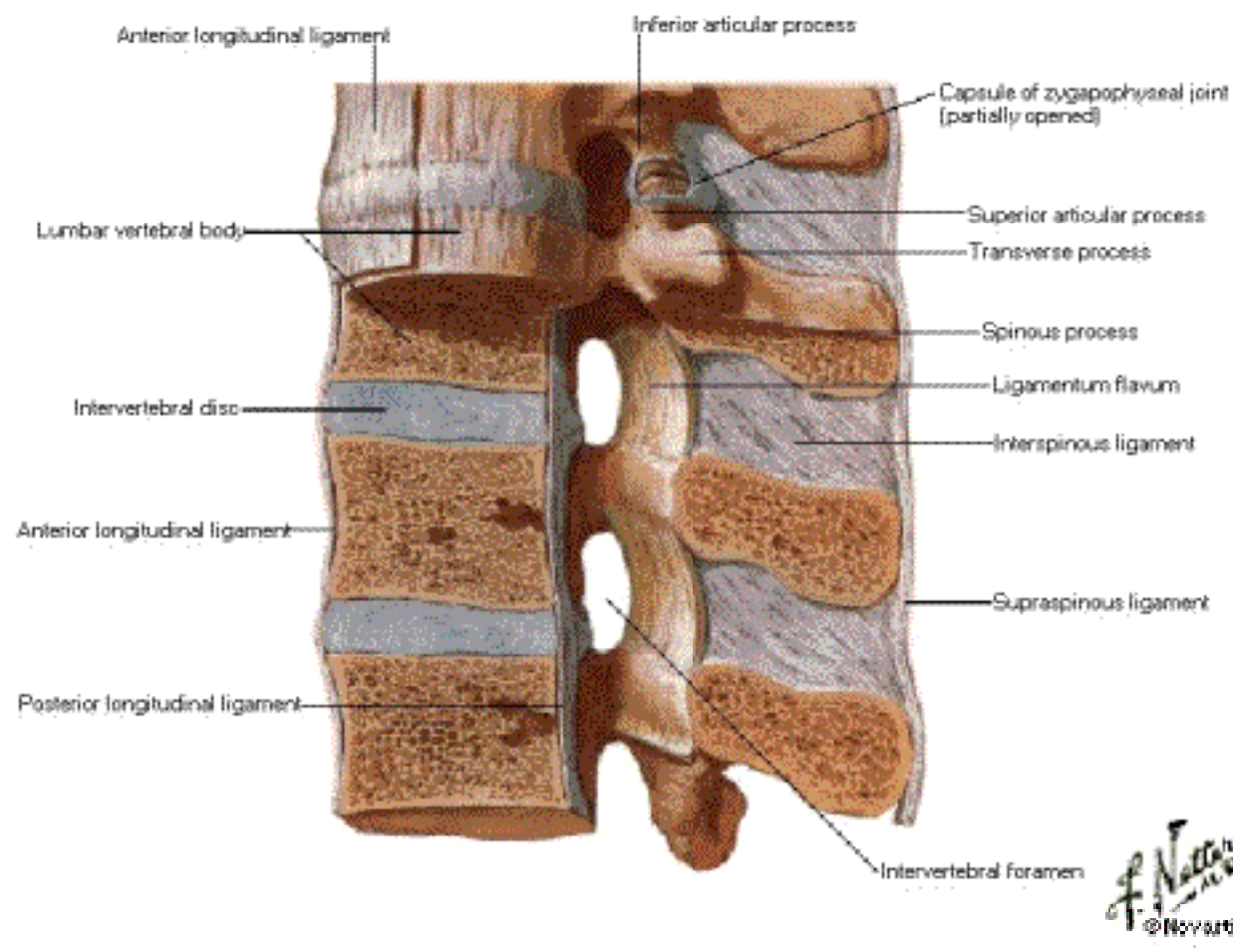
Dorsal Surface



F. Netter M.D.
© Netter

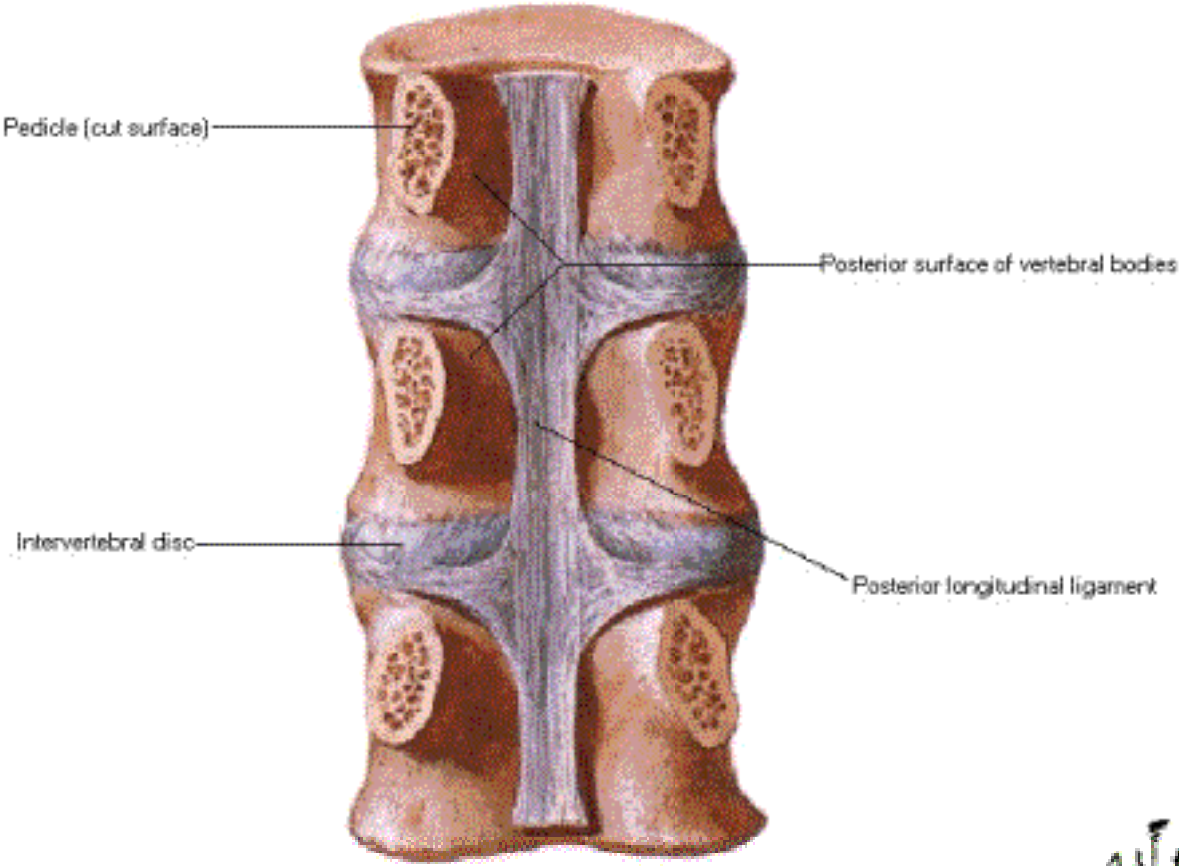
Vertebral Ligaments of Lumbar Region

Left Lateral View - Partially Sectioned



Vertebral Ligaments of Lumbar Region

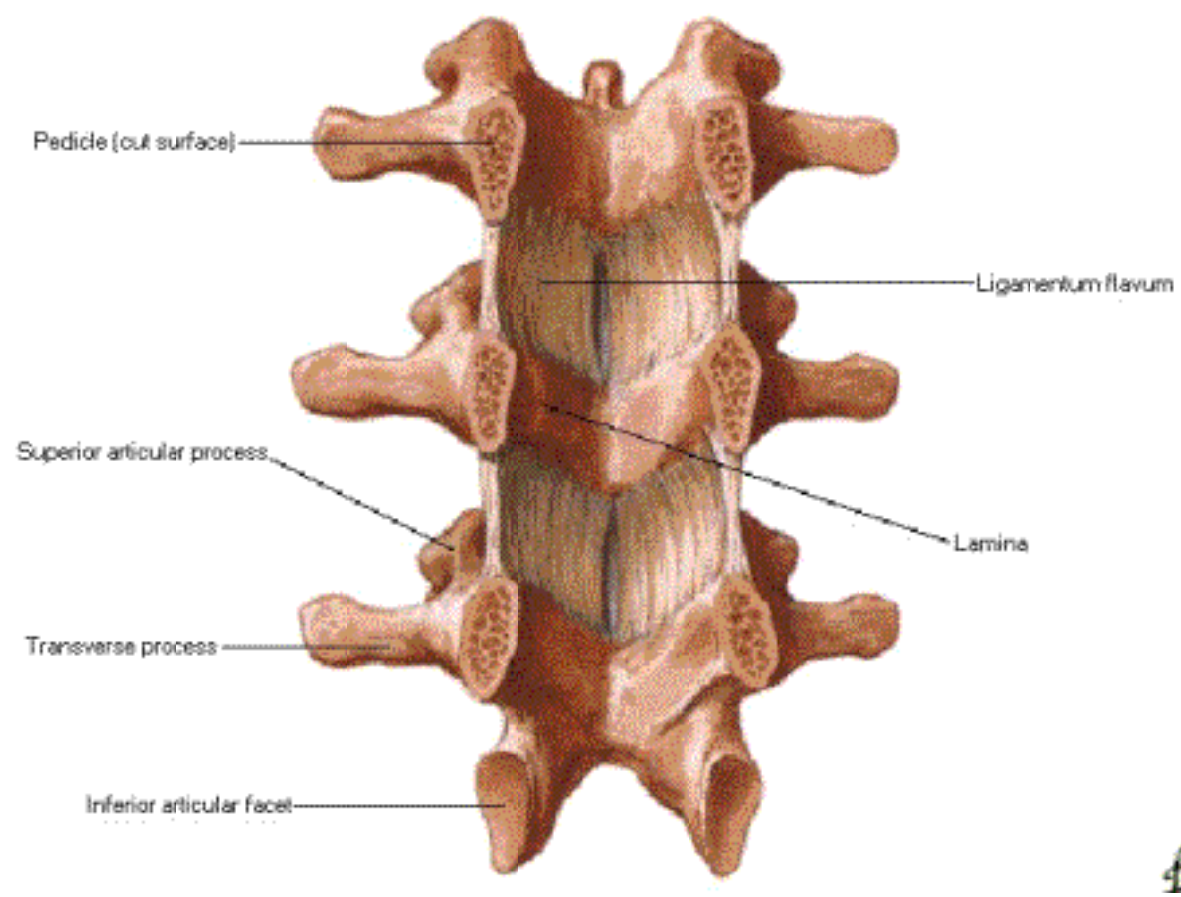
Anterior Vertebral Segments - Posterior View



2/1/20

Vertebral Ligaments of Lumbar Region

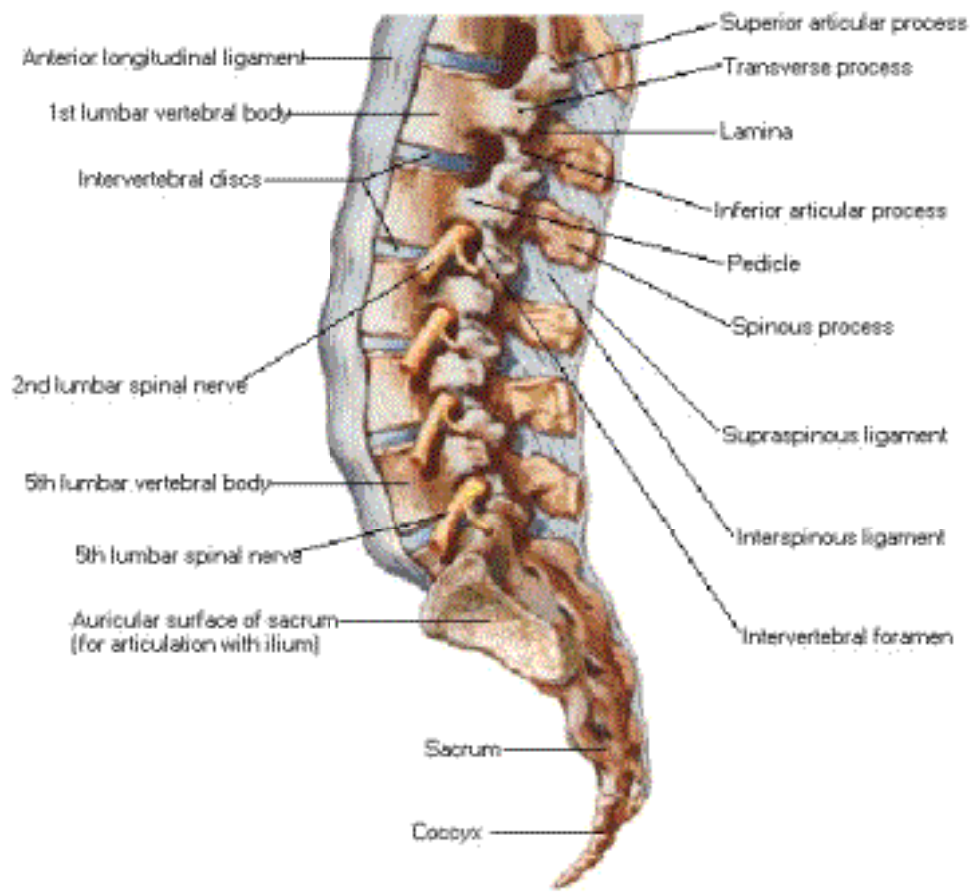
Posterior Vertebral Segments - Anterior View



4

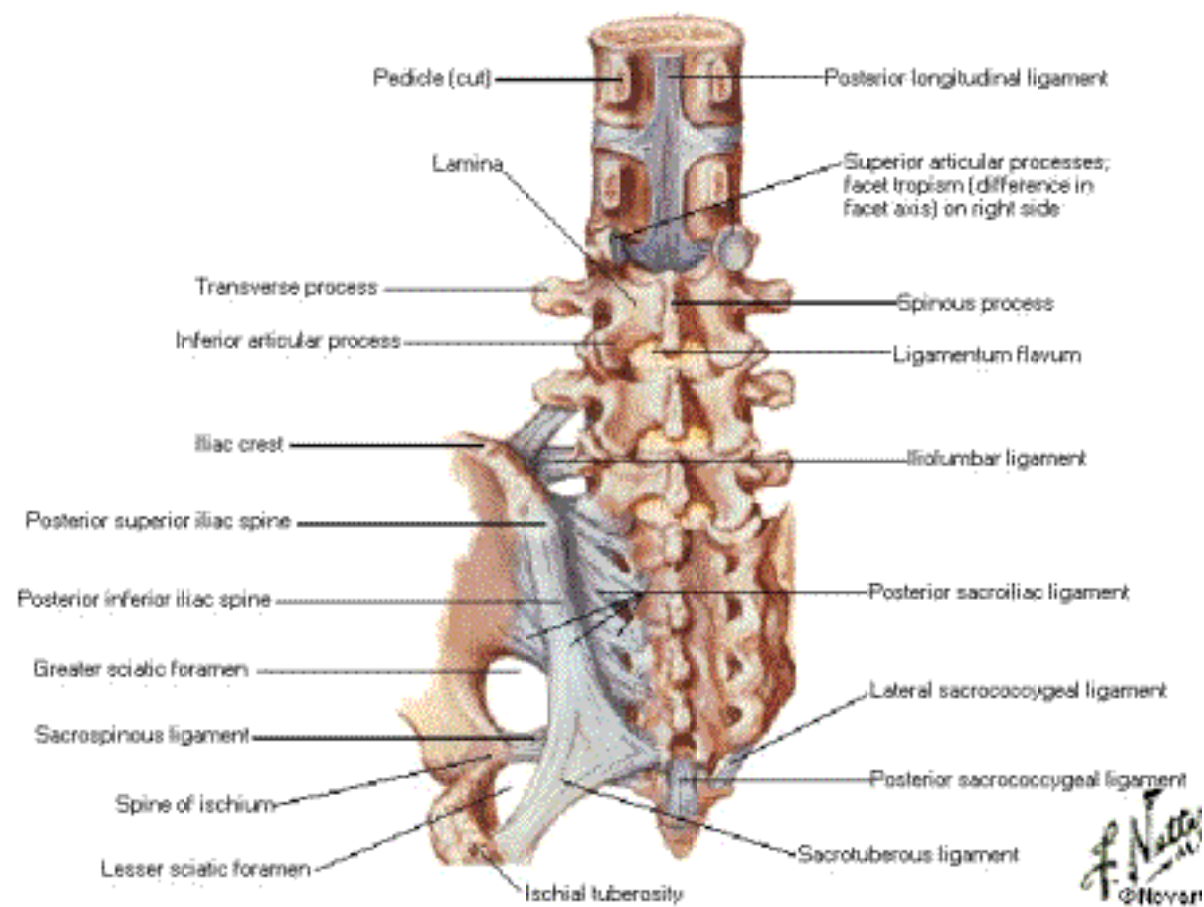
Vertebral Ligaments of Lumbosacral Region

Left Lateral View

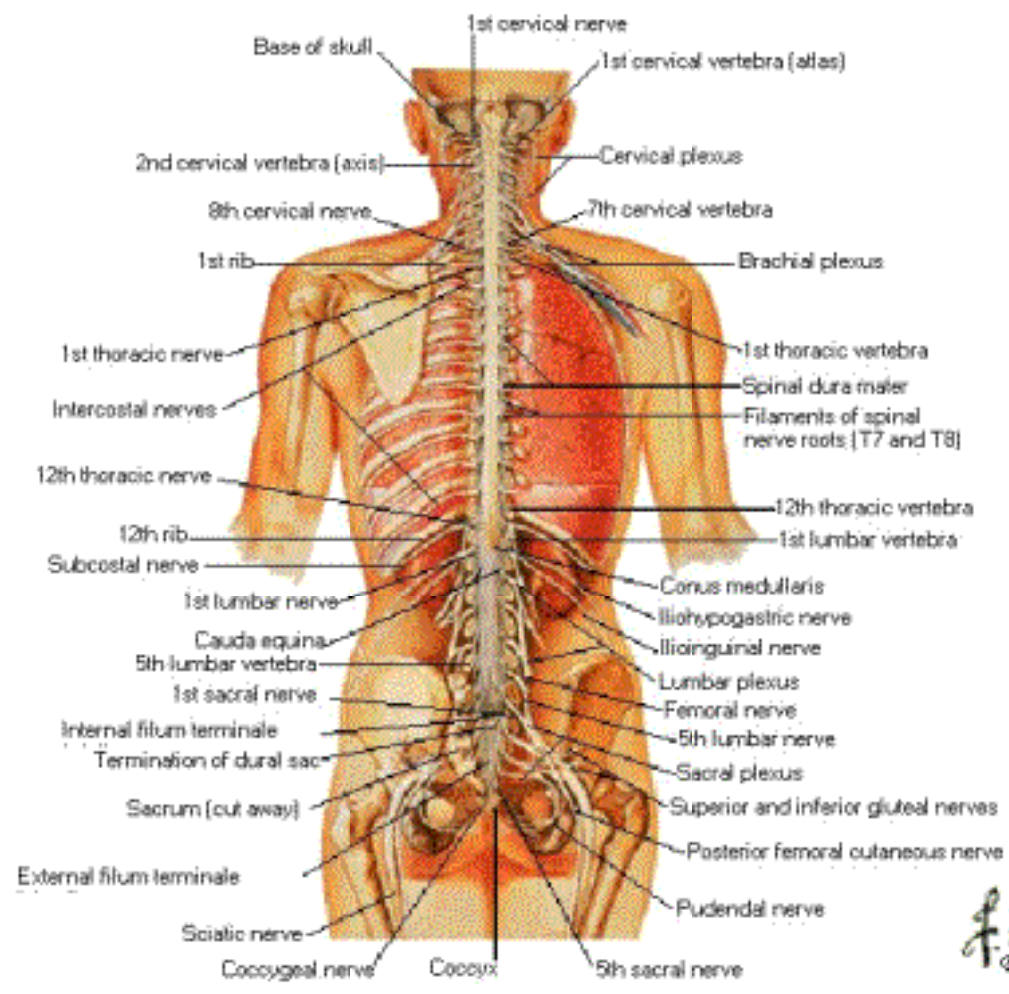


Vertebral Ligaments of Lumbosacral Region

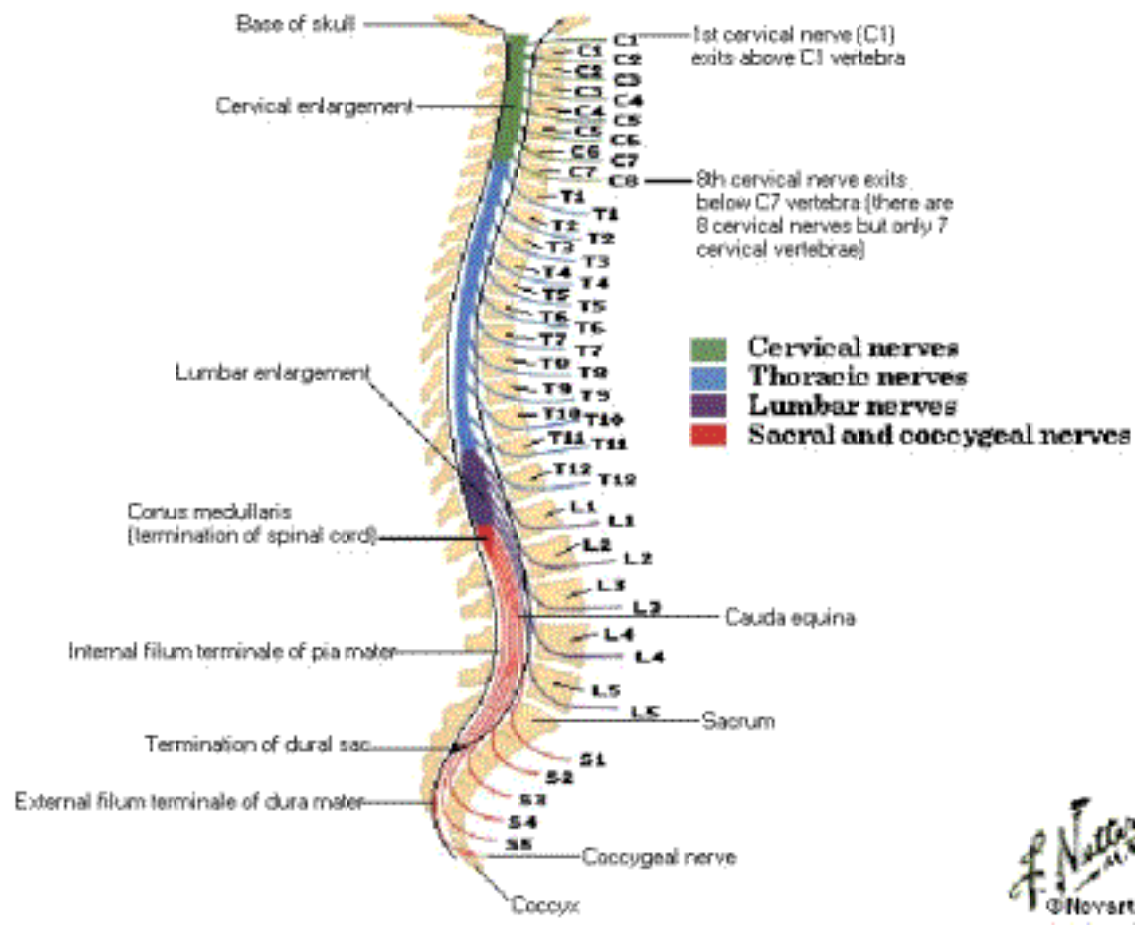
Posterior View



Spinal Cord in Situ

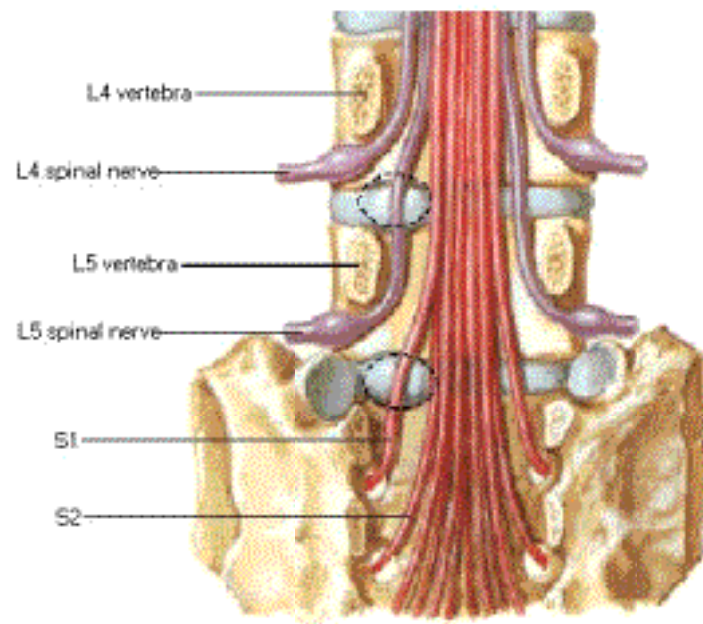


Relation of Spinal Nerve Roots to Vertebrae



Relation of Spinal Nerve Roots to Vertebrae

Lateral Protrusion

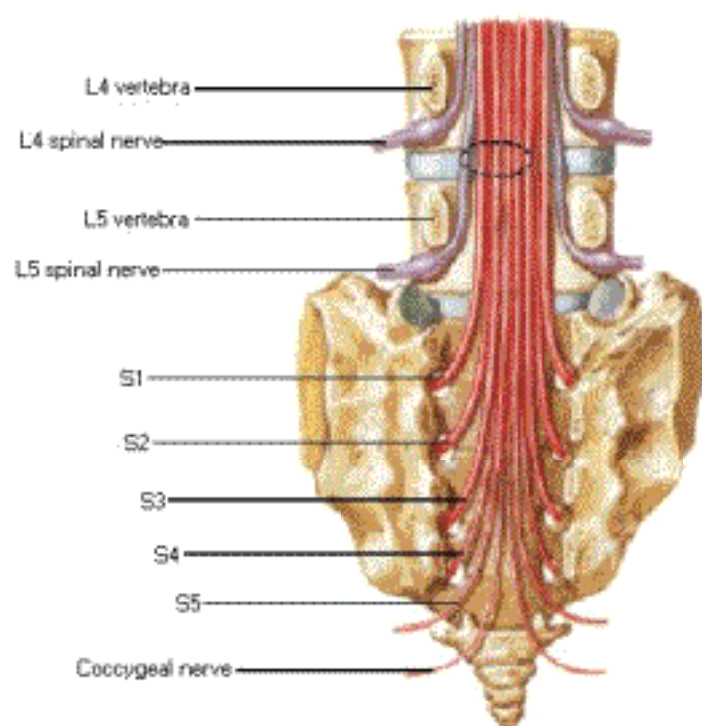


Lumbar disc protrusion does not usually affect nerve exiting above disc. Lateral protrusion at disc level L4- 5 affects 5th lumbar nerve, not 4th lumbar nerve. Protrusion at disc level L5- S1 affects 1st sacral nerve, not 5th lumbar nerve

Handwritten signature

Relation of Spinal Nerve Roots to Vertebrae

Medial Protrusion



Medial protrusion at disc level L4-5 rarely affects 4th lumbar nerve but may affect 5th lumbar nerve and sometimes 1st-4th sacral nerves

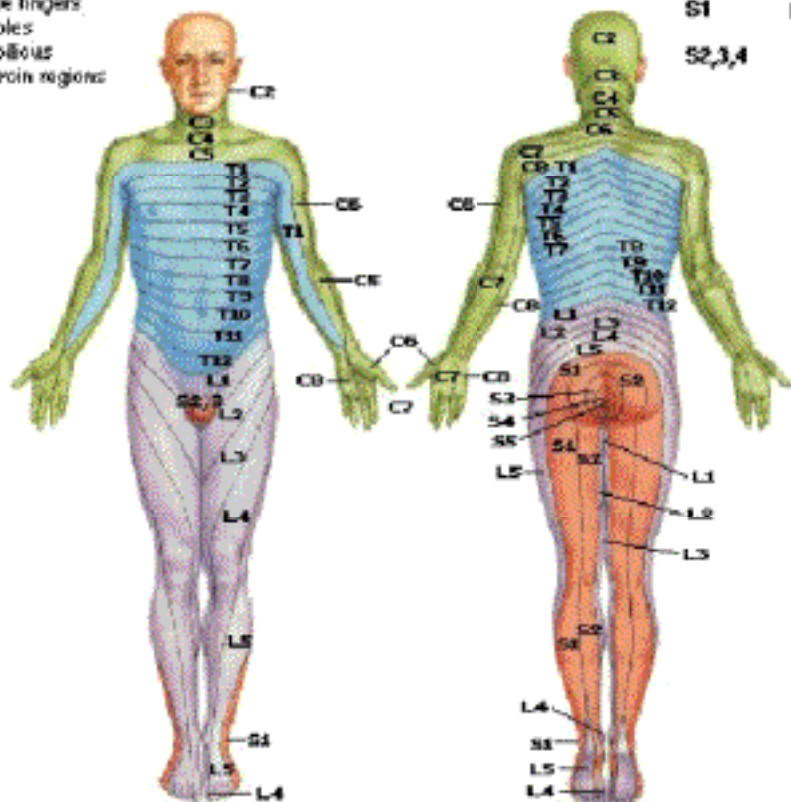
Levels of principal dermatomes

- C5** Clavicles
- C5,6,7** Lateral parts of upper limbs
- C8,T1** Medial sides of upper limbs
- C6** Thumb
- C6,7,8** Hand
- C8** Ring and little fingers
- T1** Level of nipples
- T10** Level of umbilicus
- T12** Inguinal or groin regions

Dermatomes

Levels of principal dermatomes

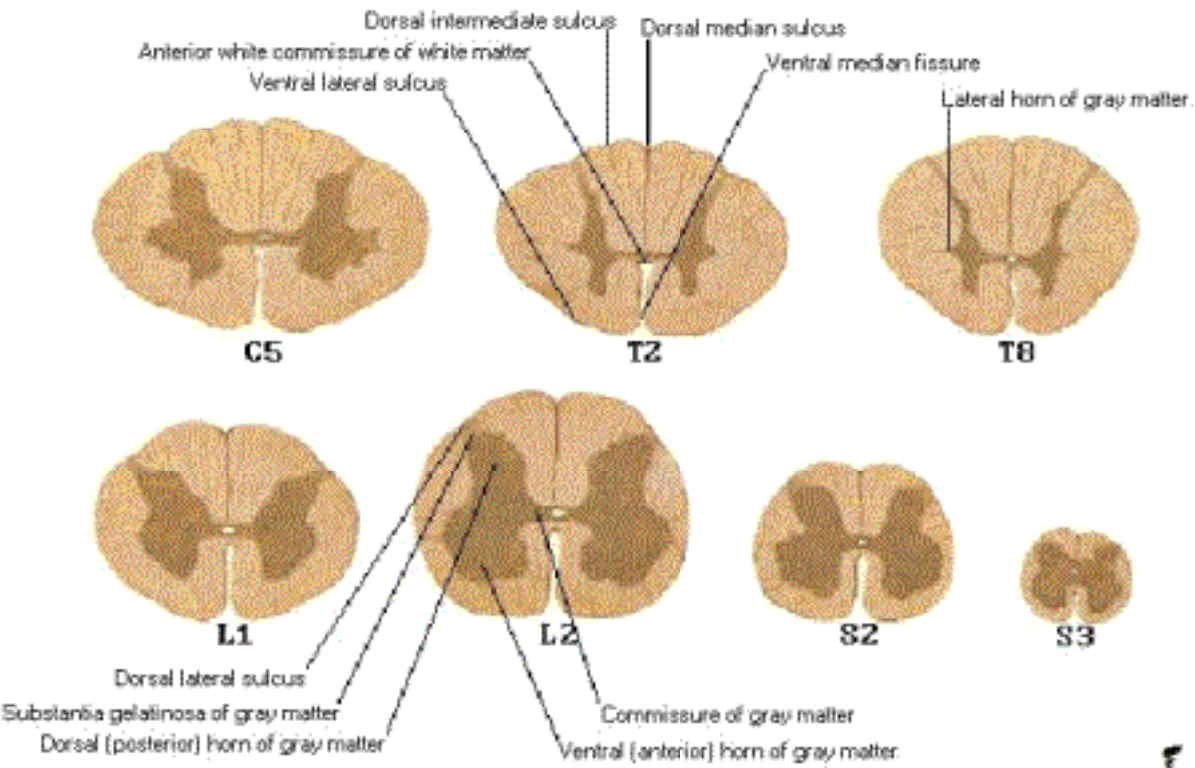
- L1,2,3,4** Anterior and inner surfaces of lower limbs
- L4,5,S1** Foot
- L4** Medial side of great toe
- S1,2,L5** Posterior and outer surfaces of lower limbs
- S1** Lateral margin of foot and little toe
- S2,3,4** Perineum



Schematic demarcation of dermatomes shown as distinct segments. There is actually considerable overlap between any two adjacent dermatomes

F. Netter M.D.
© Novartis

Spinal Cord Cross Sections

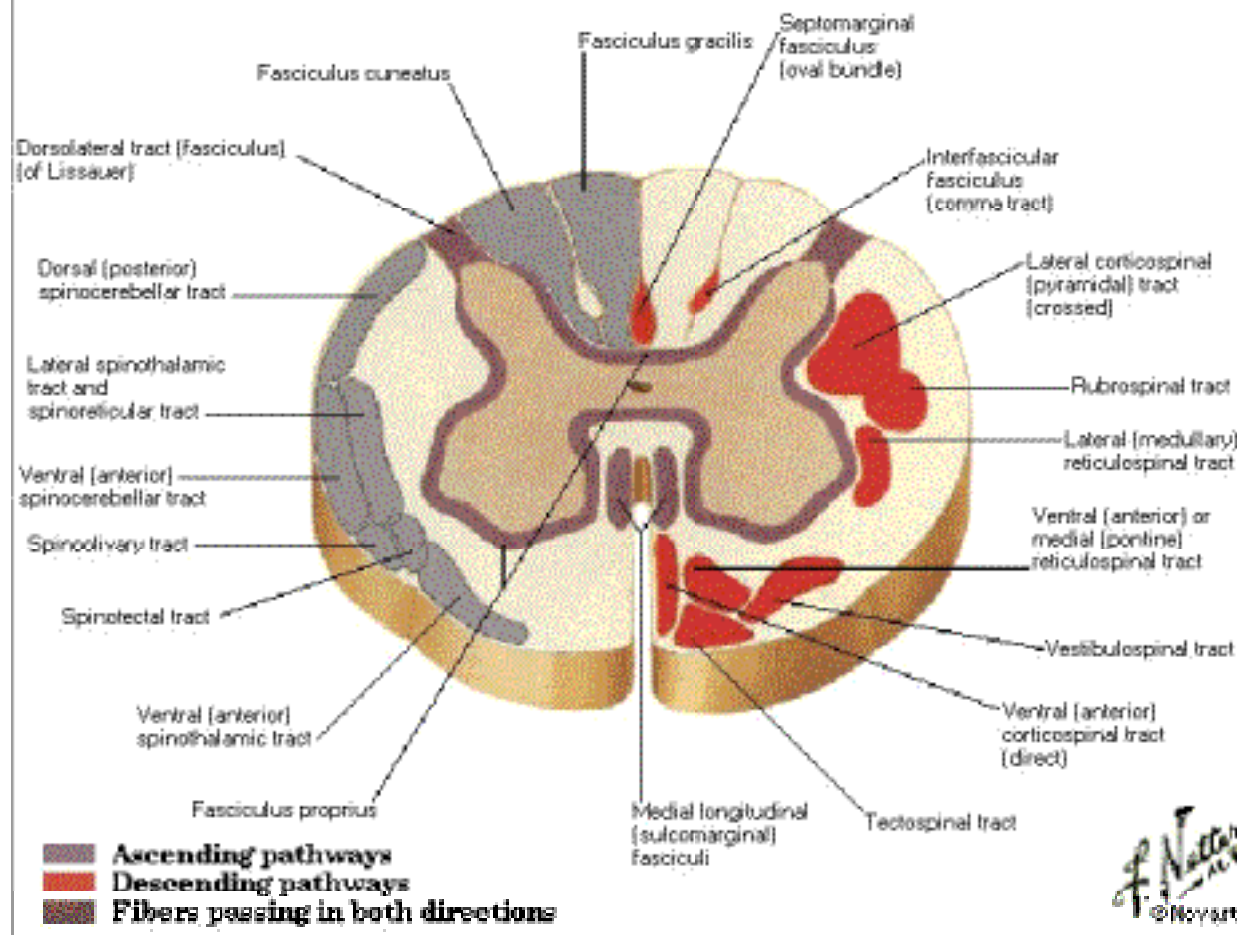


Sections through spinal cord at various levels



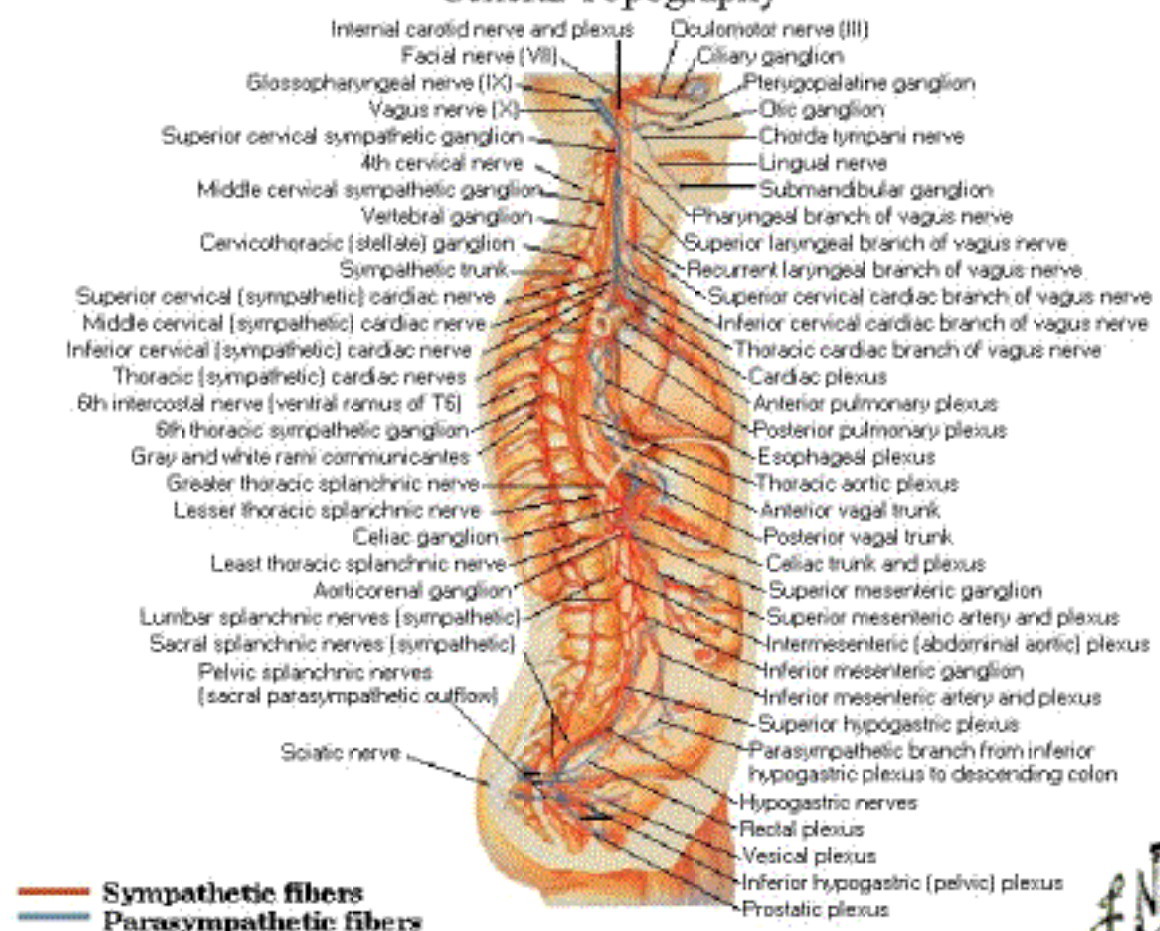
Spinal Cord Cross Sections

Fiber Tracts



Autonomic Nervous System

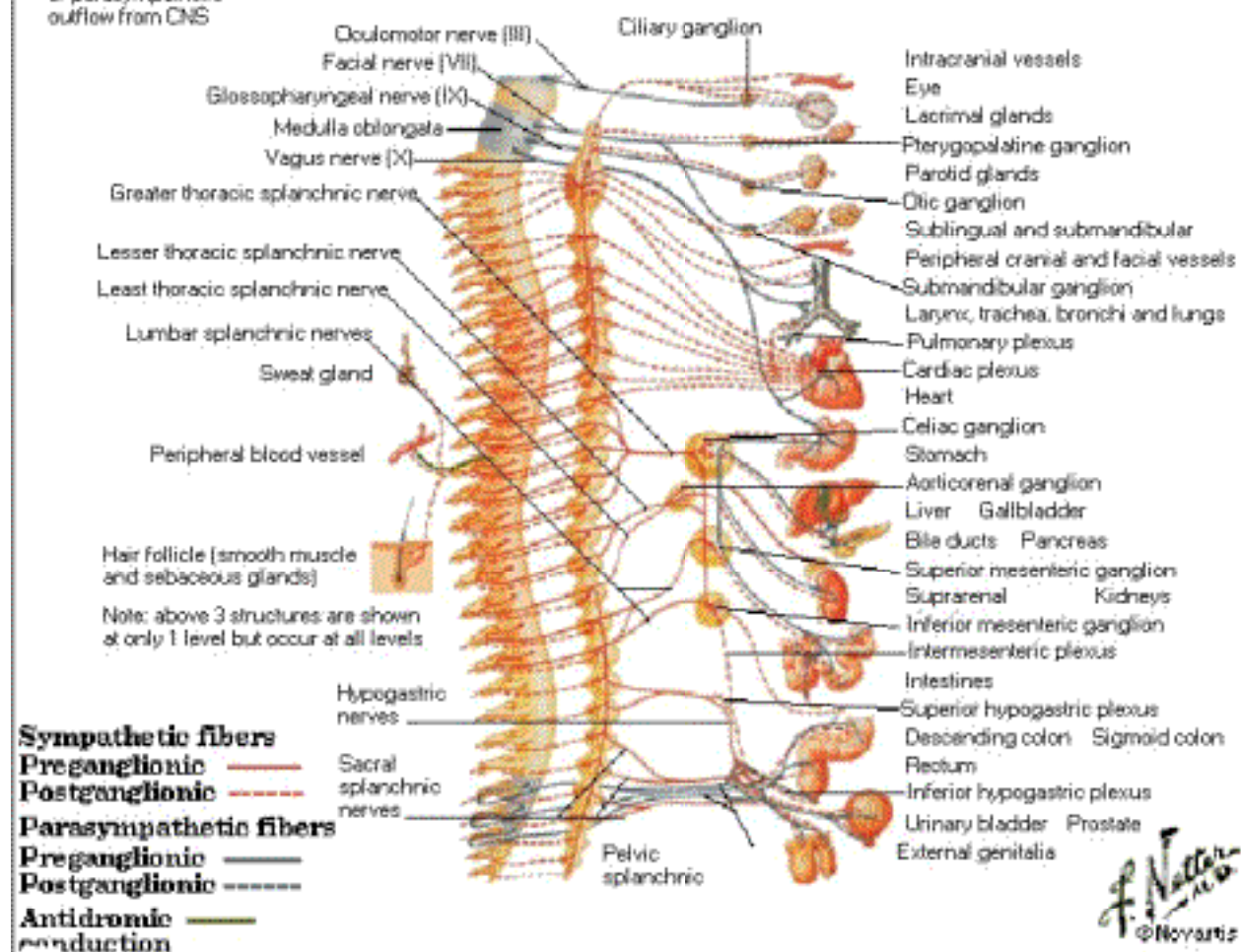
General Topography



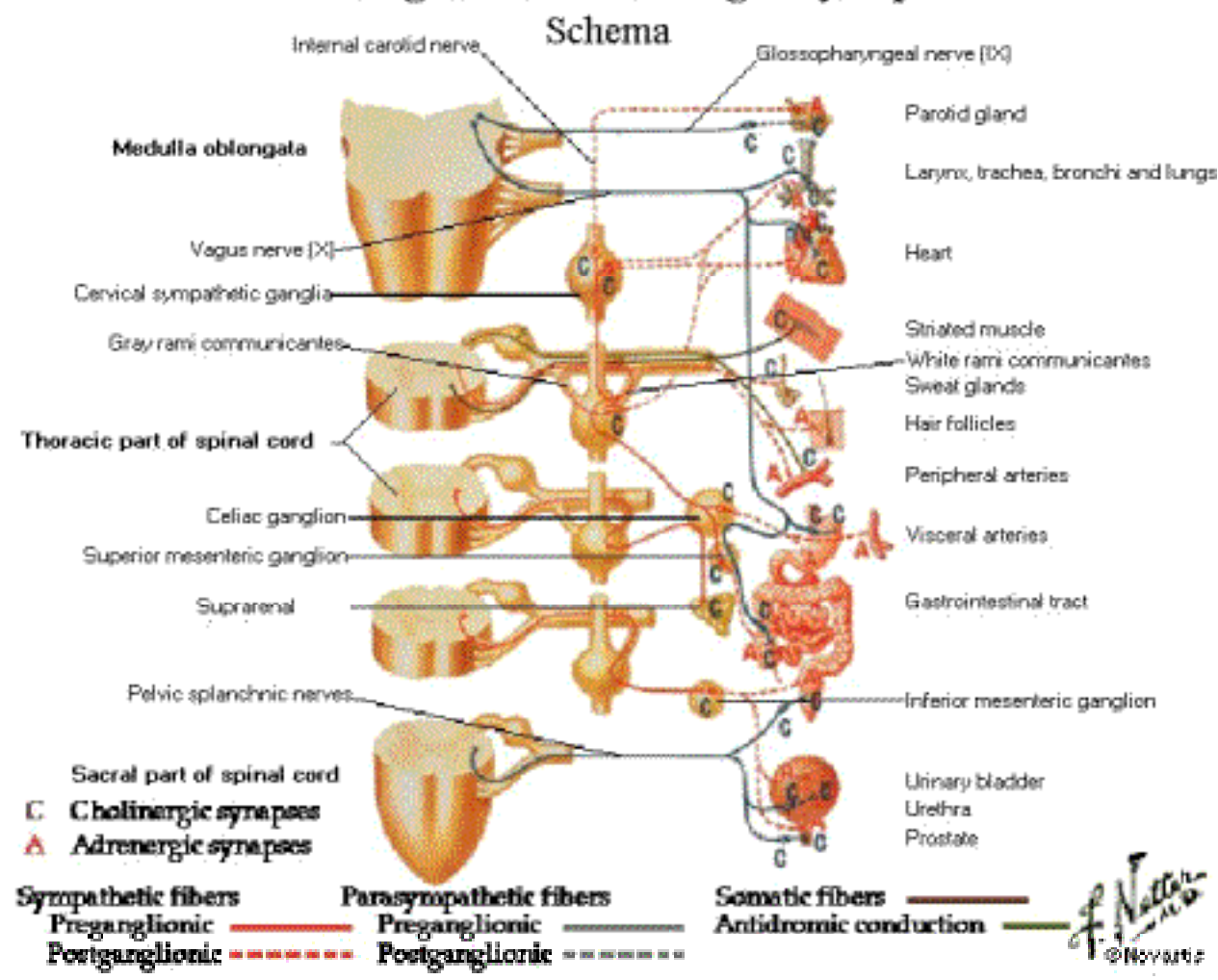
Autonomic Nervous System

Schema

Note: blue-shaded areas indicate zones of parasympathetic outflow from CNS

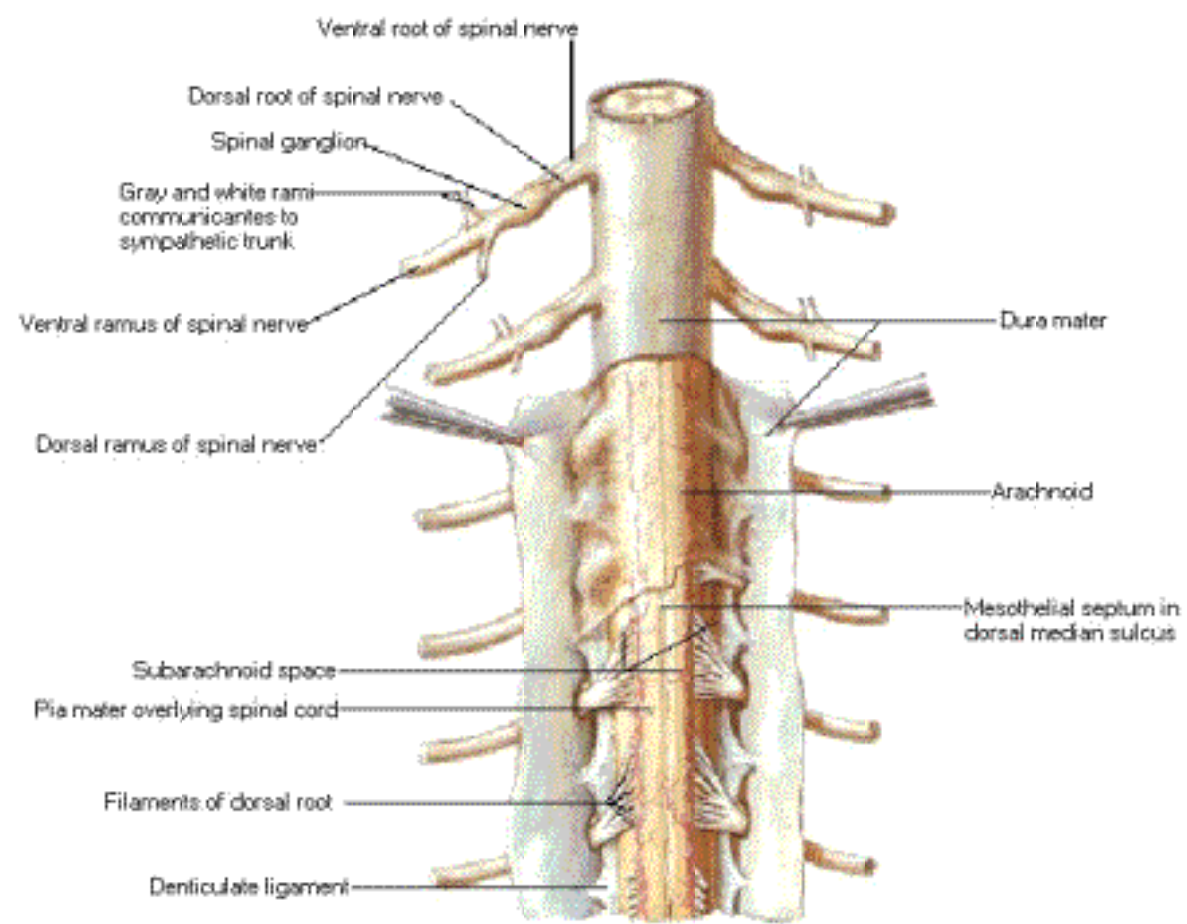


Cholinergic and Adrenergic Synapses



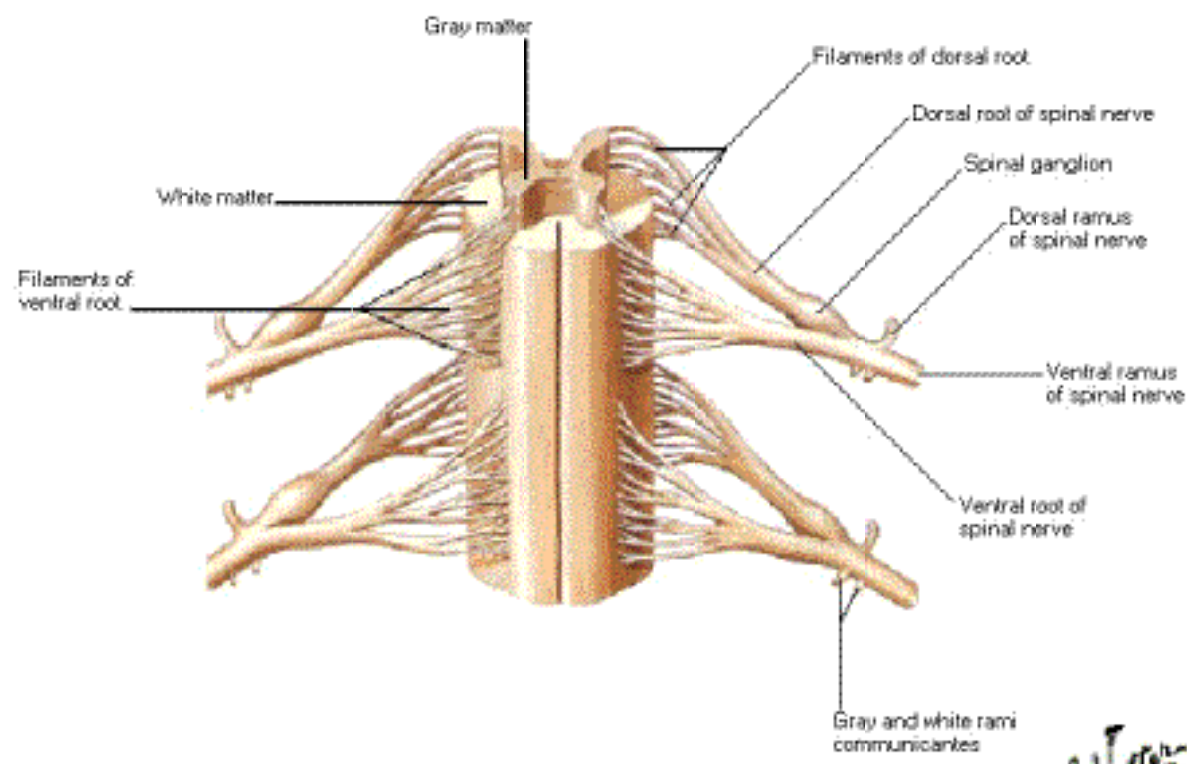
Spinal Membranes and Nerve Roots

Posterior View



Spinal Membranes and Nerve Roots

Anterior View

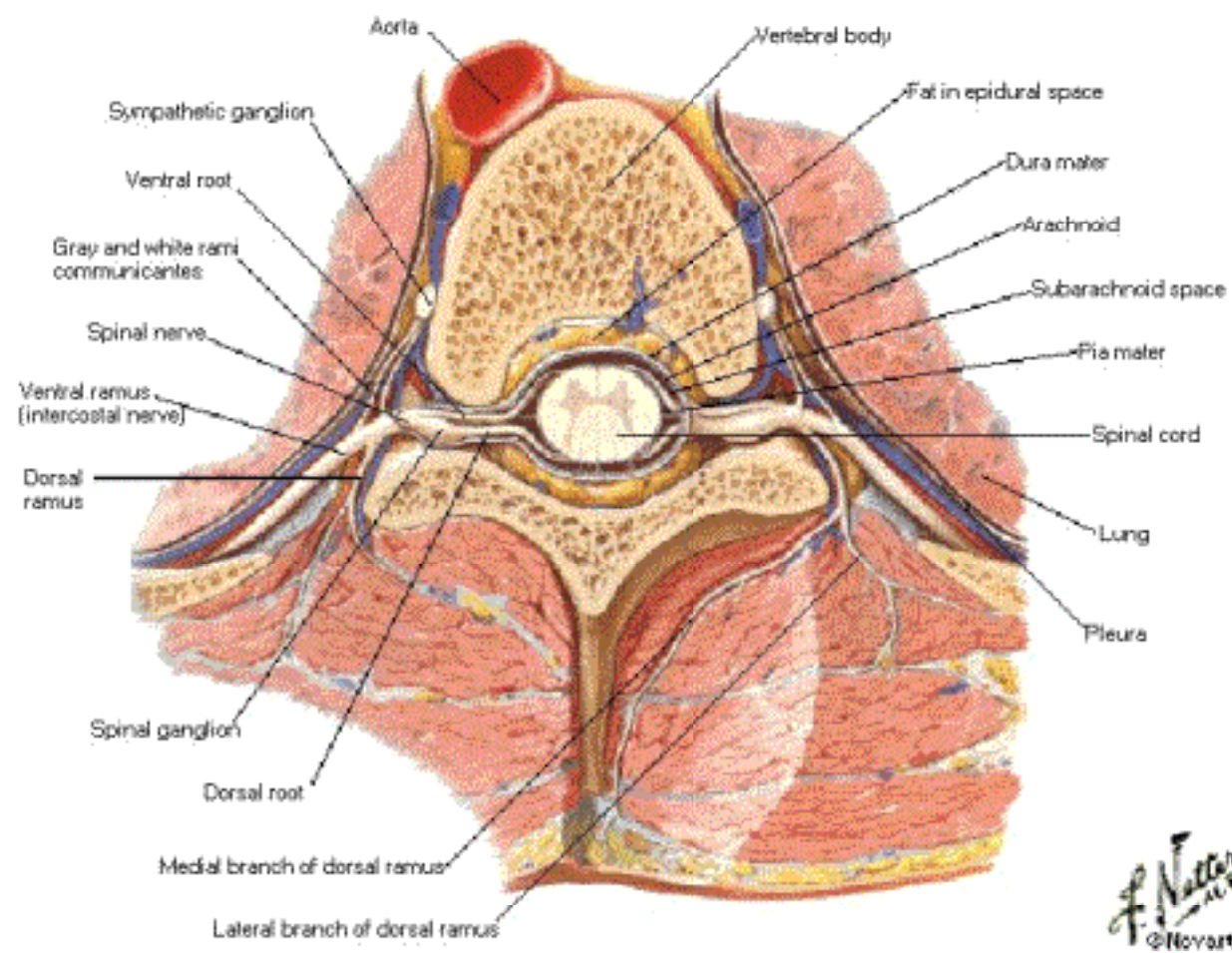


Membranes removed (greatly magnified)

F. Netter M.D.
© Novartis

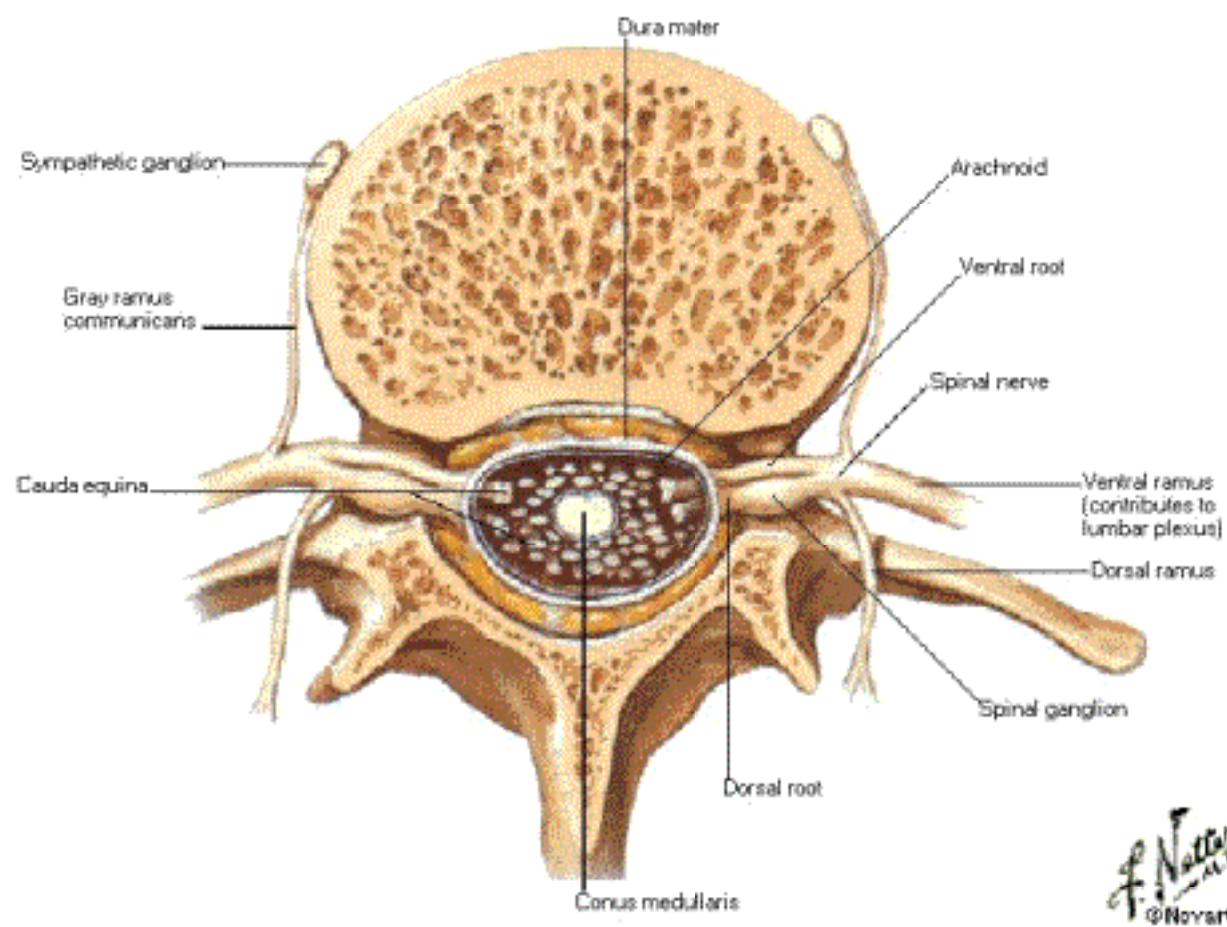
Spinal Nerve Origin

Section through Thoracic Vertebra



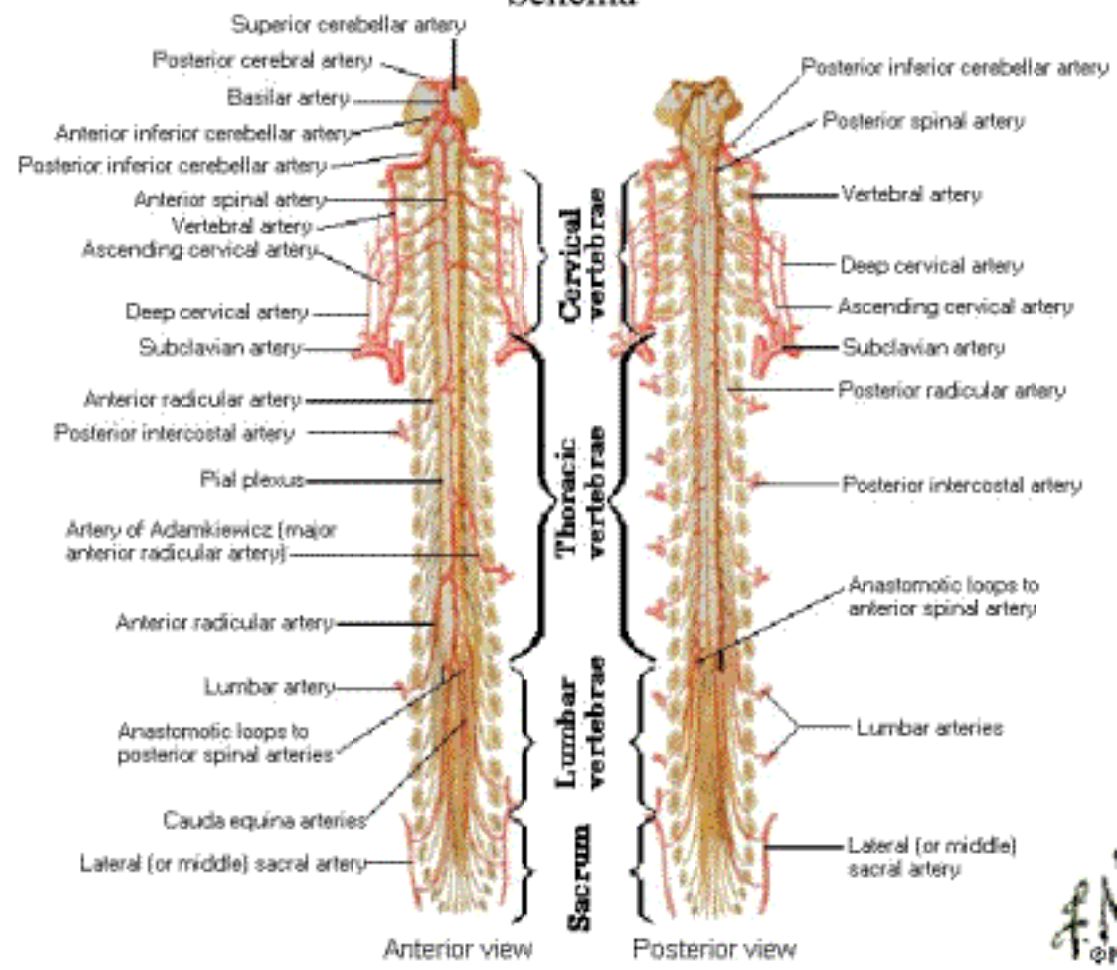
Spinal Nerve Origin

Section through Lumbar Vertebra



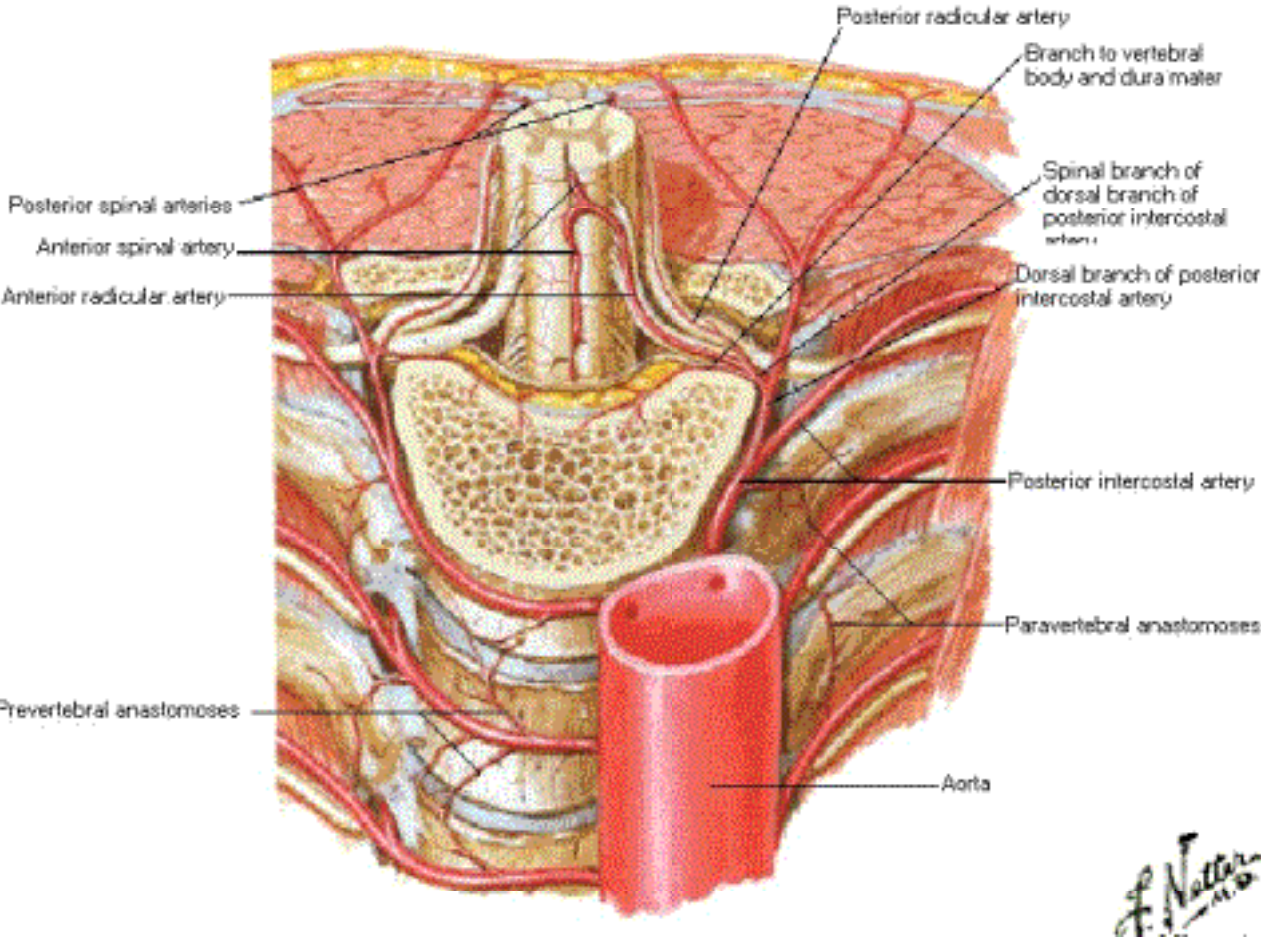
Arteries of Spinal Cord

Schema

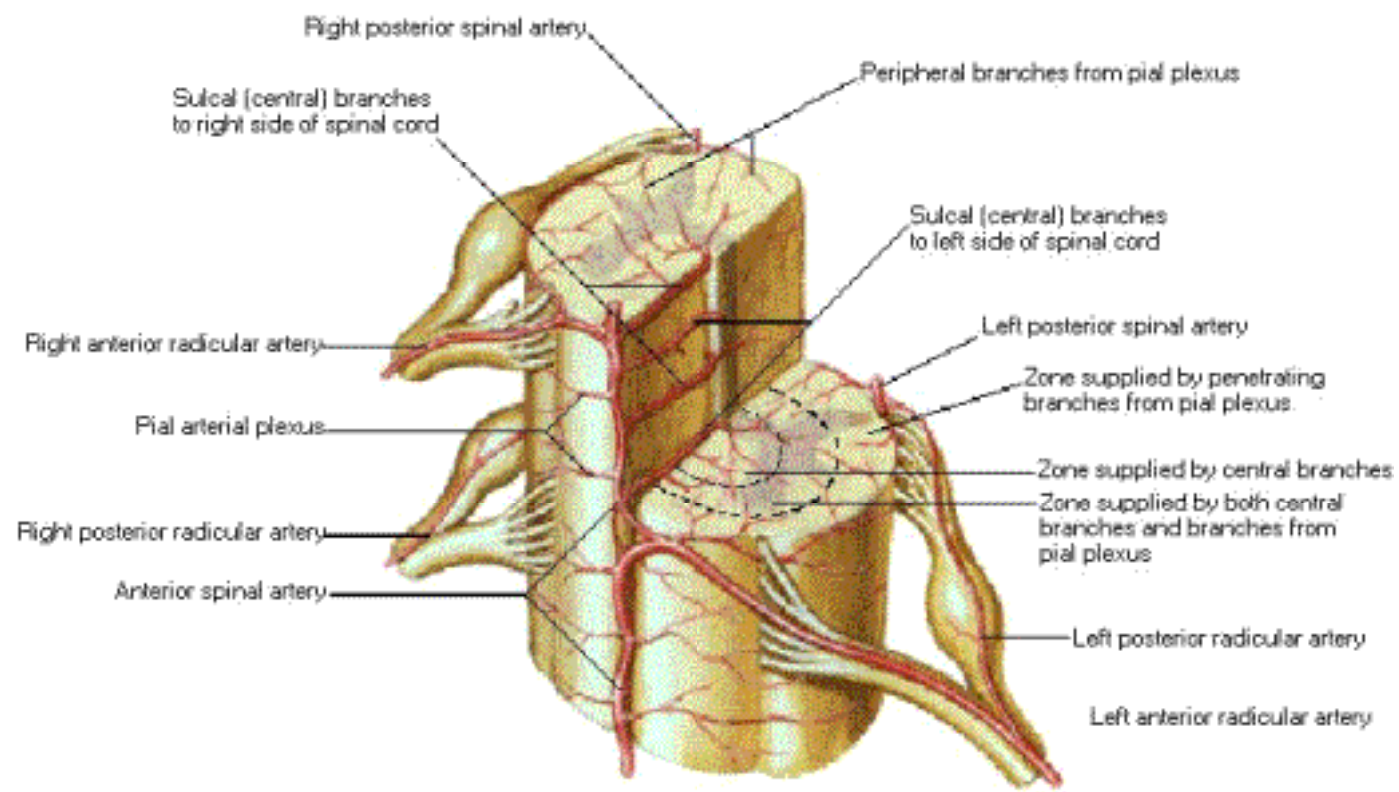


Arteries of Spinal Cord - Intrinsic Distribution

Thoracic Section

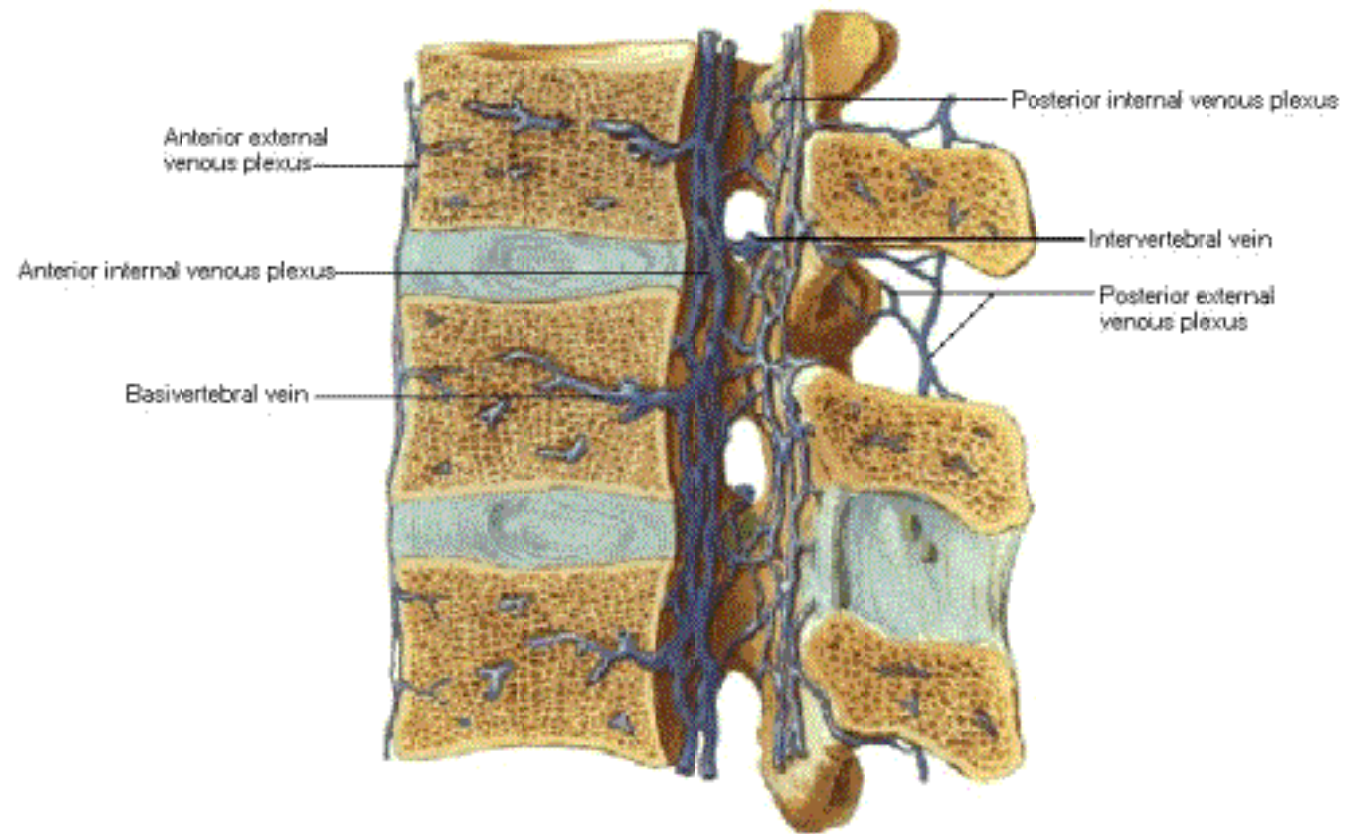


Arteries of Spinal Cord - Intrinsic Distribution Schema



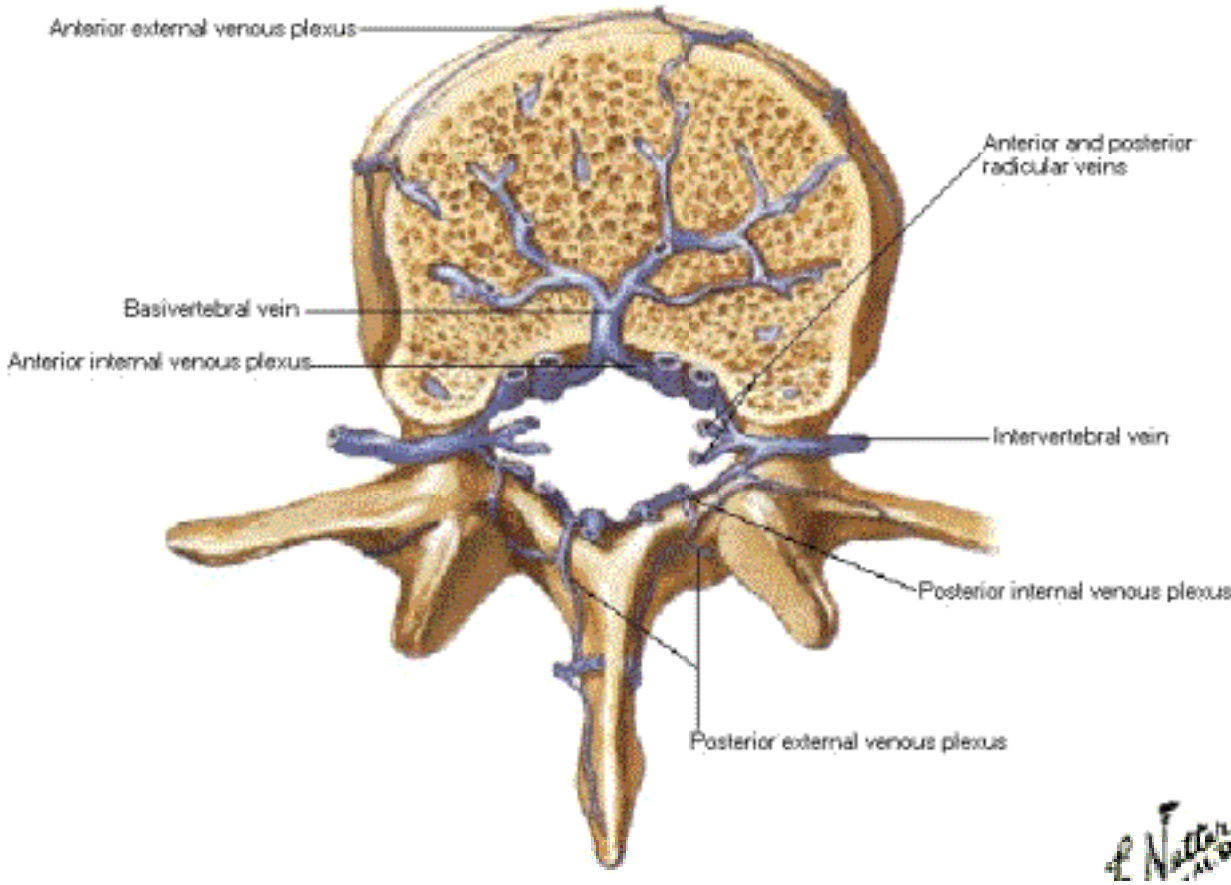
Veins of Spinal Cord

Sagittal Section [without Cord]



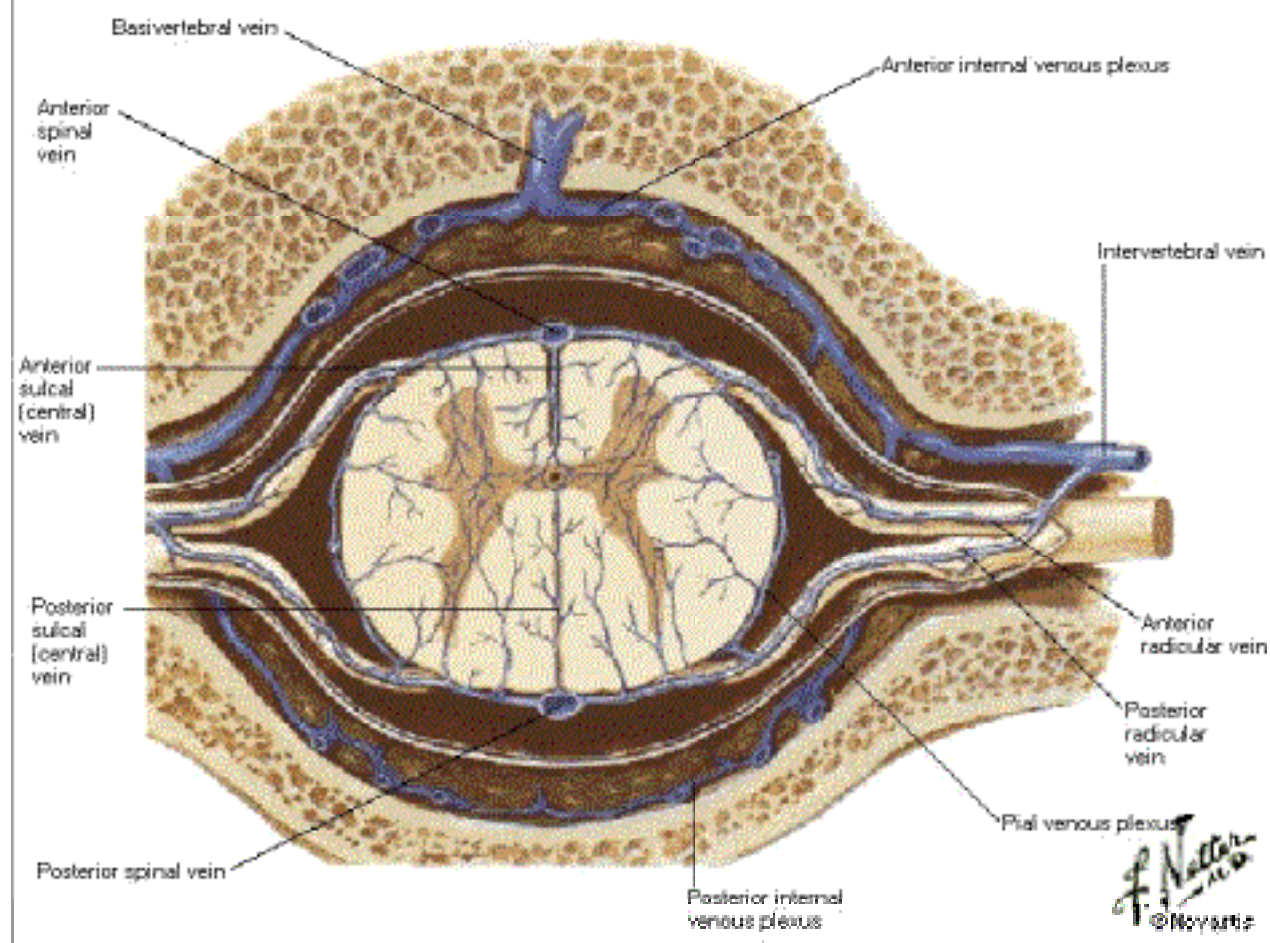
Veins of Spinal Cord

Superior View [without Cord]

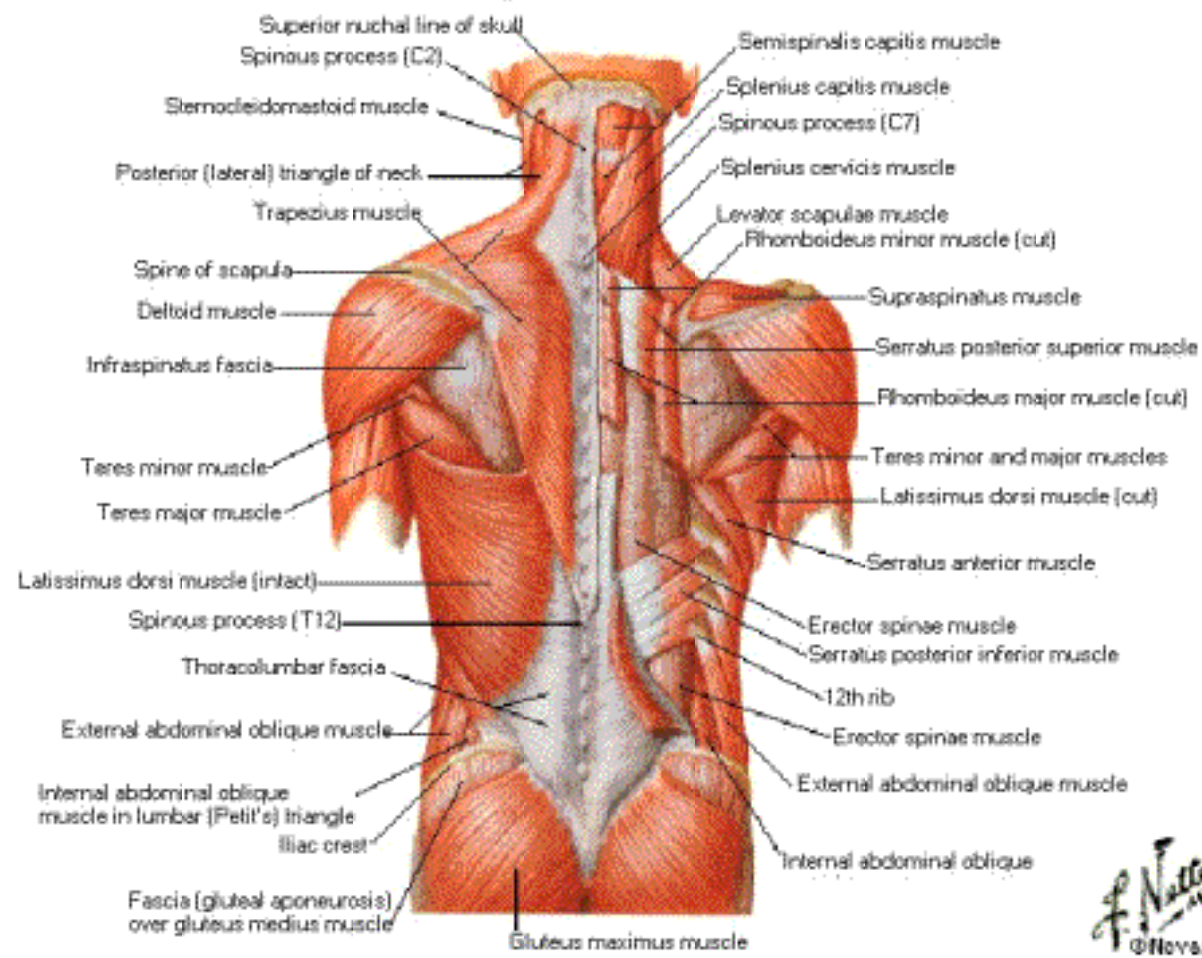


Veins of Spinal Cord

Superior View [Magnified with Cord]



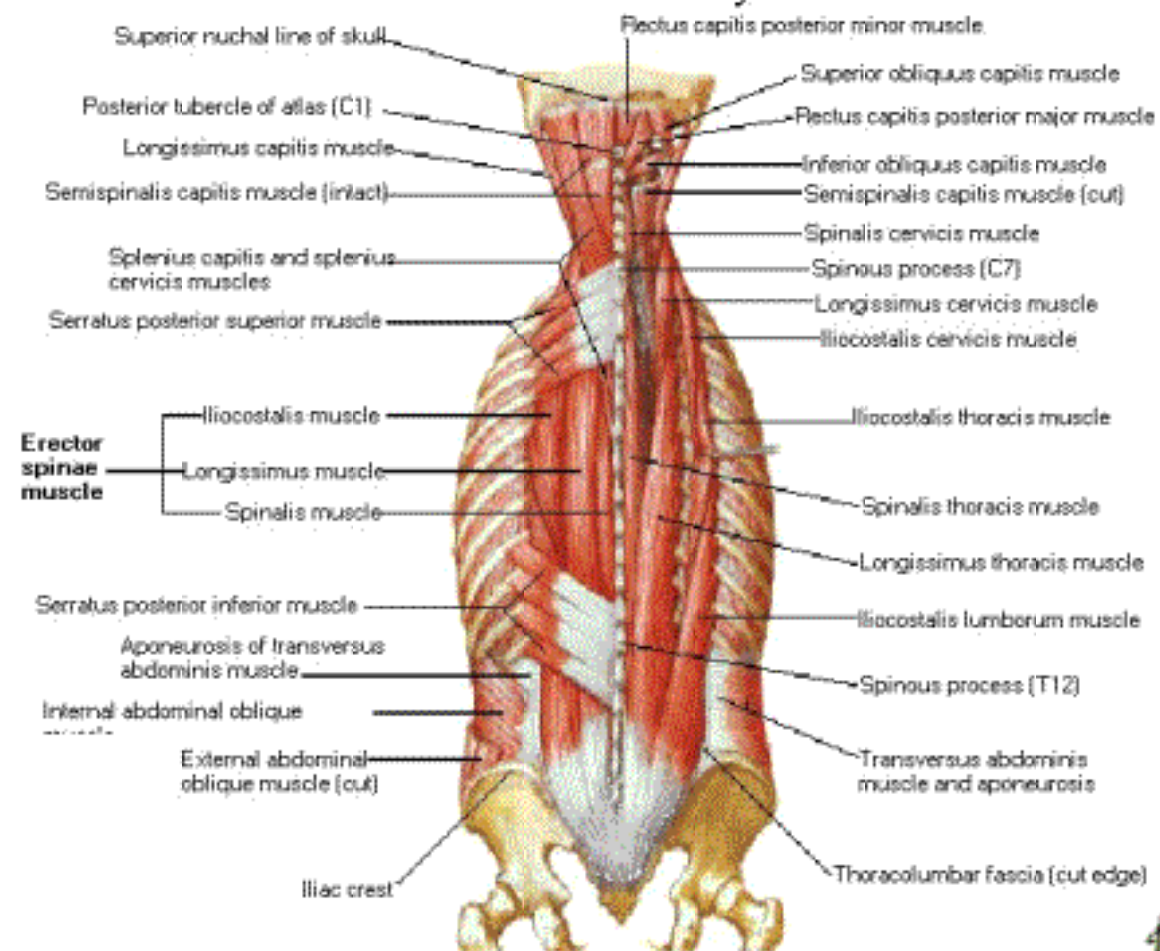
Muscles of Back Superficial Layers



F. Naga
@Naga

Muscles of Back

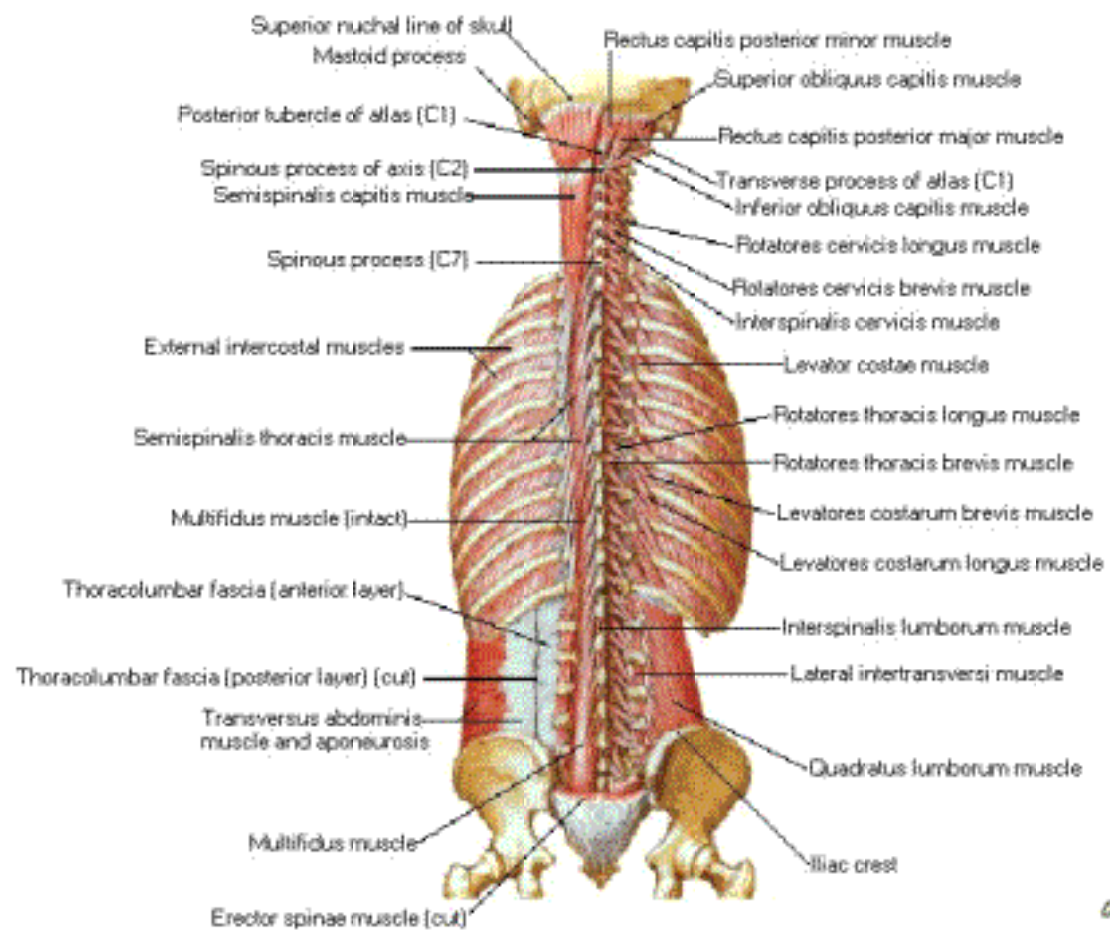
Intermediate Layers



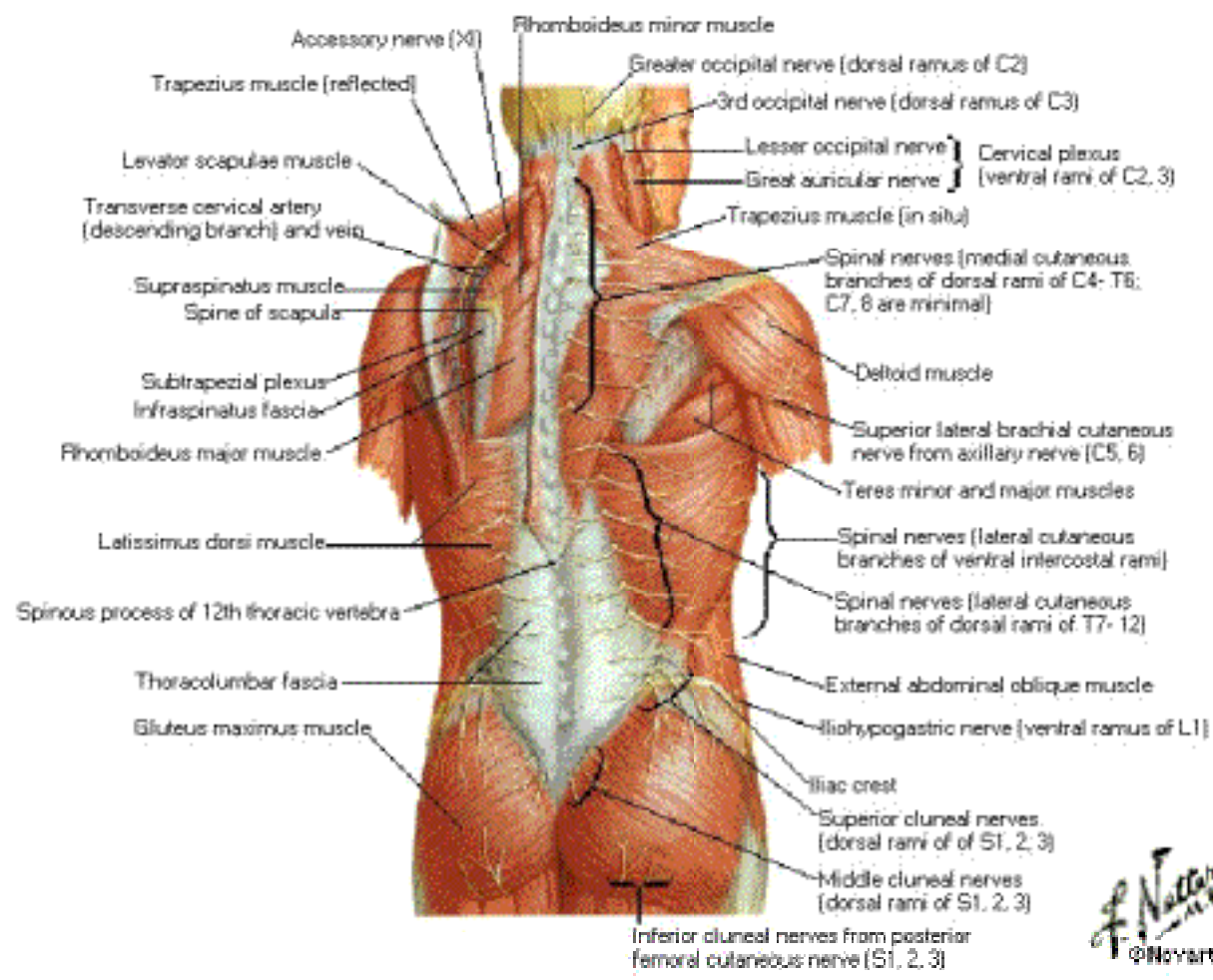
♀

Muscles of Back

Deep Layers

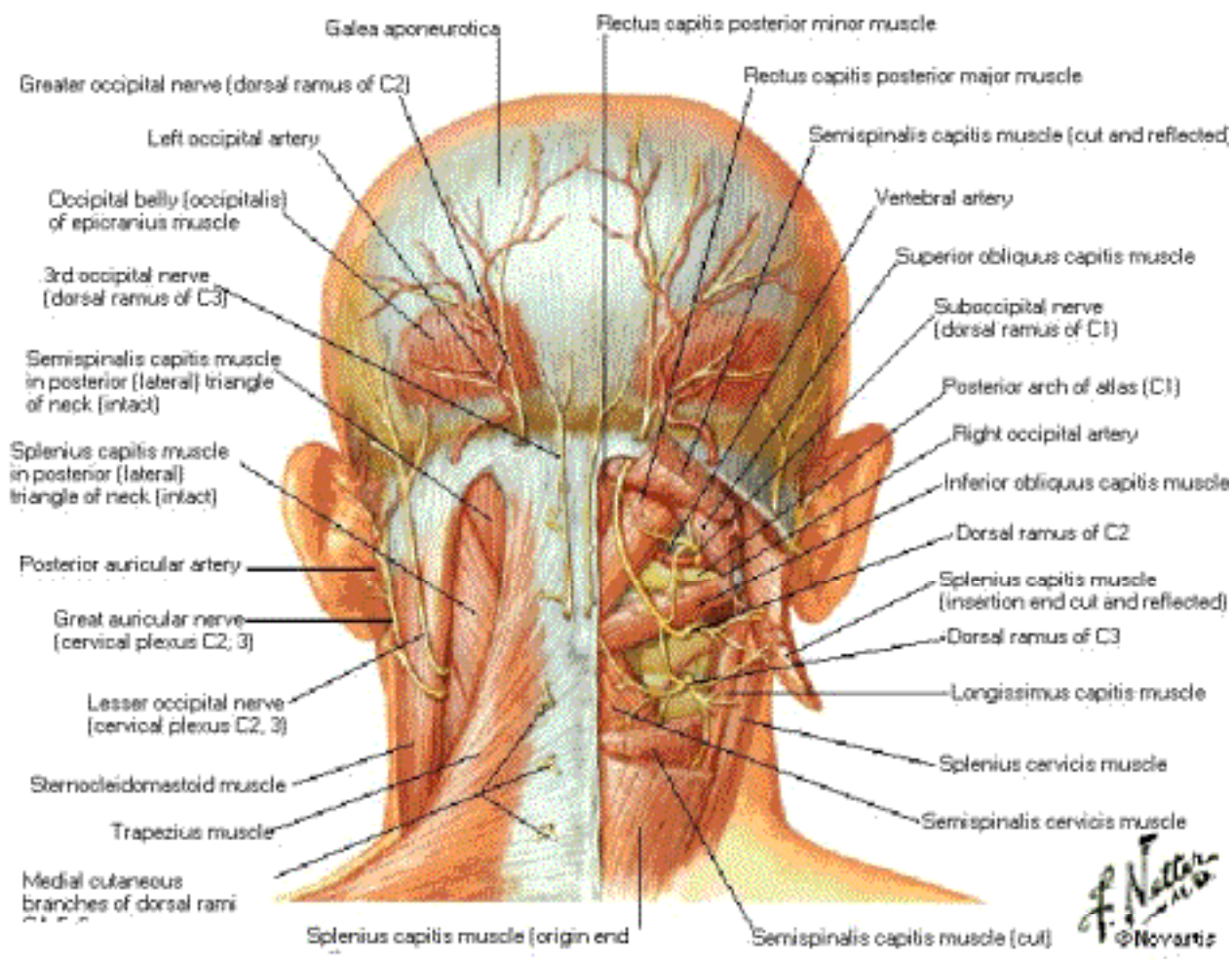


Nerves of Back



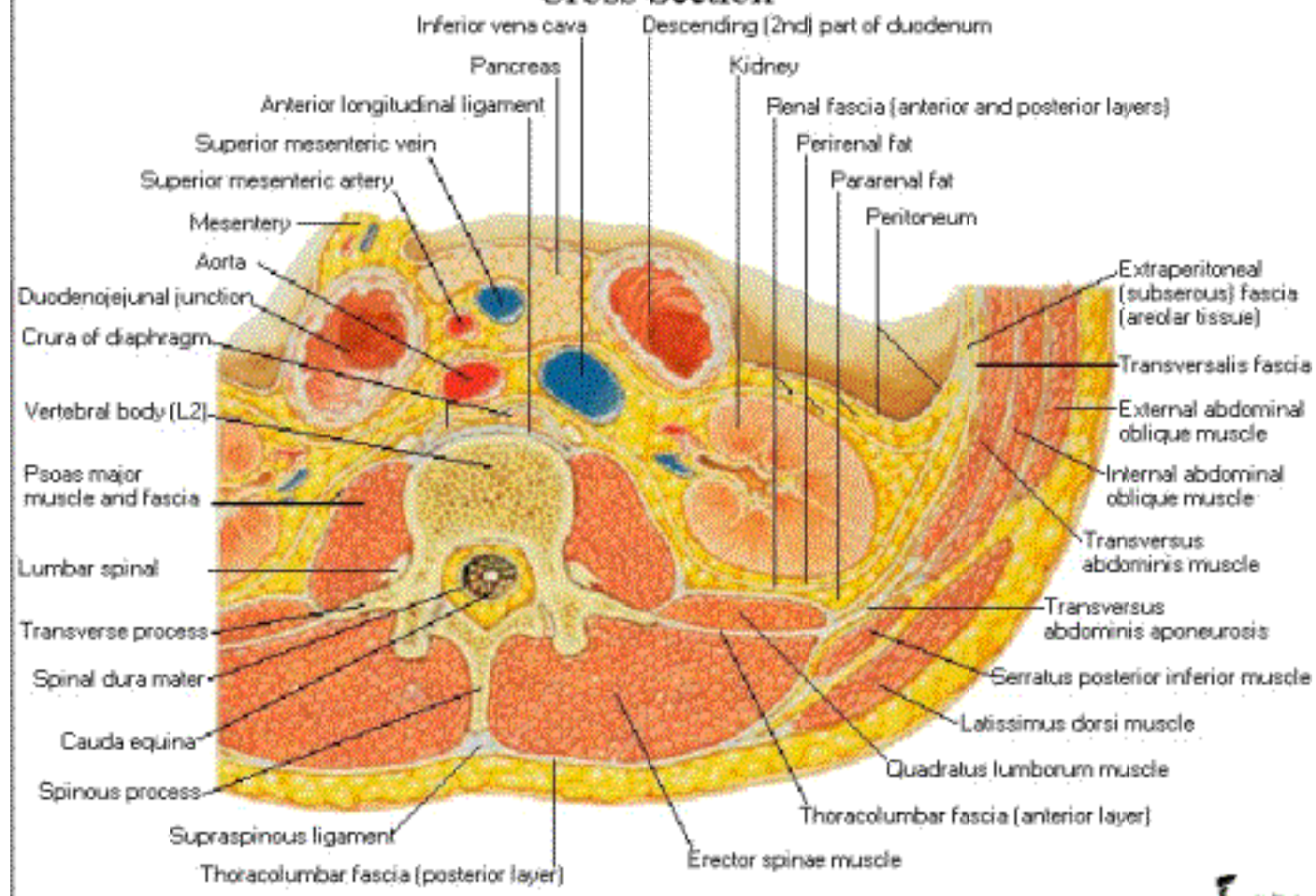
F. N. N. N.
 ©Novart

Suboccipital Triangle



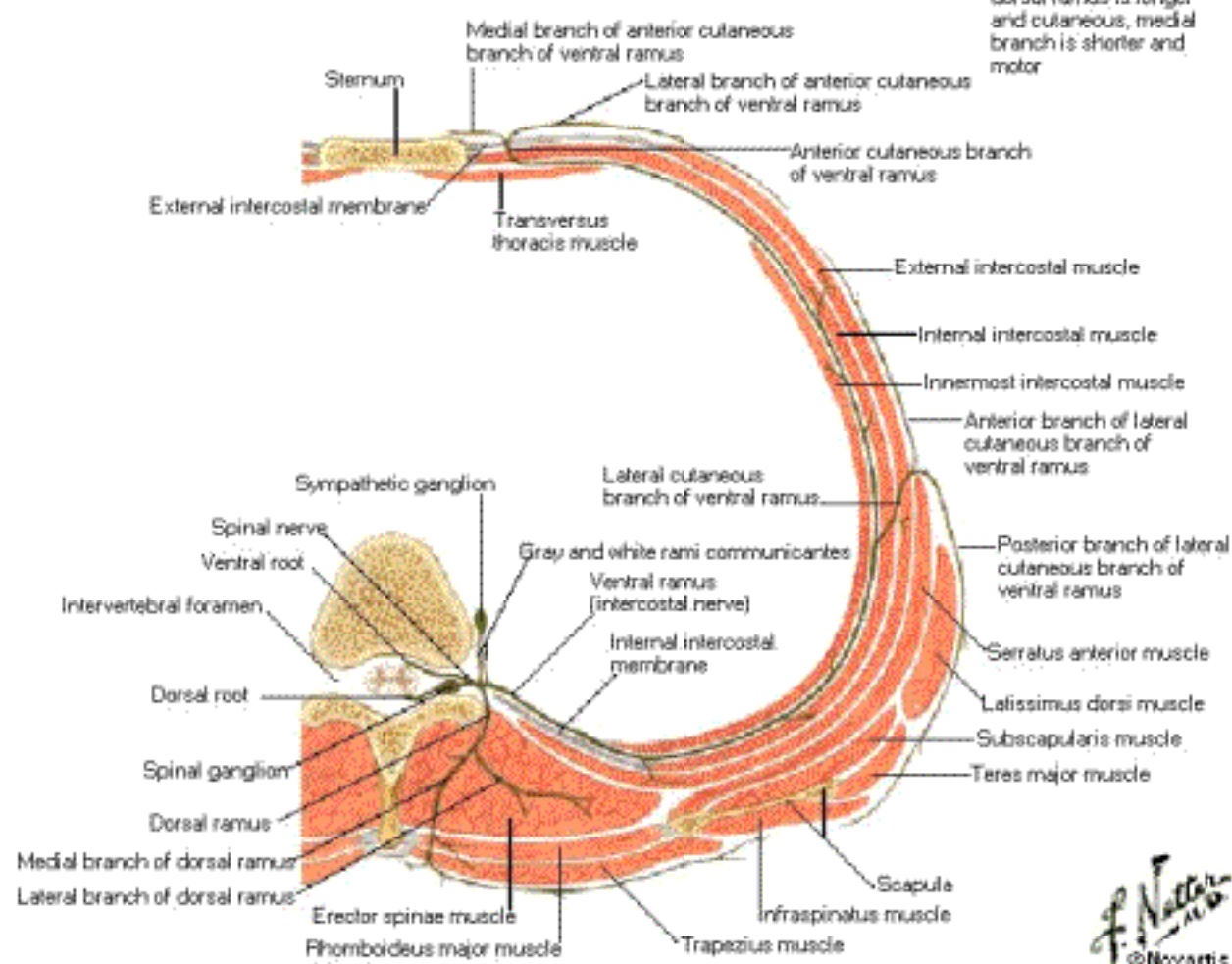
Lumbar Region of Back

Cross Section



Typical Thoracic Spinal Nerve

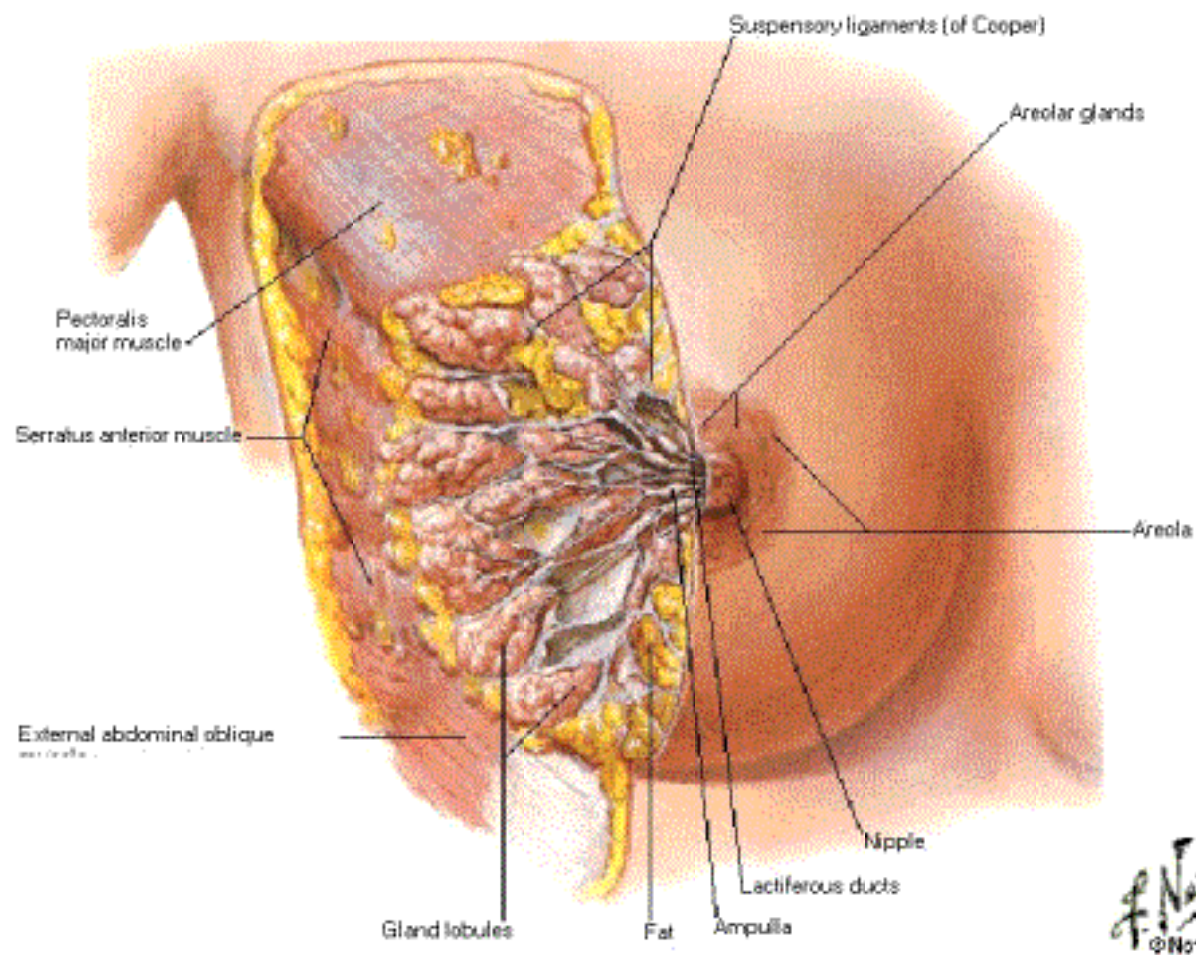
Note: in lower thoracic region lateral branch of dorsal ramus is longer and cutaneous, medial branch is shorter and motor



F. Netter
© Novartis

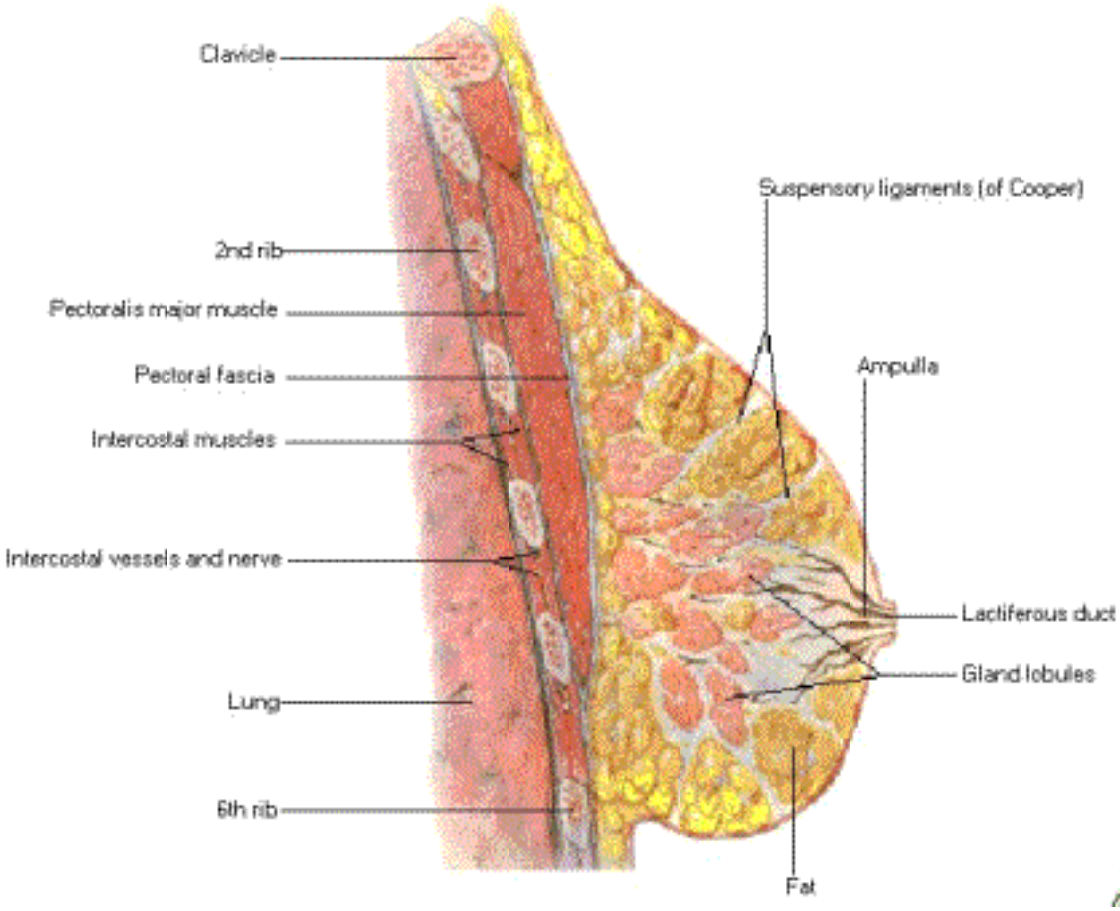
Mammary Gland

Anterolateral Dissection

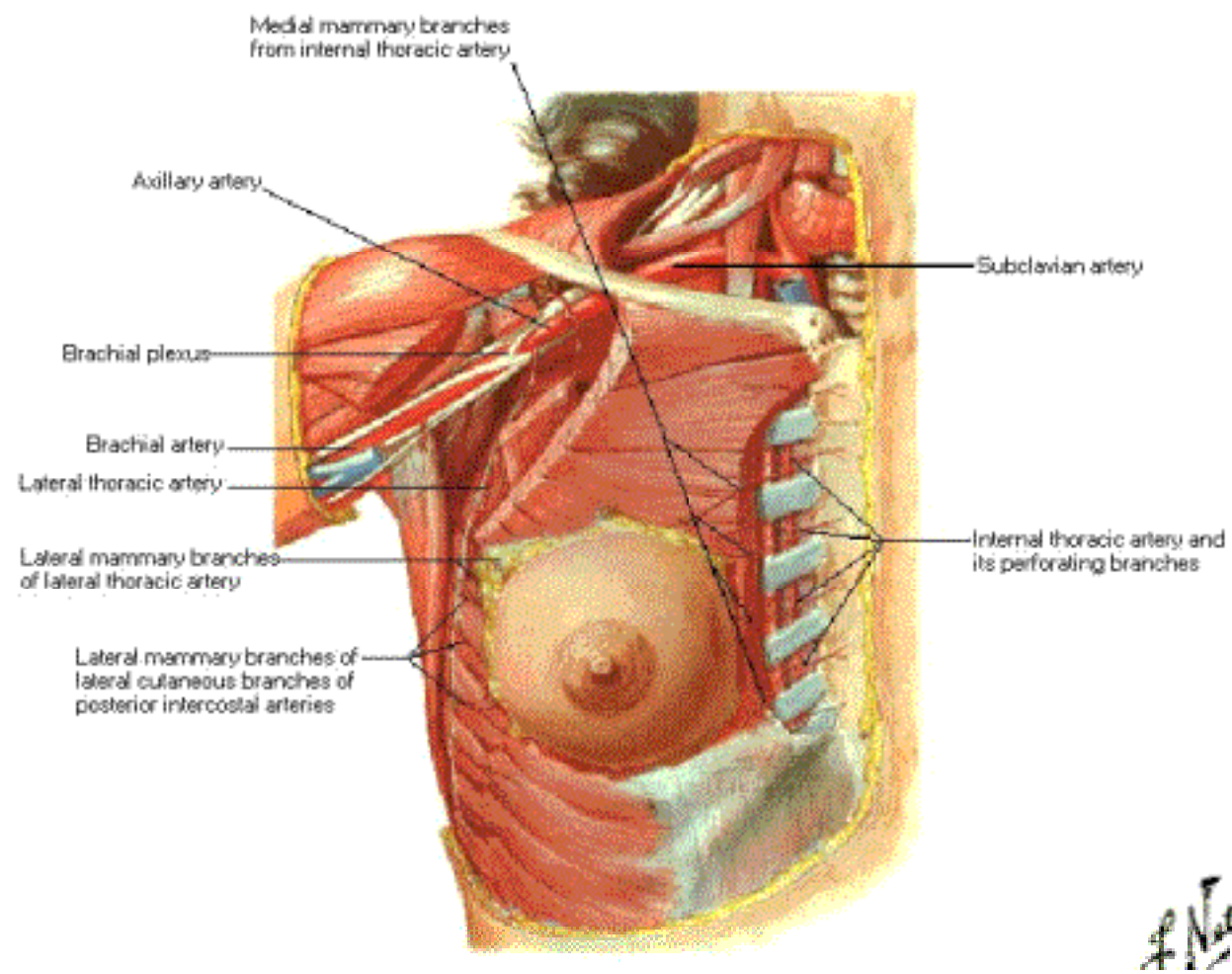


Mammary Gland

Sagittal Section

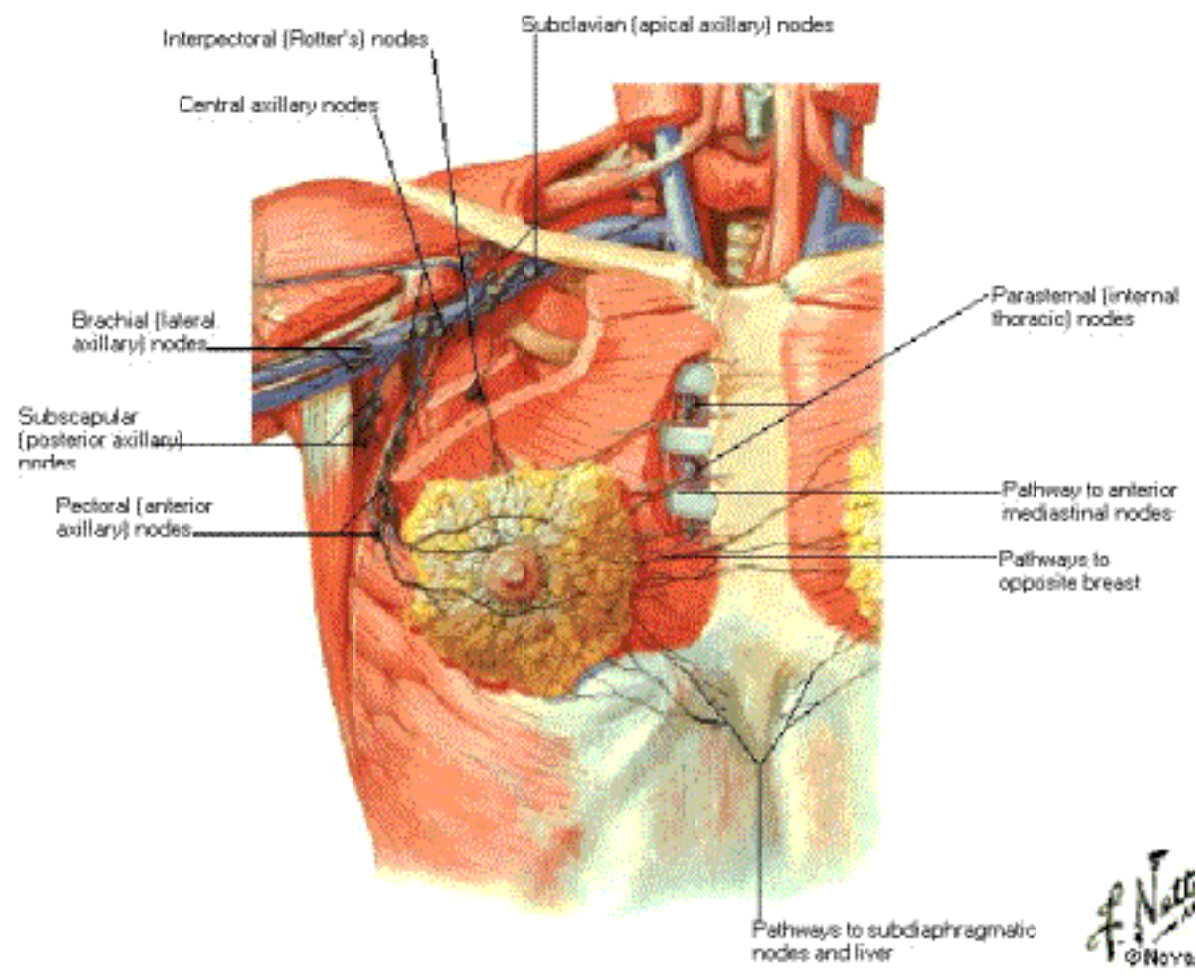


Arteries of Mammary Gland

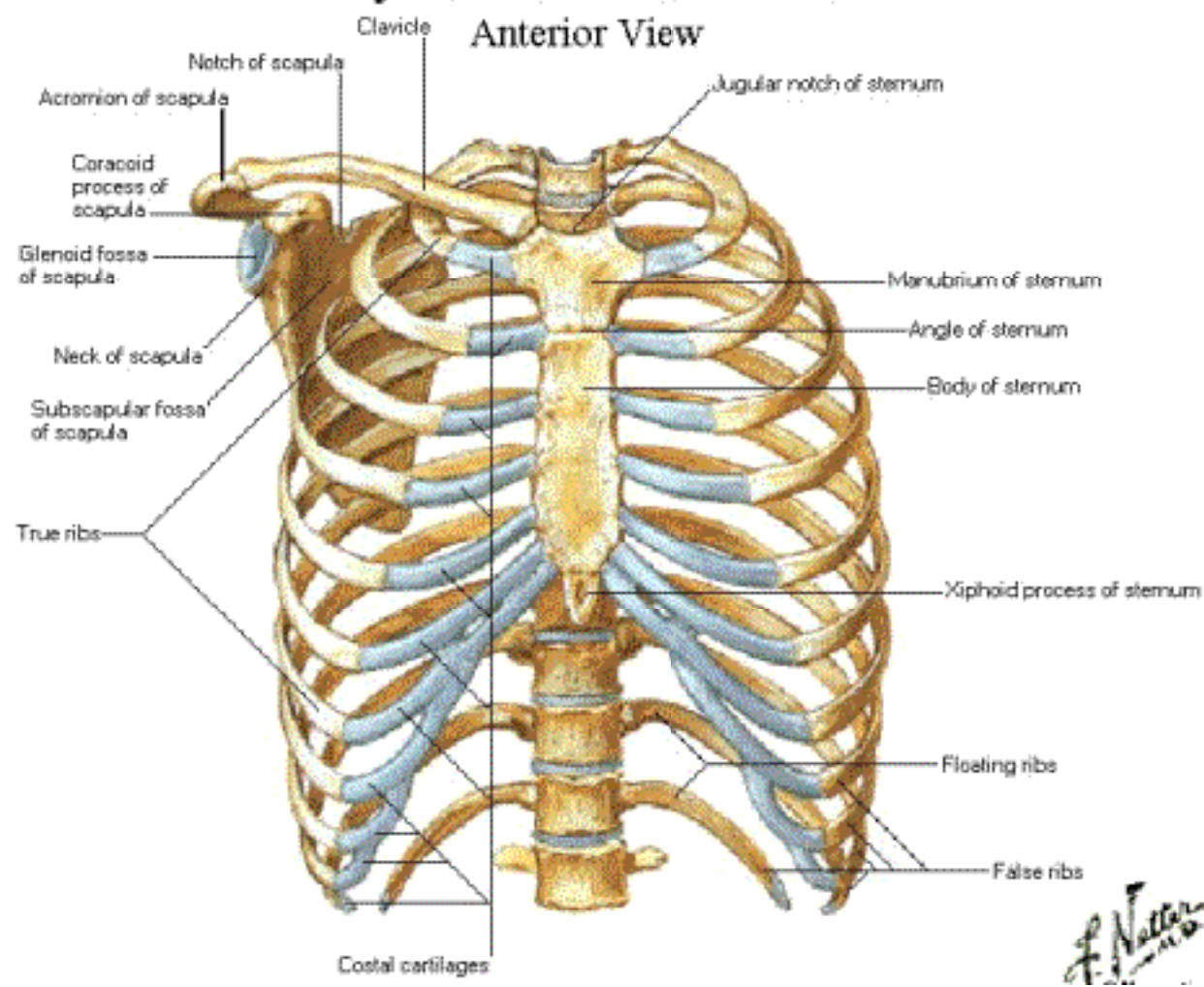


Handwritten signature

Lymph Vessels and Nodes of Mammary Gland

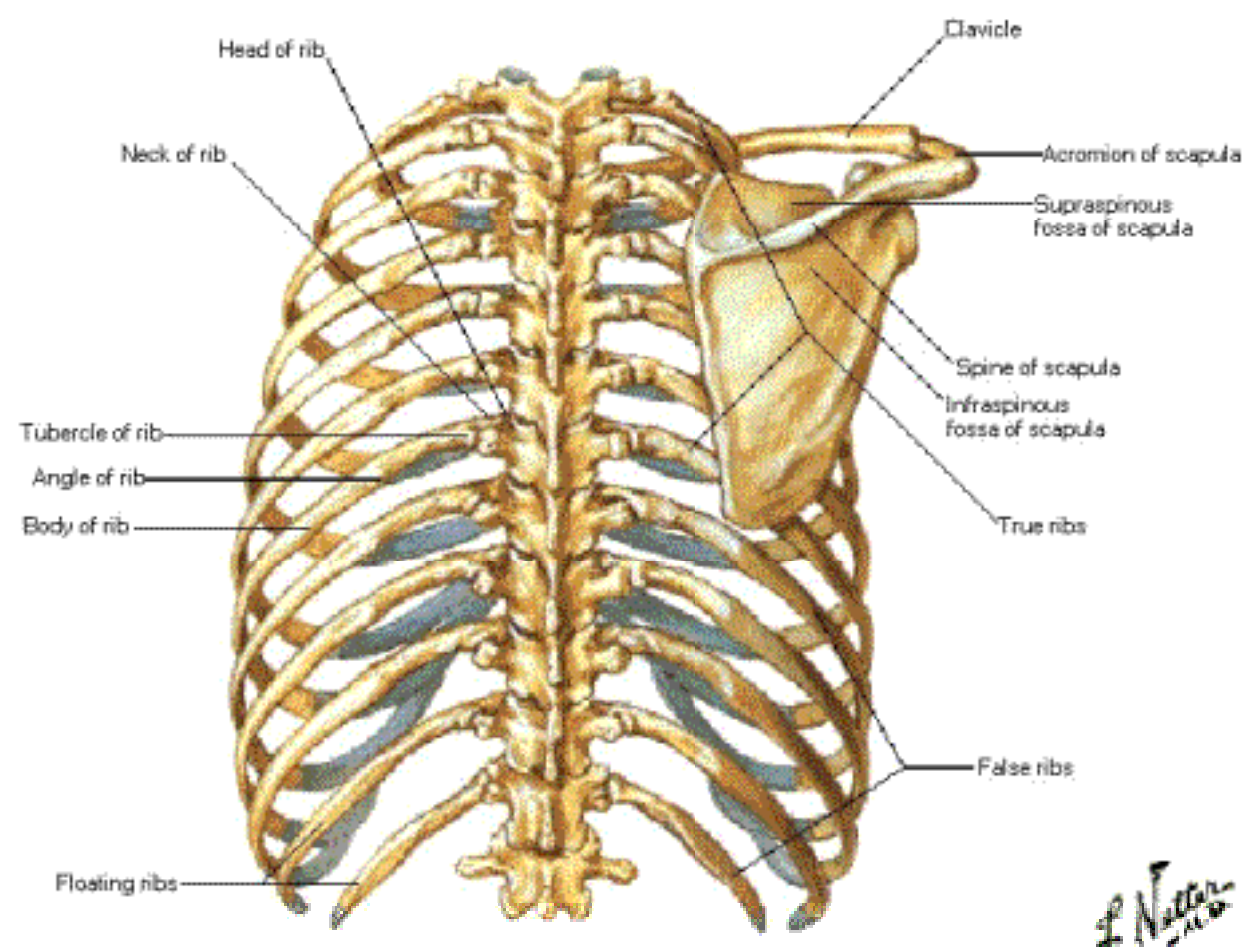


Bony Framework of Thorax

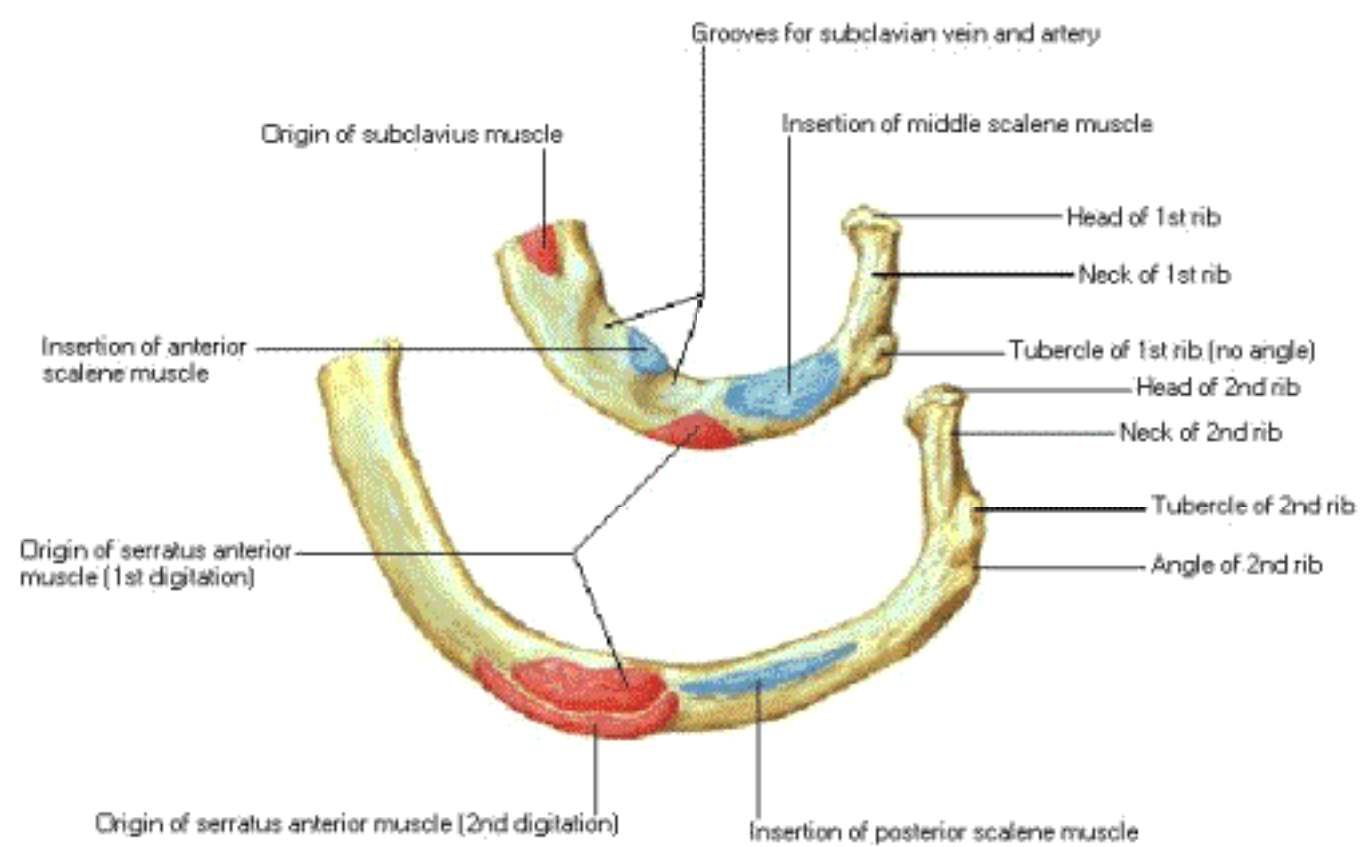


Bony Framework of Thorax

Posterior View

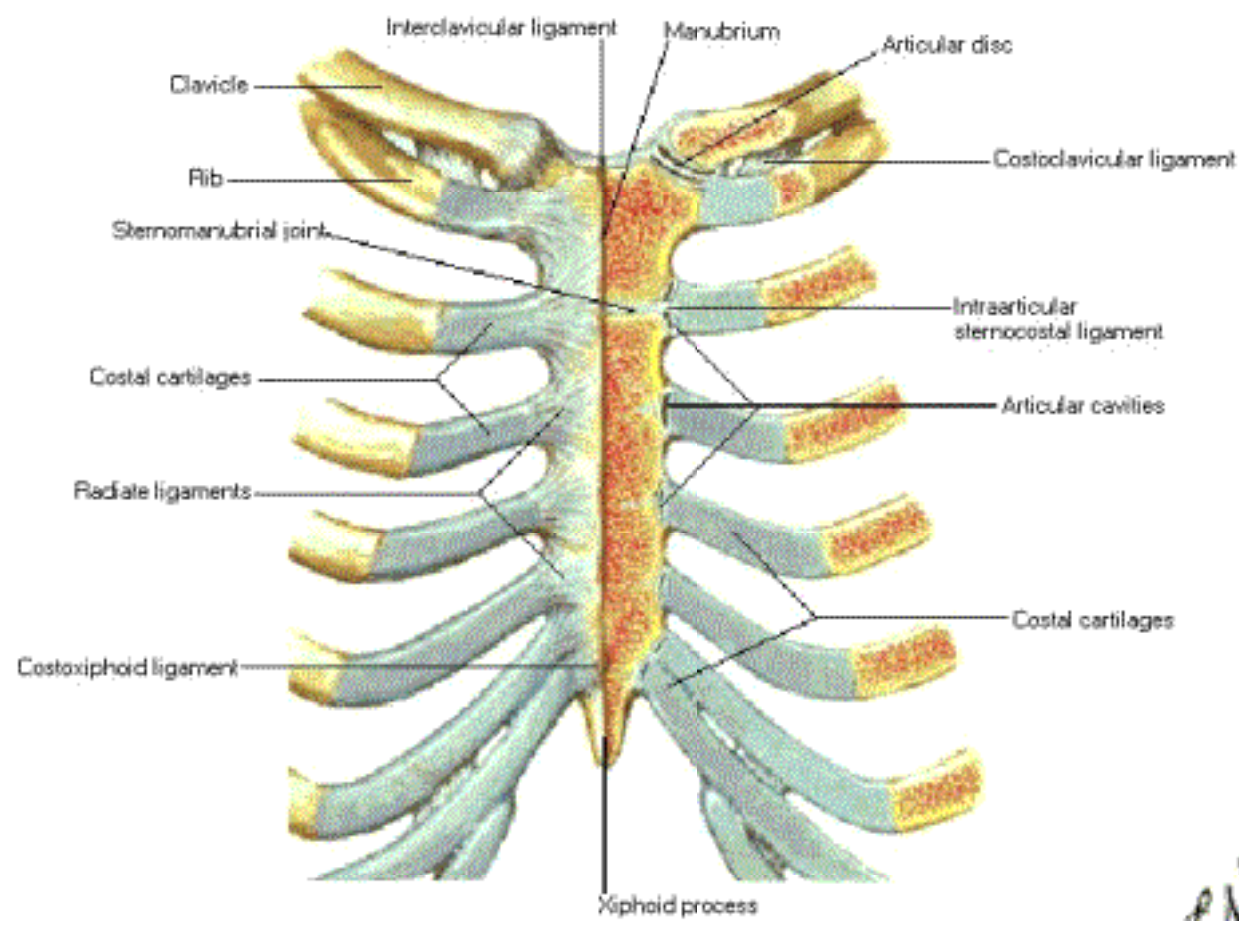


Left 1st and 2nd Ribs Superior Views



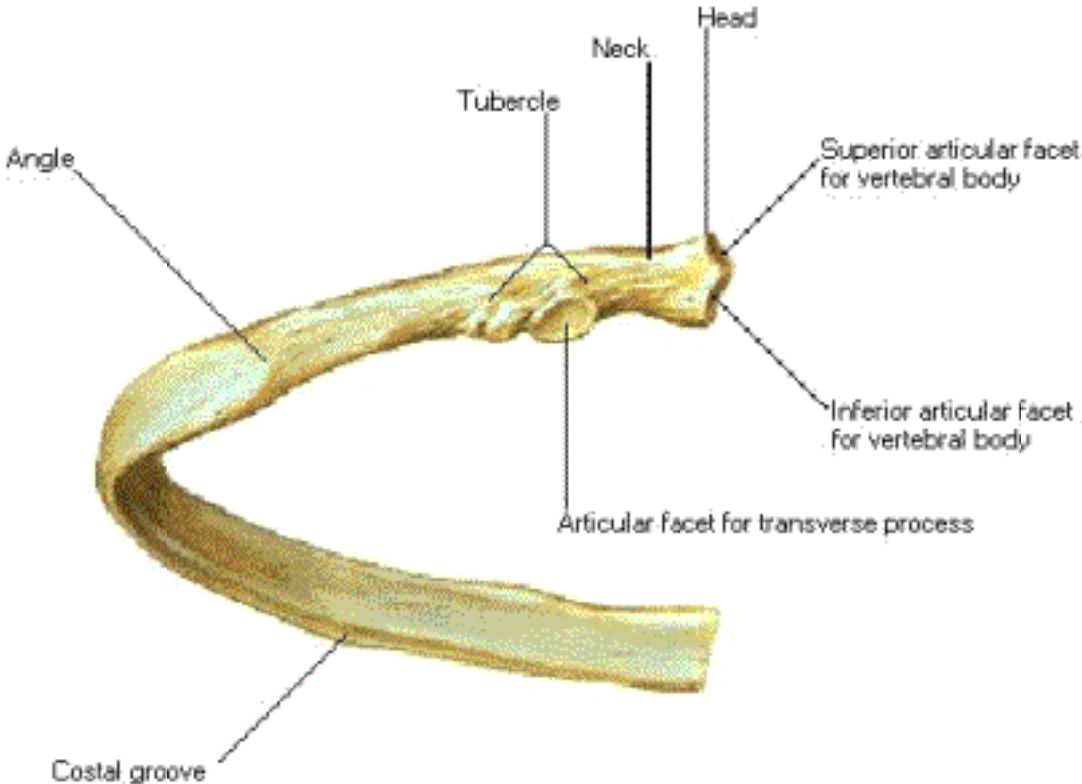
Sternocostal Articulations

Anterior View



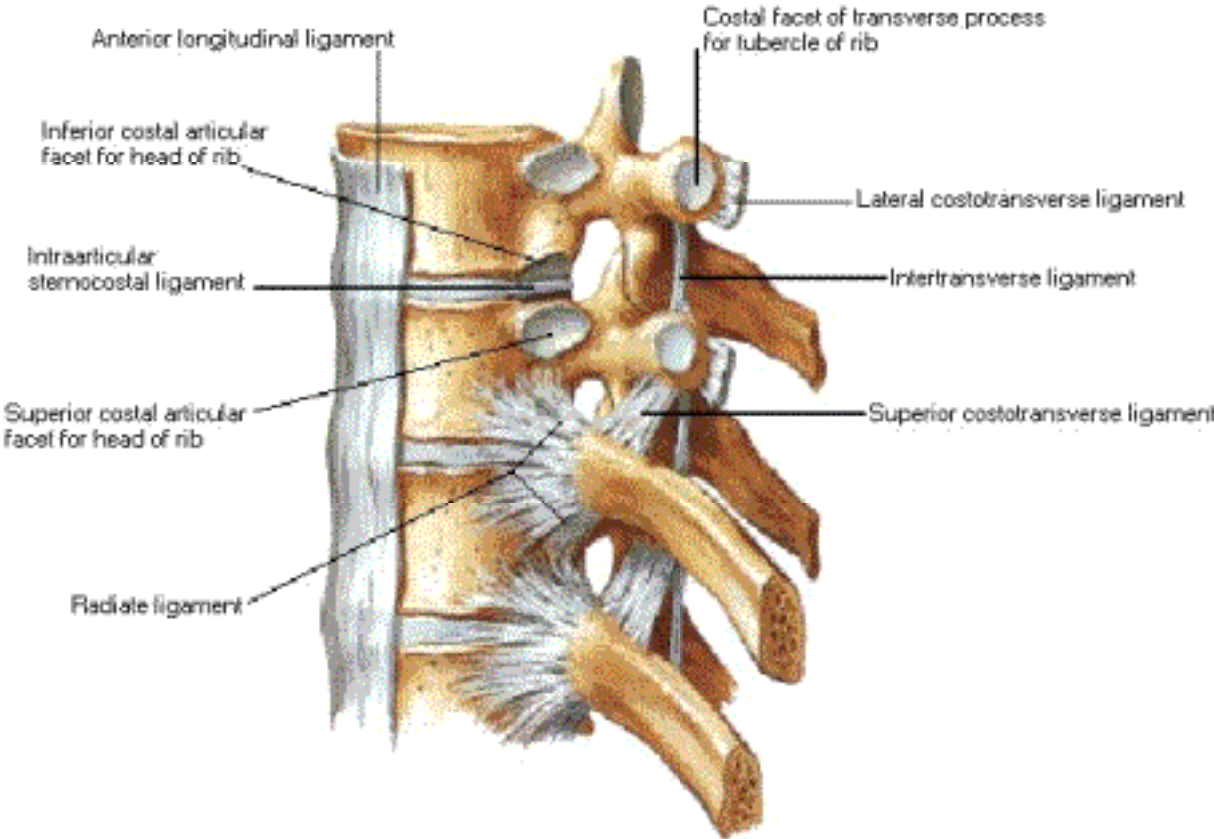
Middle Rib

Posterior View



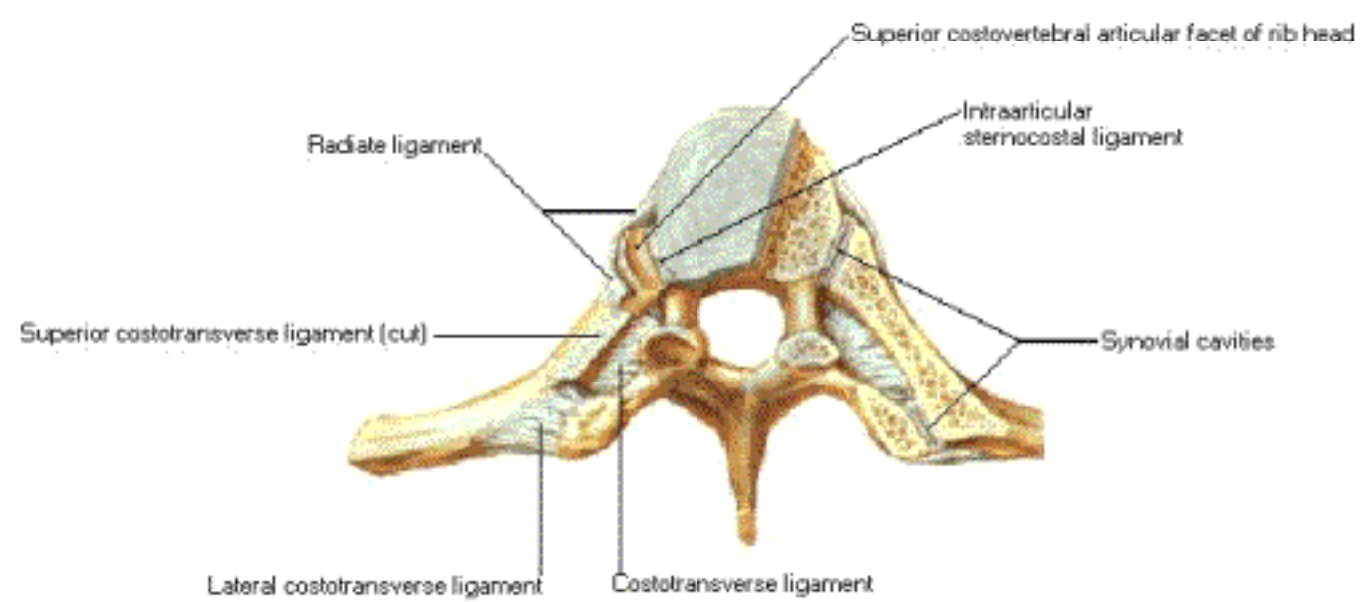
Costovertebral Joints

Left Lateral View



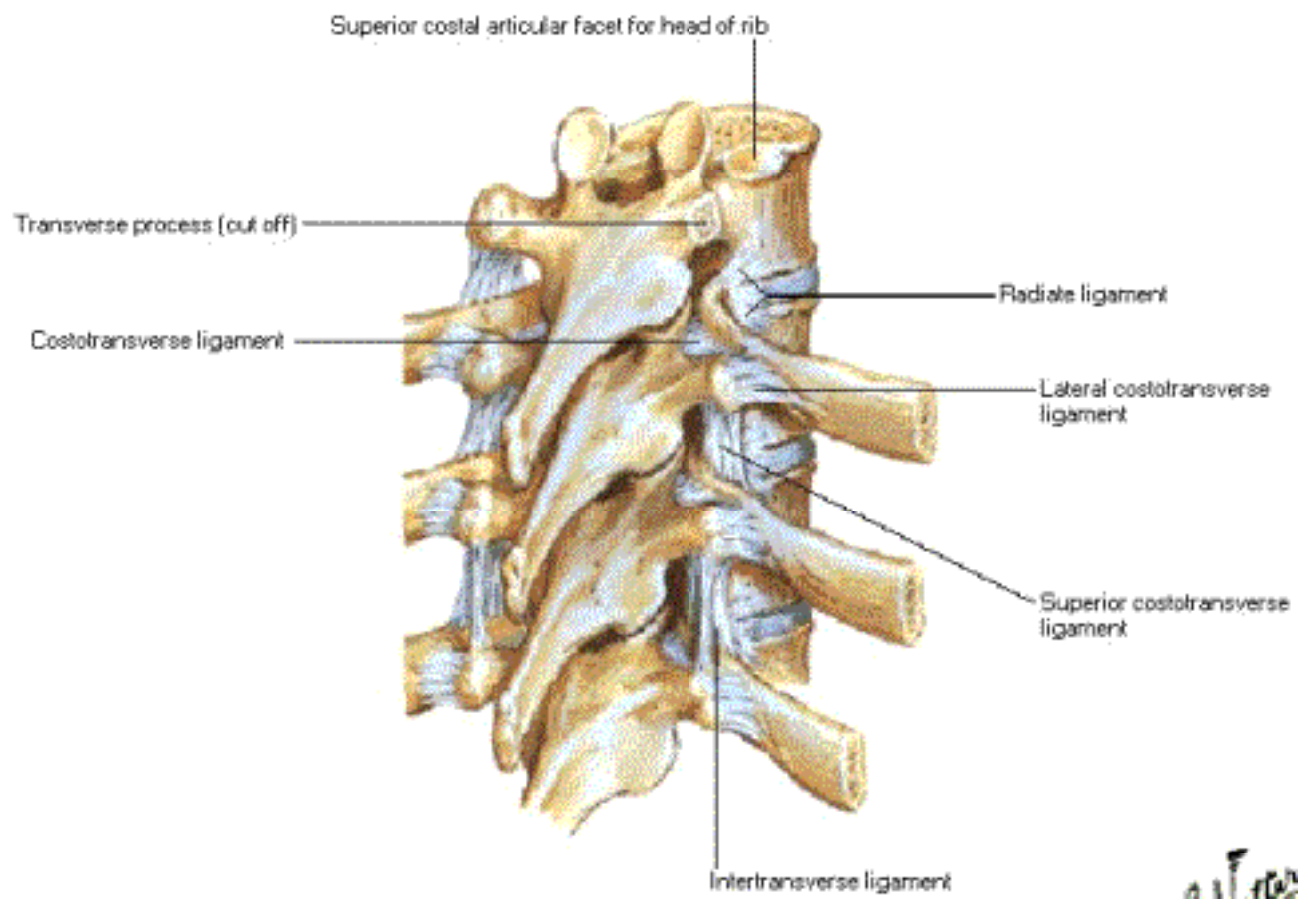
Costovertebral Joints

Transverse Section - Superior View

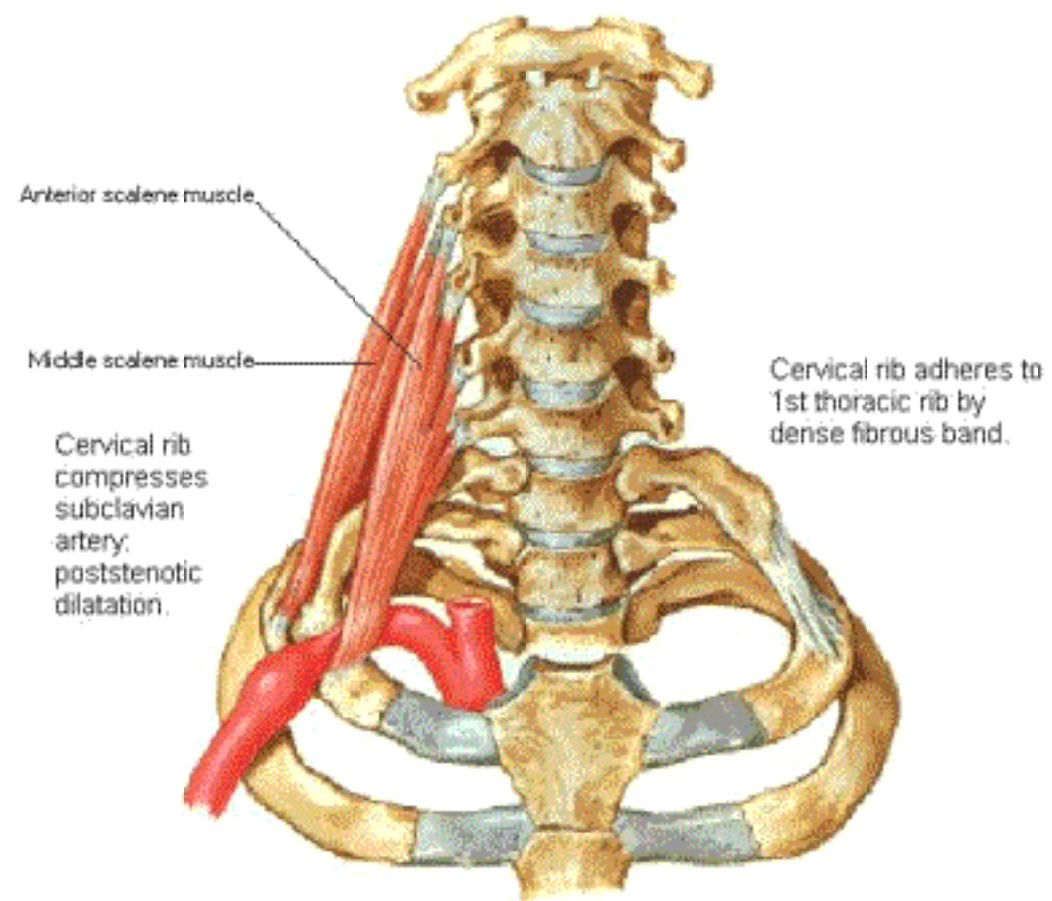


Costovertebral Joints

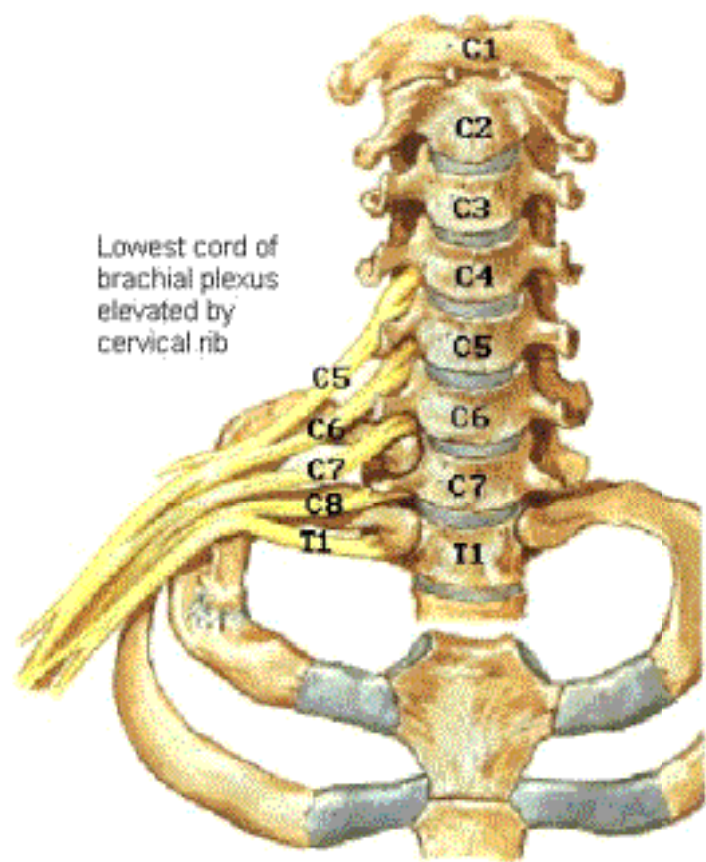
Right Posterolateral View



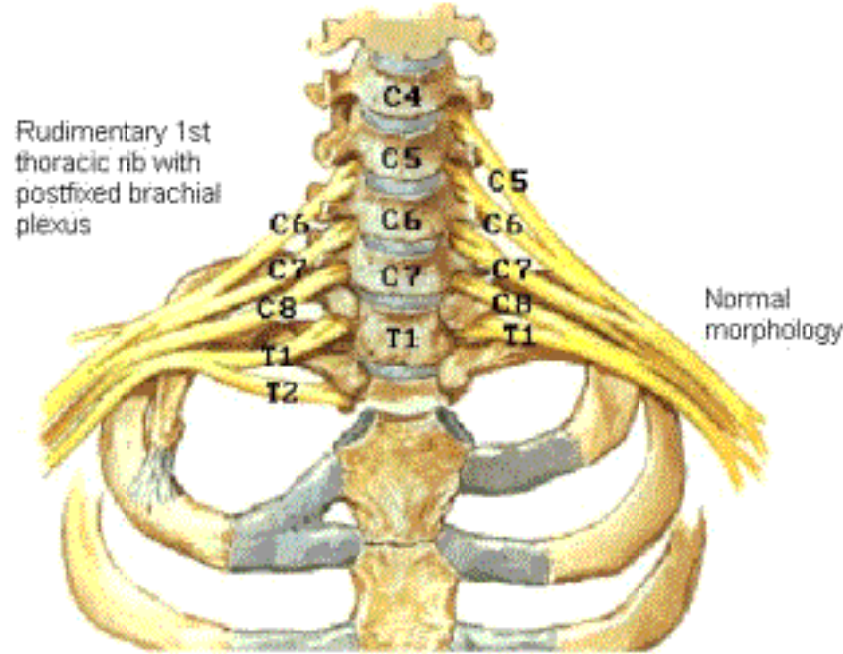
Cervical Ribs and Related Anomalies 1



Cervical Ribs and Related Anomalies 2

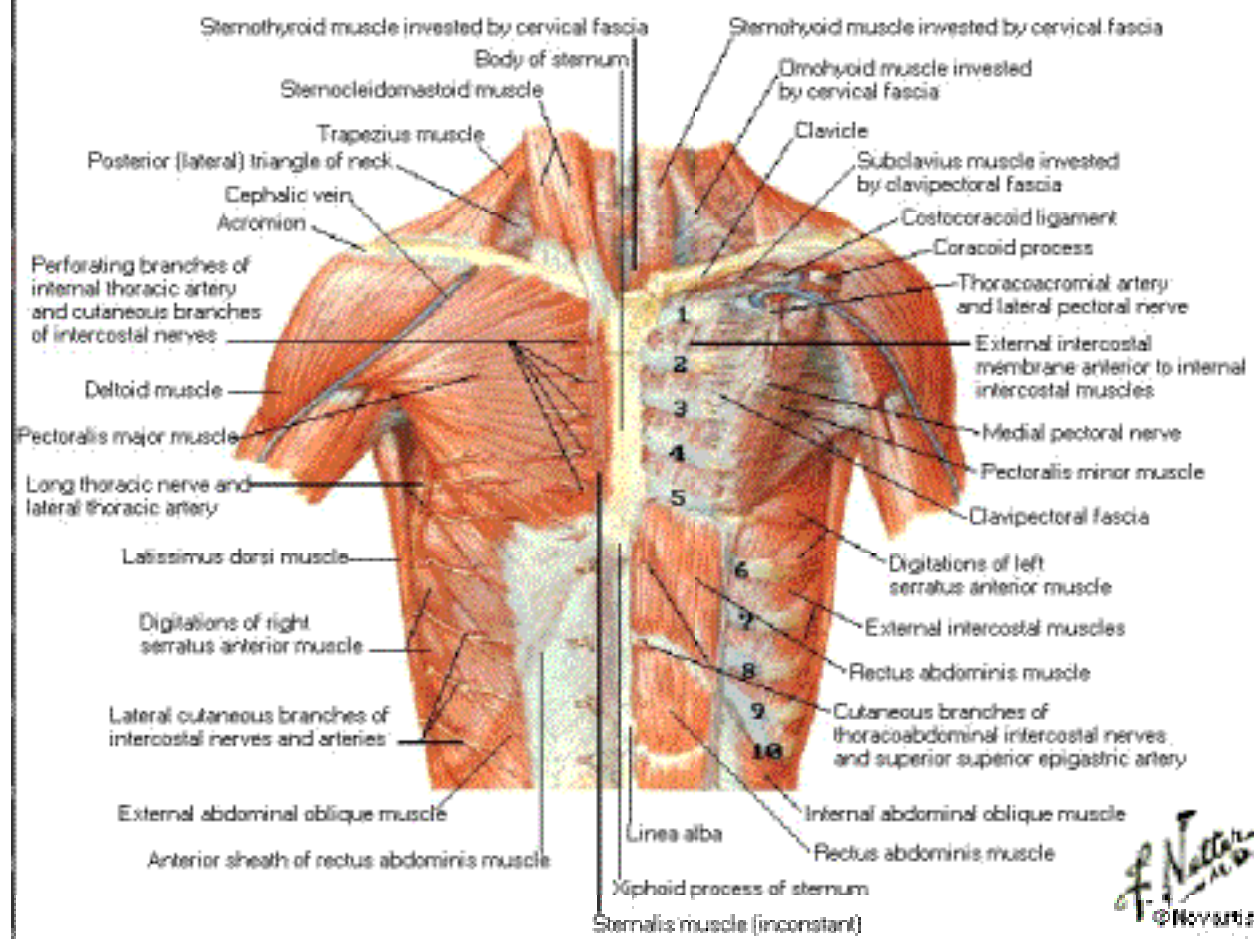


Cervical Ribs and Related Anomalies 3

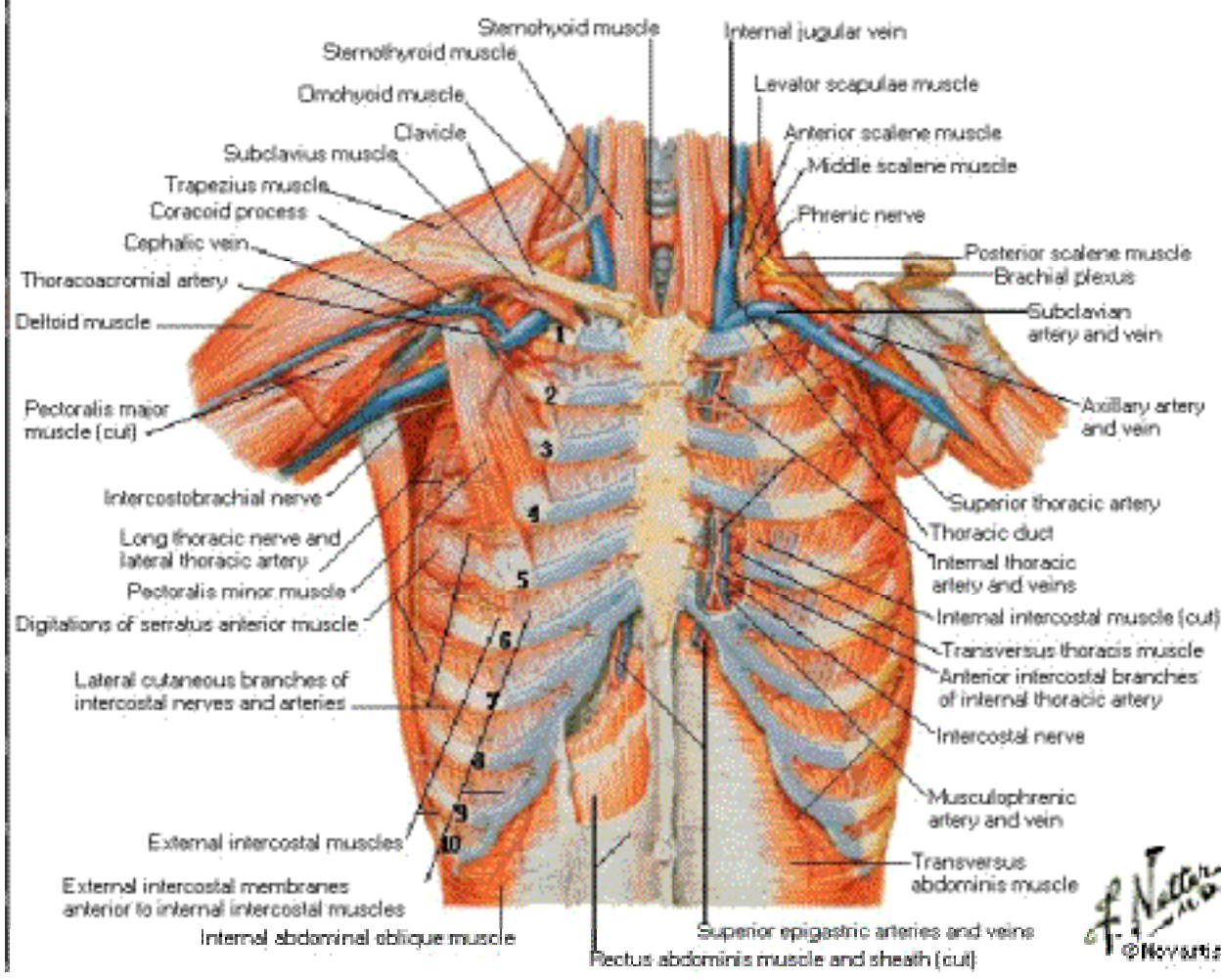


Note: cervical rib also often asymptomatic

Anterior Thoracic Wall

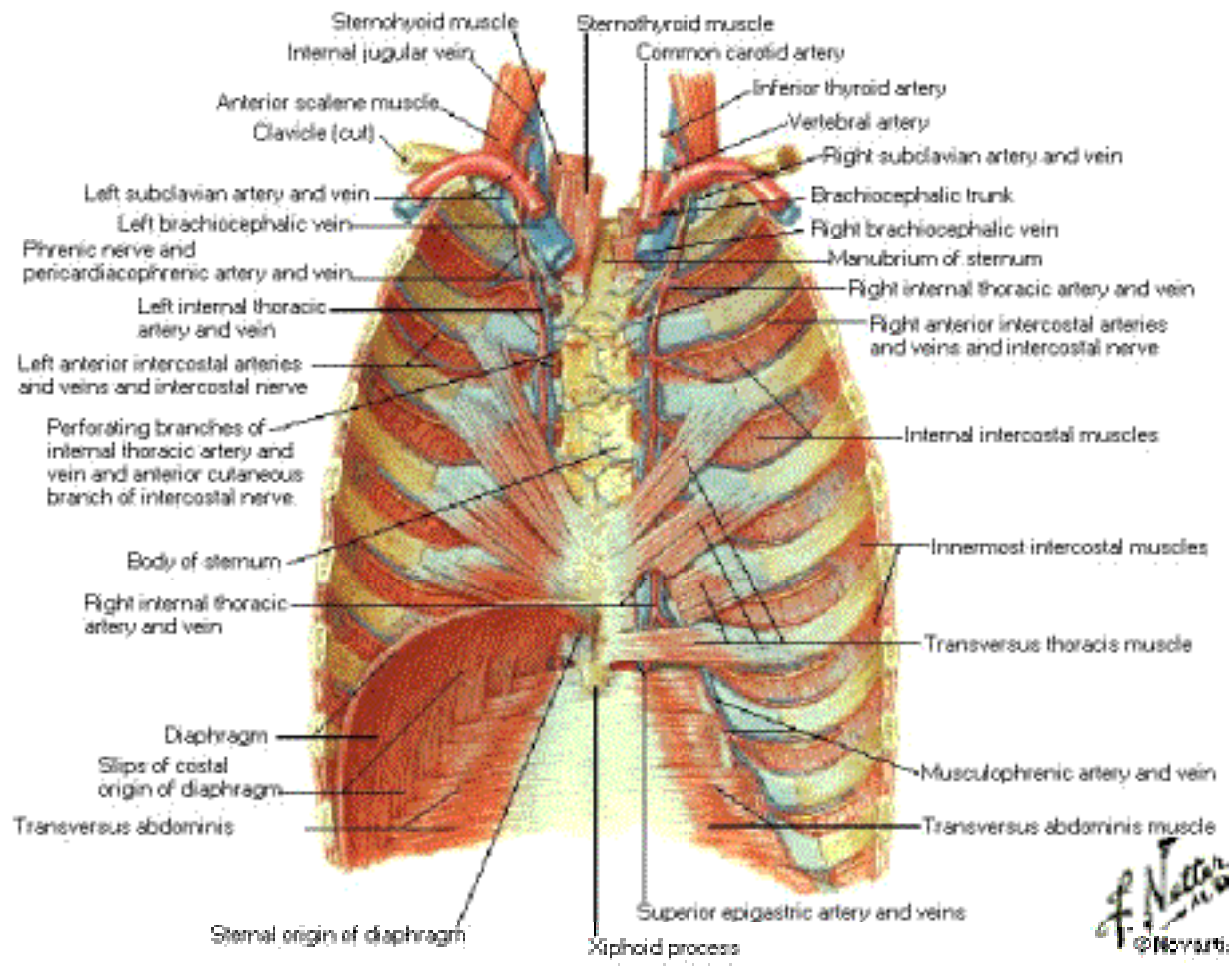


Anterior Thoracic Wall [Continued]

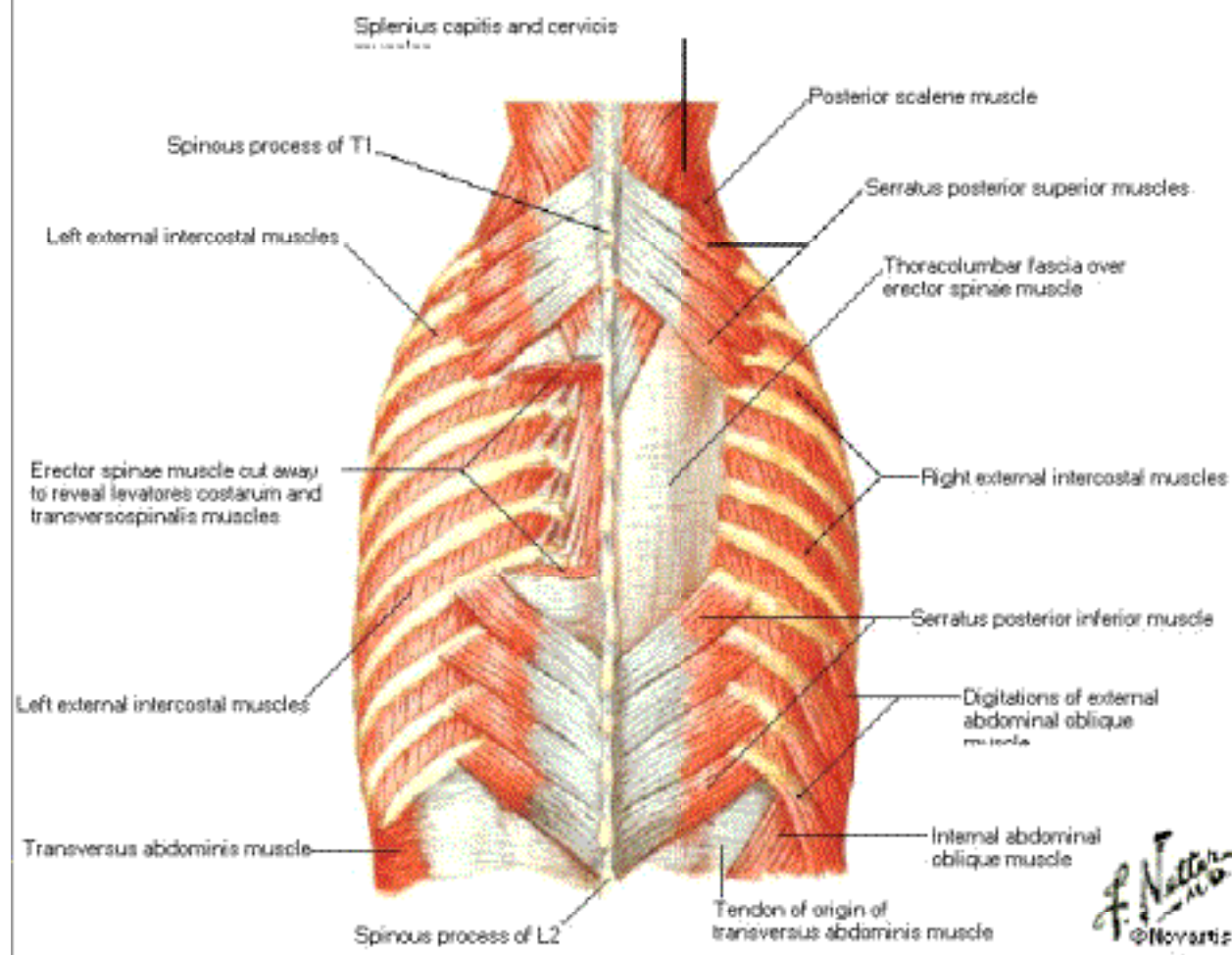


Anterior Thoracic Wall

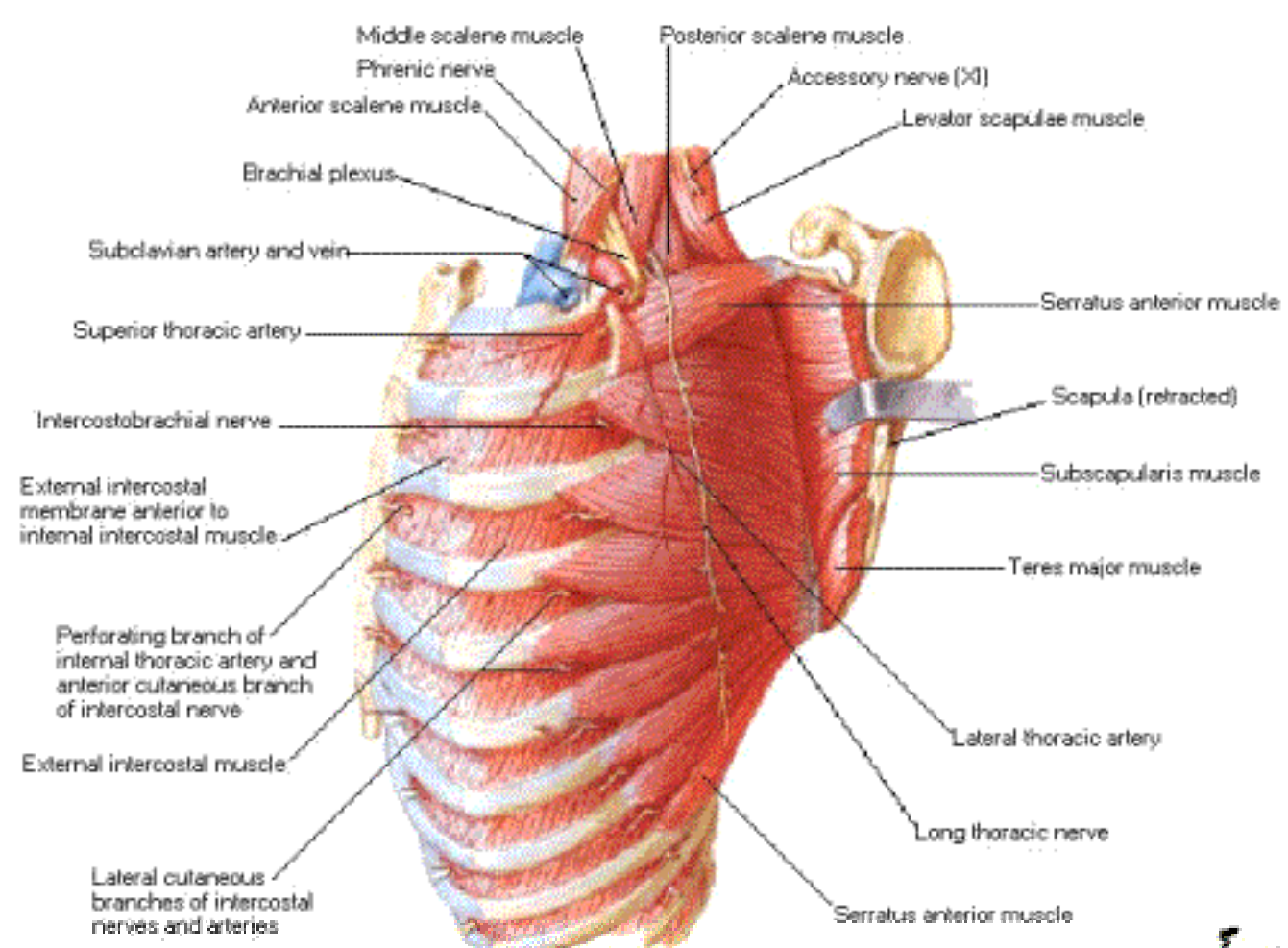
Internal View



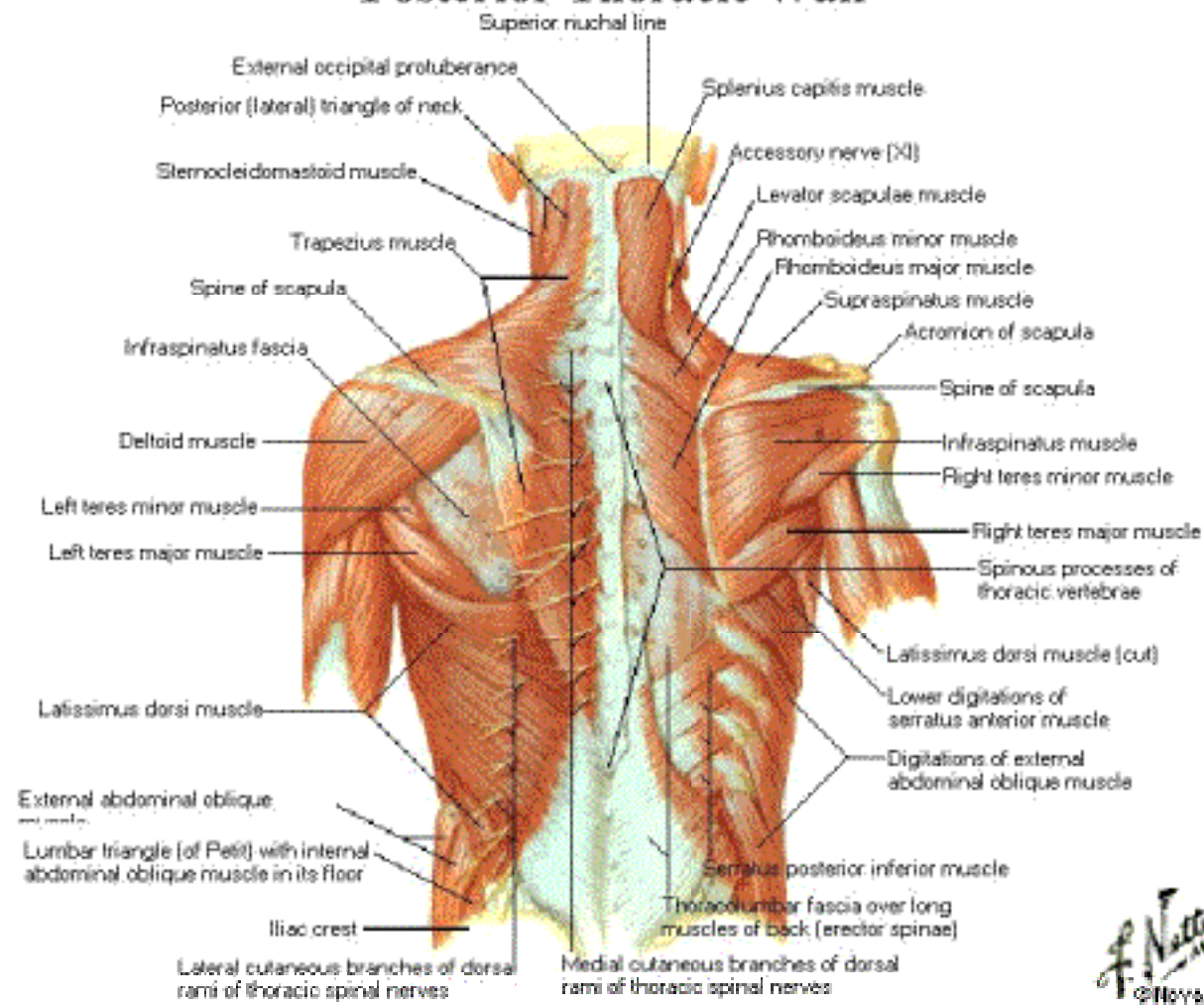
Deep Posterior Thoracic Wall



Lateral Thoracic Wall

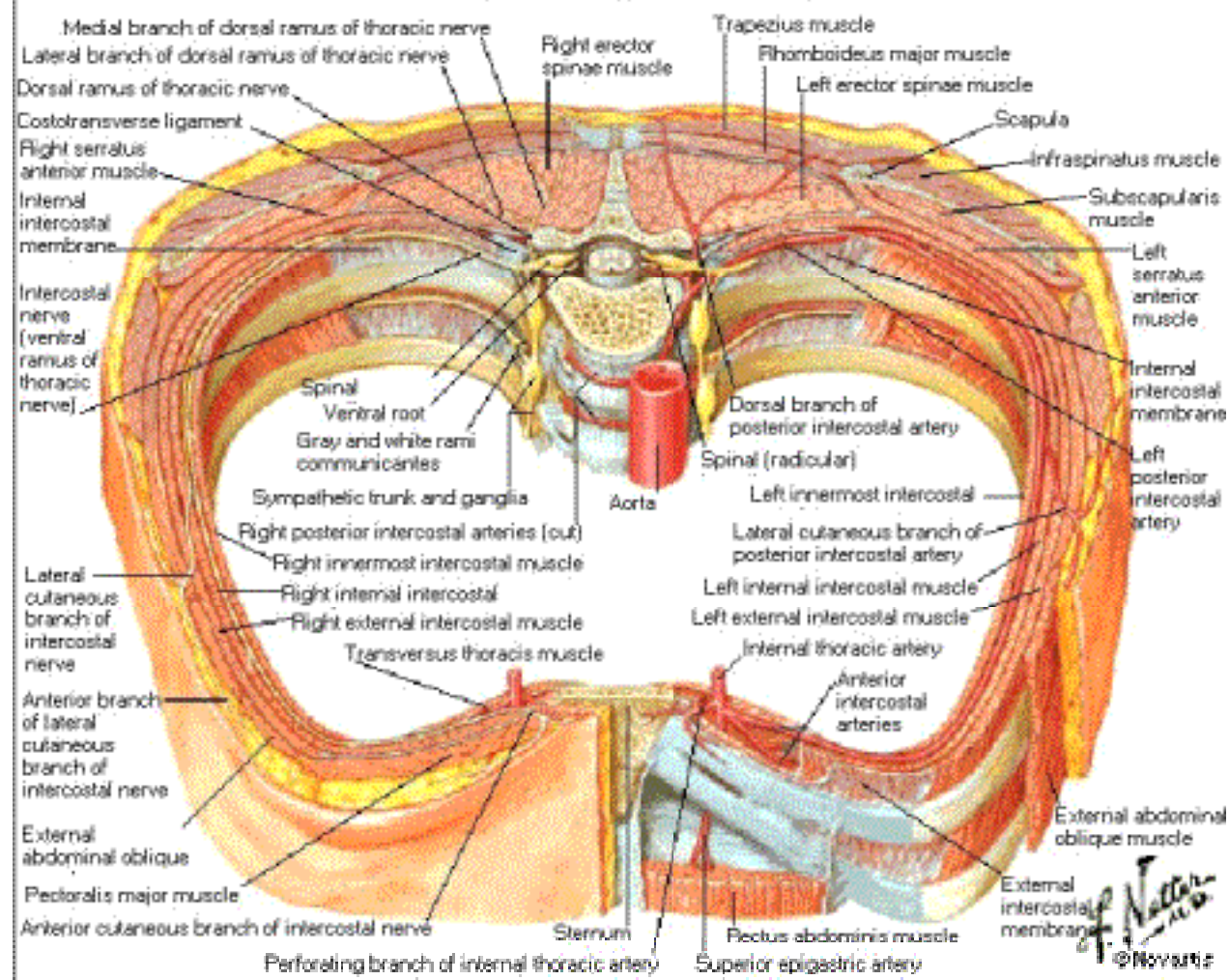


Posterior Thoracic Wall



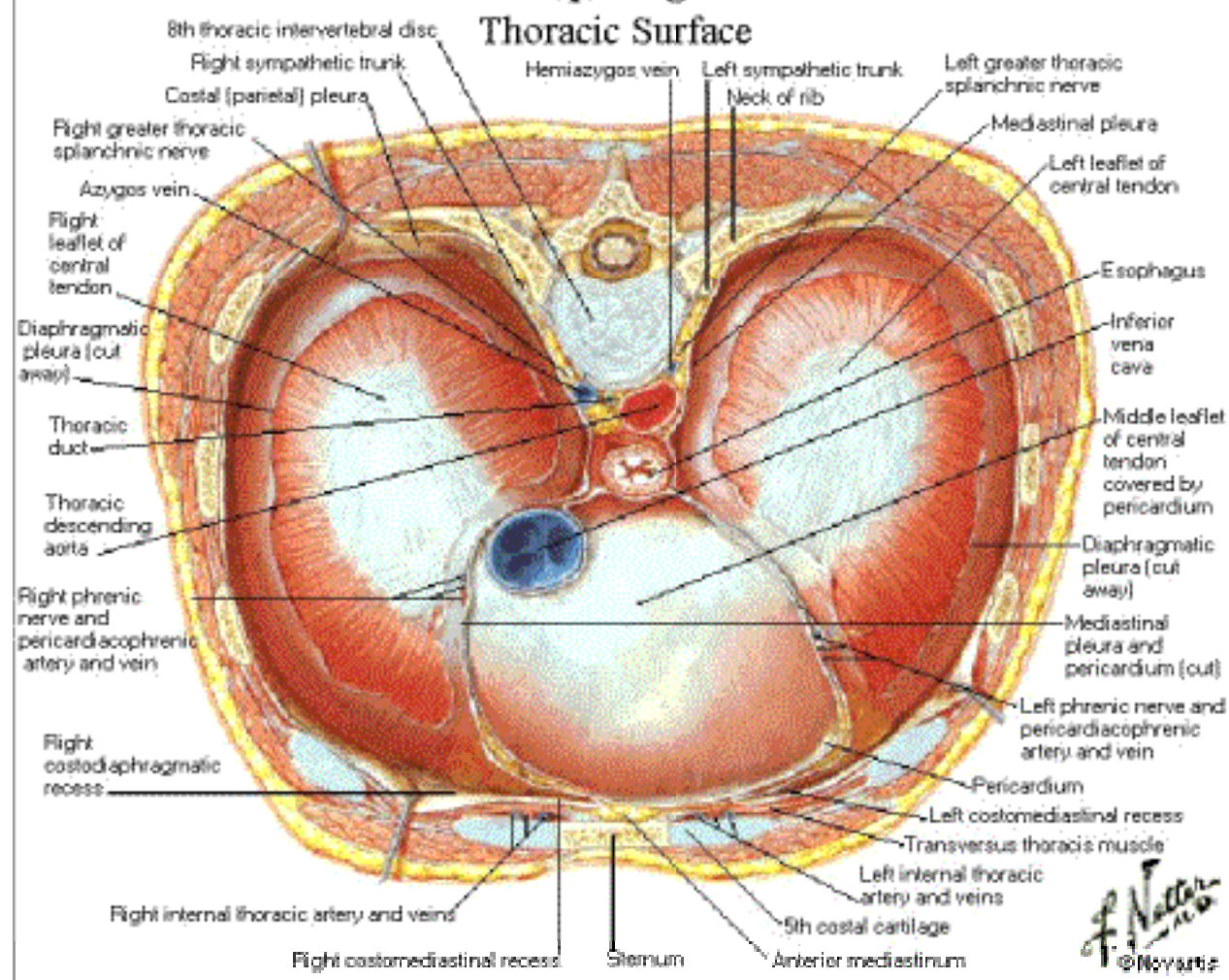
F. Netter M.D. © 1989

Intercostal Nerves and Arteries



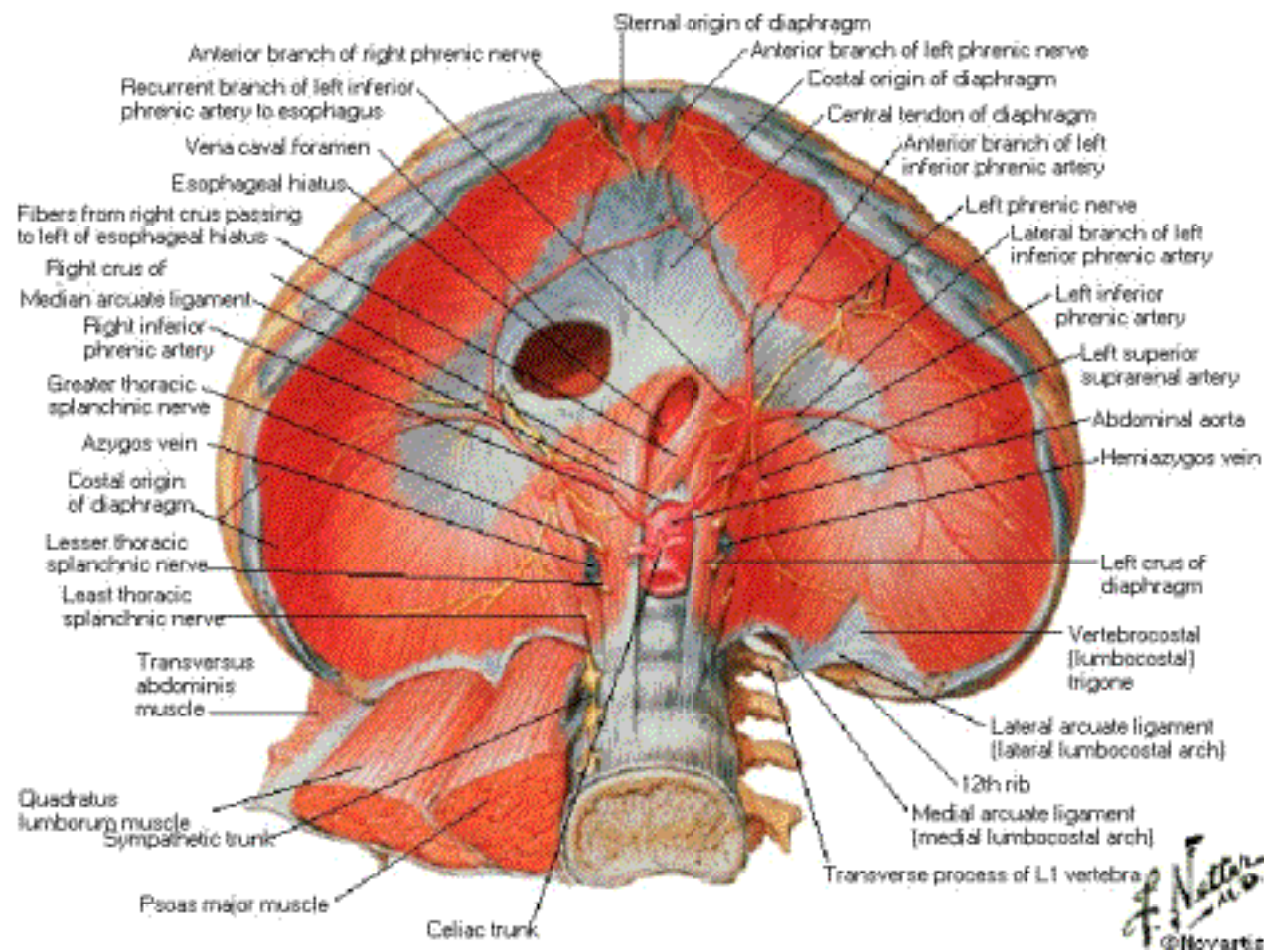
Diaphragm

Thoracic Surface

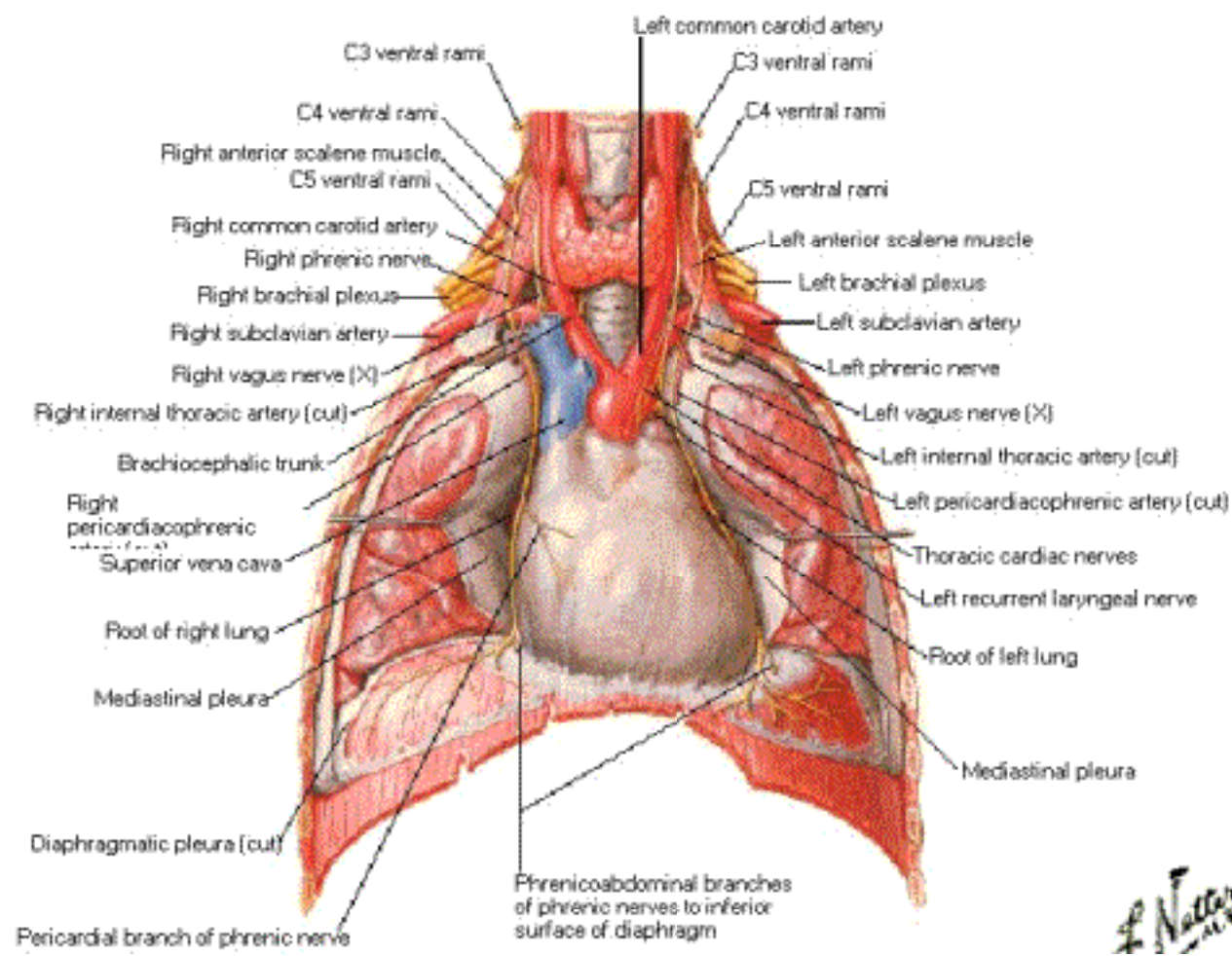


Diaphragm

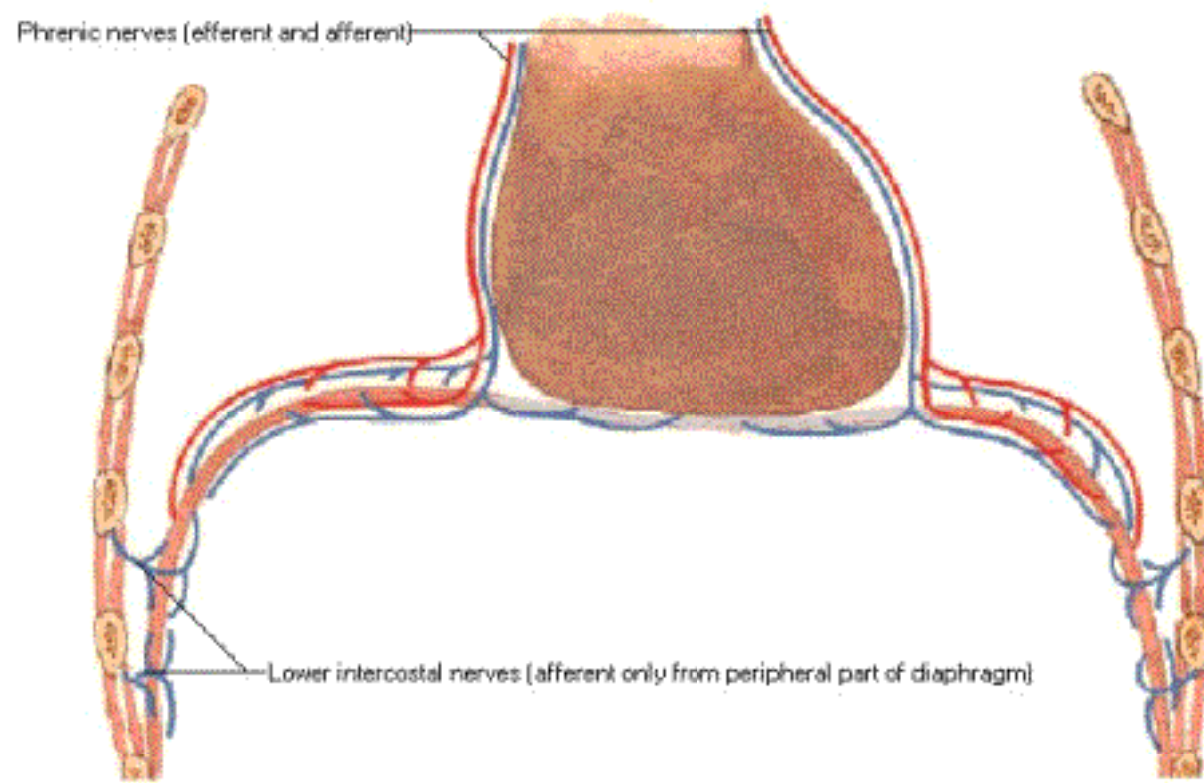
Abdominal Surface



Phrenic Nerve in Situ



Phrenic Nerve Schema



Muscles of Respiration

Muscles of inspiration

Accessory

Sternocleidomastoid

Sternocleidomastoid - This accessory muscle of inspiration elevates the sternum.

Middle scalene

Anterior scalene

Posterior scalene

Scalenes - These accessory muscles of inspiration elevate and fix the upper ribs.

Principal

External intercostals

External intercostals - These principal muscles of inspiration elevate the ribs, thus increasing the width of the thoracic cavity.

Intercostal part of internal intercostals

Intercostal part - This part acts as a principal muscle of inspiration by elevating the ribs.

Diaphragm

Diaphragm - The domes of this principal muscle of inspiration descend, thus increasing the longitudinal dimension of the thoracic cavity. The diaphragm also helps in elevating the lower ribs.

Muscles of expiration

Quiet breathing

Expiration results from passive recoil of lungs

Active breathing

Internal intercostals, except intercostal part

Internal intercostals - These muscles of active expiration lower the ribs, thus decreasing the width of the thoracic cavity.

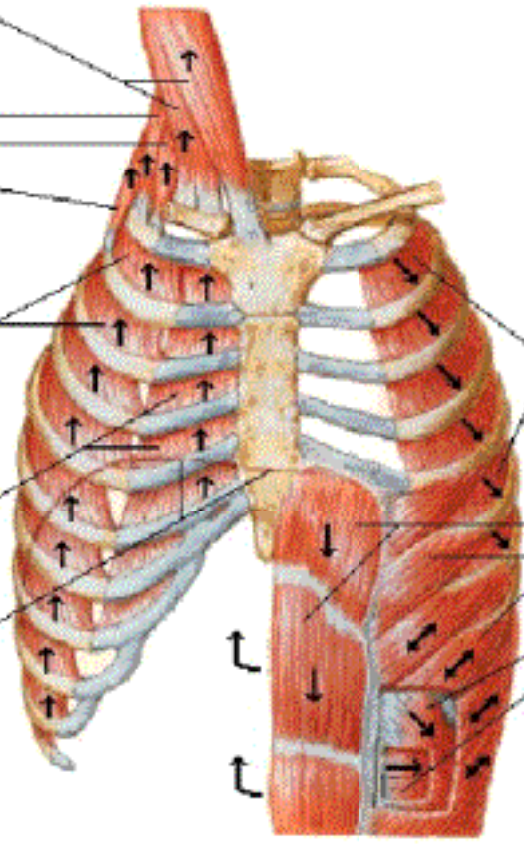
Rectus abdominis

External oblique

Internal oblique

Transversus abdominis

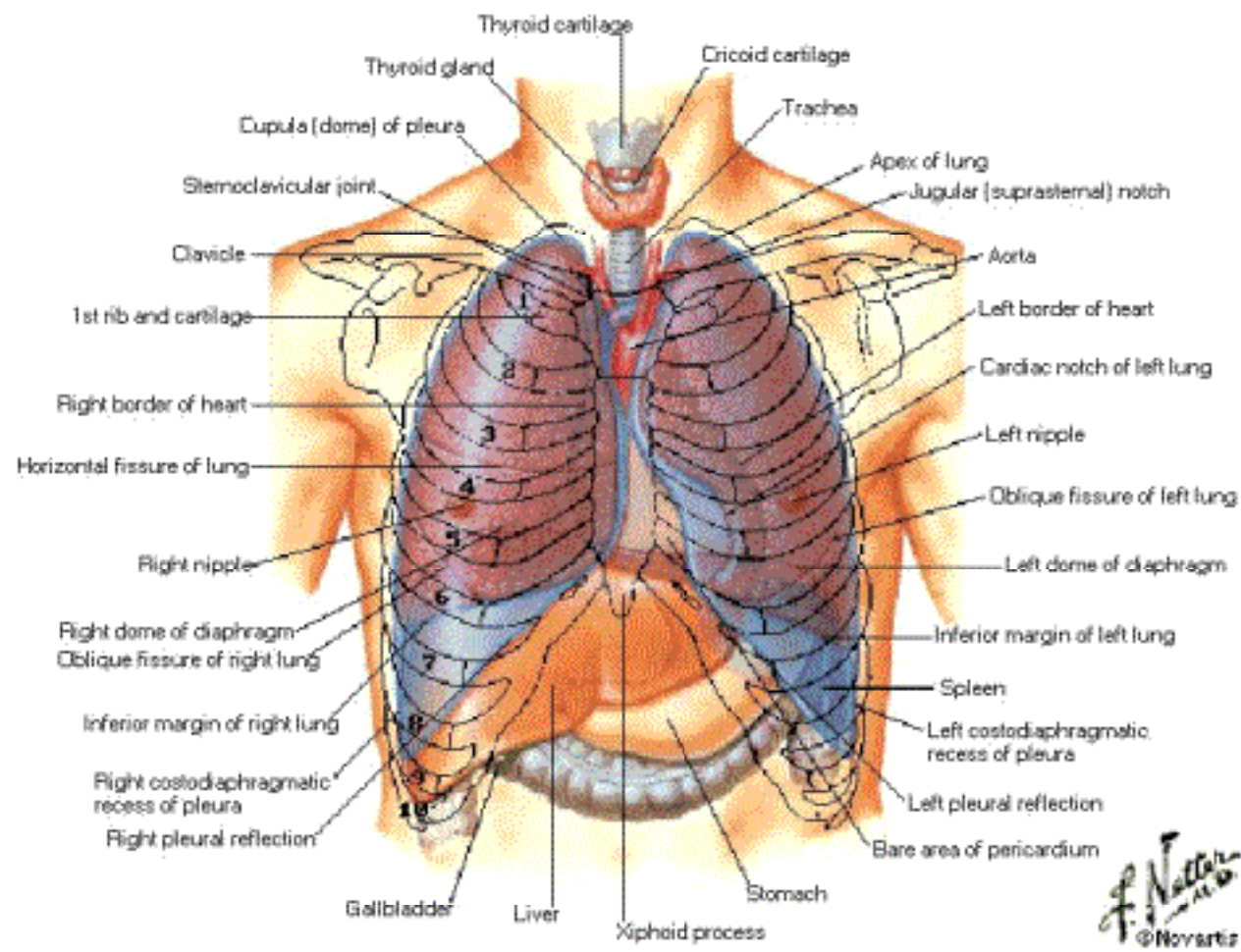
Abdominal muscles - This muscle of active expiration depress the lower ribs and compress abdominal contents, thus pushing up the diaphragm.



F. Netter
© Novartis

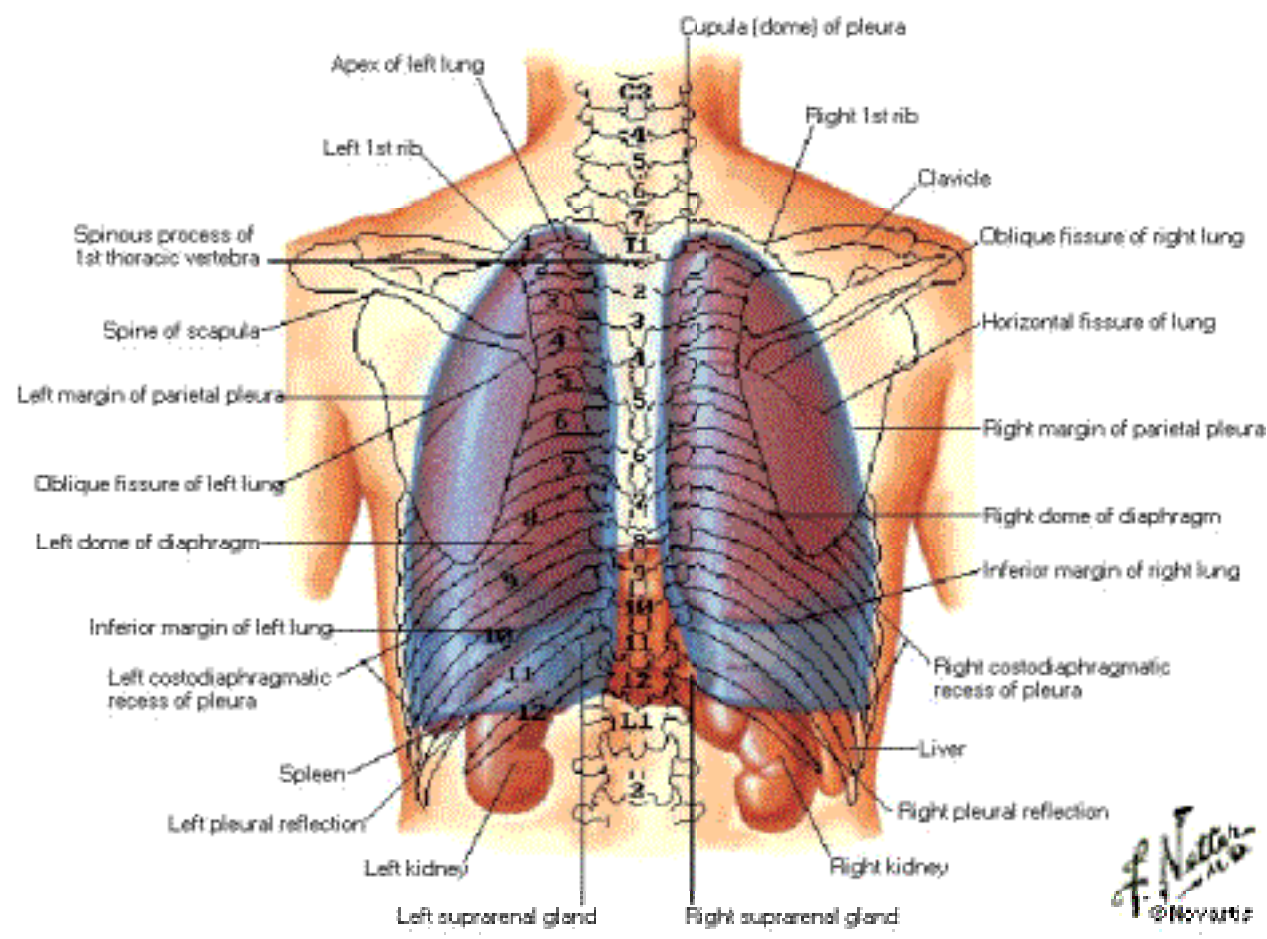
Topography of Lungs

Anterior View



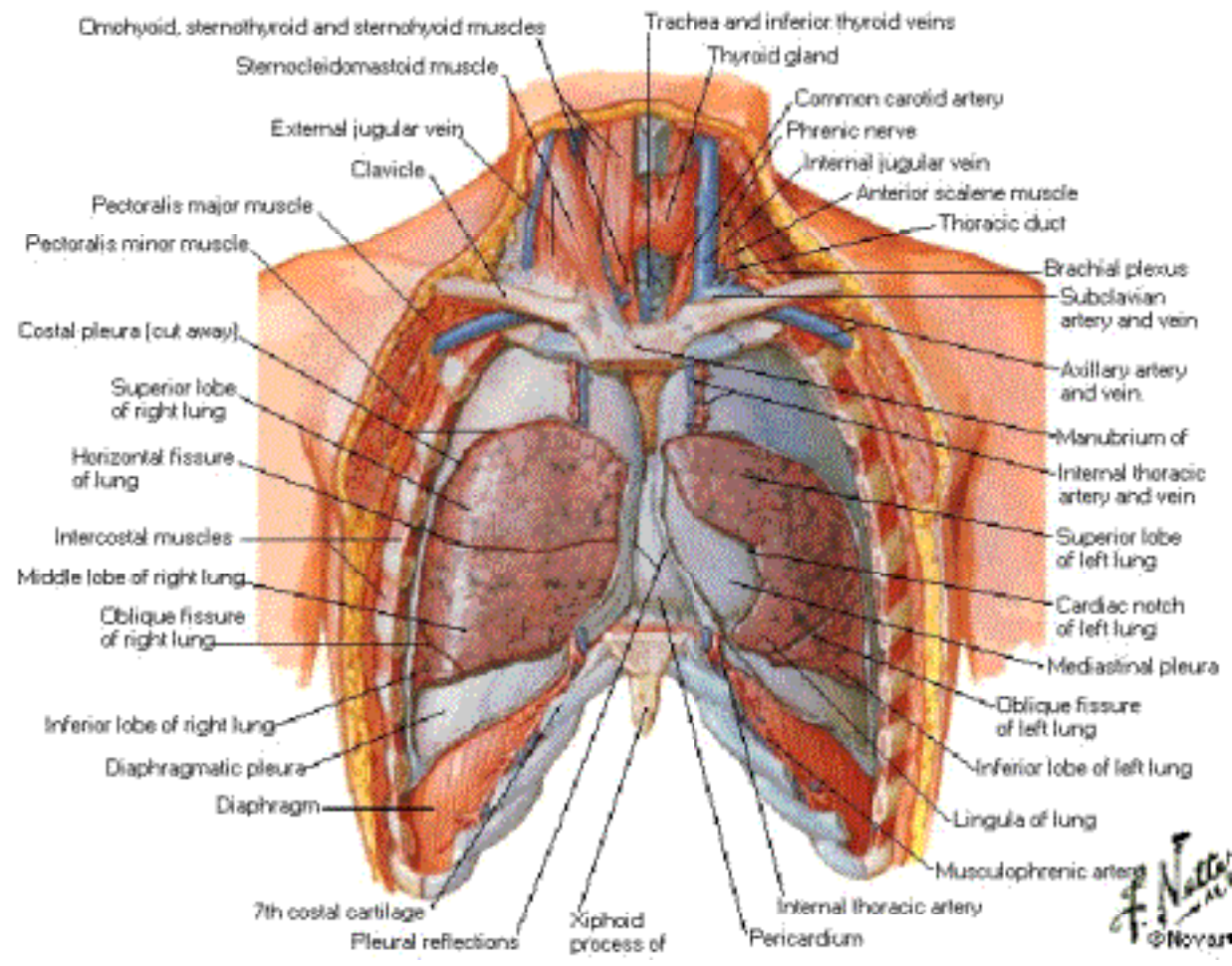
Topography of Lungs

Posterior View

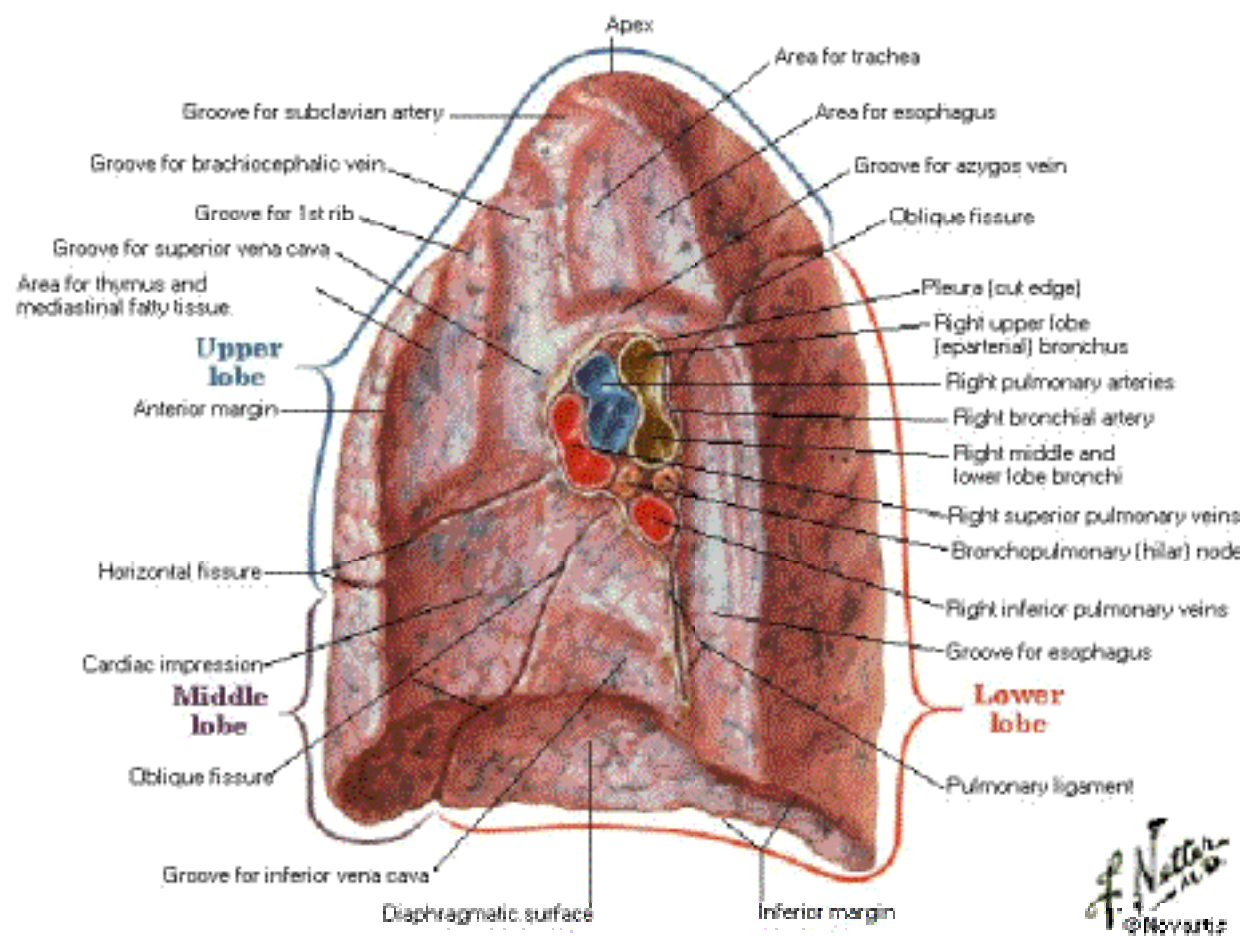


Lungs in Situ

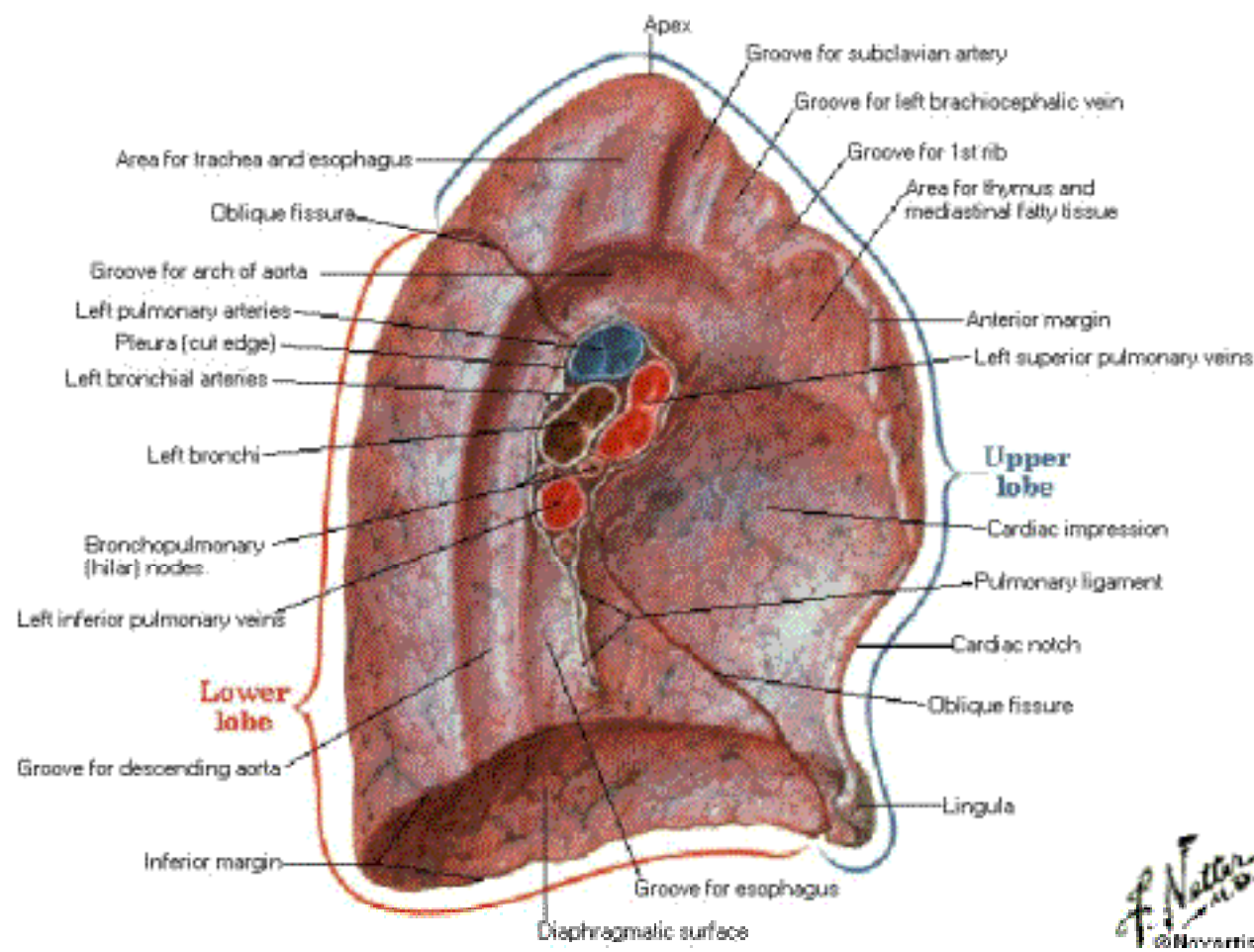
Anterior View



Right Lung Medial View



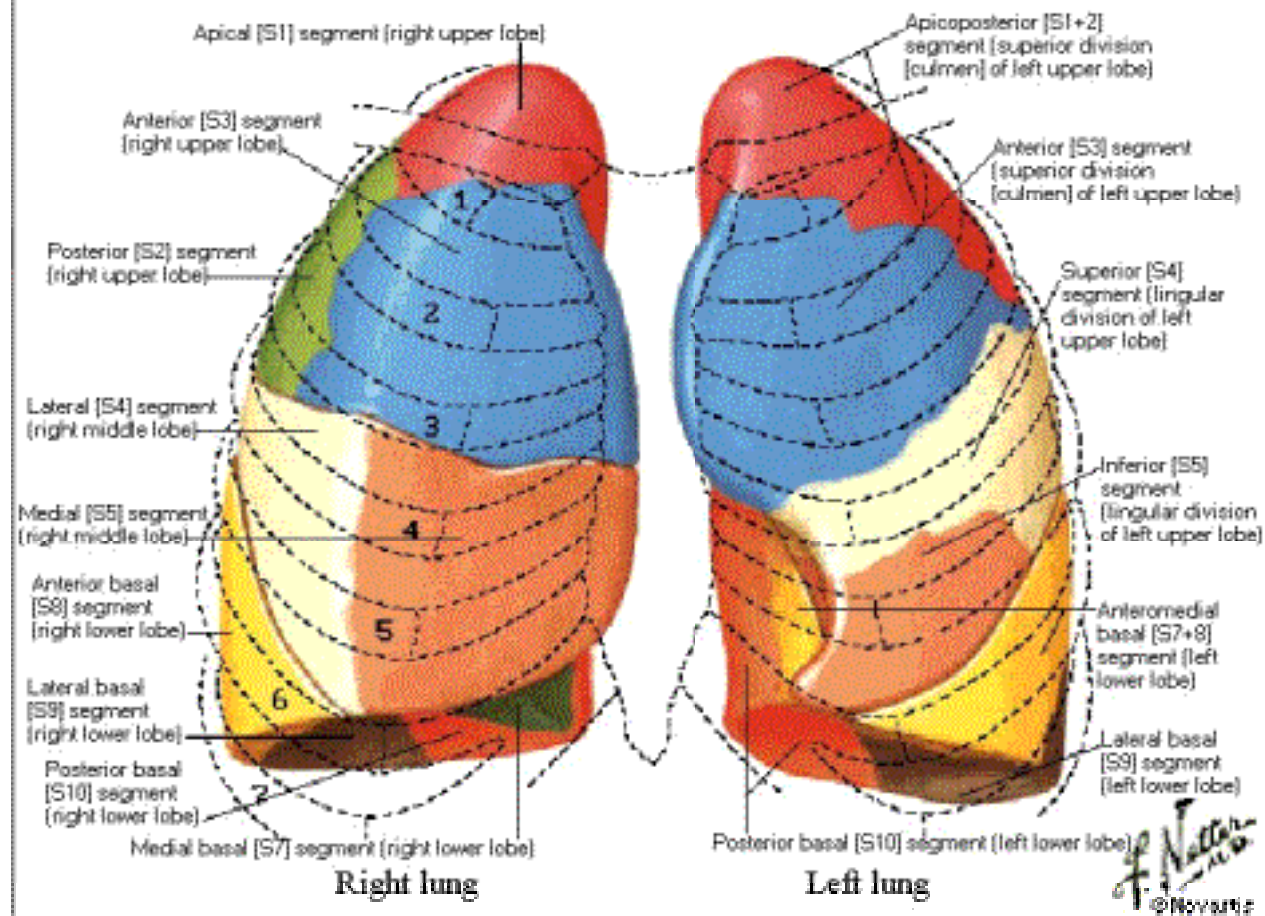
Left Lung Medial View



F. Netter M.D.
© 2004

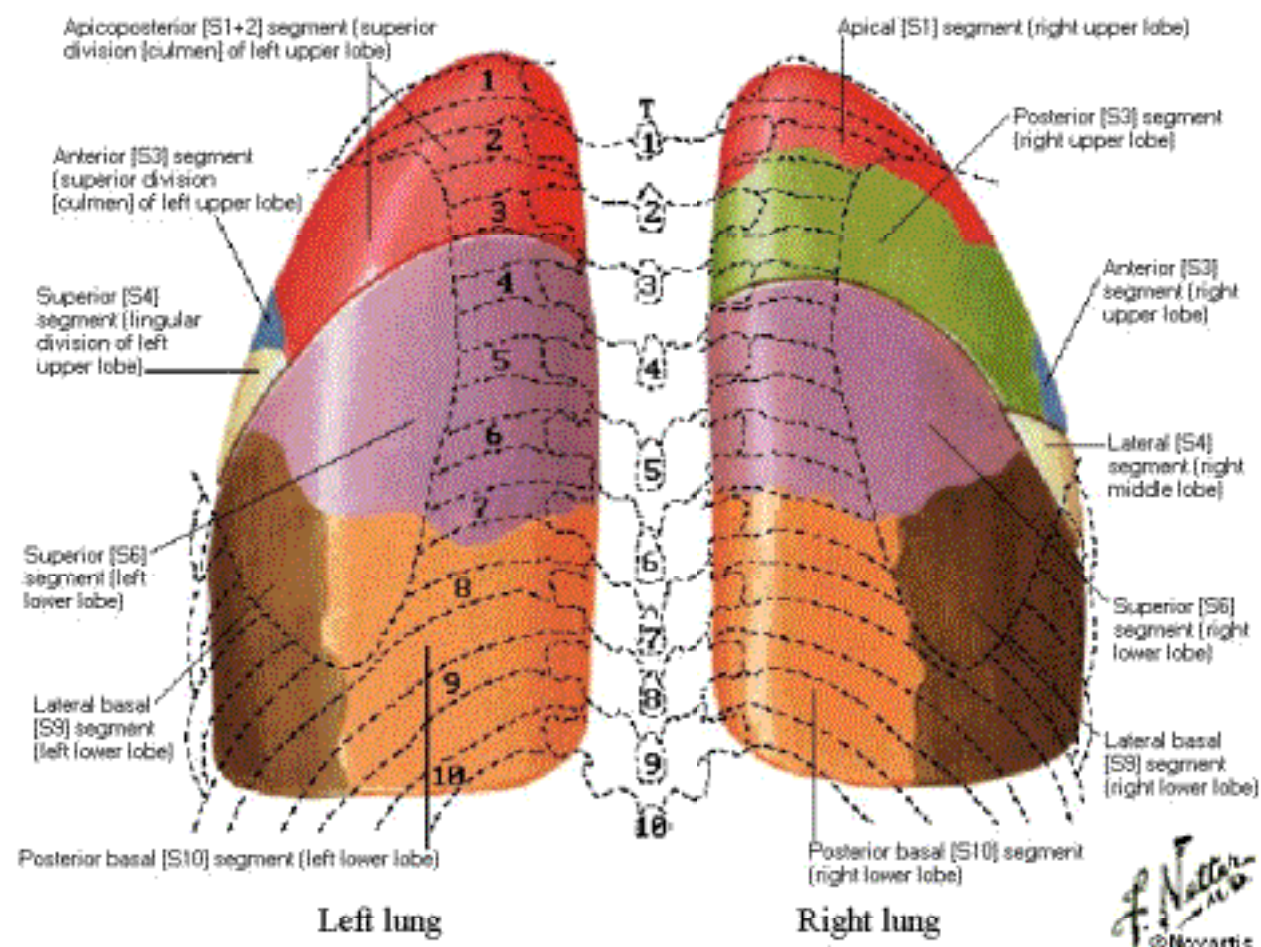
Bronchopulmonary Segments

Anterior View



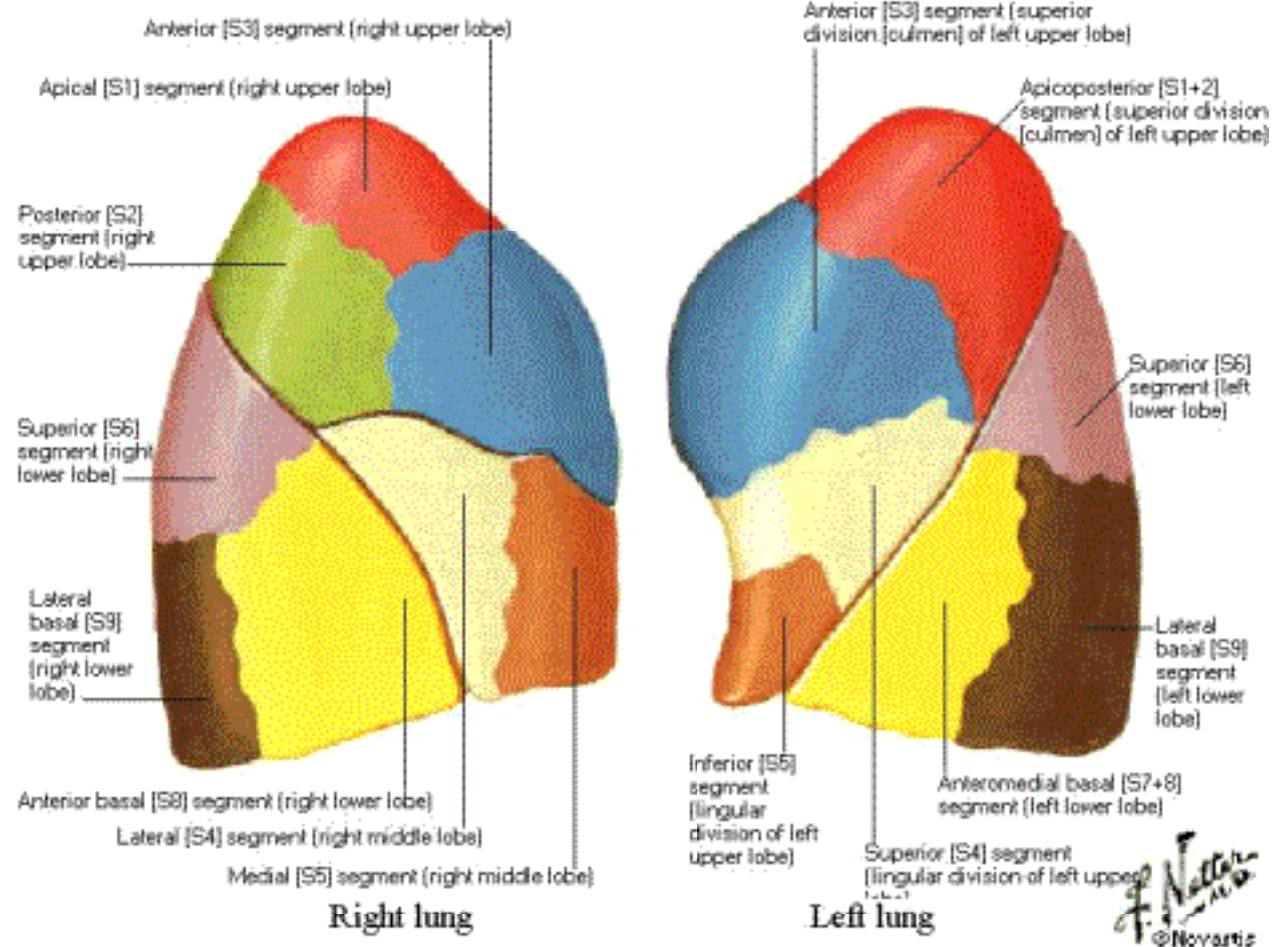
Bronchopulmonary Segments

Posterior View



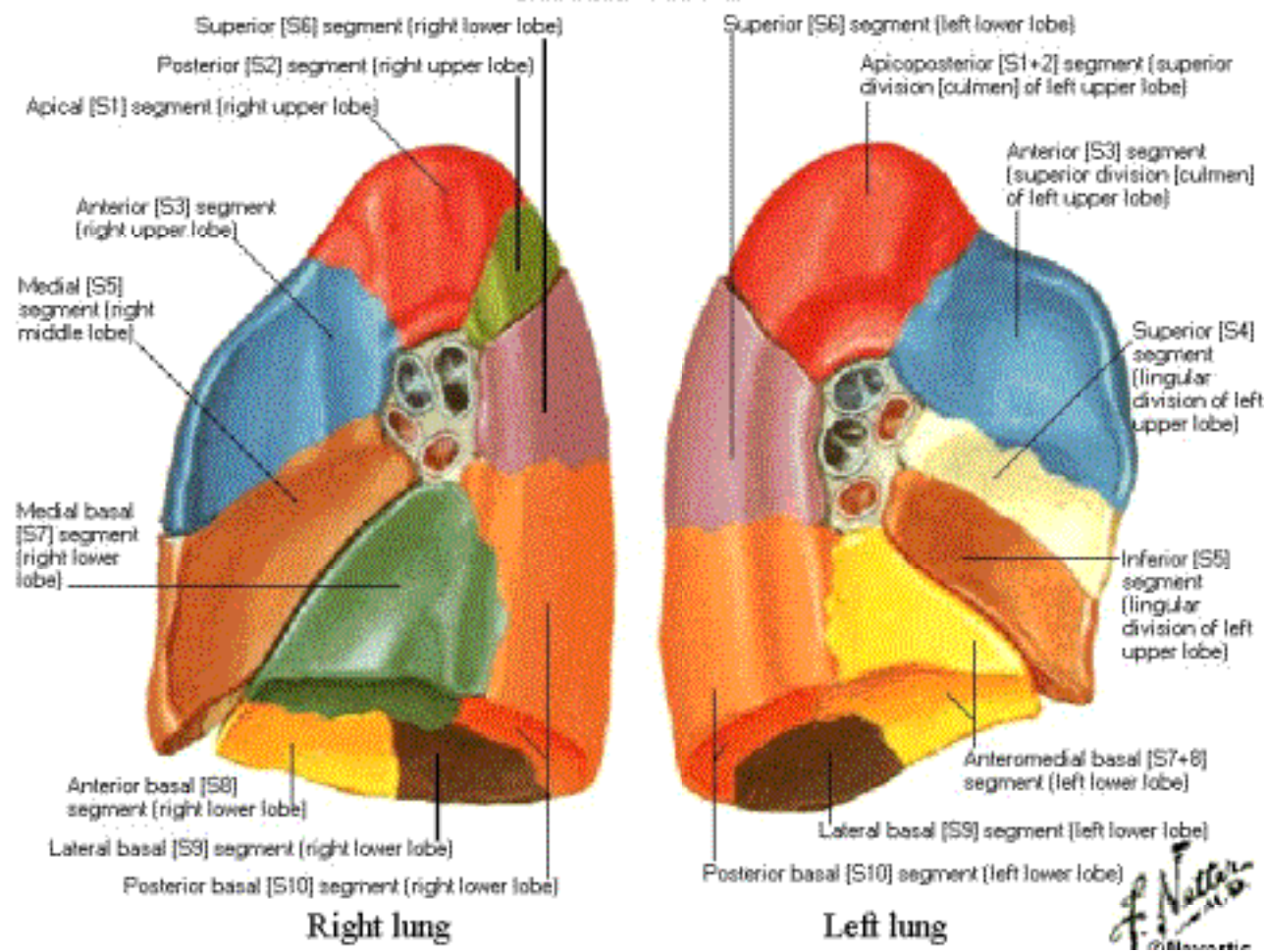
Bronchopulmonary Segments

Lateral Views



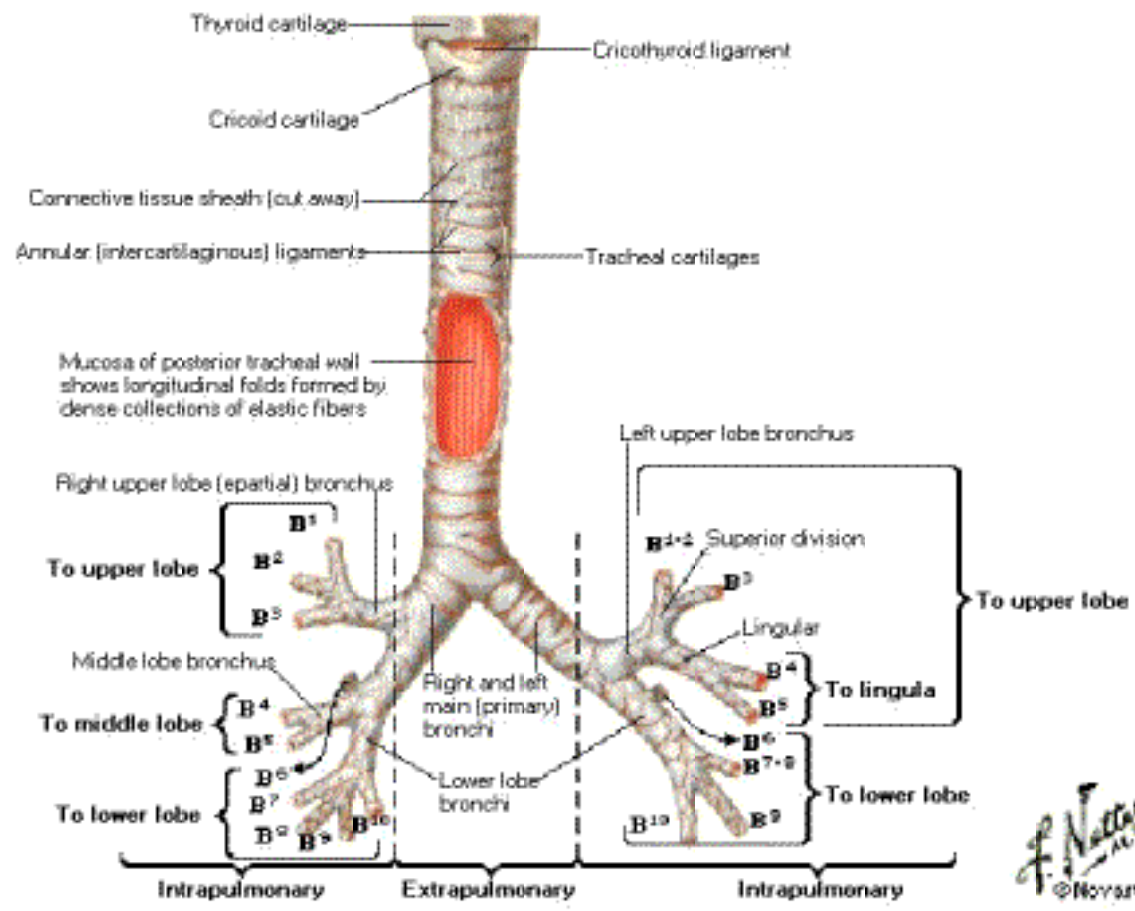
Bronchopulmonary Segments

Medial Views



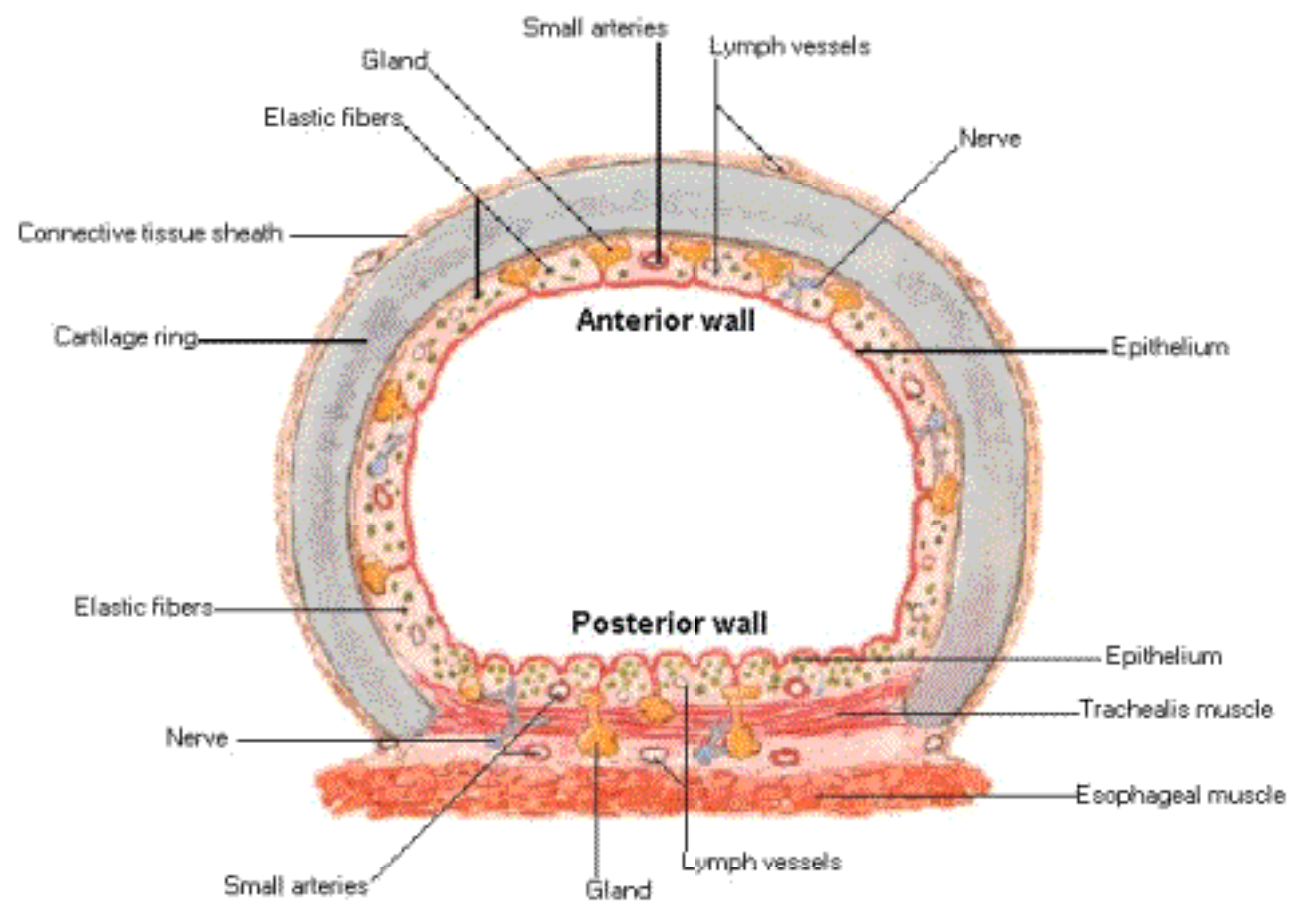
Trachea and Major Bronchi

Anterior View



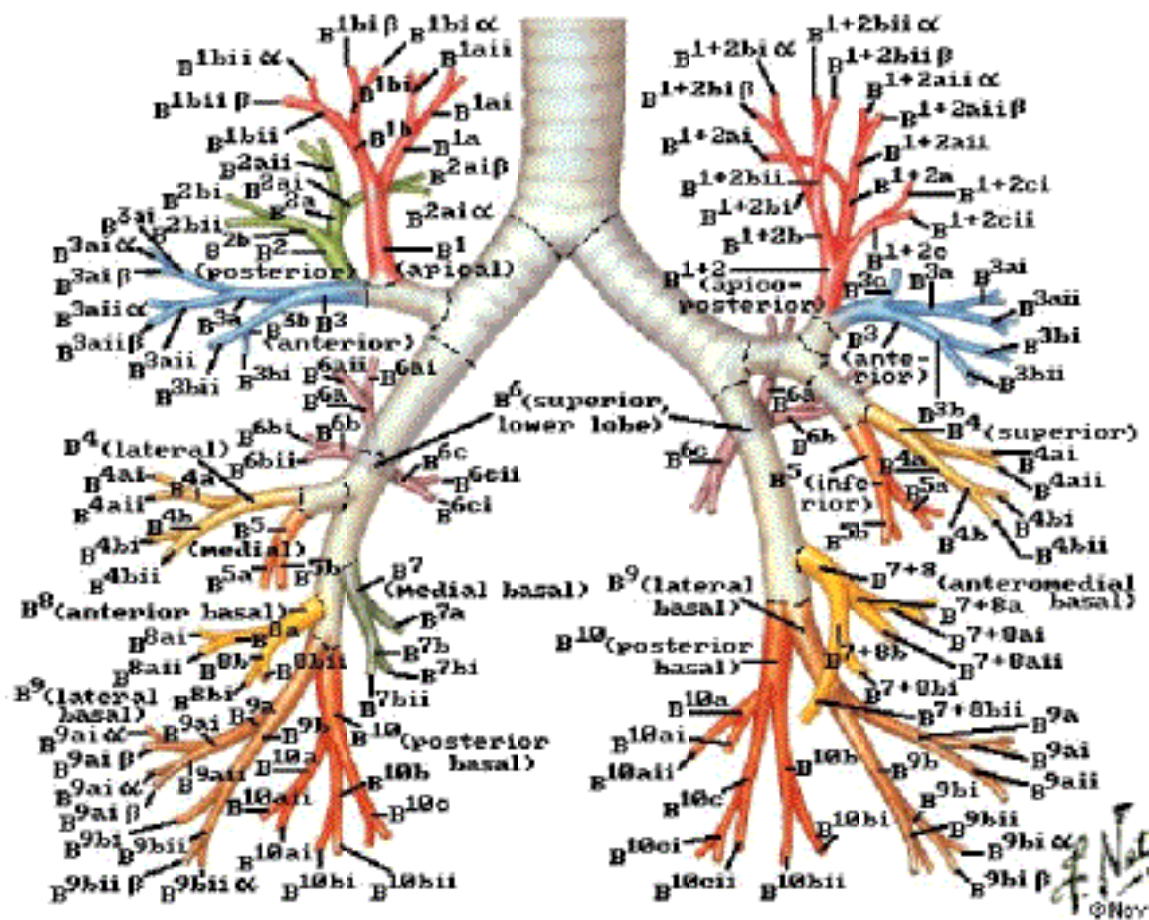
Trachea

Cross Section



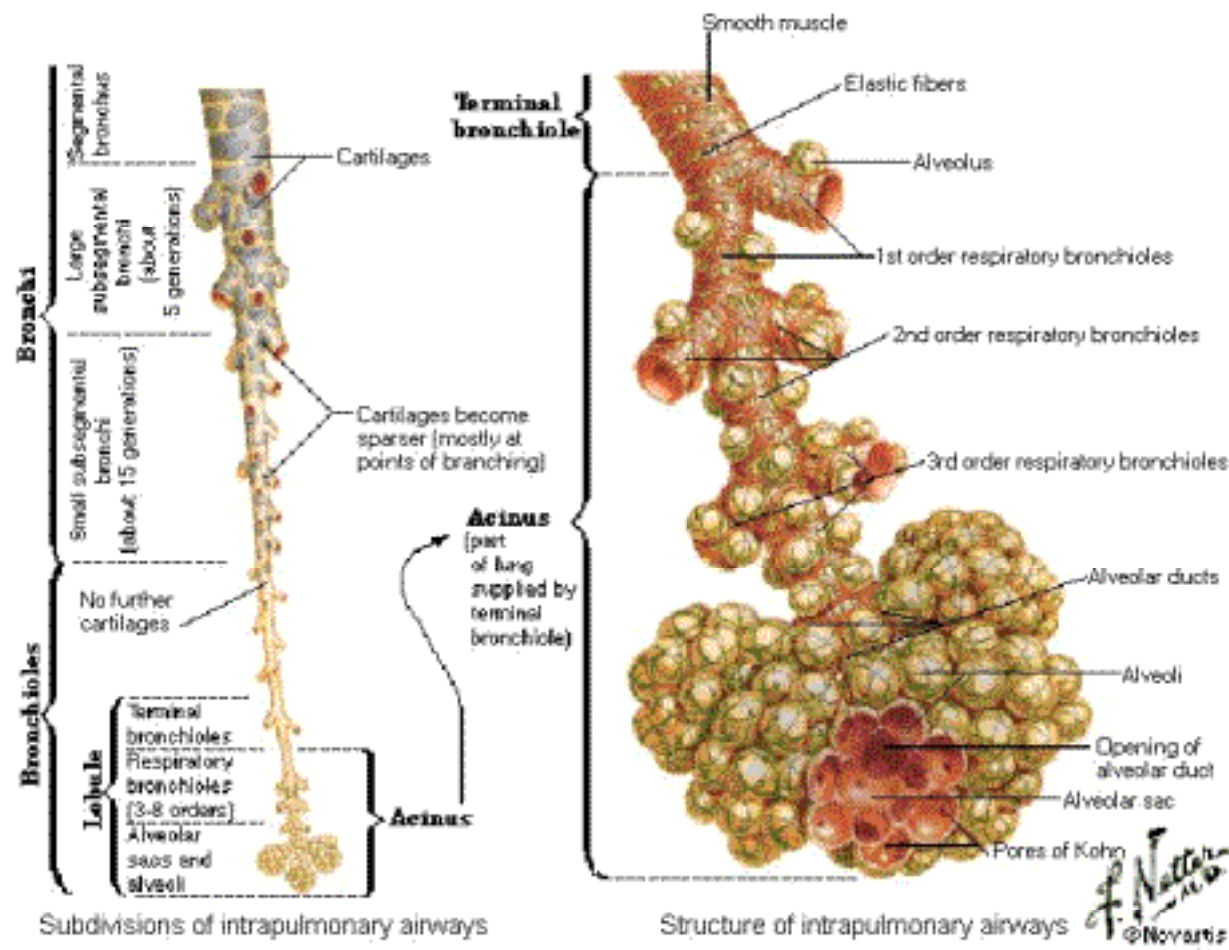
Nomenclature of Bronchi

Schema

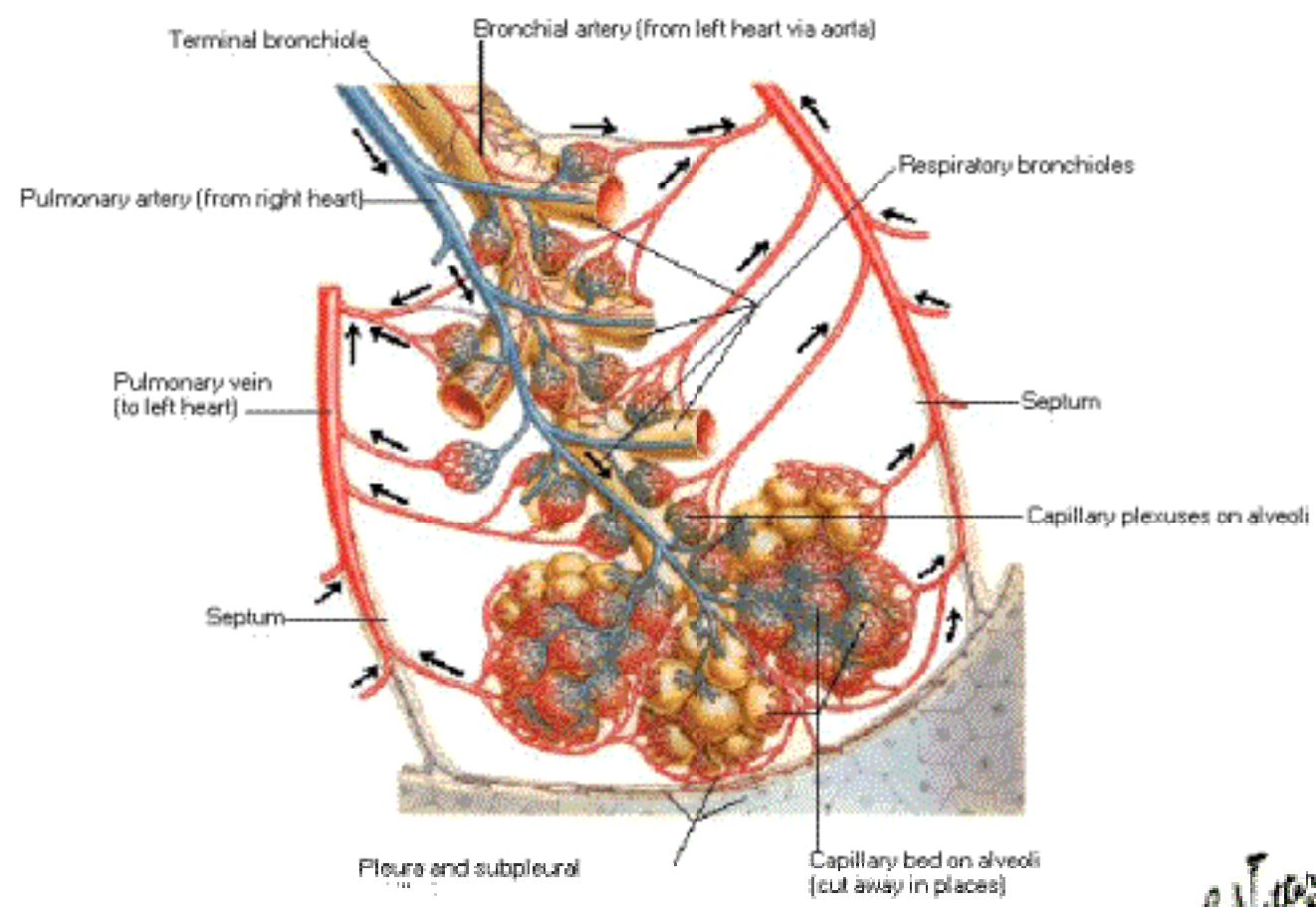


Intrapulmonary Airways

Schema

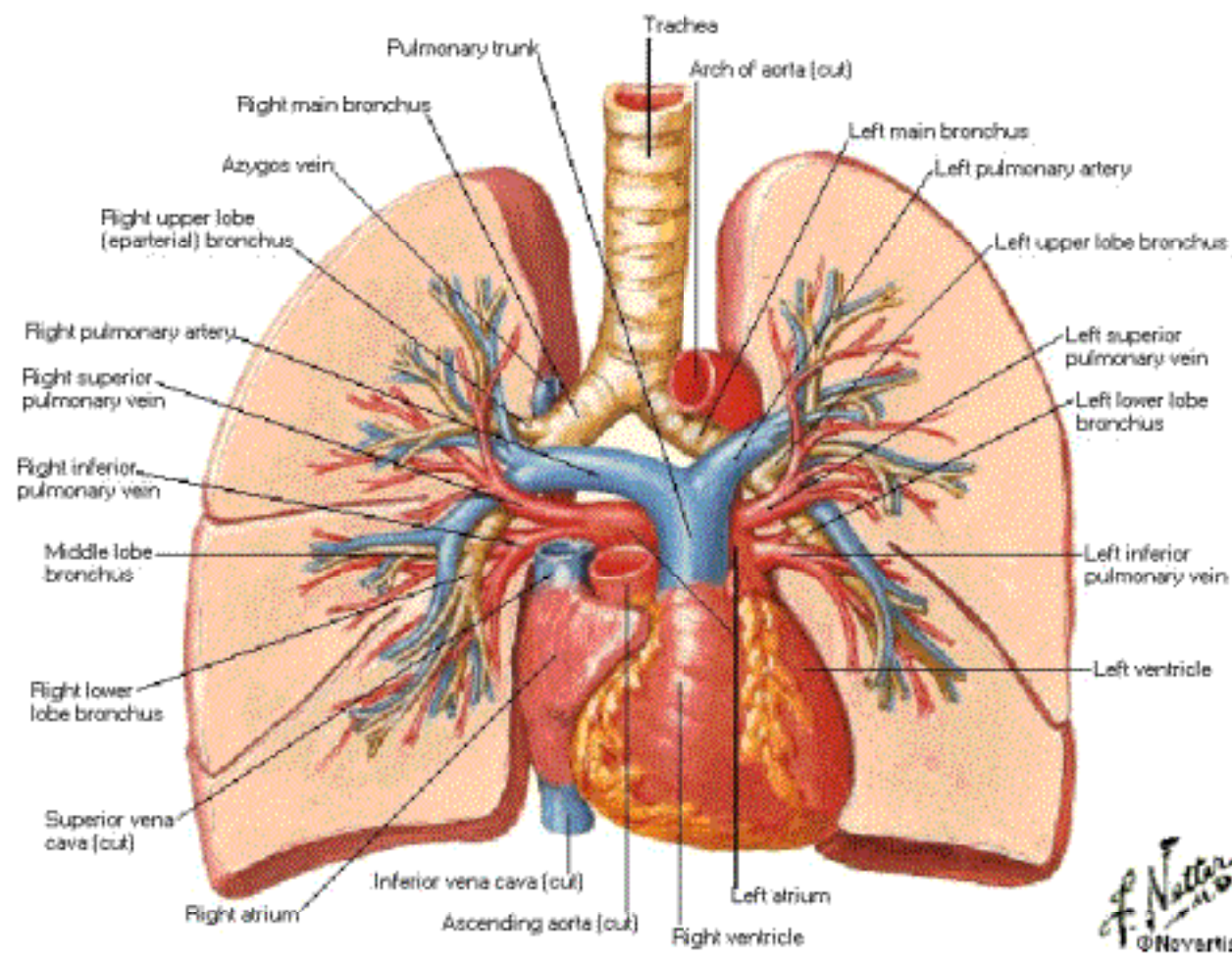


Intrapulmonary Blood Circulation Schema

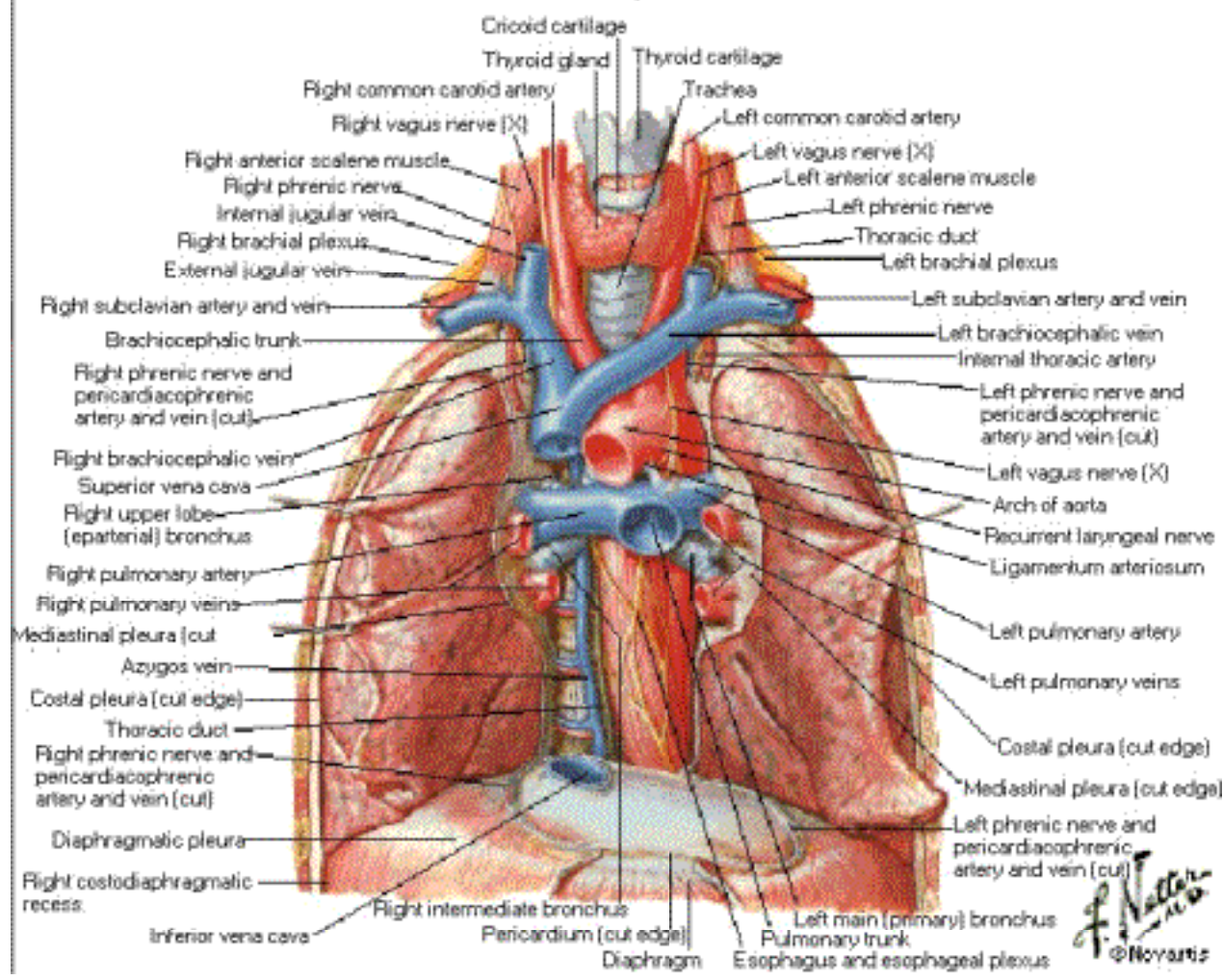


0 1.1002

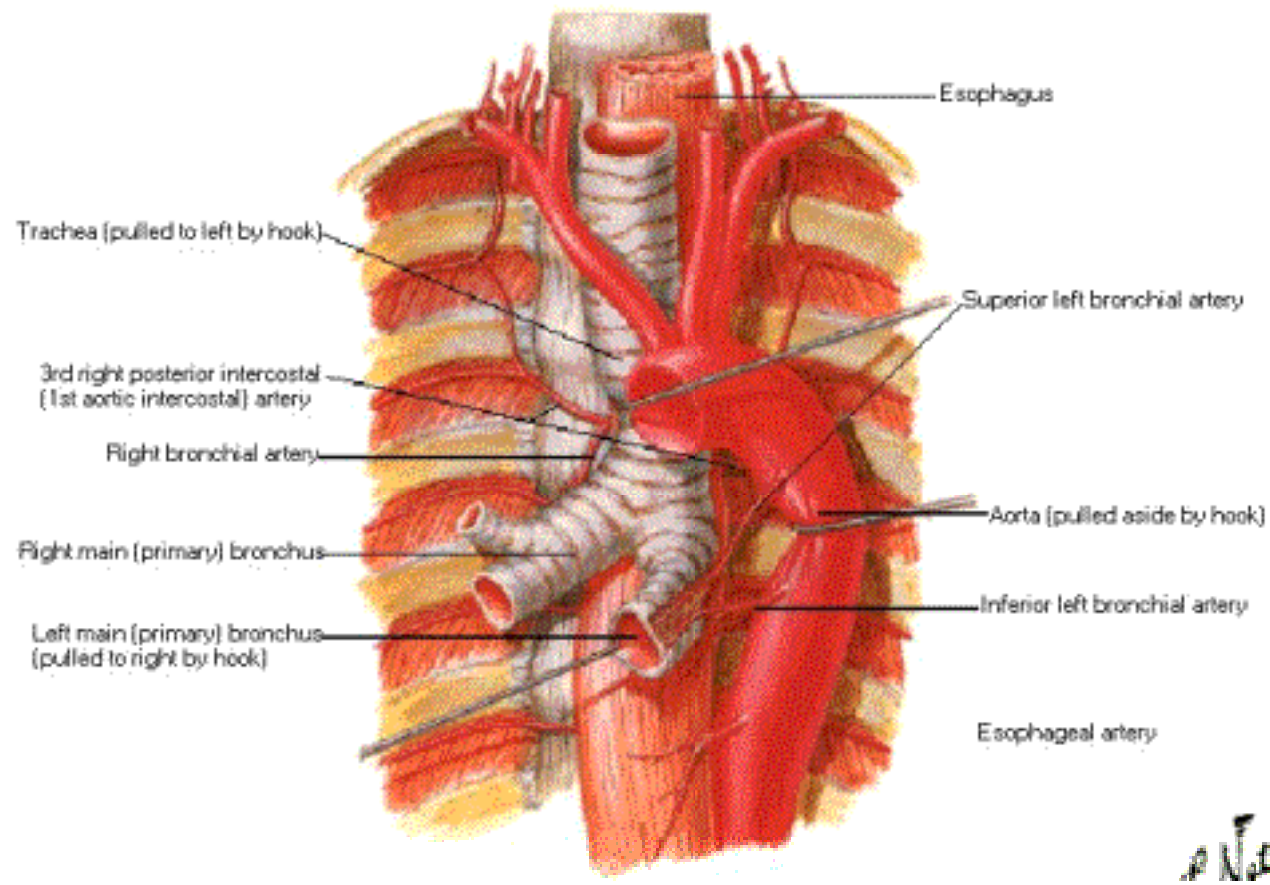
Pulmonary Arteries and Veins



Main Bronchi With Pulmonary Arteries and Veins in Situ

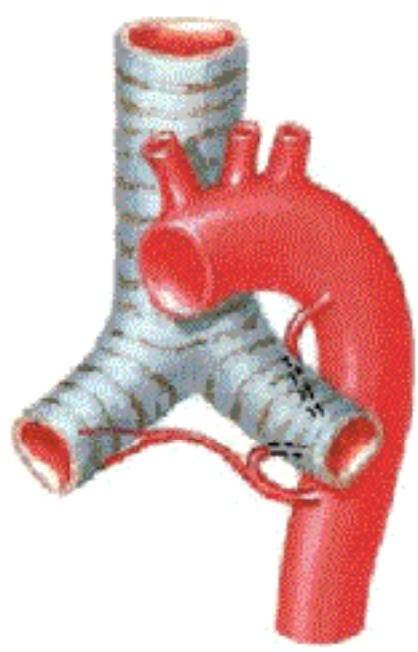


Bronchial Arteries

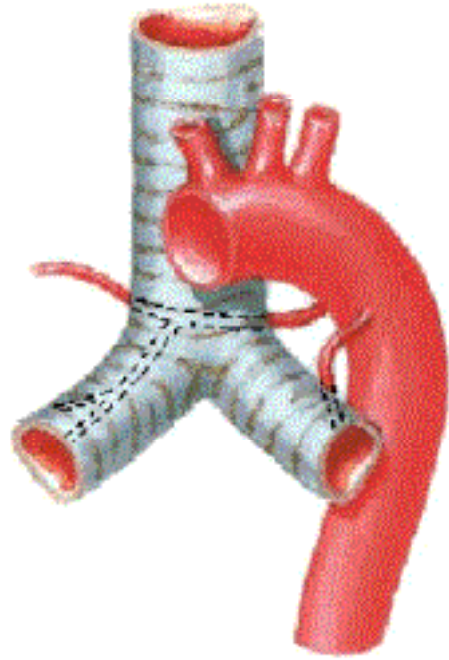


Bronchial Arteries

Variations

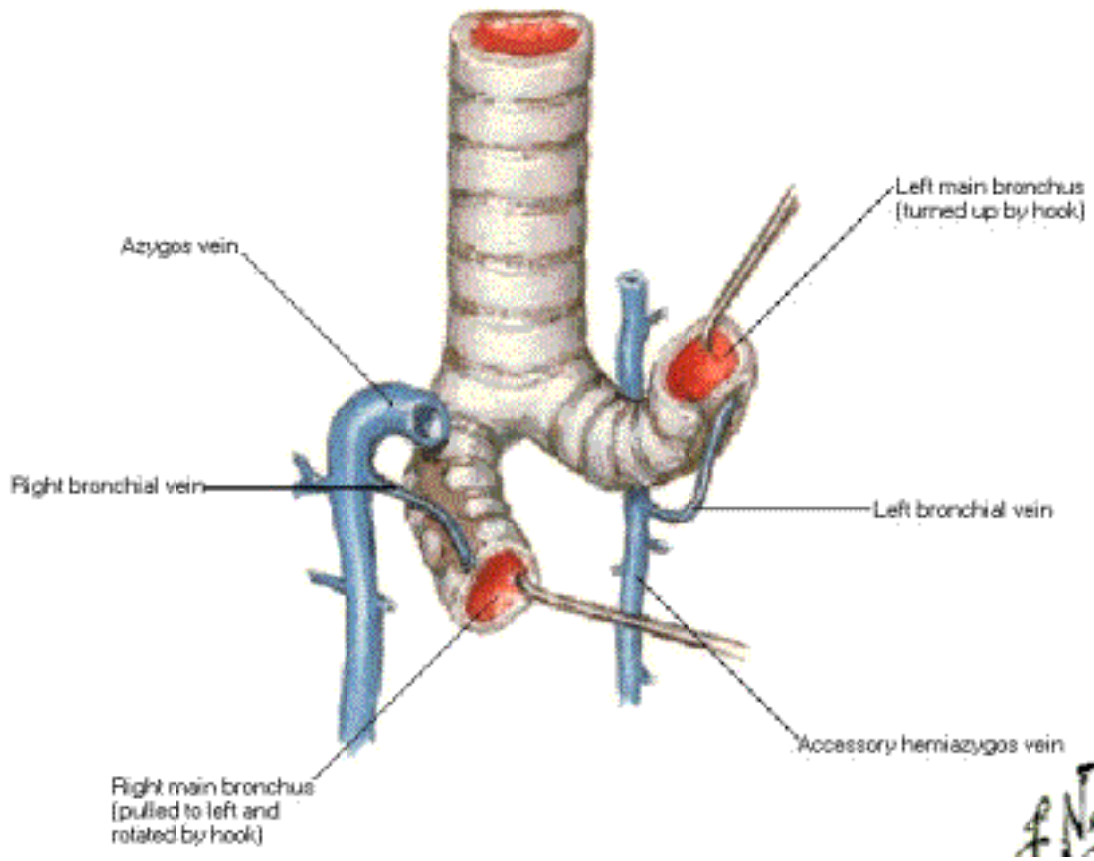


Right and left bronchial arteries originating from aorta by single stem

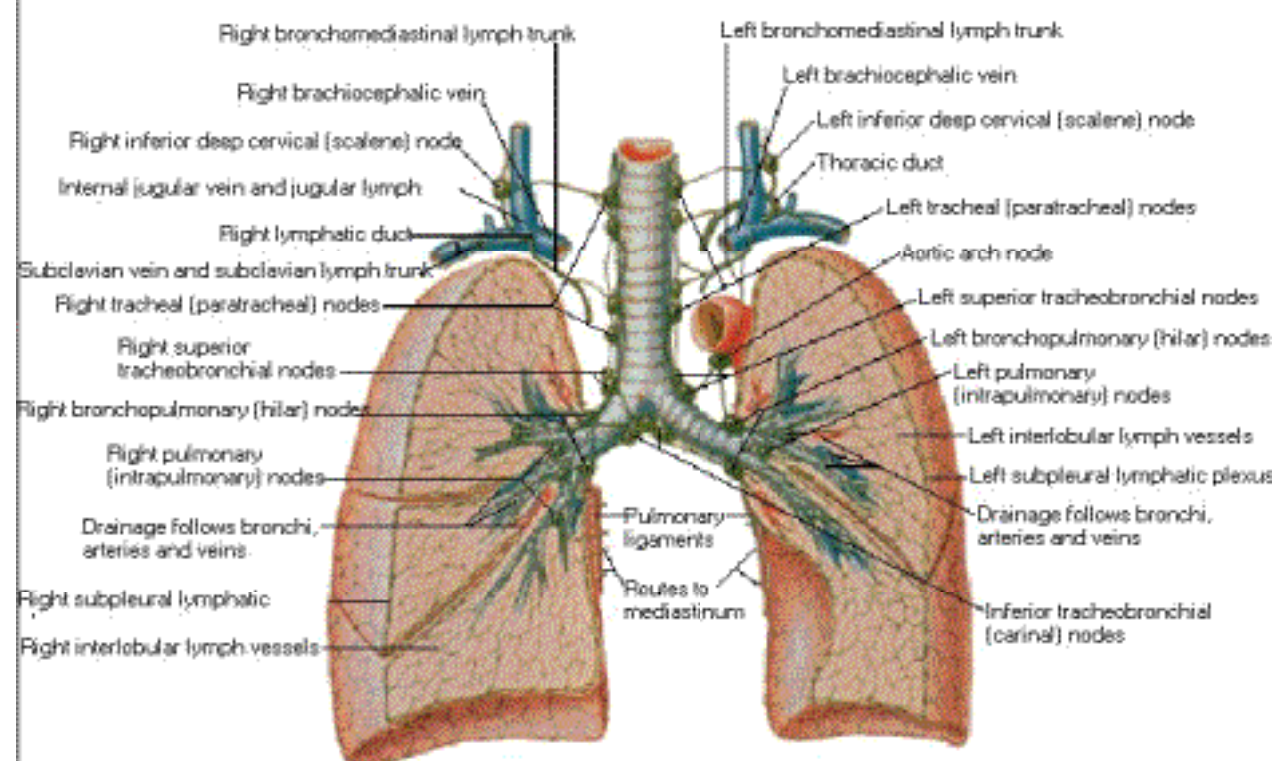


Only single bronchial artery to each bronchus (normally, two to left bronchus)

Bronchial Veins



Lymph Vessels and Nodes of Lung

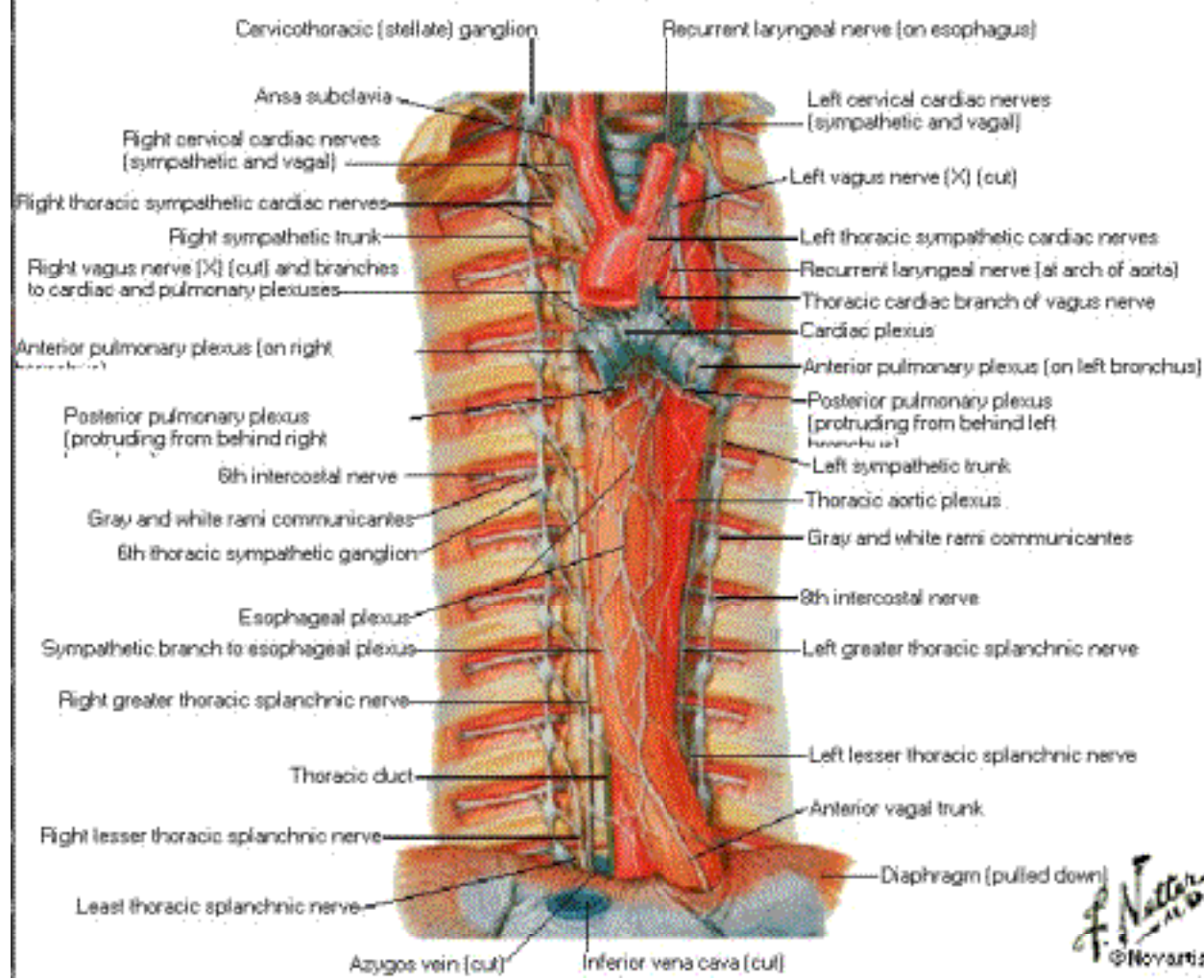


Right lung: All lobes drain to intrapulmonary and bronchopulmonary (hilar) nodes, then to inferior tracheobronchial (carinal) nodes, right superior tracheobronchial nodes and to right tracheal nodes on way to brachiocephalic vein via bronchomediastinal lymph trunk and/or scalene node.

Left lung: Upper lobe drains to pulmonary and hilar nodes, carinal nodes, left superior tracheobronchial nodes, left tracheal nodes and/or aortic arch node, then to brachiocephalic vein via left bronchomediastinal trunk and thoracic duct. Left lower lobe drains also to pulmonary and hilar nodes and to carinal nodes, but then mostly to right superior tracheobronchial nodes, where it follows same route as lymph from right lung.

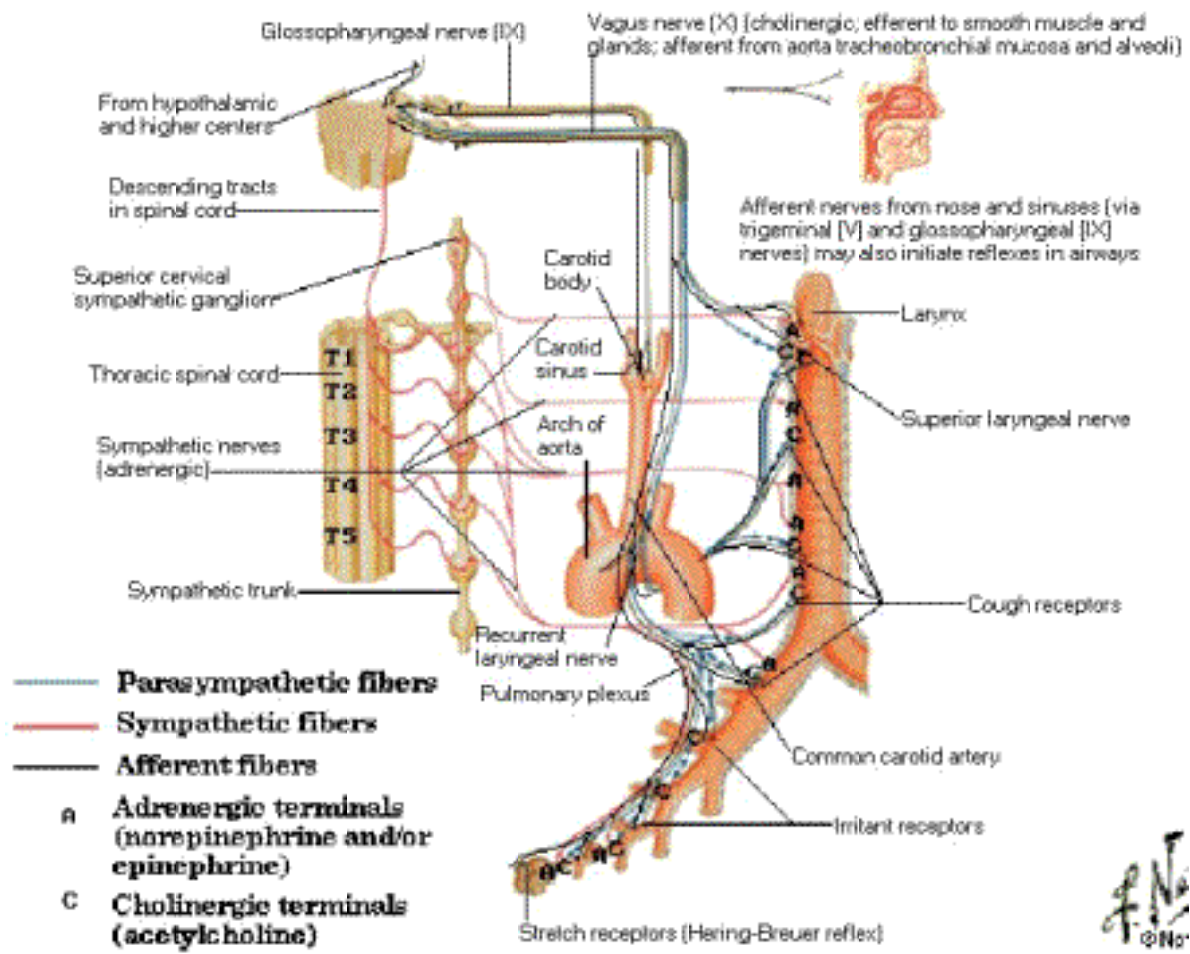
F. Netter M.D.
© 1996

Autonomic Nerves in Thorax



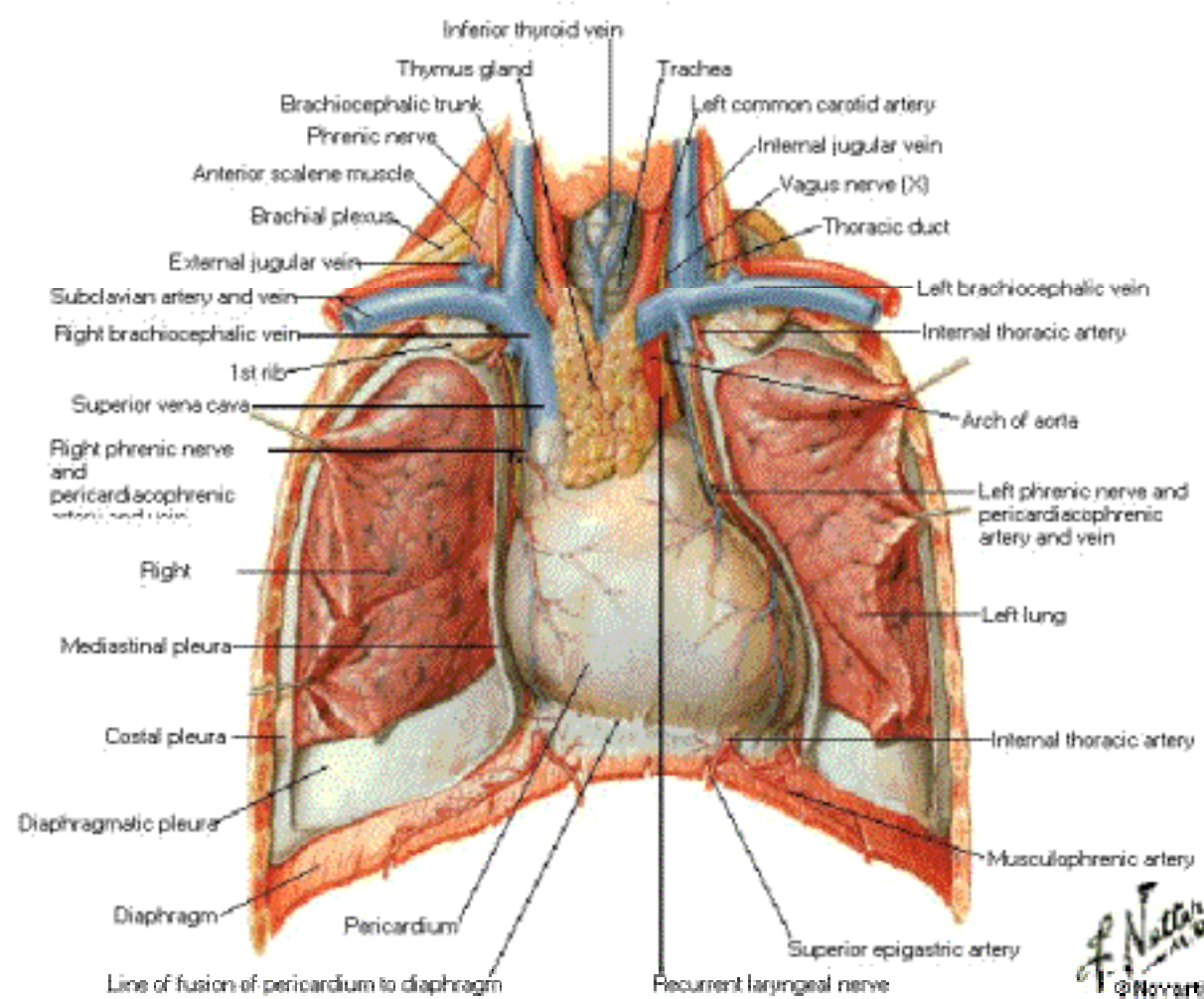
Innervation of Tracheobronchial Tree

Schema



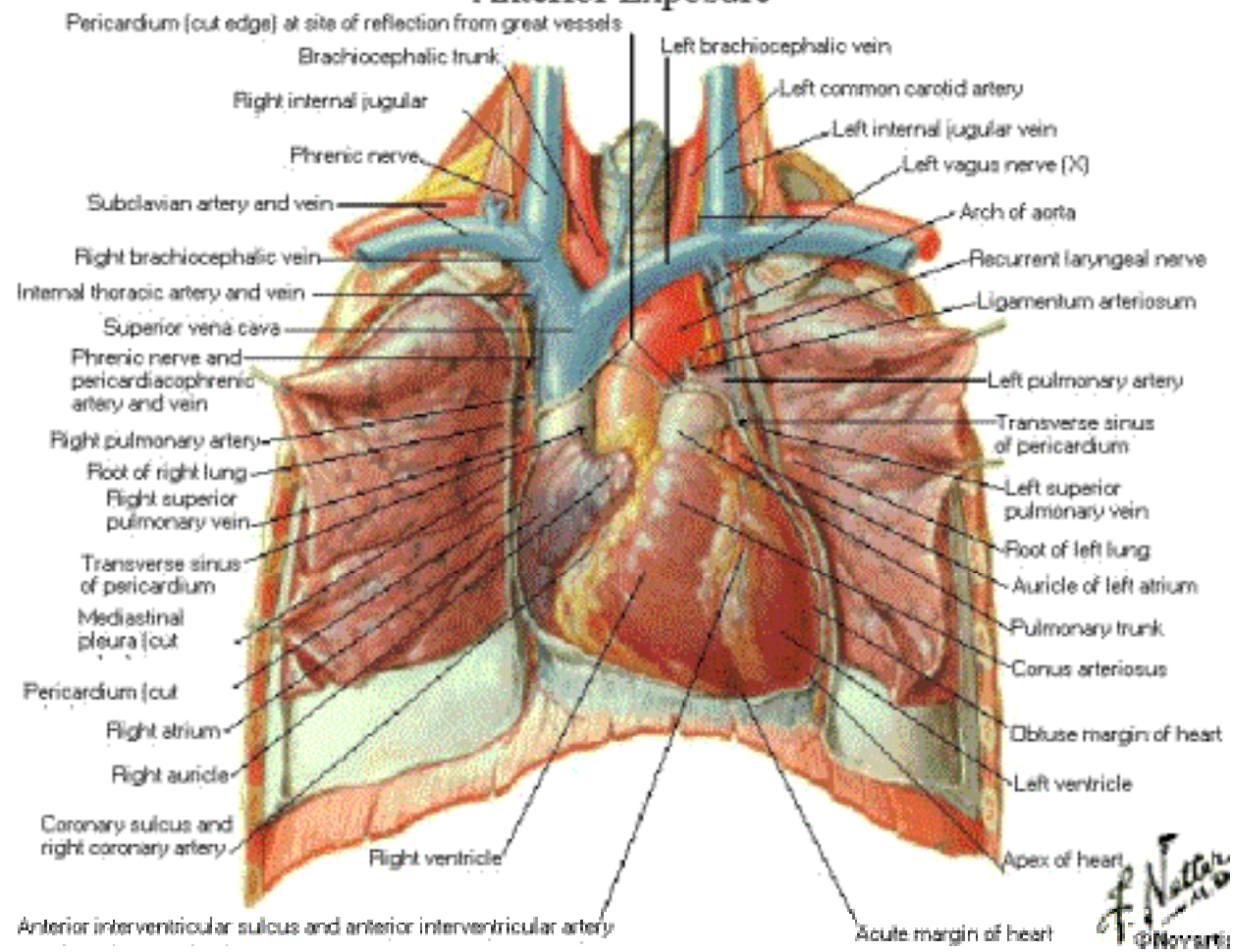
F.N.
© No.

Heart in Situ



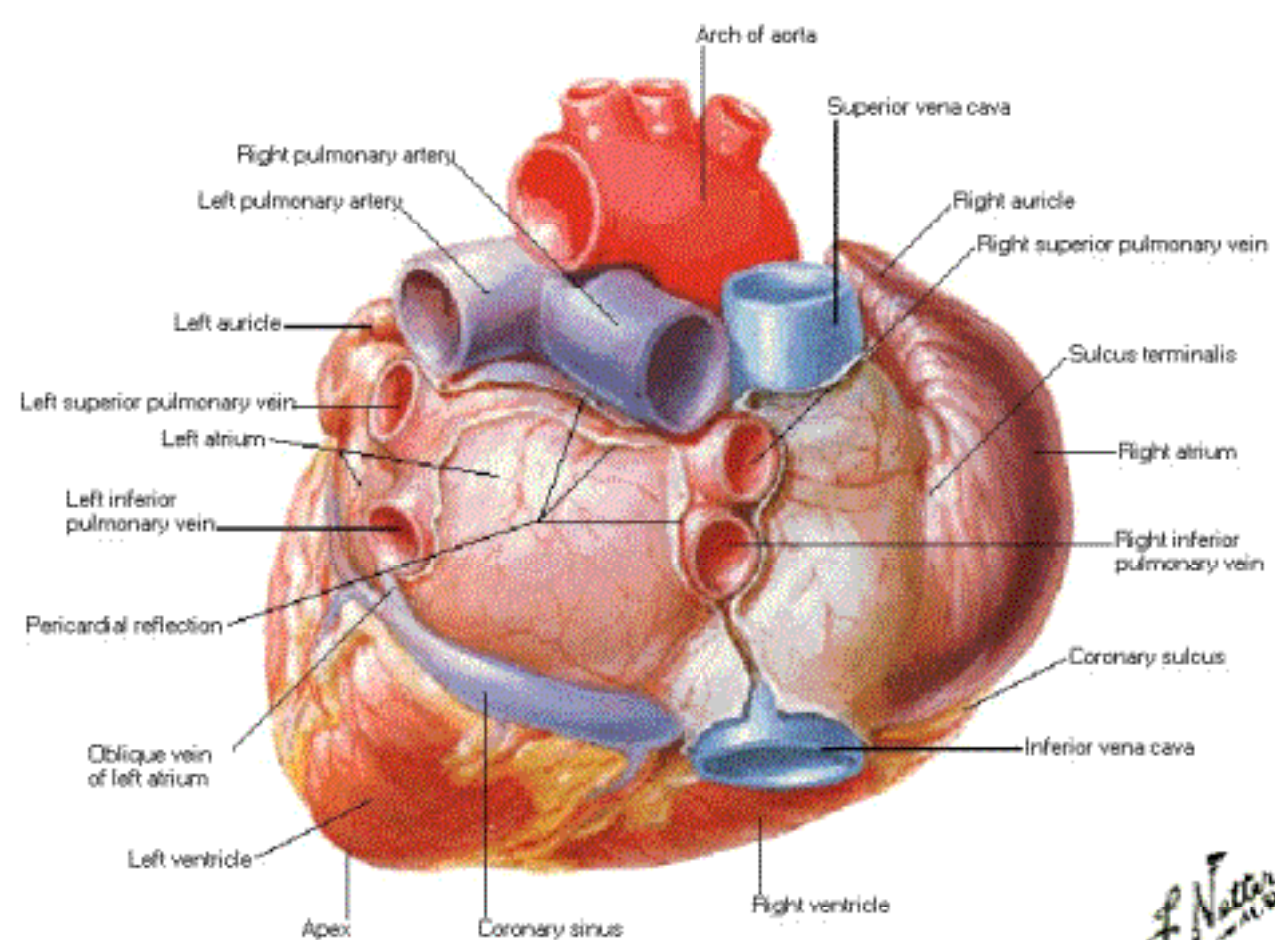
Heart

Anterior Exposure



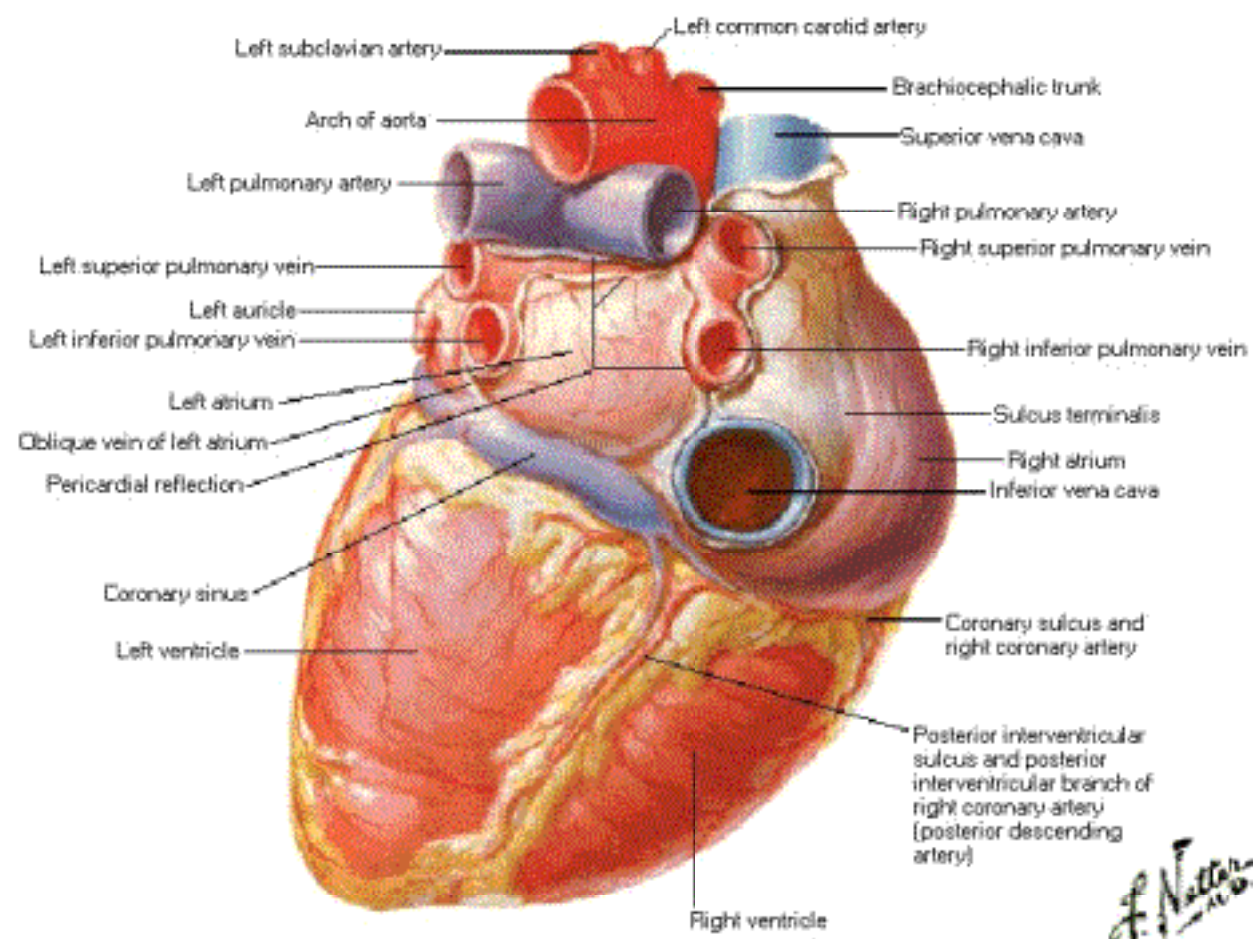
Heart - Basal Surface

Posterior View



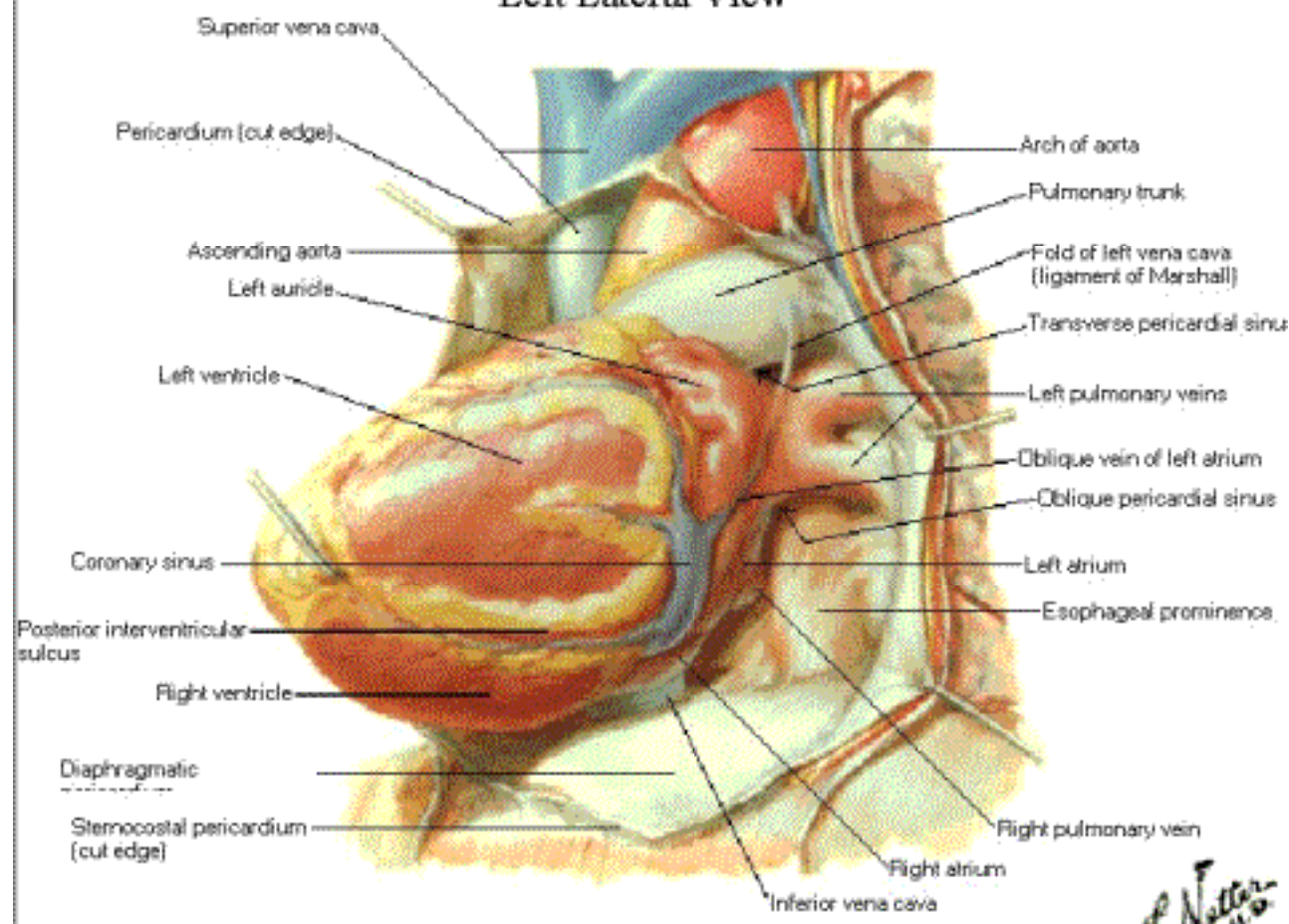
Heart - Diaphragmatic Surface

Posteroinferior View



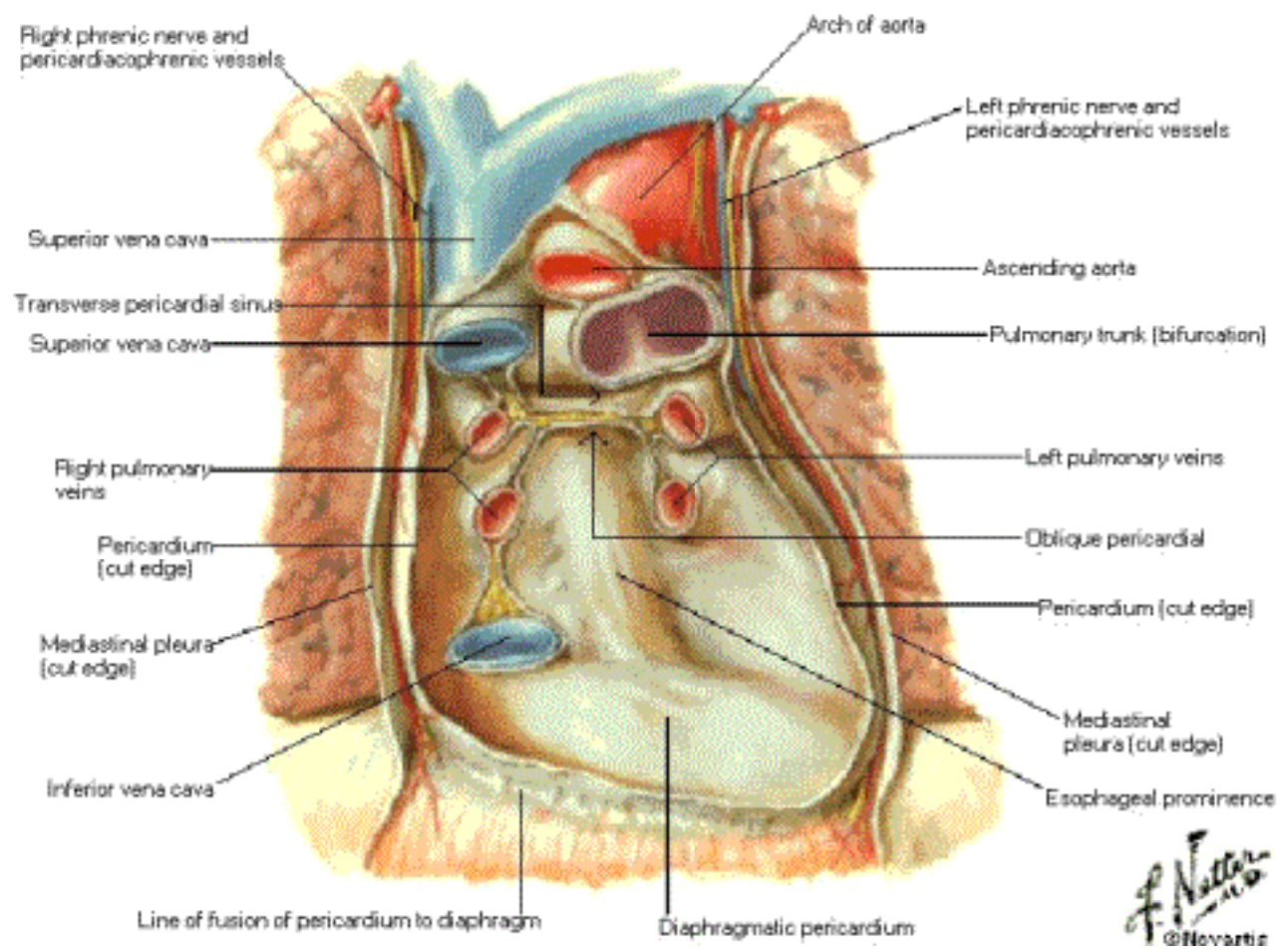
Pericardial Sac - Heart Drawn Out

Left Lateral View



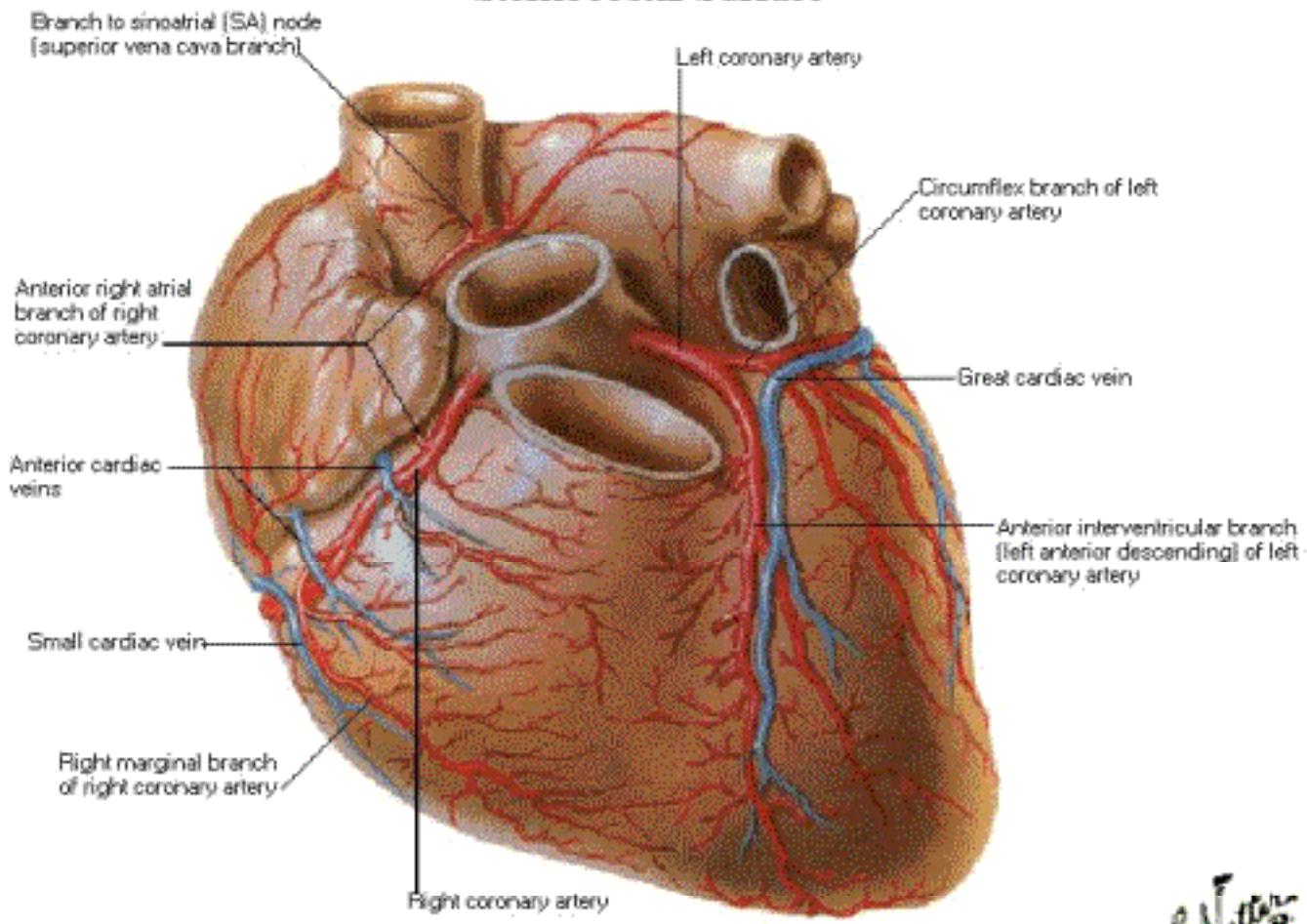
Pericardial Sac - Heart Removed

Anterior View



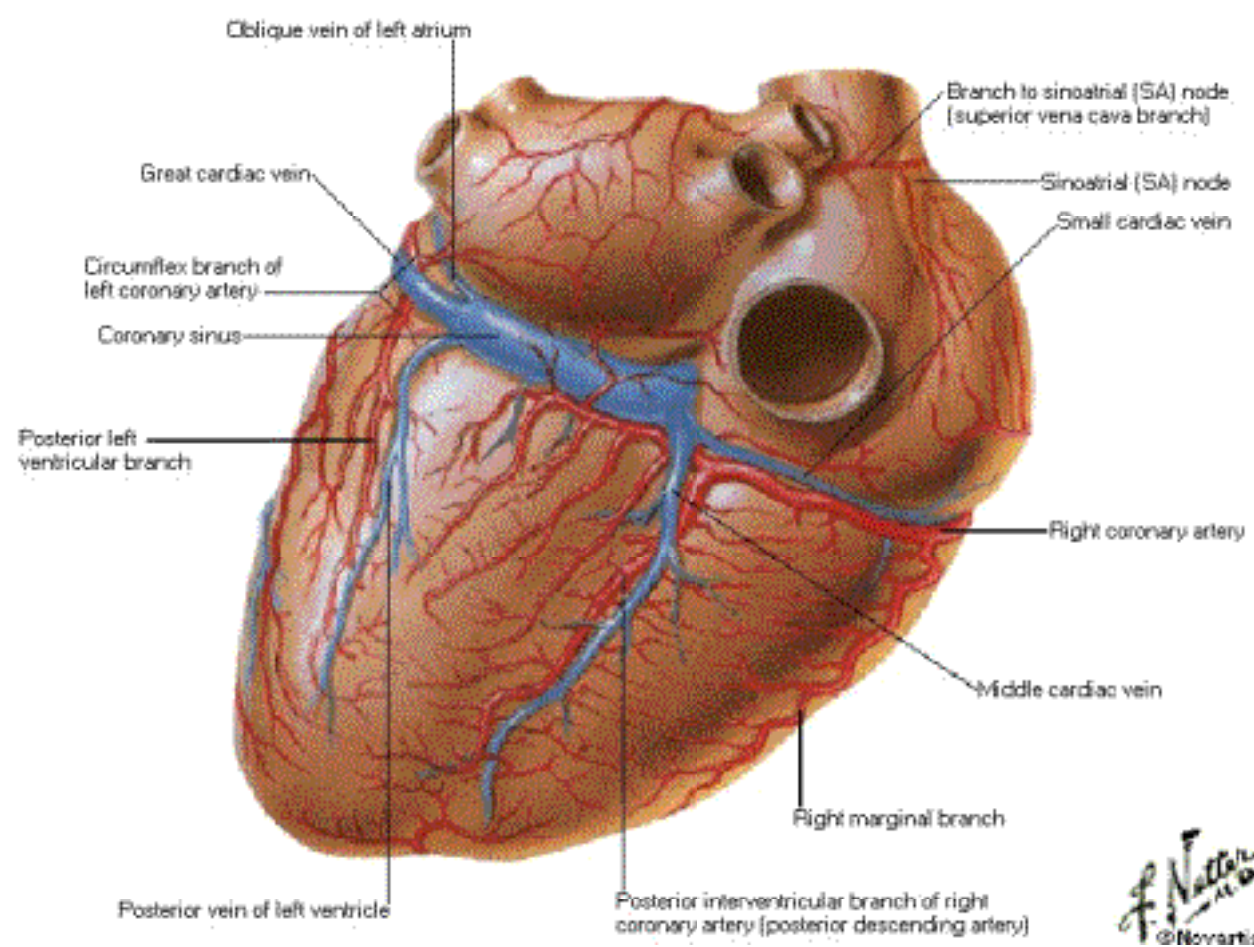
Coronary Arteries and Cardiac Veins

Sternocostal Surface



Coronary Arteries and Cardiac Veins

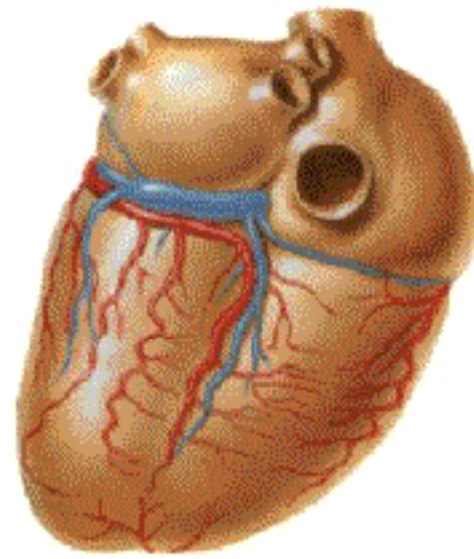
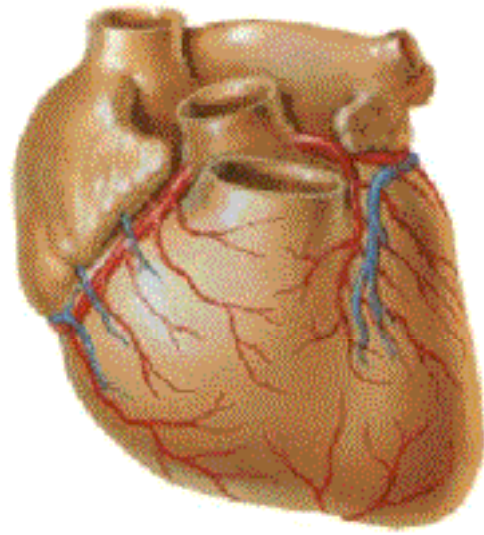
Diaphragmatic Surface



Coronary Arteries and Cardiac Veins

Variations 1

Posterior interventricular (posterior descending) branch derived from circumflex branch of left coronary artery instead of from right coronary artery.

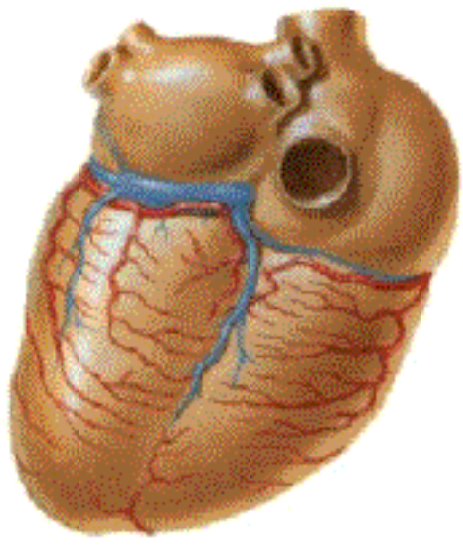


Anterior interventricular (left anterior descending) branch of left coronary artery very short. Apical part of sternocostal surface supplied by branches from posterior interventricular (posterior descending) branch of right coronary artery curving around apex.

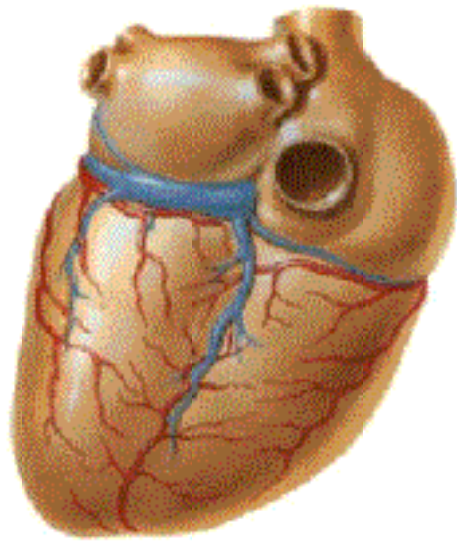
e. Netter

Coronary Arteries and Cardiac Veins

Variations 2



Posterior interventricular (posterior descending) branch absent. Area supplied chiefly by small branches from circumflex branch of left coronary artery and from right coronary artery.

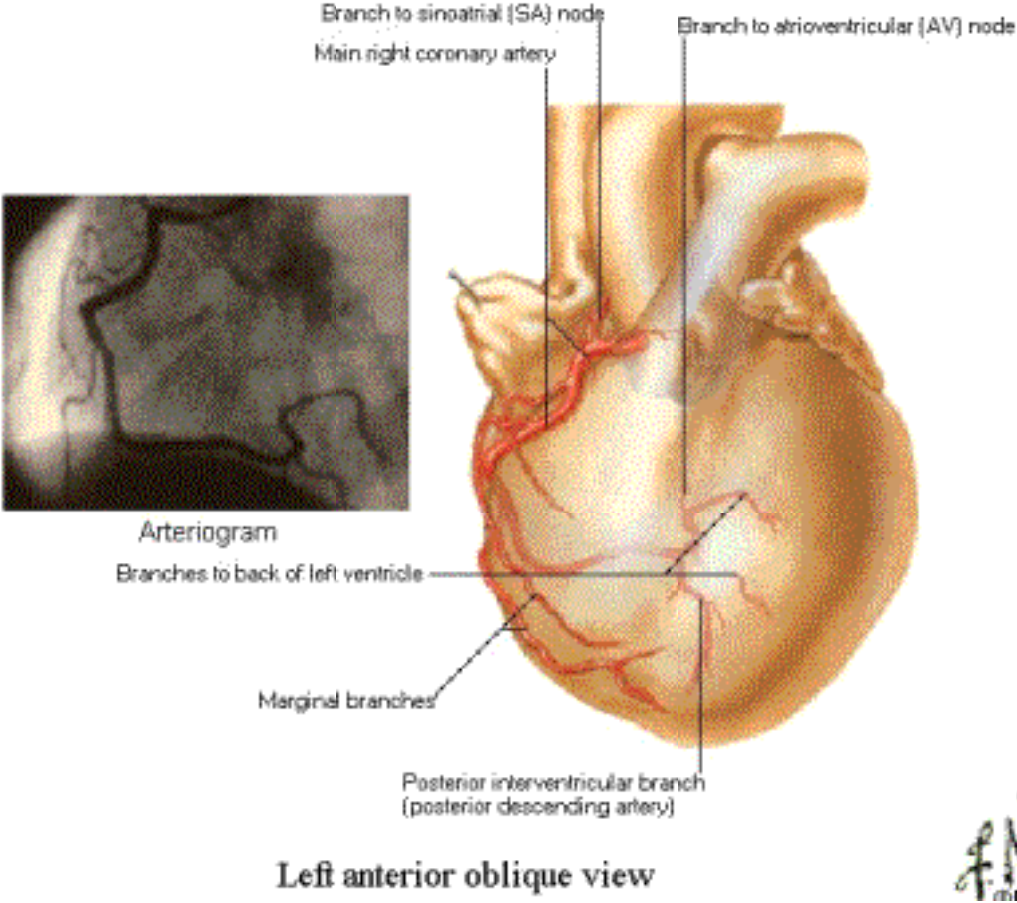


Posterior interventricular (posterior descending) branch absent. Area supplied chiefly by elongated anterior interventricular (left anterior descending) branch curving around apex.



Right Coronary Artery

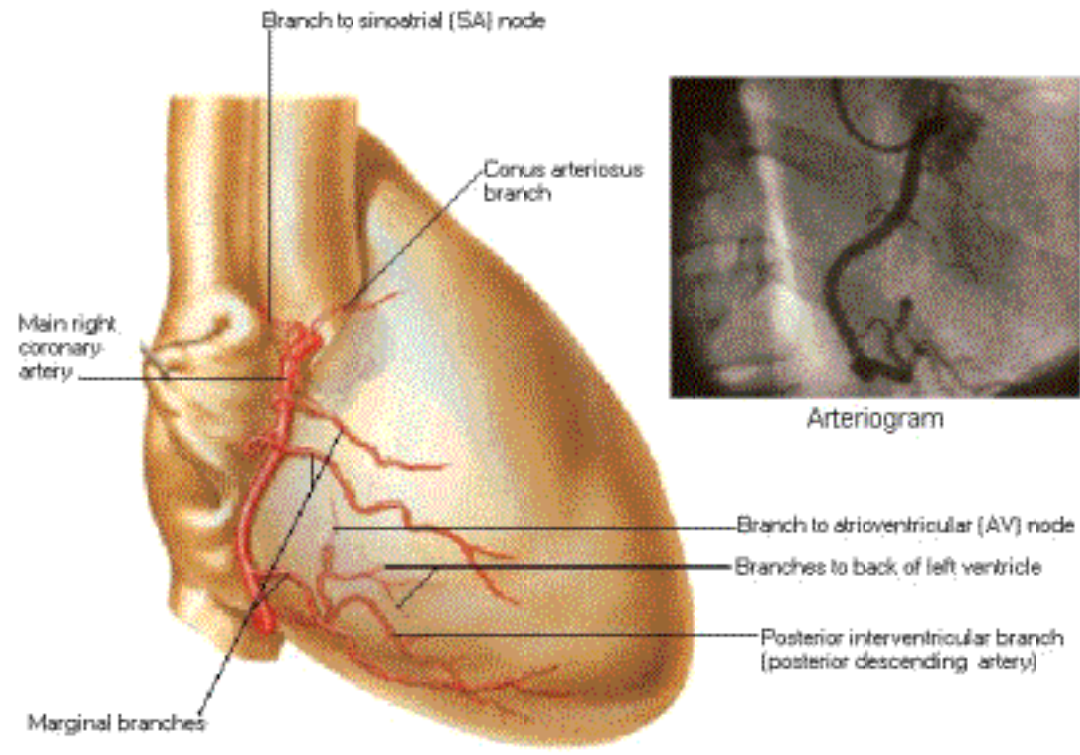
Arteriographic View 1



41

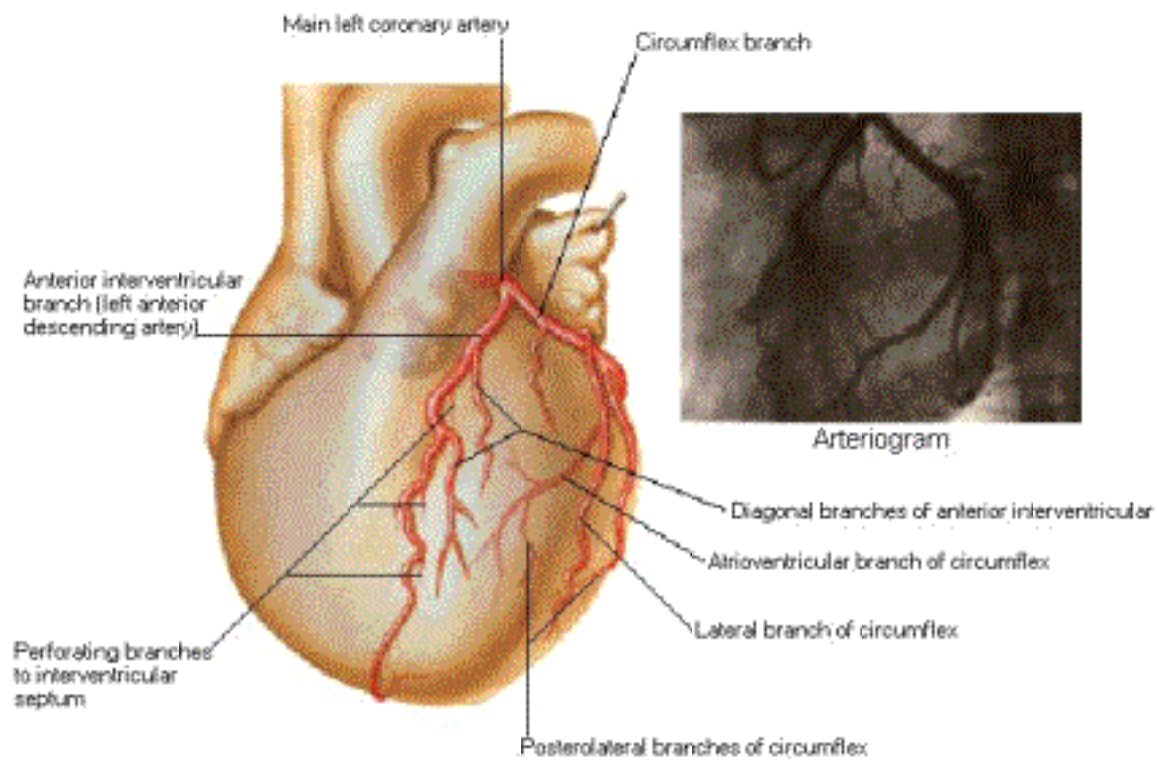
Right Coronary Artery

Arteriographic View 2



Right anterior oblique view

Left Coronary Artery Arteriographic View 1


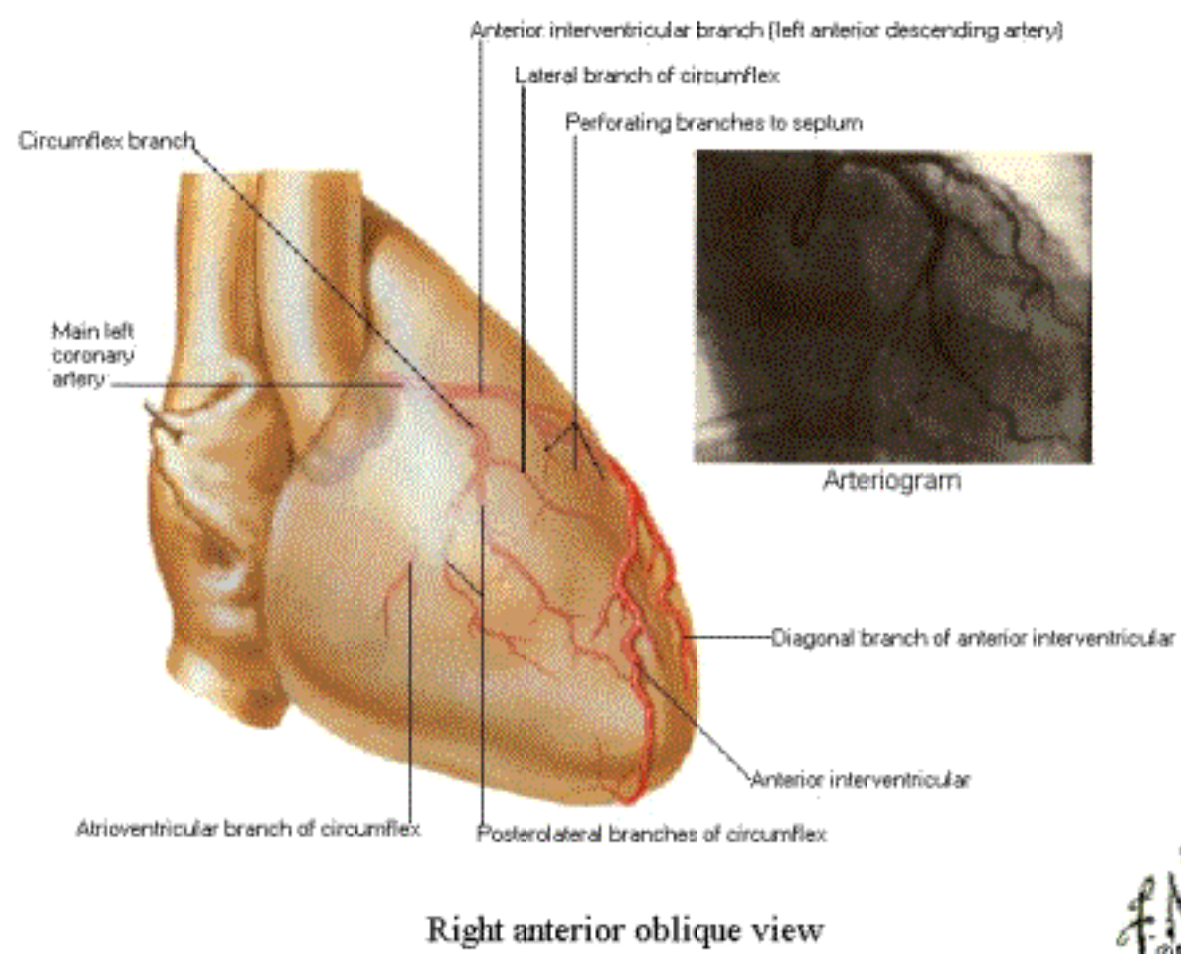


Left anterior oblique view

f.

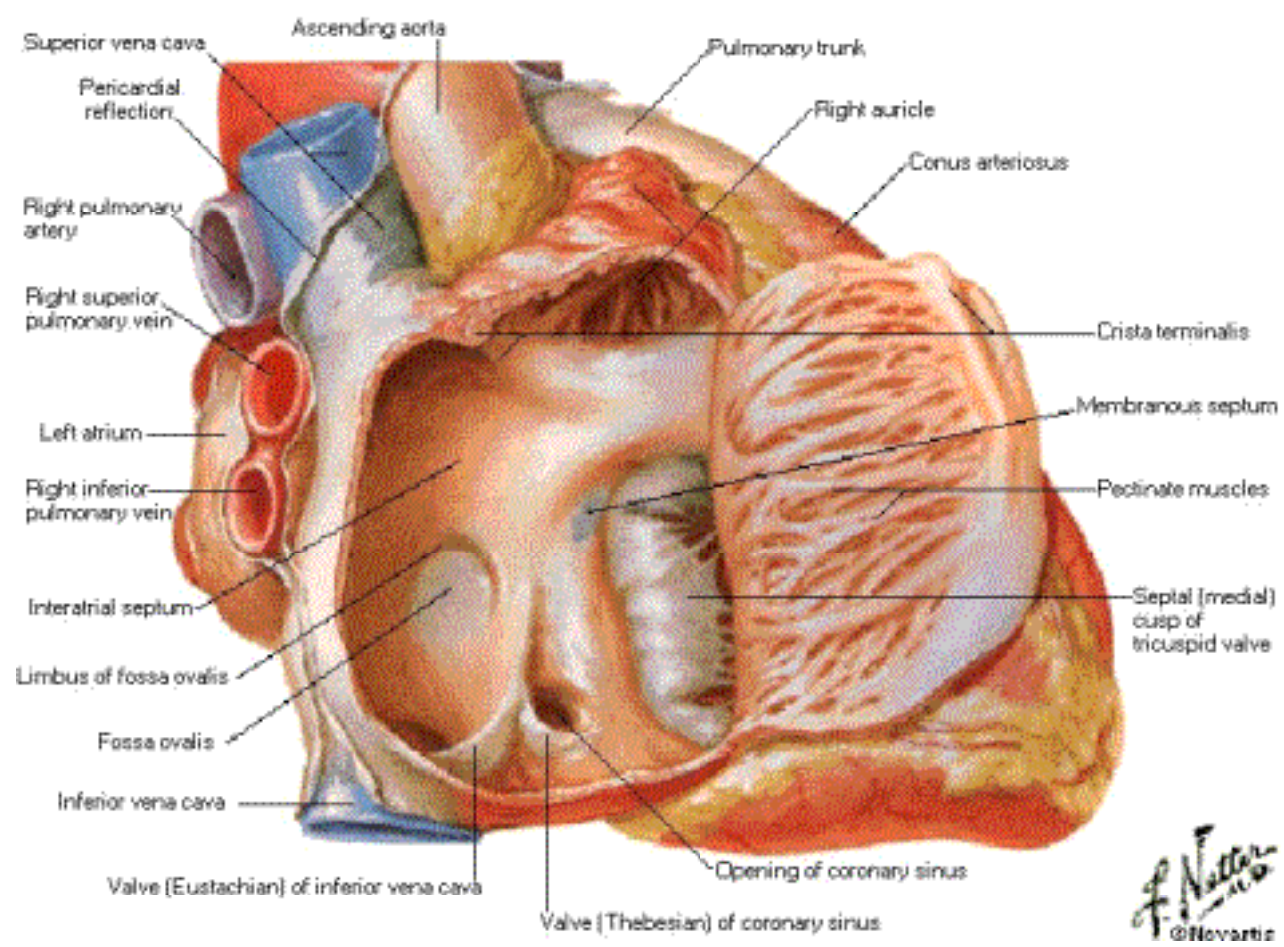
Left Coronary Artery

Arteriographic View 2

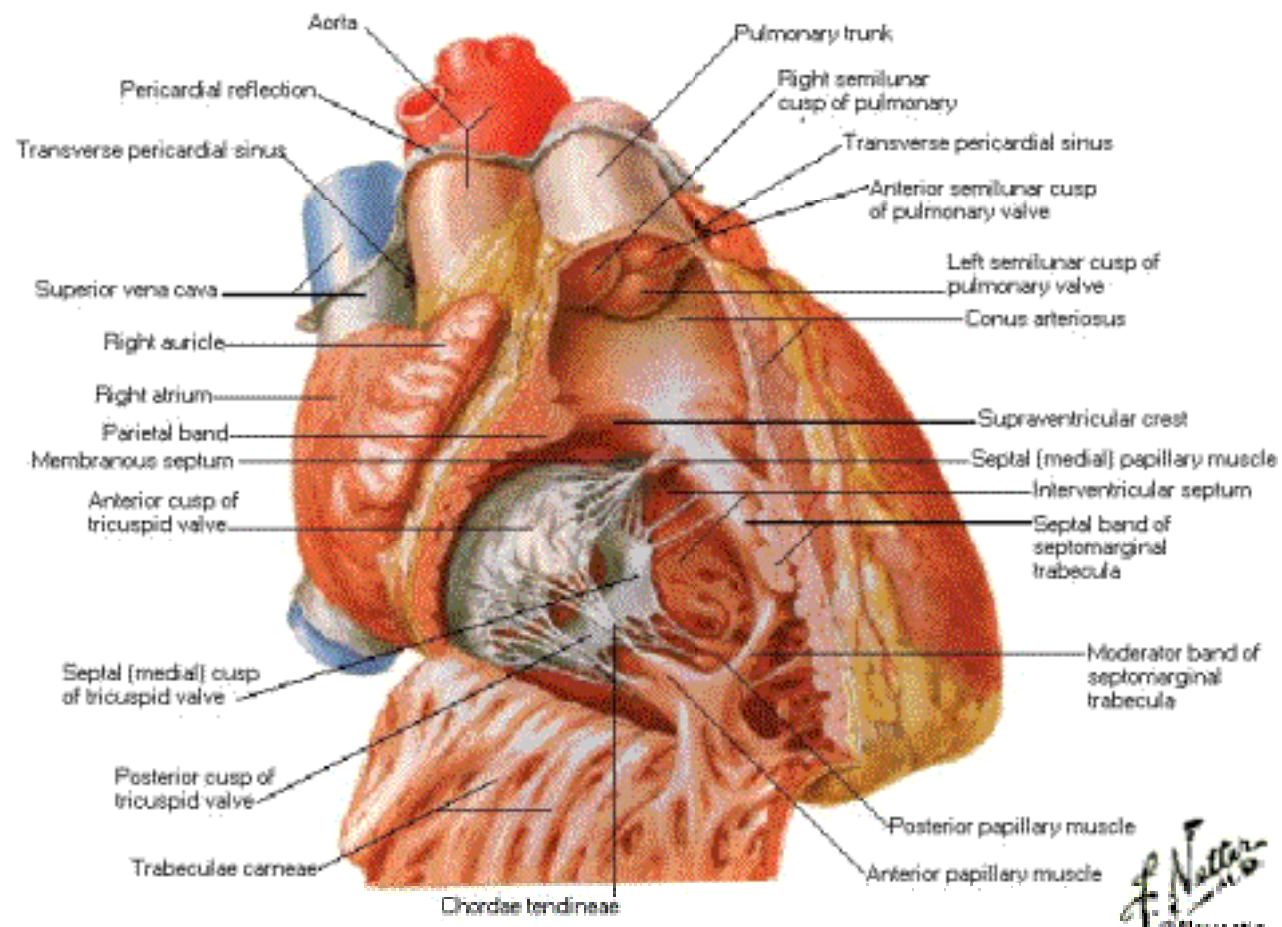


Opened Right Atrium

Right Lateral View

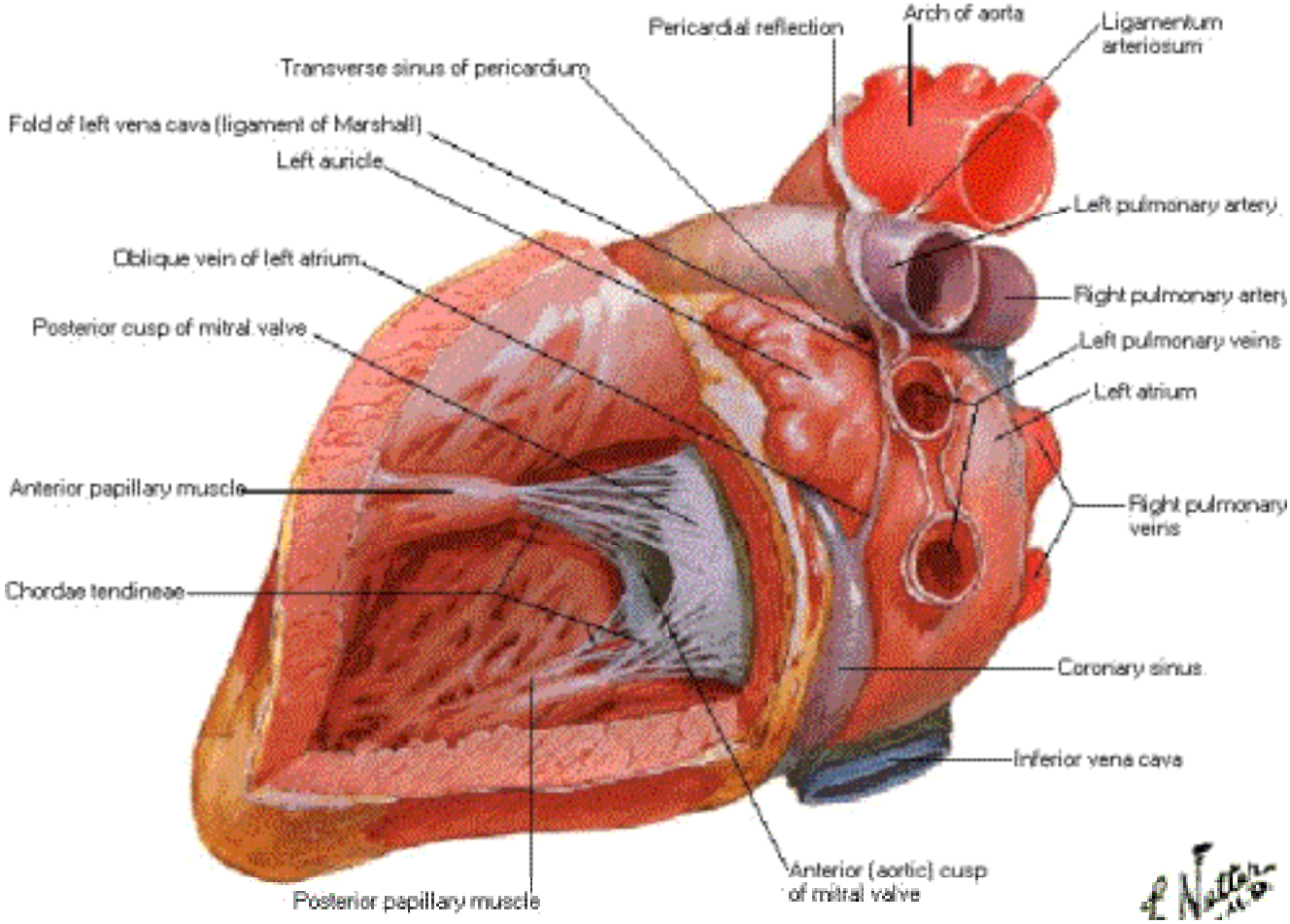


Opened Right Ventricle Anterior View

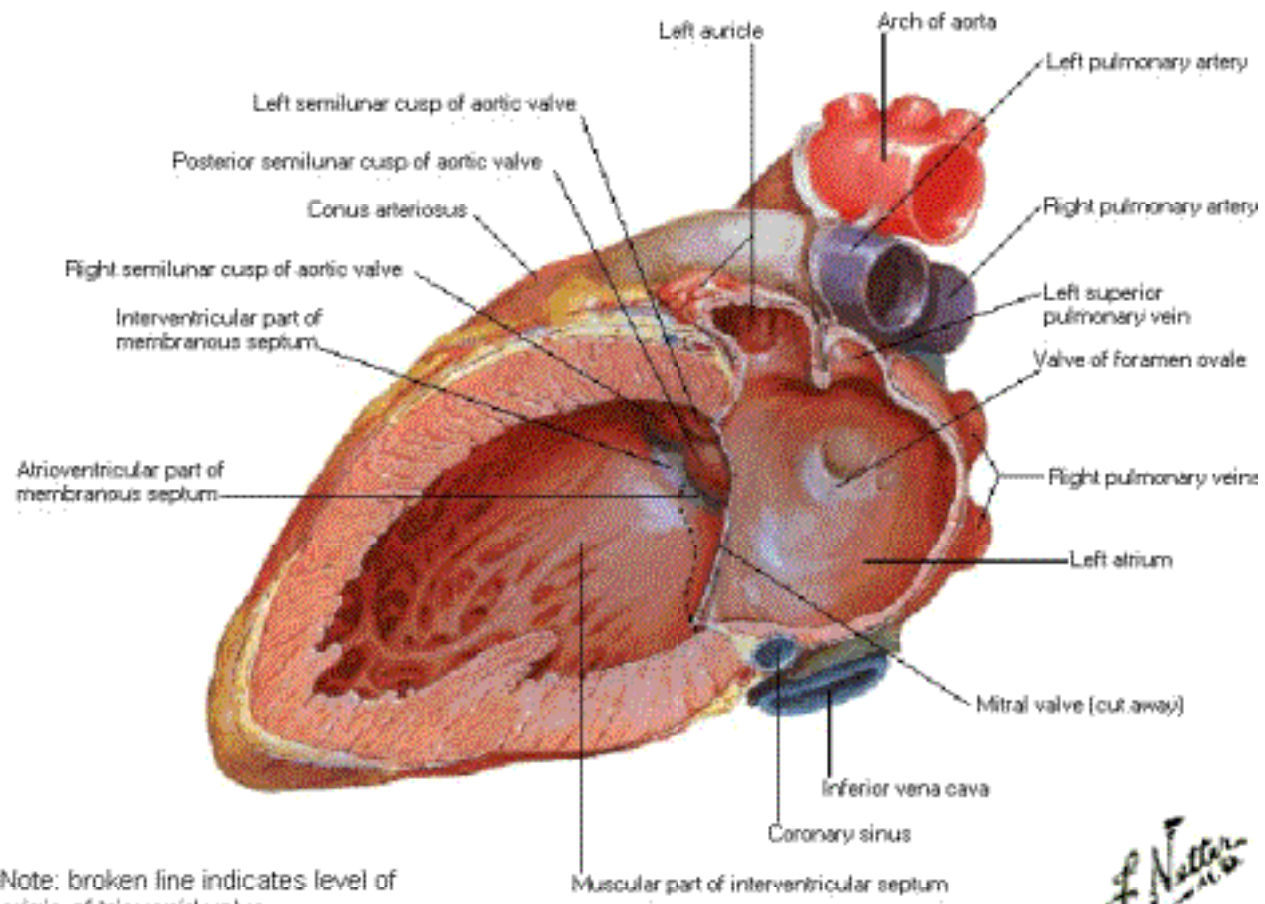


Left Ventricle

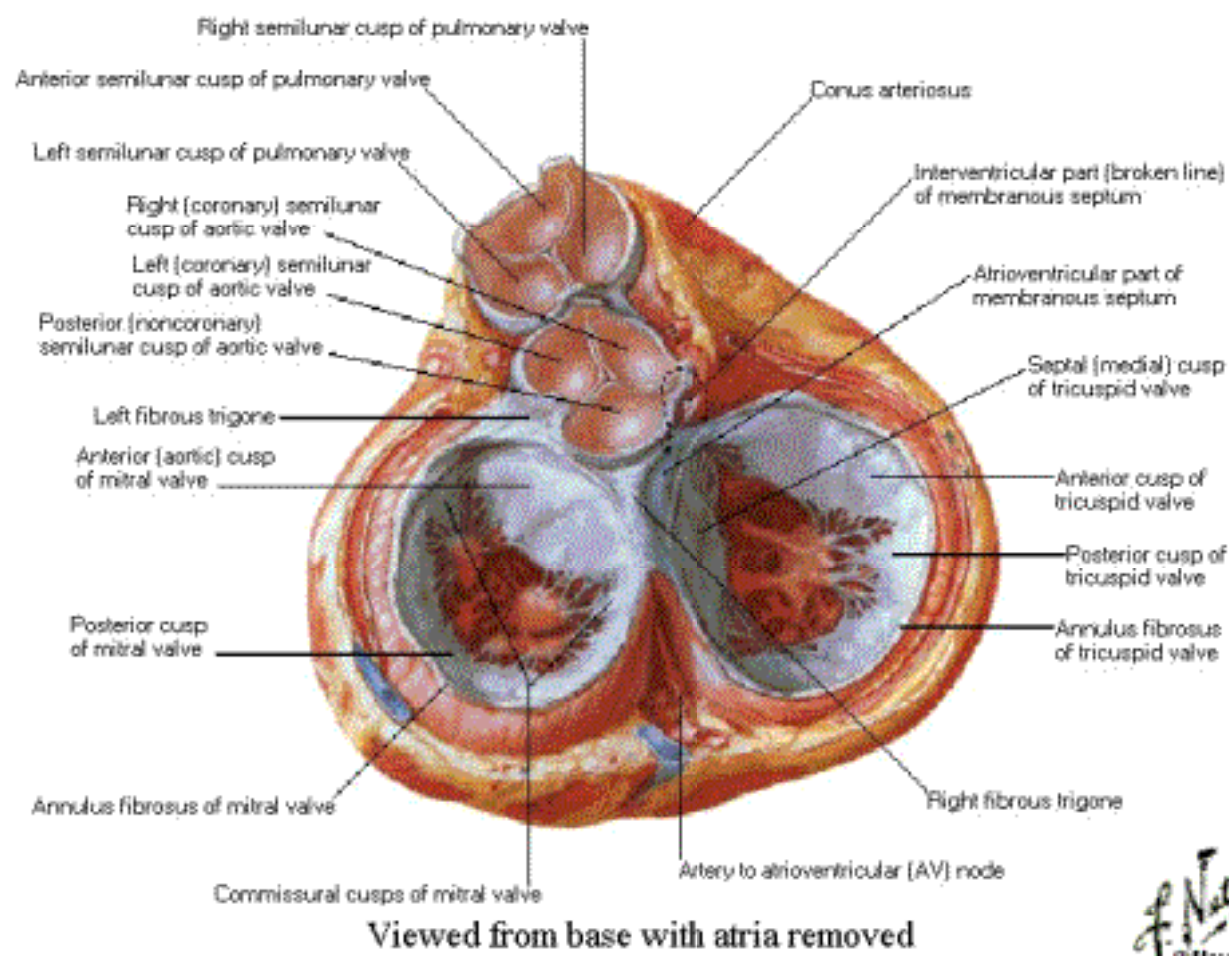
Flap Opened in Posterolateral Wall



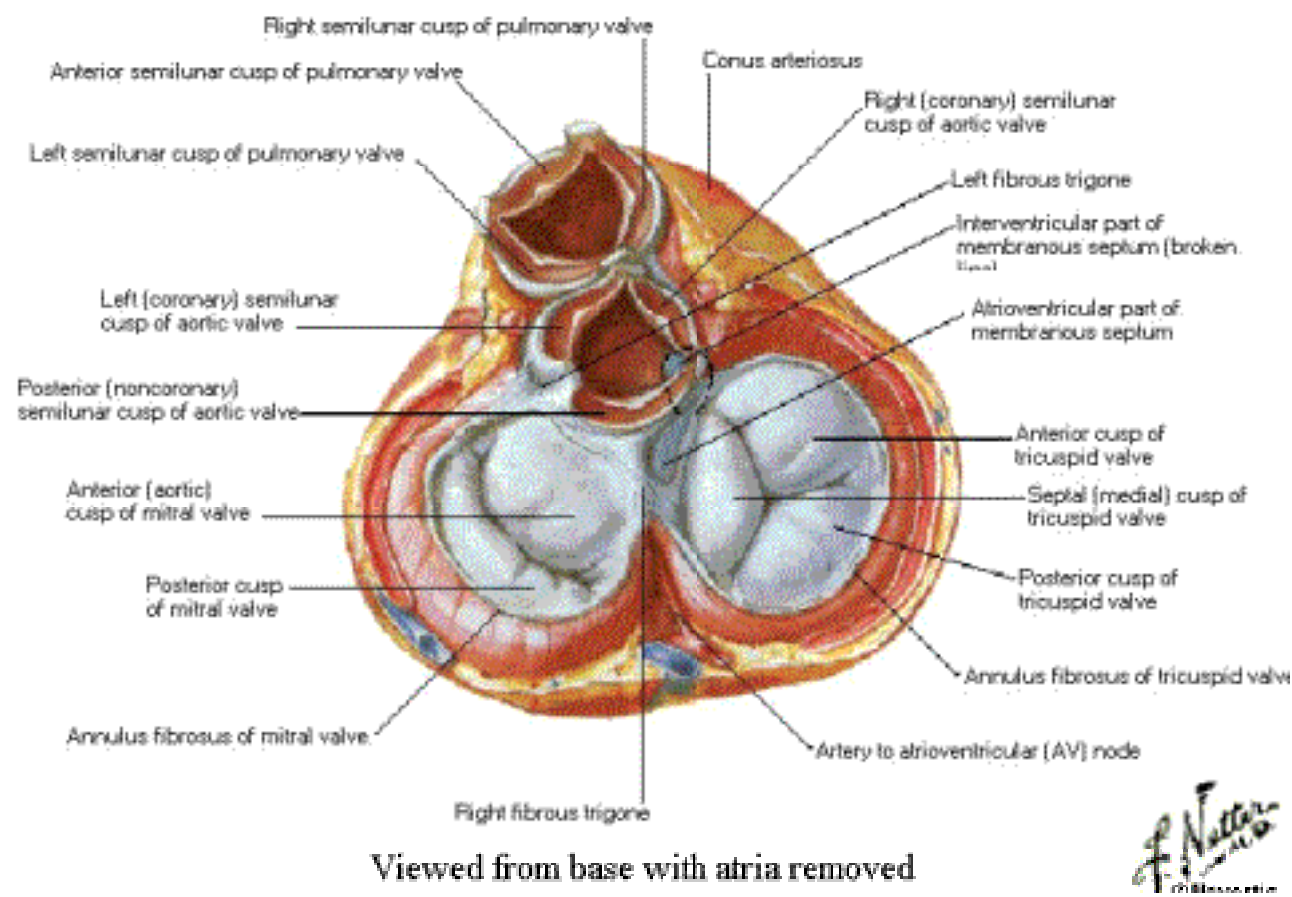
Left Atrium and Ventricle Sectioned with Mitral Valve Cut Away



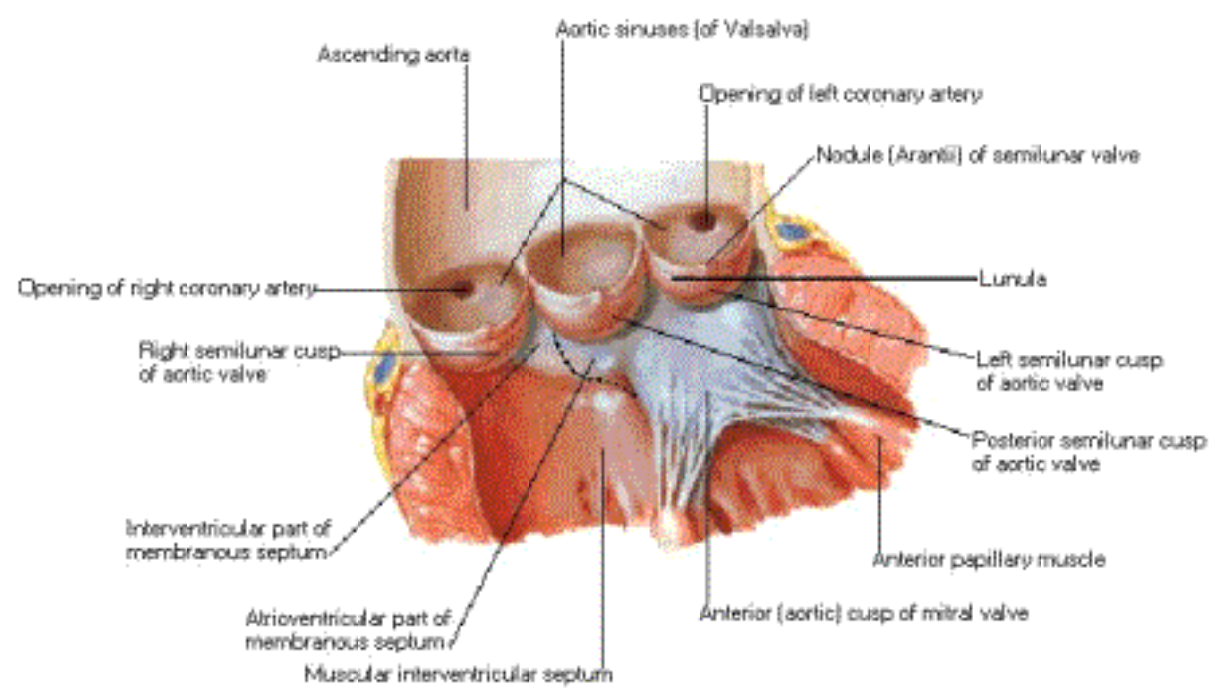
Valves of Heart in Diastole



Valves of Heart in Systole



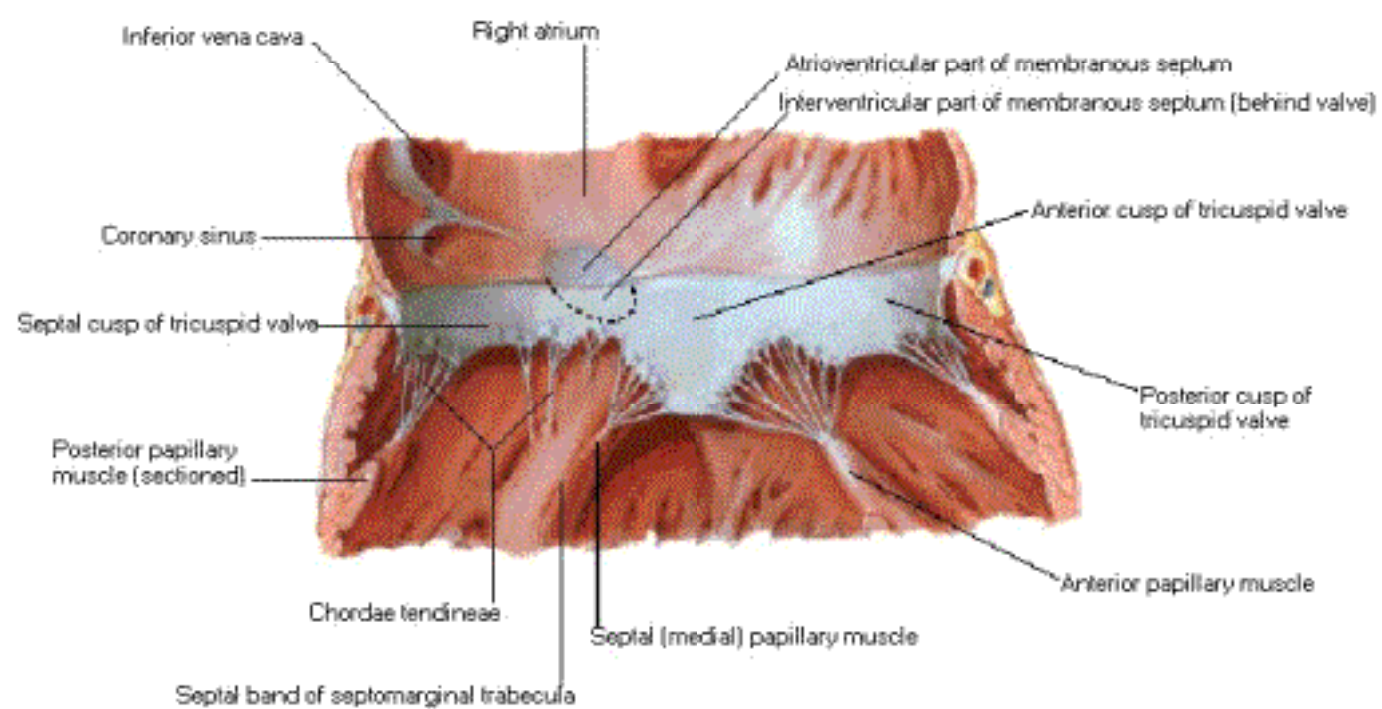
Aortic Valve



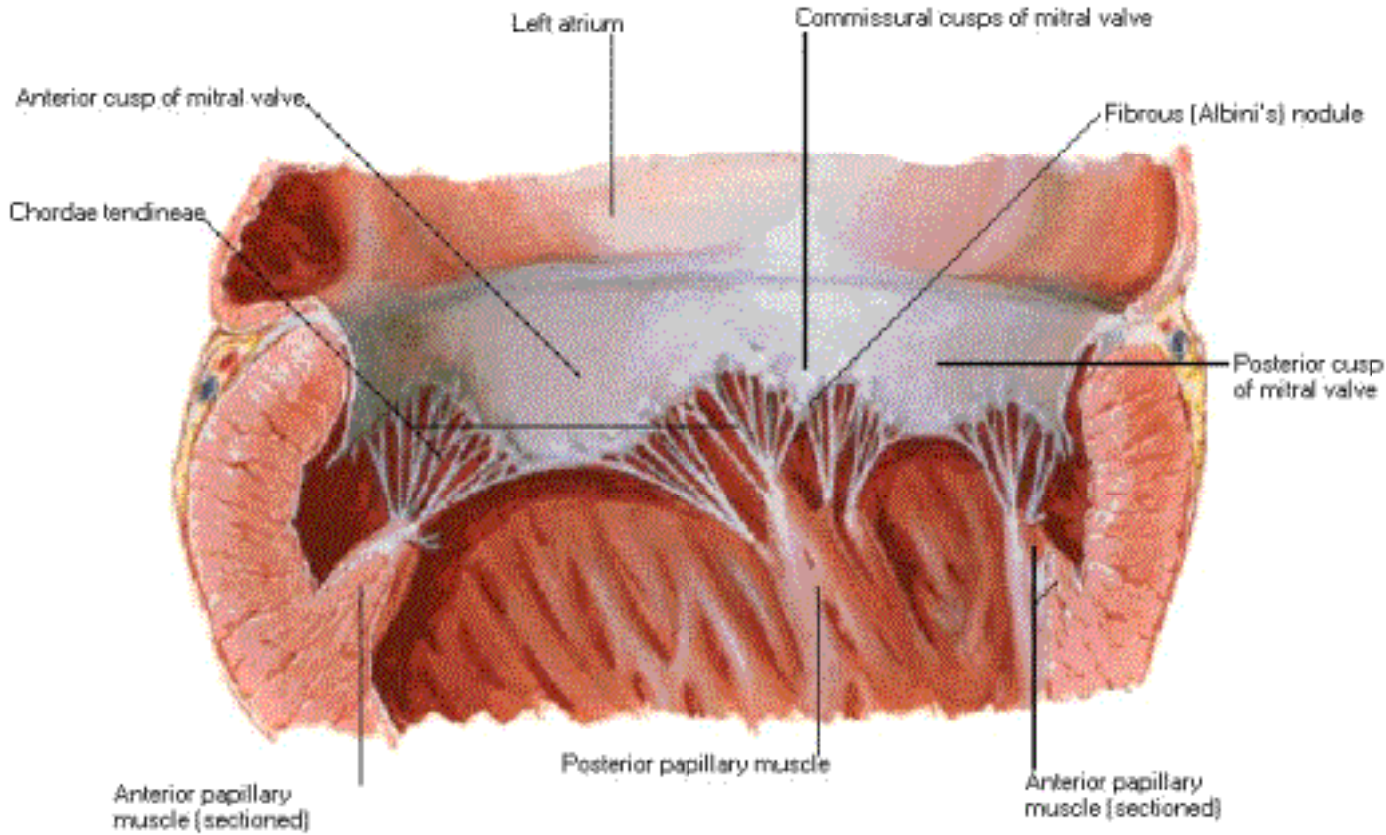
Note: broken line indicates level of origin of tricuspid valve on opposite side of septum.

f. N.
© No. 1

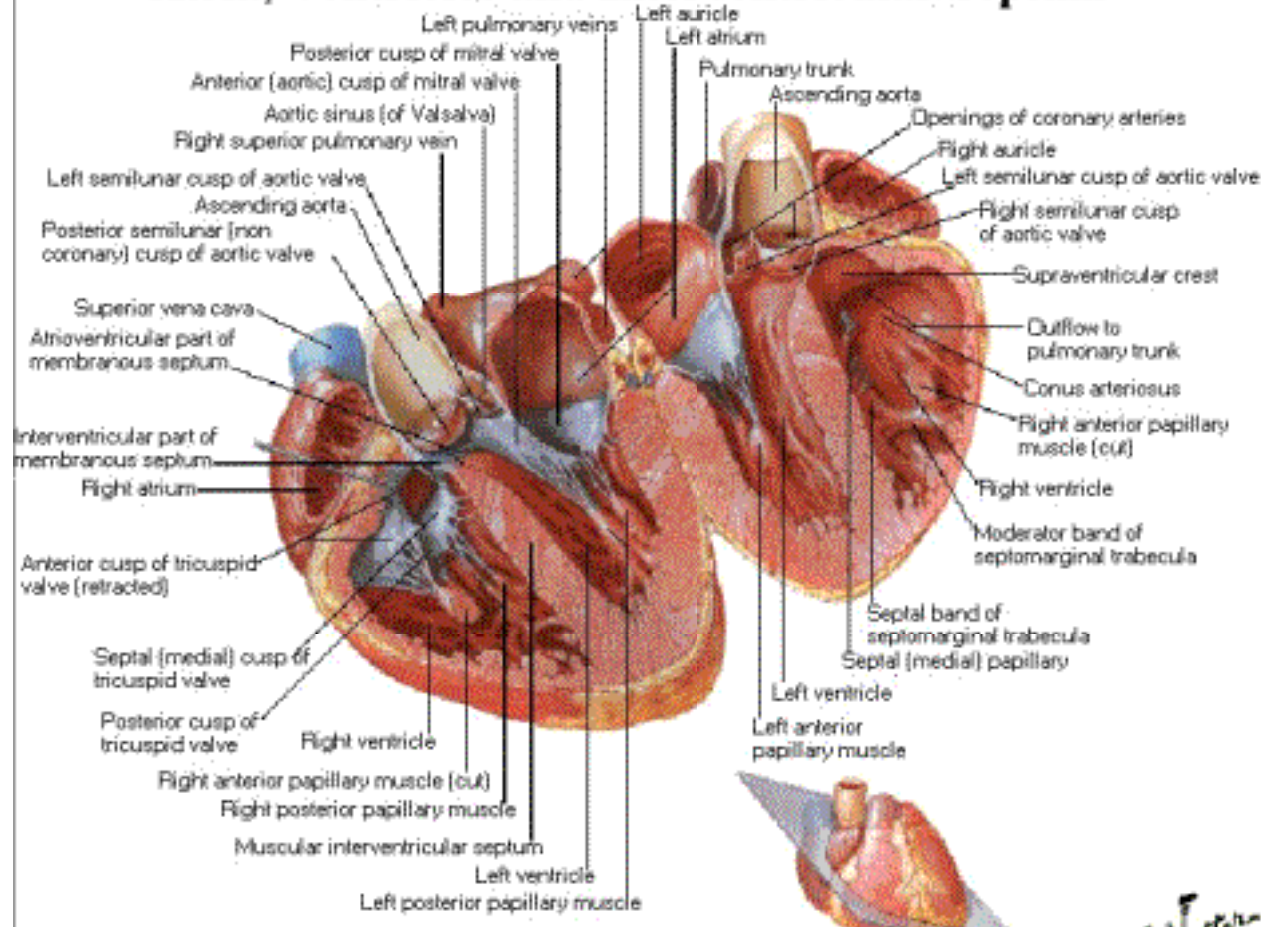
Tricuspid [Right Atrioventricular] Valve



Mitral [Left Atrioventricular] Valve



Atria, Ventricles and Interventricular Septum



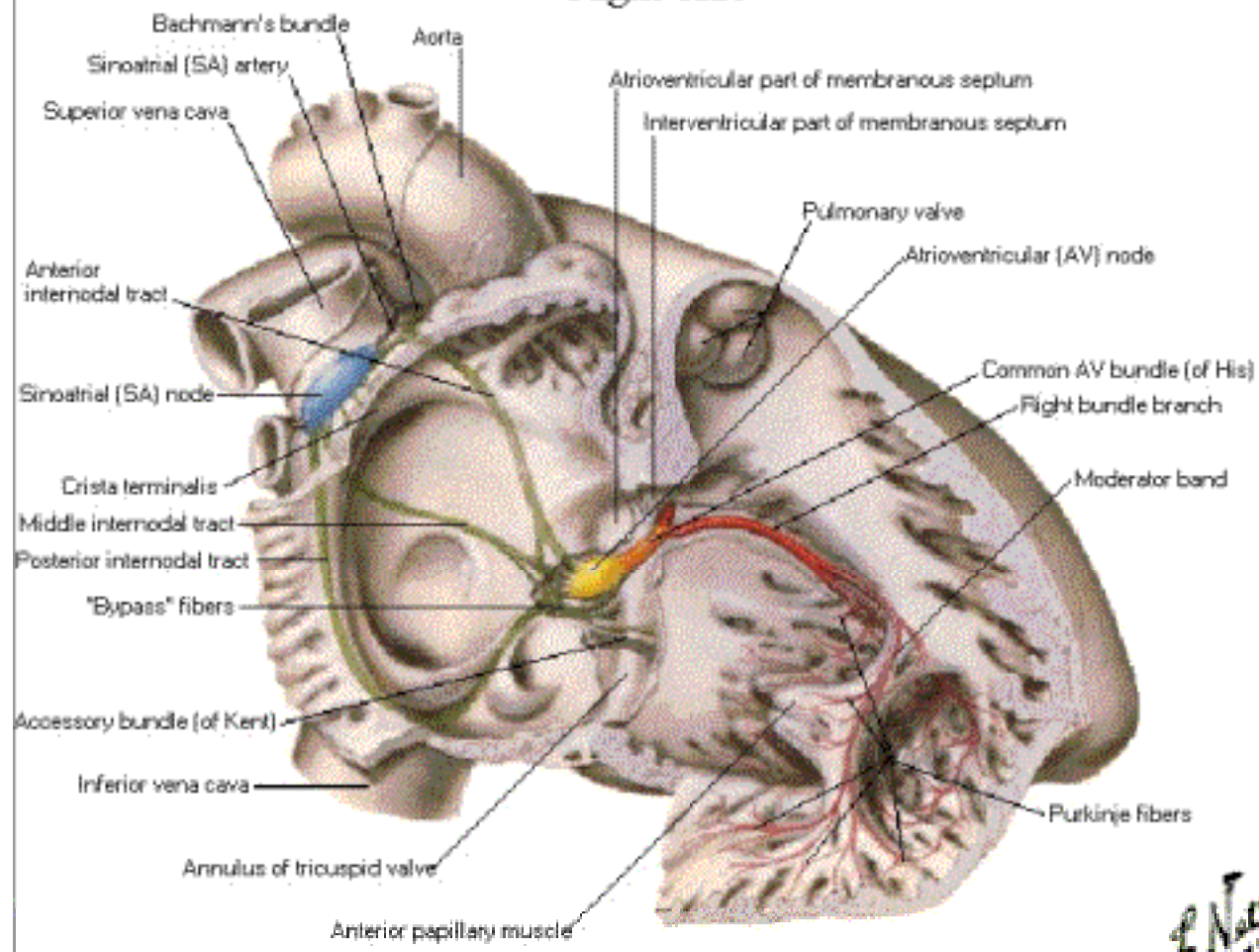
Note: broken line indicates line of attachment of septal leaflet of tricuspid valve.

Plane of section



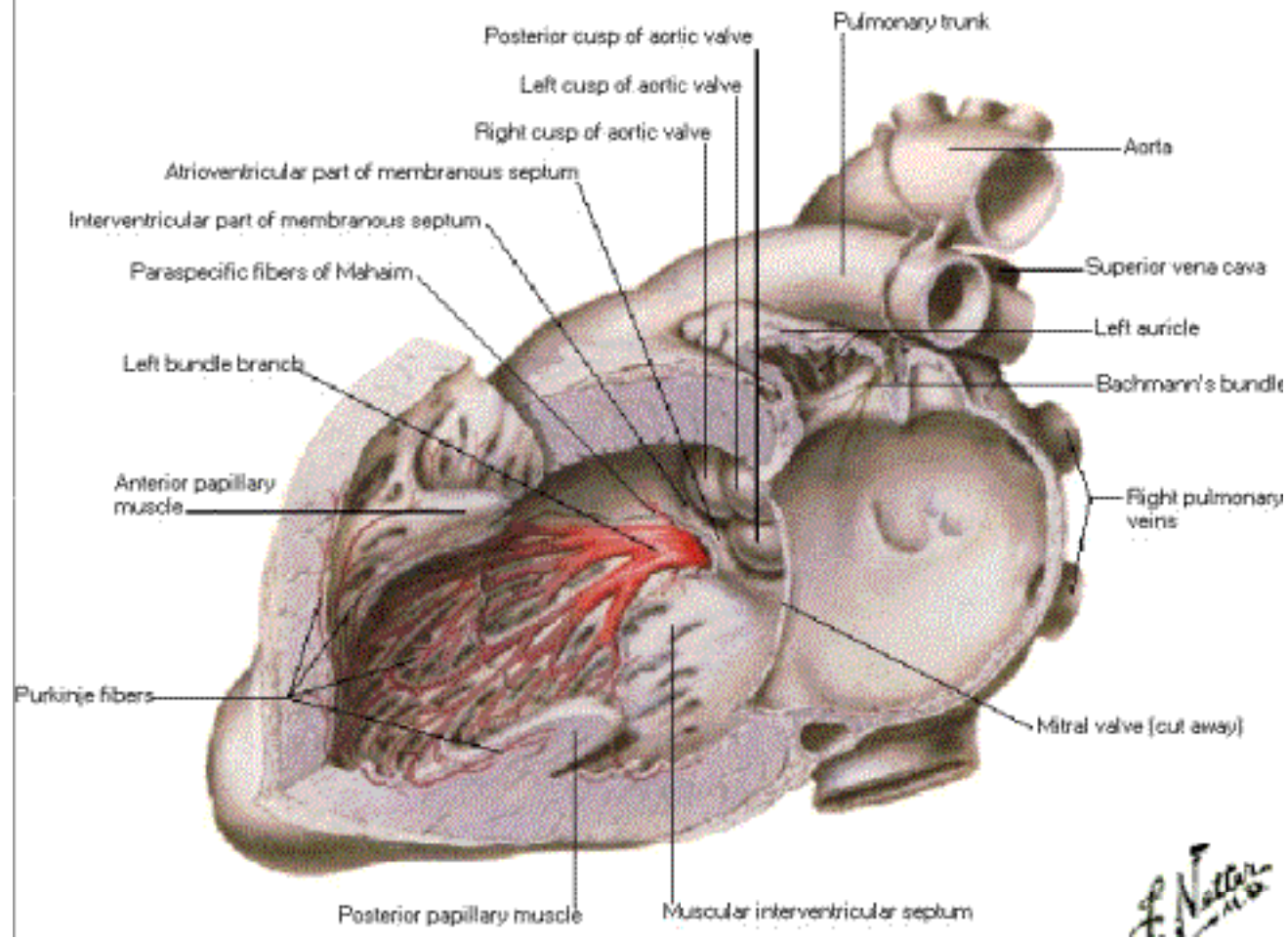
Conduction System of Heart

Right Side

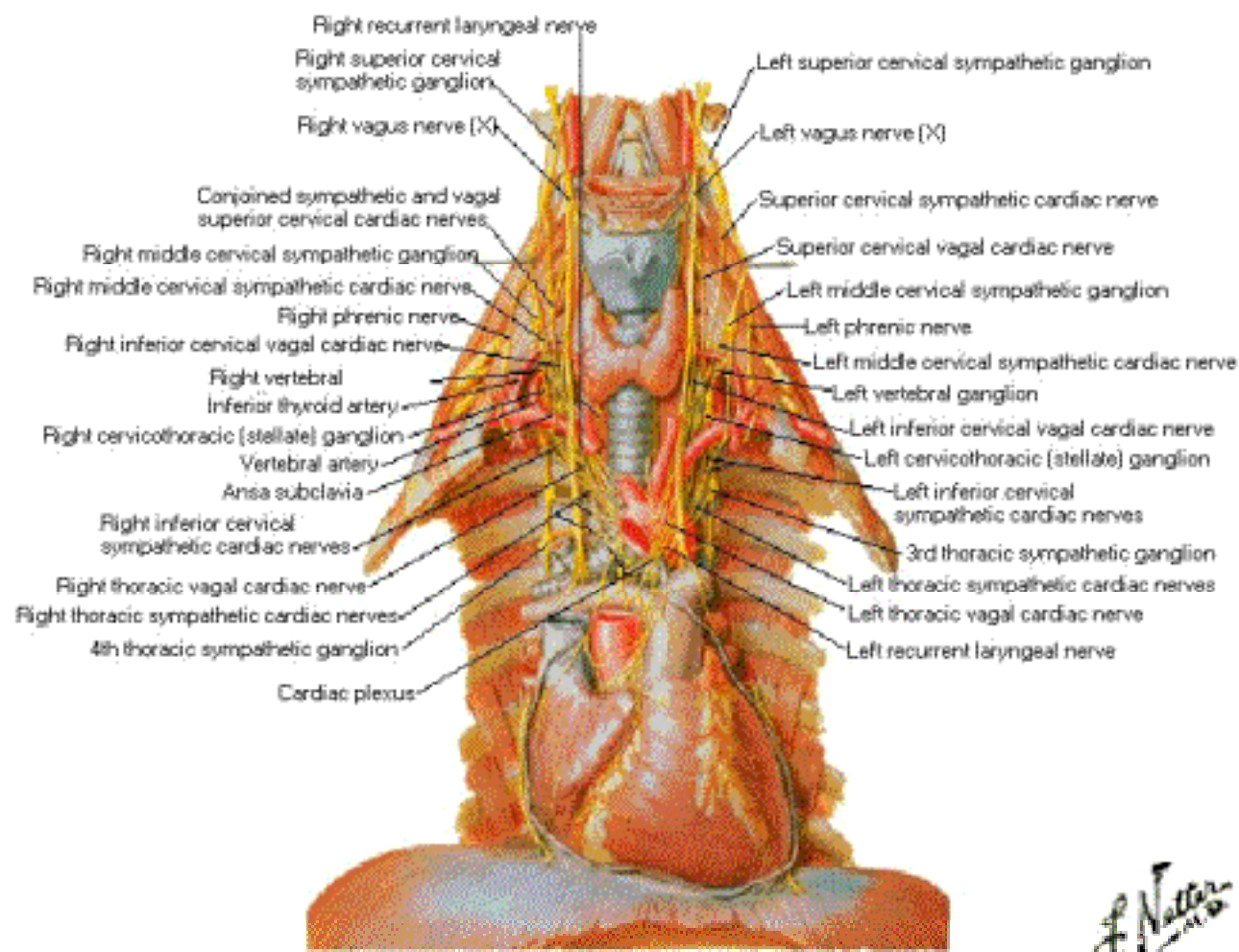


Conduction System of Heart

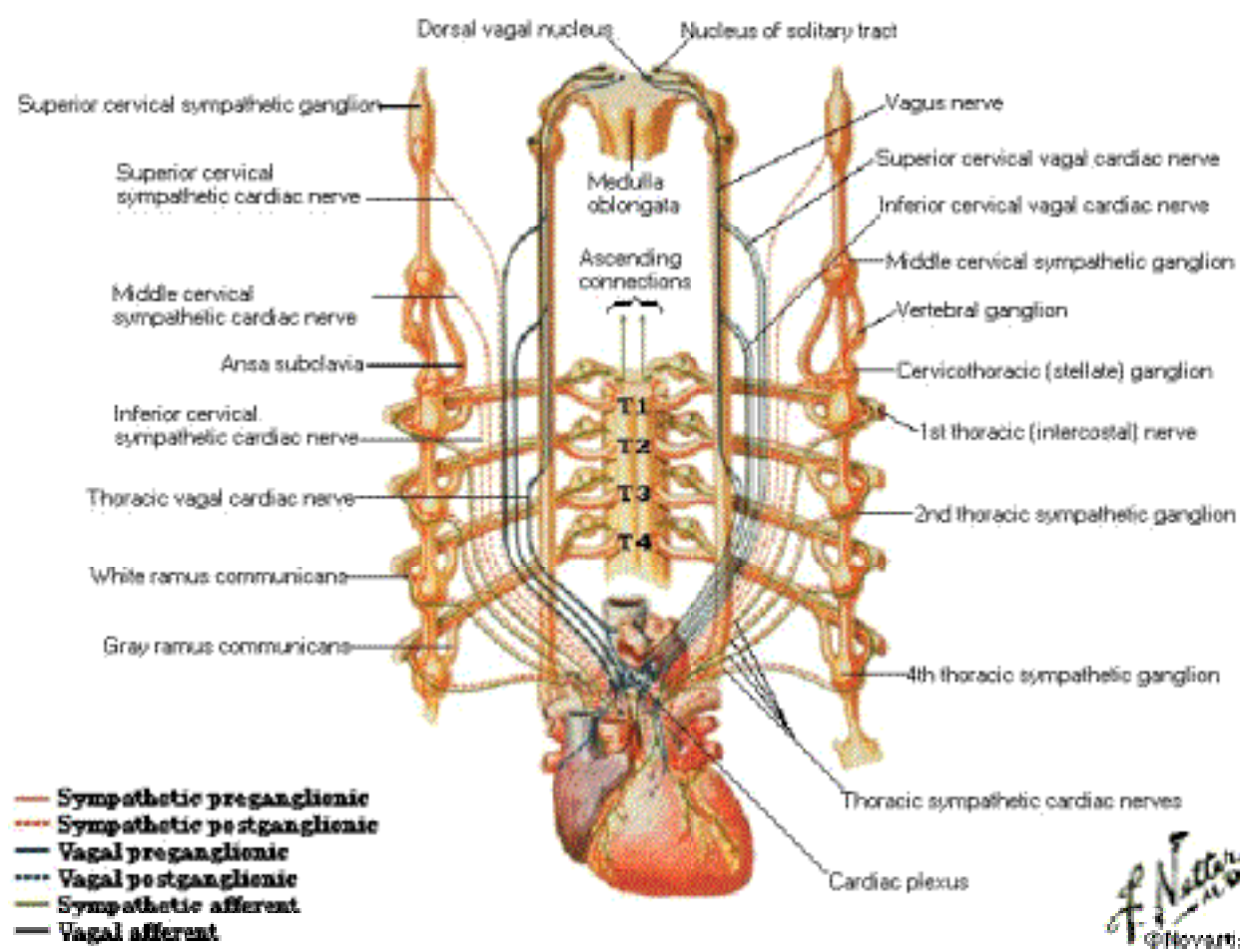
Left Side



Nerves of Heart

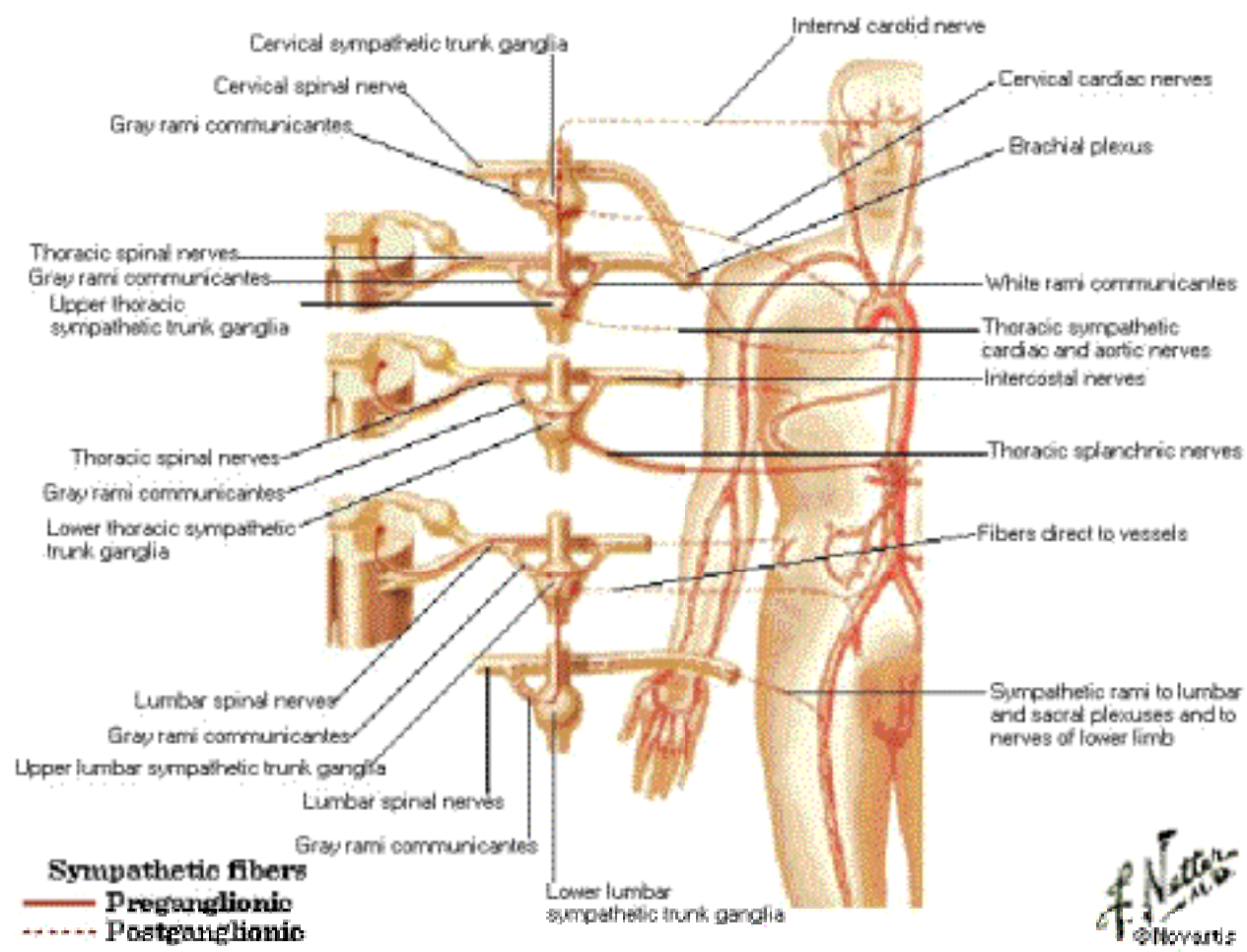


Innervation of Heart Schema

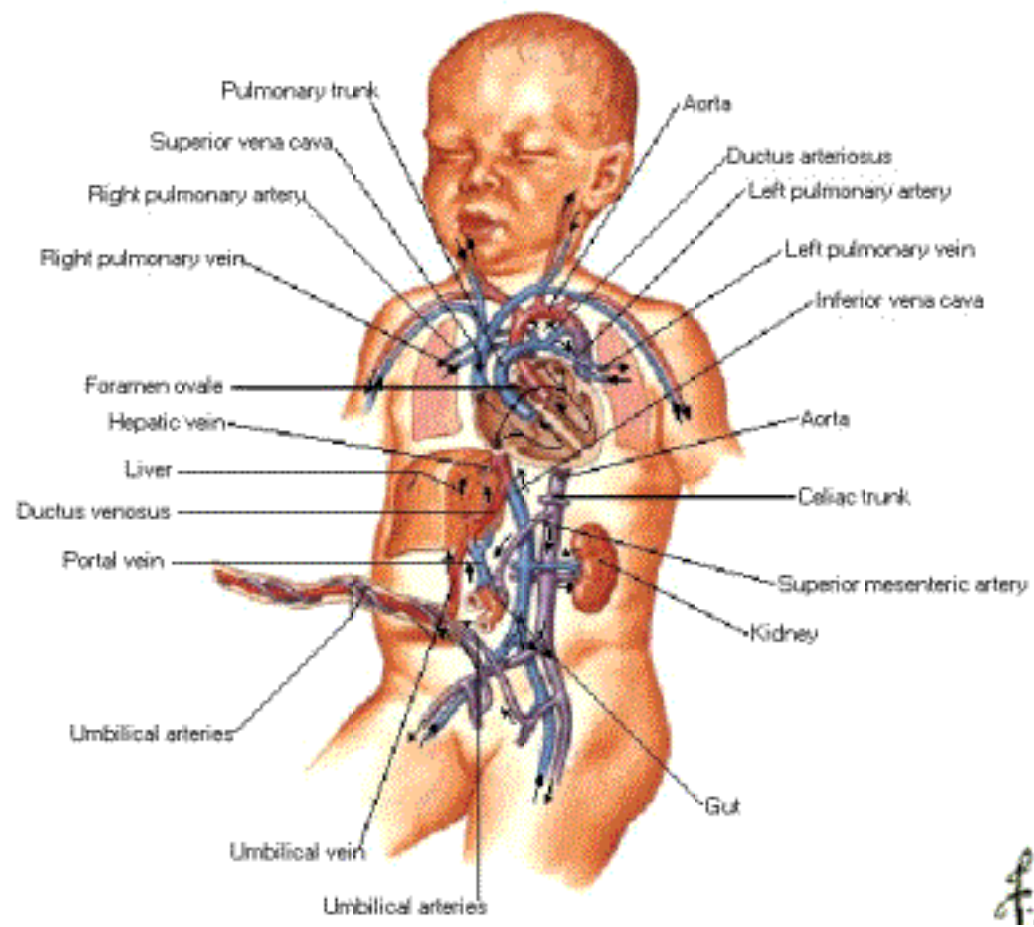


Innervation of Blood Vessels

Schema

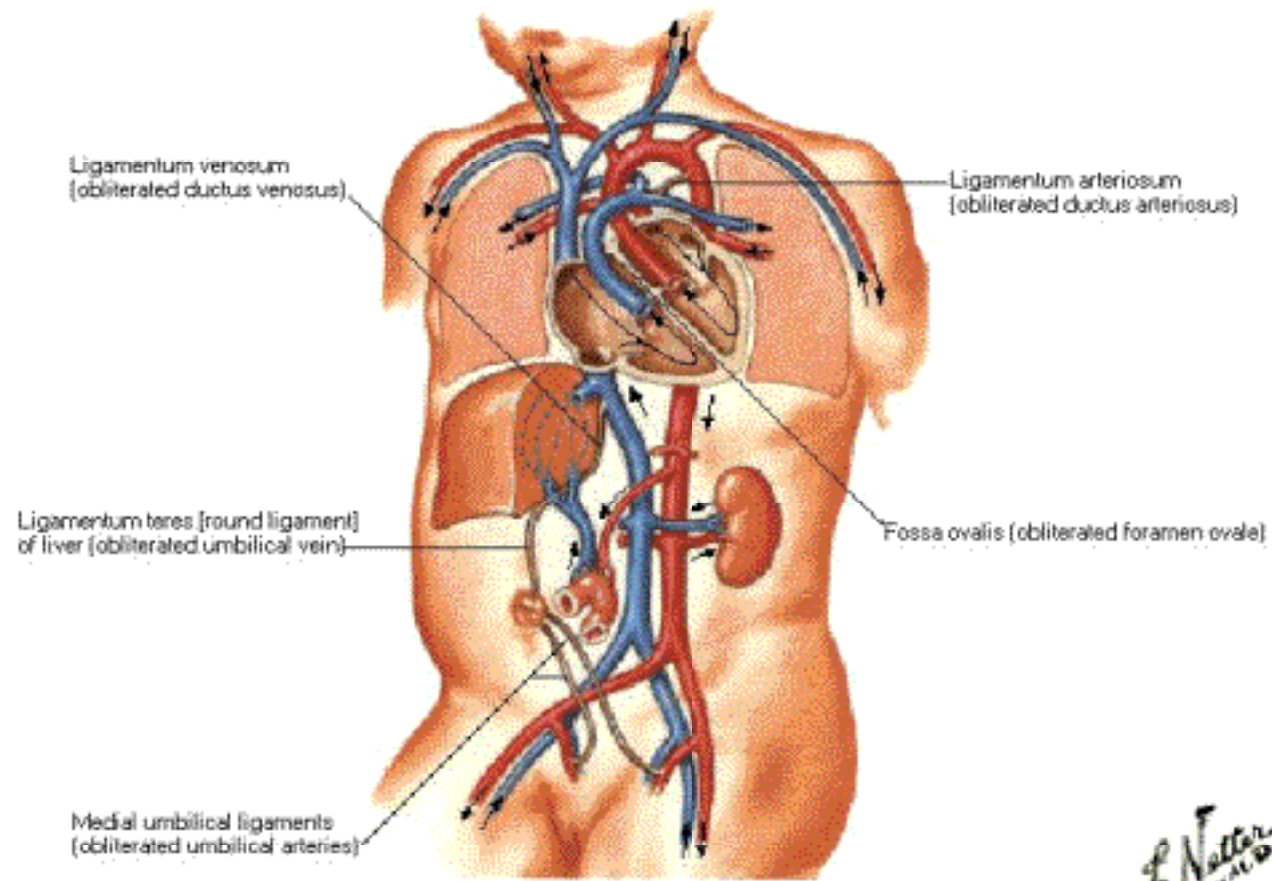


Prenatal Circulation



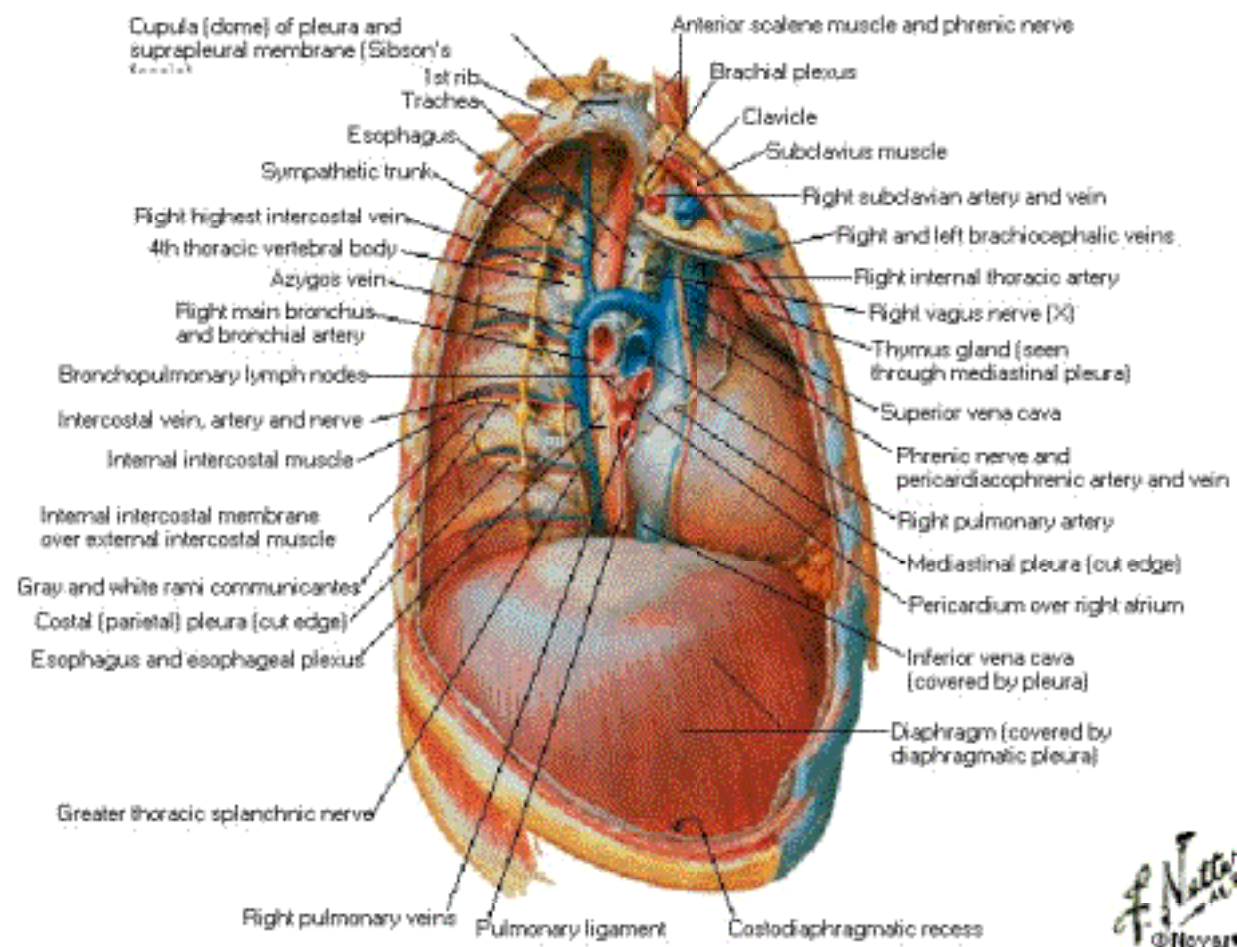
f.

Postnatal Circulation



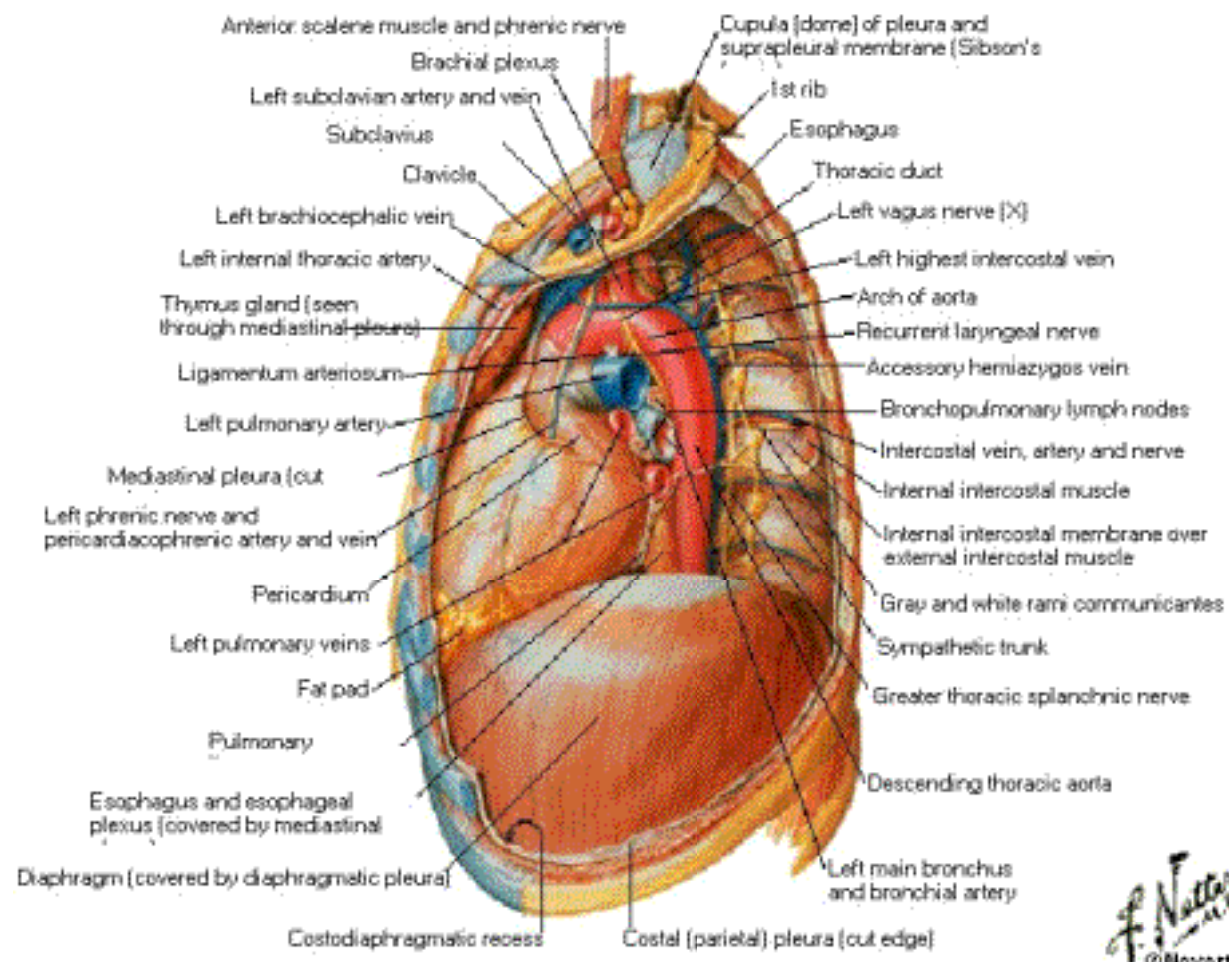
Mediastinum

Right Lateral View

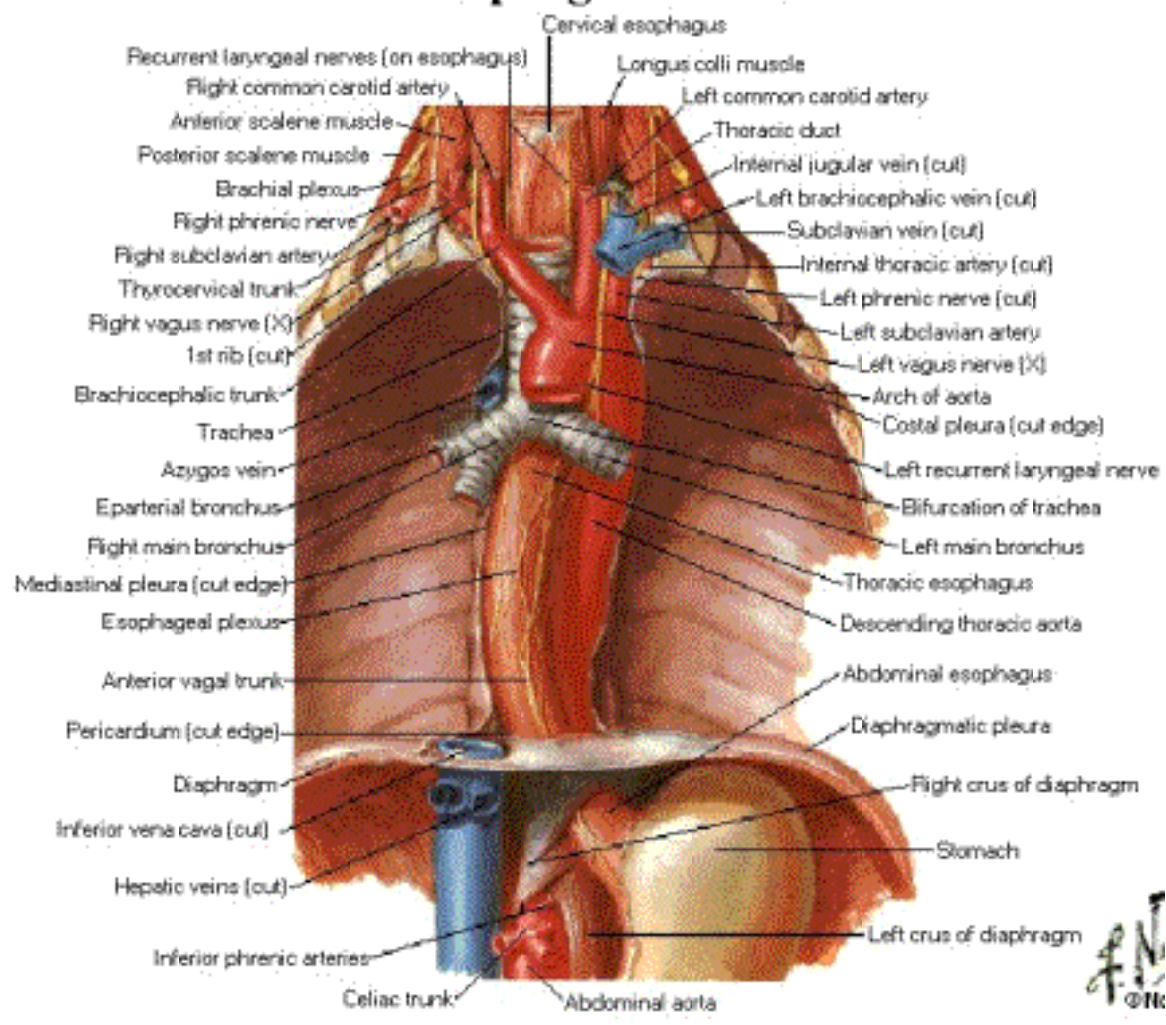


Mediastinum

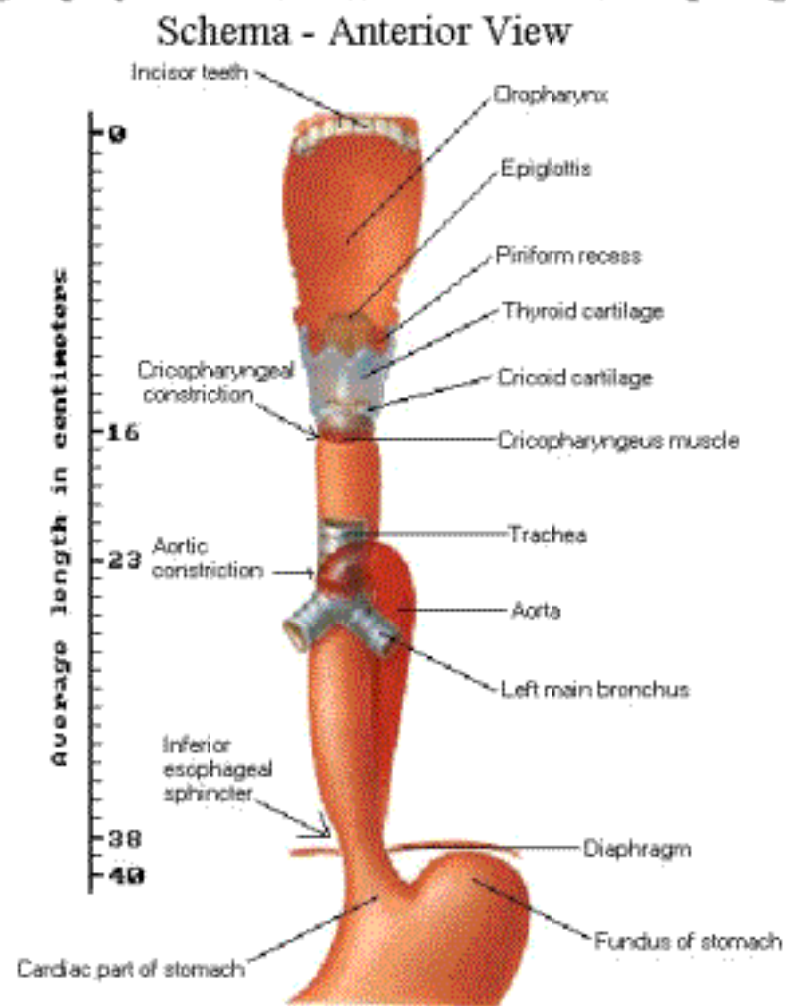
Left Lateral View



Esophagus in Situ

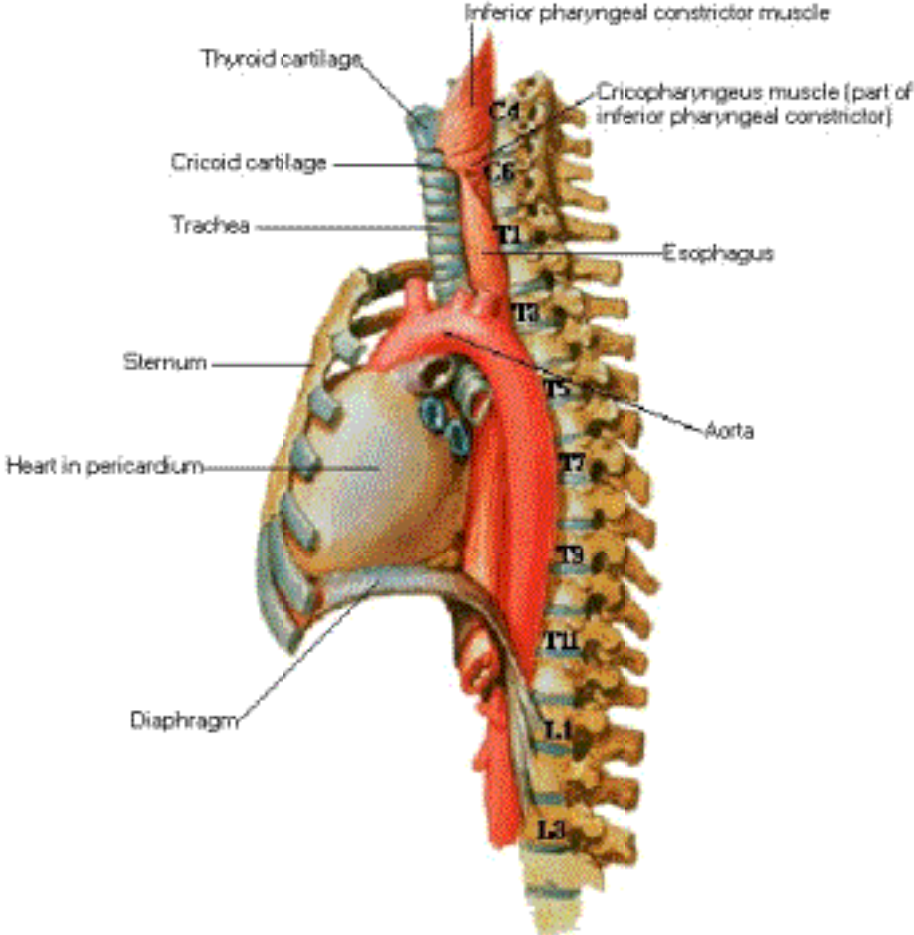


Topography and Constrictions of Esophagus

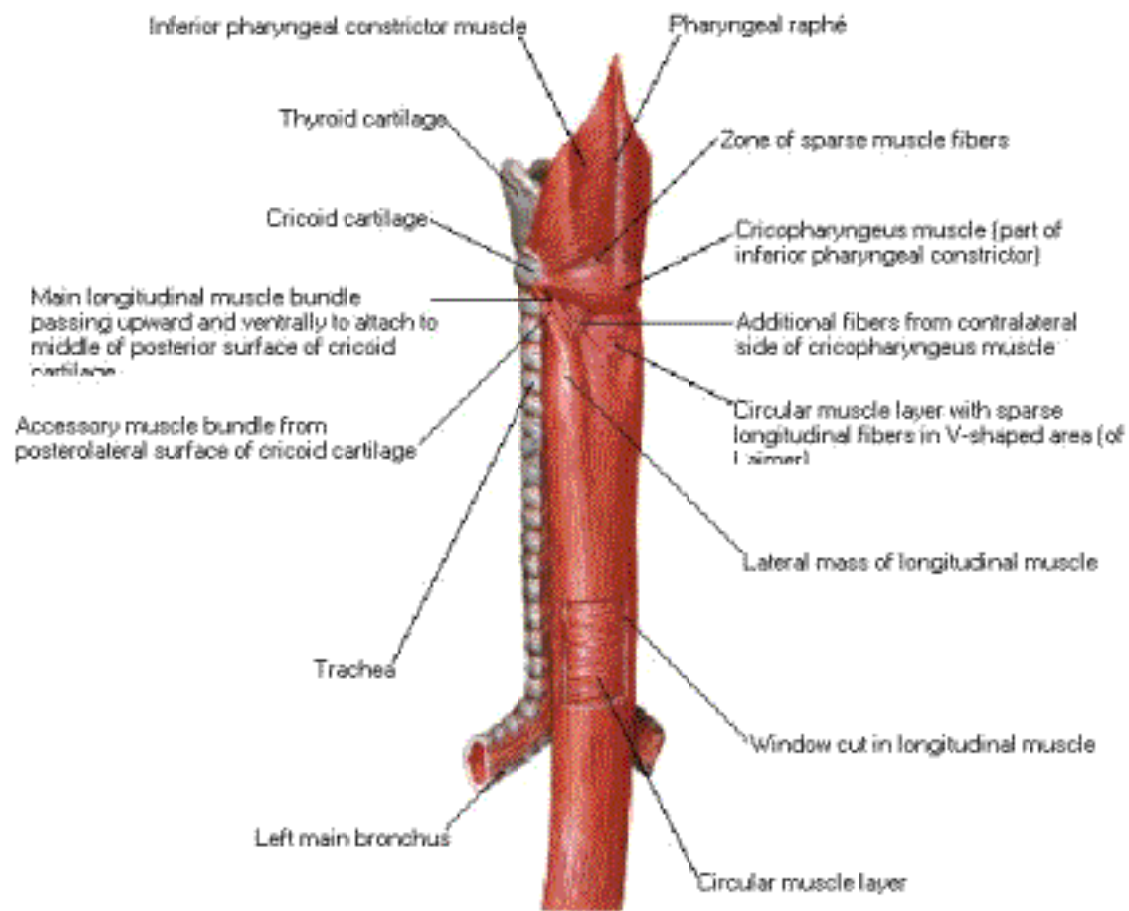


Topography and Constrictions of Esophagus

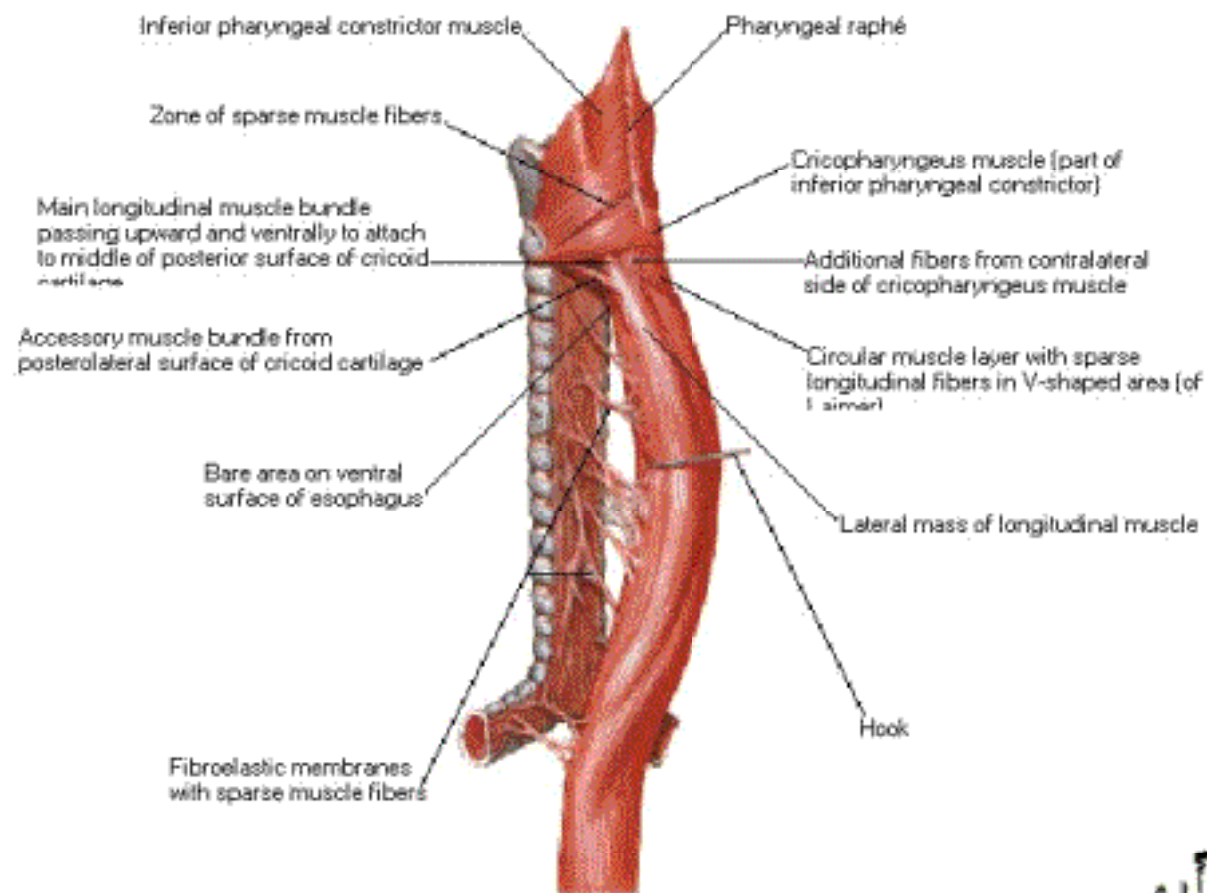
Lateral View



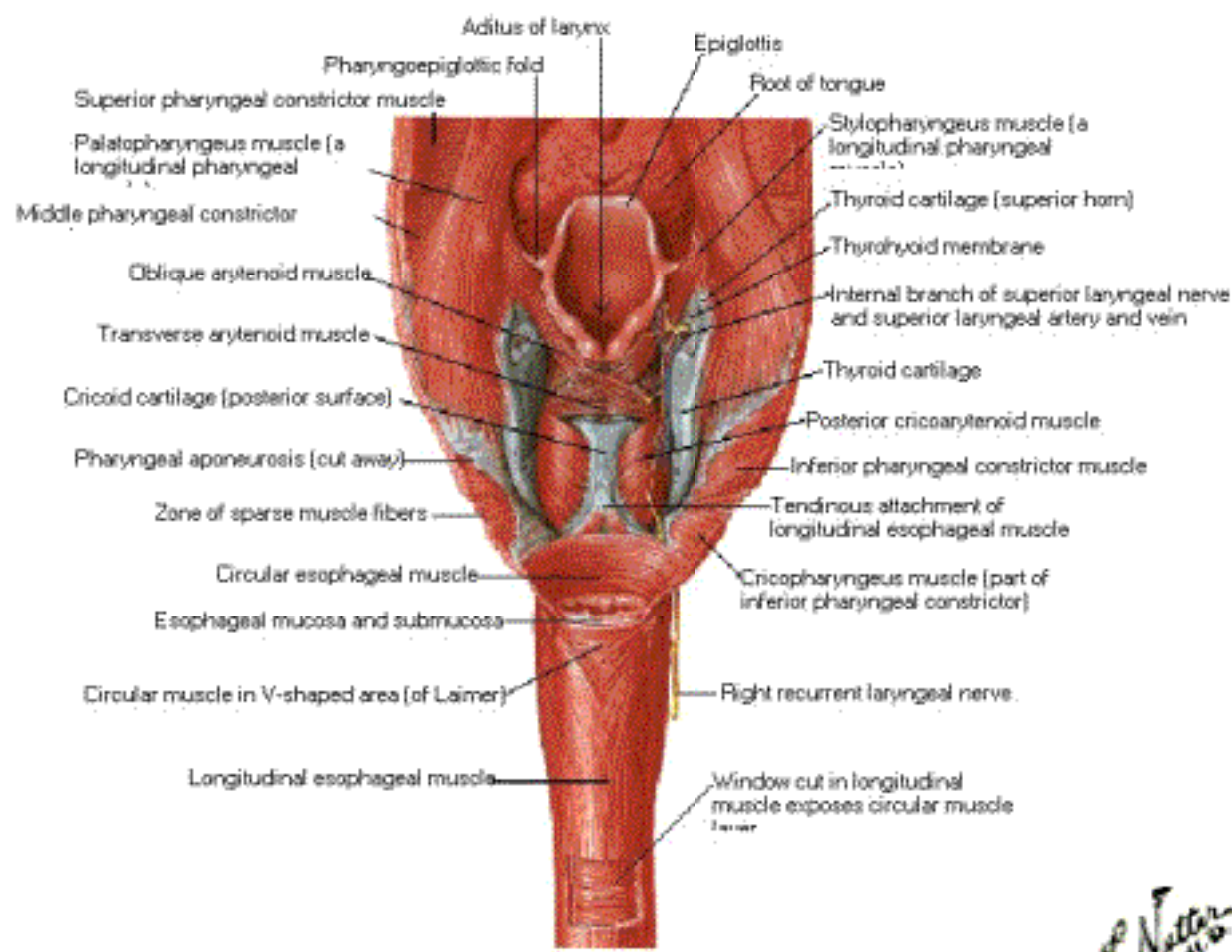
Musculature of Esophagus 1



Musculature of Esophagus 2



Pharyngoesophageal Junction

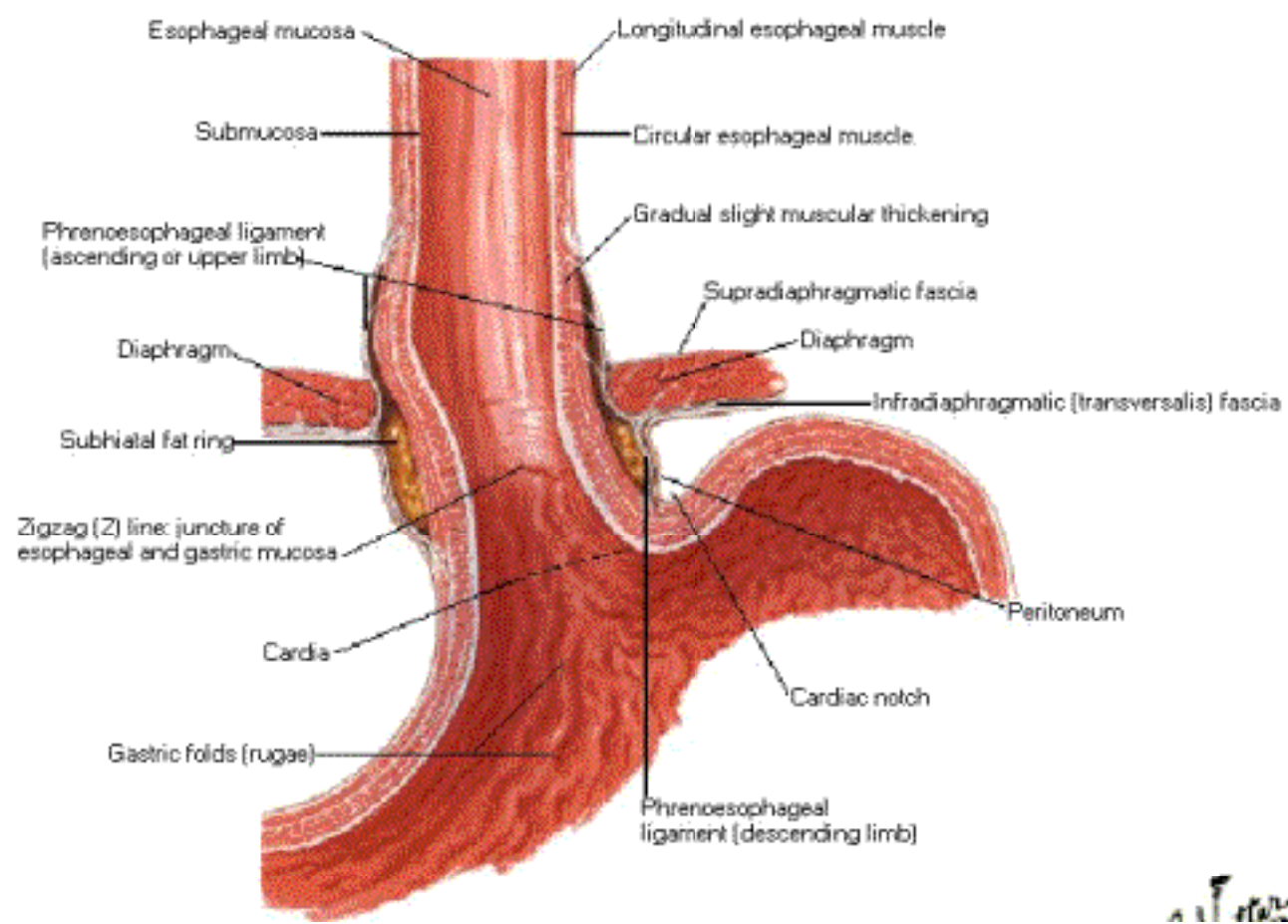


Posterior view with pharynx opened and mucosa removed

F. Netter M.D.
 © Novartis

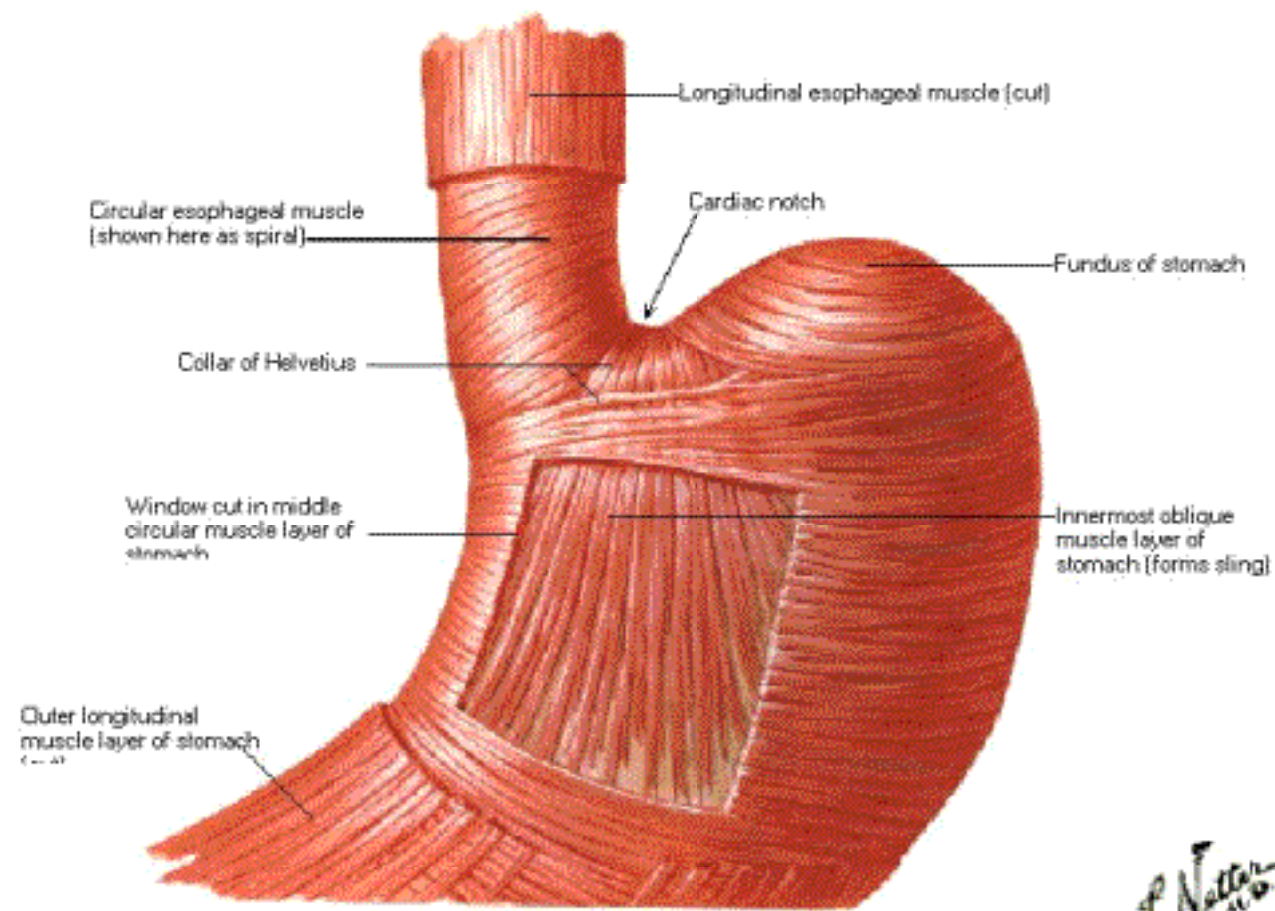
Esophagogastric Junction

Coronal Section

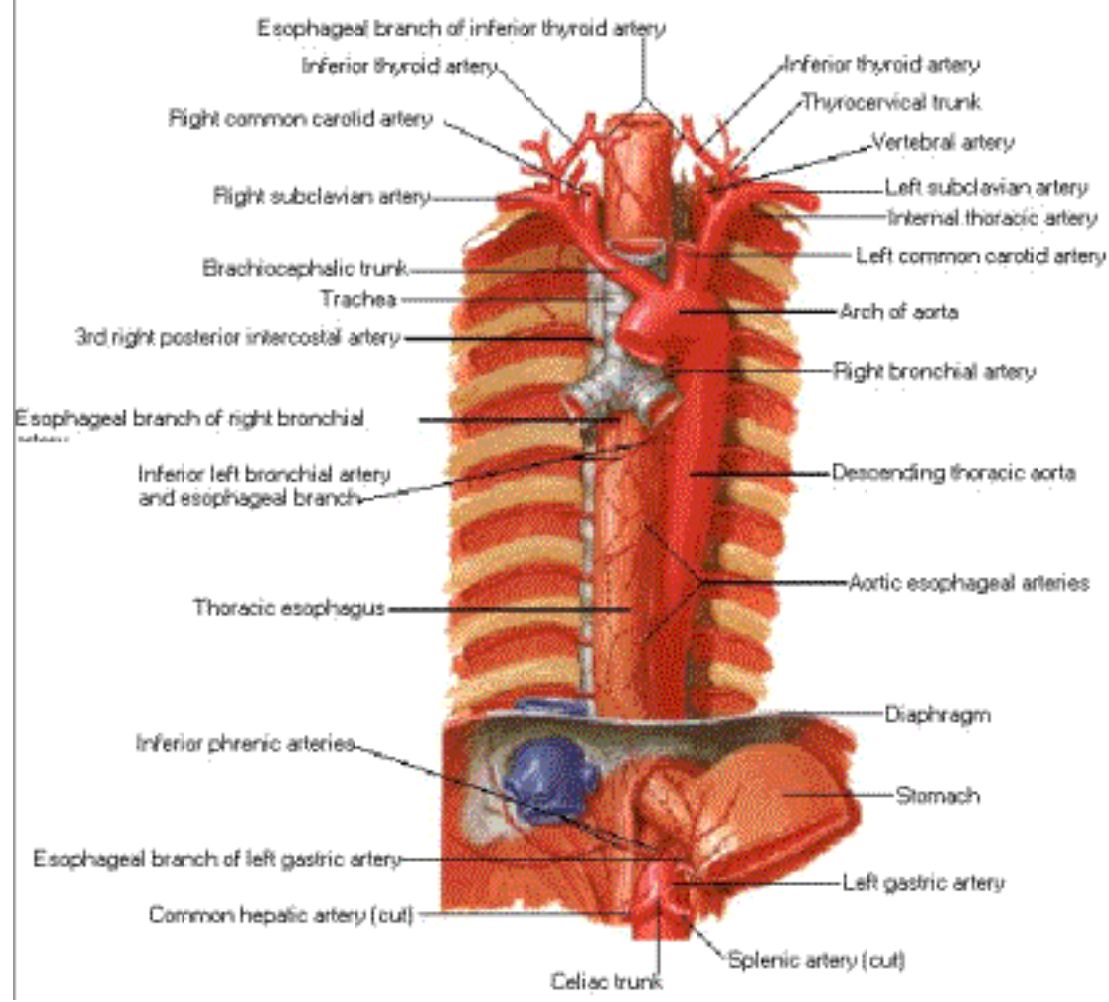


Esophagogastric Junction

Anterior View

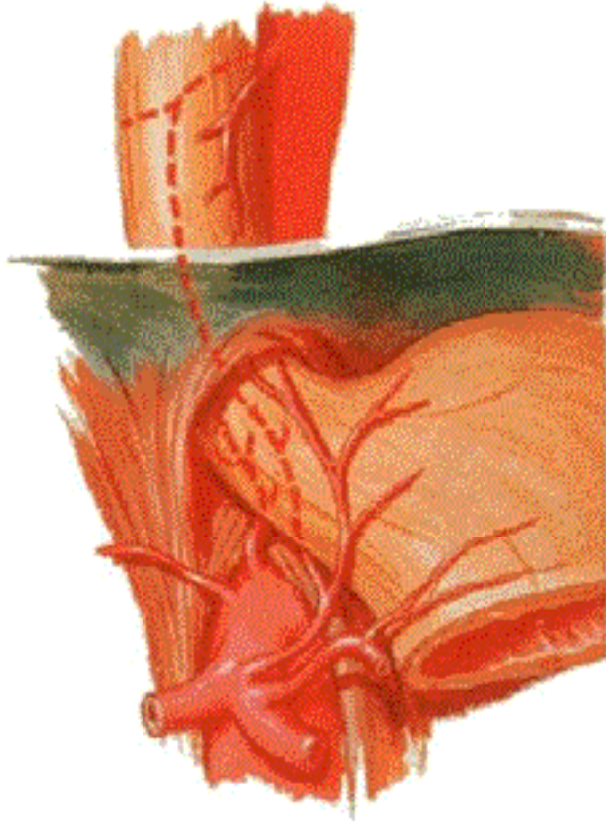


Arteries of Esophagus



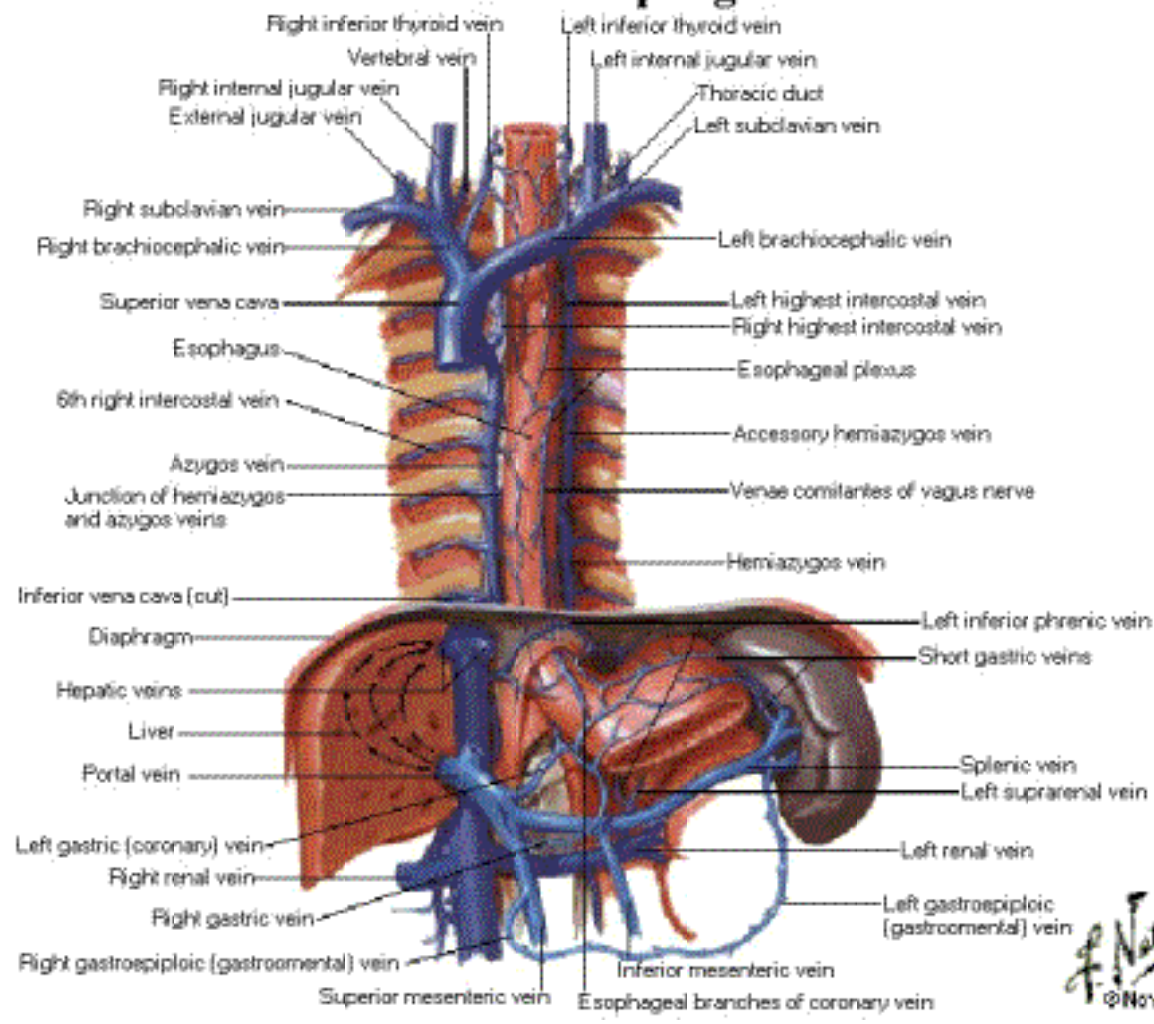
Arteries of Esophagus

Variations



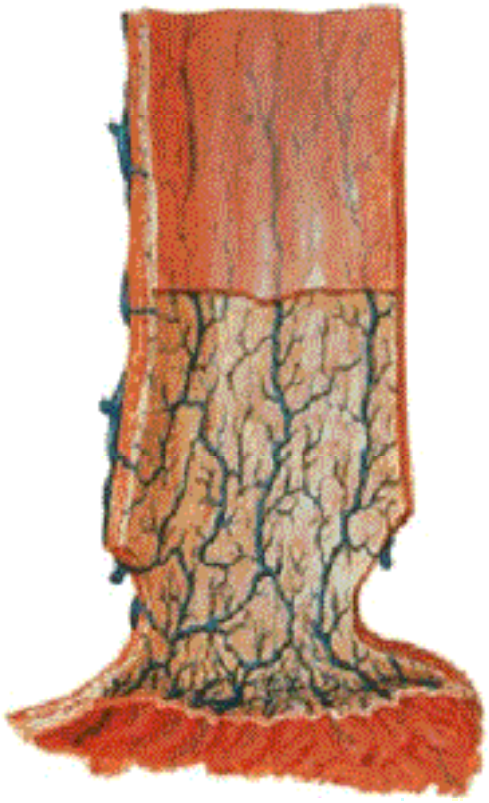Common variations: Esophageal branches may originate from left inferior phrenic artery and/or directly from celiac trunk. Branches to abdominal esophagus may also come from splenic or short gastric arteries.

Veins of Esophagus

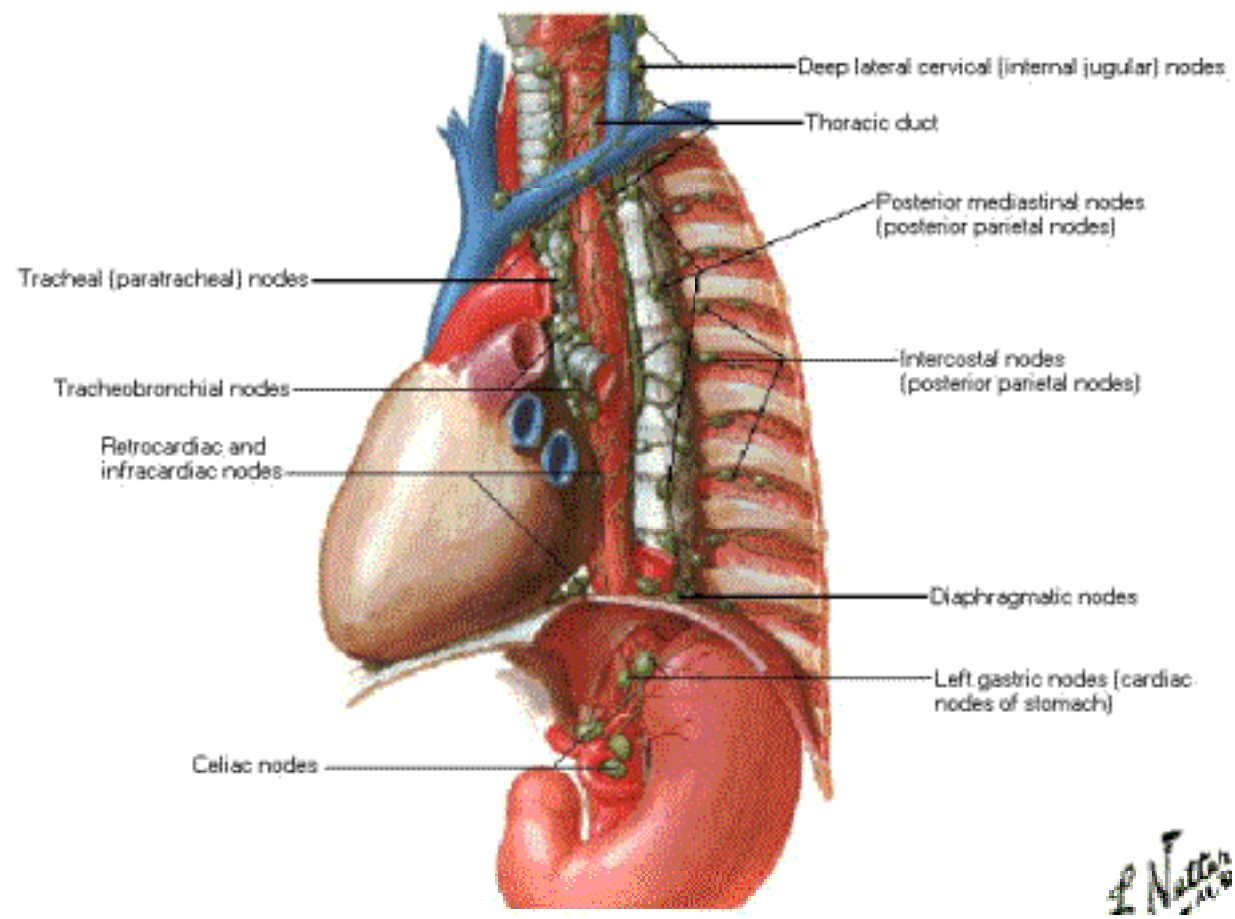


F. Net
© Nov

Veins of Esophagus
Submucous Venous Plexus

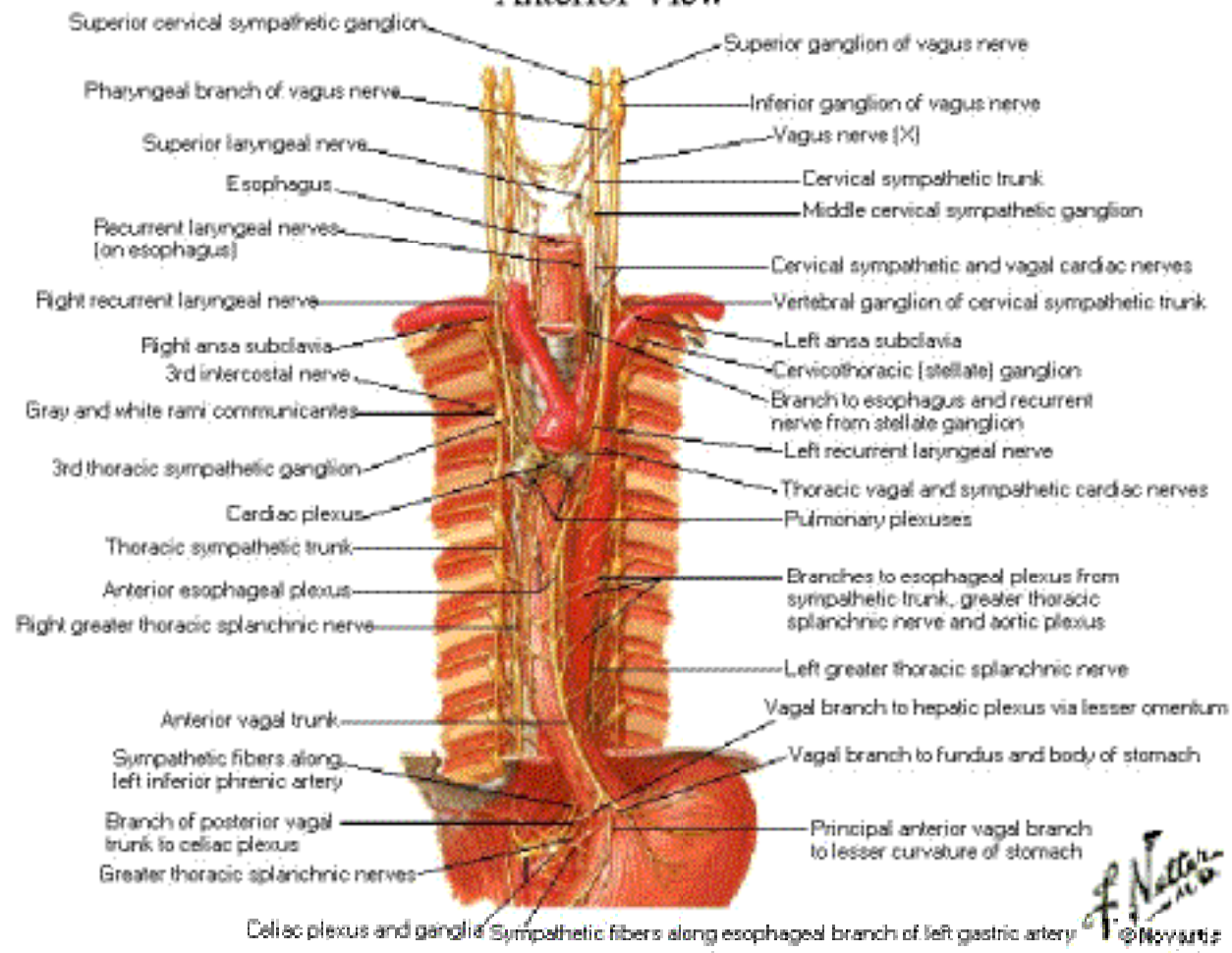


Lymph Vessels and Nodes of Esophagus



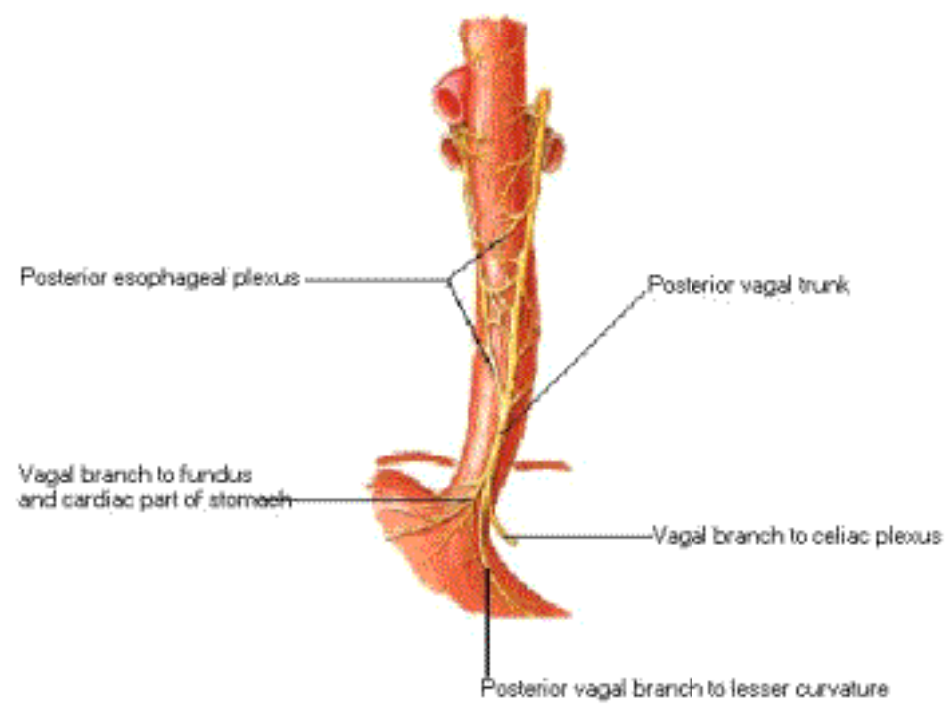
Nerves of Esophagus

Anterior View



Nerves of Esophagus

Posterior View



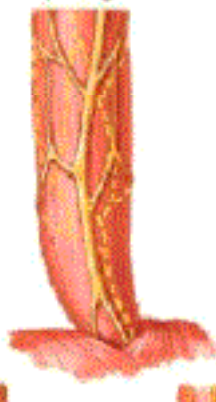Nerves of Esophagus

Variations

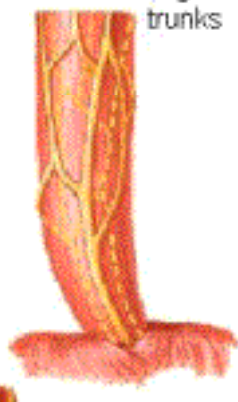Multiple anterior vagal trunks



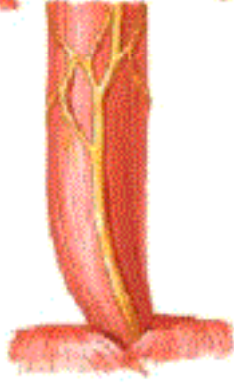Single anterior vagal trunk divides just above diaphragm



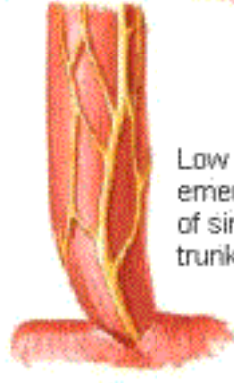
Multiple posterior vagal trunks



High emergence of single trunk

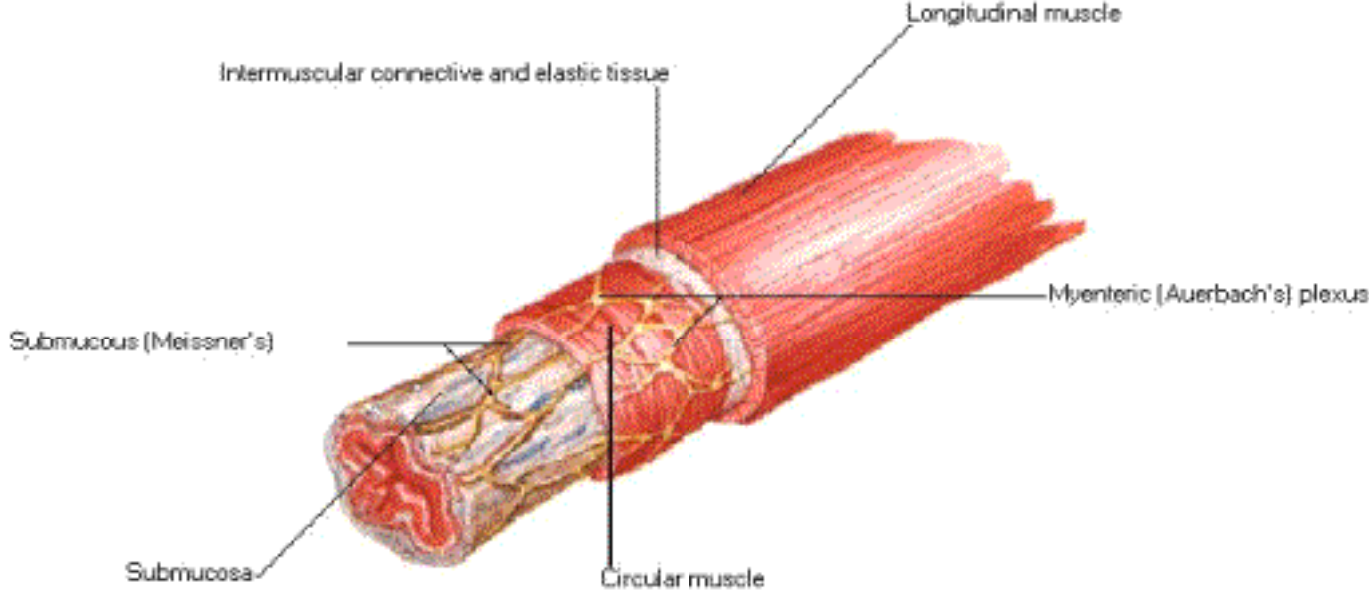


Low emergence of single trunk



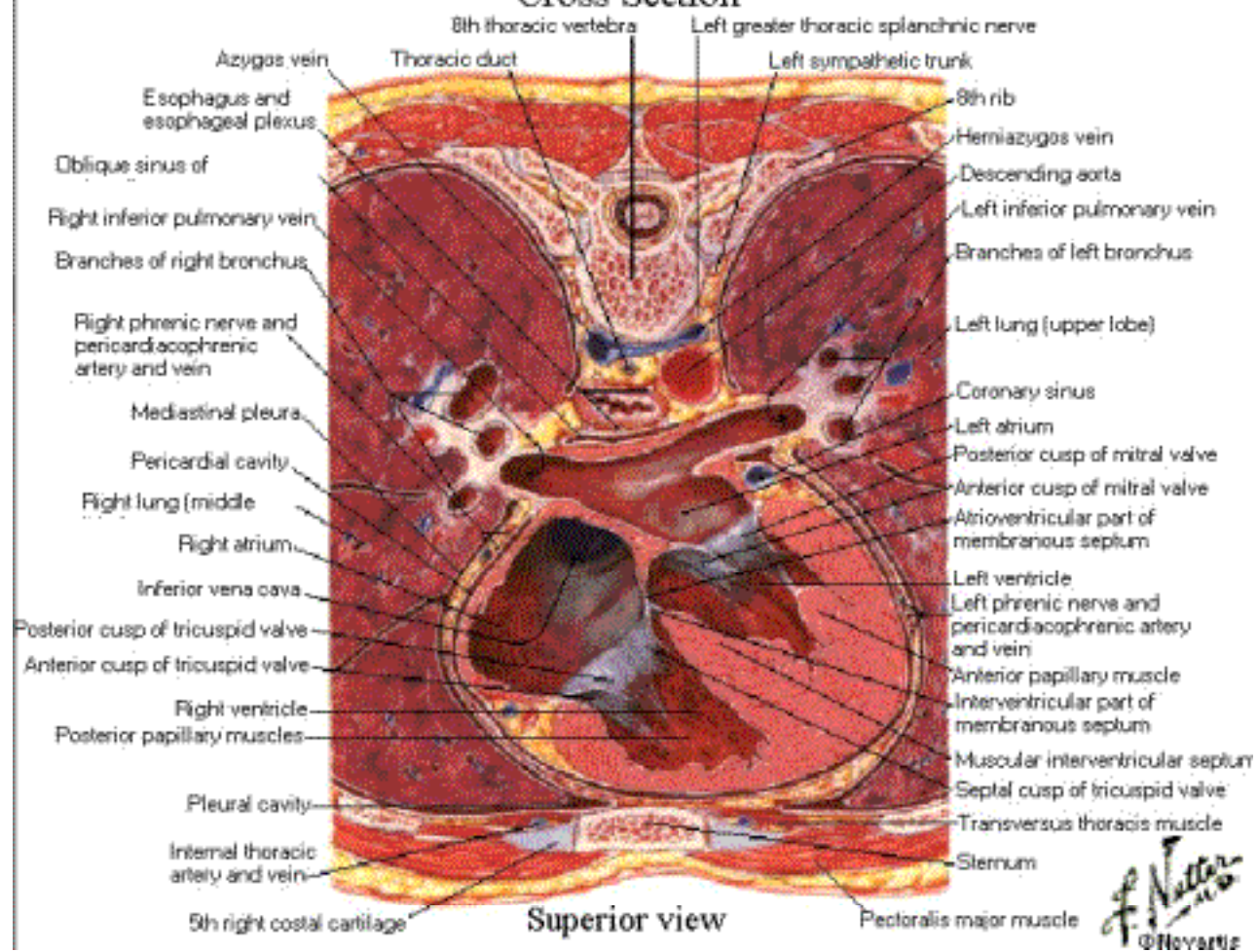
Intrinsic Nerves of Esophagus

Schema

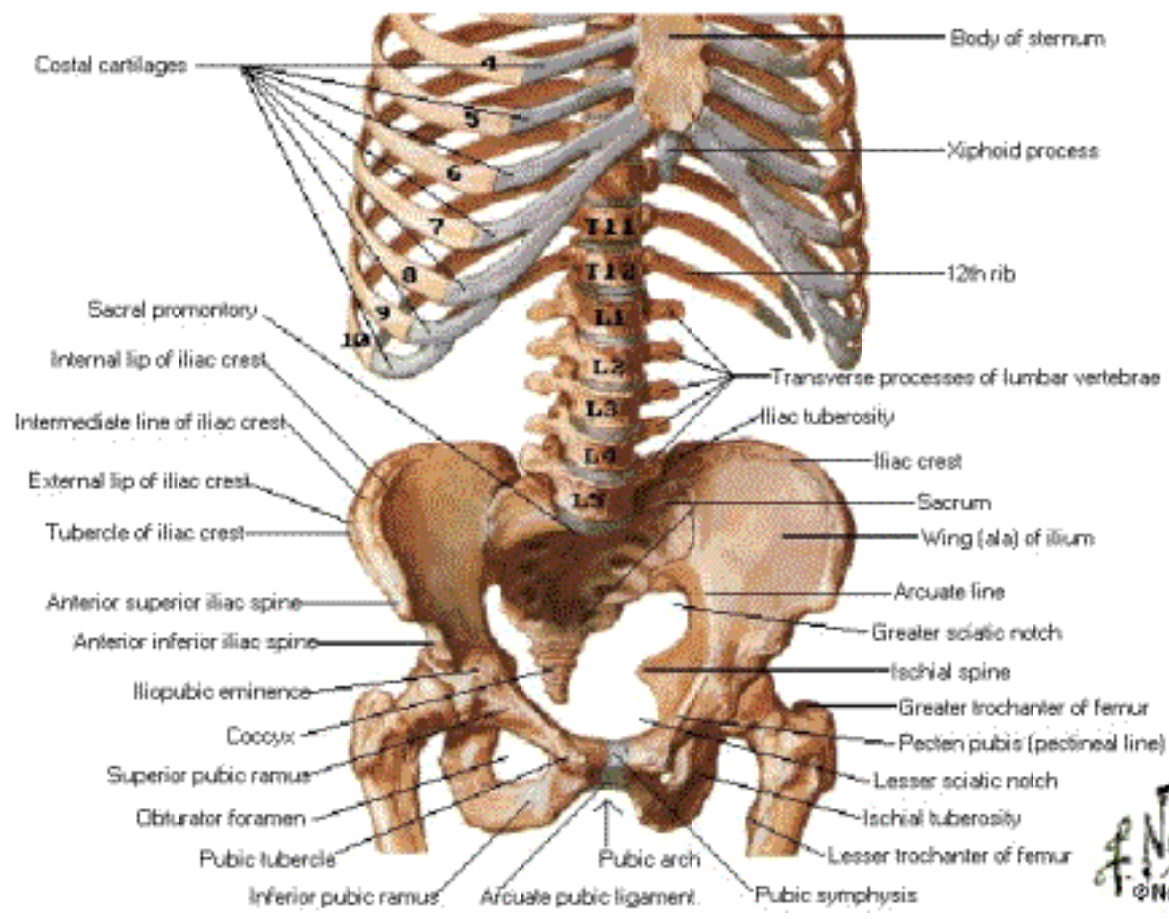


Mediastinum

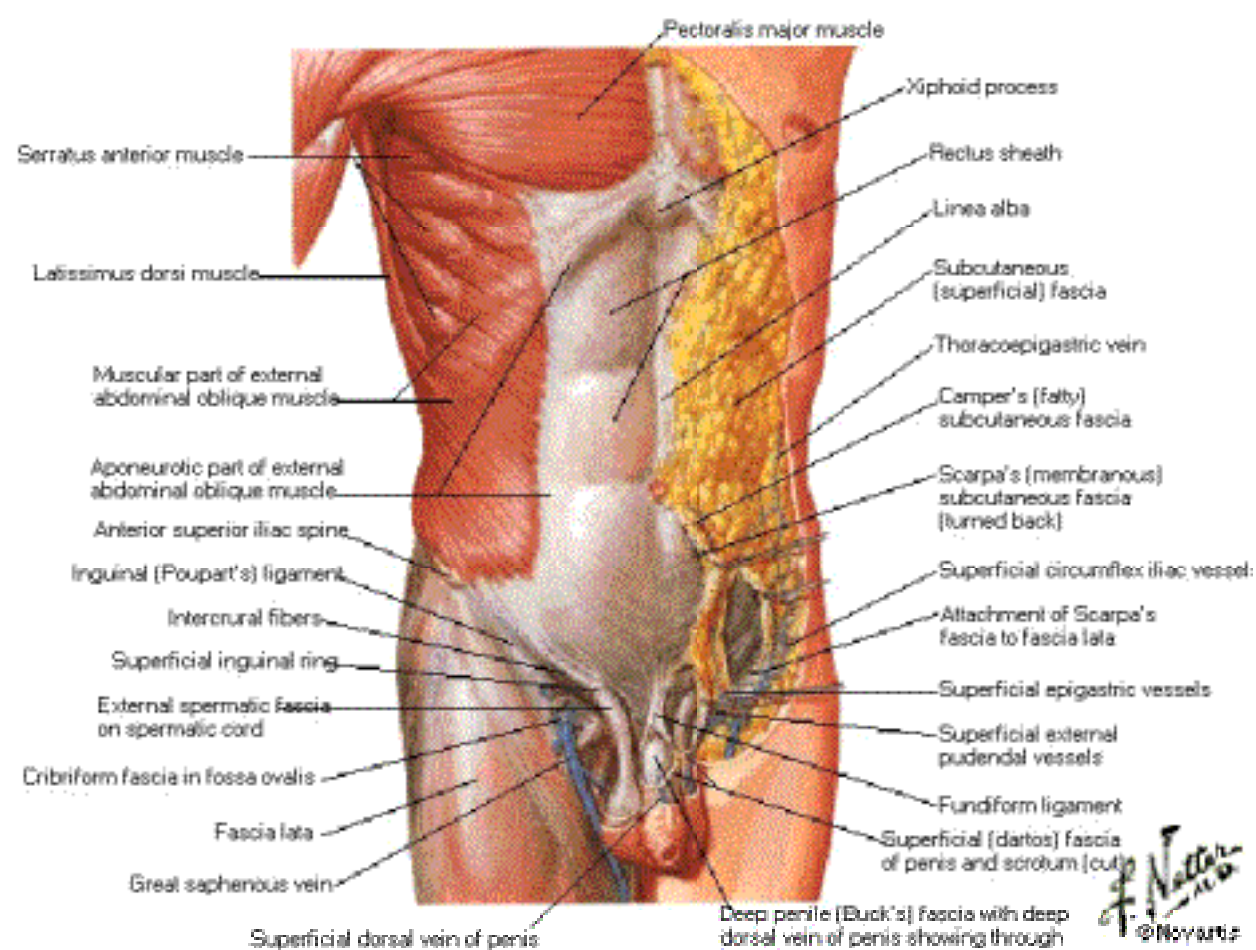
Cross Section



Bony Framework of Abdomen

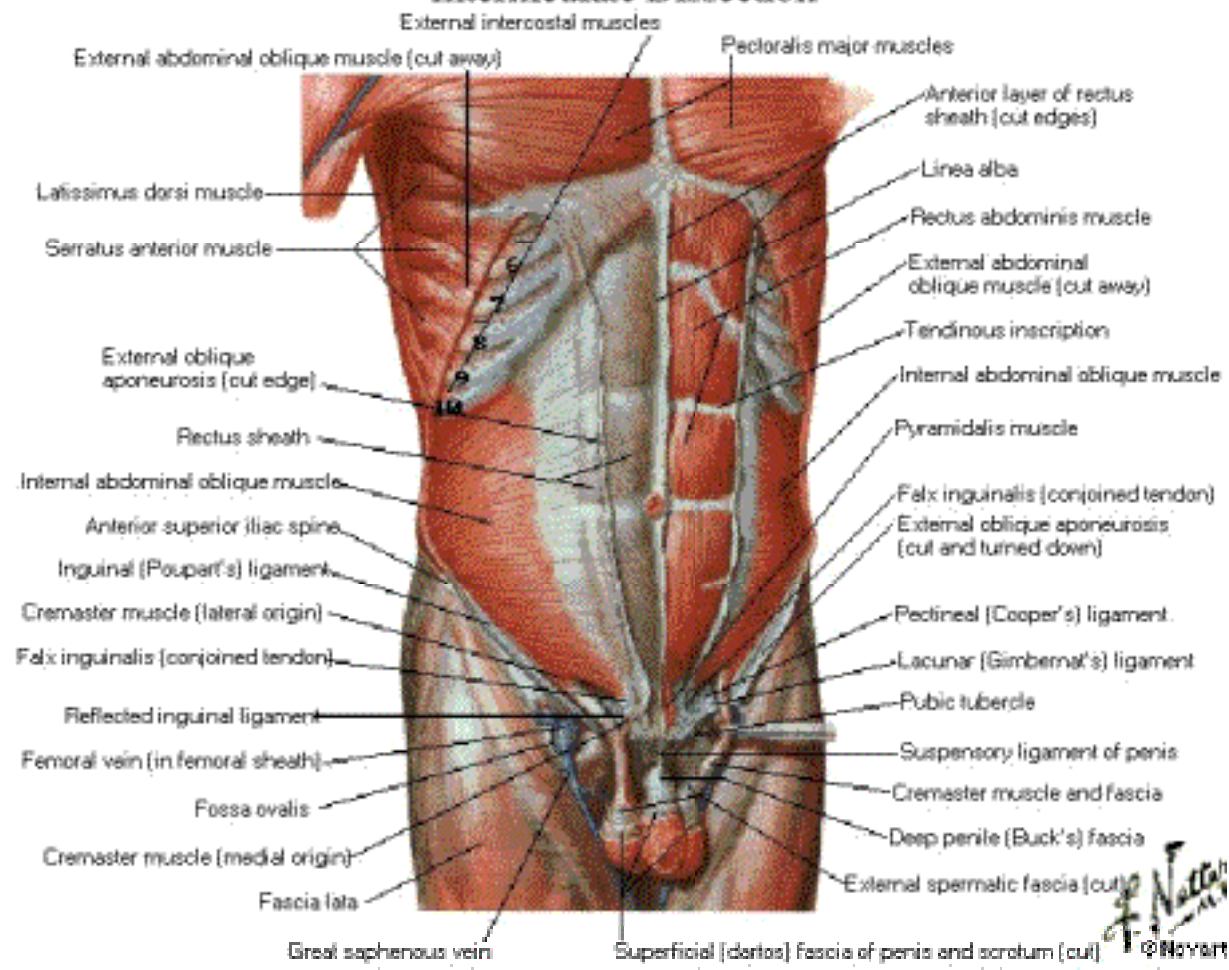


Anterior Abdominal Wall Superficial Dissection

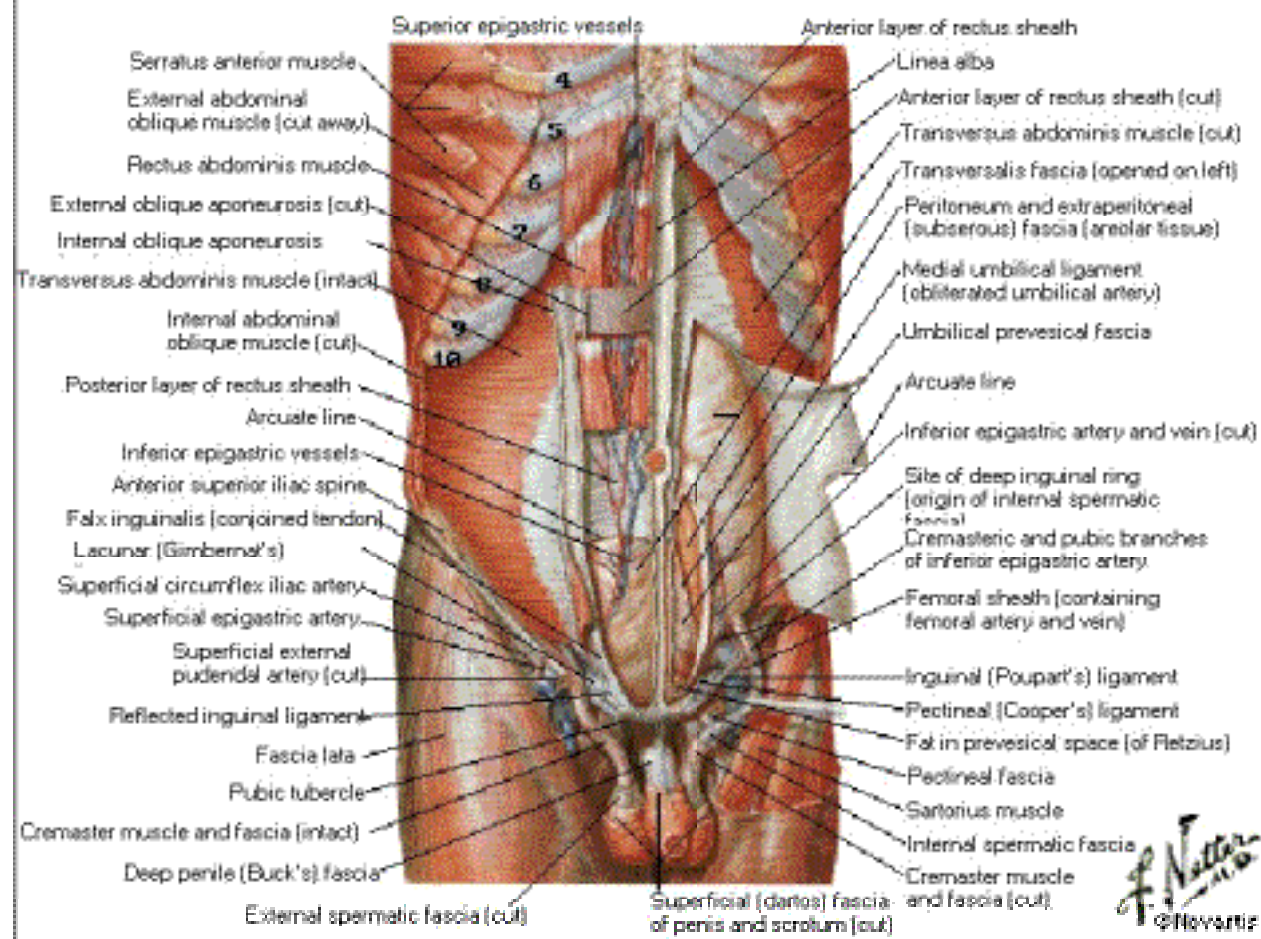


Anterior Abdominal Wall

Intermediate Dissection

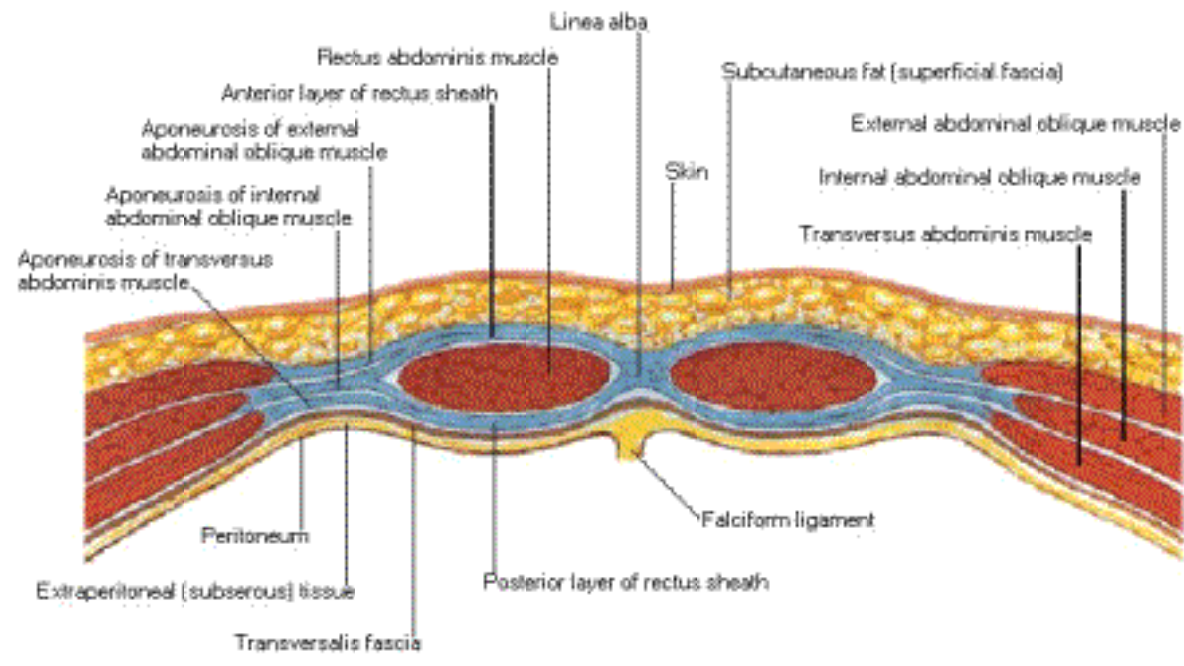


Anterior Abdominal Wall Deep Dissection



Rectus Sheath

Cross Section Above Arcuate Line

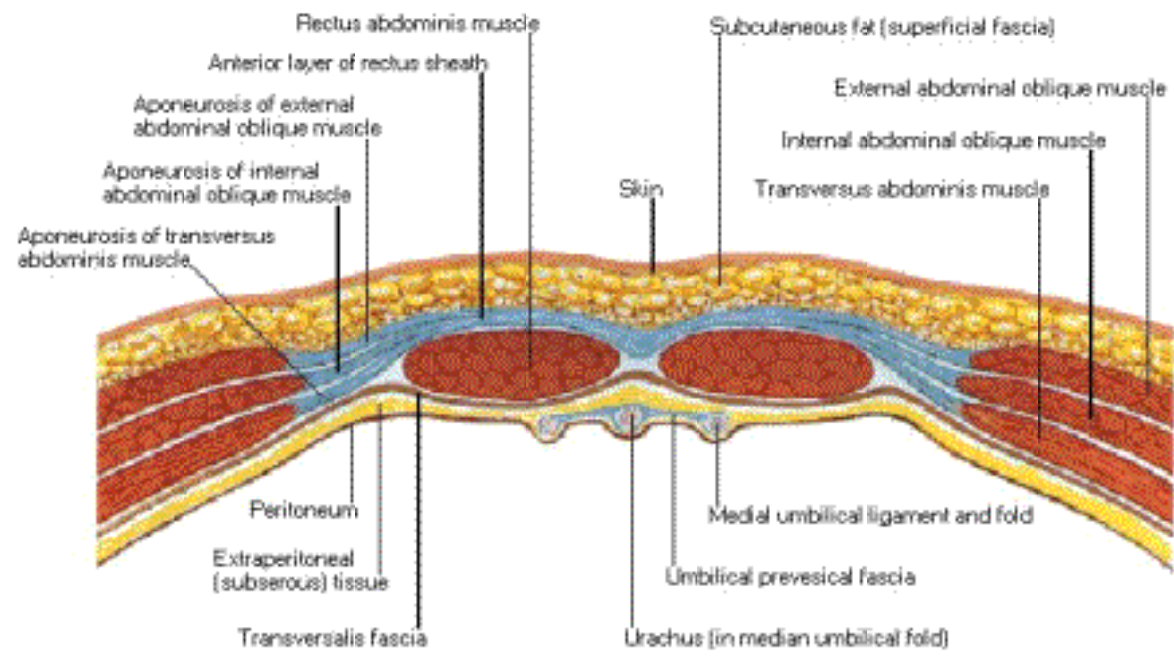


Aponeurosis of internal abdominal oblique muscle splits to form anterior and posterior layers of rectus sheath. Aponeurosis of external abdominal oblique muscle joins anterior layer of sheath; aponeurosis of transversus abdominis muscle joins posterior layer. Anterior and posterior layers of rectus sheath unite medially to form linea alba


Handwritten signature
©No.

Rectus Sheath

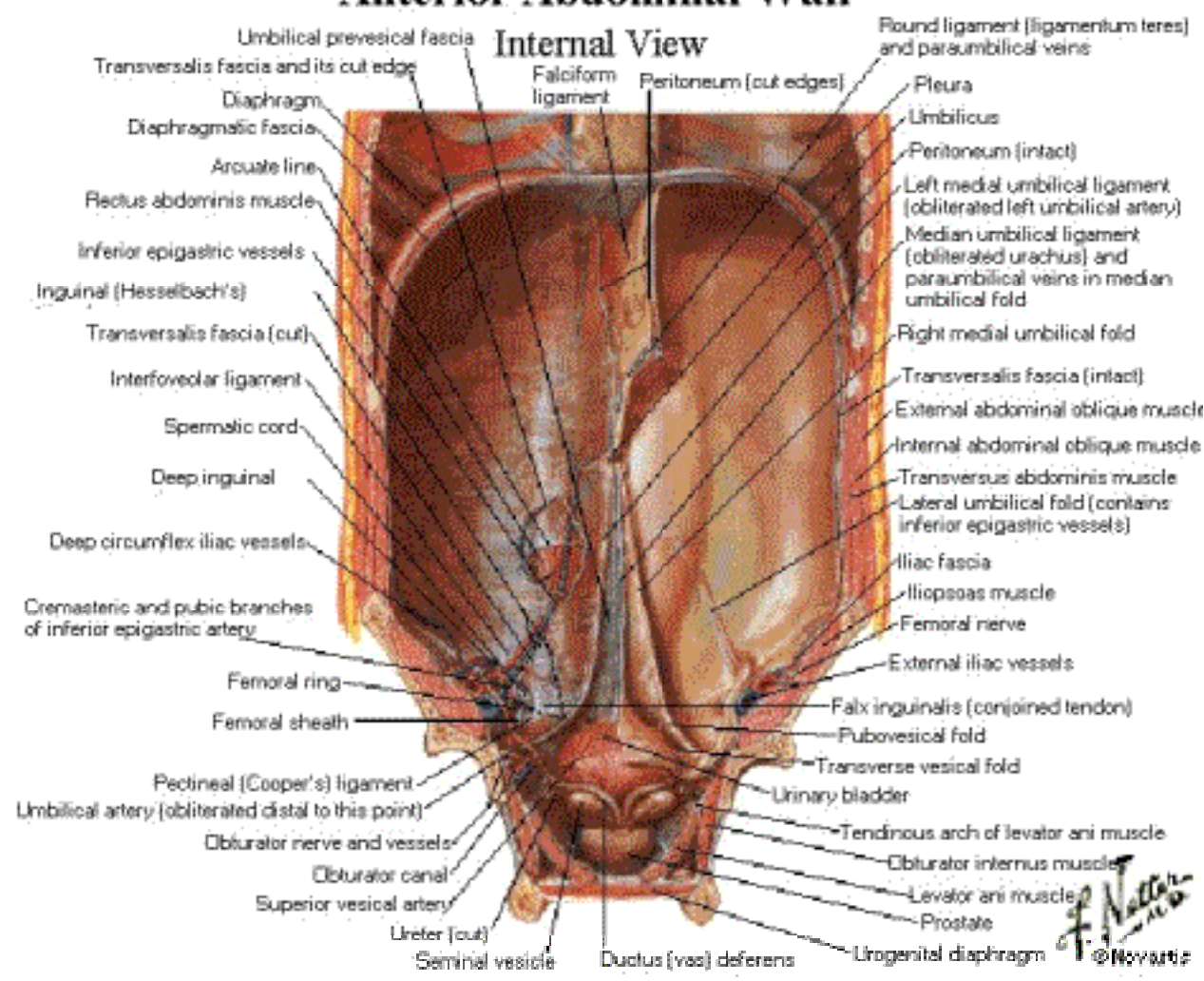
Cross Section Below Arcuate Line



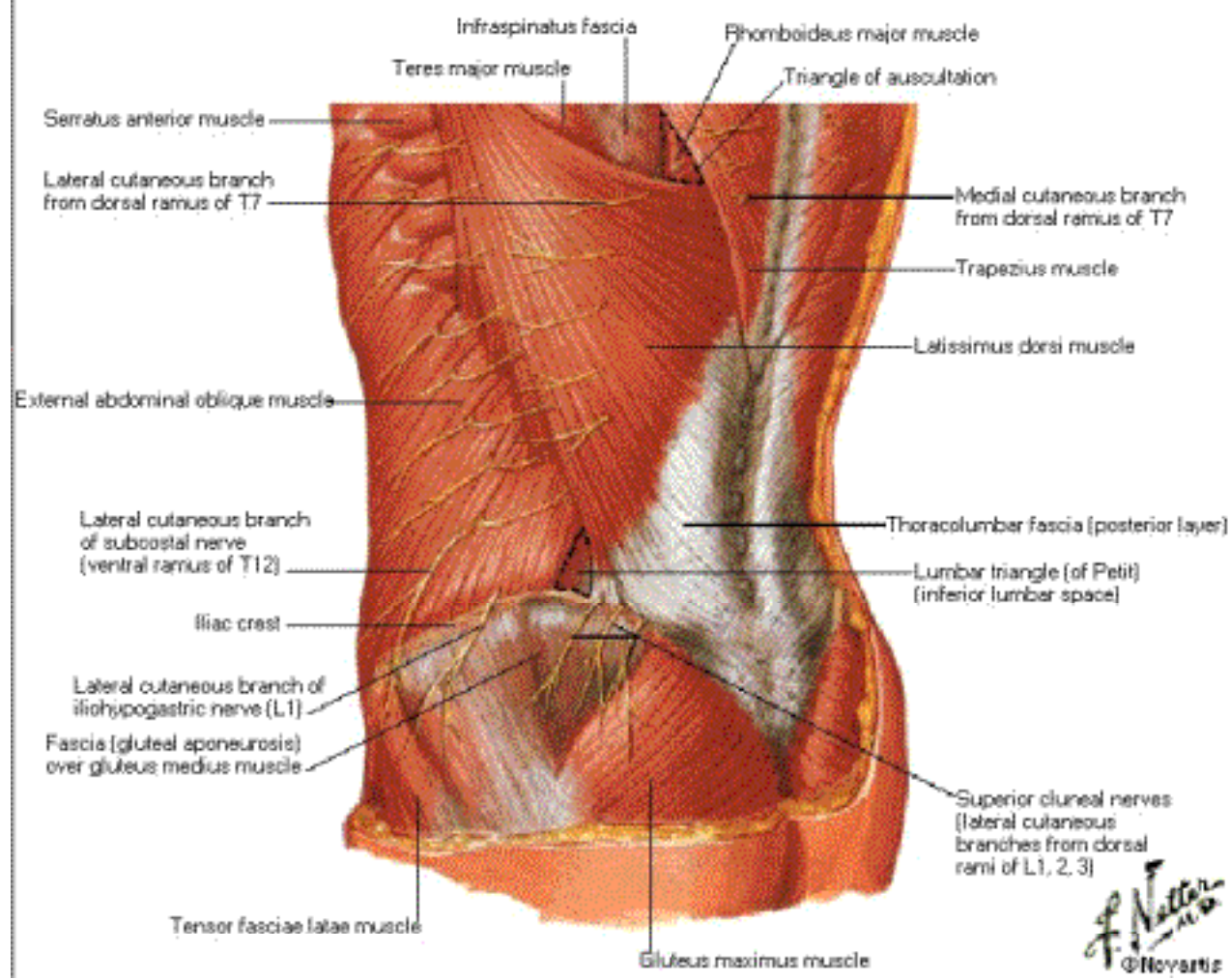
Aponeurosis of internal abdominal oblique muscle does not split at this level but passes completely anterior to rectus abdominis muscle and is fused there with both aponeurosis of external abdominal oblique muscle and that of transversus abdominis muscle. Thus posterior wall of rectus sheath is absent below arcuate line and rectus abdominis muscle lies on transversalis fascia



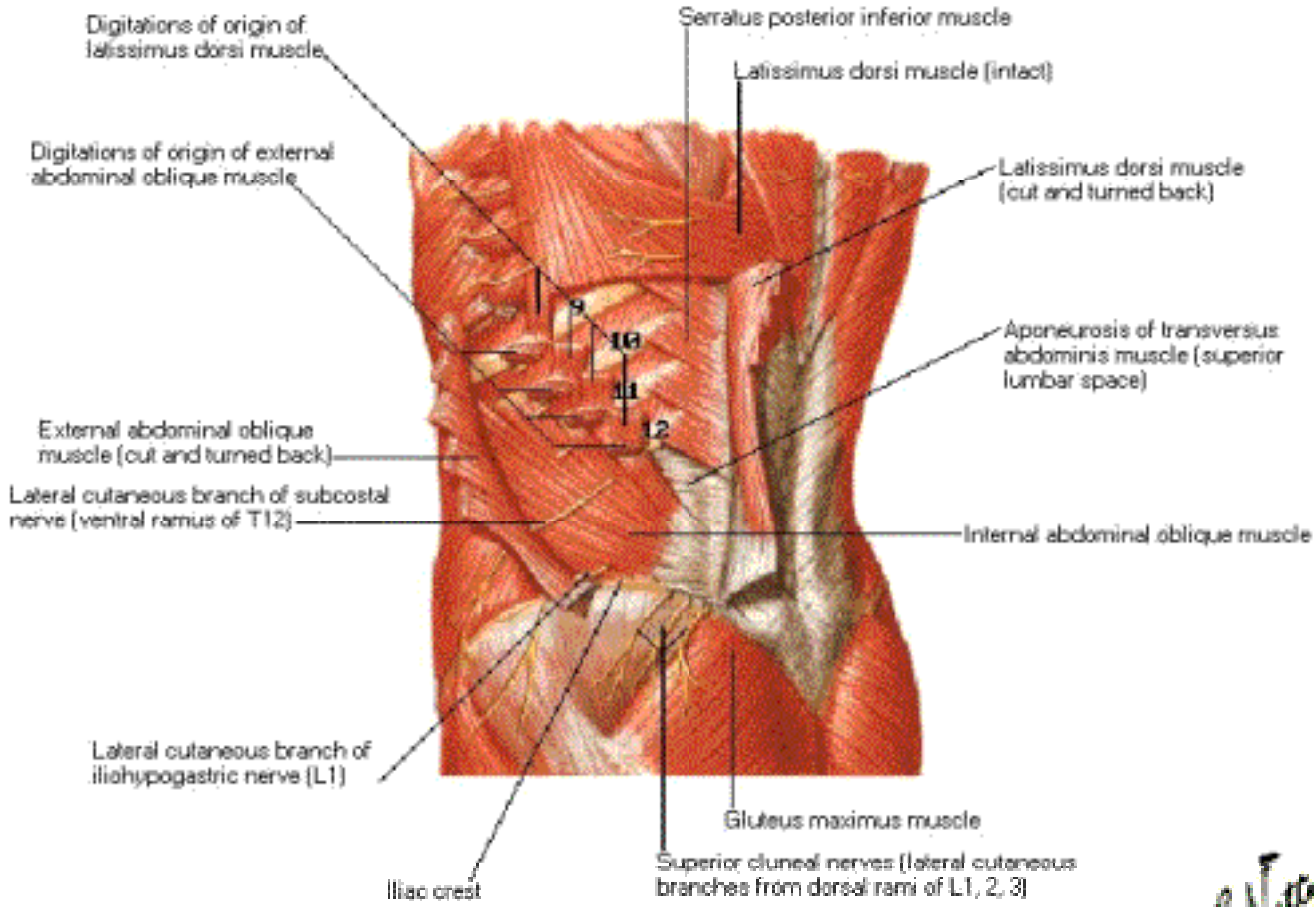
Anterior Abdominal Wall



Posterolateral Abdominal Wall

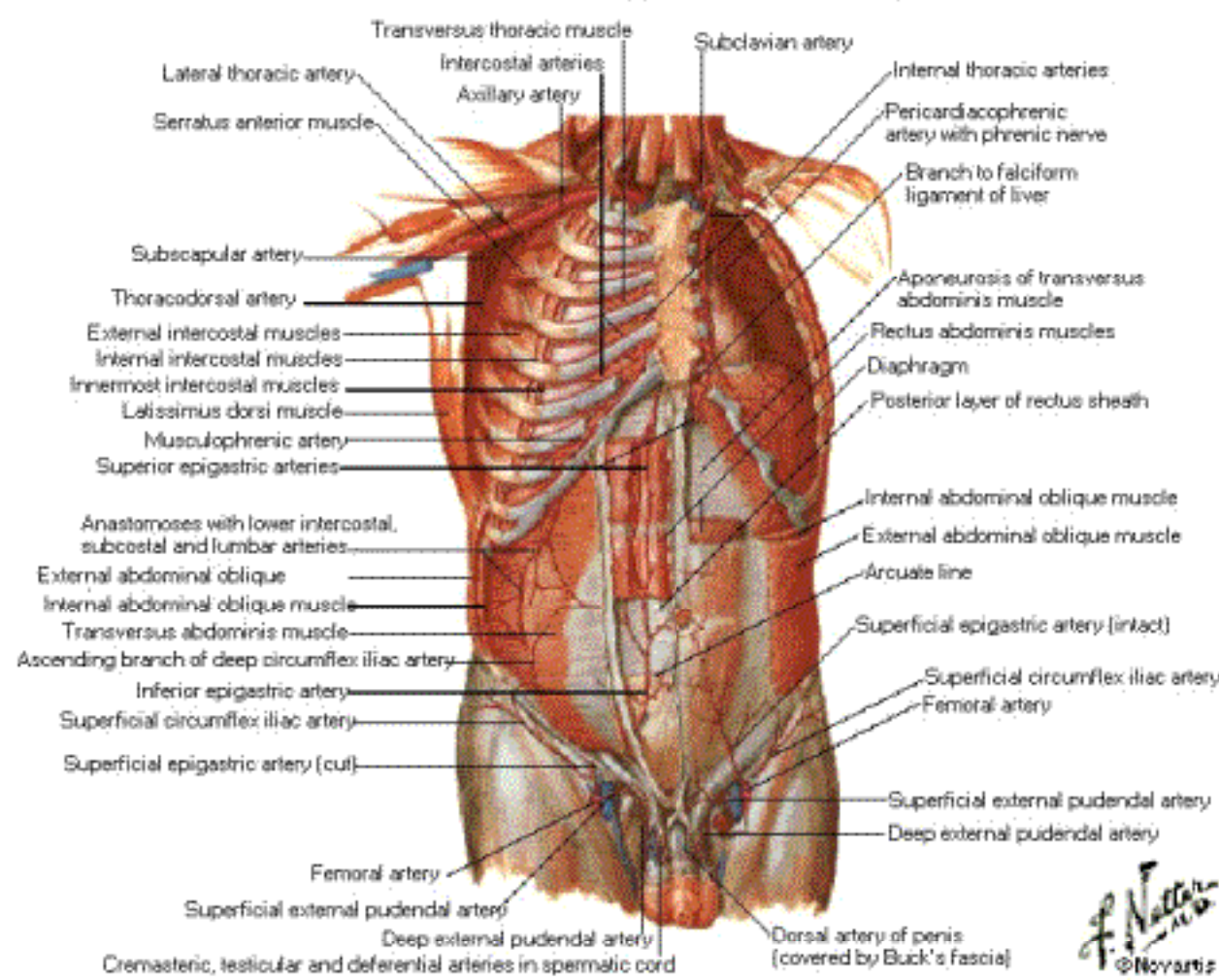


Posterolateral Abdominal Wall [Continued]



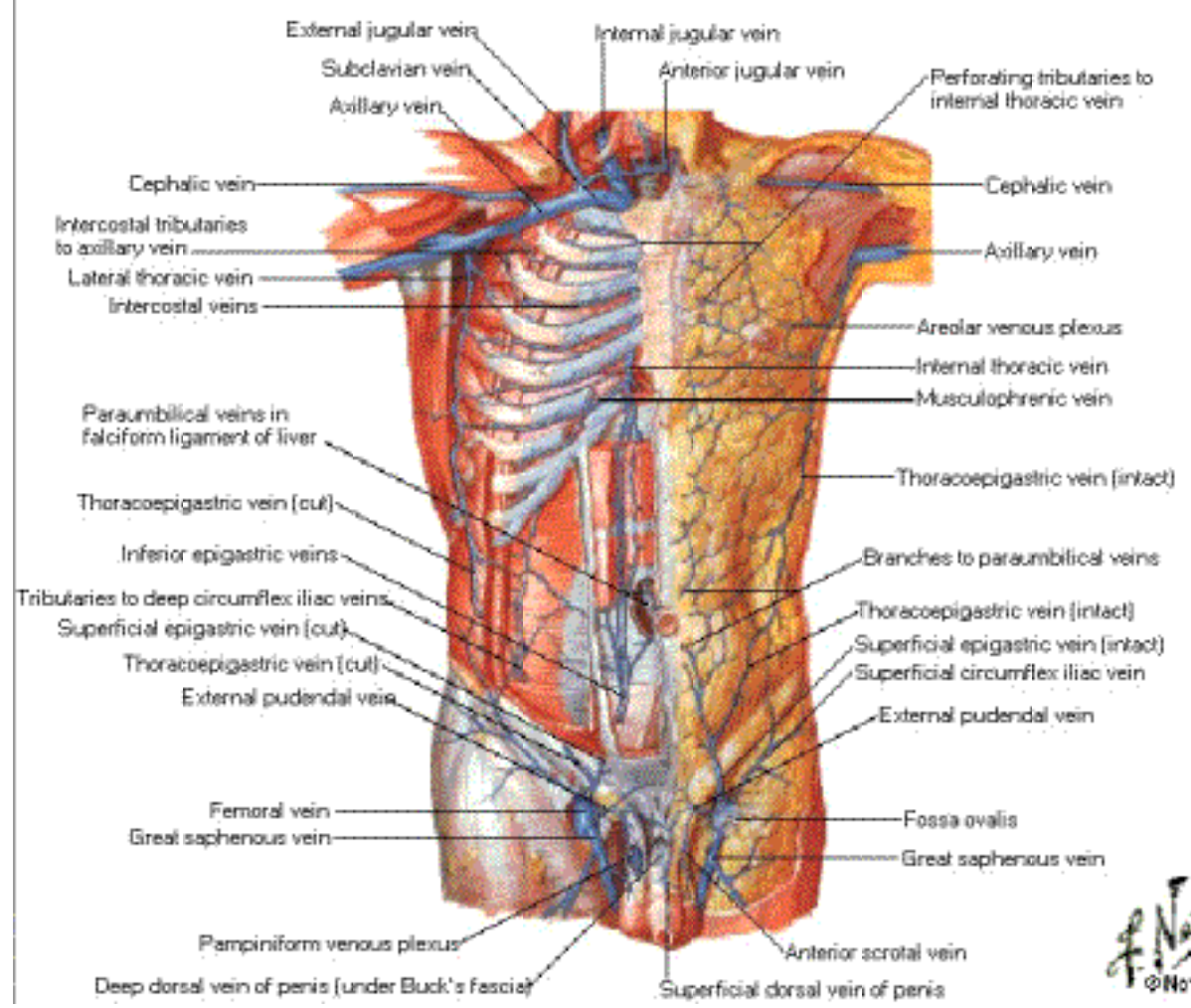
Handwritten signature

Arteries of Anterior Abdominal Wall

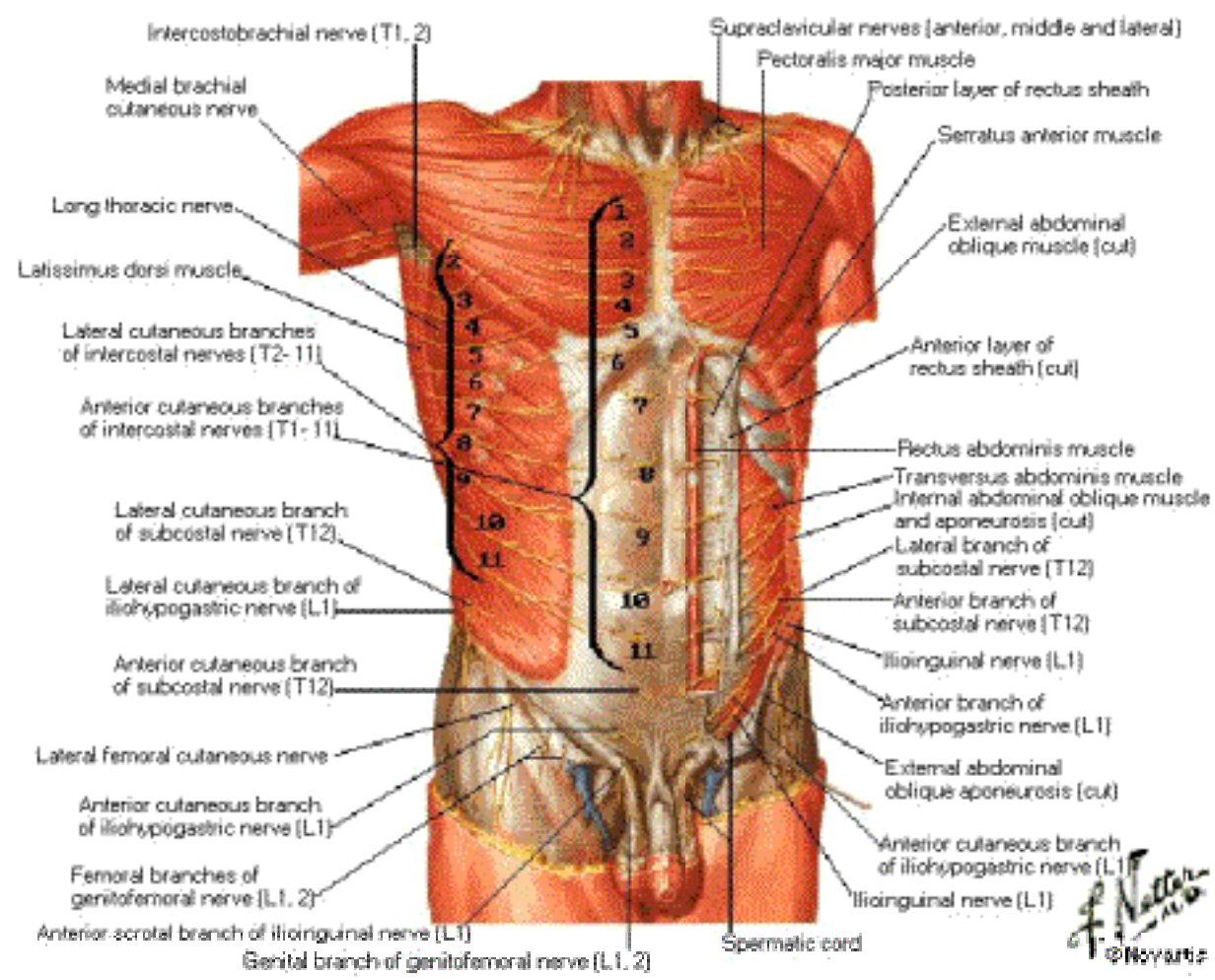


F. Netter M.D.
 © Novartis

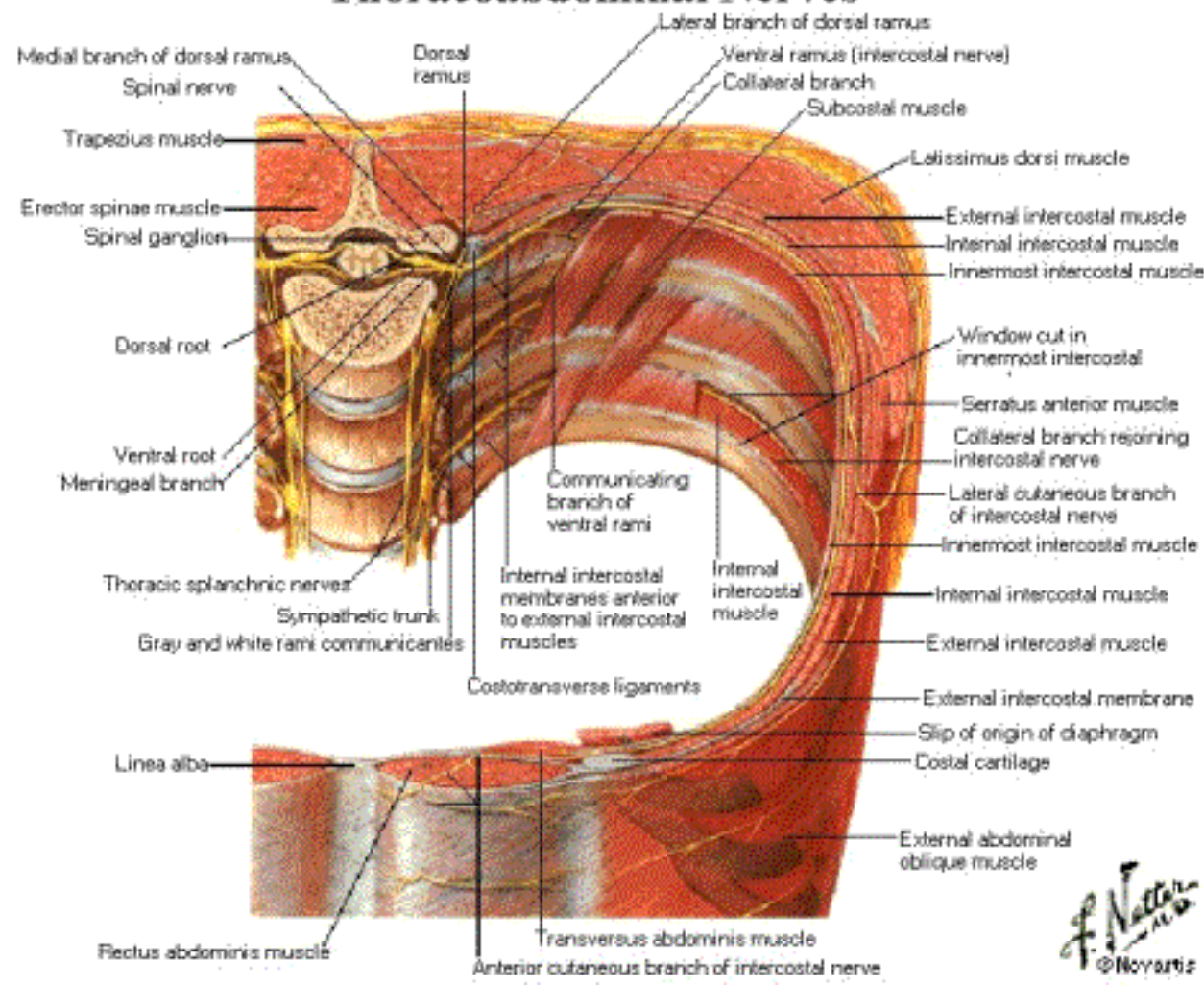
Veins of Anterior Abdominal Wall



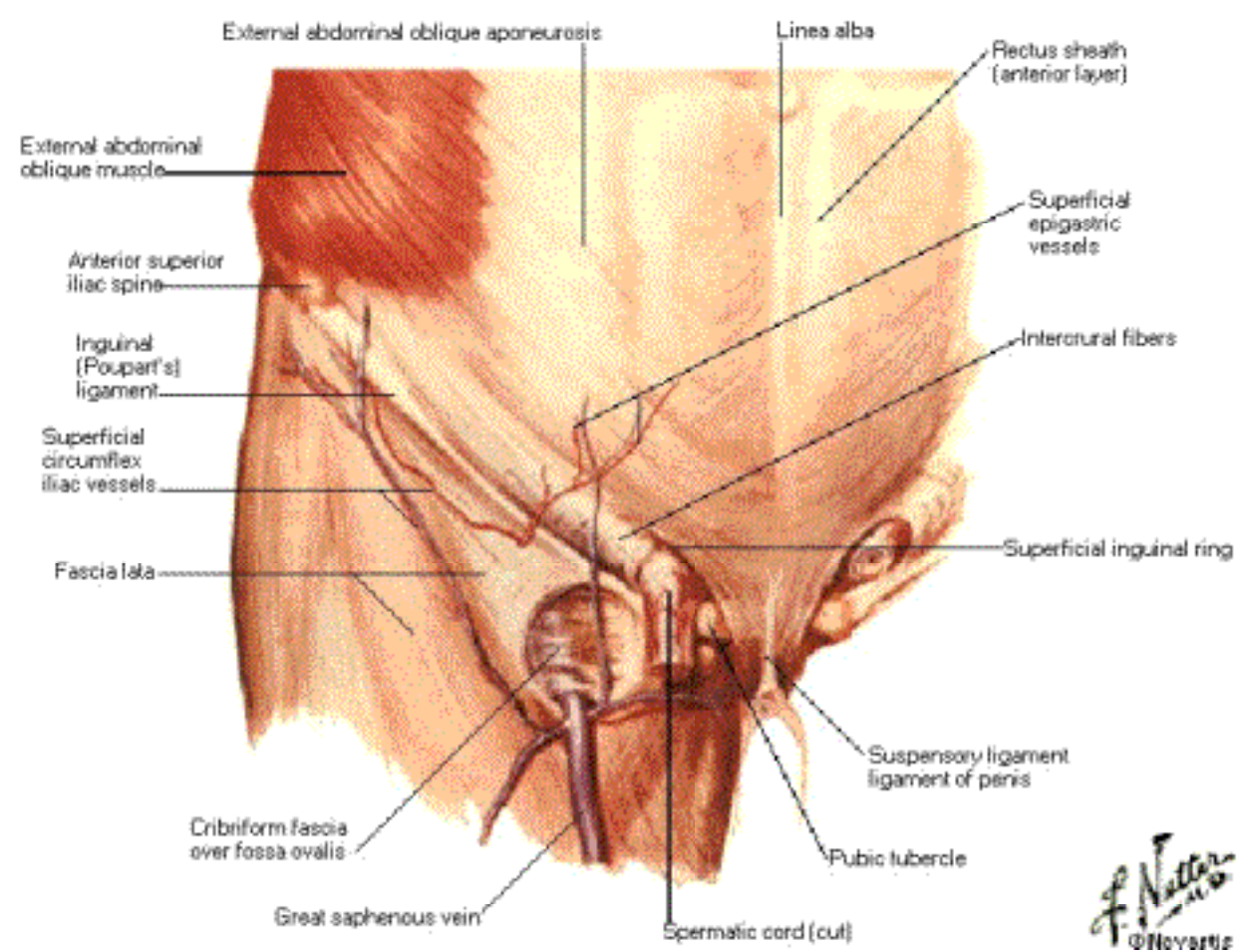
Nerves of Anterior Abdominal Wall



Thoracoabdominal Nerves

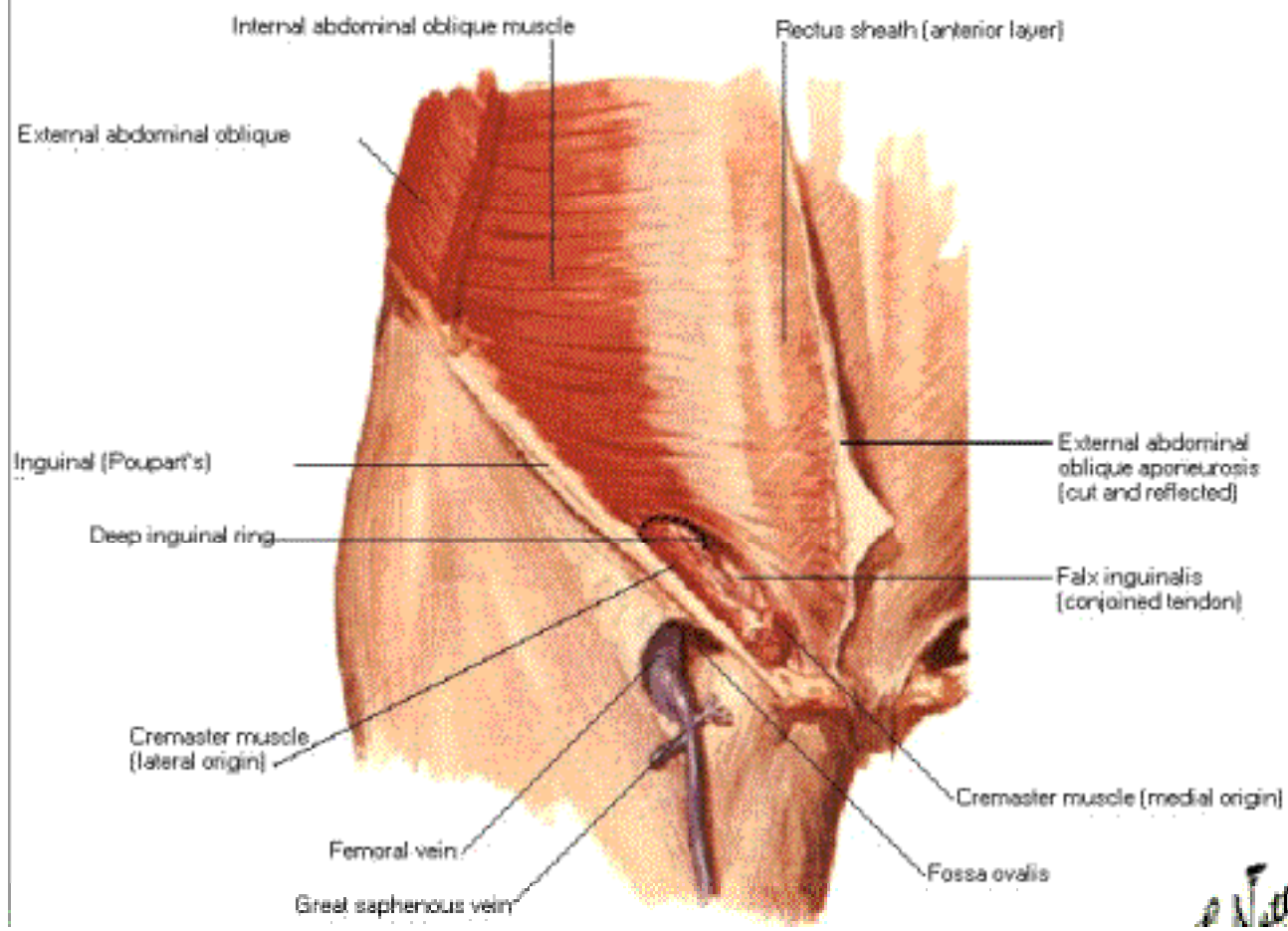


Inguinal and Femoral Regions Subcutaneous Fascia Removed



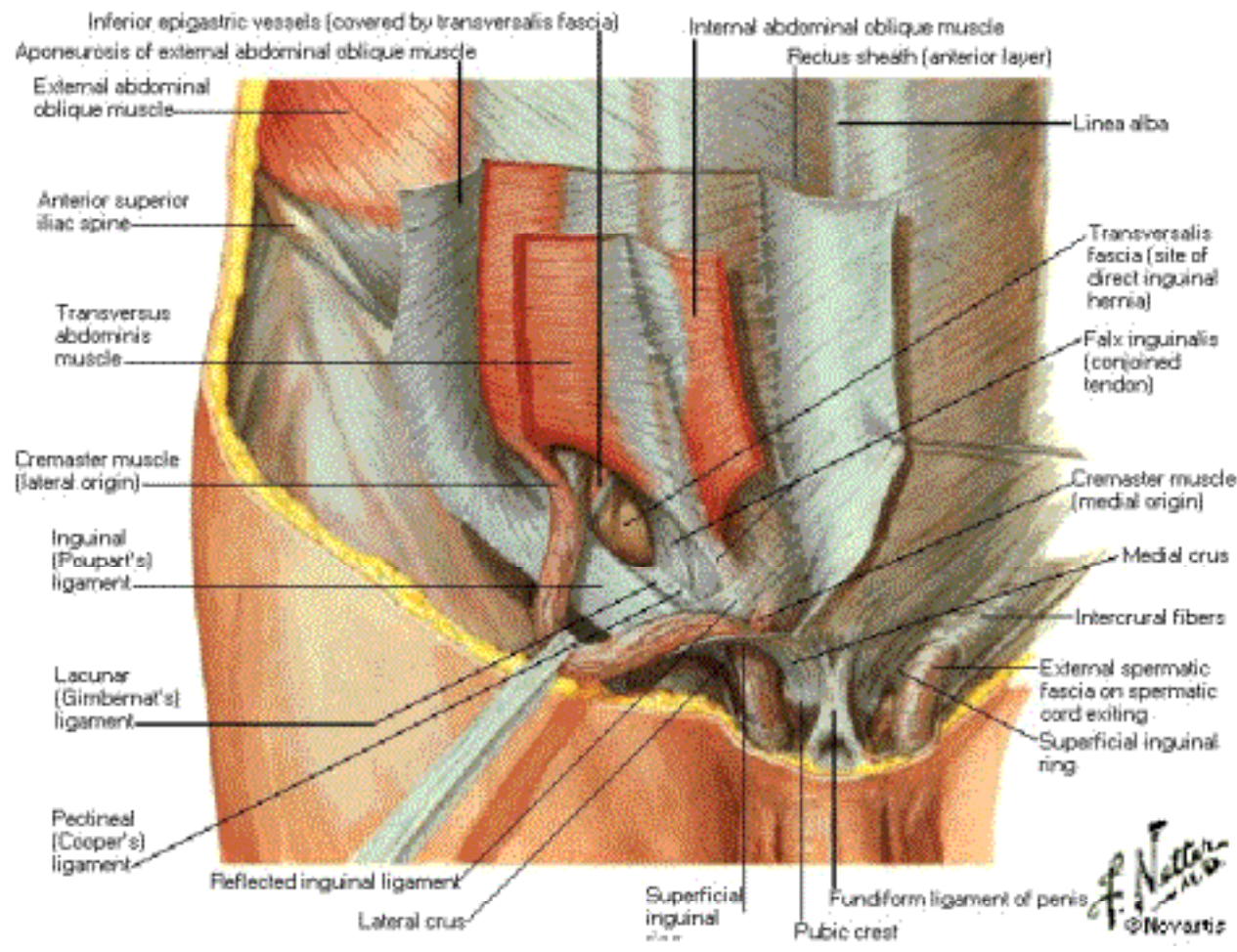
Inguinal and Femoral Regions

Cribriform Fascia Removed



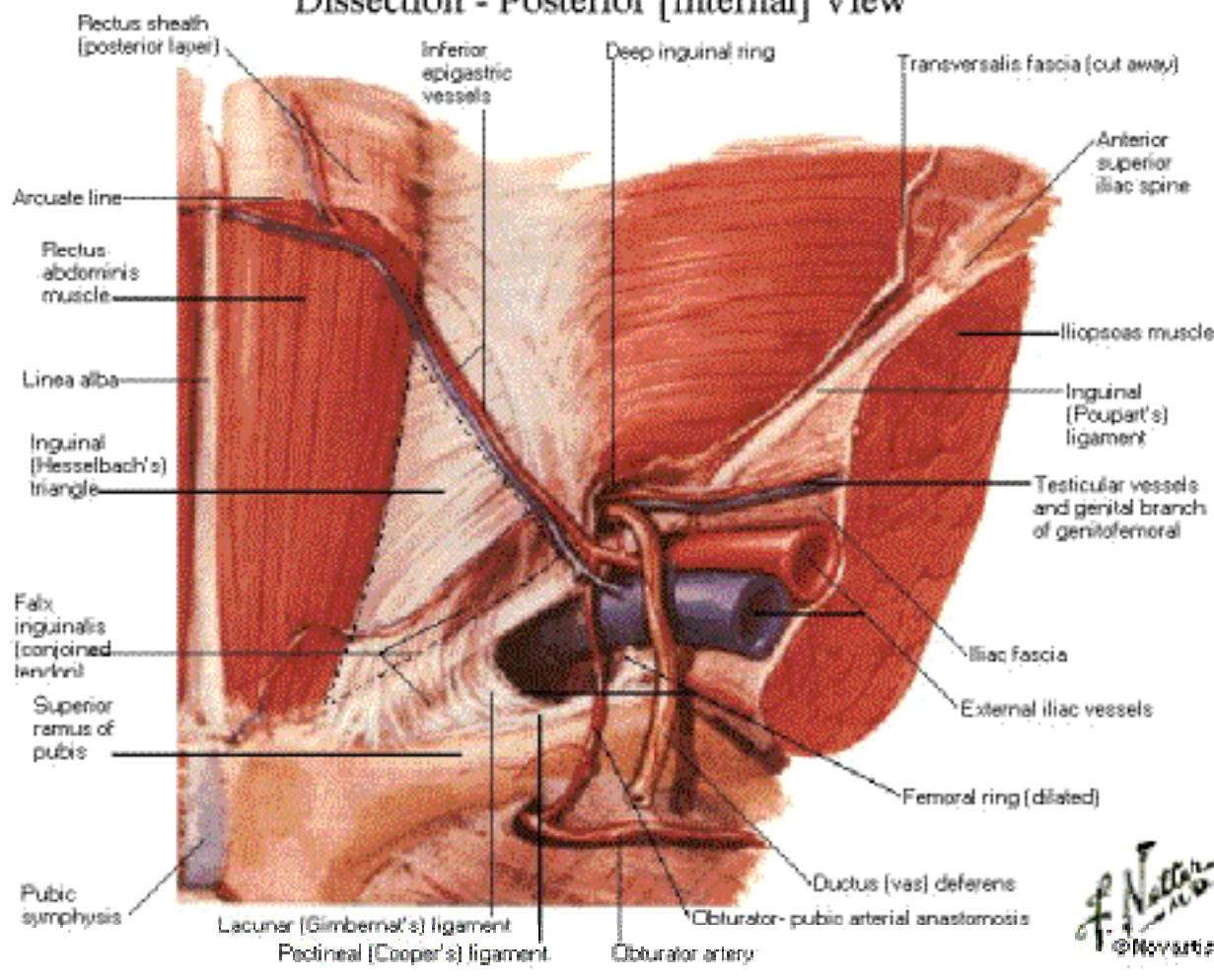
Inguinal Region

Dissection - Anterior View

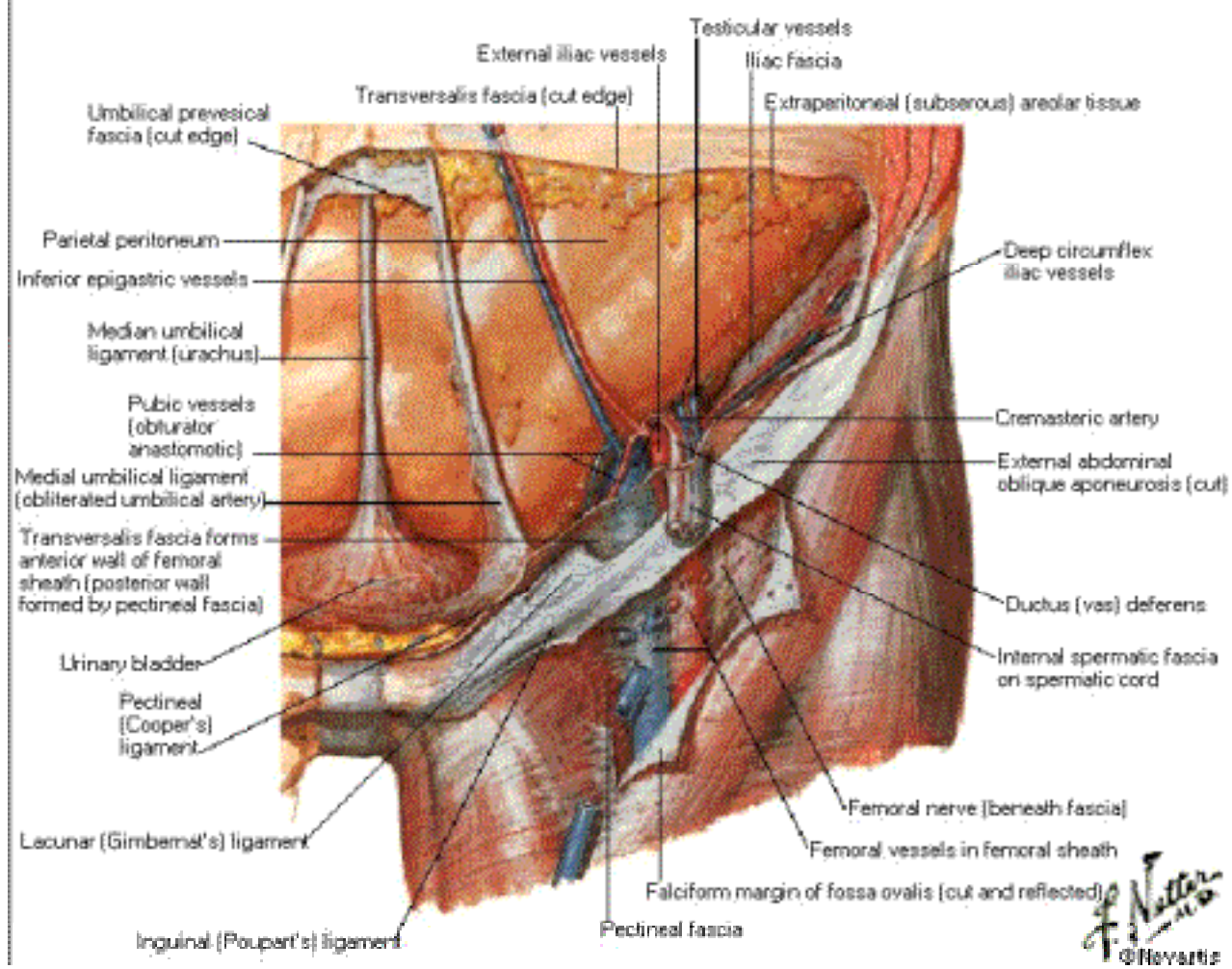


Inguinal Region

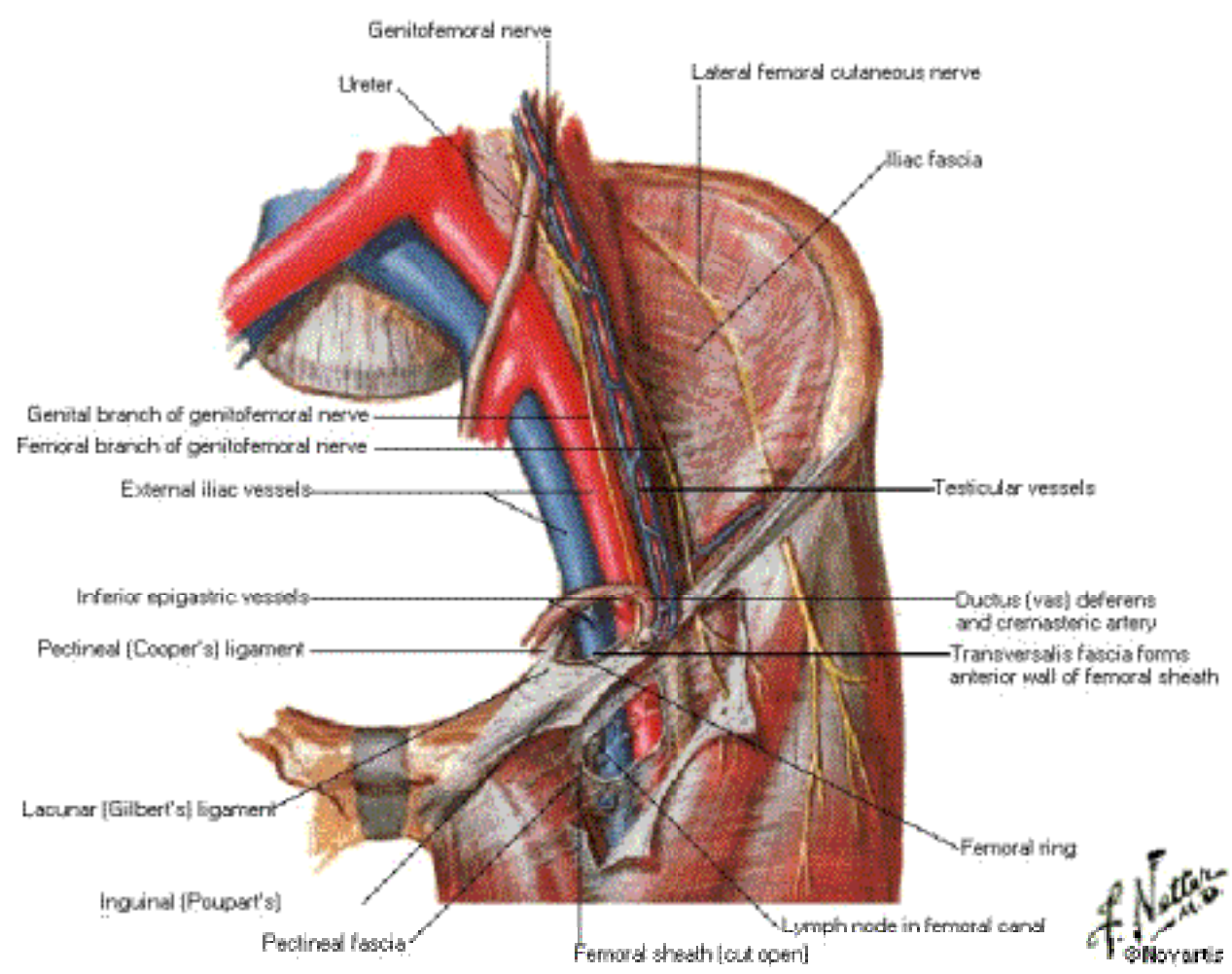
Dissection - Posterior [Internal] View



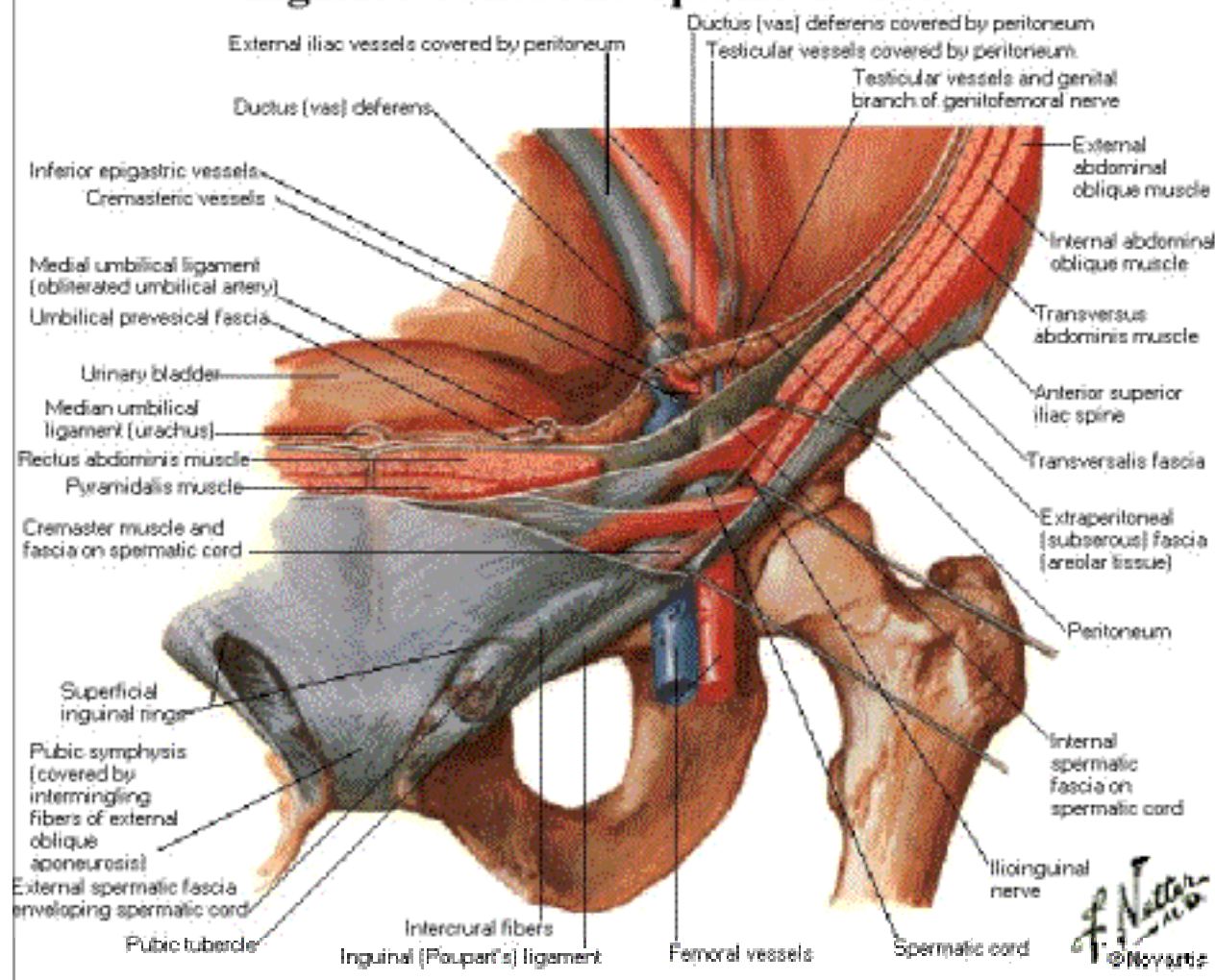
Femoral Sheath and Inguinal Canal



Femoral Sheath and Inguinal Canal [Deep]

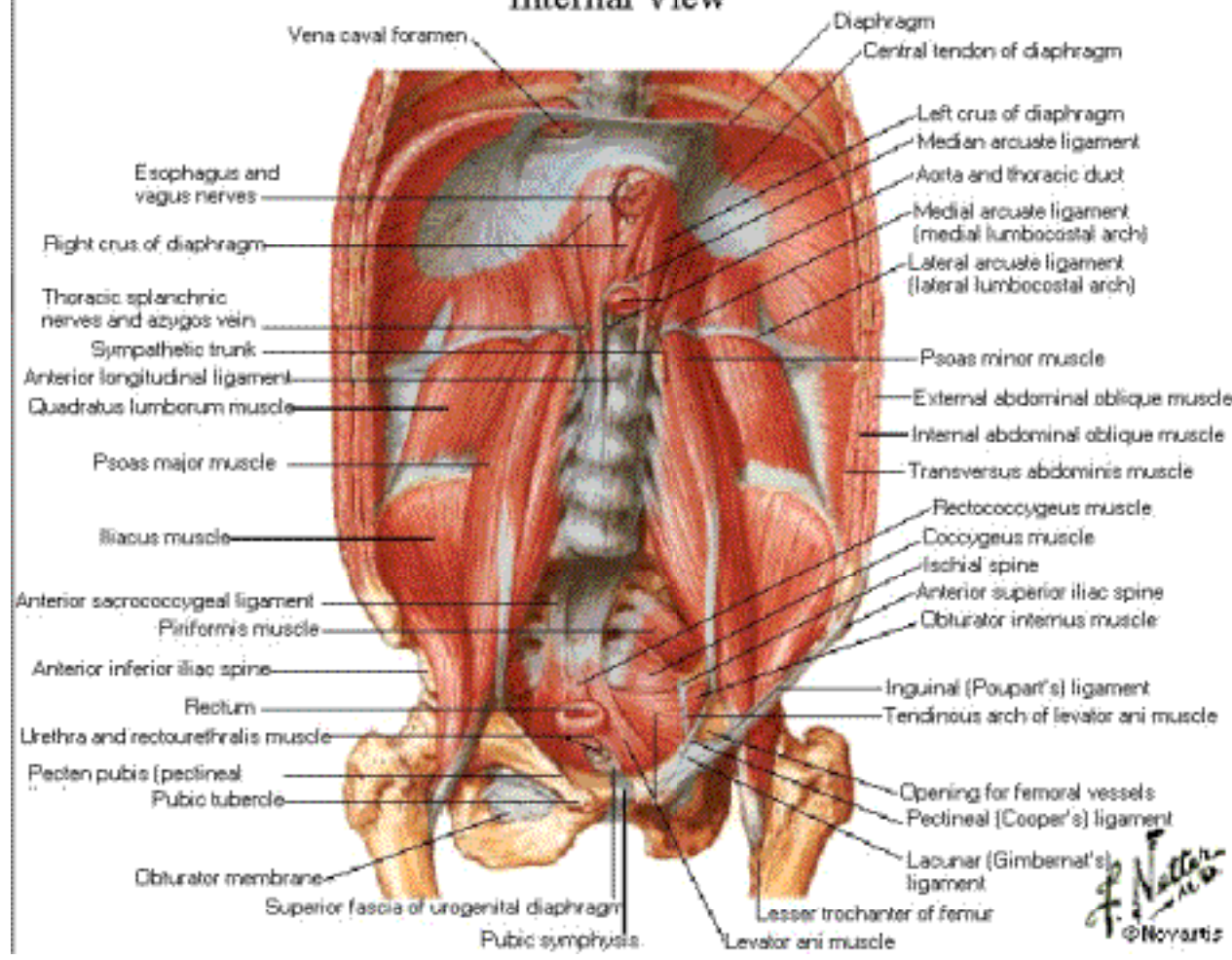


Inguinal Canal and Spermatic Cord

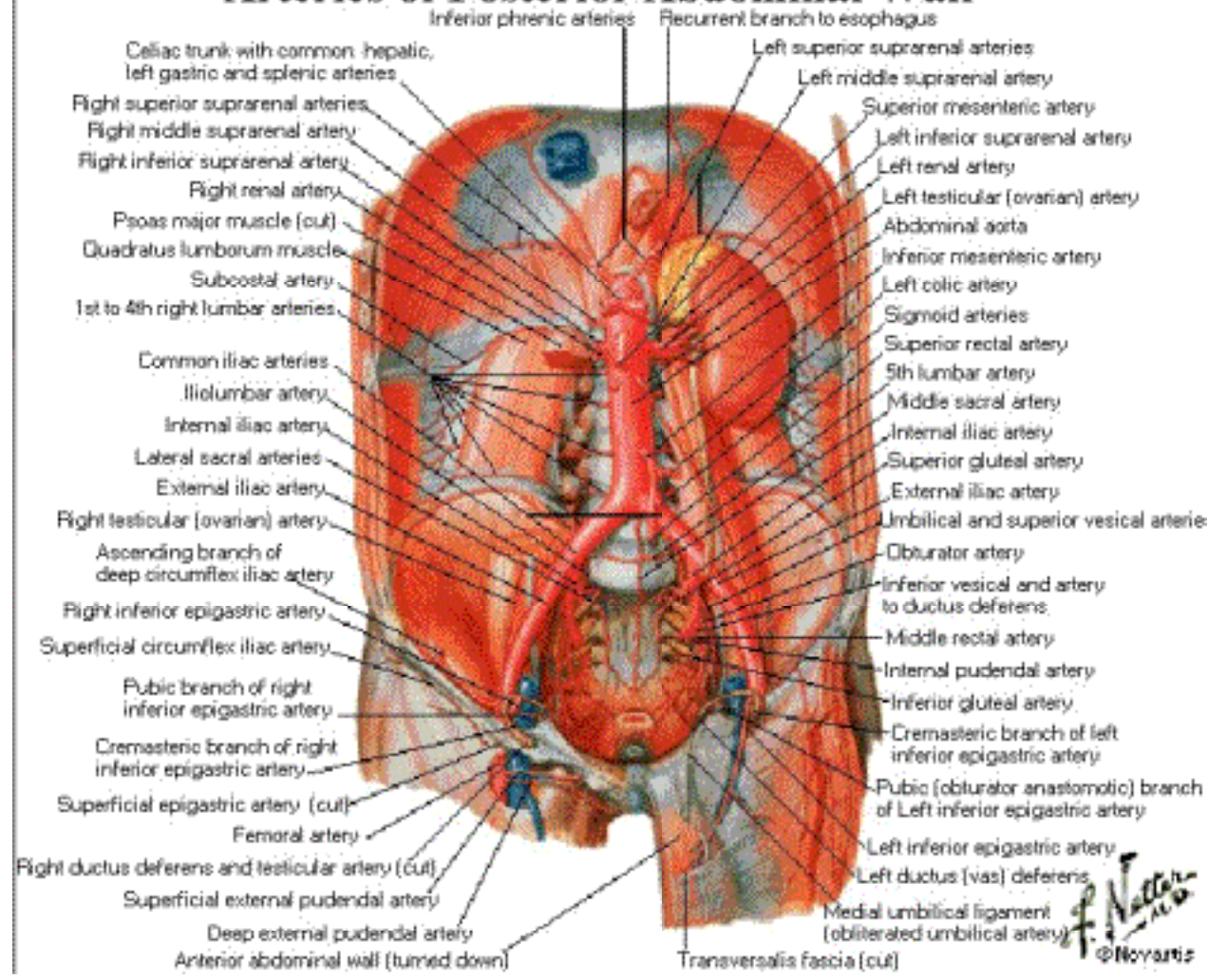


Posterior Abdominal Wall

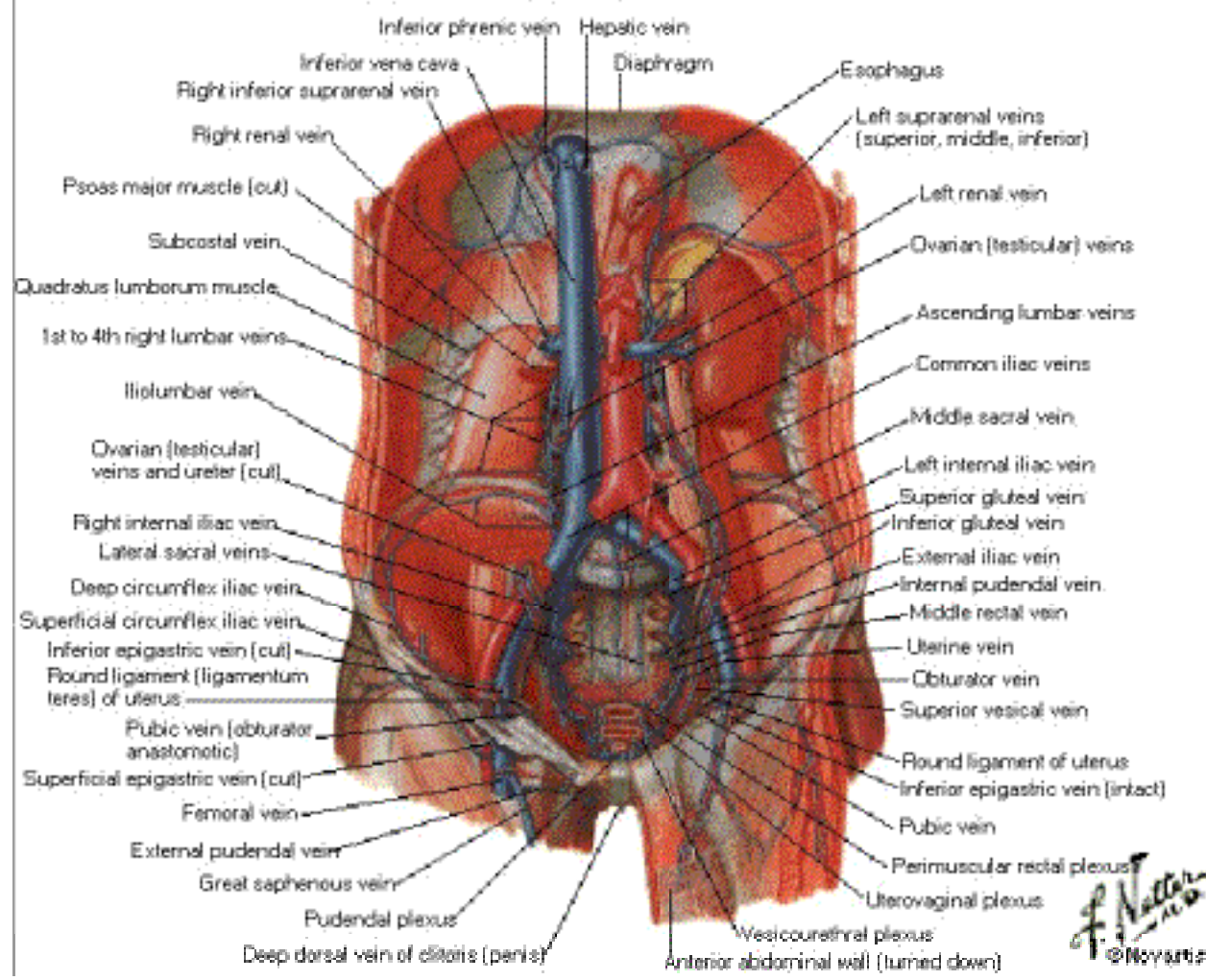
Internal View



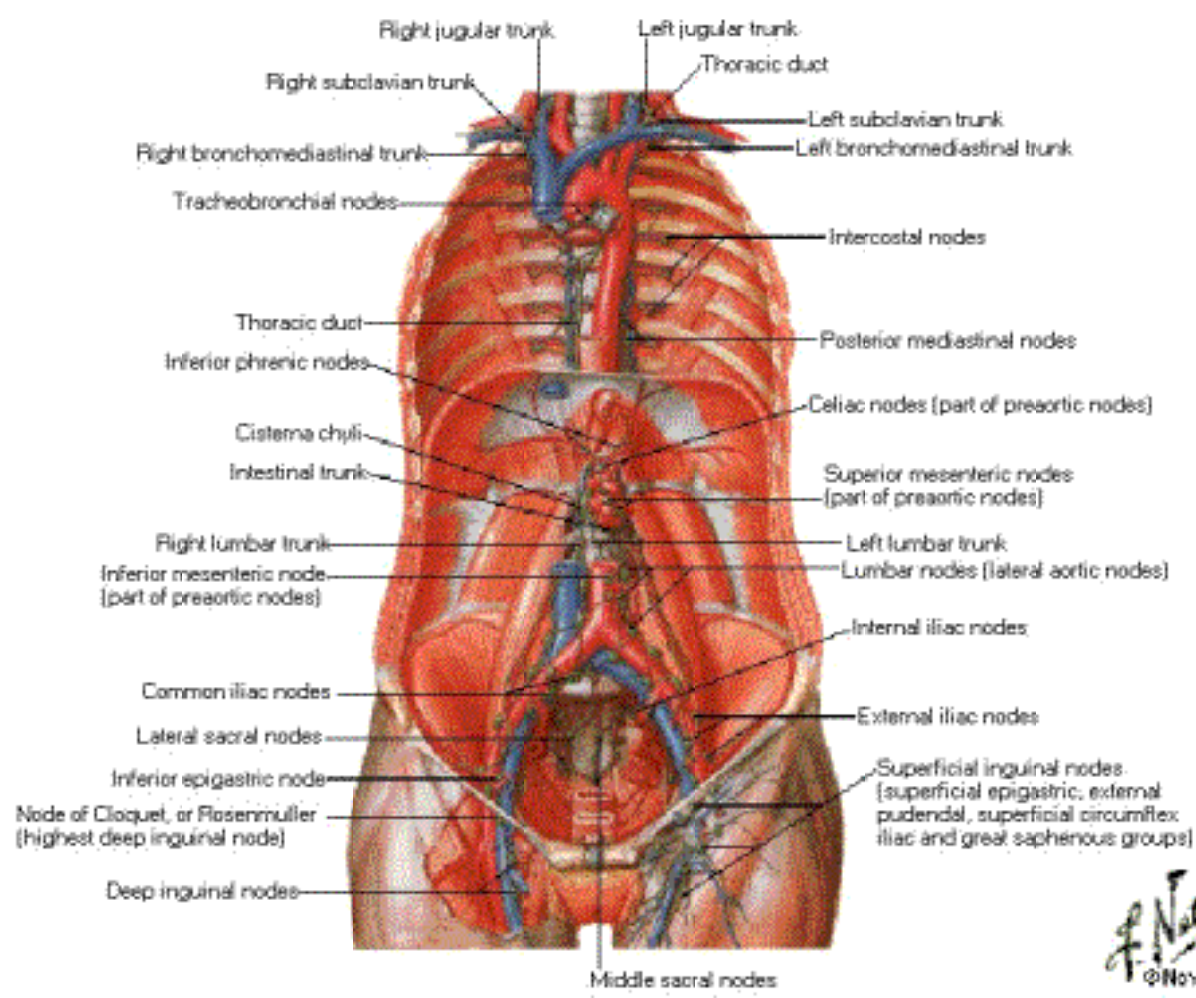
Arteries of Posterior Abdominal Wall



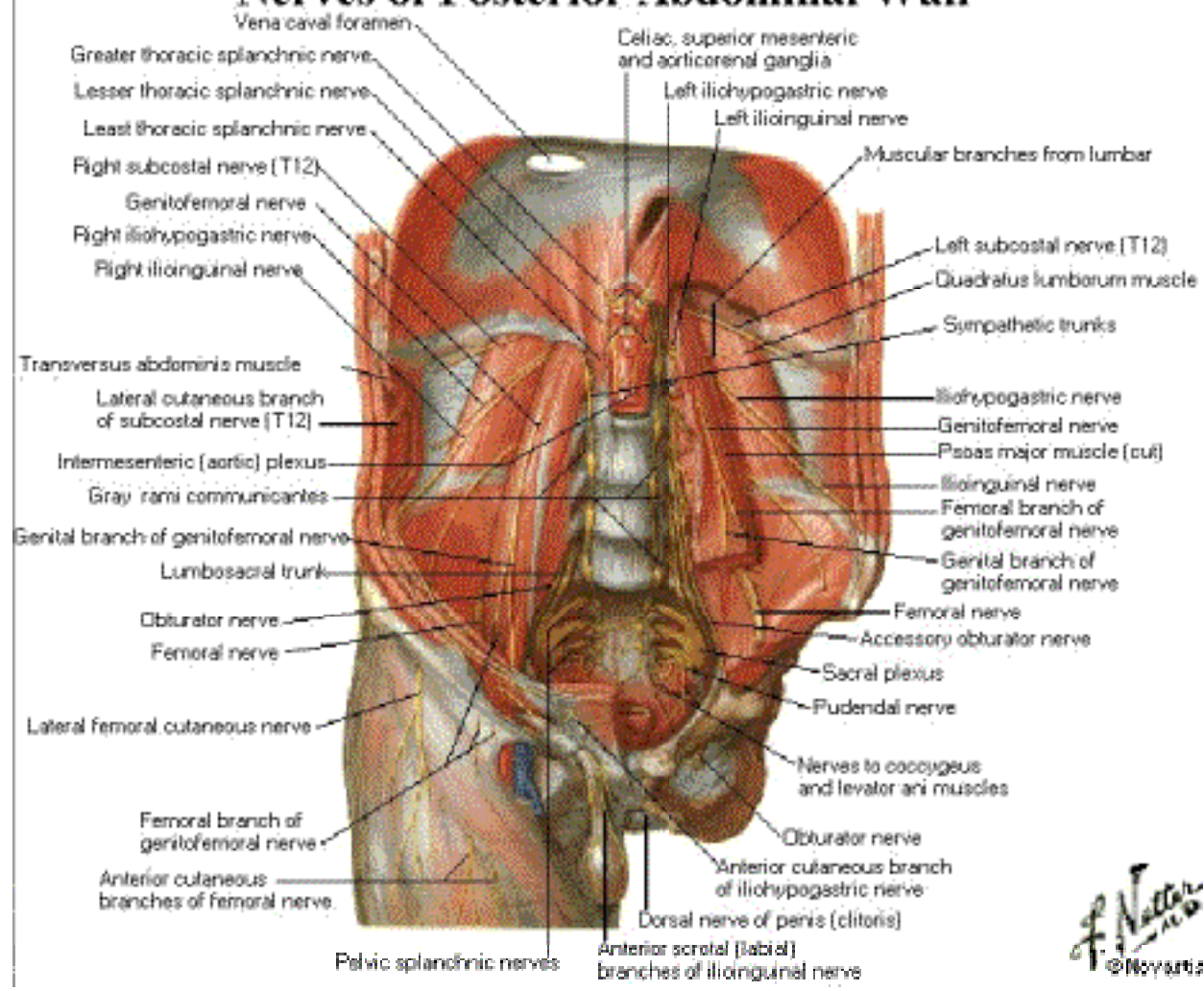
Veins of Posterior Abdominal Wall



Lymph Vessels and Nodes of Posterior Abdominal Wall

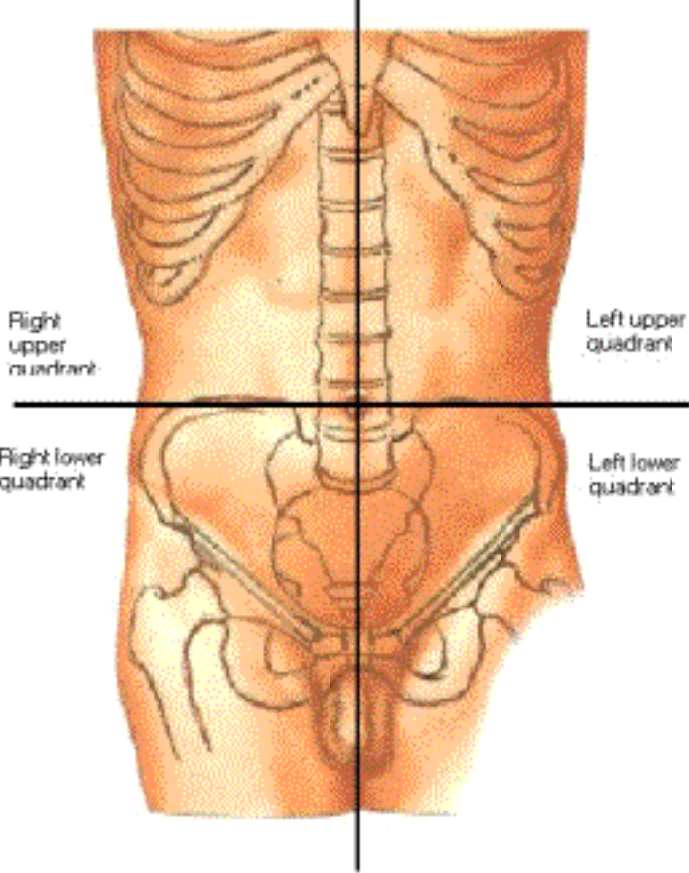


Nerves of Posterior Abdominal Wall

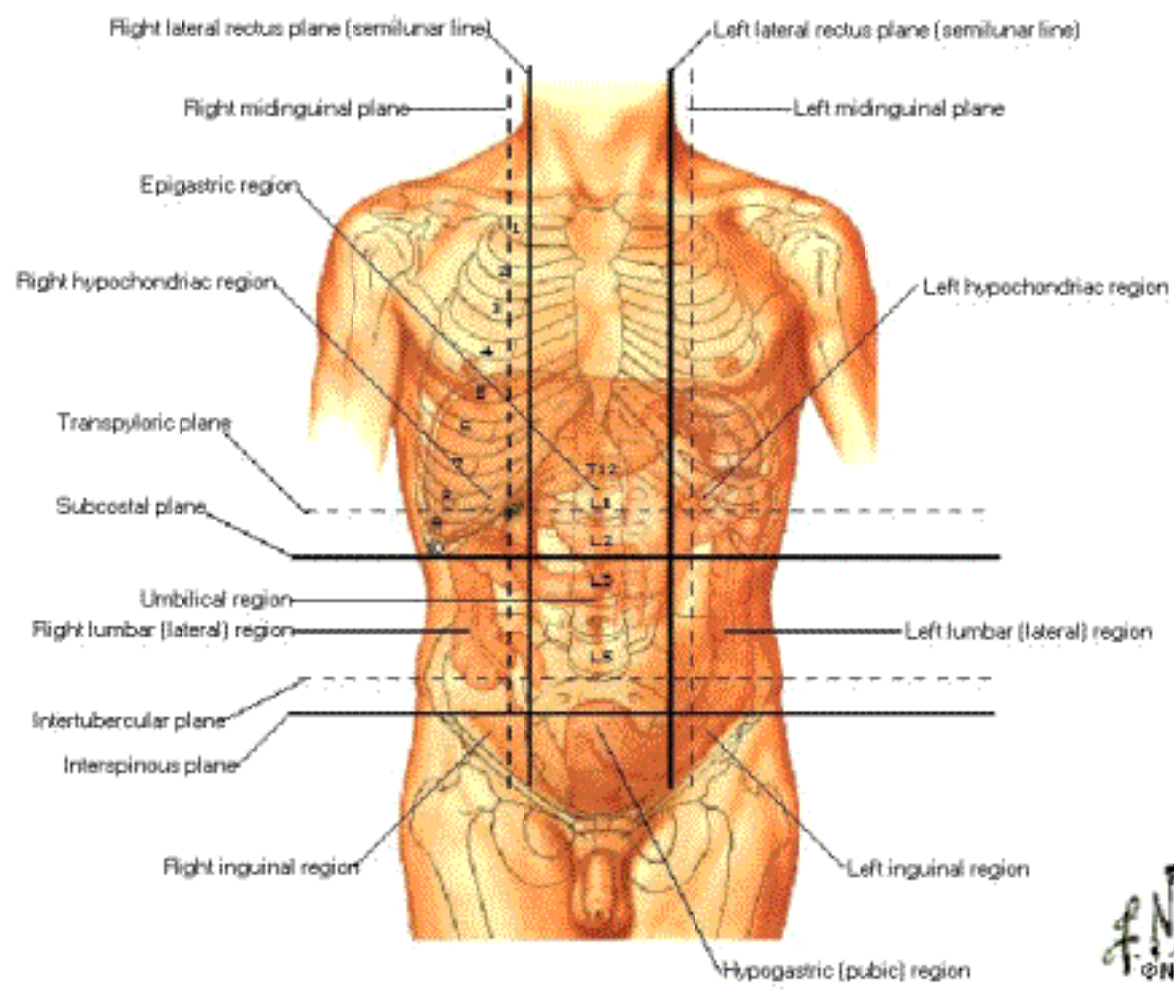


F. Netter M.D.
© 1989

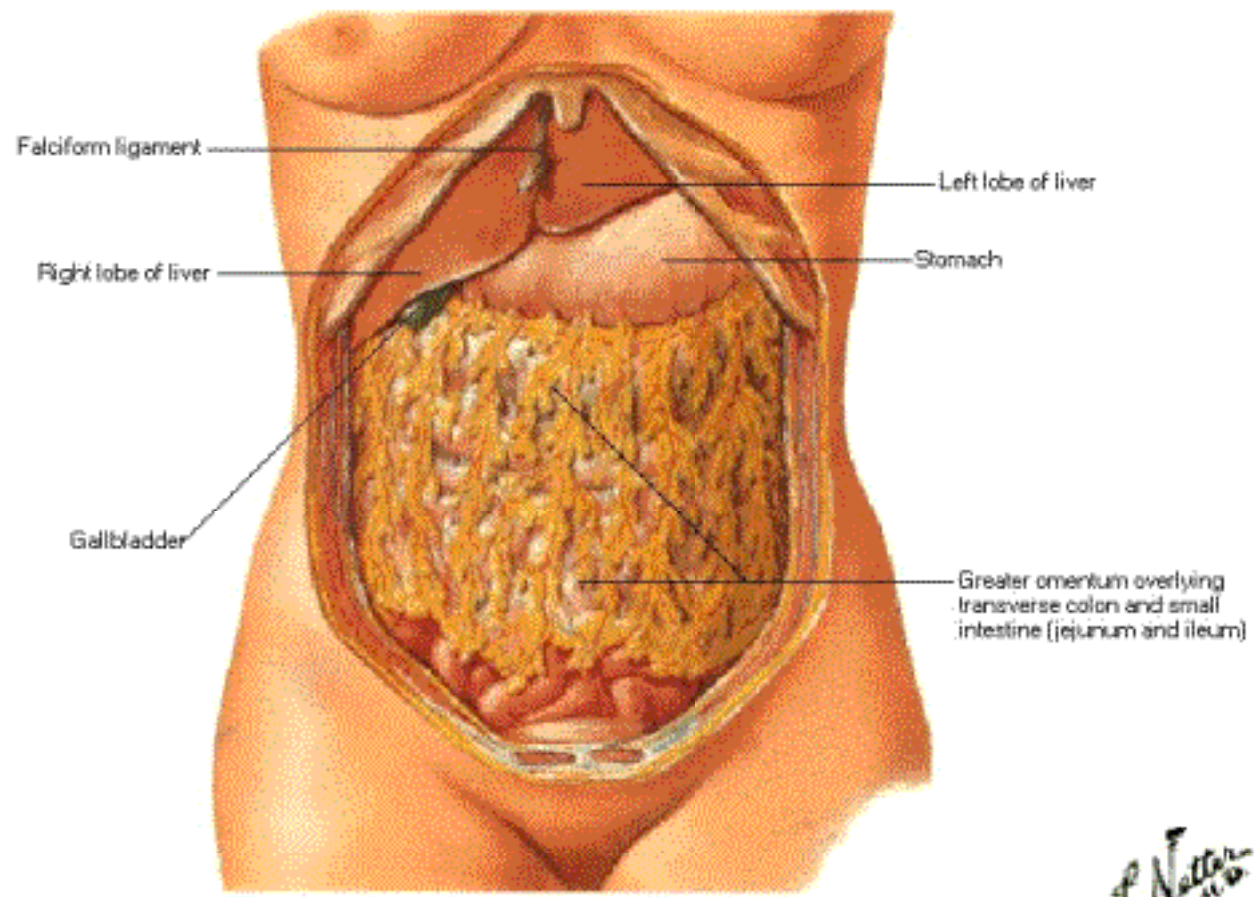
Quadrants of Abdomen



Regions and Planes of Abdomen

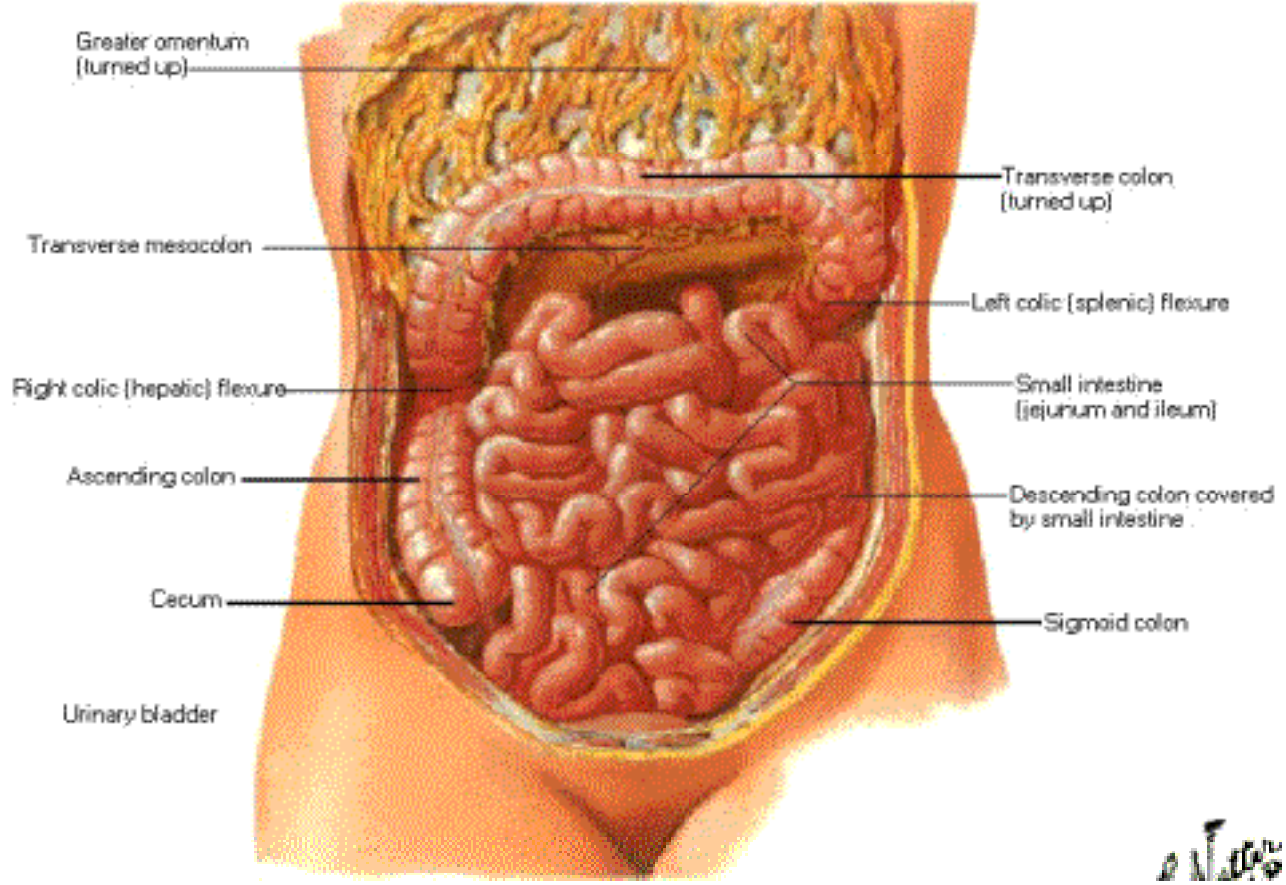


Greater Omentum and Abdominal Viscera



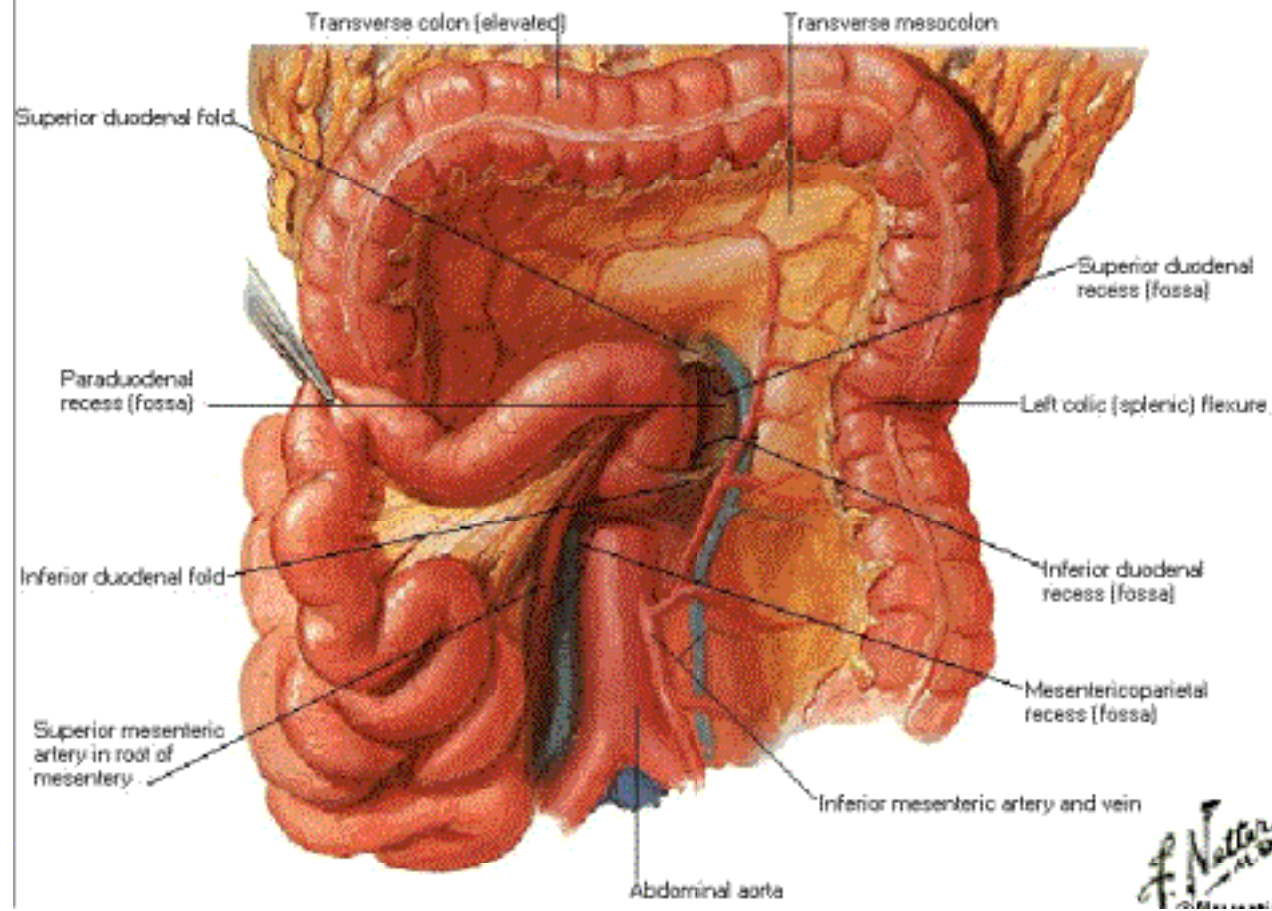
Greater Omentum and Abdominal Viscera

Omentum Raised



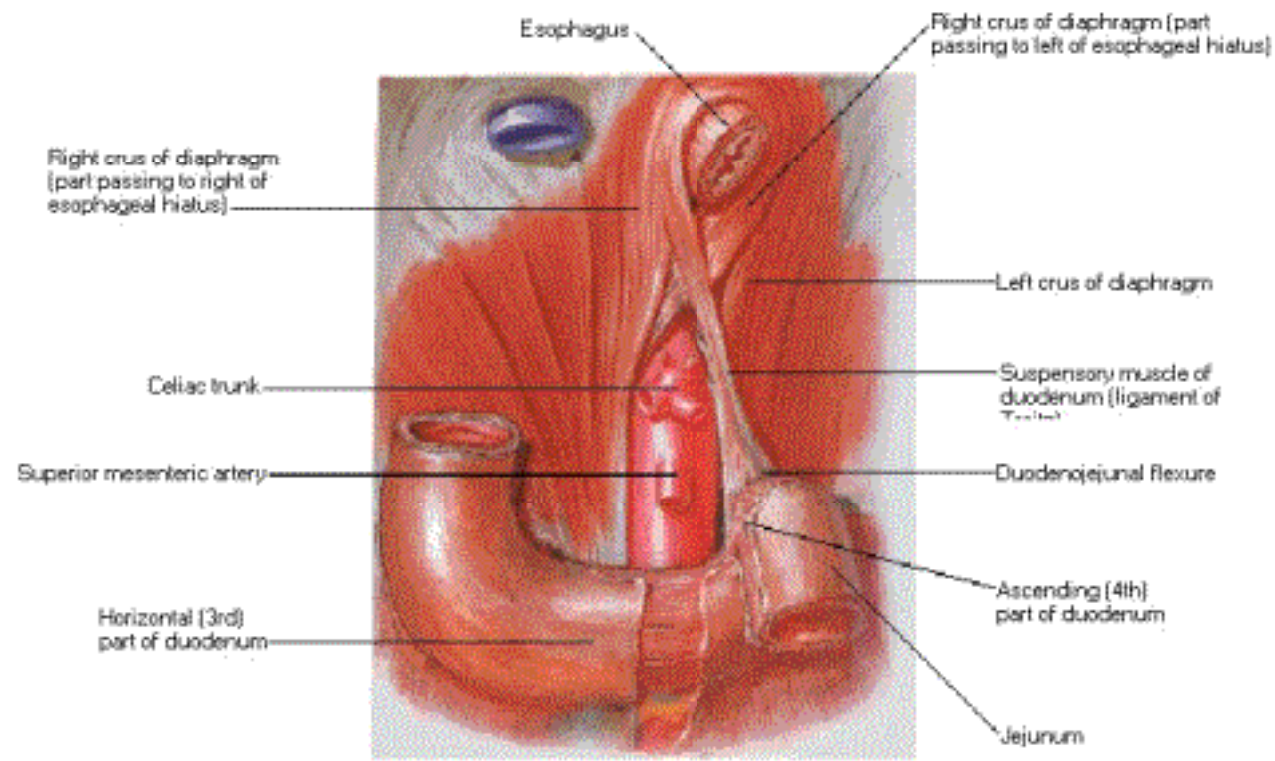
Mesenteric Relations of Intestines

Transverse Colon Elevated



Mesenteric Relations of Intestines

Suspensory Muscle of Duodenum

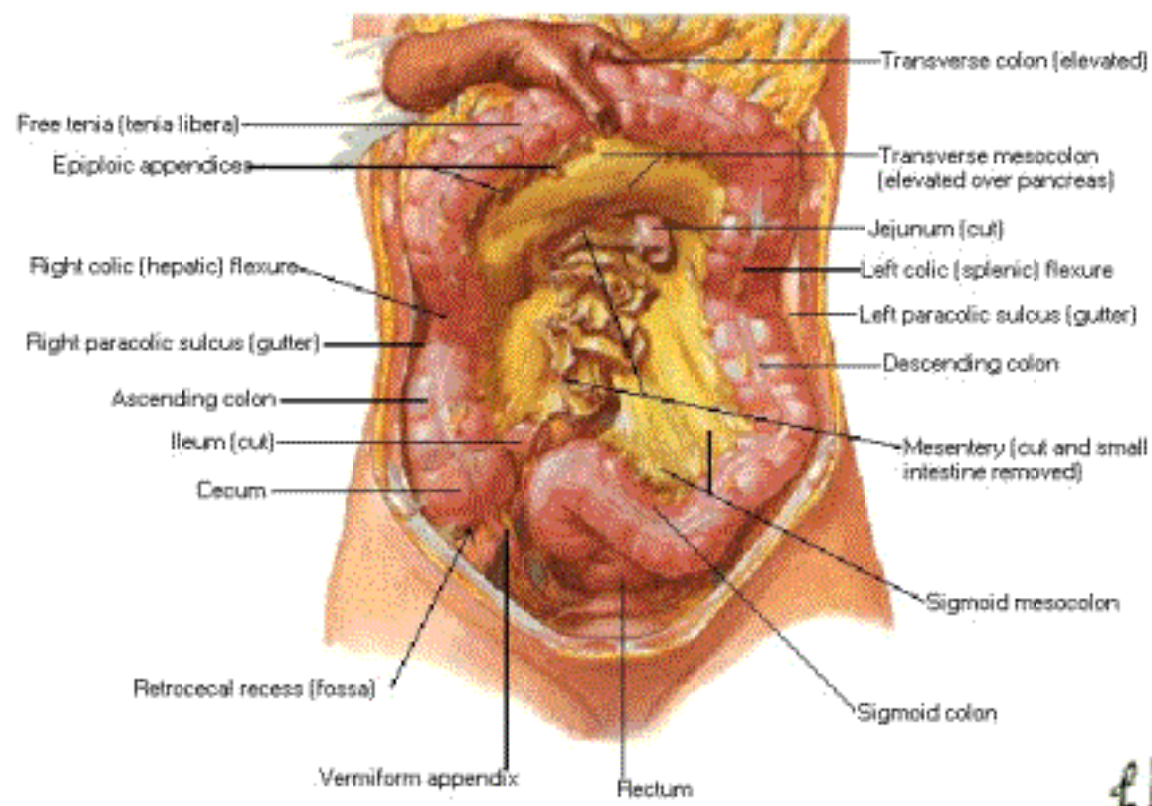


Exposure of suspensory muscle of duodenum (ligament of Treitz)

F. Netter
M.D.

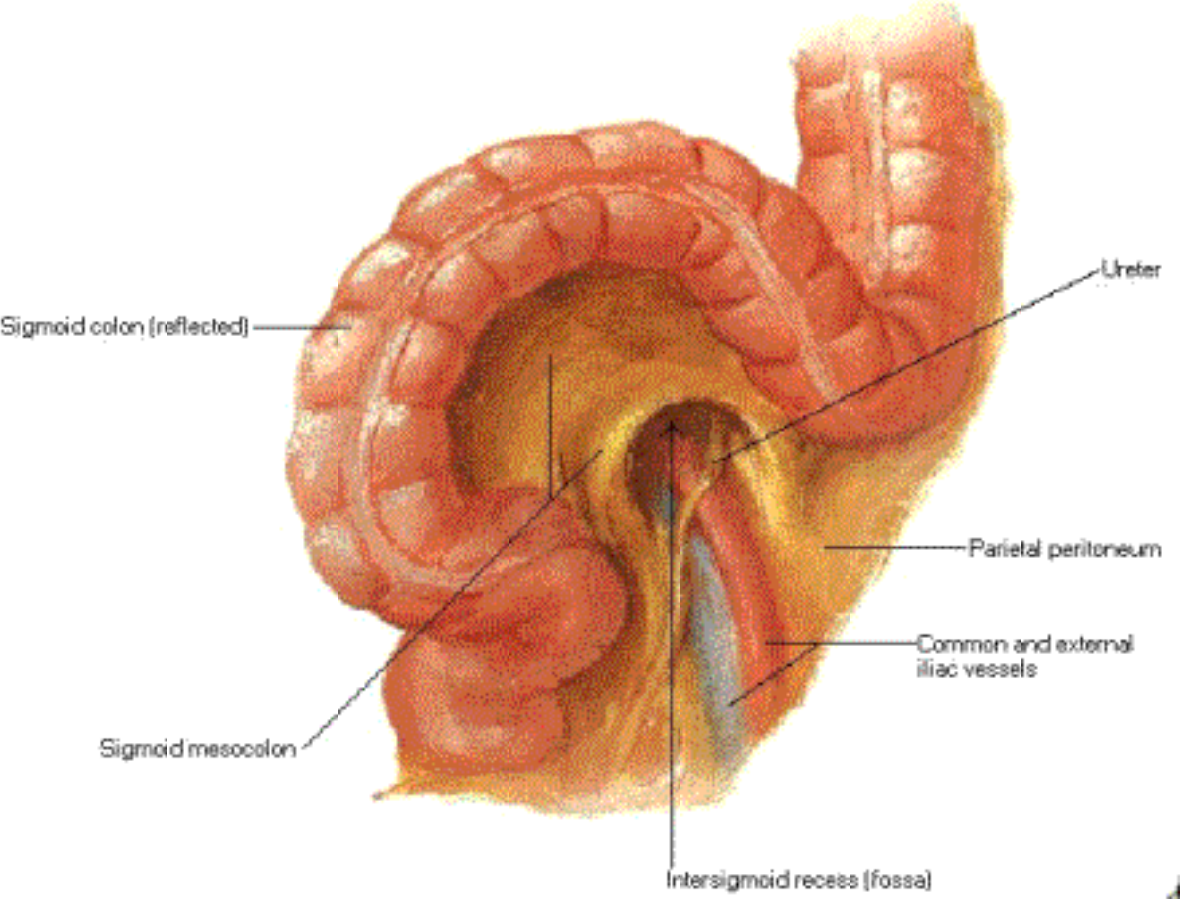
Mesenteric Relations of Intestines

Small Intestine Removed

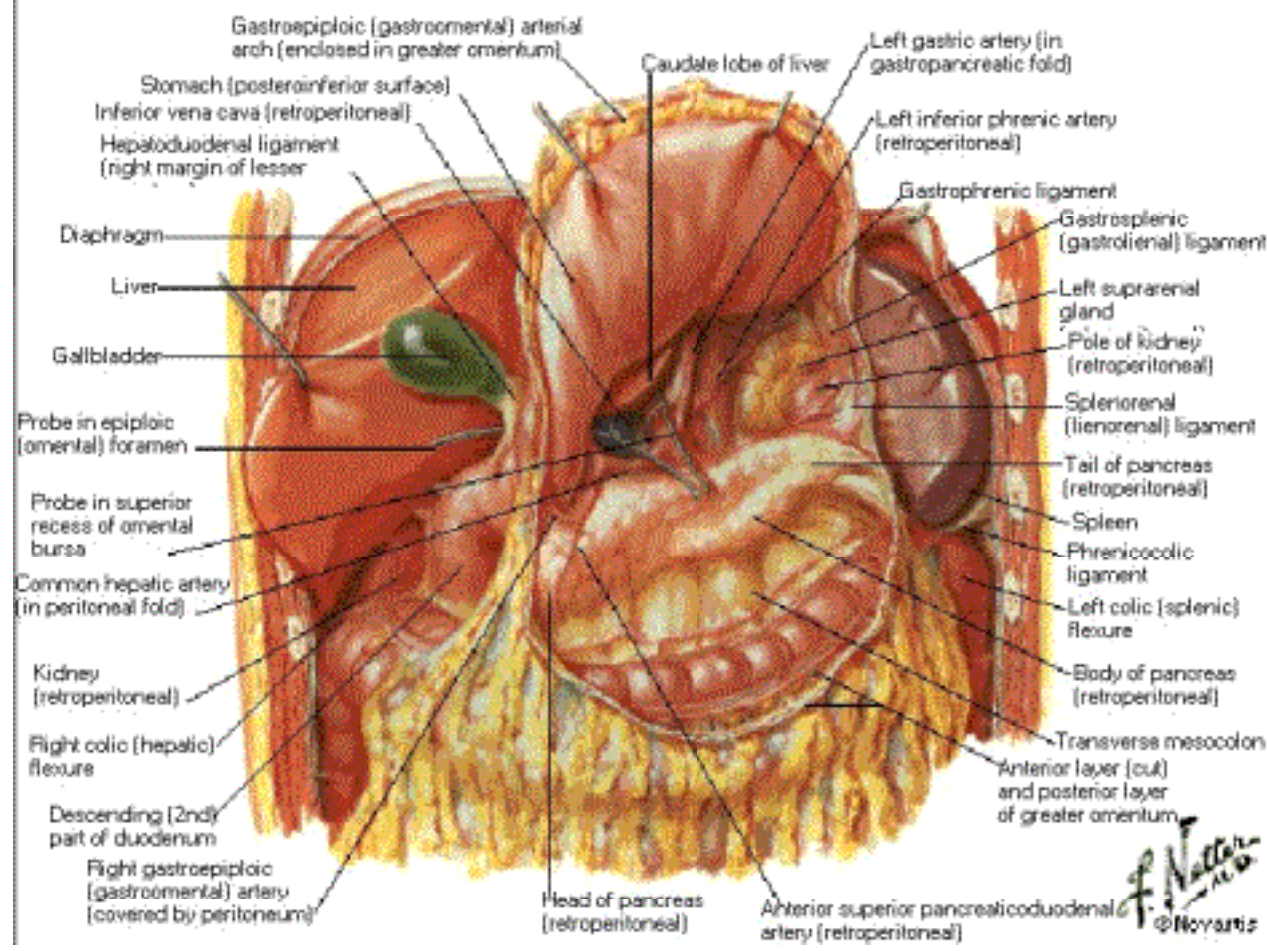


Mesenteric Relations of Intestines

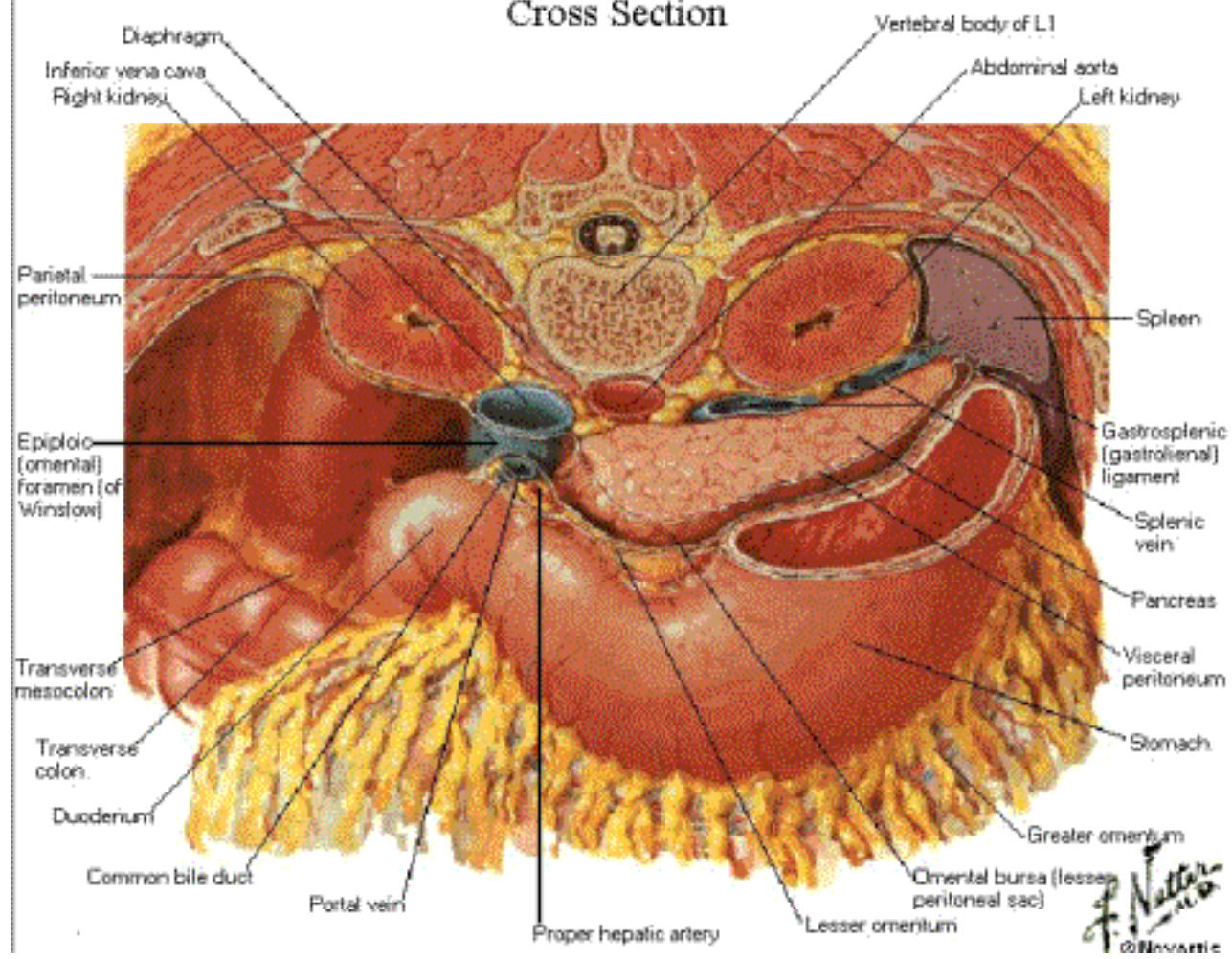
Sigmoid Colon Reflected



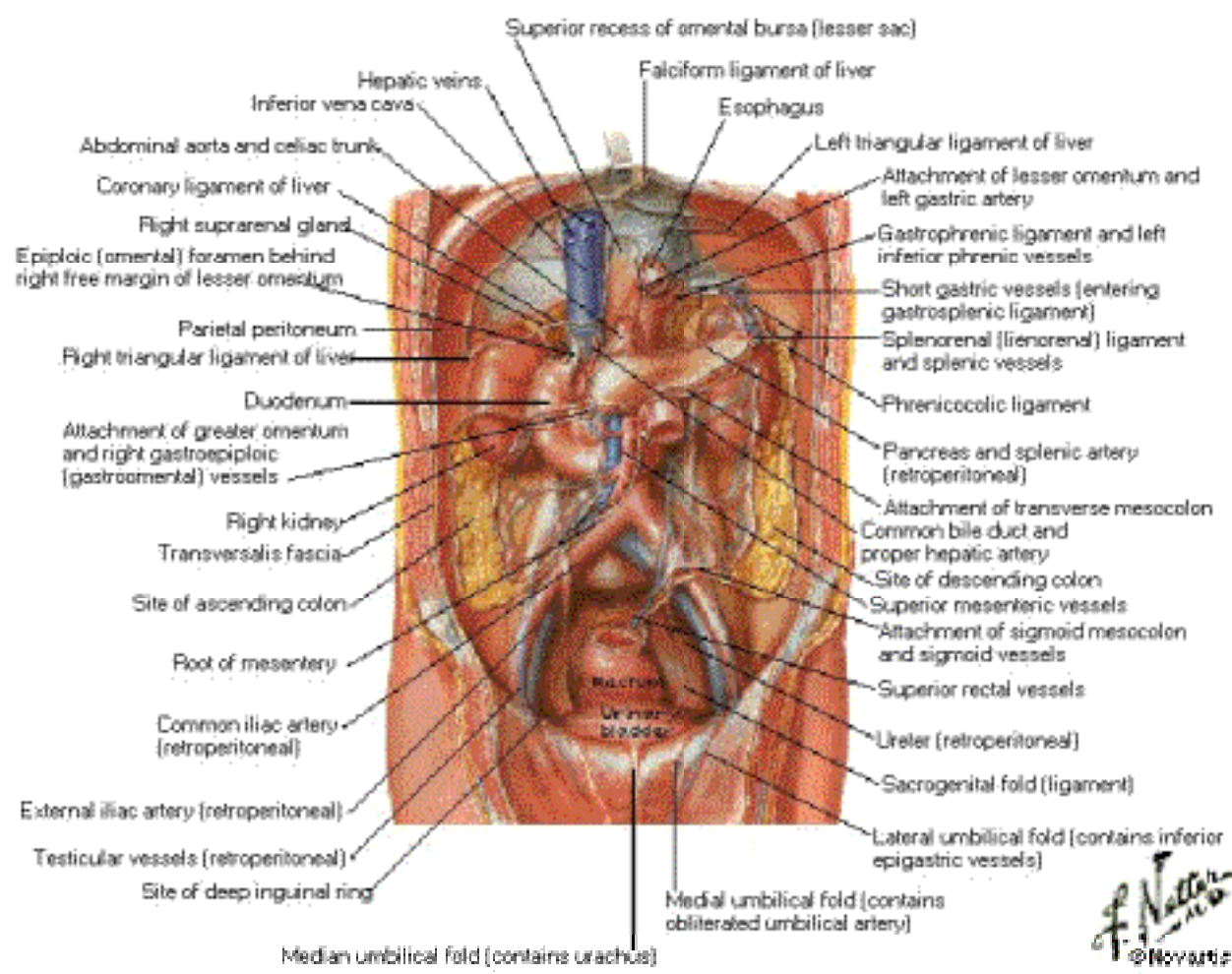
Omental Bursa Stomach Reflected



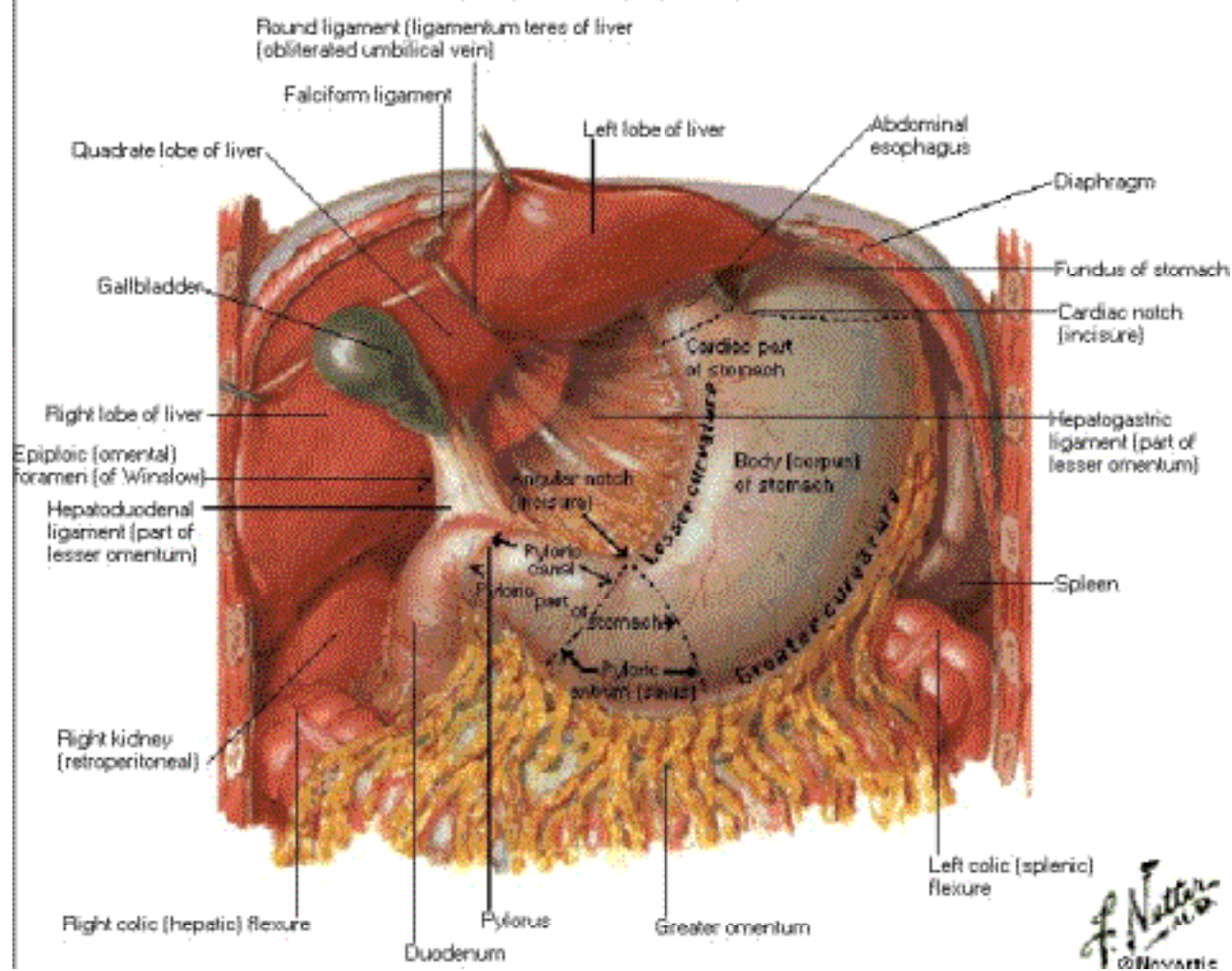
Omental Bursa Cross Section



Peritoneum of Posterior Abdominal Wall

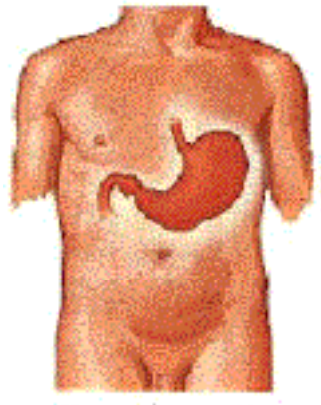


Stomach in Situ

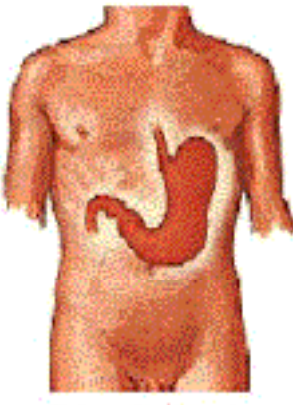

Stomach

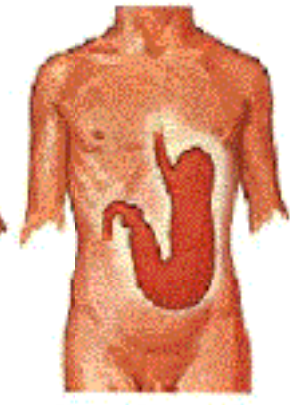
Variations in Position and Contour



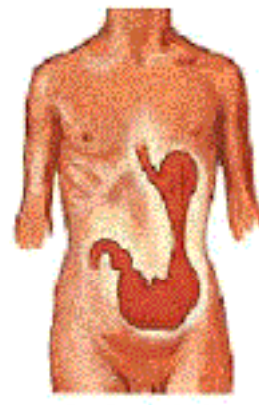Hypertonic stomach



Orthotonic stomach

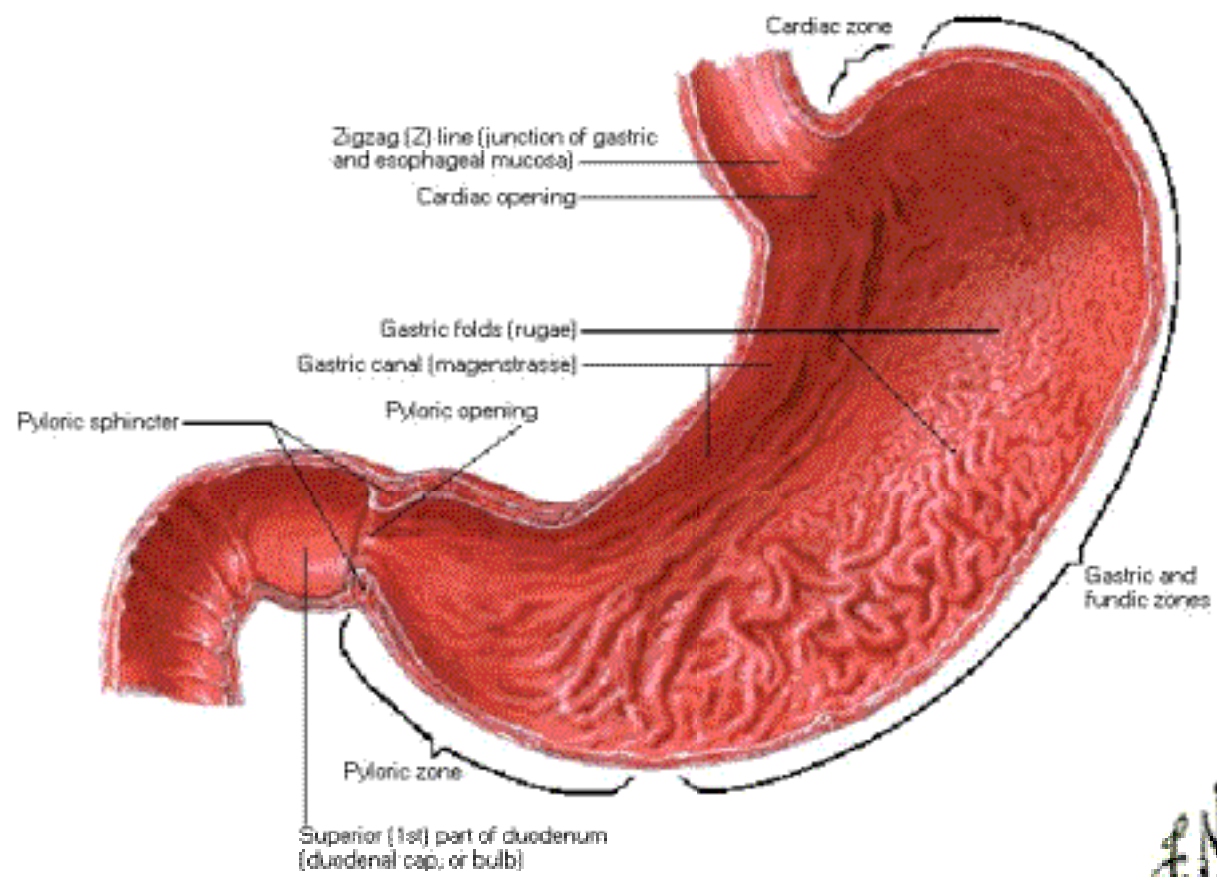


Hypotonic stomach



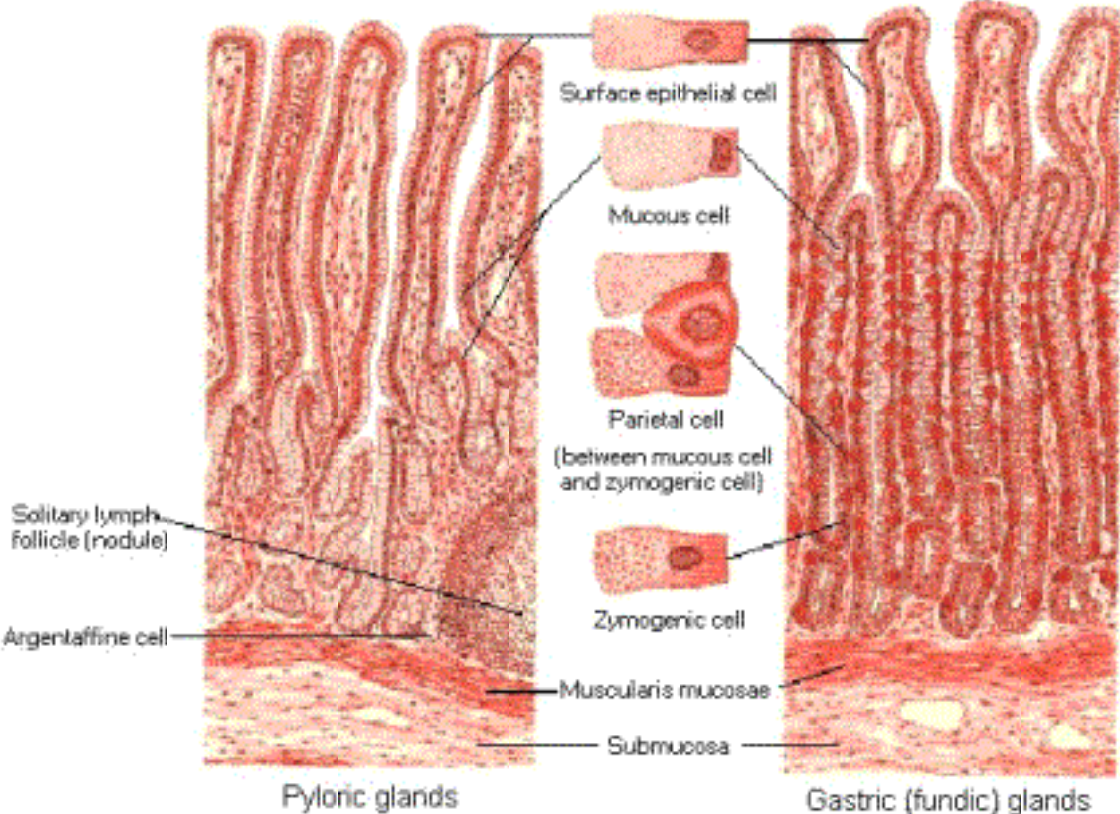
Atonic stomach

Mucosa of Stomach

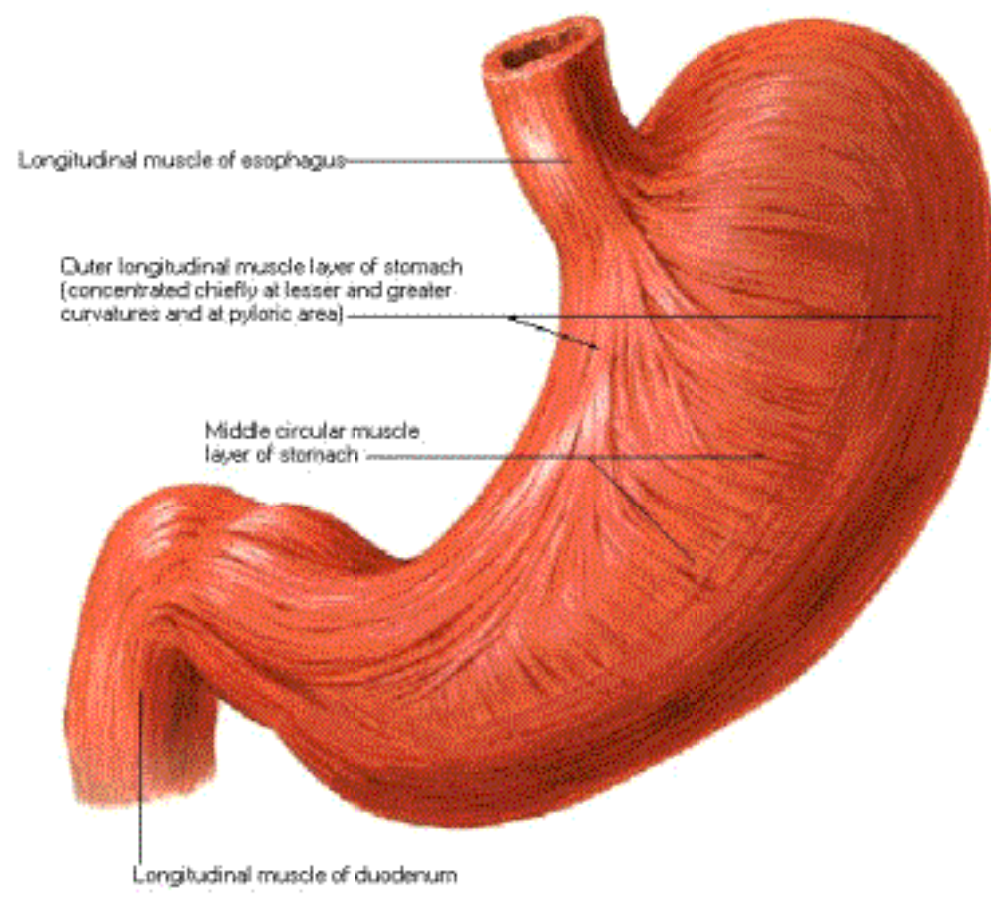


Mucosa of Stomach

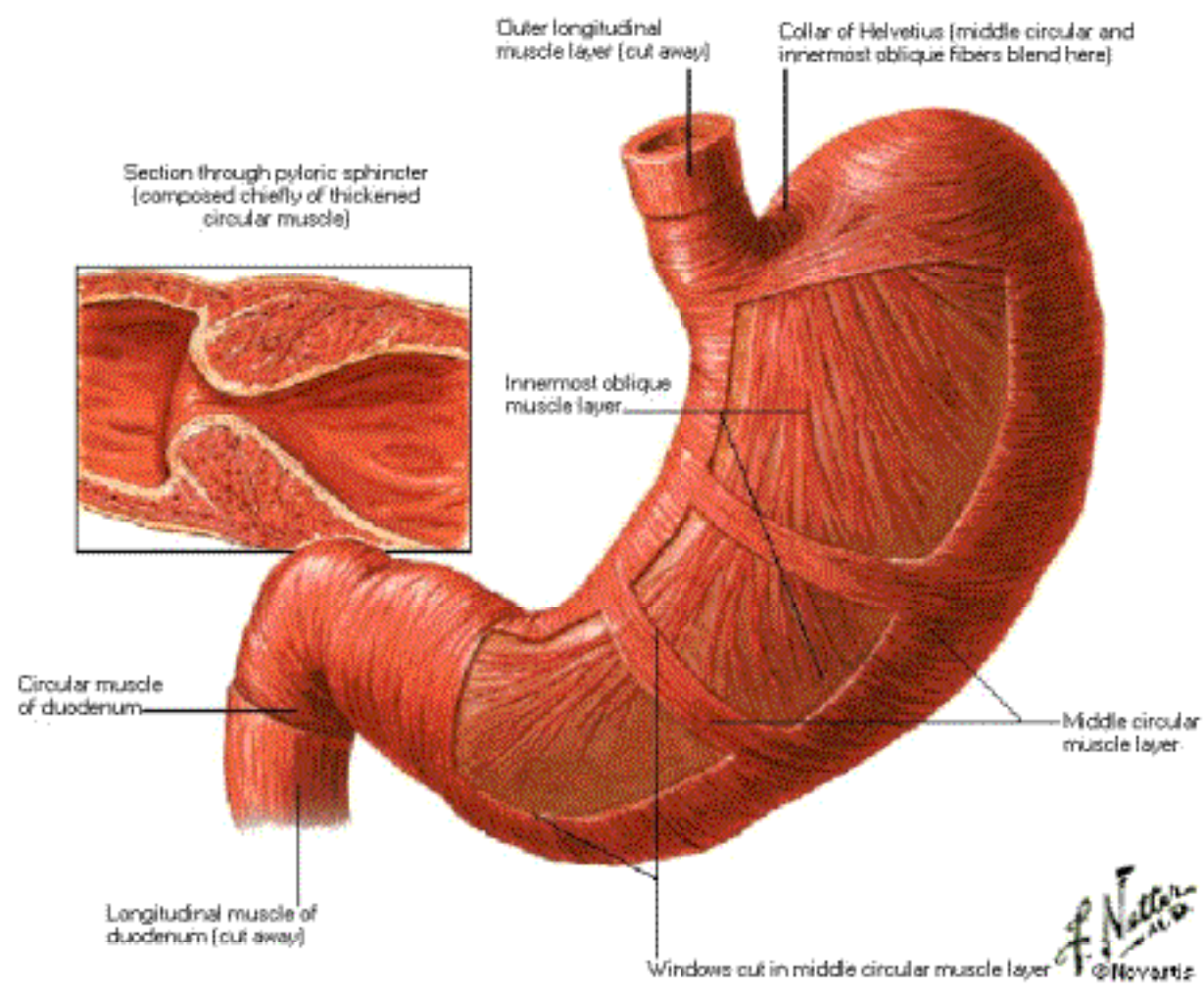
Histology



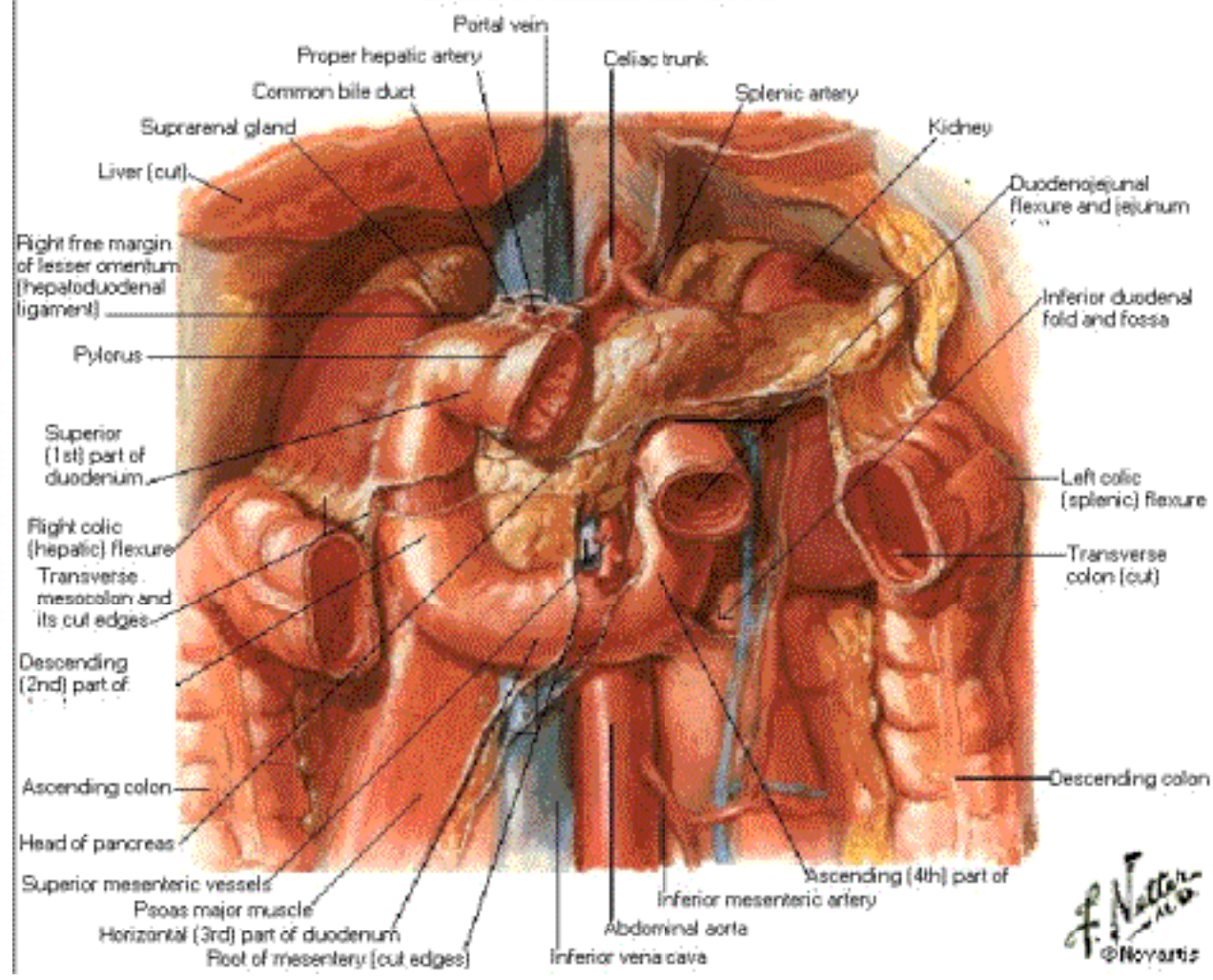
Musculature of Stomach



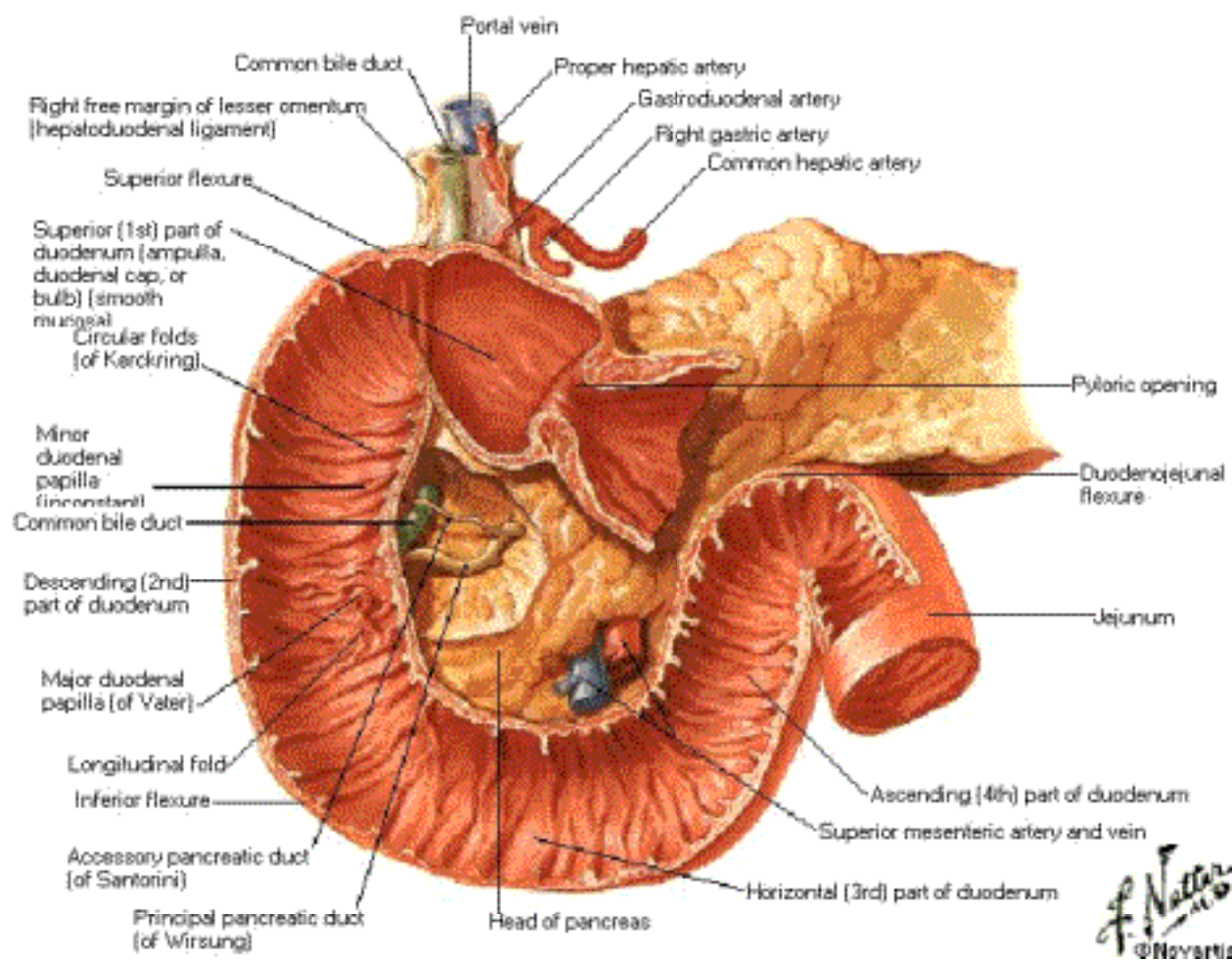
Musculature of Stomach [Continued]



Duodenum in Situ

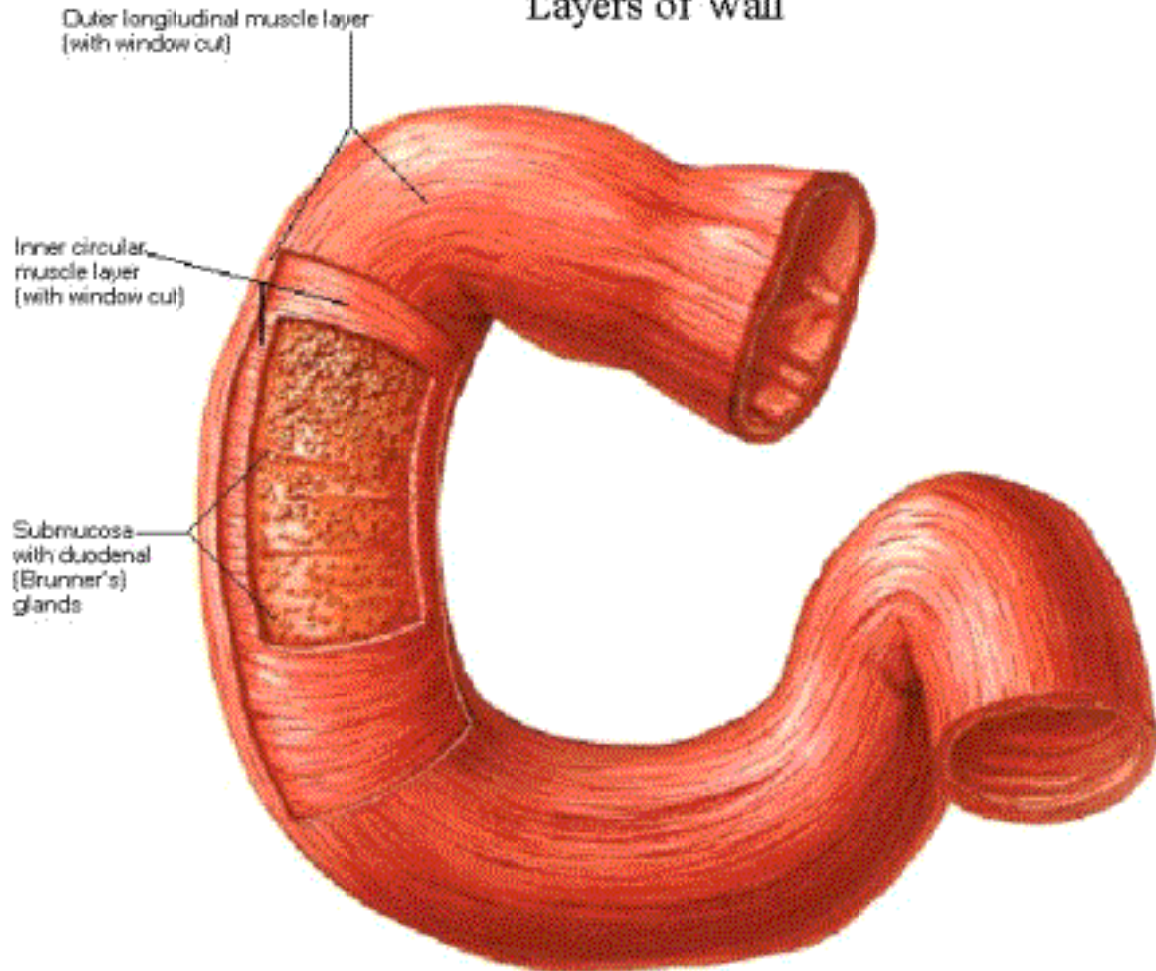


Mucosa of Duodenum

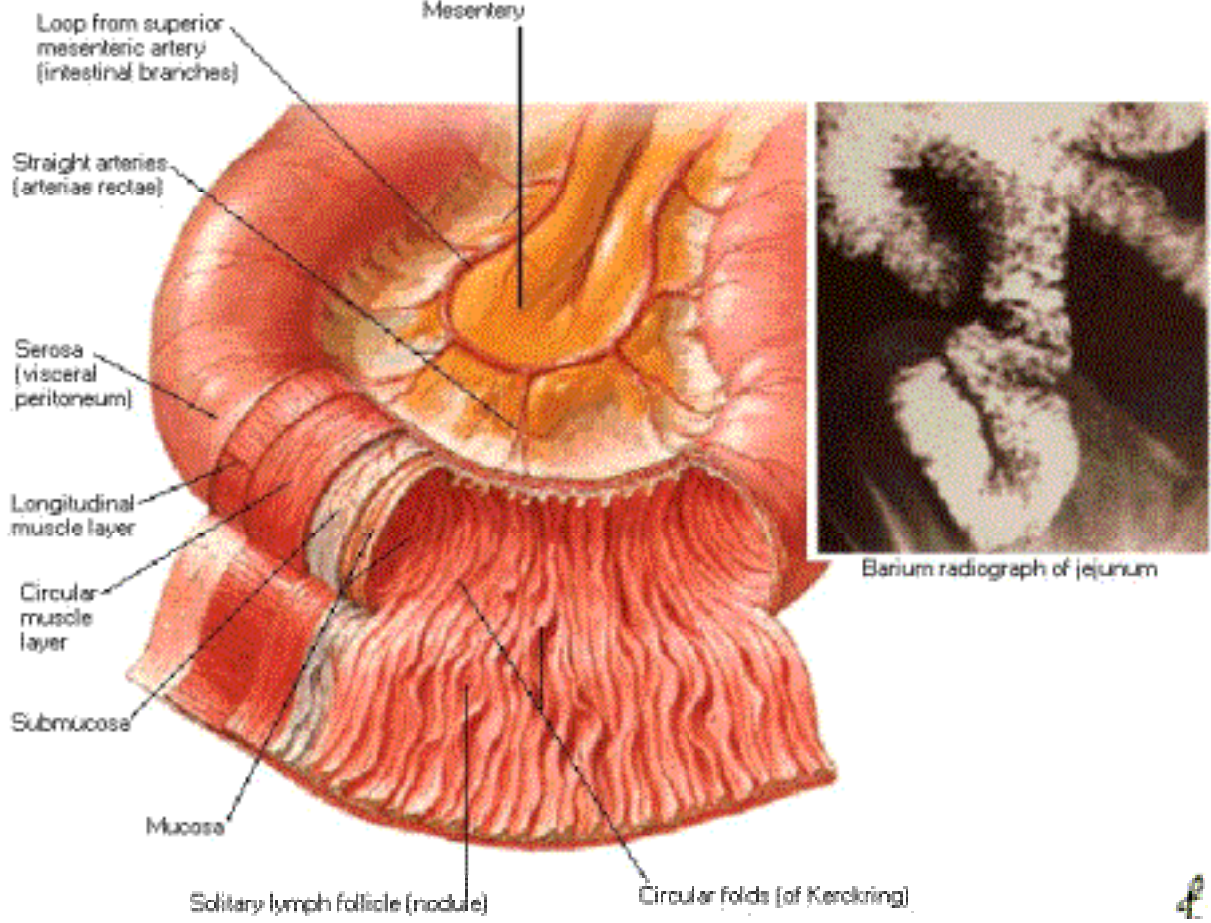


Musculature of Duodenum

Layers of Wall

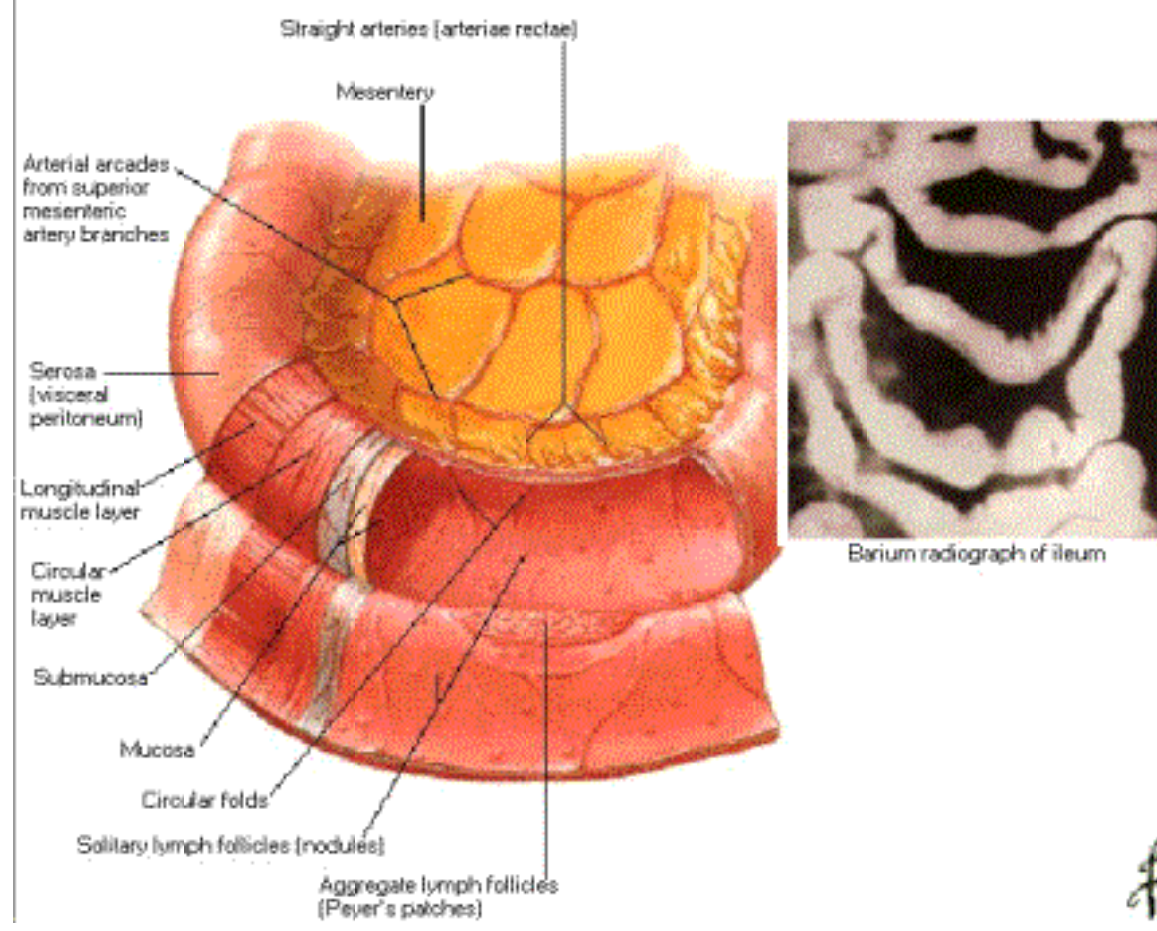


Mucosa and Musculature of Jejunum



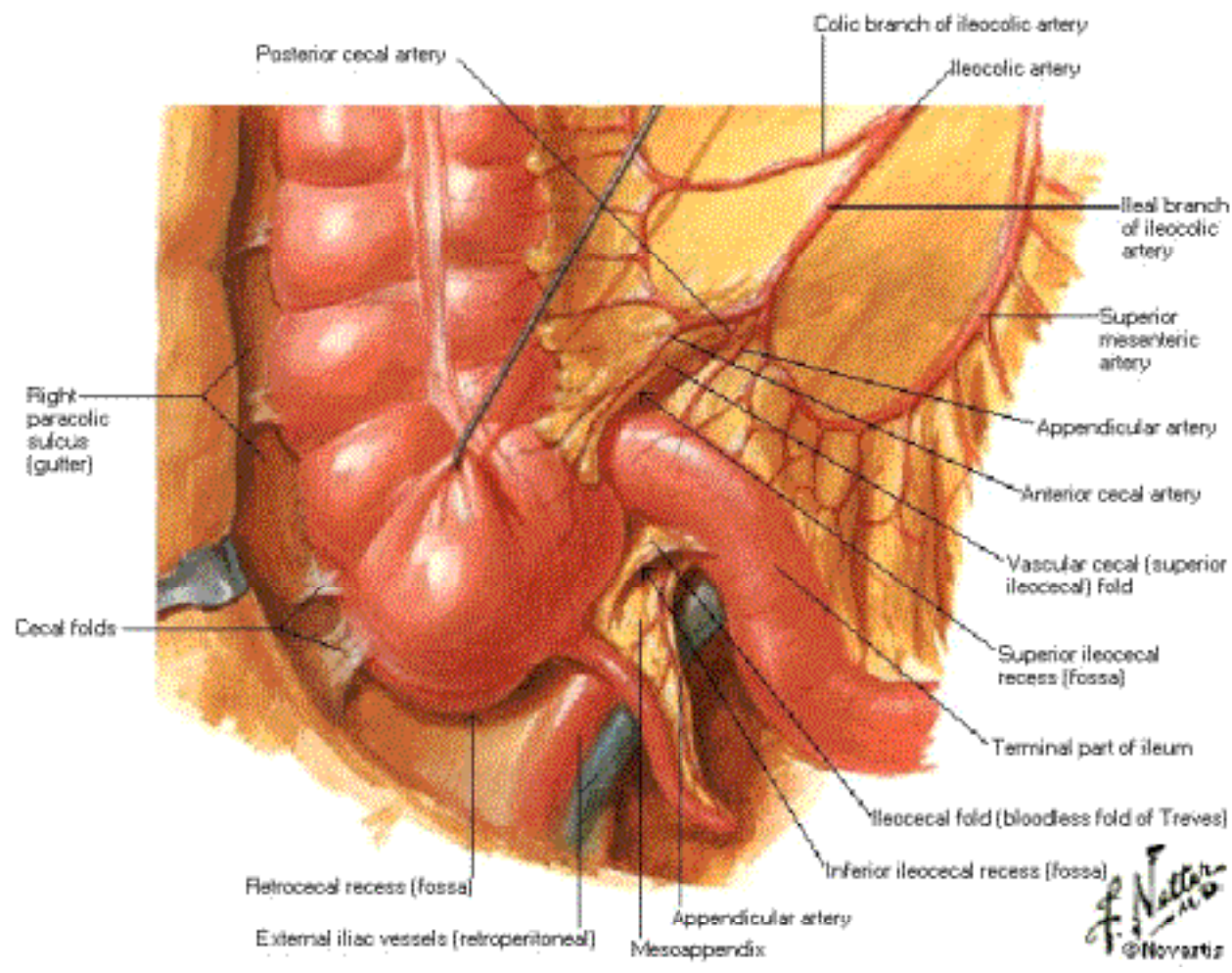
41

Mucosa and Musculature of Ileum



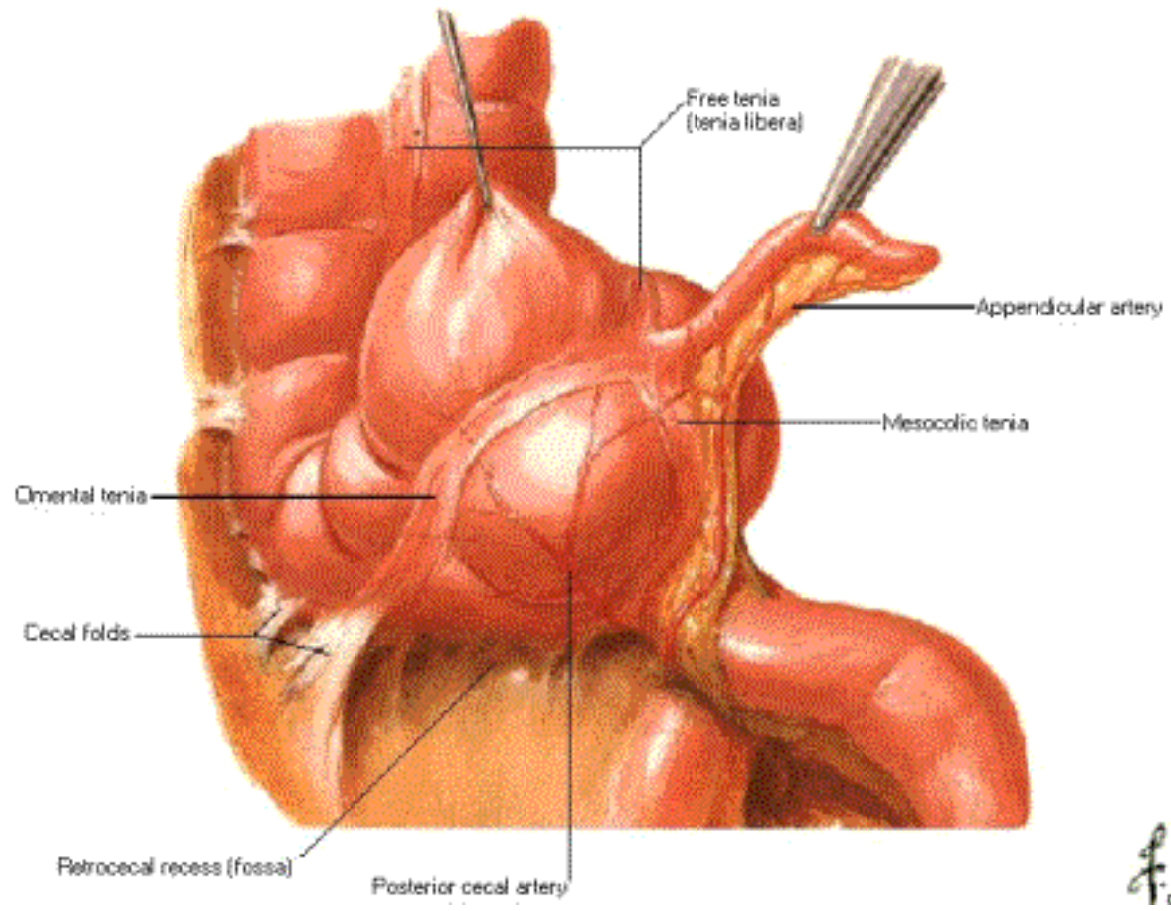
f.

Ileocecal Region



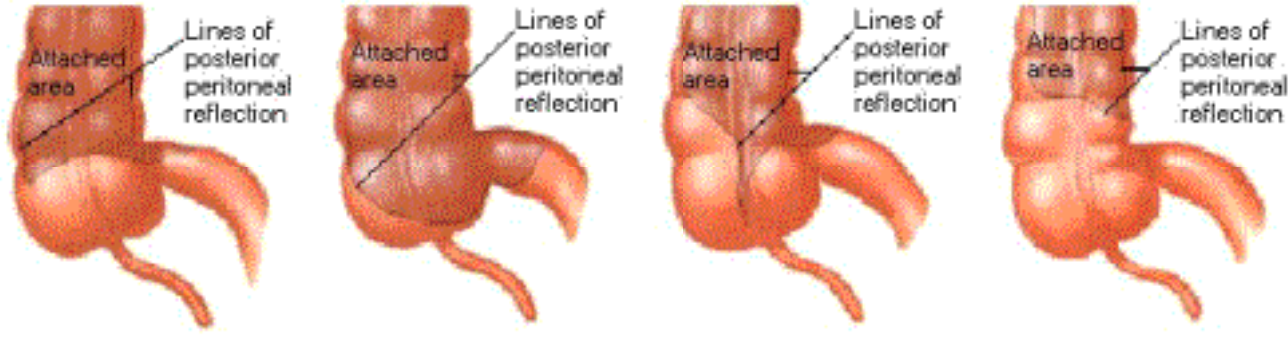
Ileocecal Region

Retrocecal Recess Exposed



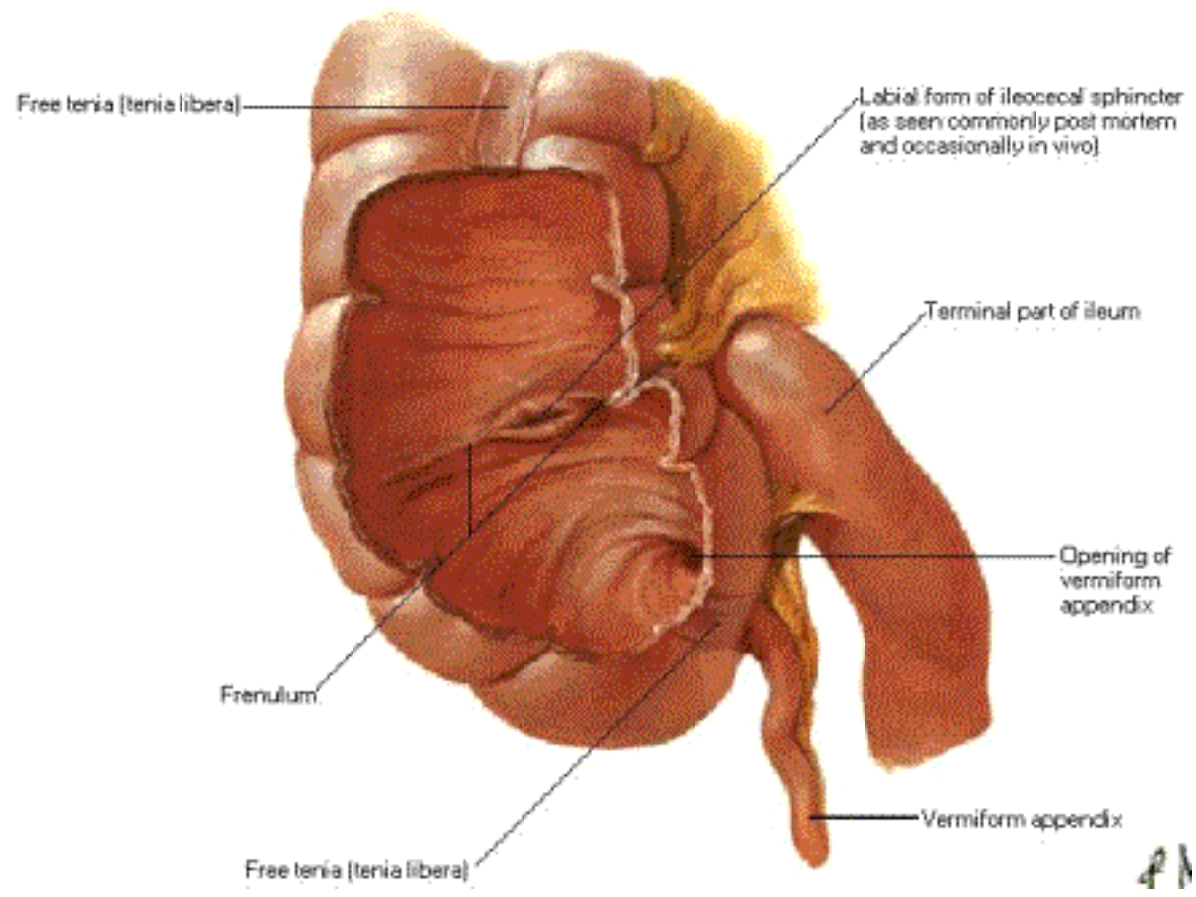
Ileocecal Region

Variations in Posterior Peritoneal Attachment



Ileocecal Region

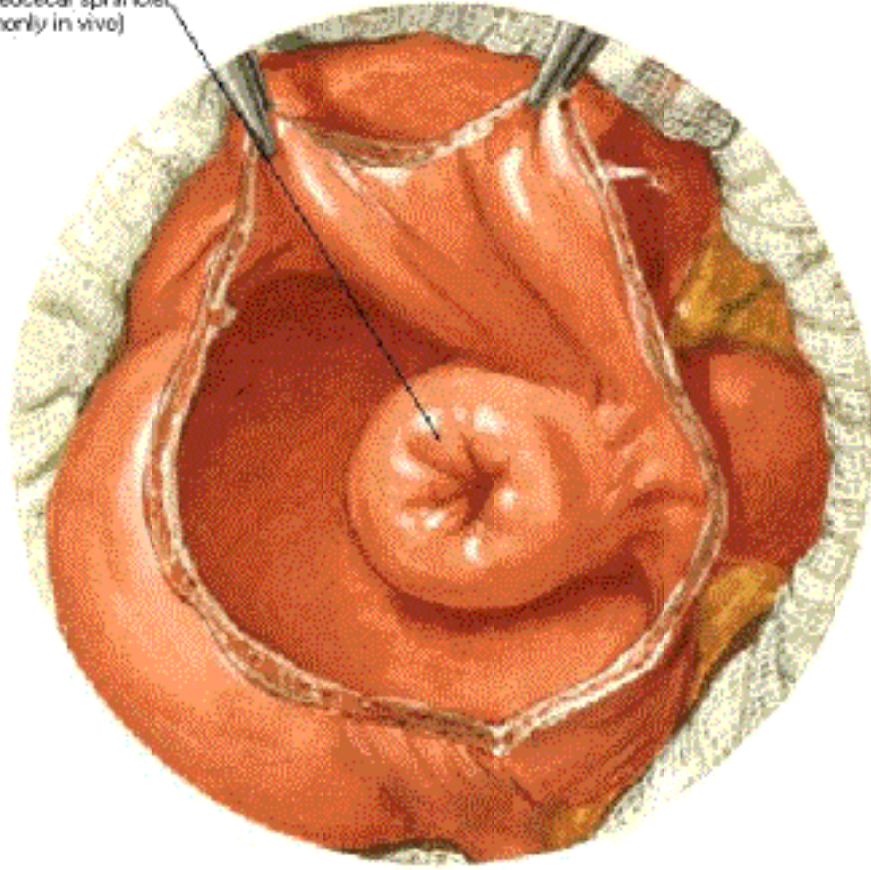
Labial Form of Ileocecal Sphincter



Ileocecal Region

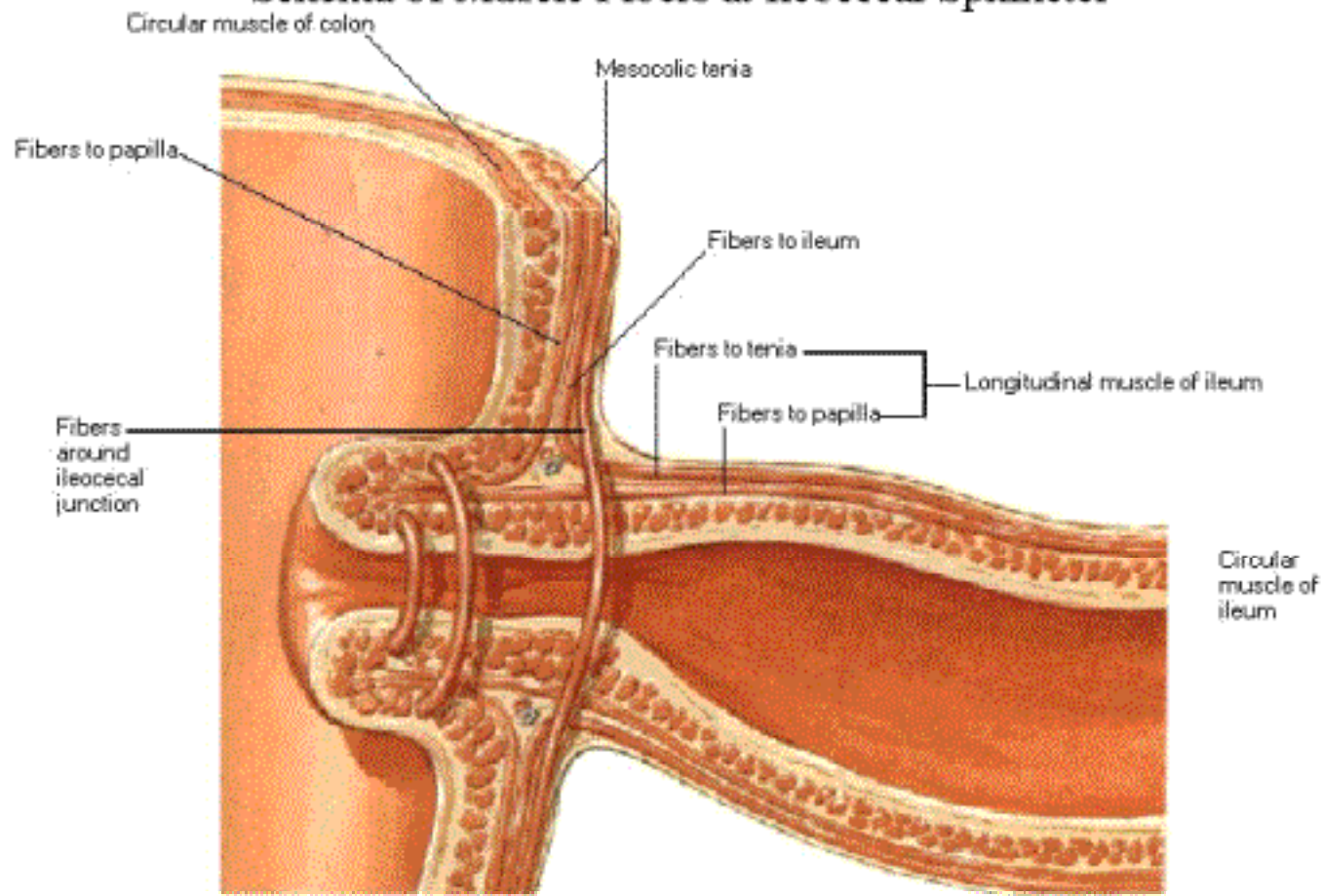
Papillary Form of Ileocecal Sphincter

Papillary form of ileocecal sphincter
(found most commonly in vivo)

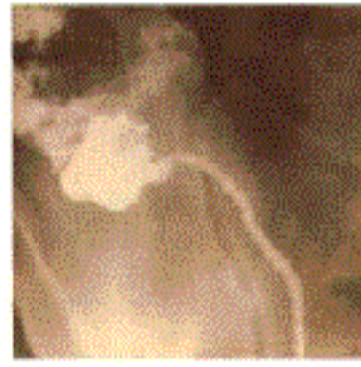
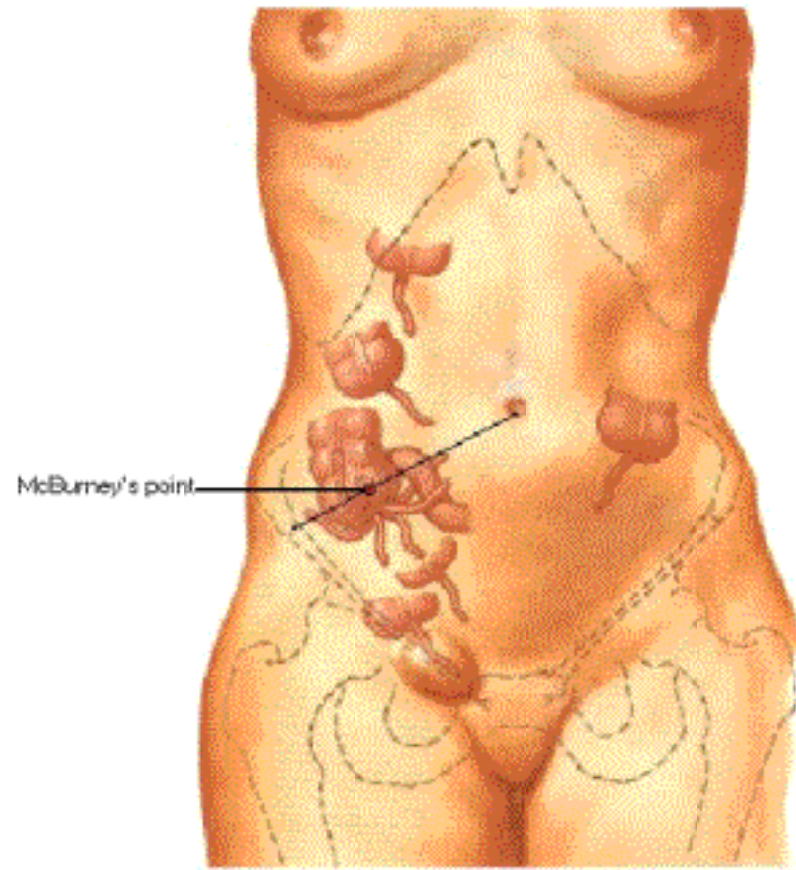


Ileocecal Region

Schema of Muscle Fibers at Ileocecal Sphincter



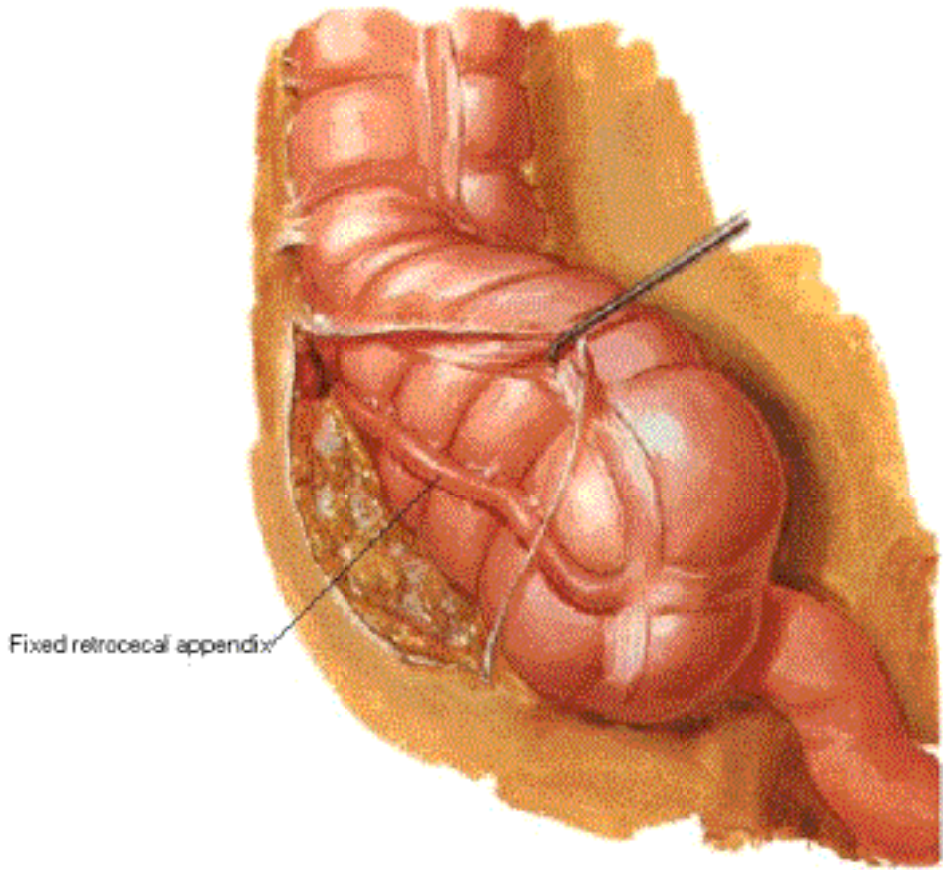
Vermiform Appendix Variations in Position



Unusually long appendix
extending into pelvis (barium
radiograph)

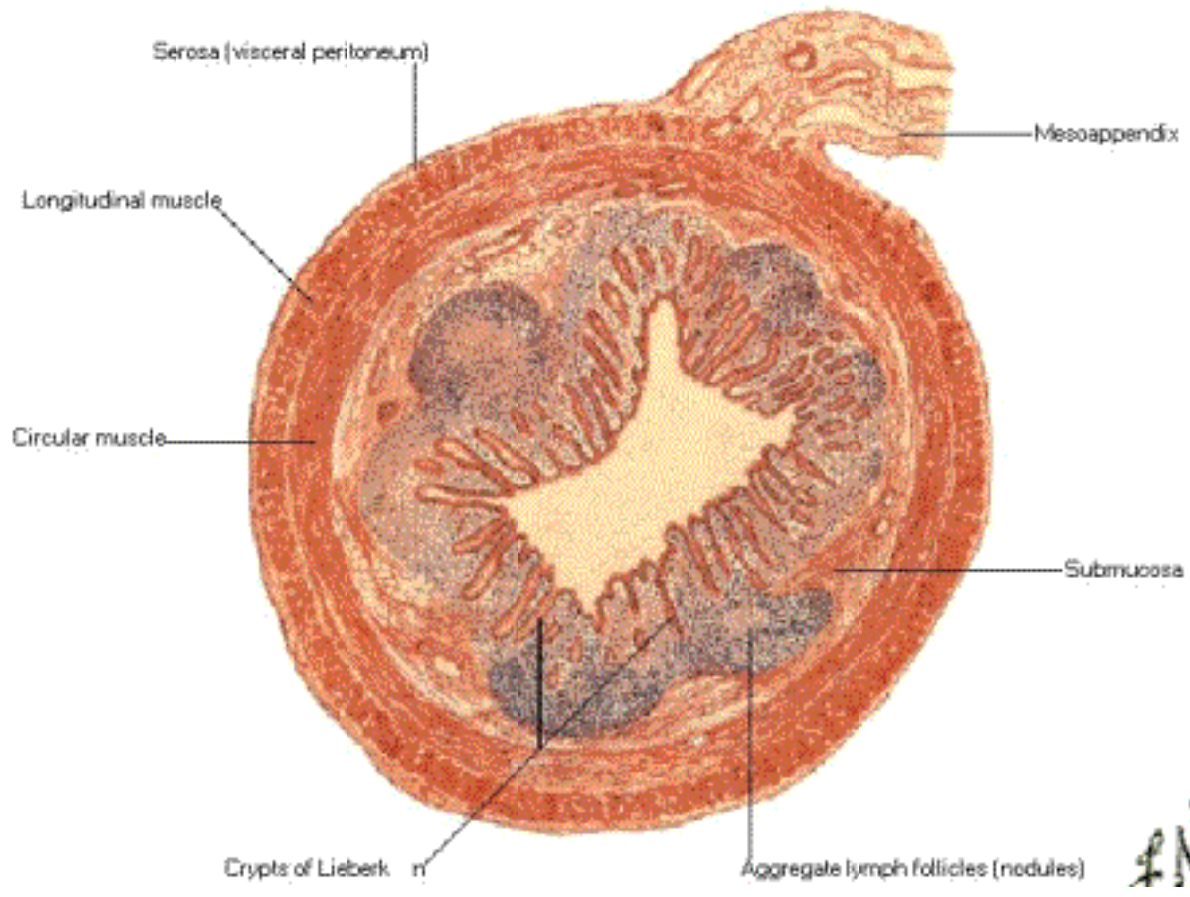
Vermiform Appendix

Fixed Retrocecal

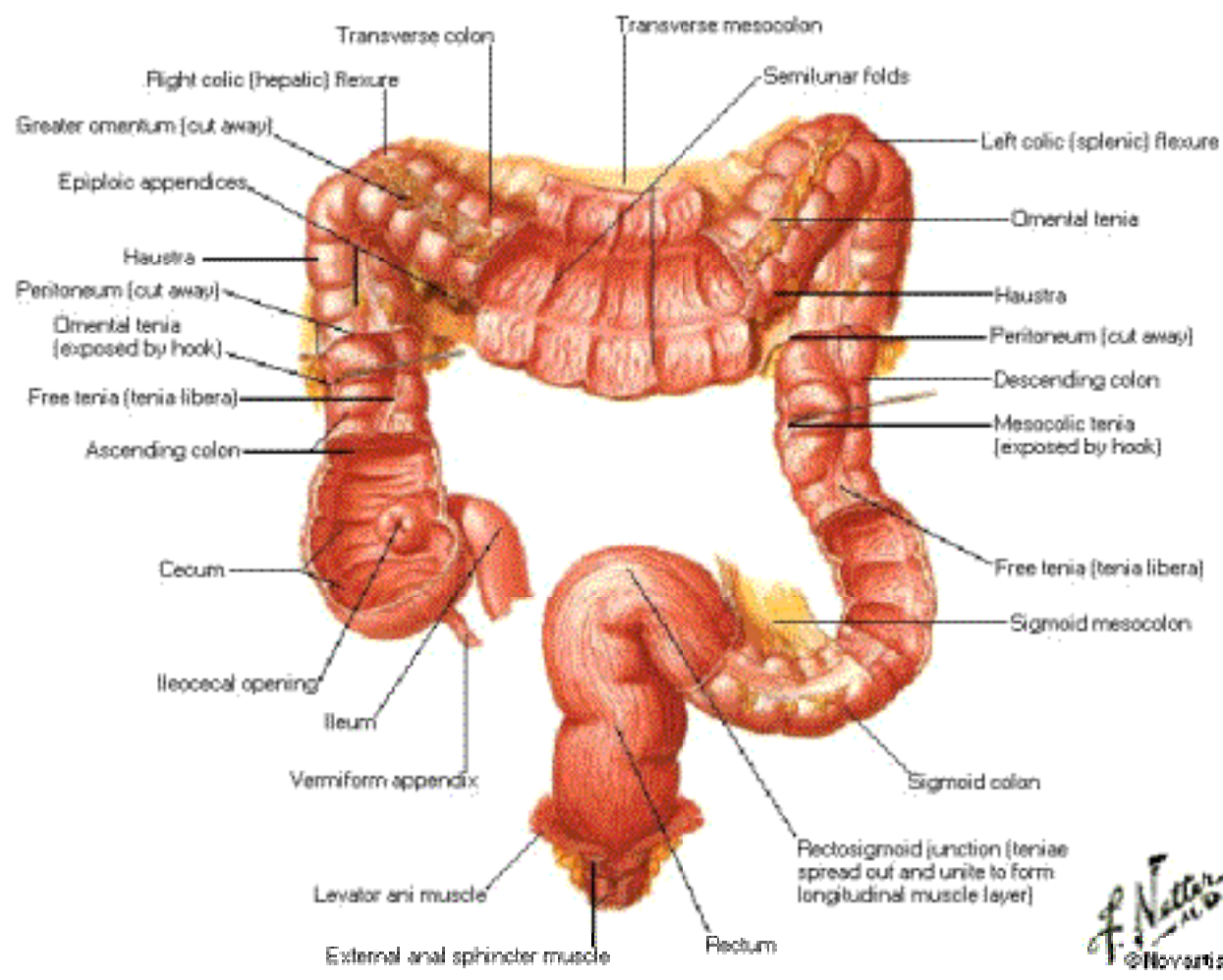


Fixed retrocecal appendix

Vermiform Appendix Cross Section

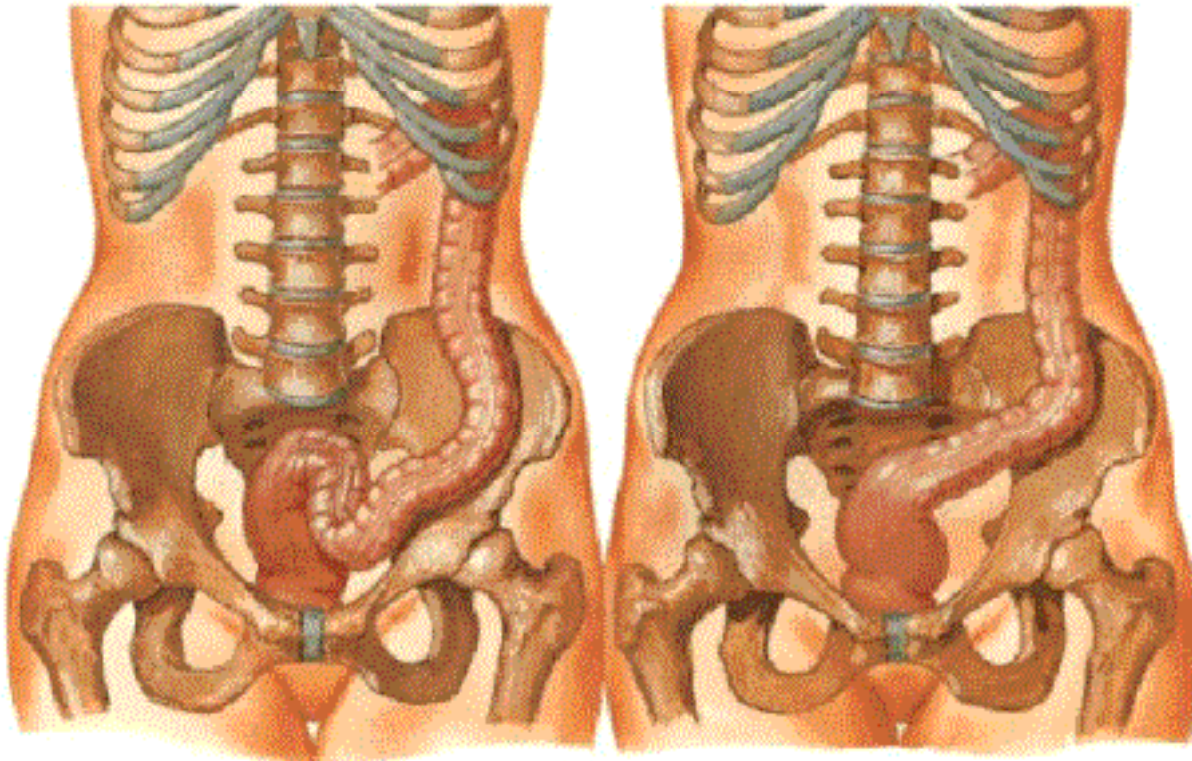


Mucosa and Musculature of Large Intestine



Sigmoid Colon

Variations in Position

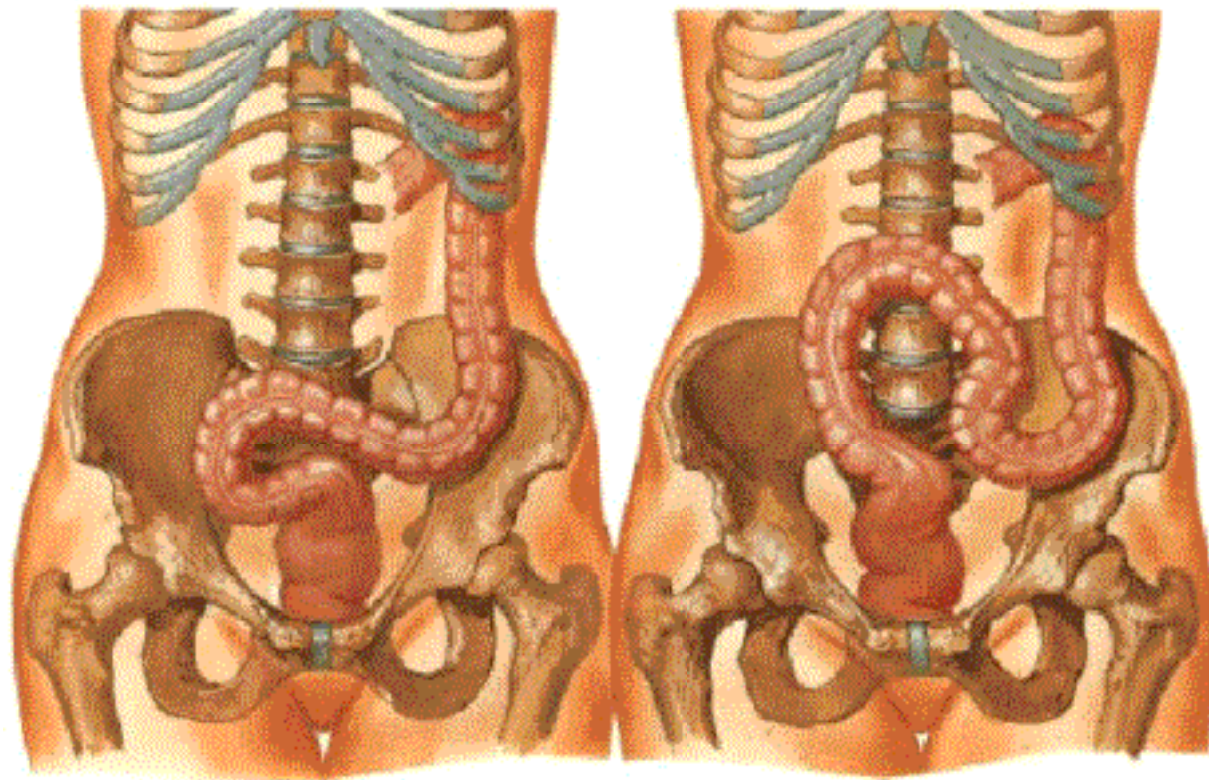


Typical

Short, straight, obliquely into pelvis

Sigmoid Colon [Continued]

Variations in Position

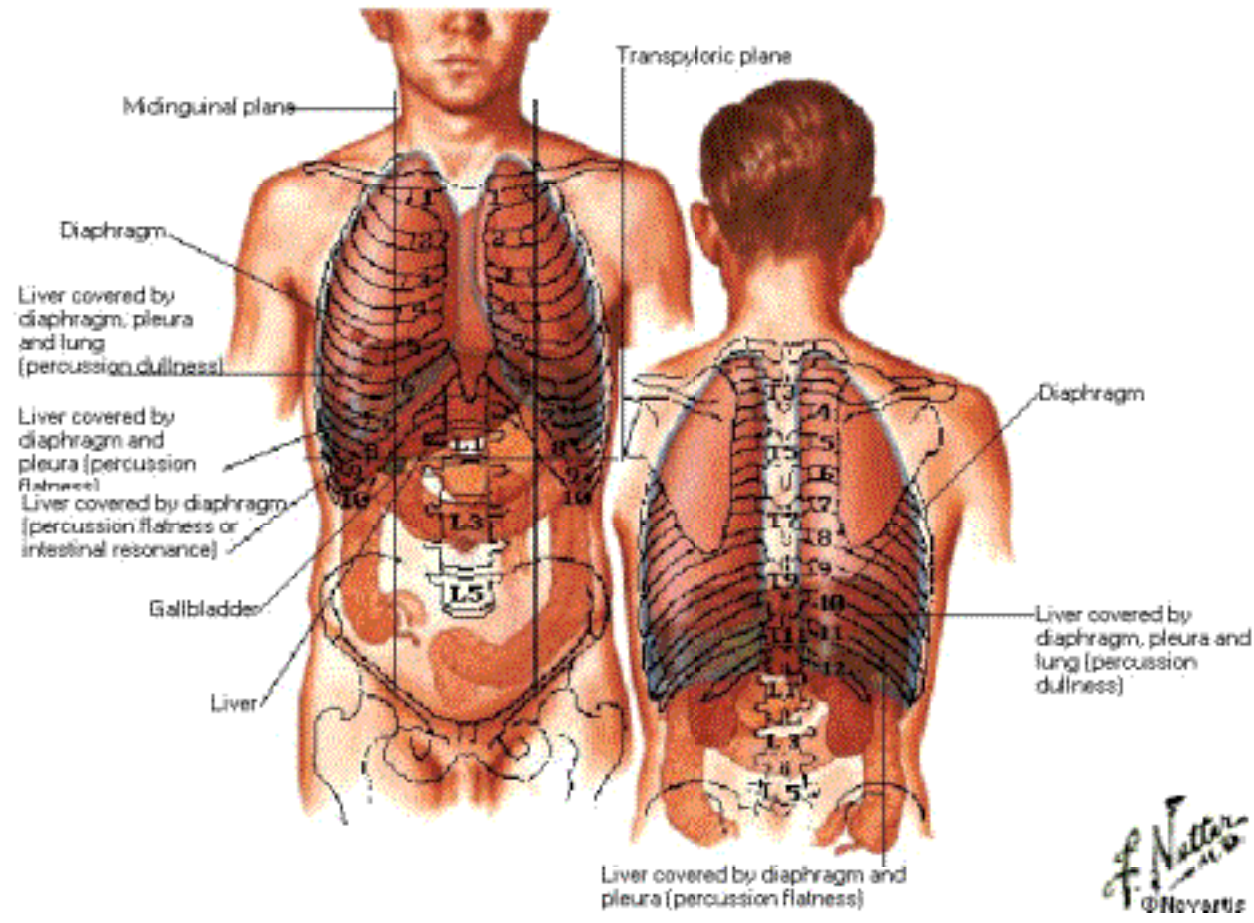


Looping to right side

Ascending high into abdomen

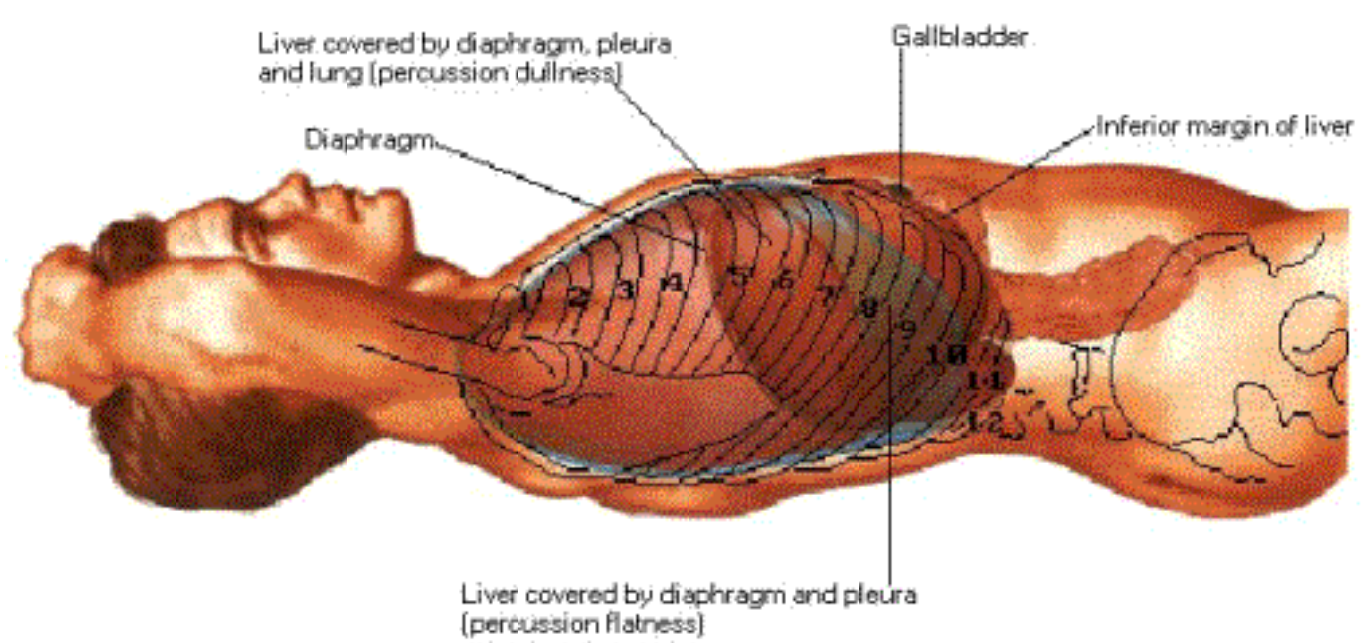
Topography of Liver

Anterior and Posterior Views



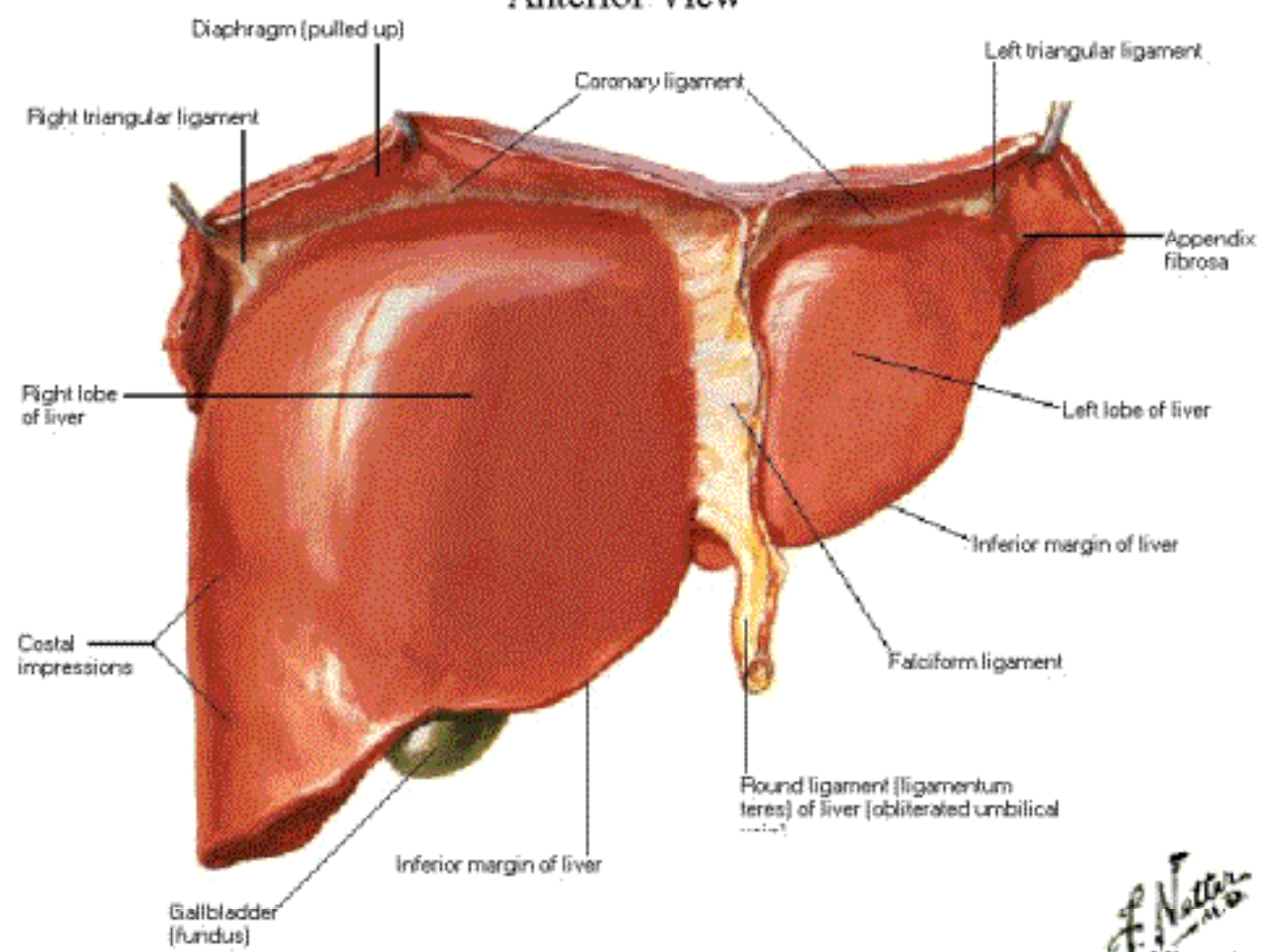
Topography of Liver

Lateral View



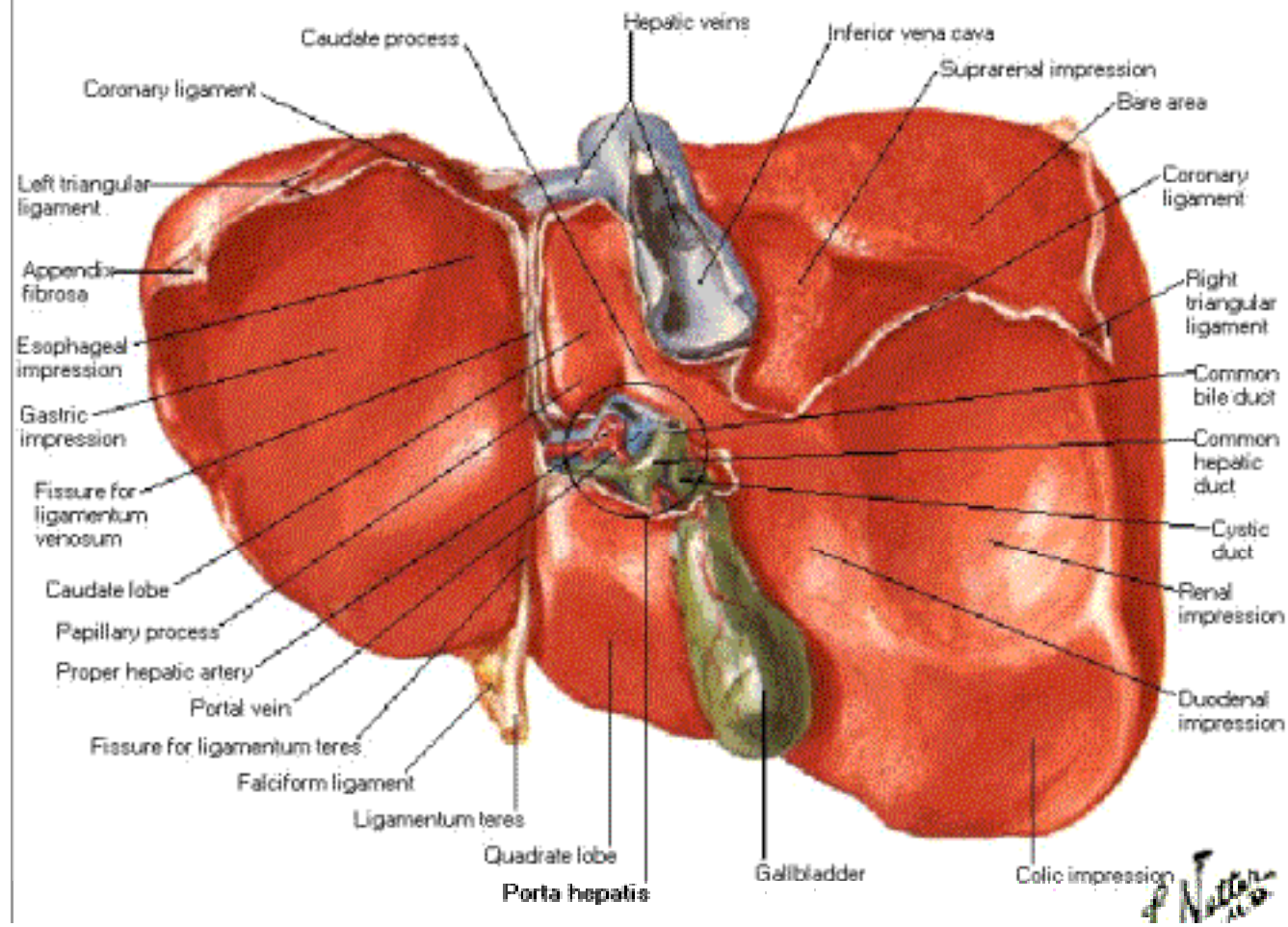
Surfaces and Bed of Liver

Anterior View



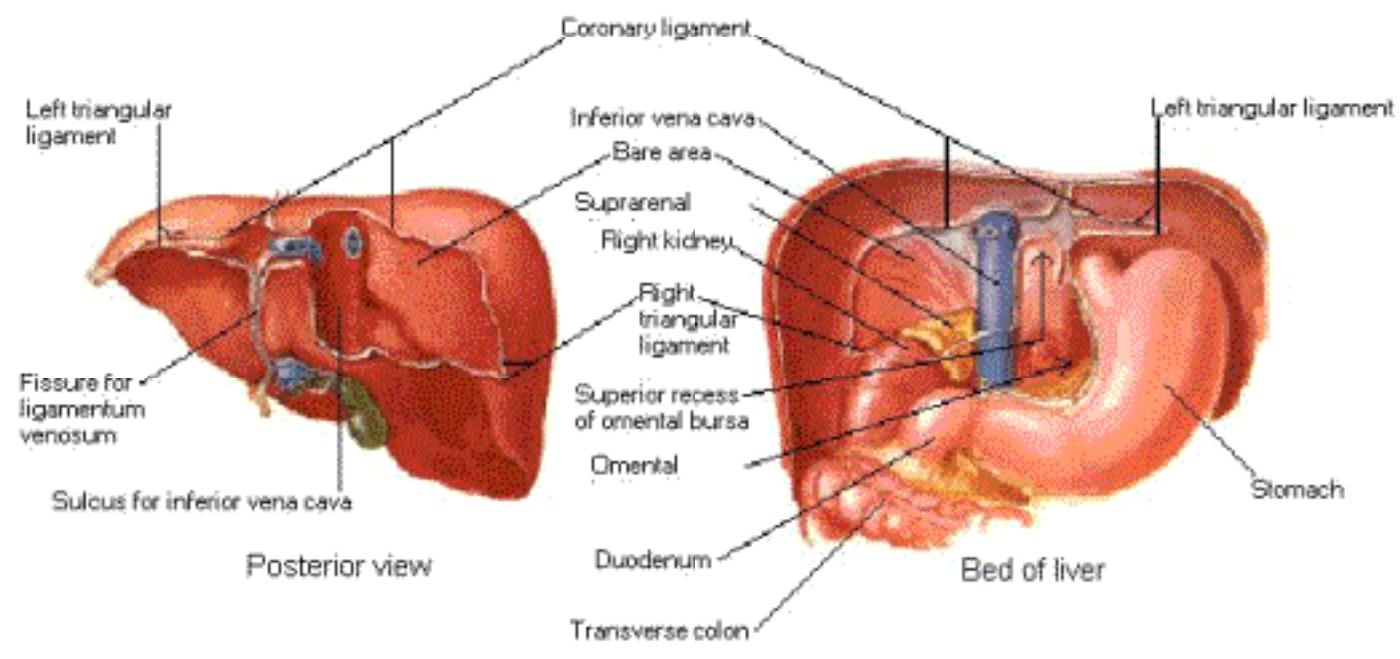
Surfaces and Bed of Liver

Visceral Surface

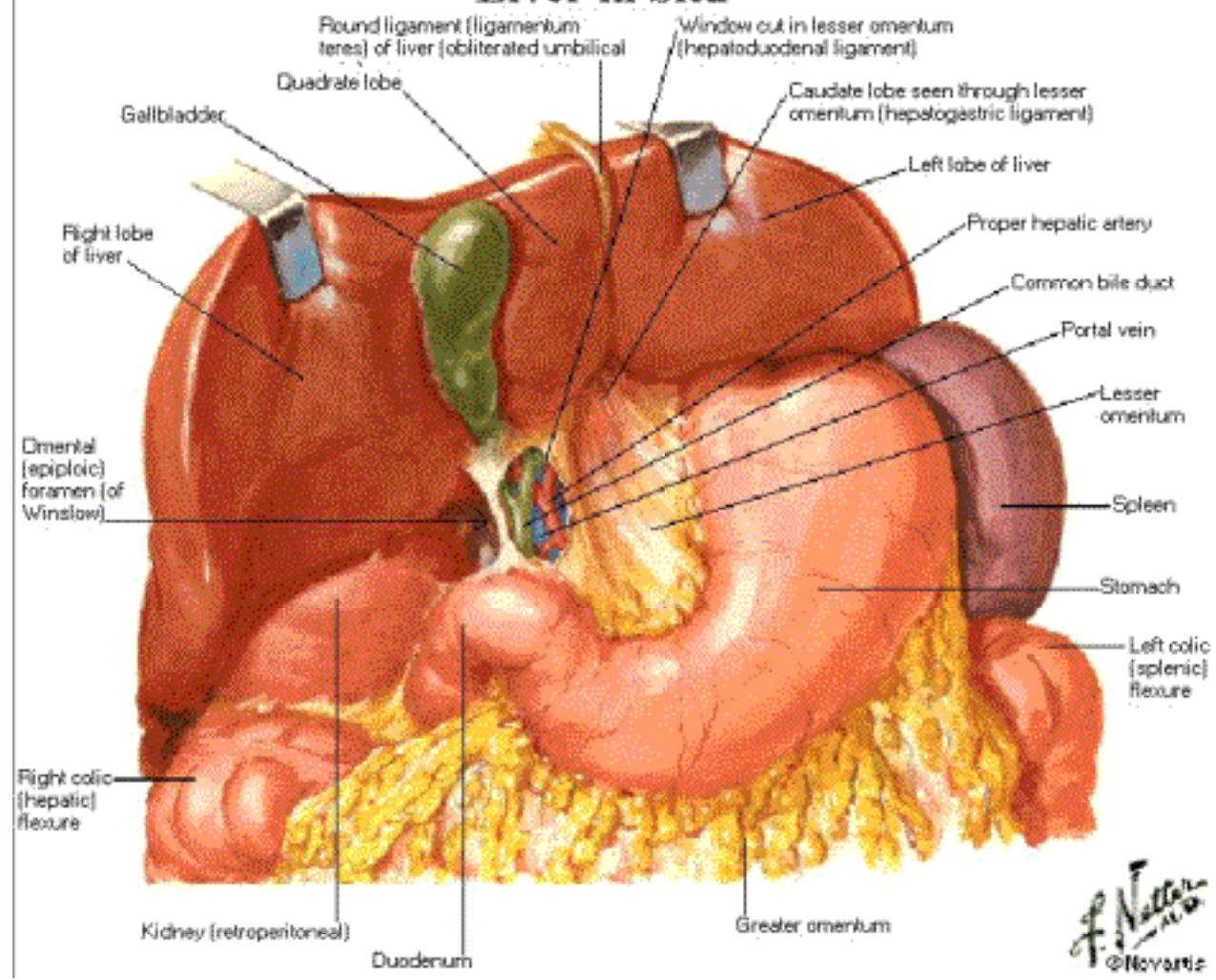


Surfaces and Bed of Liver

Posterior View and Bed of Liver

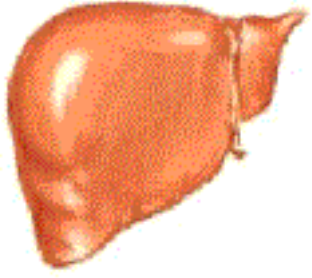

Liver in Situ



Variations in Form of Liver

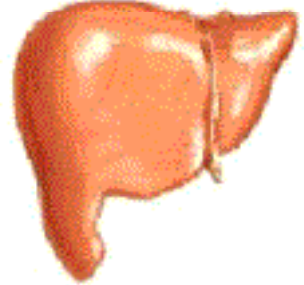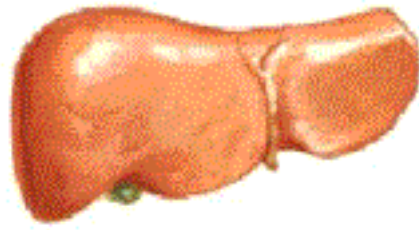
Very small left lobe,
deep costal
impressions



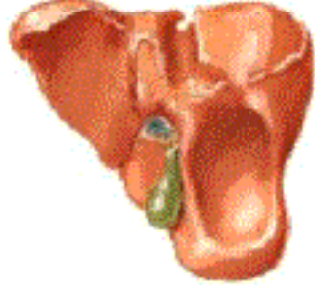Complete atrophy of left
lobe (left portal vein
compression)



Transverse,
"saddlelike" liver,
relatively large left lobe



"Tonguelike" process
of right lobe



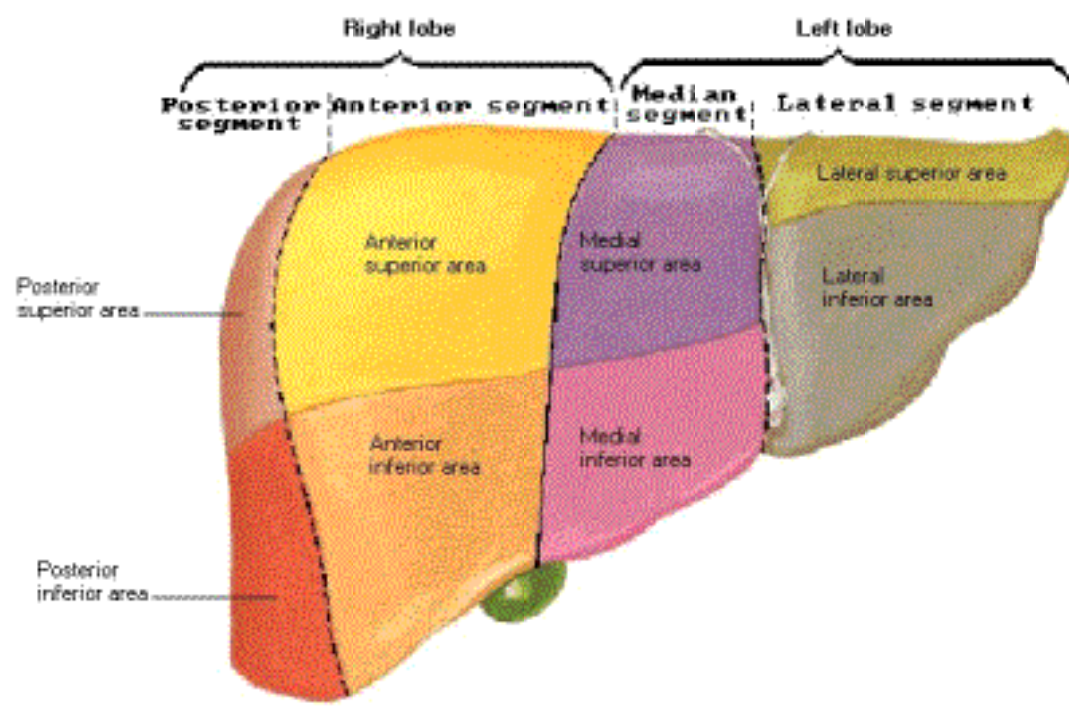
Very deep renal
impression and
"corset constriction"



Diaphragmatic
grooves.

Liver Segments and Lobules

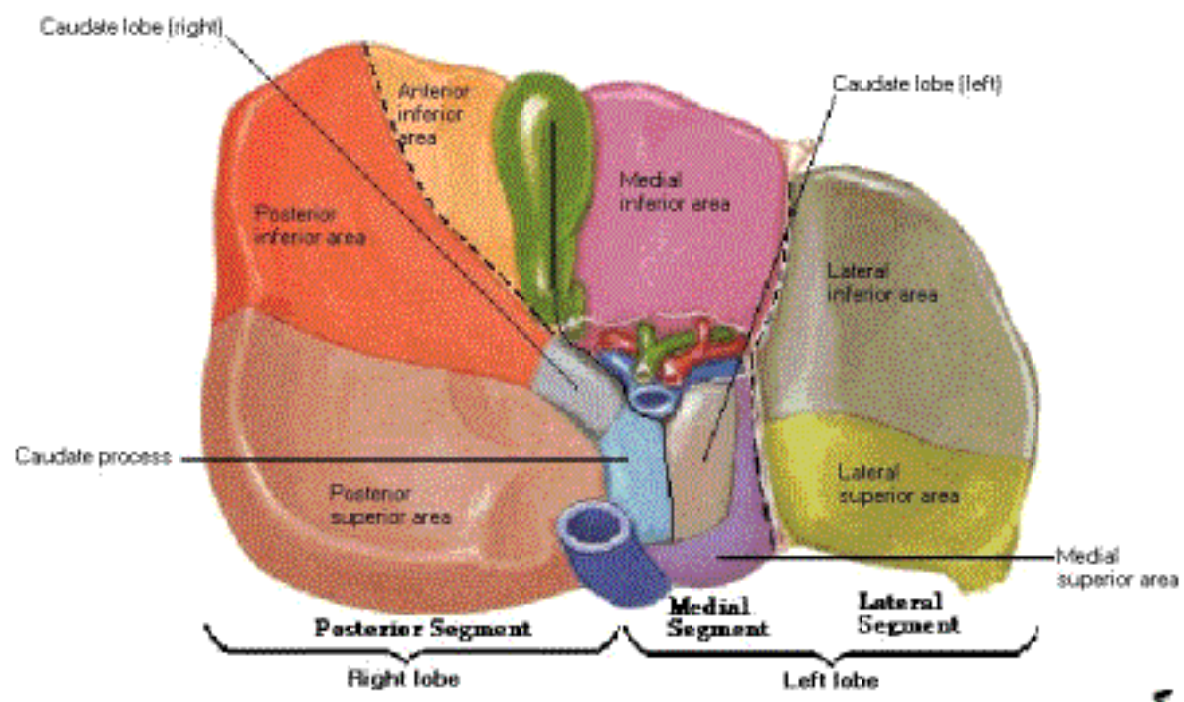
Parietal Surface



Division into segments is based upon ramifications of bile ducts and hepatic vessels. It does not entirely correspond with division into lobes

Liver Segments and Lobules

Visceral Surface

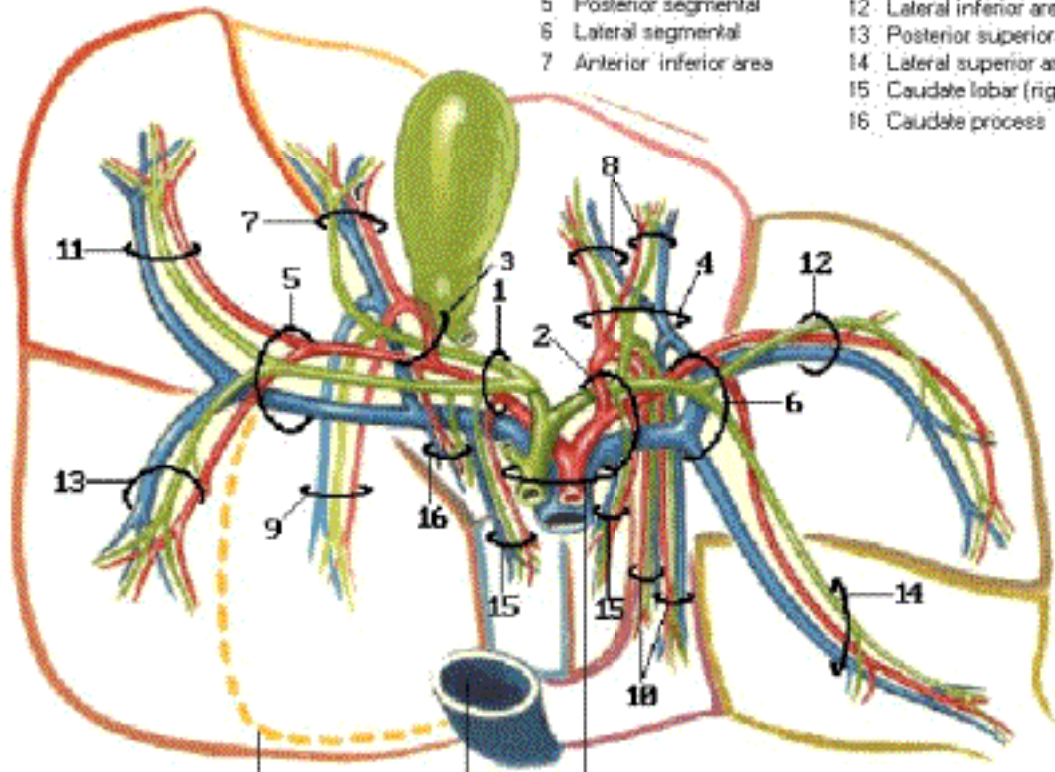


Division into segments is based upon ramifications of bile ducts and hepatic vessels. It does not entirely correspond with division into lobes

F. N. S.
© Nov

Distribution of Vessels and Ducts of Liver

- | | |
|---------------------------|------------------------------------|
| 1. Right lobar | 8. Medial inferior area |
| 2. Left lobar | 9. Anterior superior area |
| 3. Anterior segmental | 10. Medial superior area |
| 4. Medial segmental | 11. Posterior inferior area |
| 5. Posterior segmental | 12. Lateral inferior area |
| 6. Lateral segmental | 13. Posterior superior area |
| 7. Anterior inferior area | 14. Lateral superior area |
| | 15. Caudate lobar (right and left) |
| | 16. Caudate process |



Phantom division between anterior and posterior superior areas

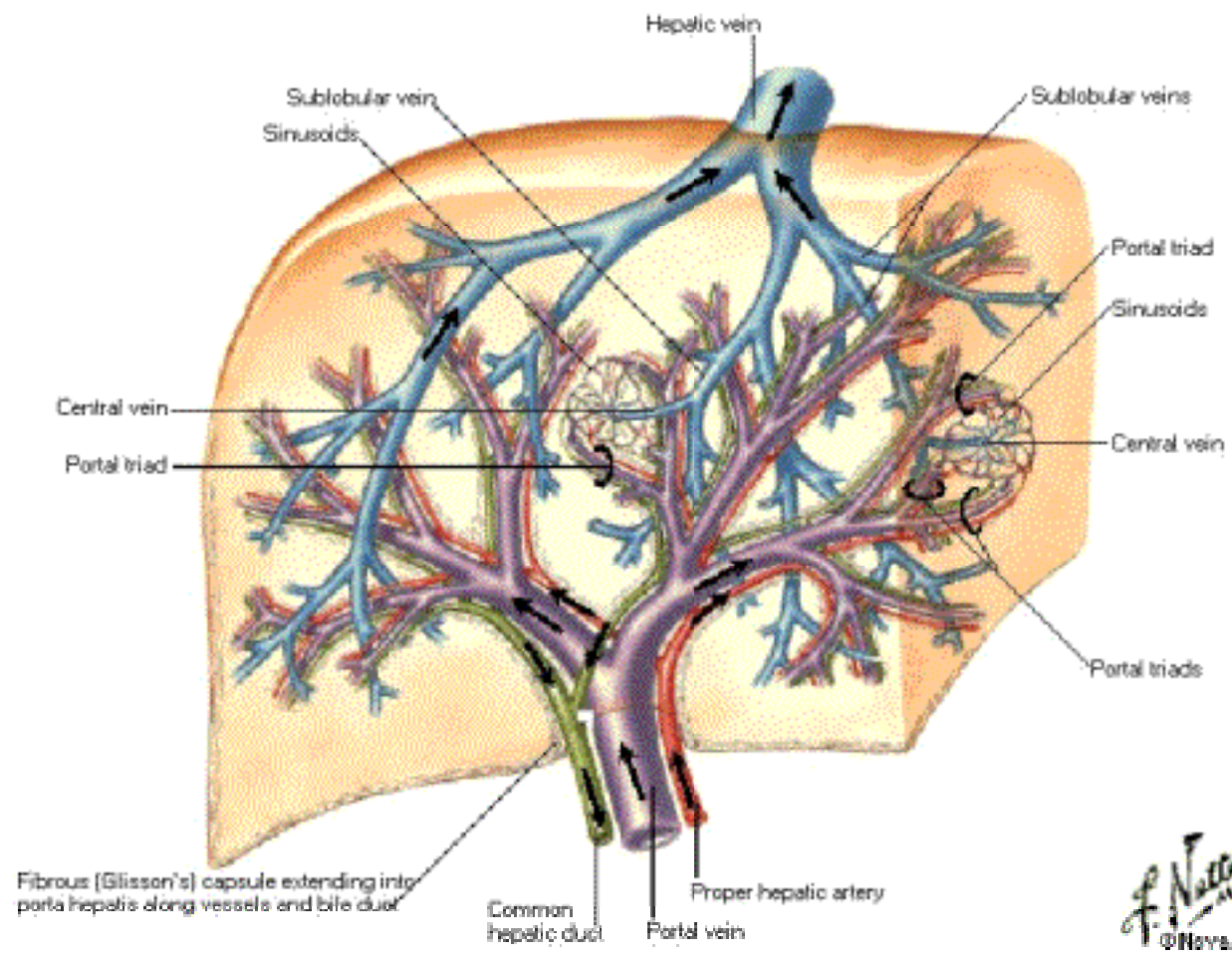
Inferior vena cava

Common hepatic duct, portal vein and proper hepatic artery

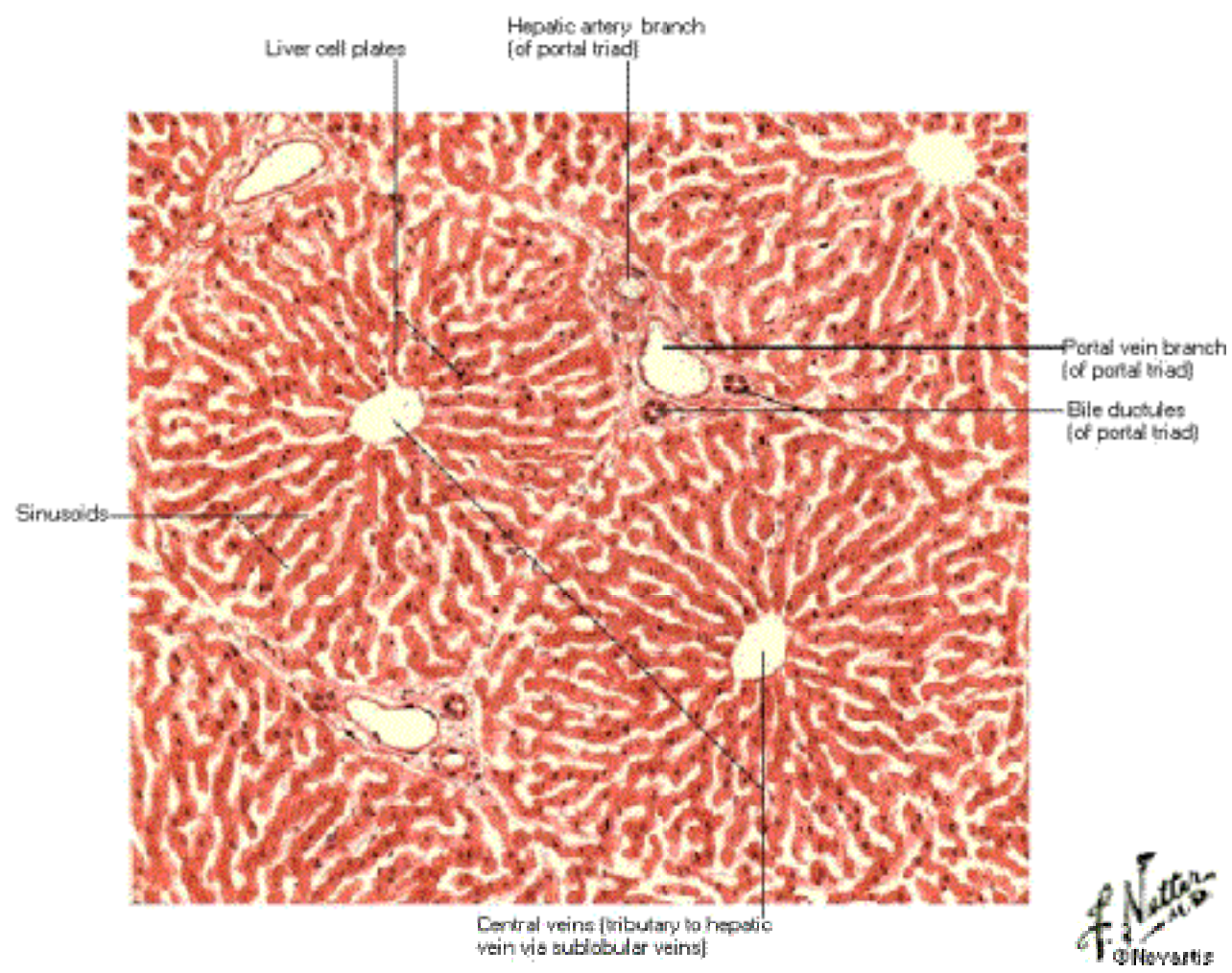
F. Netter M.D.

Intrahepatic Vascular and Duct Systems

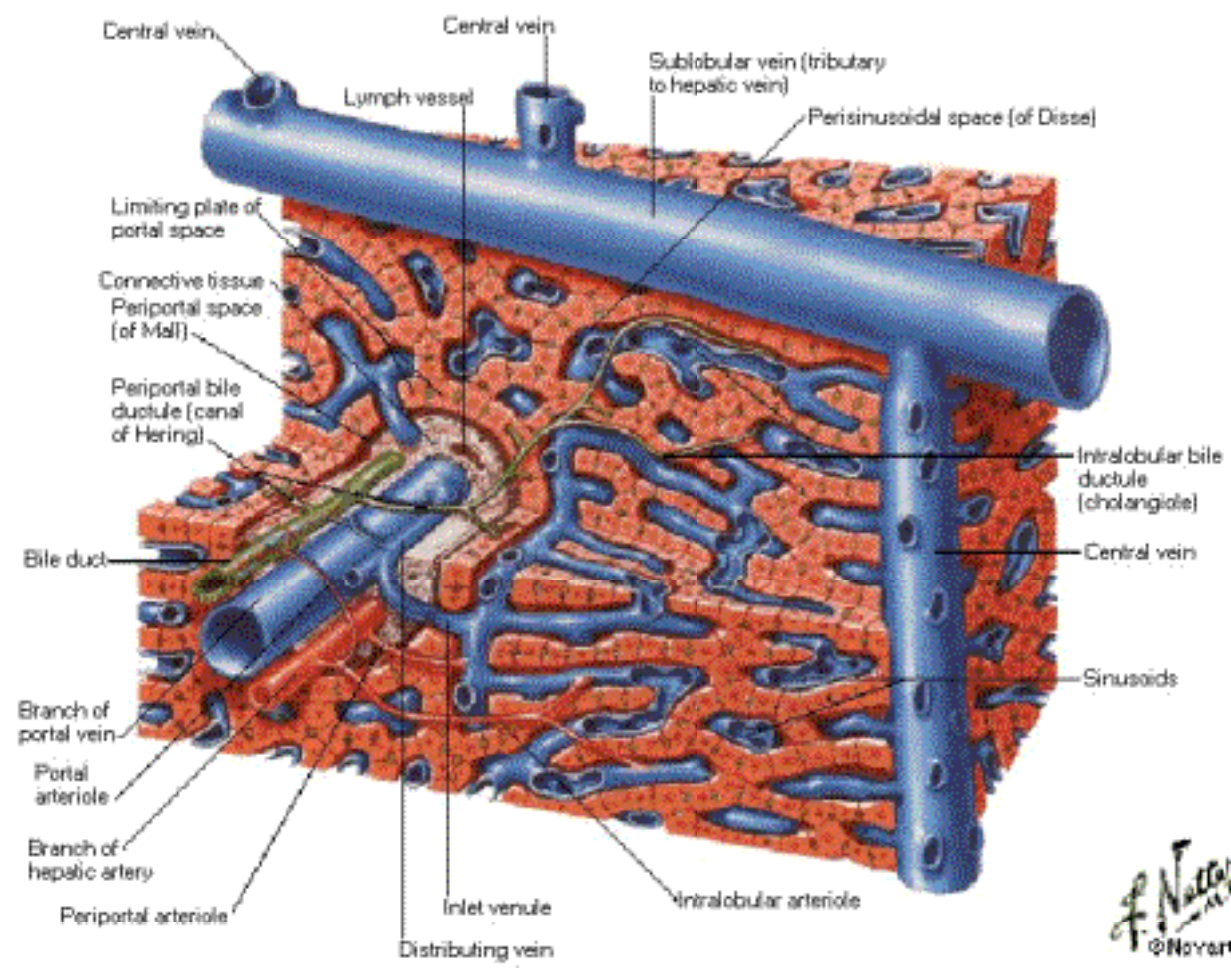
Schema



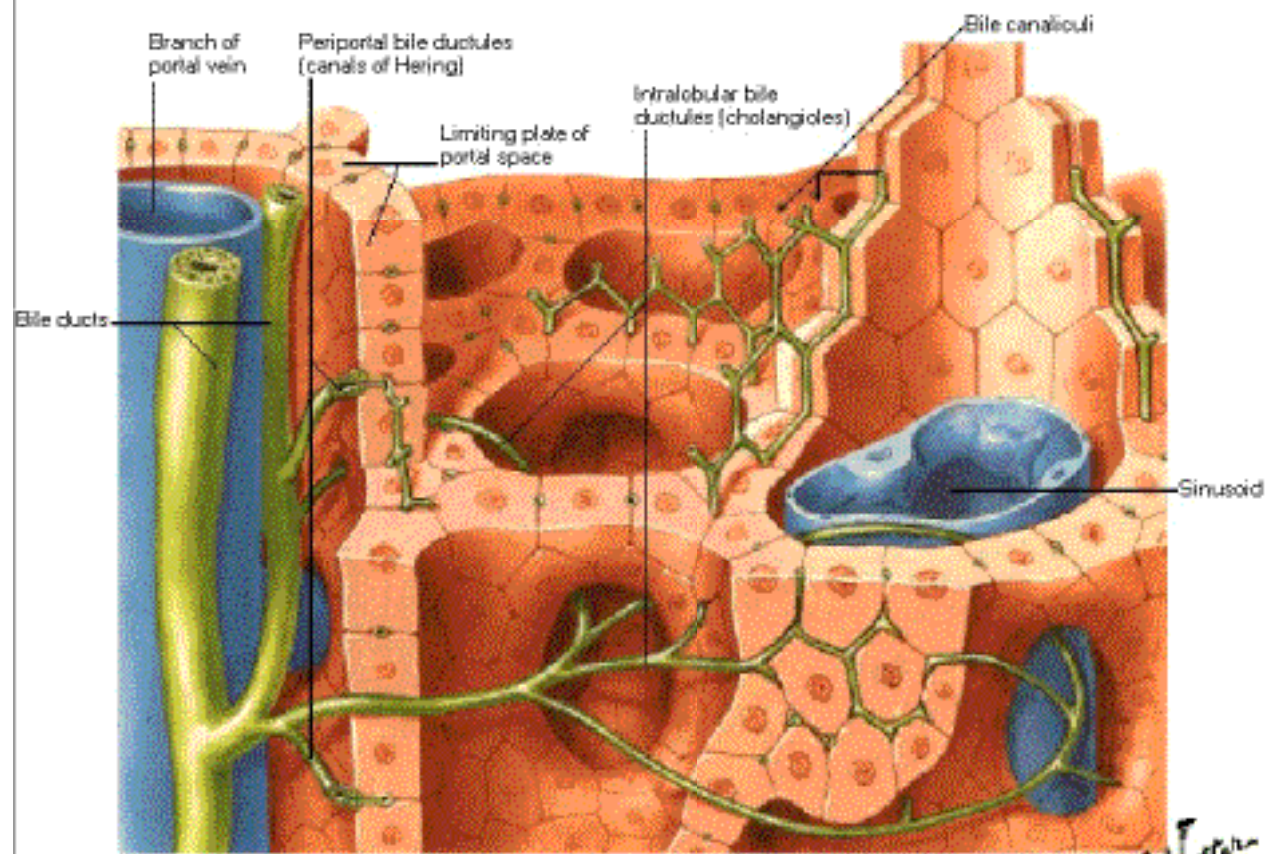
Normal Lobular Pattern of Liver



Liver Structure Schema



Intrahepatic Biliary System Schema

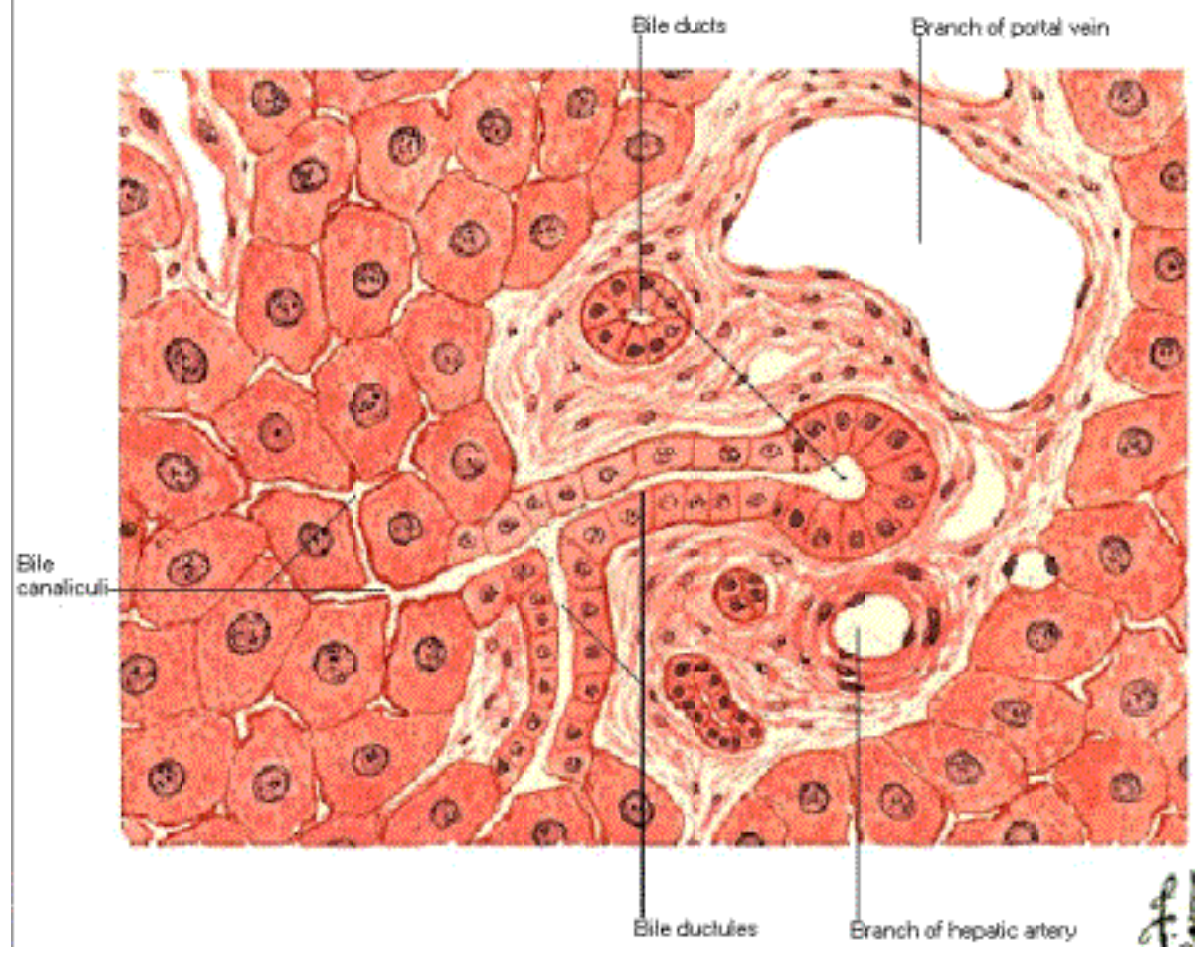


Note: in this illustration, bile canaliculi appear as structures with walls of their own. However, as shown in image 275B, boundaries of canaliculi are actually a specialization of surface membranes of adjoining liver parenchymal cells

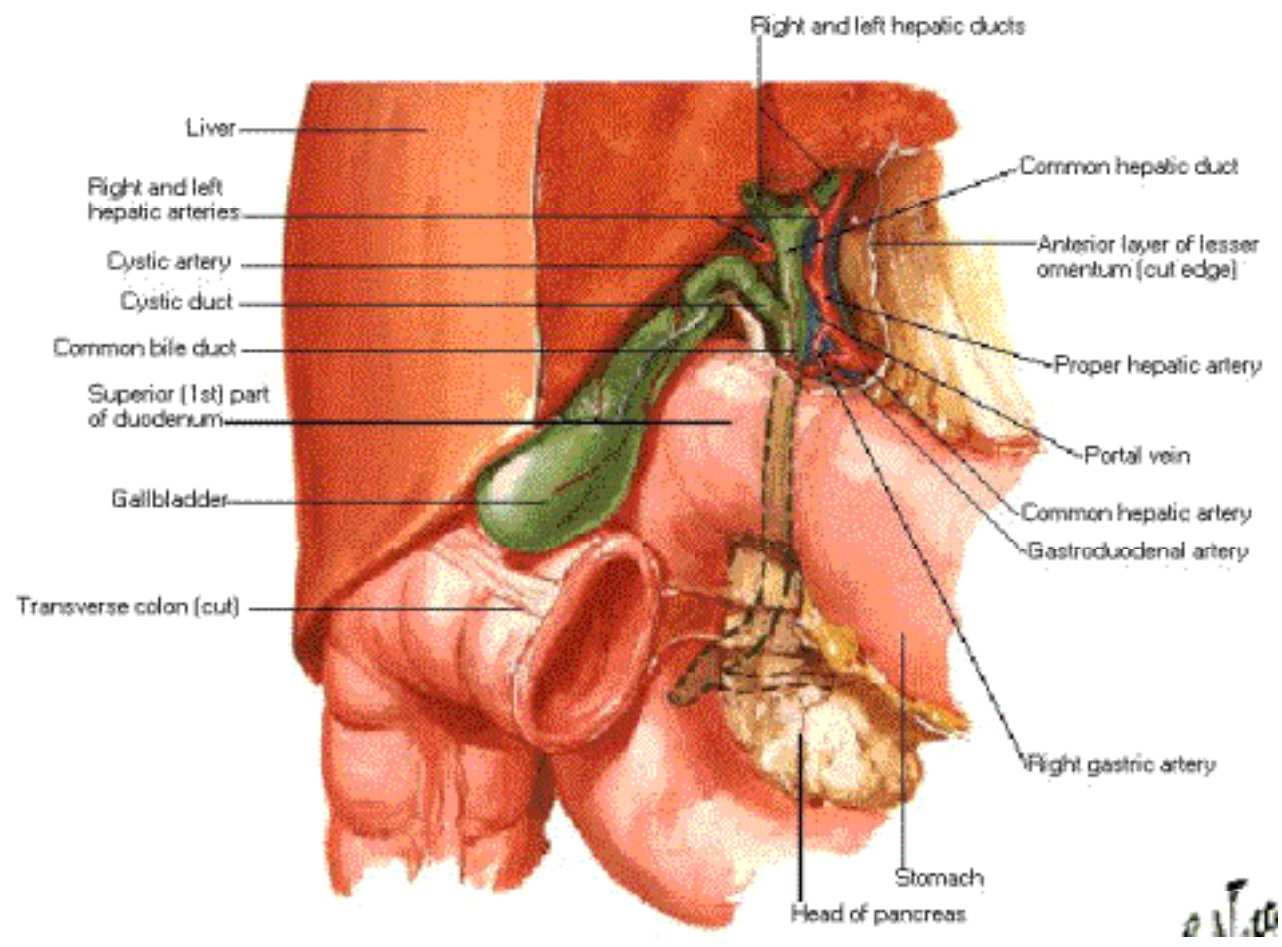
F. Netter M.D.
© 1996

Intrahepatic Biliary System

Histology

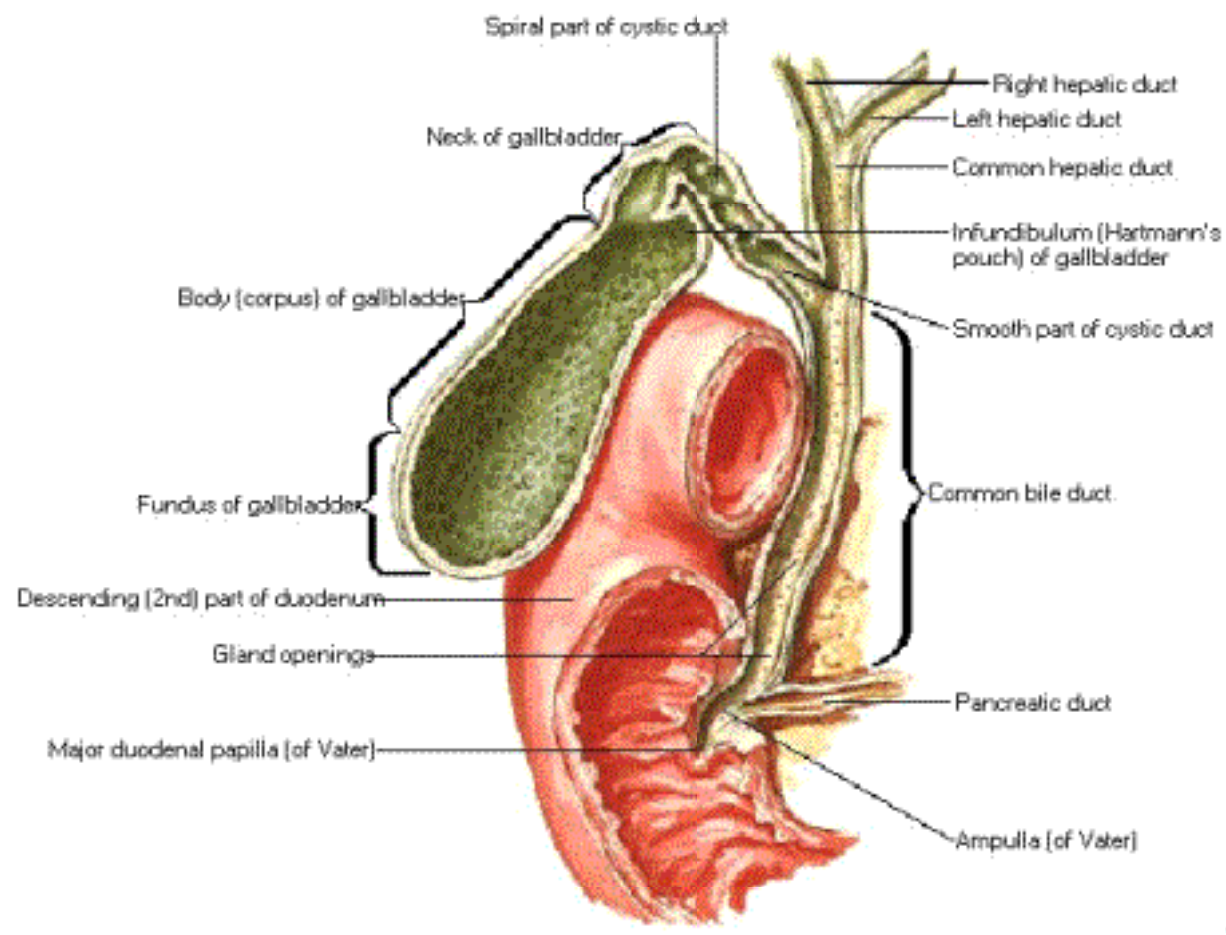


Gallbladder and Extrahepatic Bile Ducts



Gallbladder and Extrahepatic Bile Ducts

Sectioned



Variations in Cystic Duct

Low union with common hepatic duct



Adherent to common hepatic duct



High union with common hepatic duct



Cystic duct absent or very short



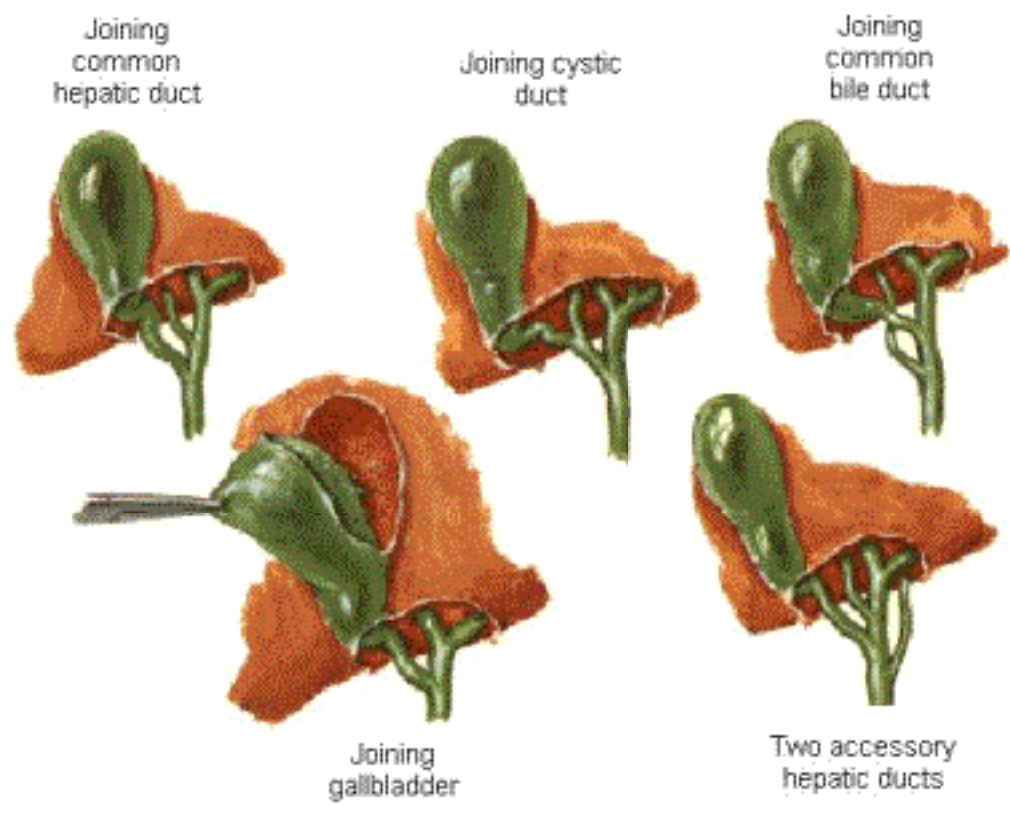
Anterior spiral joining common hepatic duct on left side



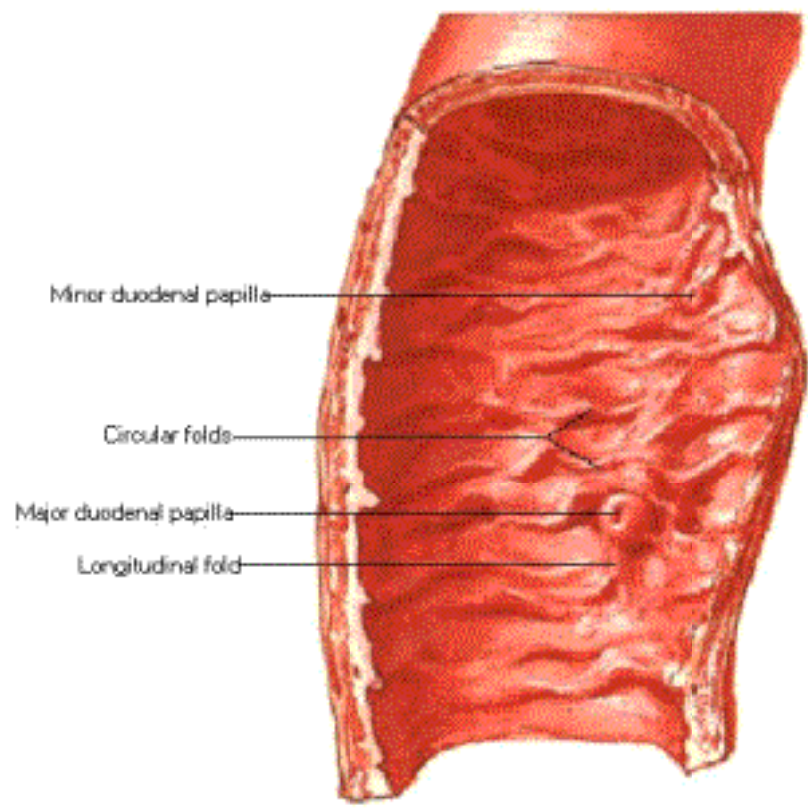
Posterior spiral joining common hepatic duct on left side



Variations in Accessory [Aberrant] Hepatic Ducts



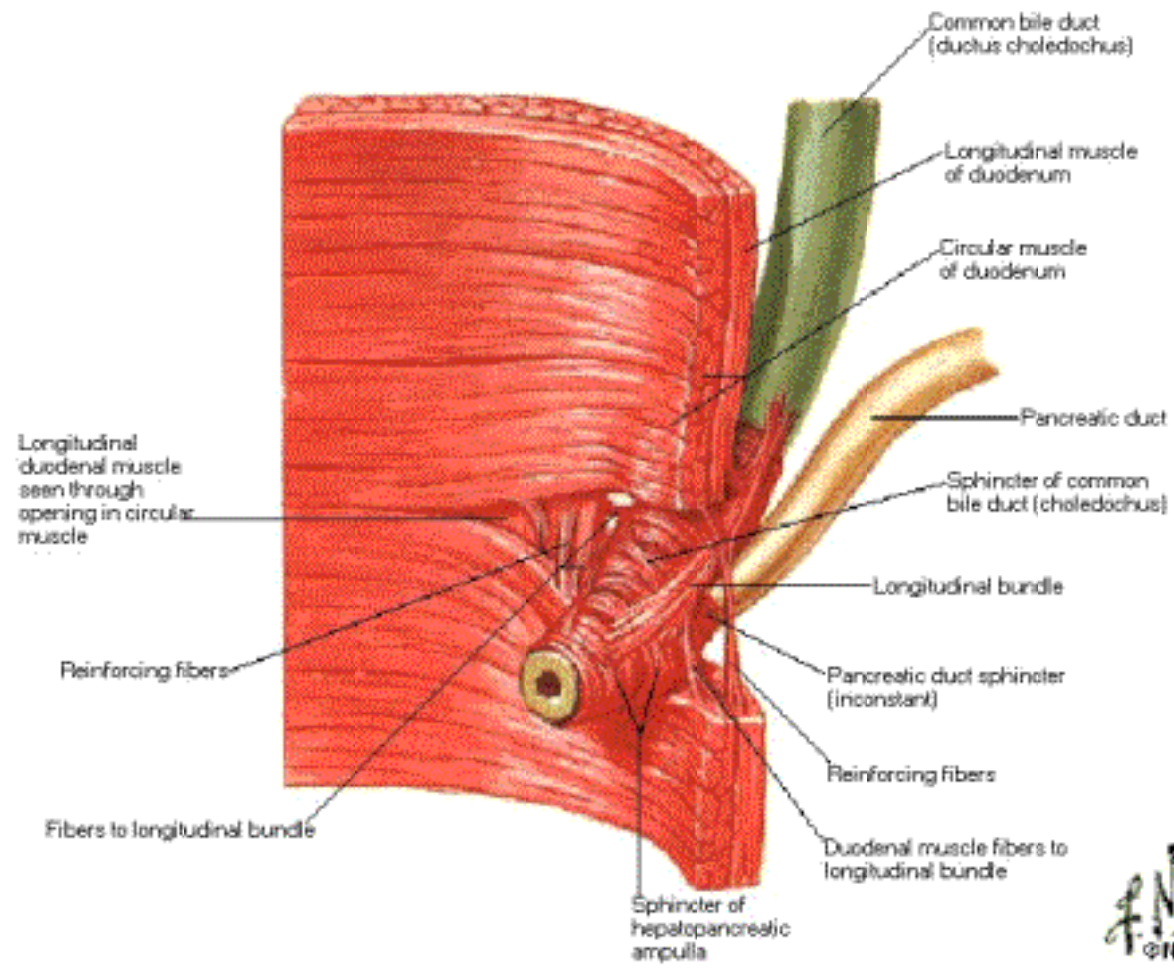
Choledochoduodenal Junction



Interior of descending (2nd) part of duodenum

Choledochoduodenal Junction

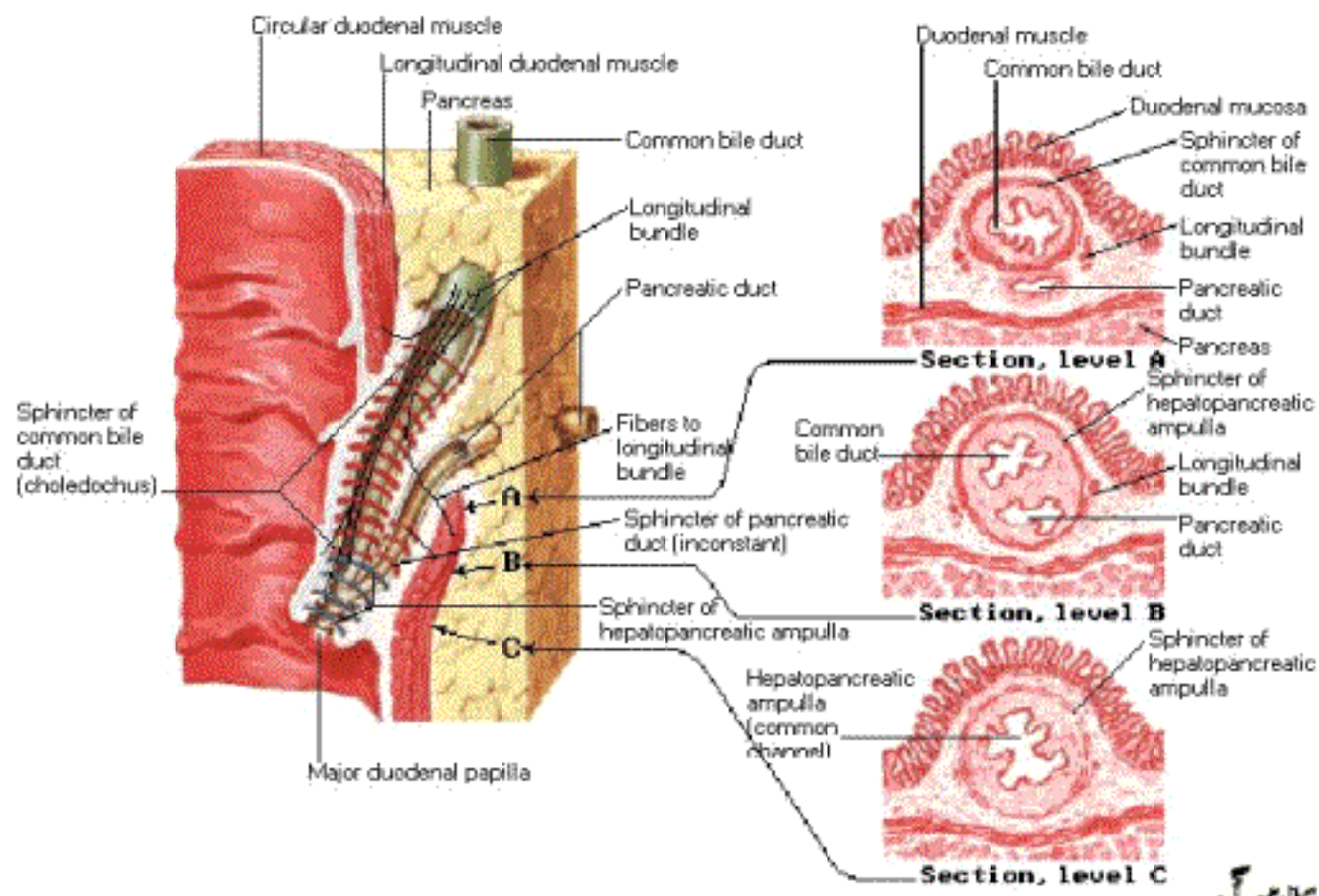
Dissection



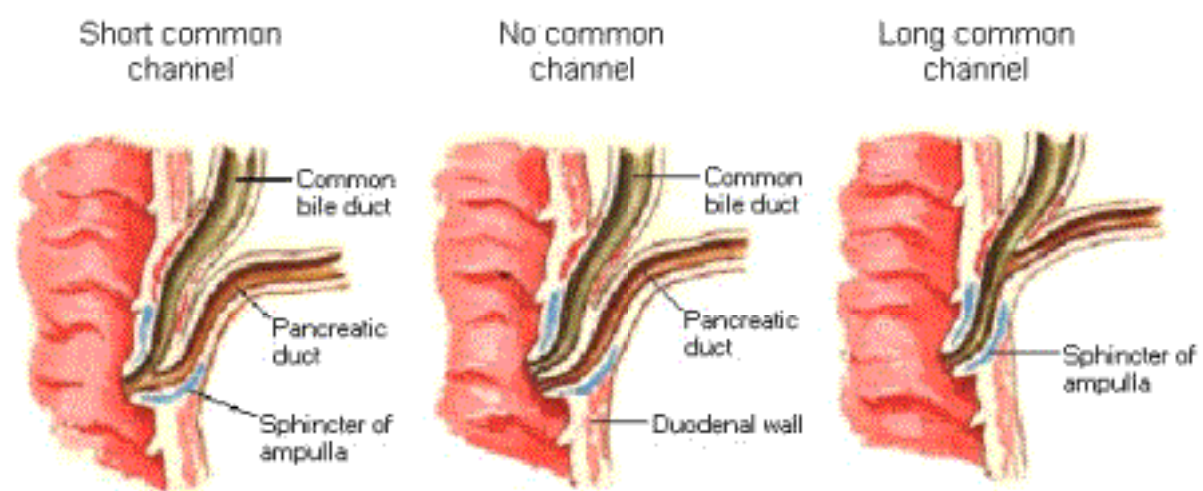
FN
OH

Choleloduodenal Junction

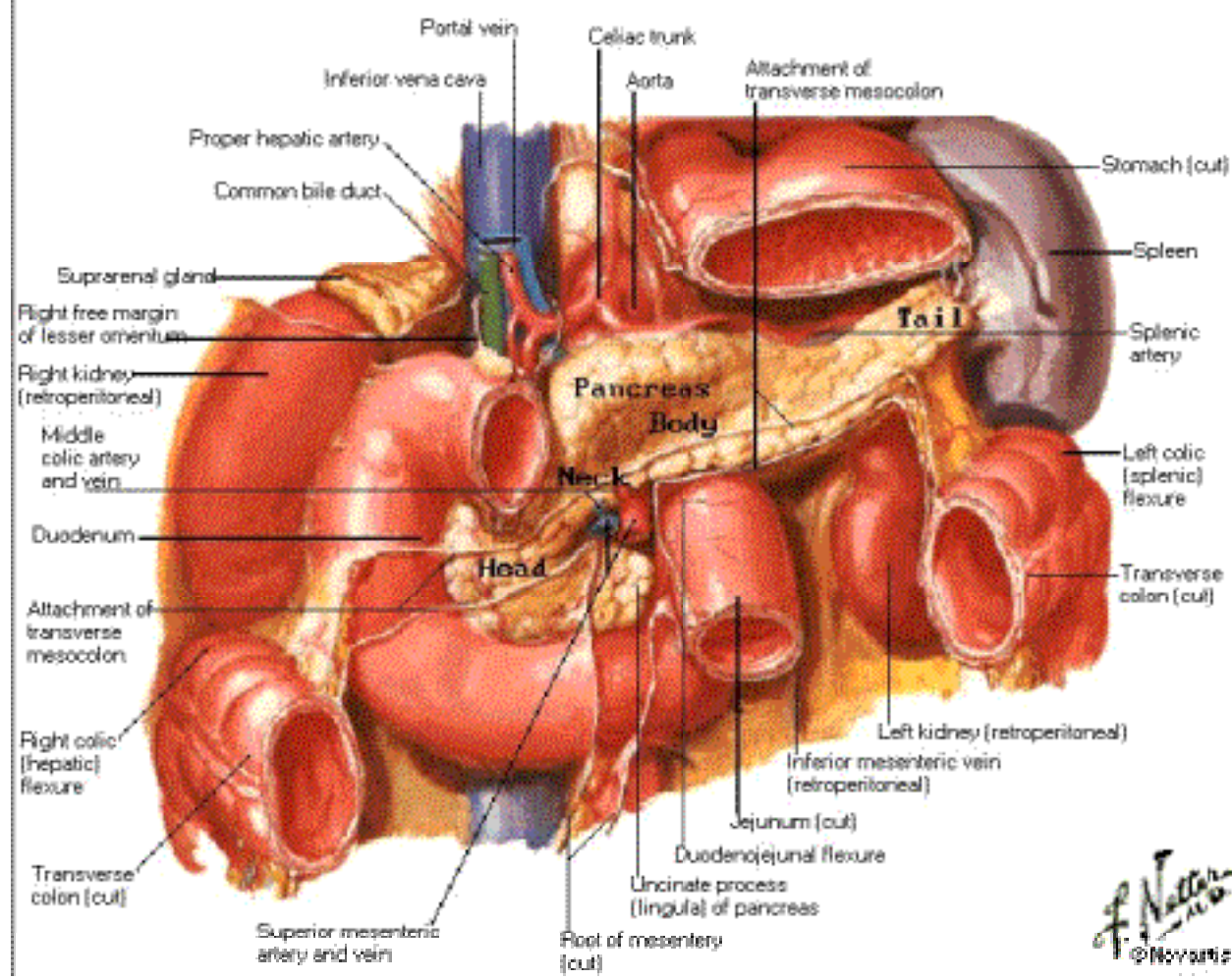
Reconstruction



Variations in Union of Bile and Pancreatic Ducts

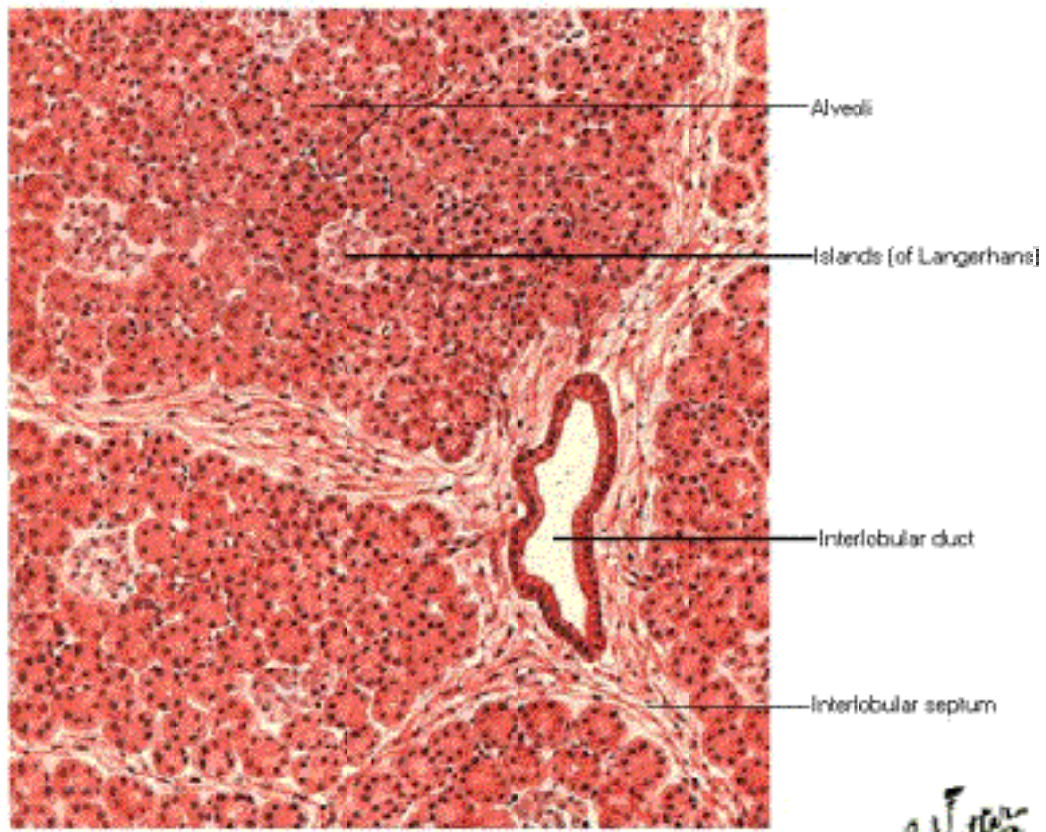


Pancreas in Situ



Pancreas

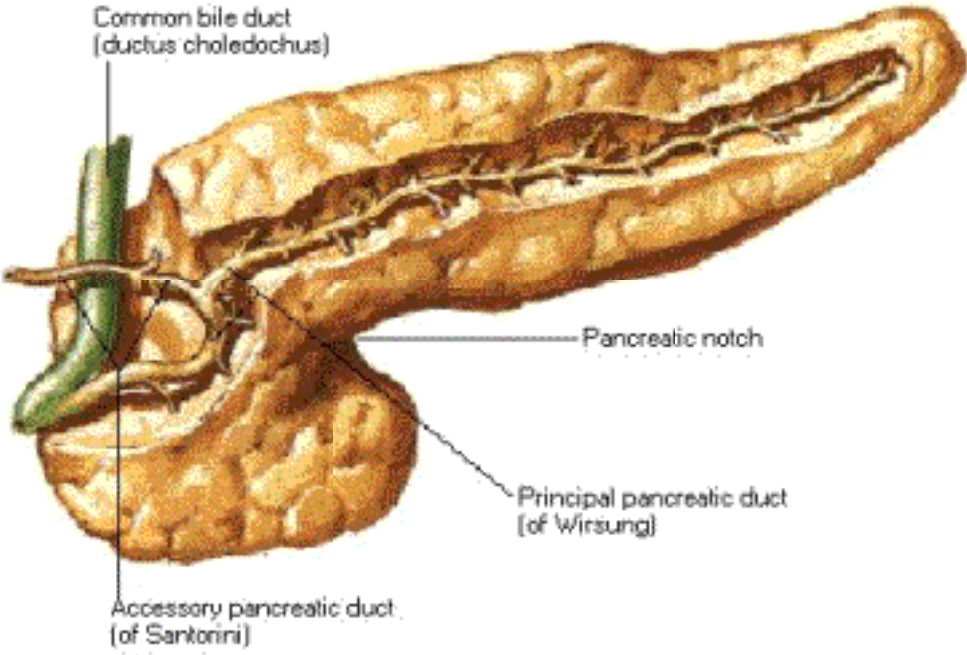
Histology



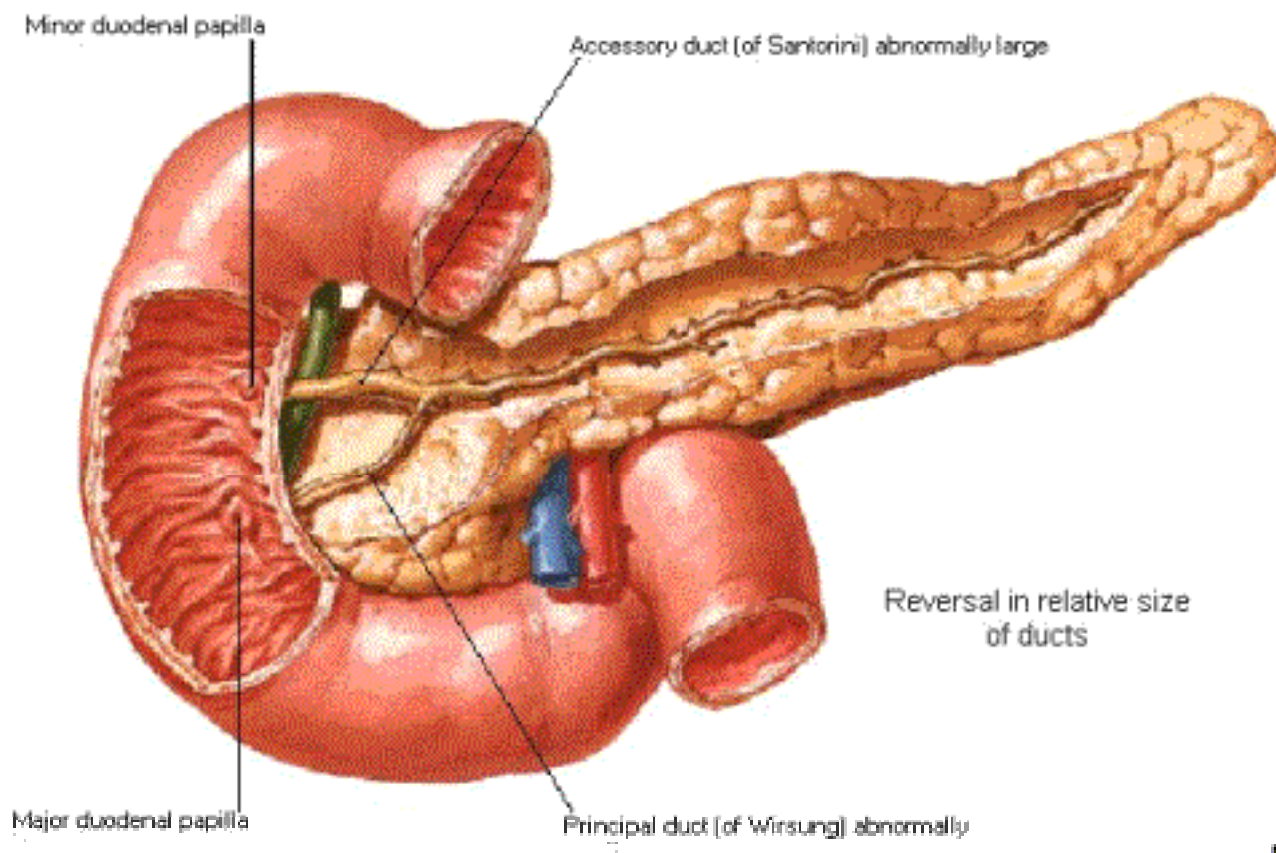
Low-power section of pancreas

F. Netter
M.D.

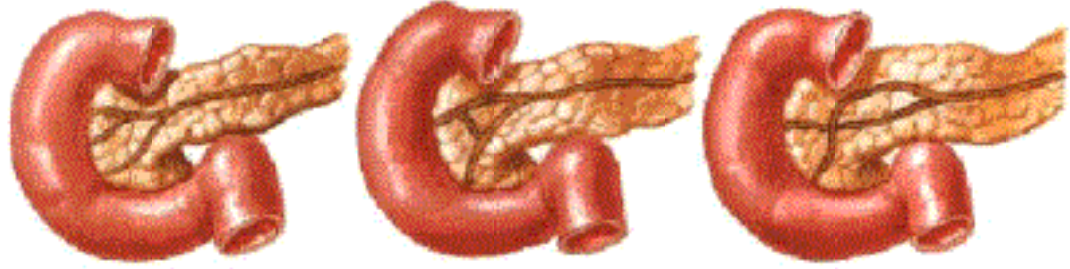Pancreas



Variations in Pancreatic Ducts



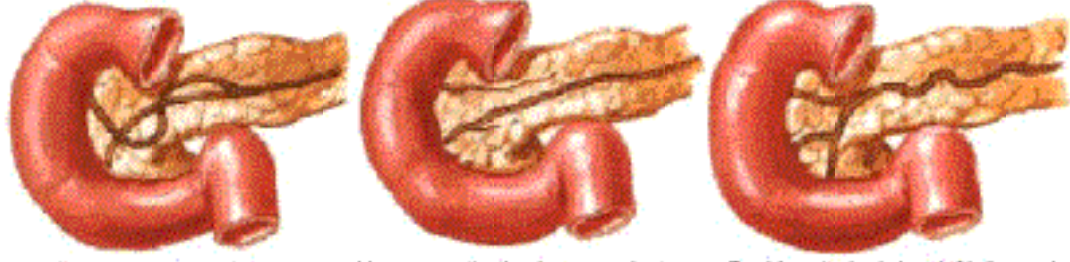Variations in Pancreatic Ducts [Continued]



Double accessory duct (of Santorini)

Anastomosis between ducts

Crossing ducts



Double crossing of ducts

No communication between ducts

Double principal duct (of Wirsung)

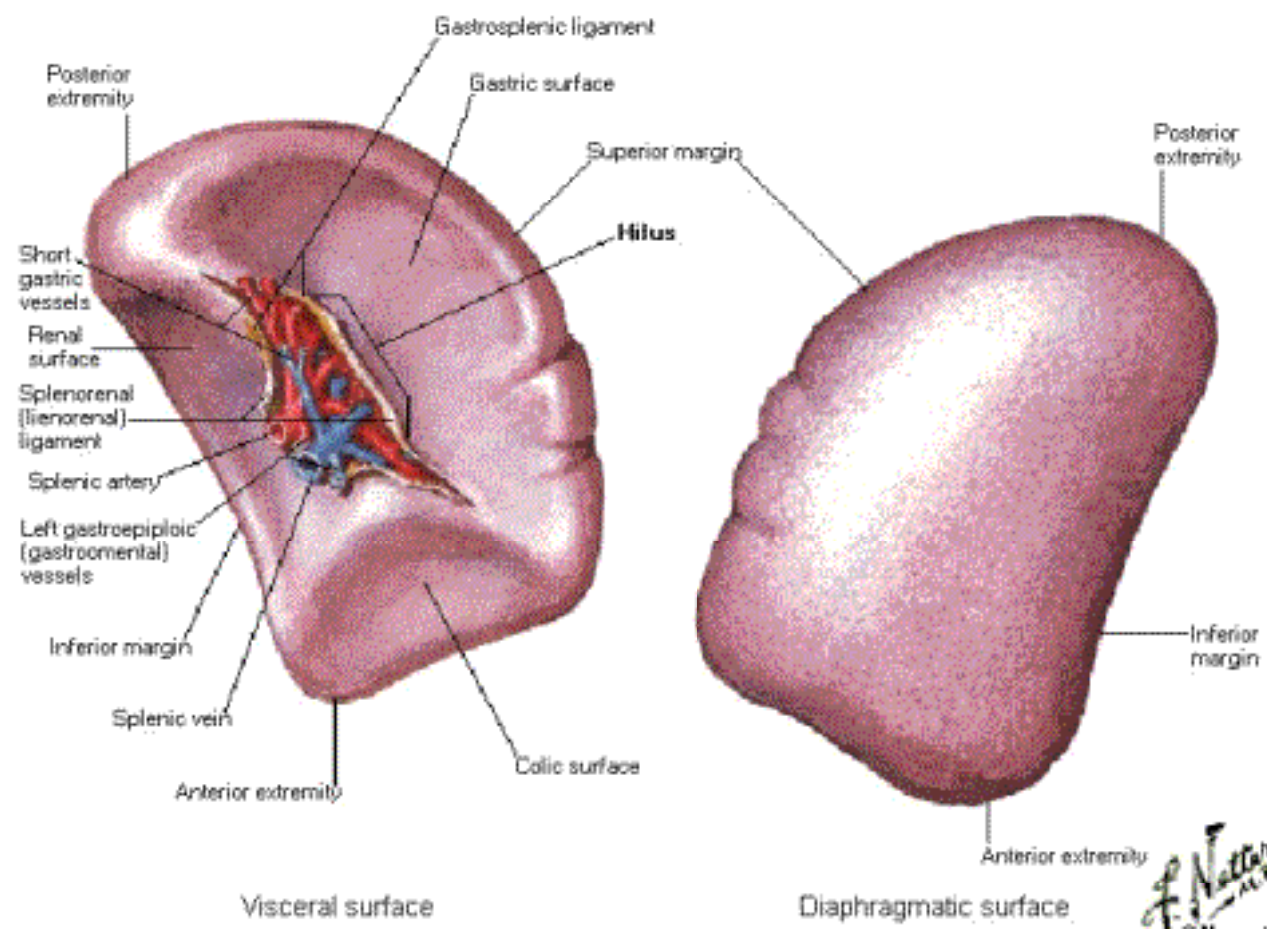


Tortuosity of ducts

Absence of accessory duct (of Santorini)

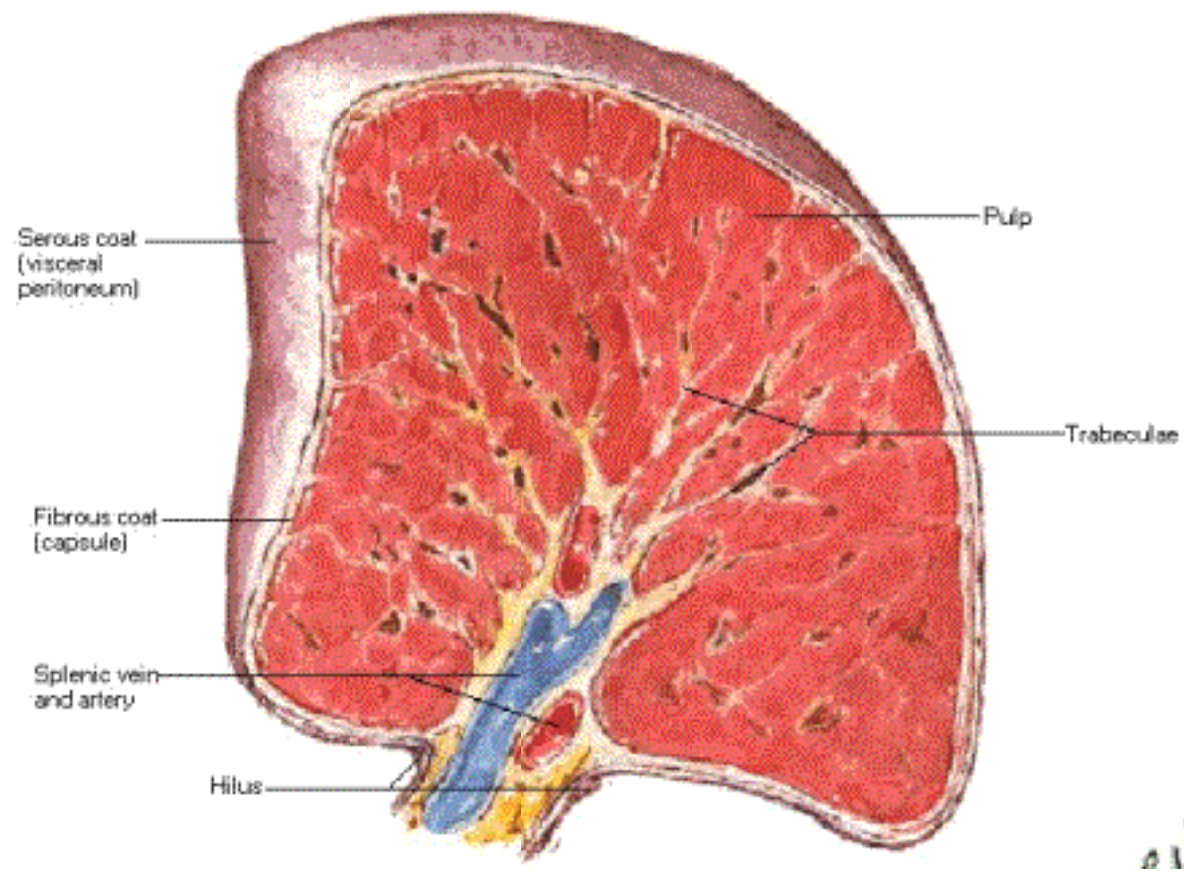
Spleen

Visceral and Diaphragmatic Surfaces

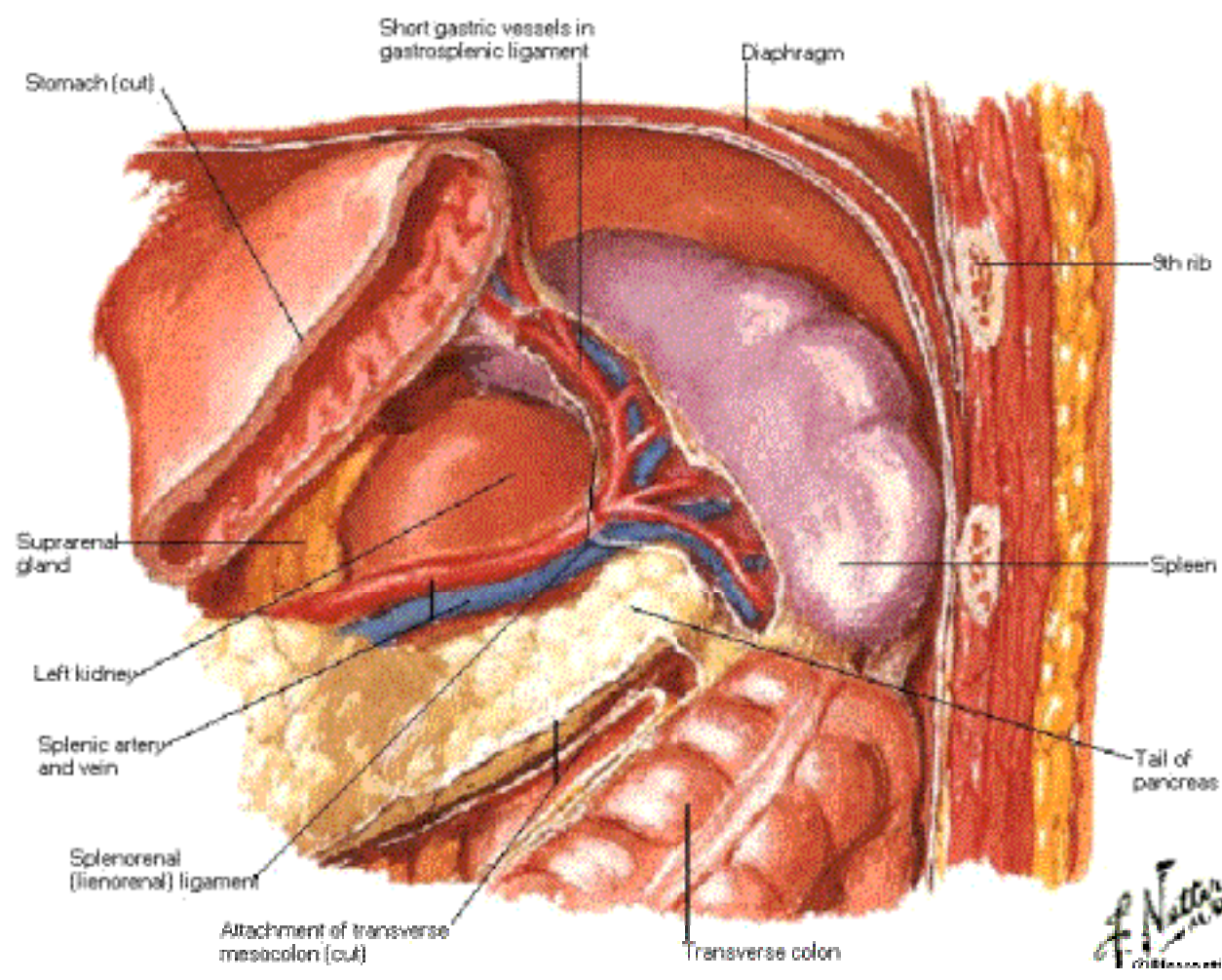


Spleen

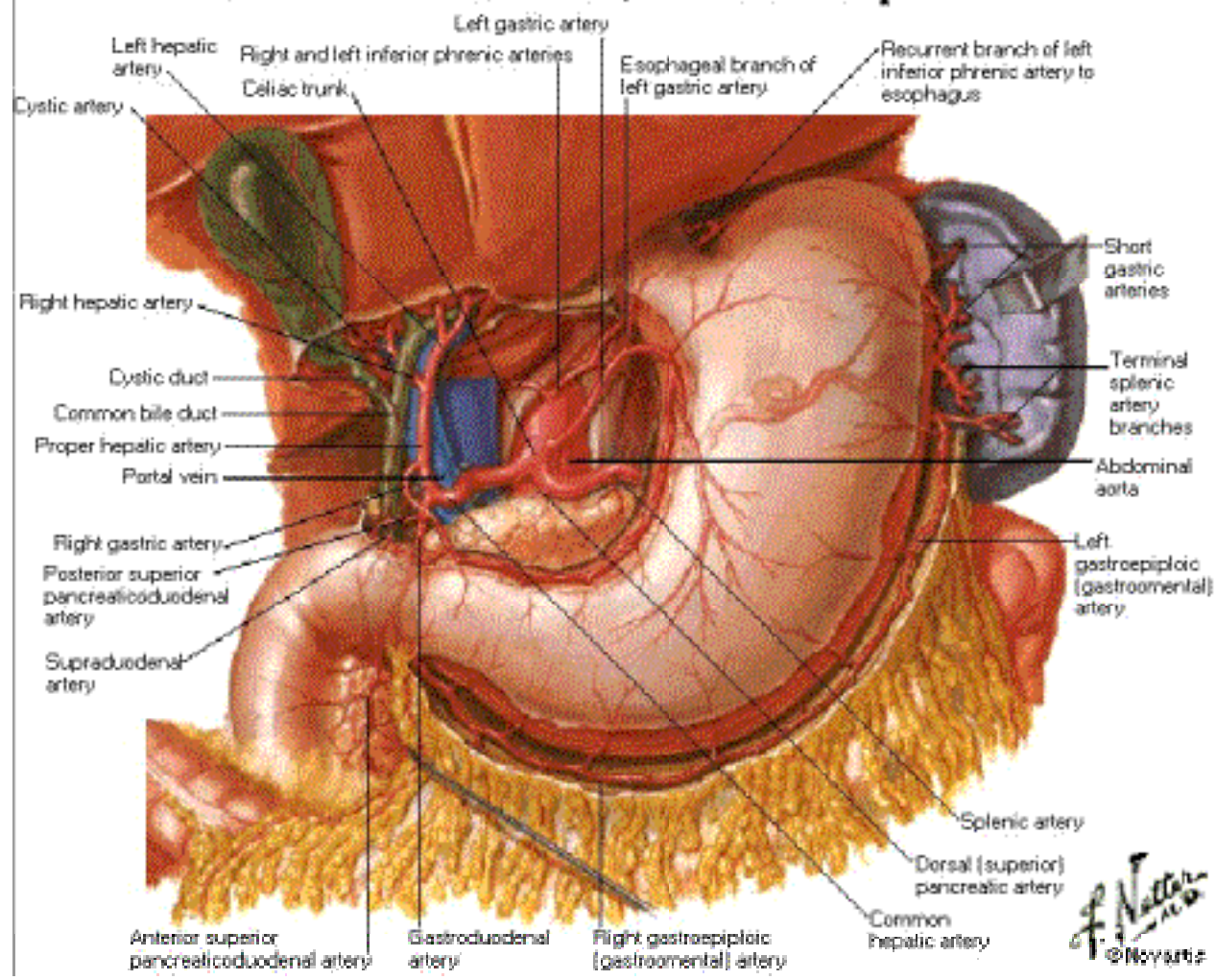
Cross Section



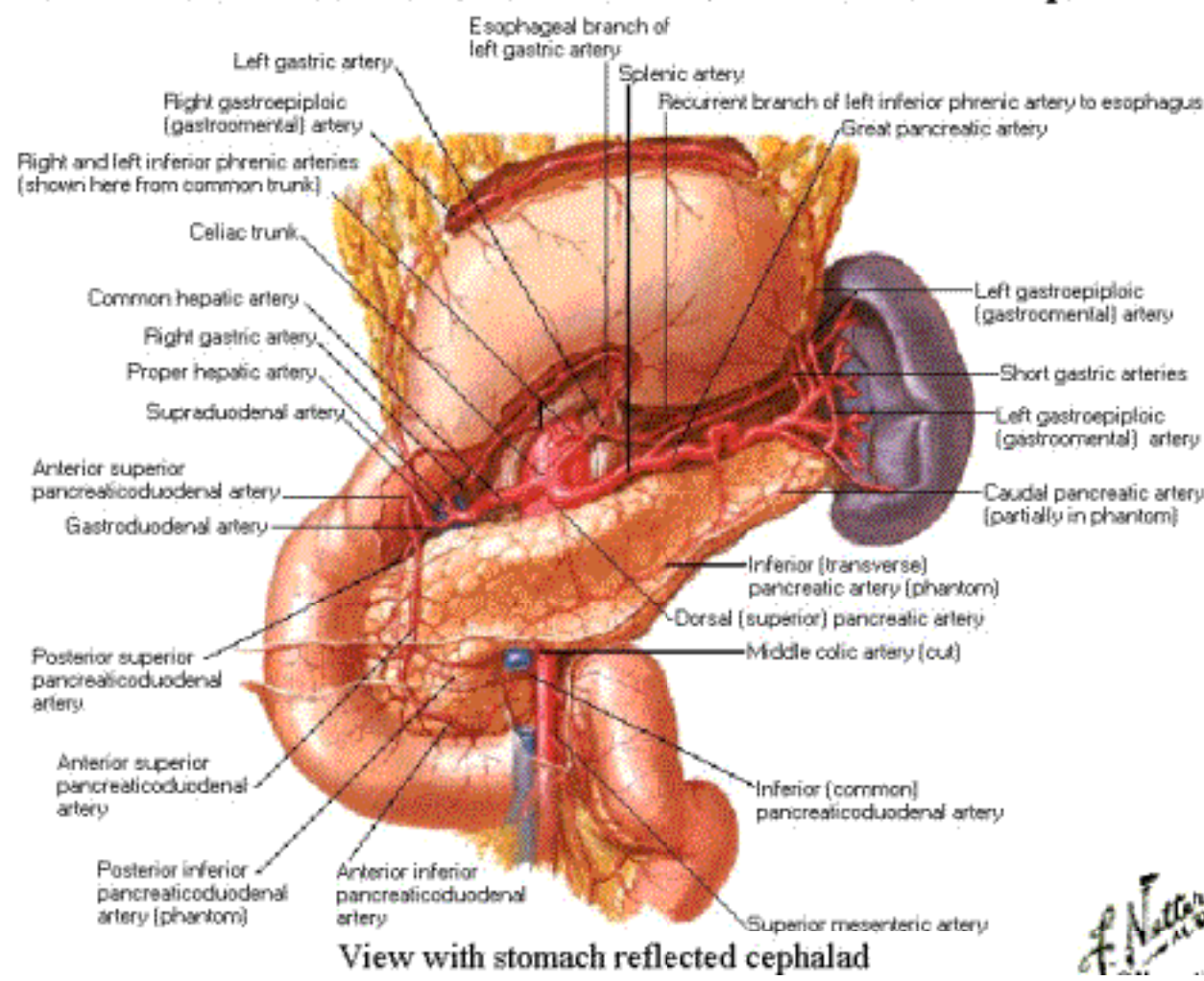
Spleen in Situ



Arteries of Stomach, Liver and Spleen

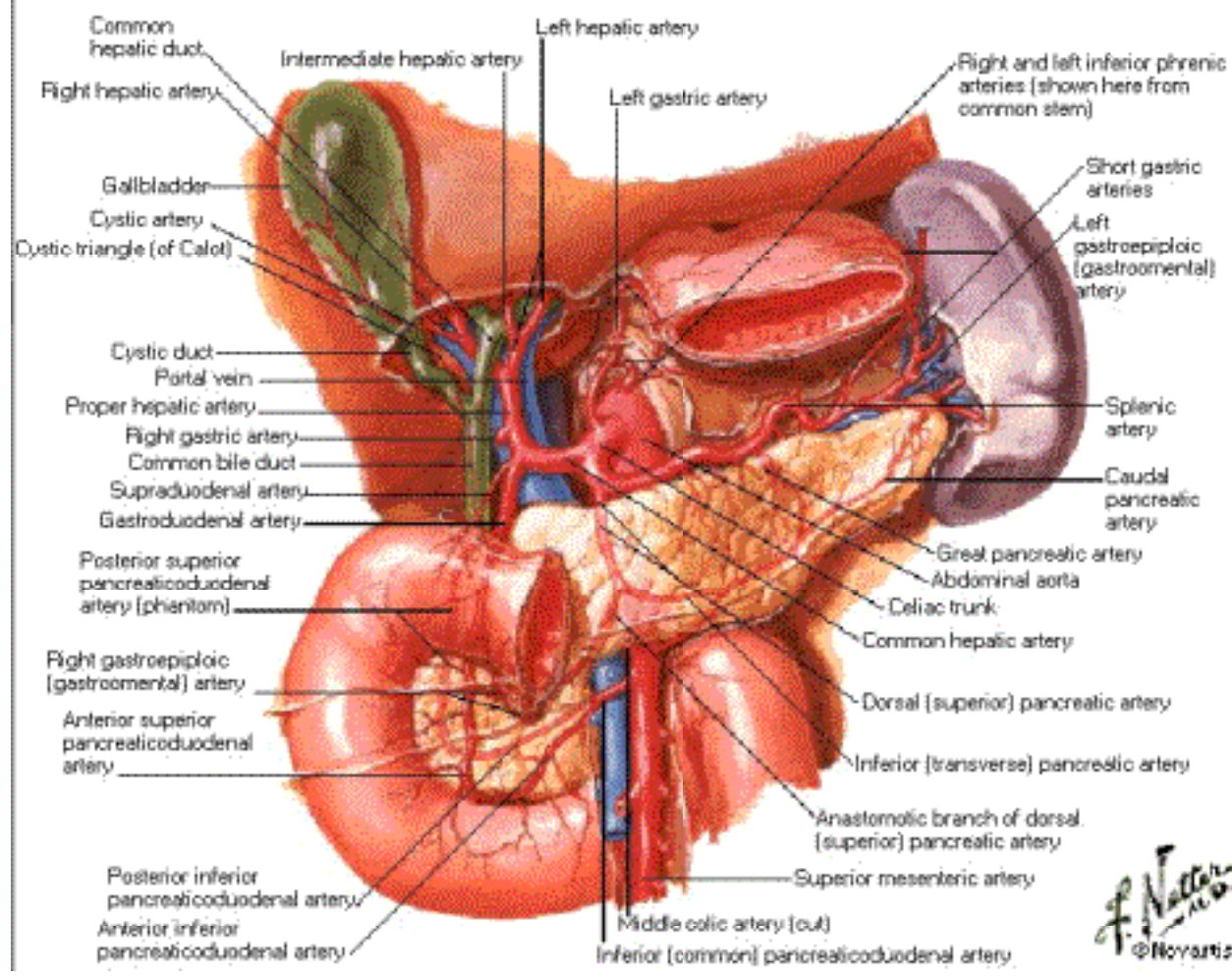


Arteries of Stomach, Duodenum, Pancreas and Spleen



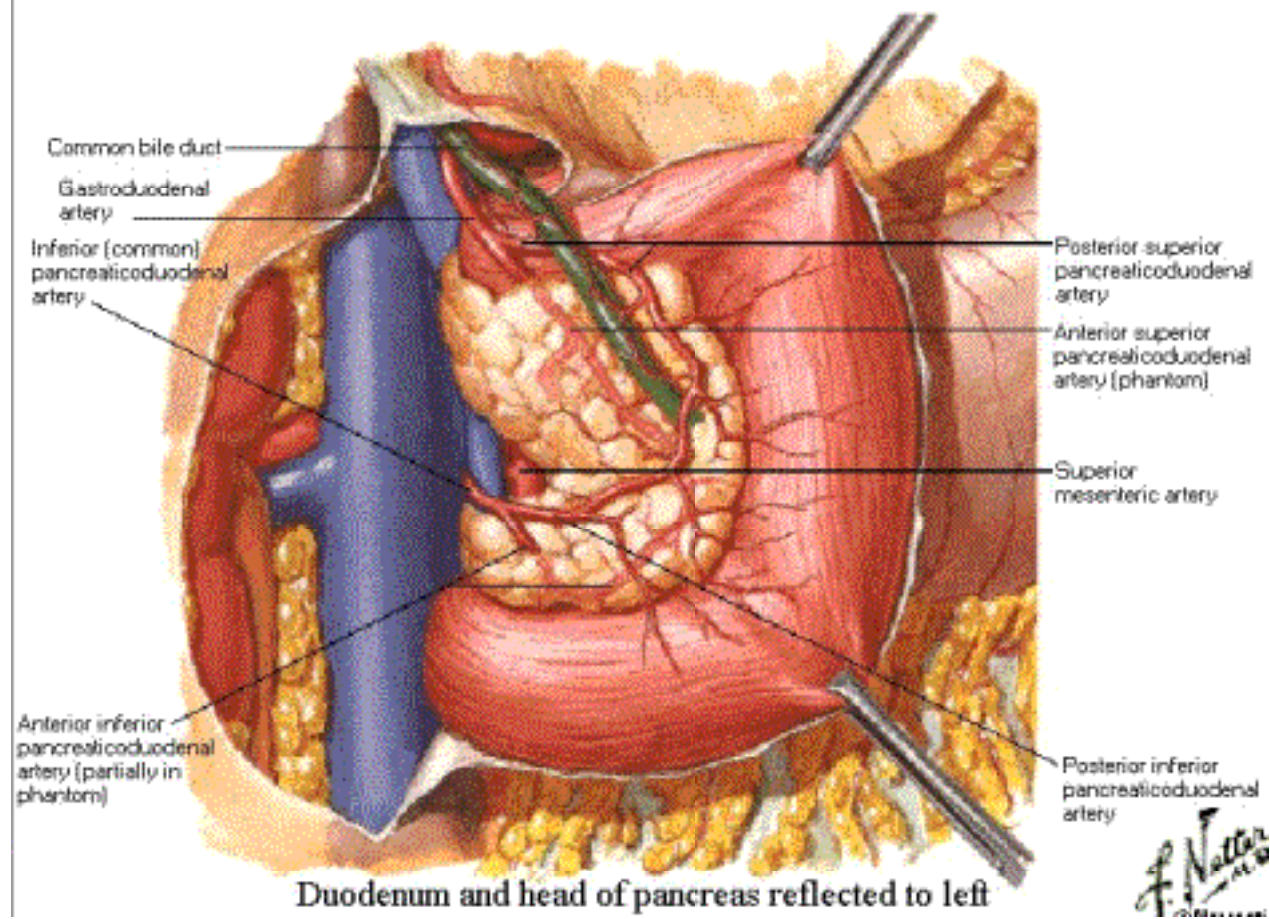
F. Netter M.D.

Arteries of Liver, Pancreas, Duodenum and Spleen



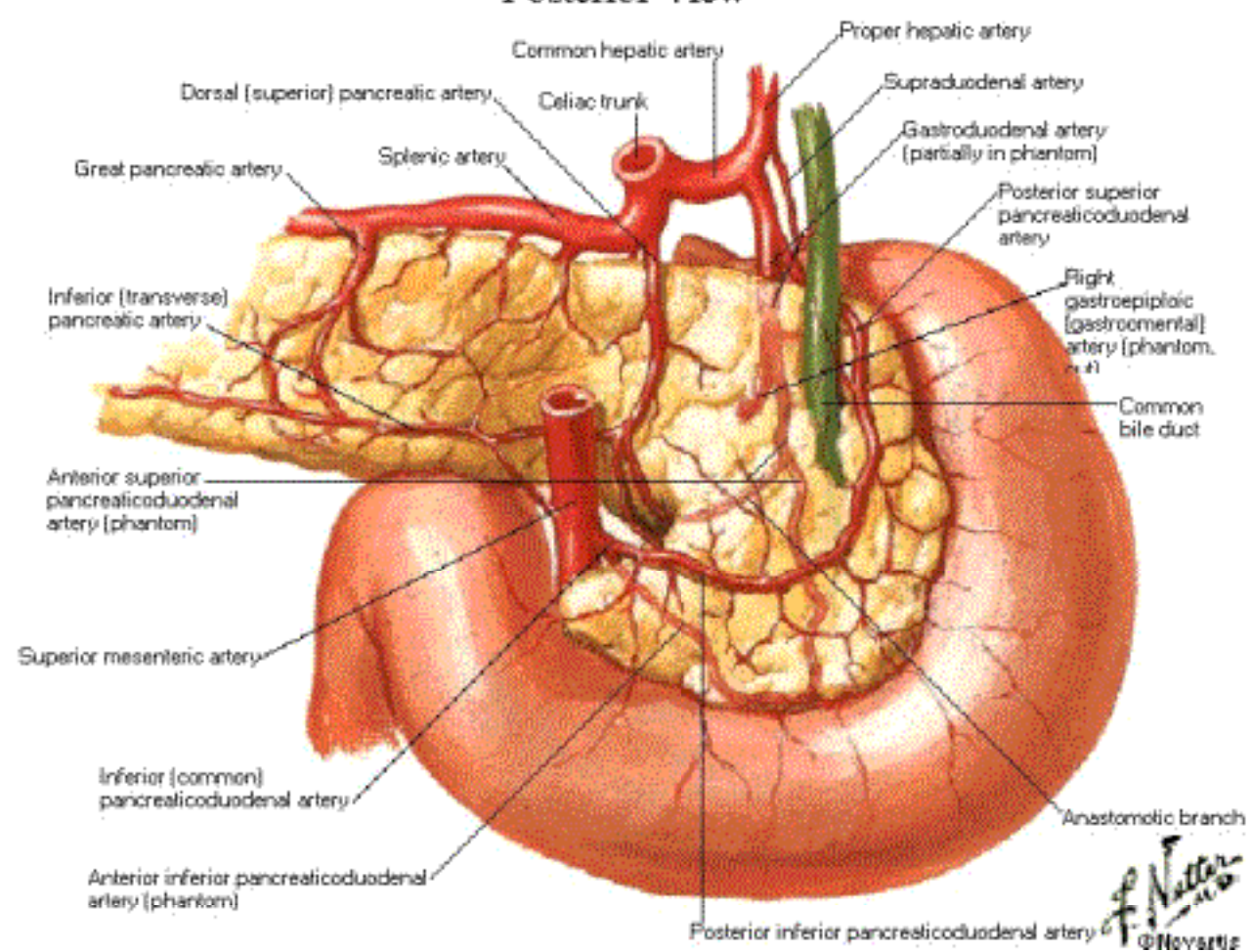
Arteries of Duodenum and Head of Pancreas

Reflected to Left

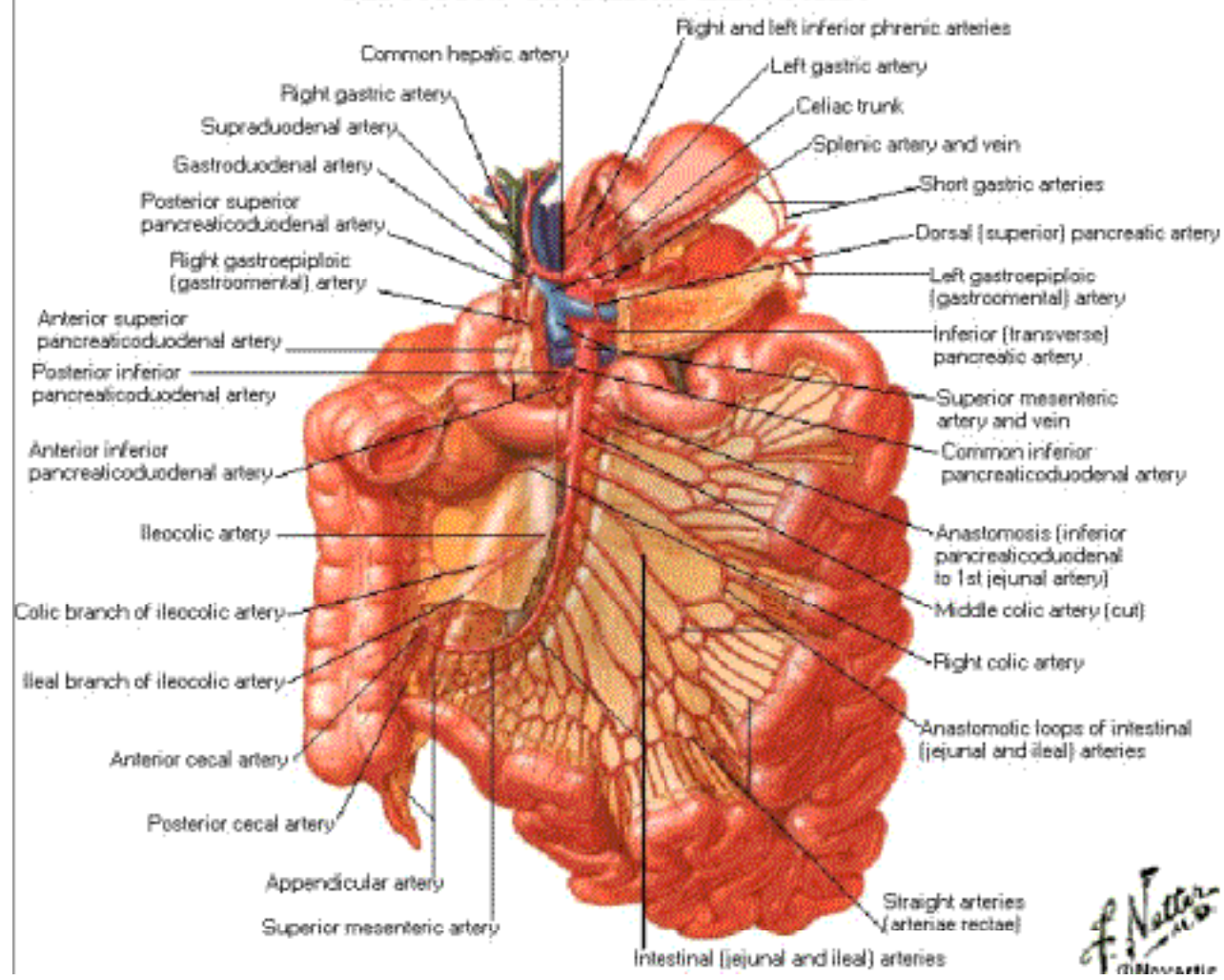


Arteries of Duodenum and Head of Pancreas

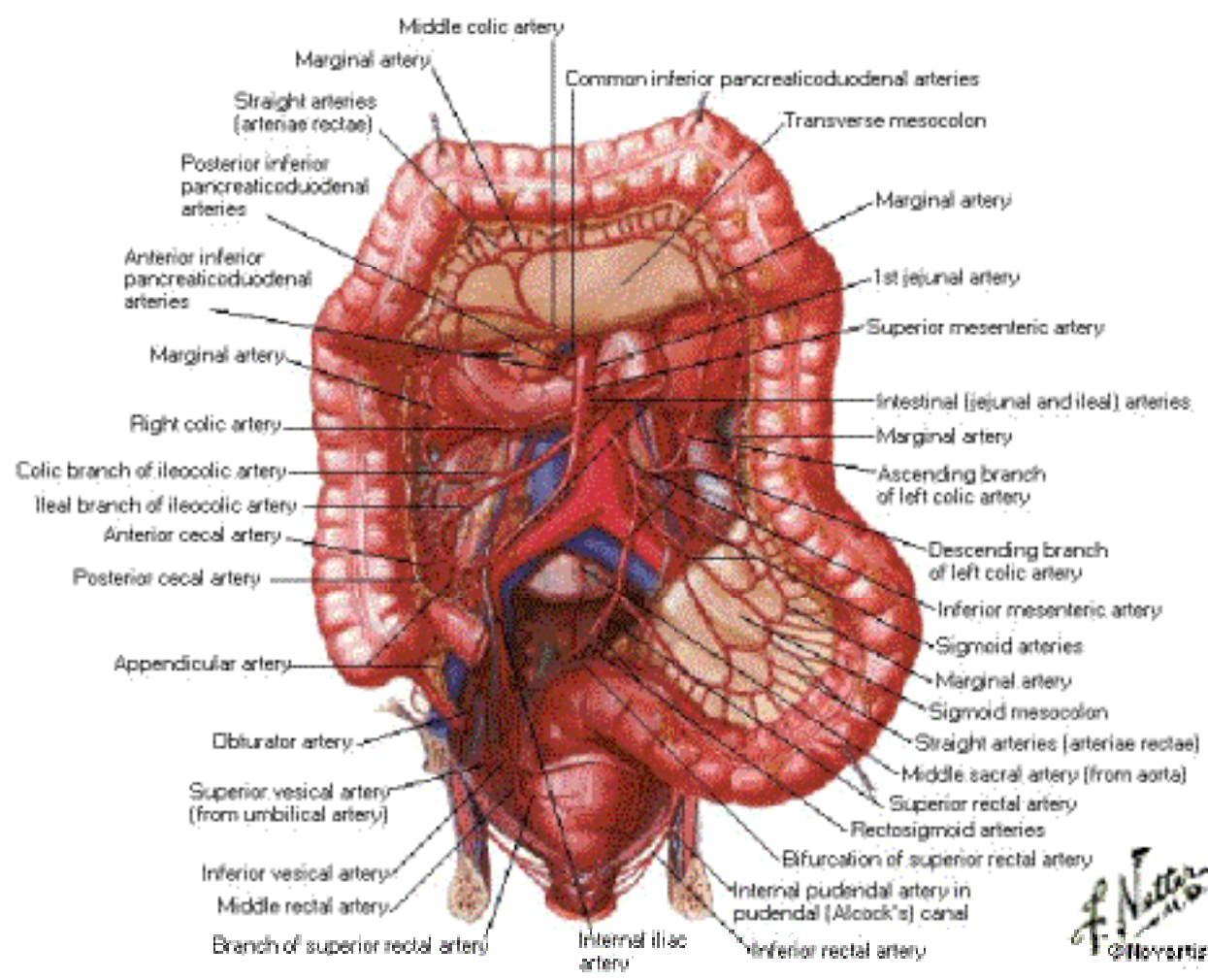
Posterior View



Arteries of Small Intestine

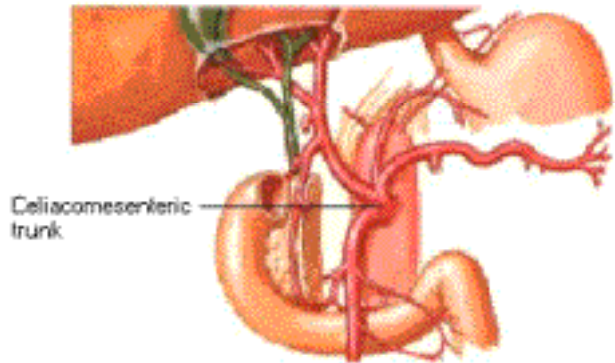


Arteries of Large Intestine

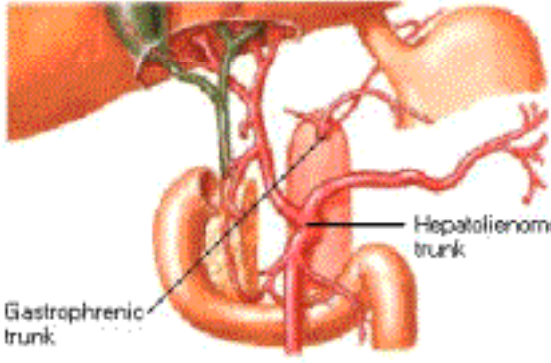
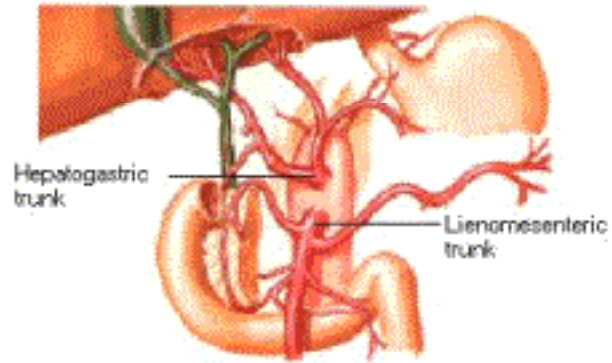


Variations in Celiac Trunk

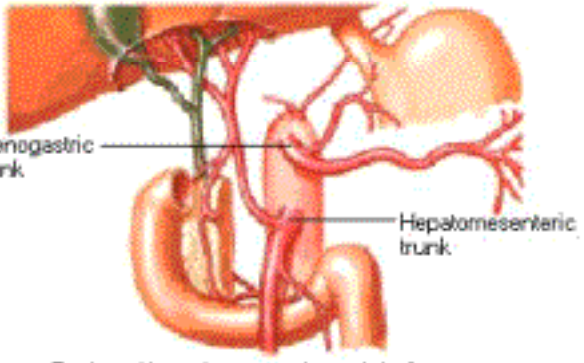
Common origin of celiac trunk and superior mesenteric artery



Splenic artery takes origin from superior mesenteric (note replaced left hepatic artery from left gastric)



Splenic and hepatic arteries take origin from superior mesenteric

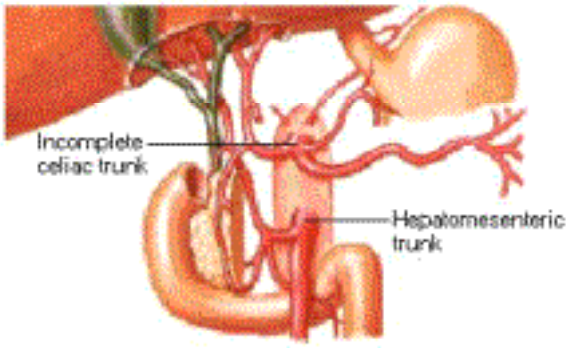


Replaced hepatic artery takes origin from superior mesenteric (note inferior pancreaticoduodenal artery from 1st jejunal)

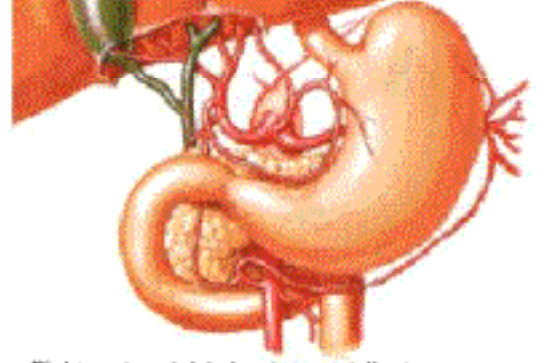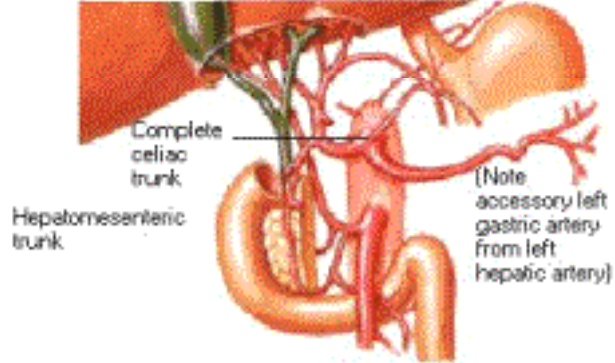
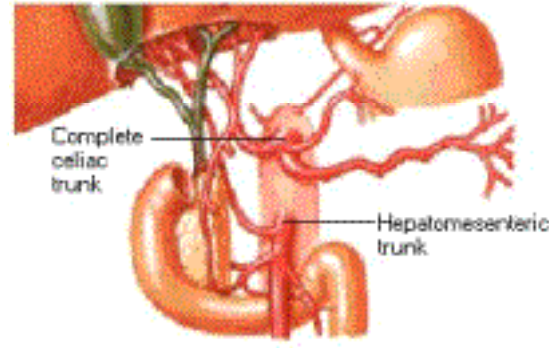
Netter

Variations in Celiac Trunk [Continued]

Replaced right hepatic artery takes origin from superior mesenteric; inferior pancreaticoduodenal and 1st jejunal arteries from replaced right hepatic artery



Accessory right hepatic artery takes origin from superior mesenteric artery

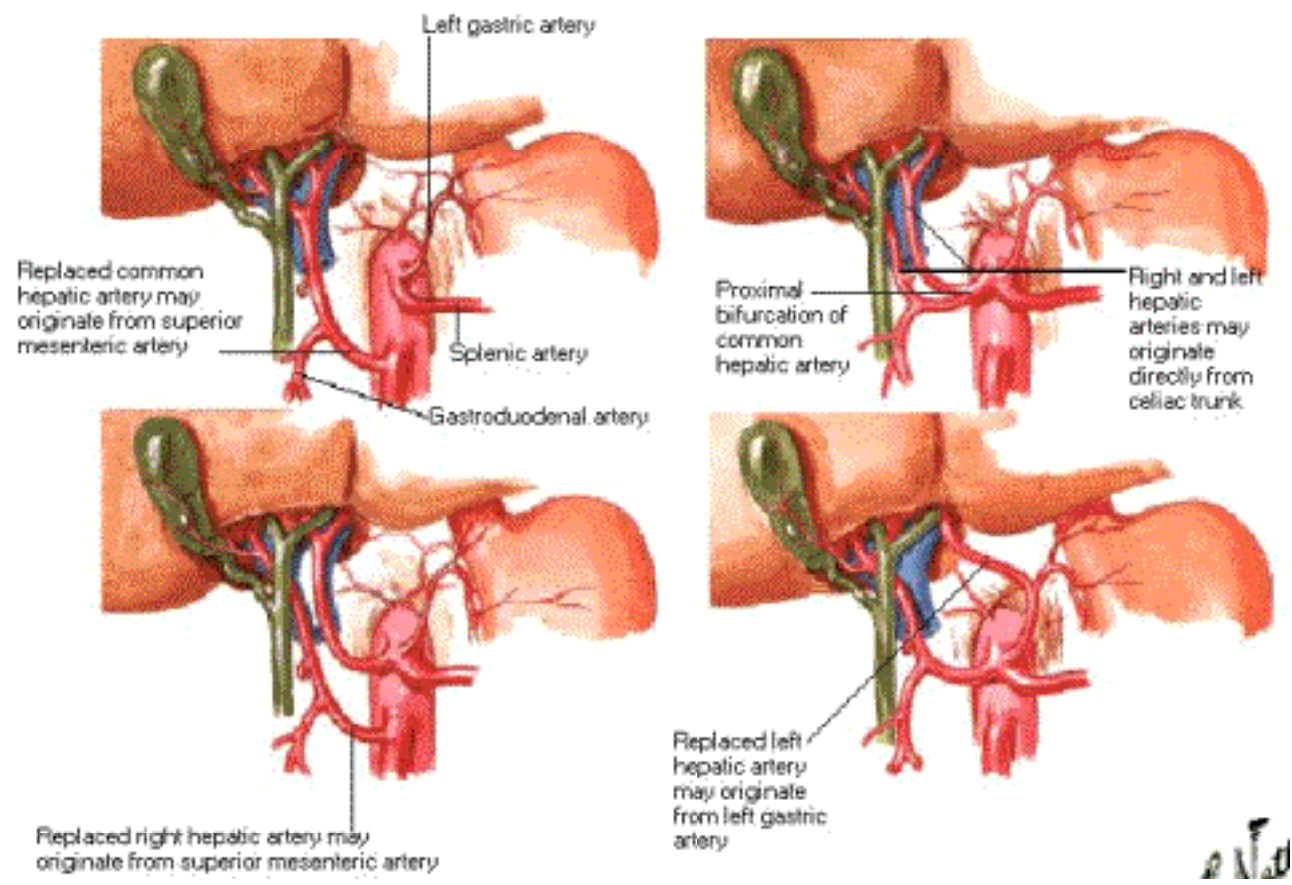


Accessory right hepatic artery takes origin from superior mesenteric; inferior pancreaticoduodenal arteries from accessory right hepatic; 1st jejunal artery from anterior inferior pancreaticoduodenal artery

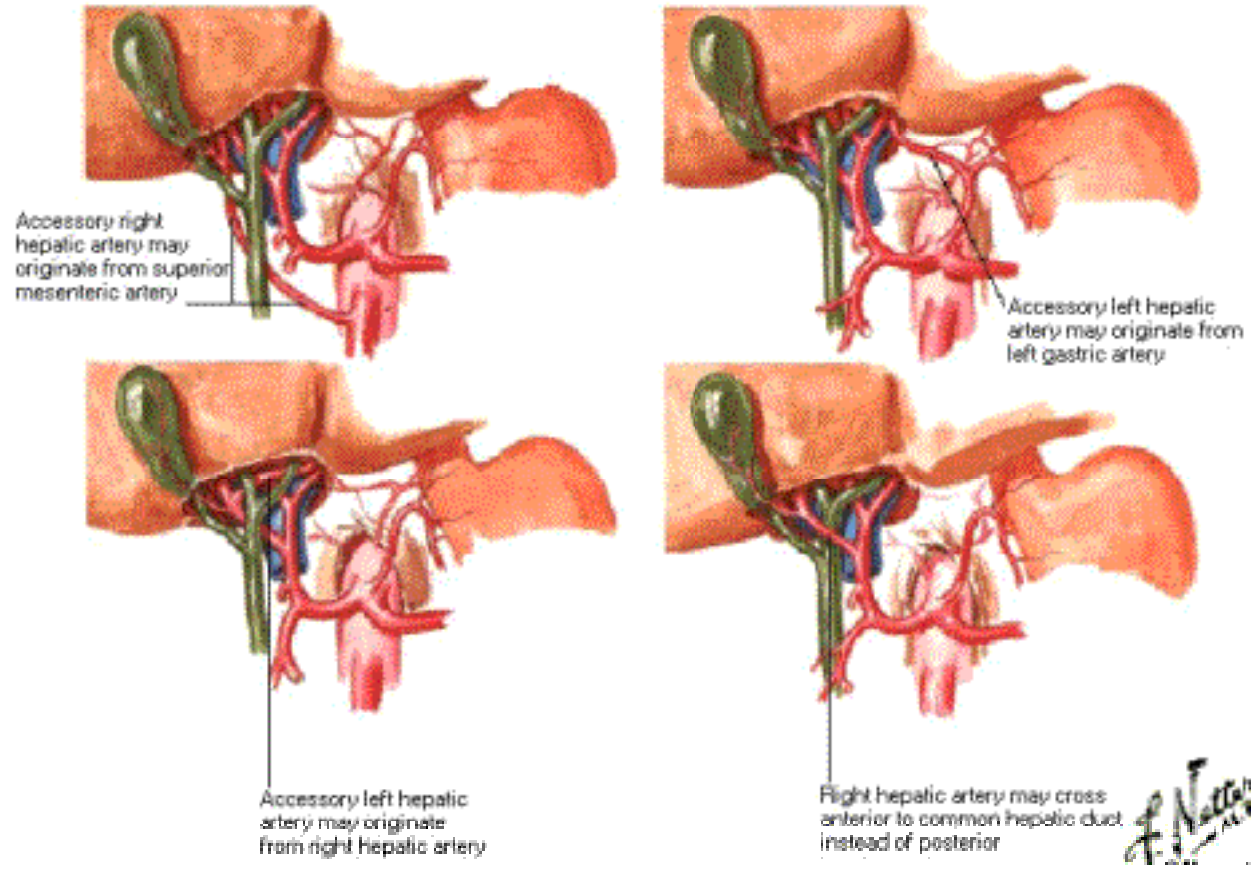
Right gastroepiploic (gastrointestinal) artery takes origin from superior mesenteric artery (note accessory left hepatic artery from left gastric)

Handwritten signature: N. N. N.

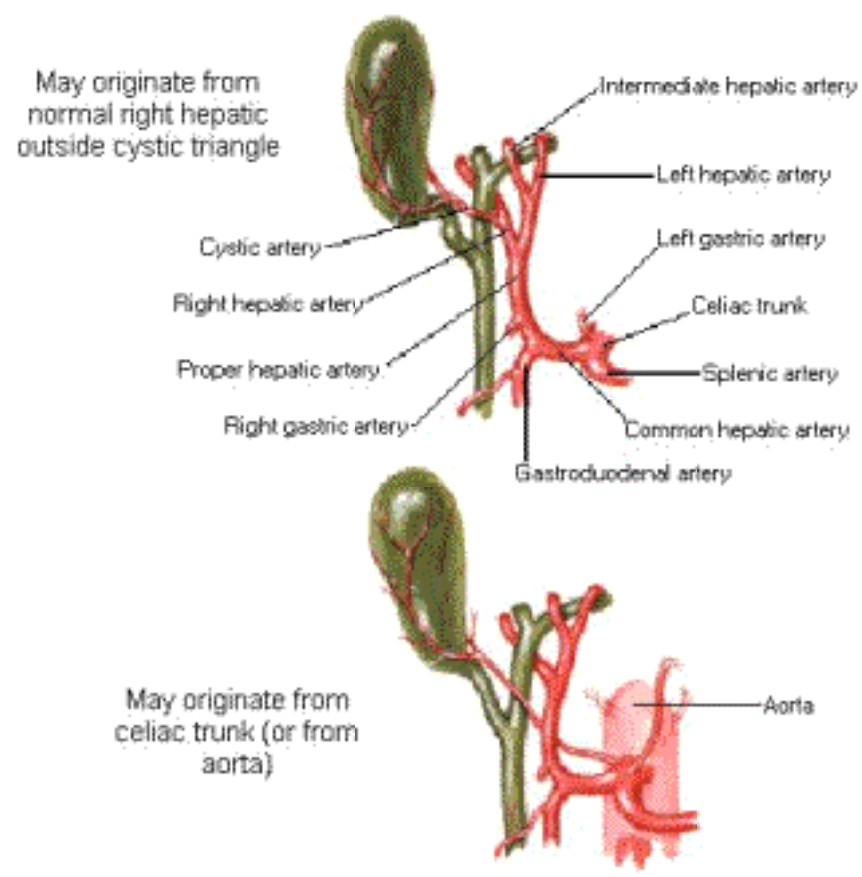
Variations in Hepatic Arteries



Variations in Hepatic Arteries [Continued]



Variations in Cystic Artery 1

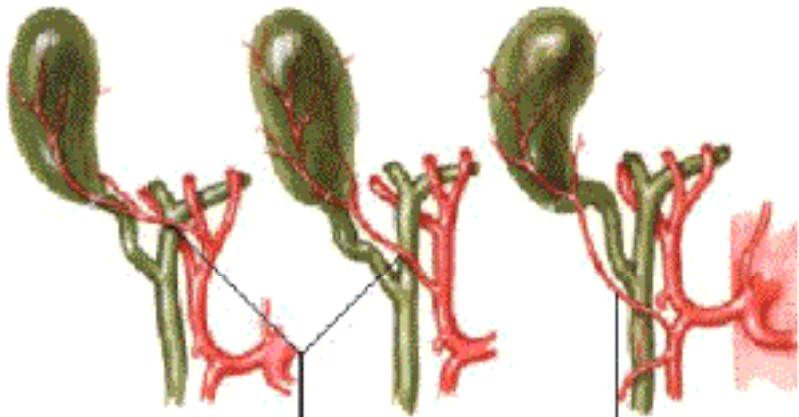


Variations in Cystic Artery 2

May originate from intermediate (or left) hepatic

May originate from proper hepatic

May originate from gastroduodenal

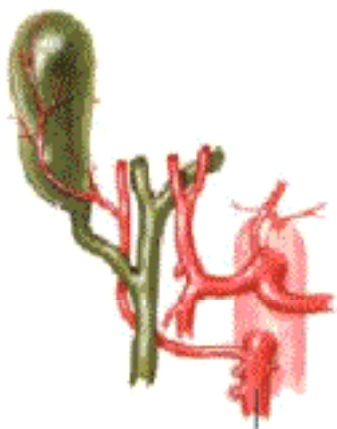

May cross anterior to hepatic duct

May cross anterior to common bile duct

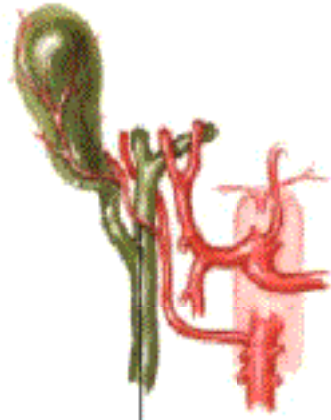Variations in Cystic Artery 3

May originate in cystic triangle from aberrant right hepatic (from superior mesenteric)



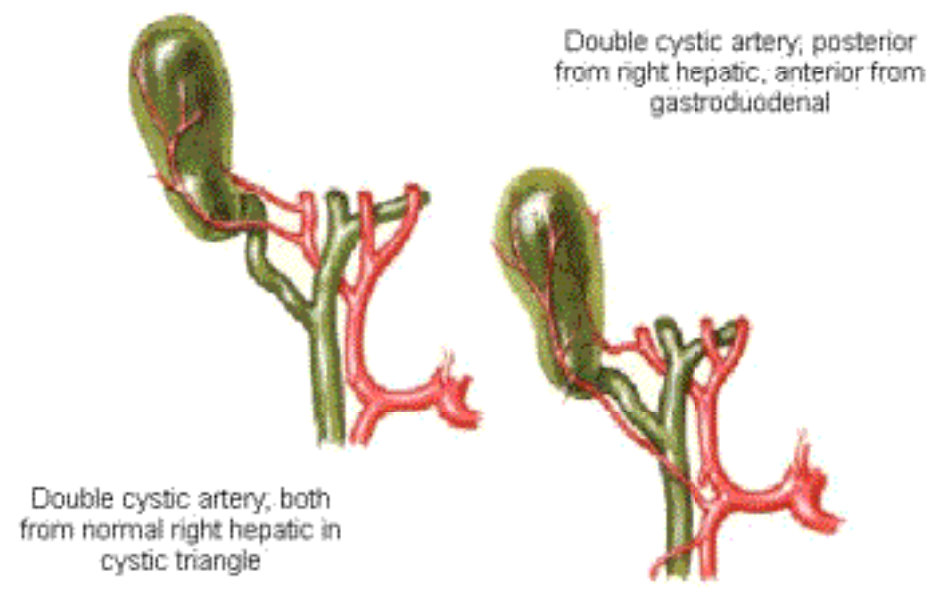
Superior mesenteric artery

May originate outside cystic triangle from aberrant right hepatic

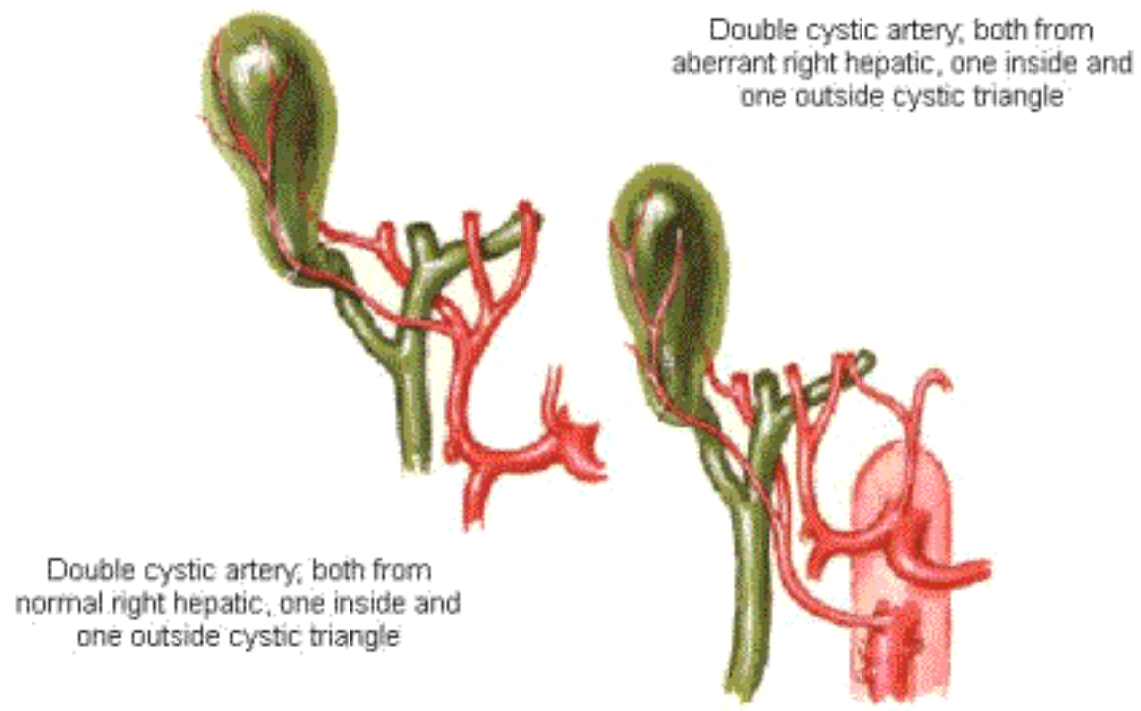


May cross anterior to hepatic duct

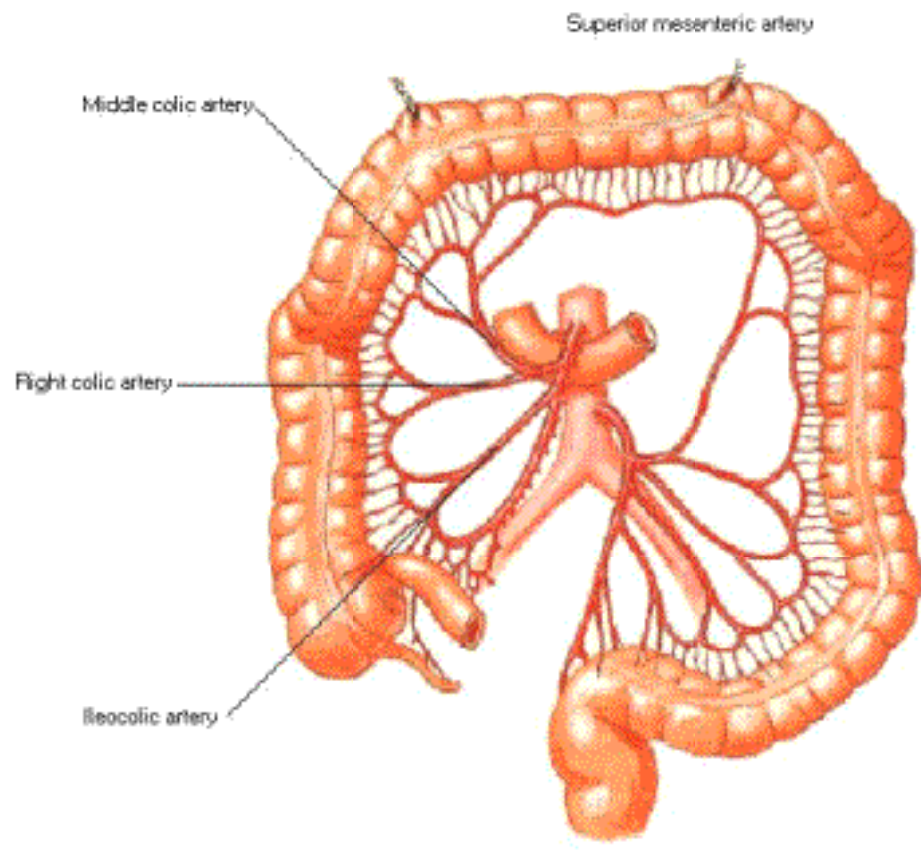
Variations in Cystic Artery 4



Variations in Cystic Artery 5

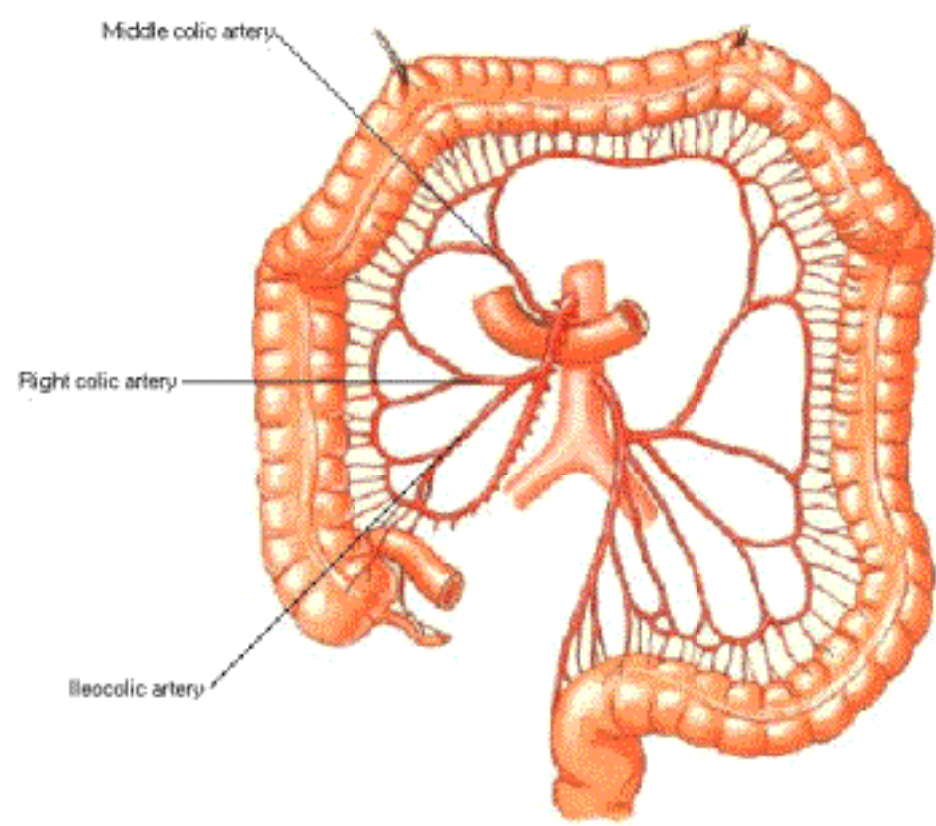


Variations in Colic Arteries 1



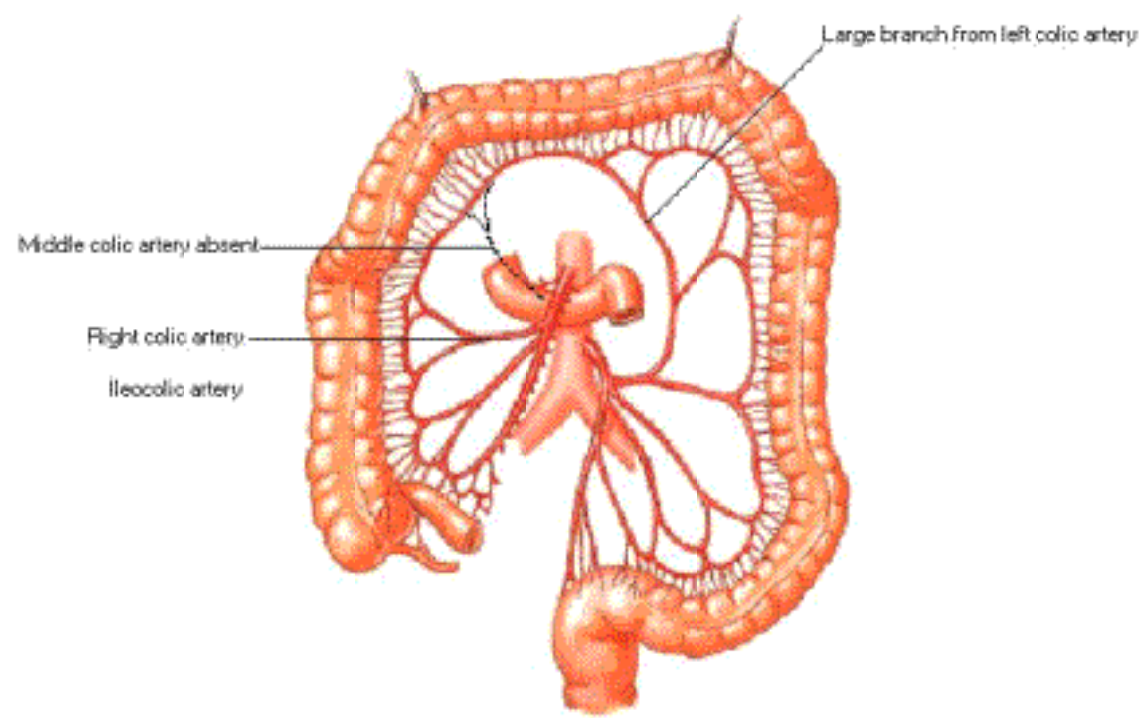
Common origin of right colic and middle colic arteries

Variations in Colic Arteries 2



Common origin of right colic and ileocolic arteries

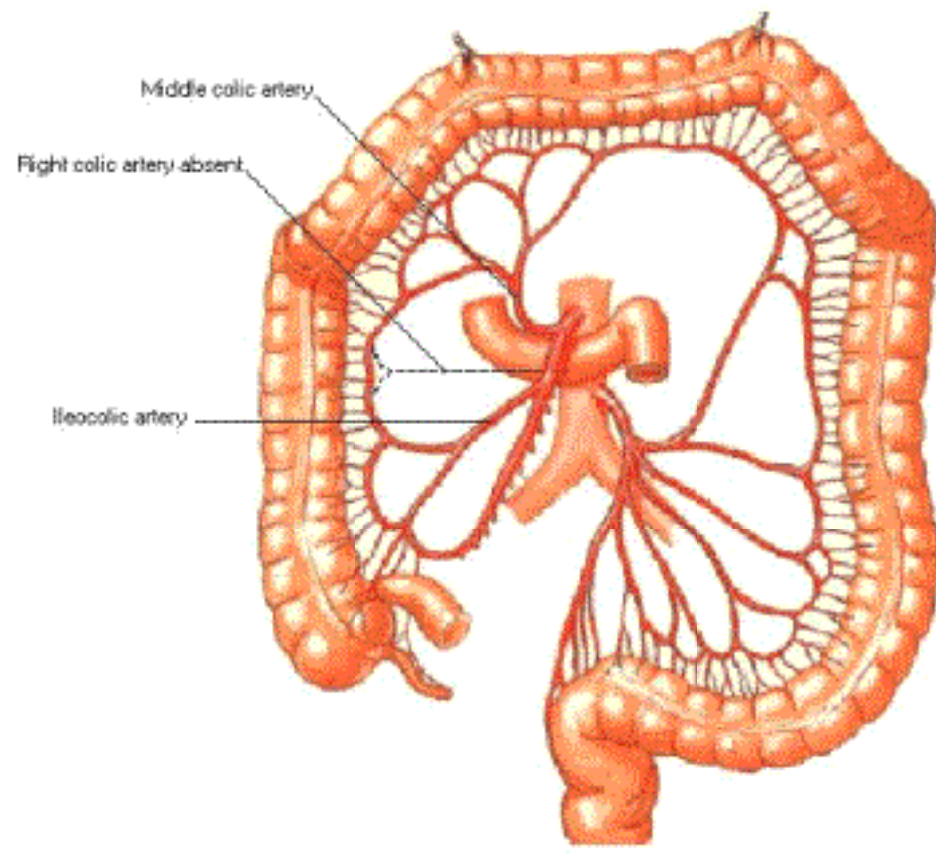
Variations in Colic Arteries 3



Absence of middle colic artery replaced by large branch from left colic artery

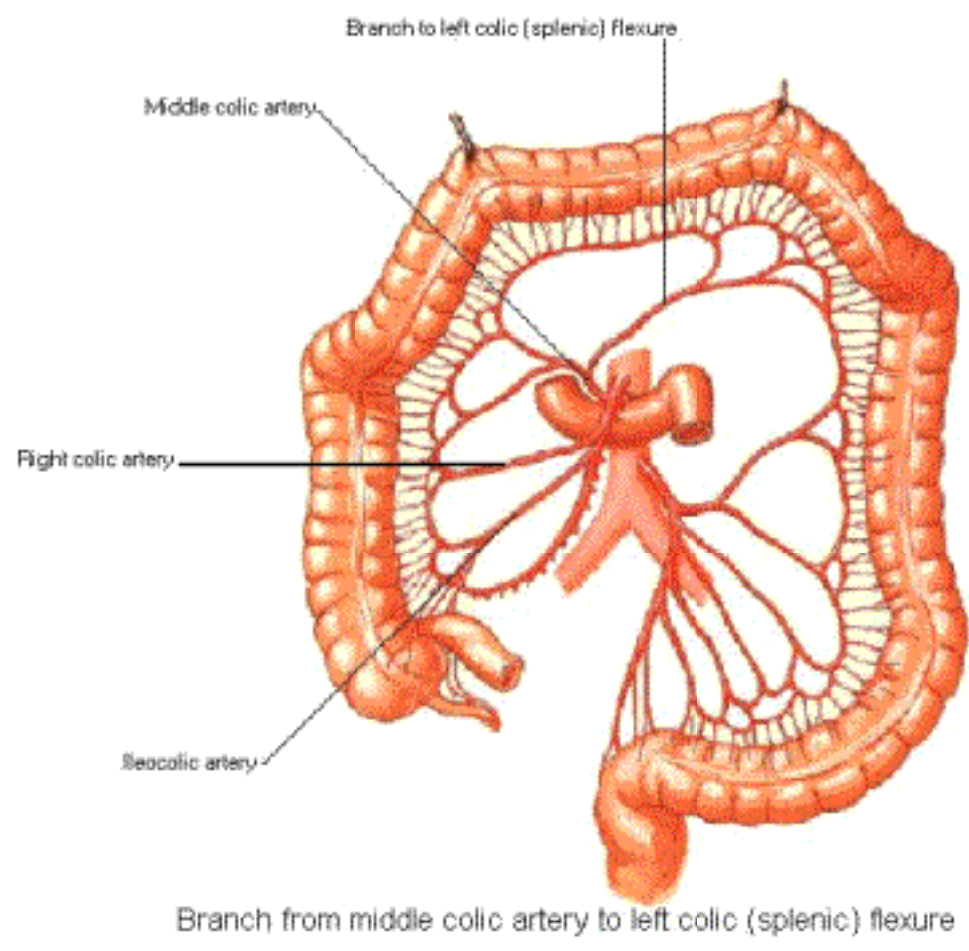


Variations in Colic Arteries 4

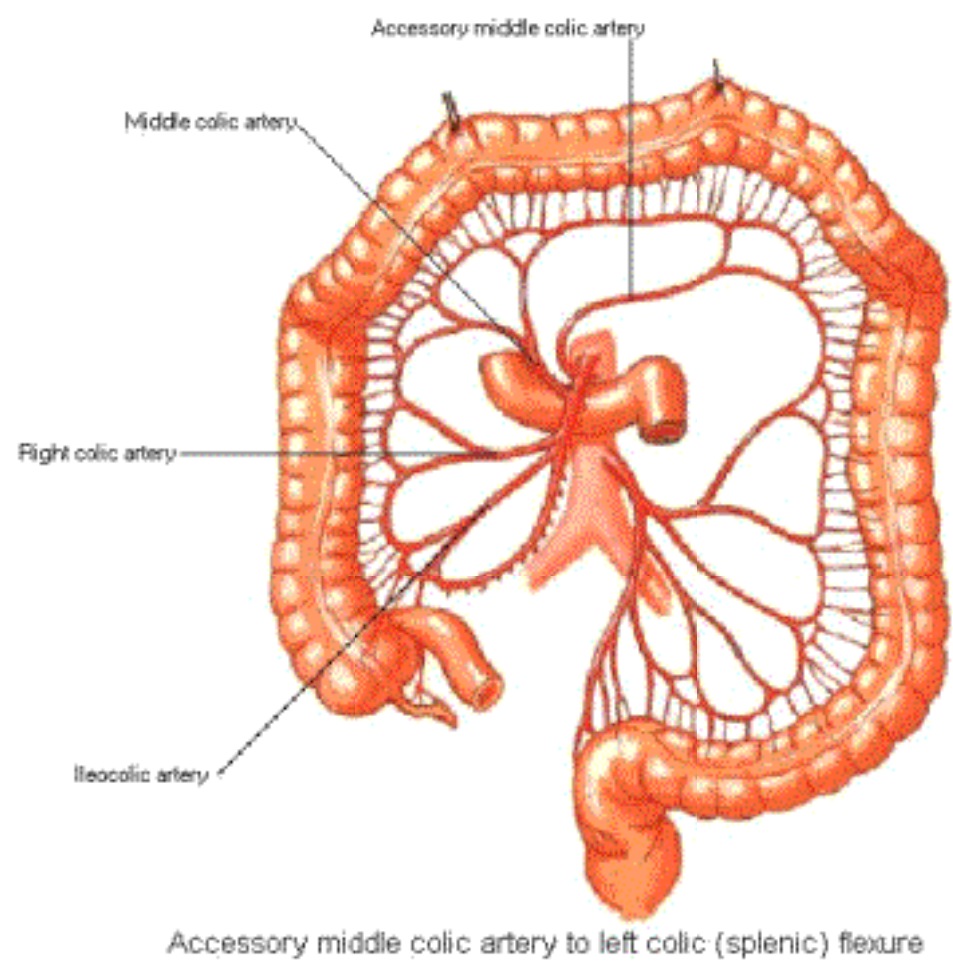


Absence of right colic artery

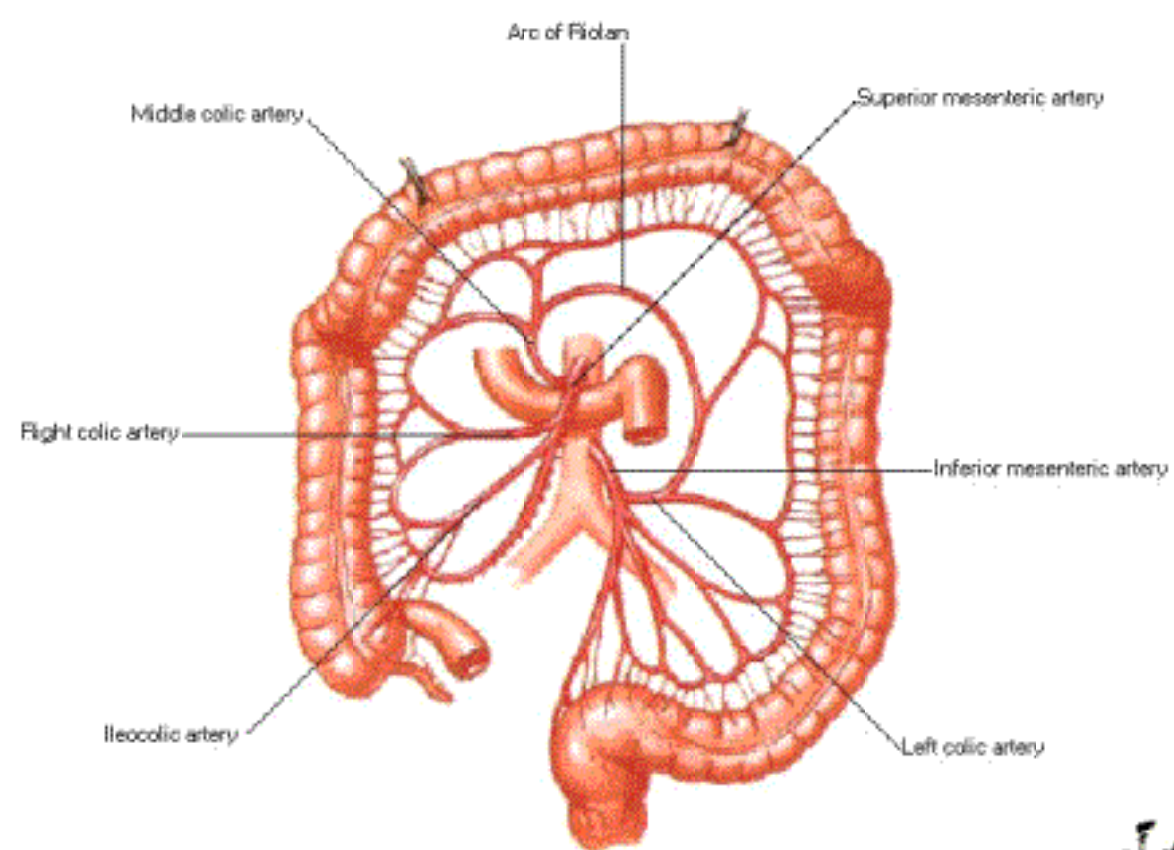
Variations in Colic Arteries 5




Variations in Colic Arteries 6



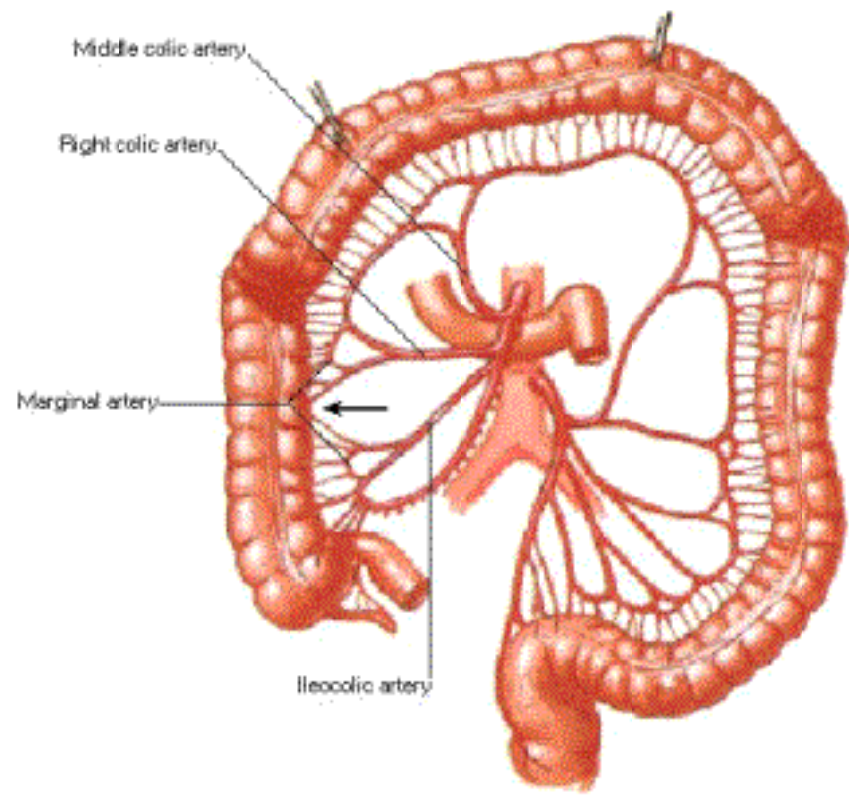
Variations in Colic Arteries 7



Arc of Riolan between middle colic artery and left colic artery

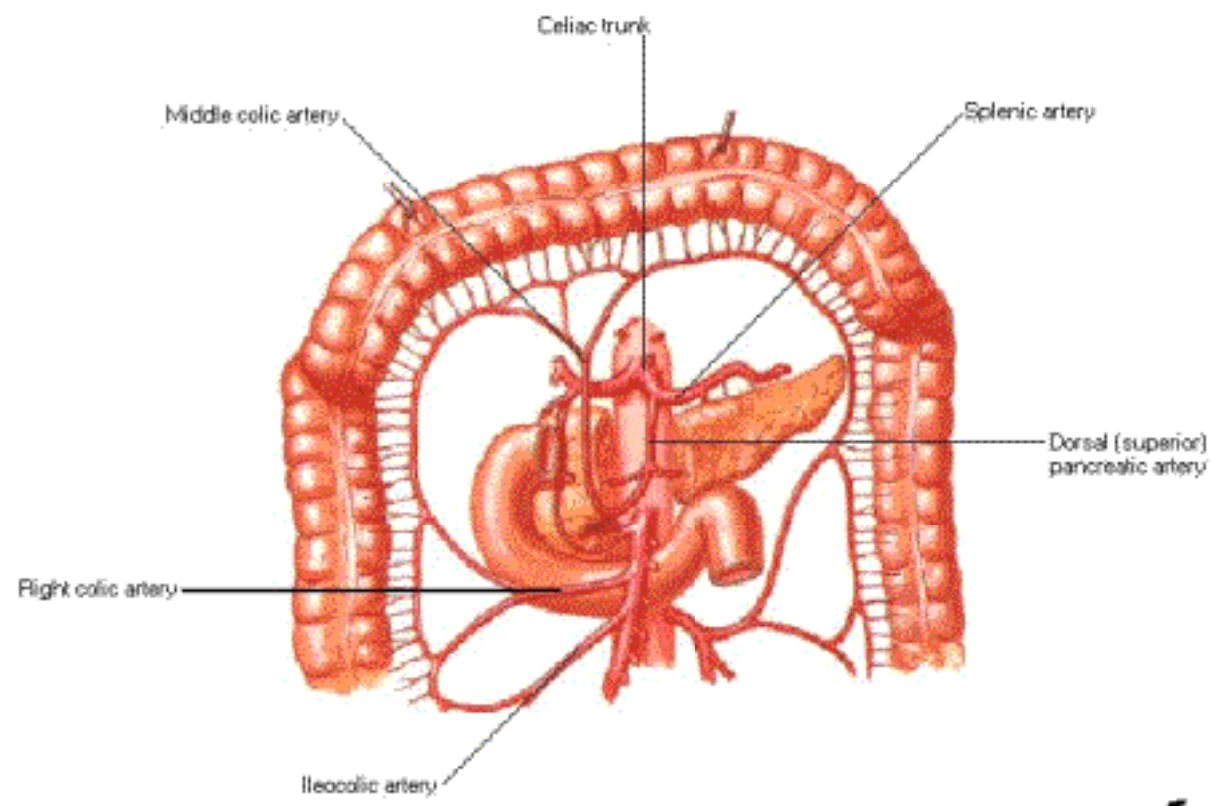


Variations in Colic Arteries 8



Discontinuity of marginal artery between right colic artery and ileocolic arteries

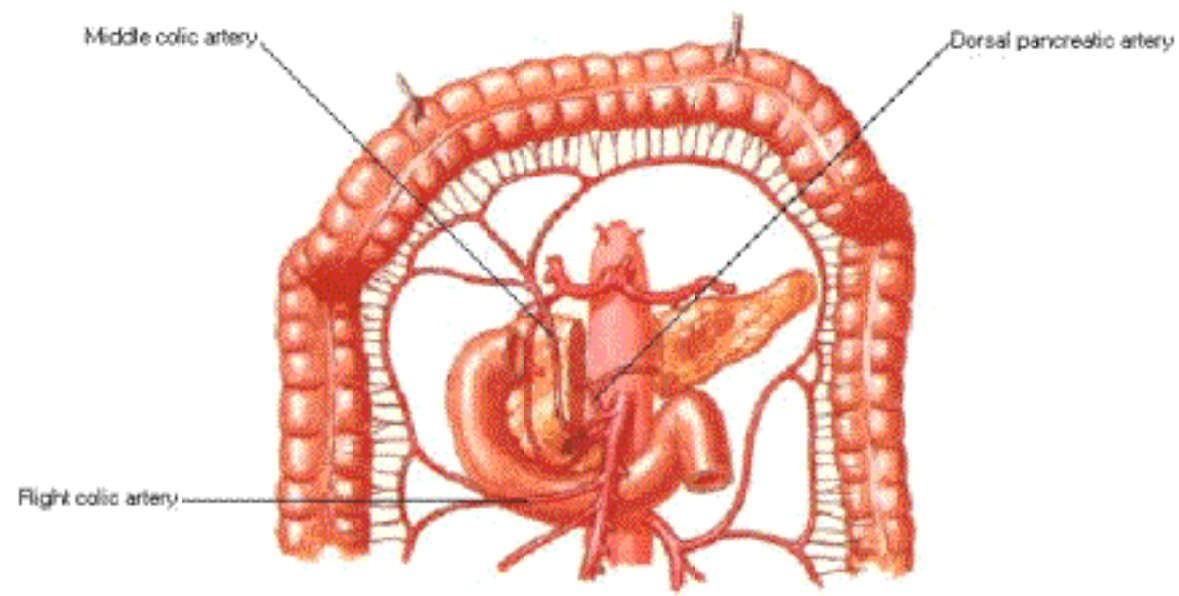
Variations in Colic Arteries 9



Middle colic artery originates from celiac trunk via dorsal pancreatic artery

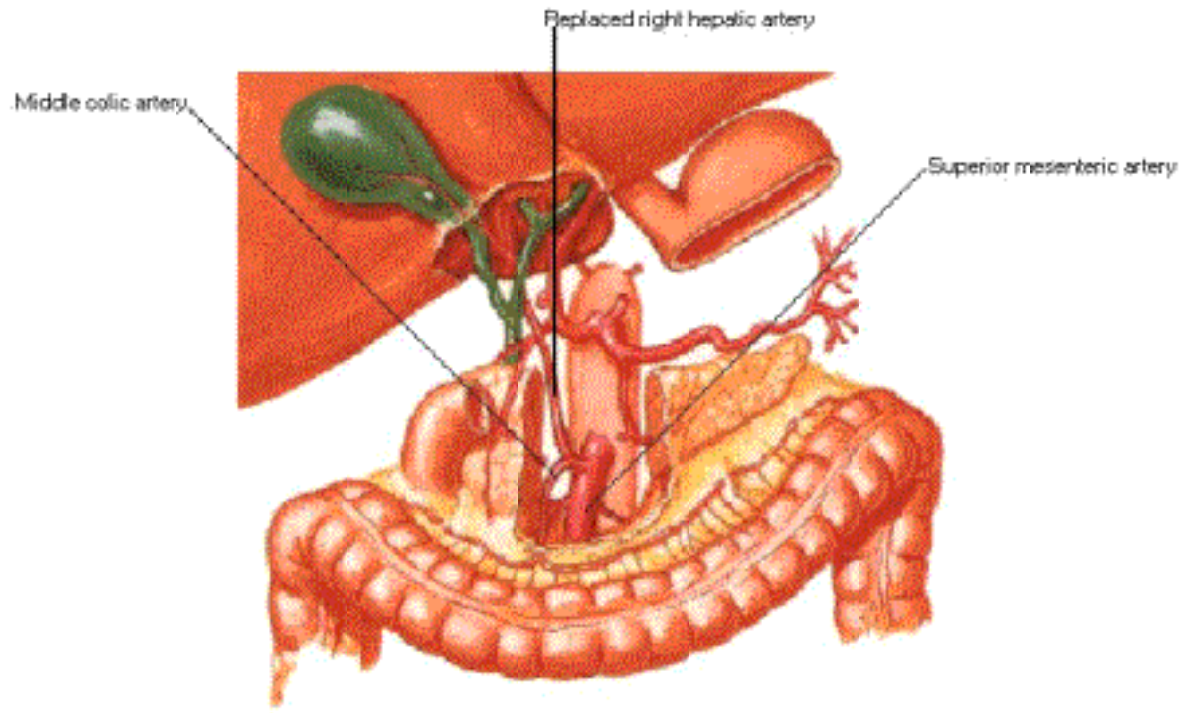
F. N. N. N.

Variations in Colic Arteries 10



Middle colic artery gives origin to dorsal pancreatic artery

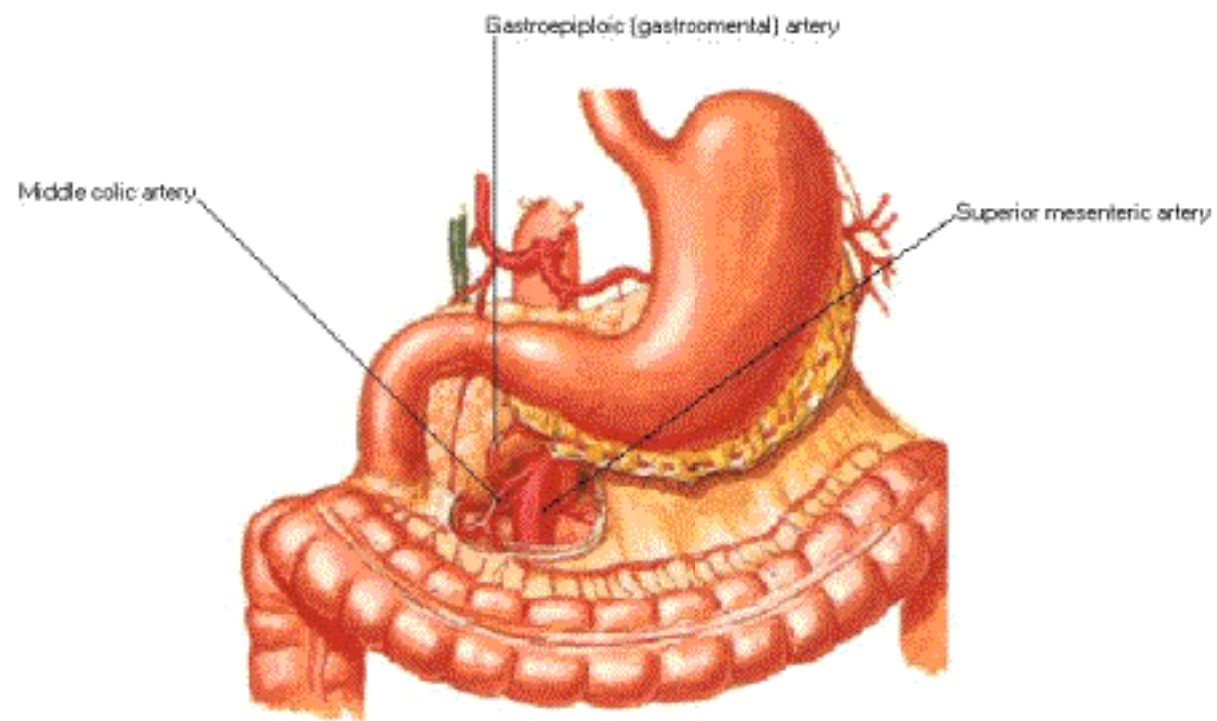
Variations in Colic Arteries 11



Middle colic artery originates from or with replaced right hepatic artery (from superior mesenteric artery)

F. Netter M.D.
© 1989

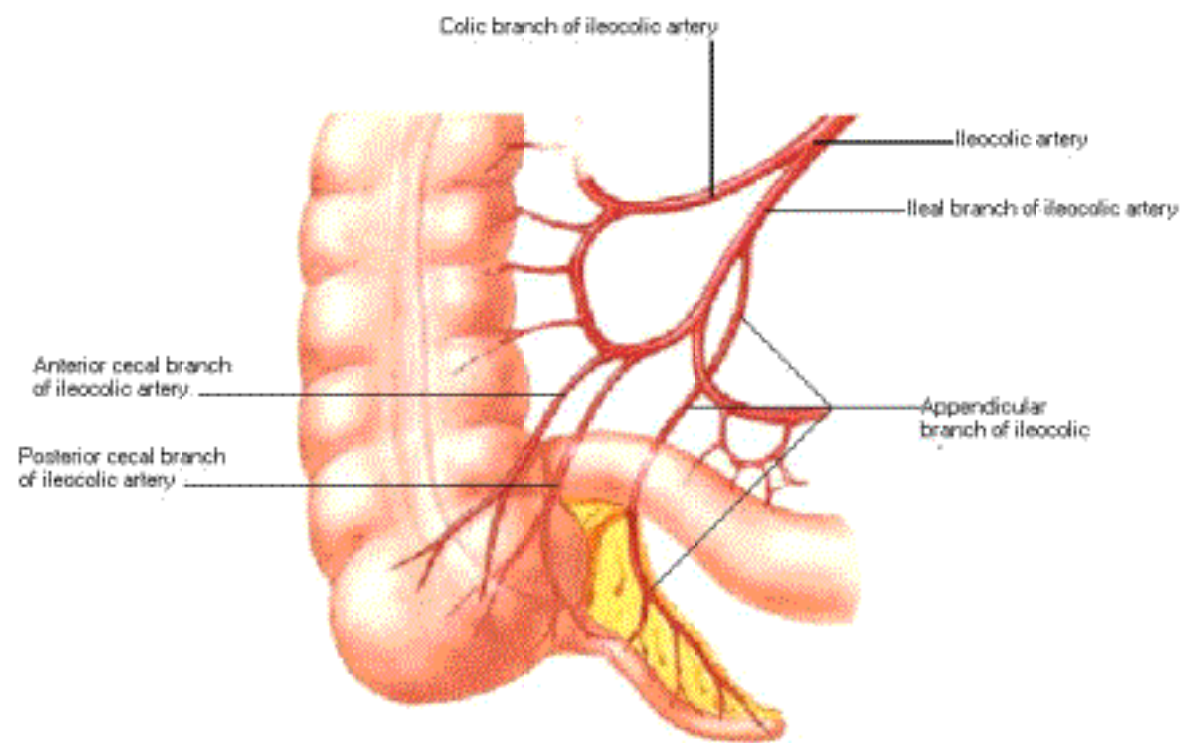
Variations in Colic Arteries 12



Middle colic artery has common origin with right gastroepiploic (gastrointestinal) artery from superior mesenteric artery

F. N. 2011

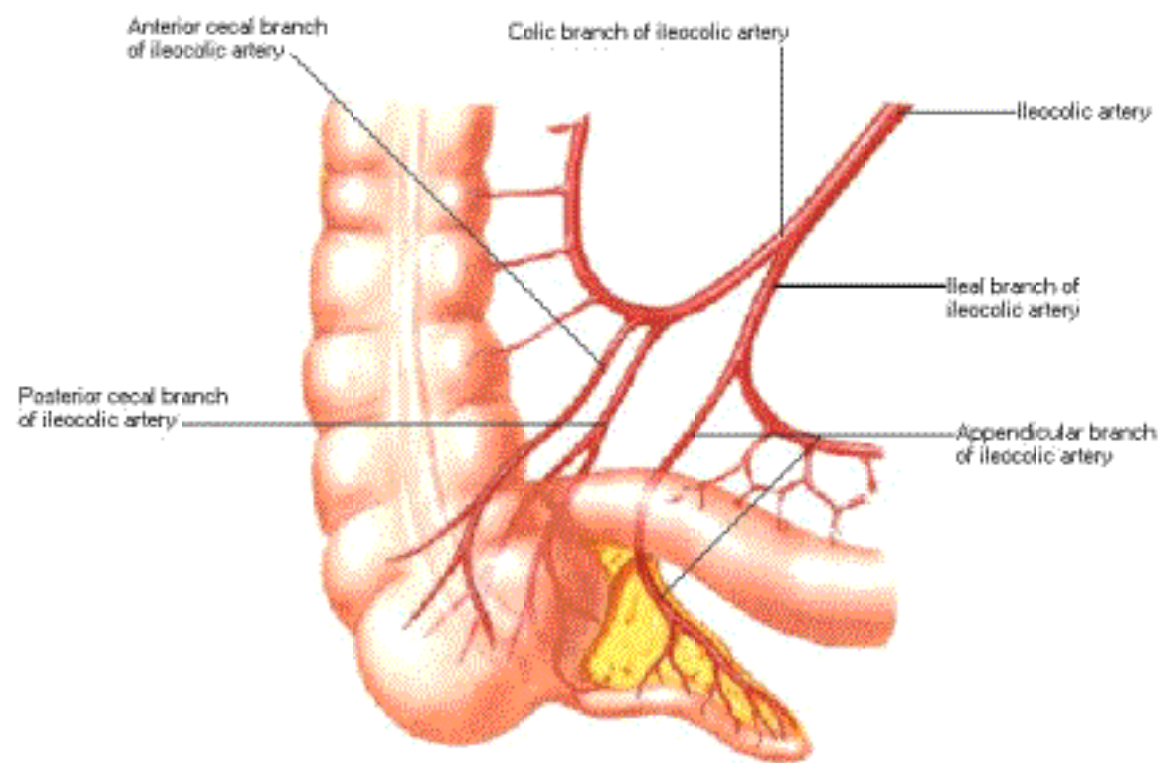
Variations in Cecal and Appendicular Arteries 1



Anterior cecal and posterior cecal arteries originate from arcade between colic and ileal branches of ileocolic; appendicular artery from ileal branch

F. Netter M.D.
© Novartis

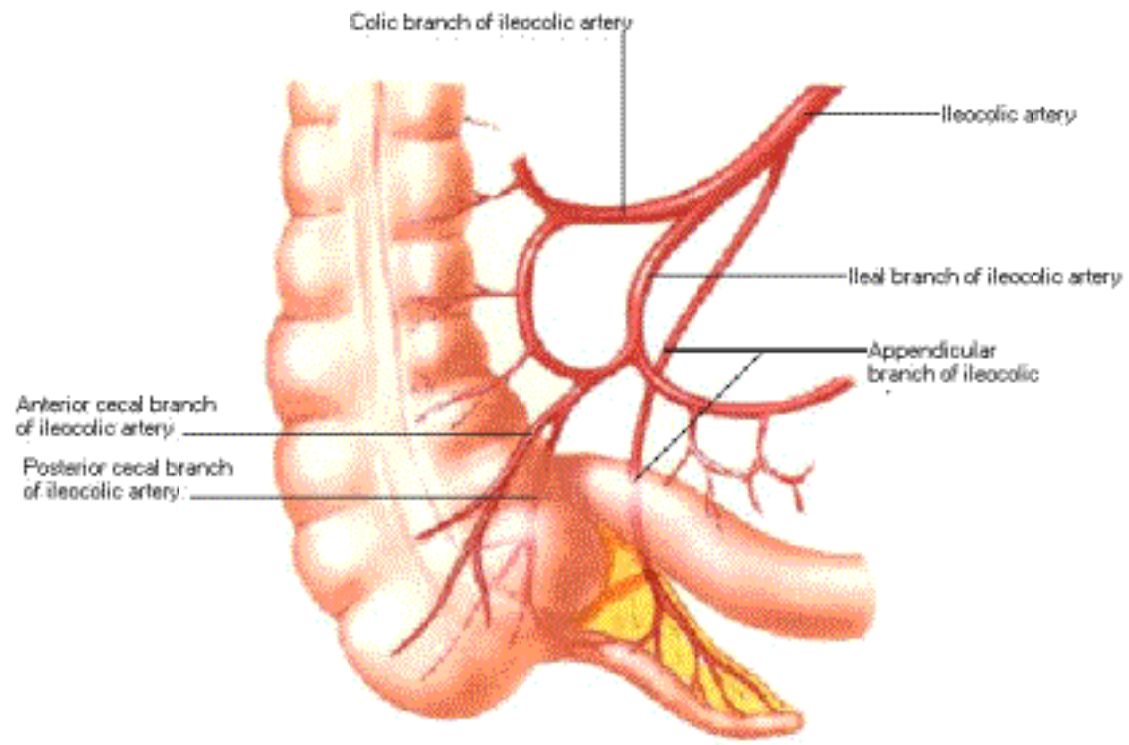
Variations in Cecal and Appendicular Arteries 2



Anterior cecal and posterior cecal arteries originate from colic branch; appendicular artery from ileal branch of ileocolic artery



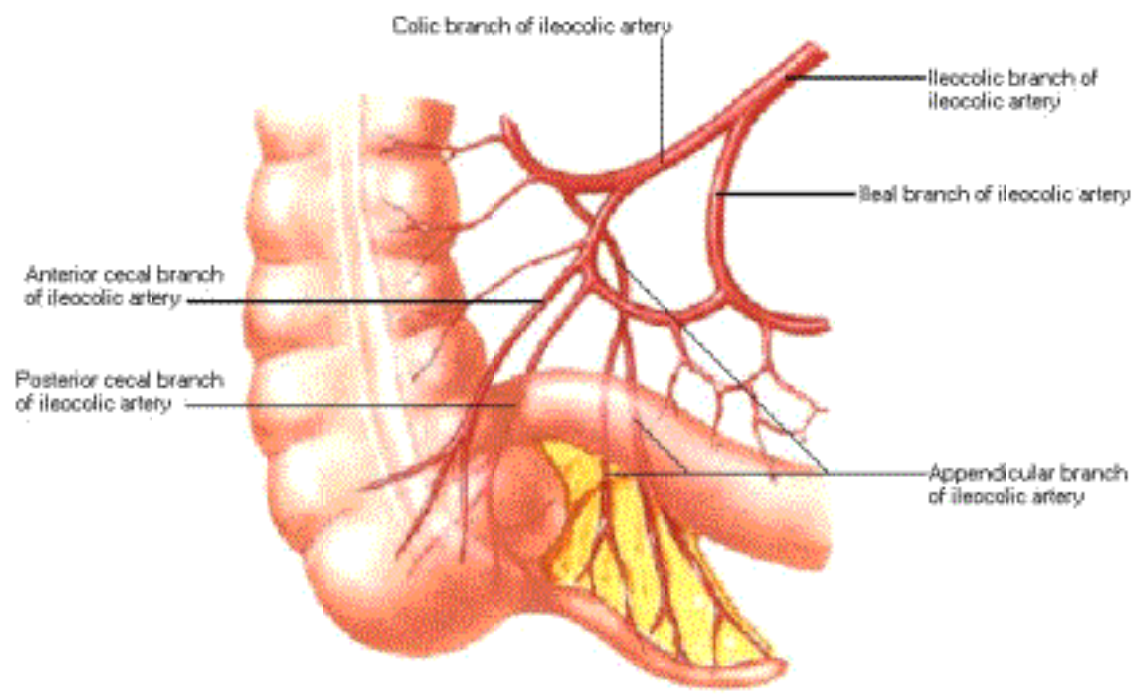
Variations in Cecal and Appendicular Arteries 3



Anterior cecal and posterior cecal arteries have common origin from arcade; appendicular artery from ileocolic artery proper



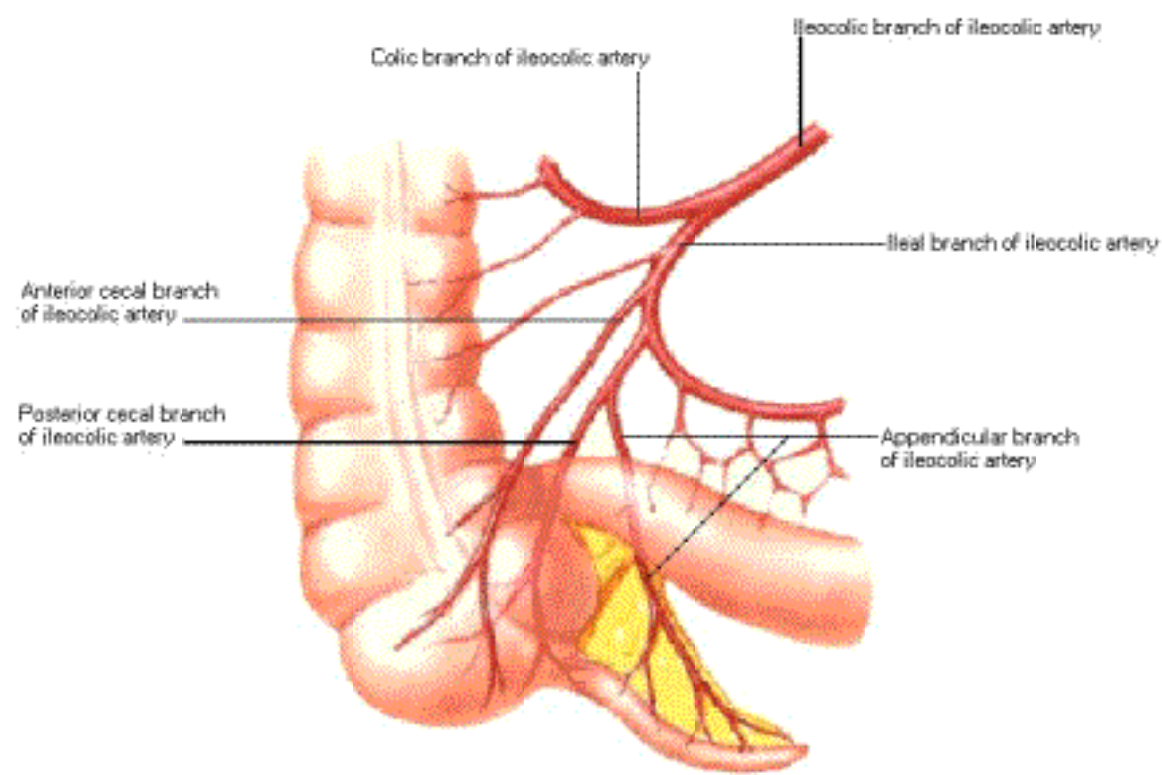
Variations in Cecal and Appendicular Arteries 4



Anterior cecal and posterior cecal arteries originate from arcade between colic and ileal branches of ileocolic artery, appendicular artery from colic branch bifurcates high

F. Netter M.D.
© Elsevier

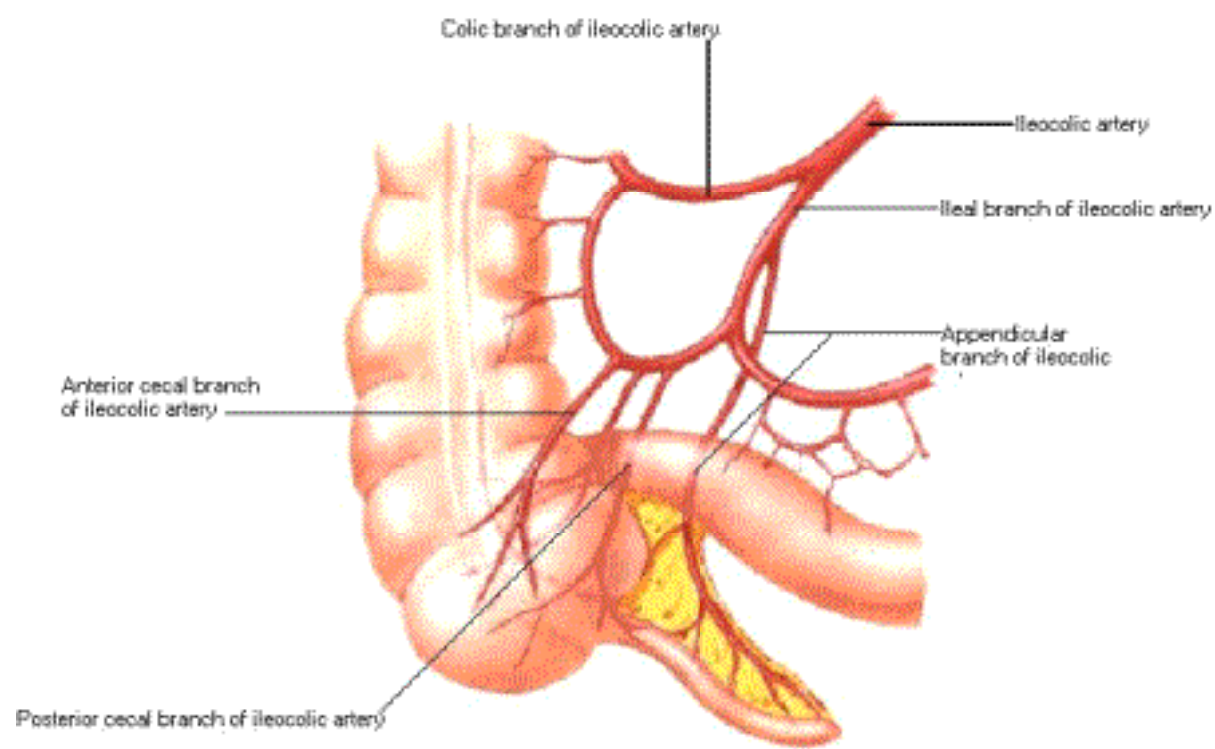
Variations in Cecal and Appendicular Arteries 5



Anterior cecal and posterior cecal arteries originate from ileal branch of ileocolic artery, appendicular artery from posterior cecal artery

F. N. N. N.
© Nov 1

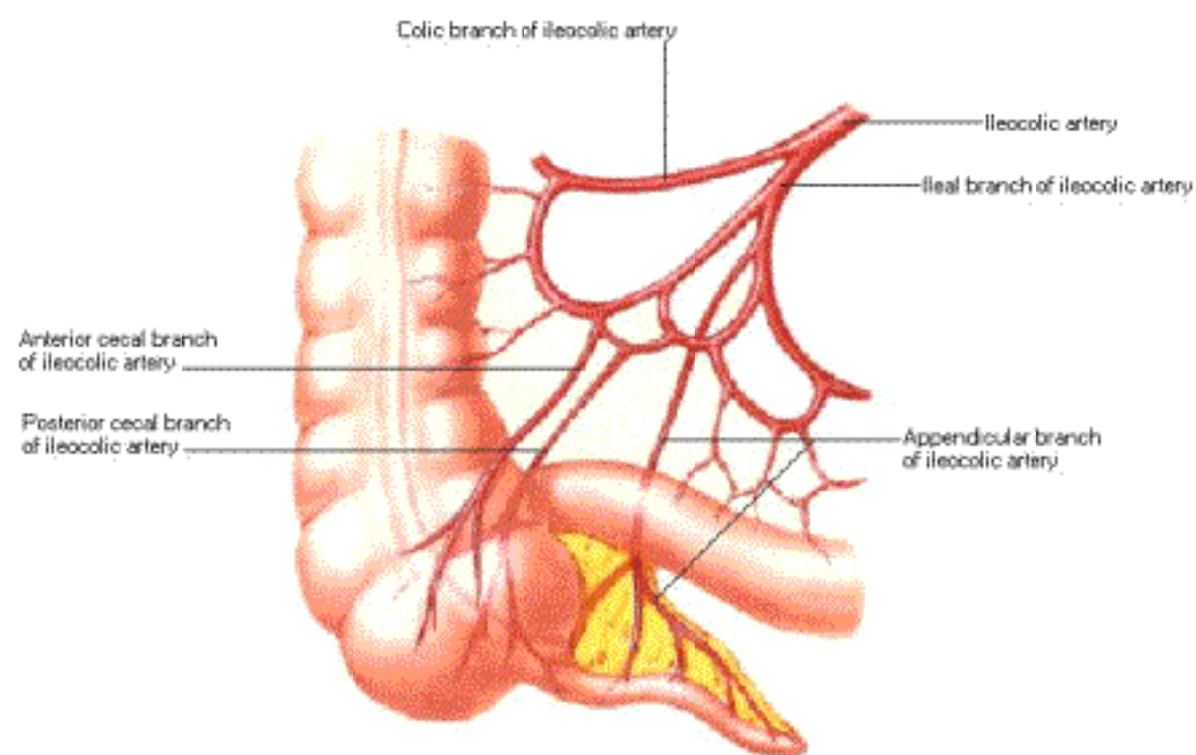
Variations in Cecal and Appendicular Arteries 6



Anterior cecal and two posterior cecal arteries originate from arcade; appendicular artery from ileal branch of ileocolic artery



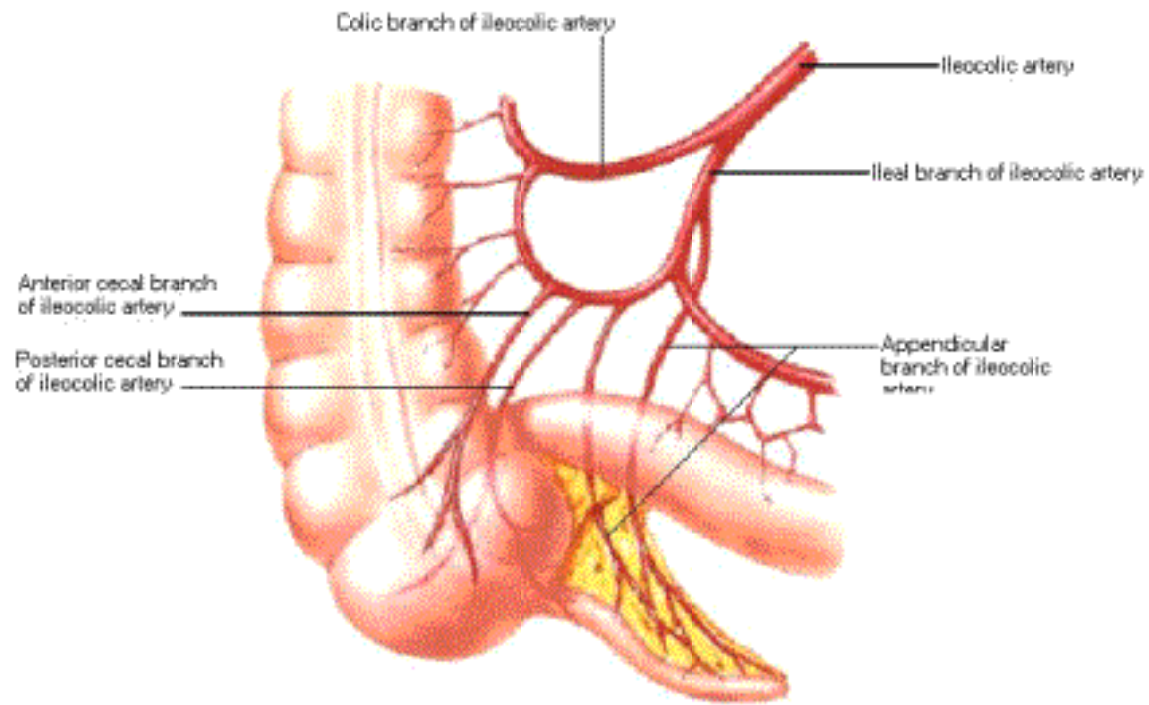
Variations in Cecal and Appendicular Arteries 7



Multiple arcades between ileal branch and colic branch of ileocolic artery; anterior cecal and posterior cecal arteries originate from these arcades; appendicular artery from ileal branch of ileocolic artery

F. Netter
© Elsevier

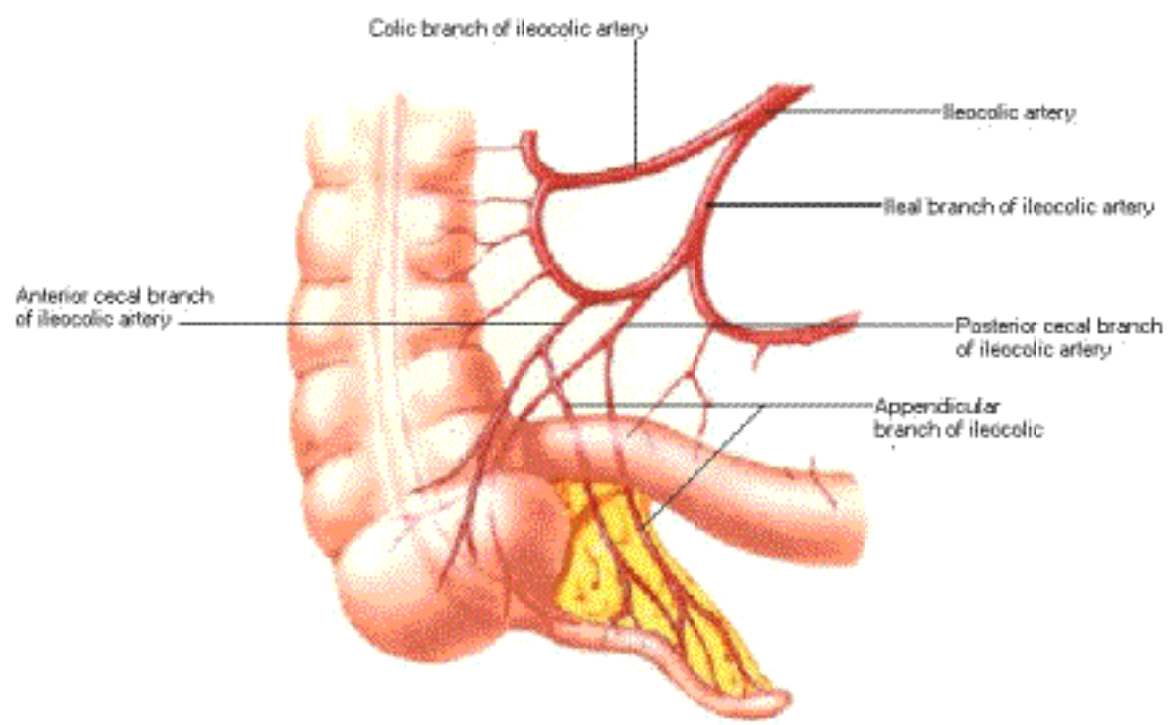
Variations in Cecal and Appendicular Arteries 8



Anterior cecal and posterior cecal arteries originate from arcade between colic and ileal branches of ileocolic artery; two appendicular arteries, one from arcade, one from ileal branch of ileocolic artery

F. Netter
© Netter

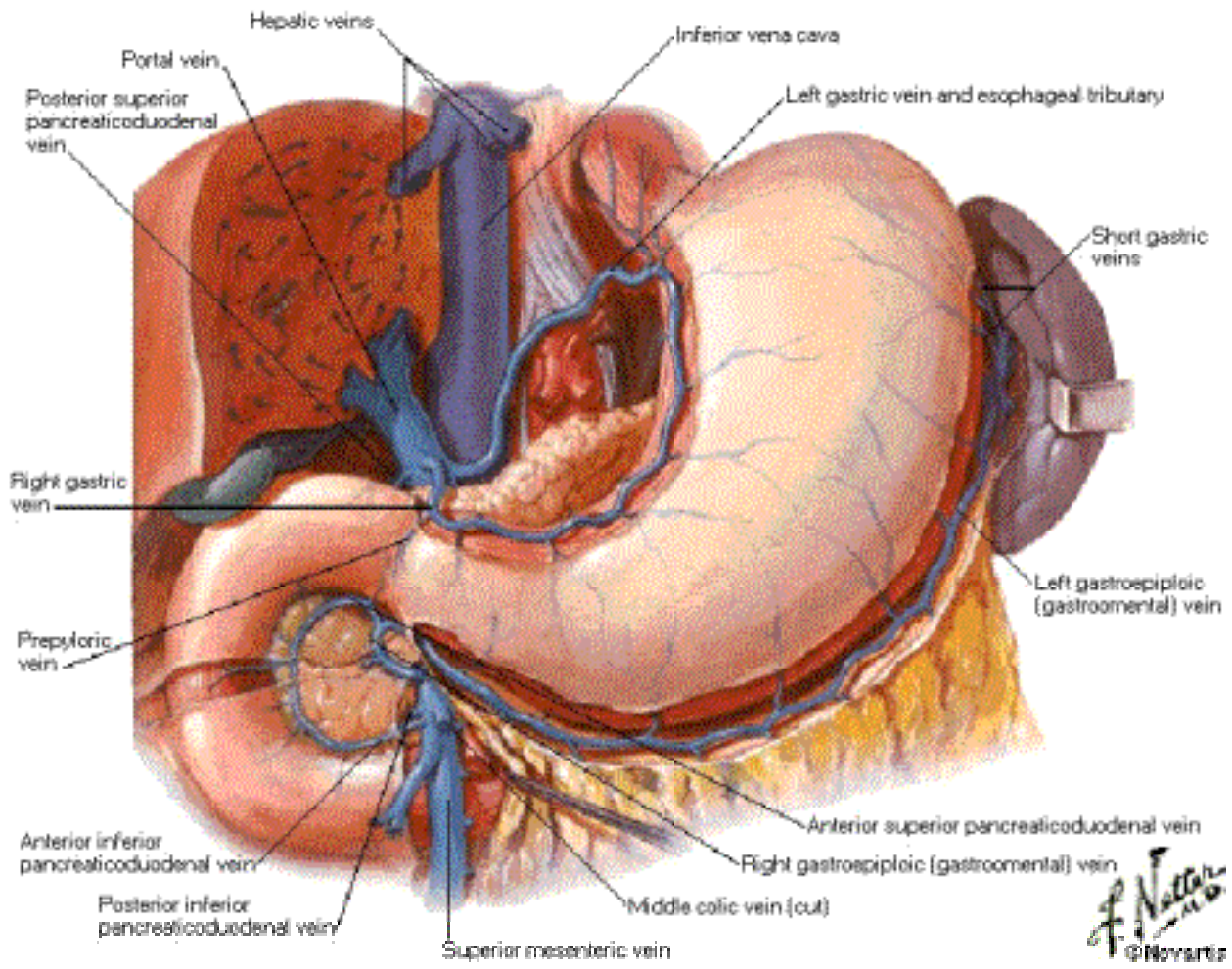
Variations in Cecal and Appendicular Arteries 9



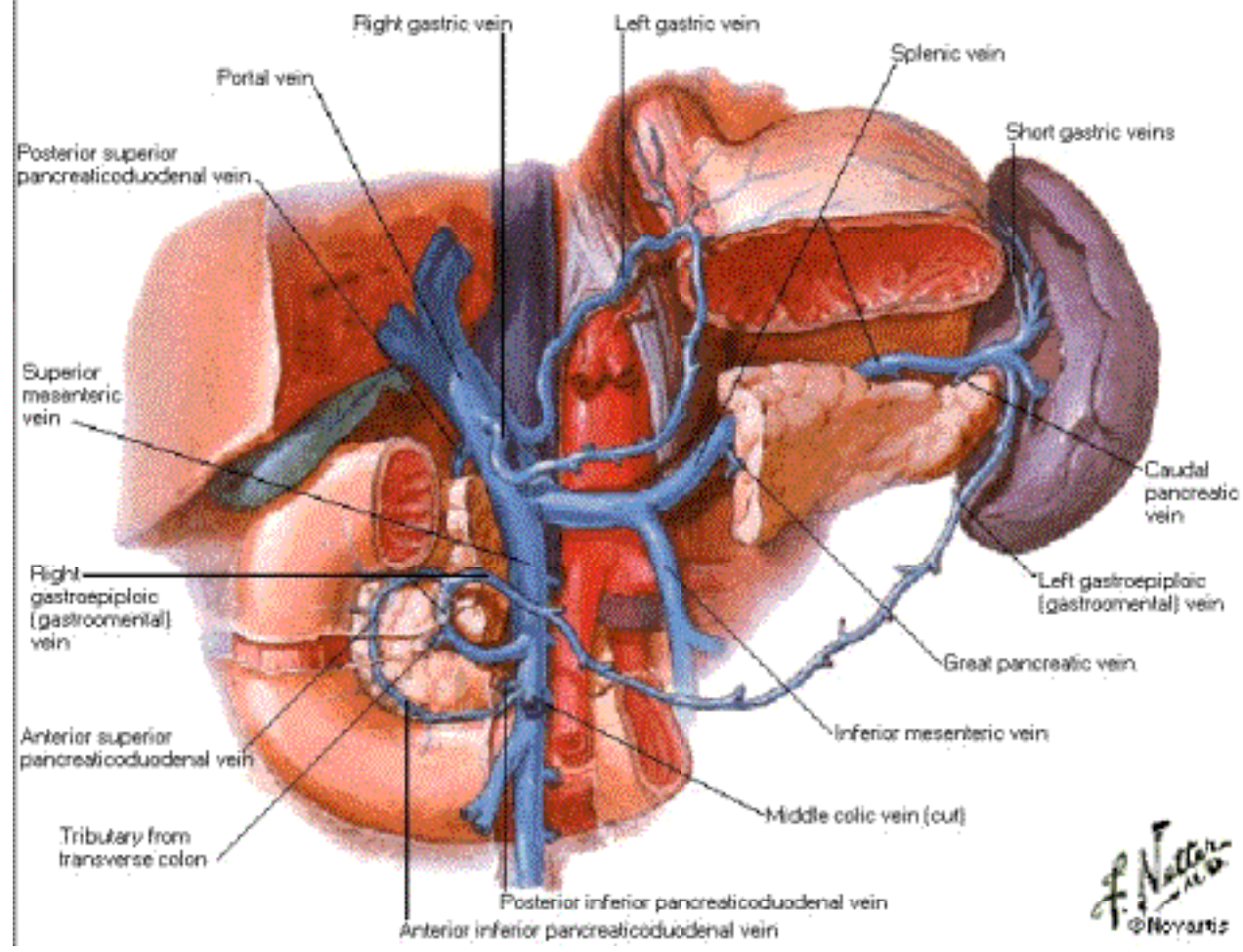
Anterior cecal and posterior cecal arteries originate from arcade; two appendicular arteries, one from anterior cecal, other from posterior cecal artery

F. Natta
© Noval

Veins of Stomach, Duodenum and Pancreas

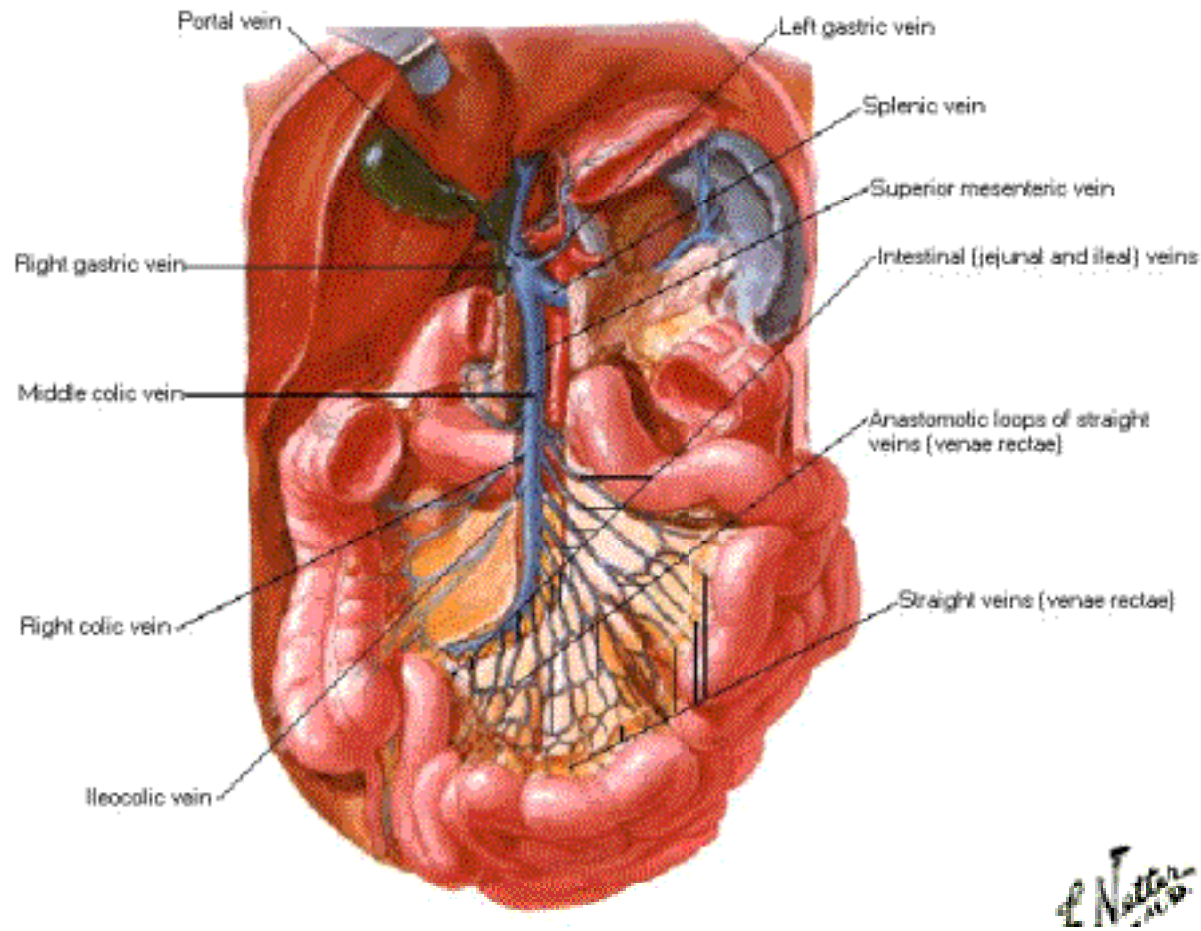


Veins of Stomach, Duodenum and Pancreas [Continued]



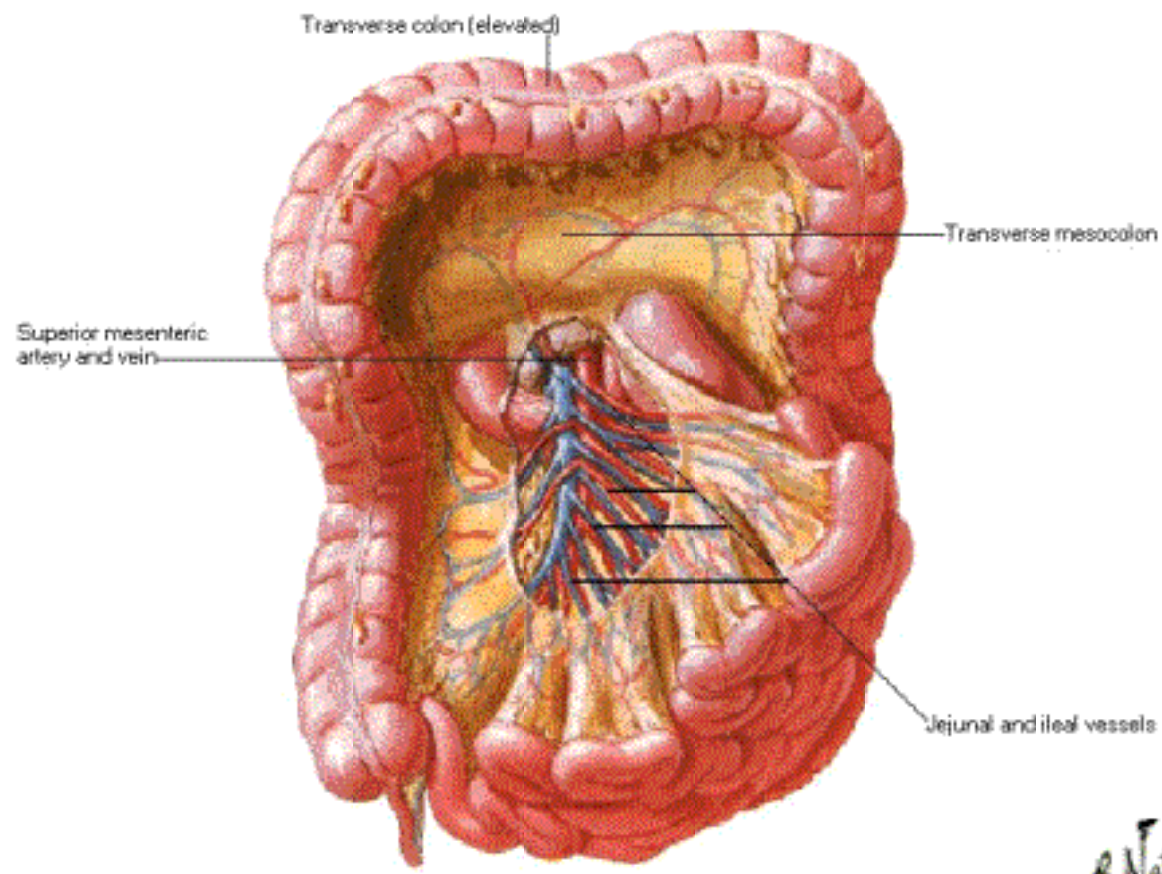
Veins of Small Intestine

Transverse Colon Cut



Veins of Small Intestine

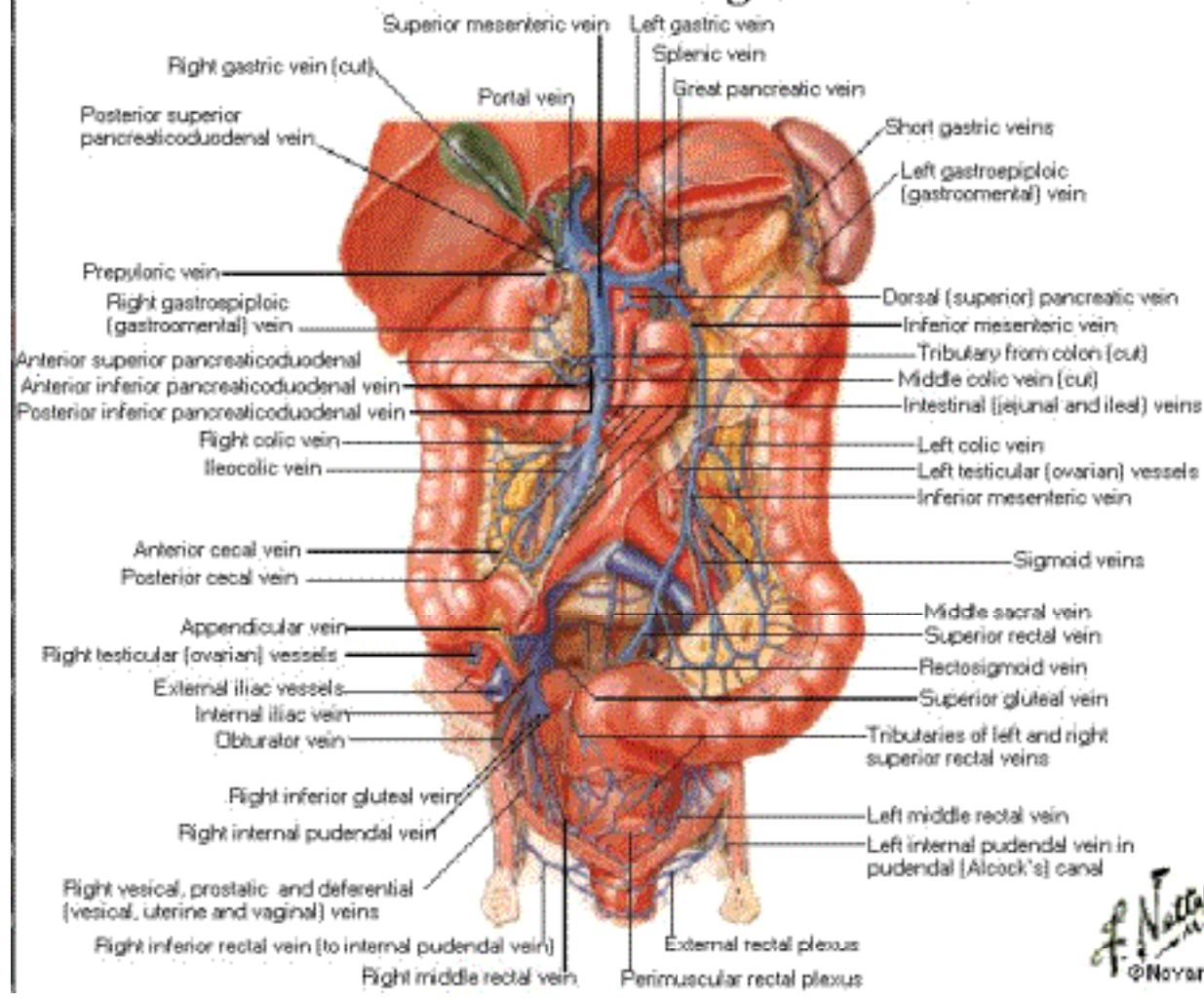
Transverse Colon Elevated



Relations of superior mesenteric vein and artery in root of mesentery

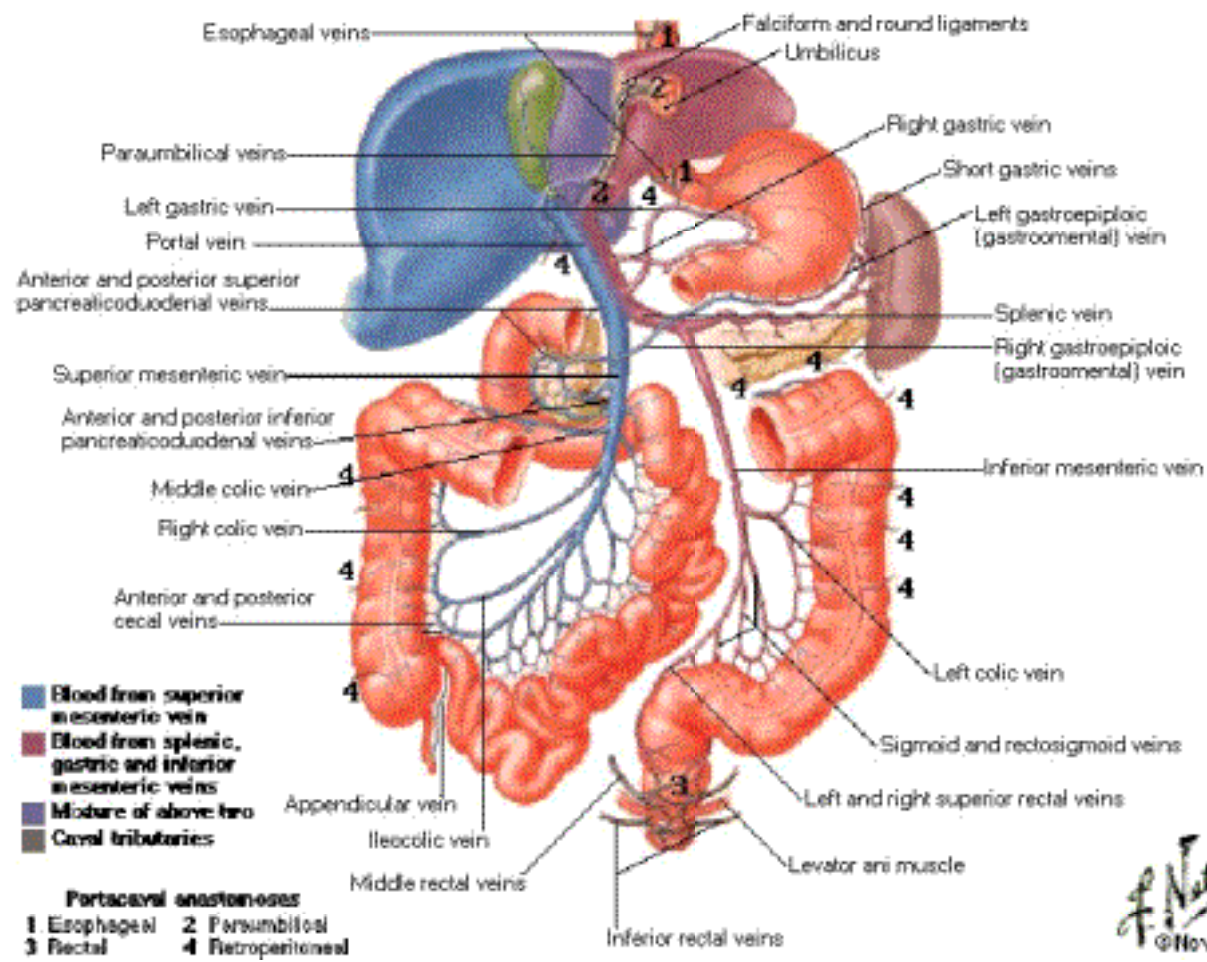
F. Net
© 1886

Veins of Small and Large Intestines



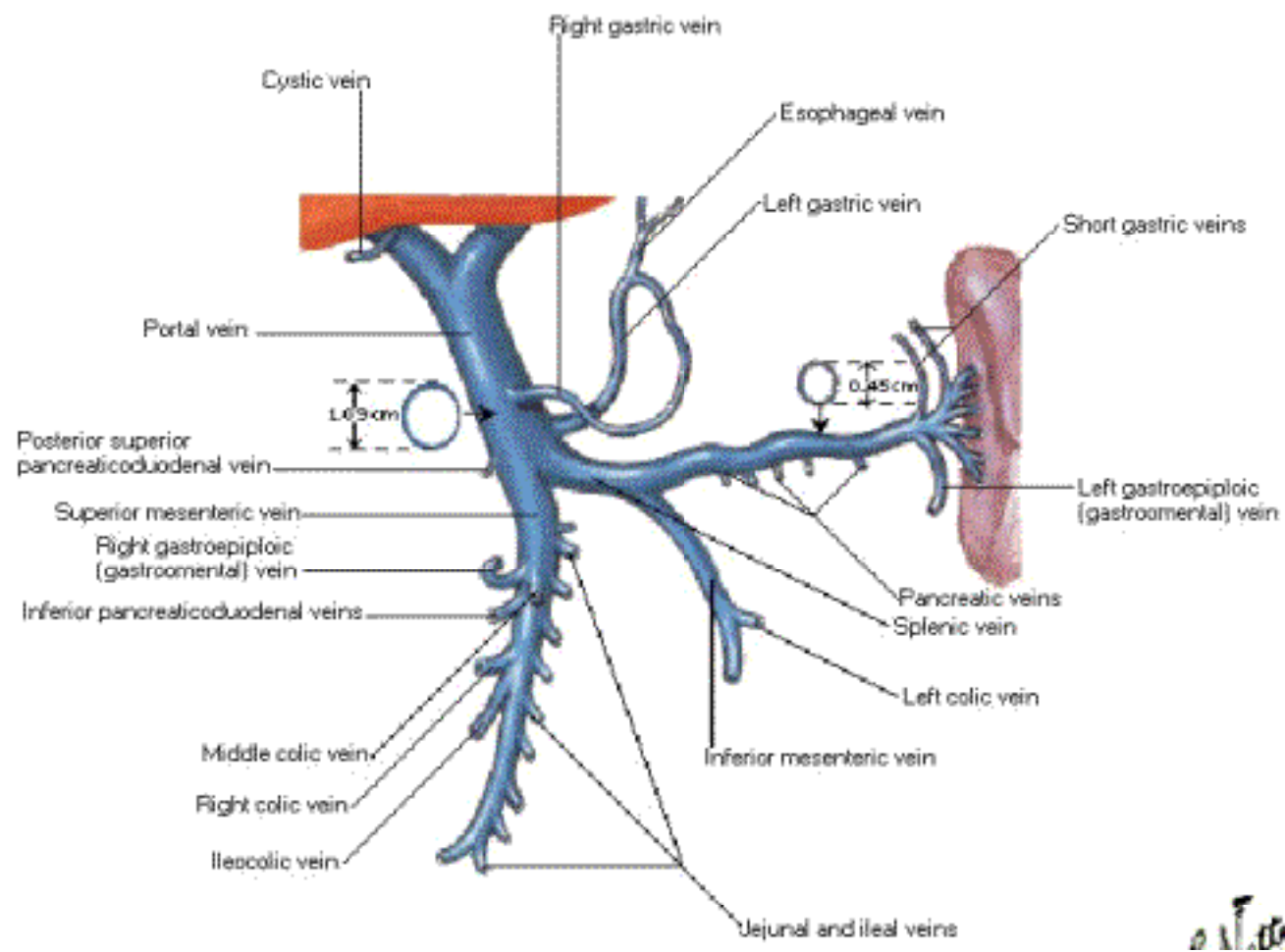
Portal Vein Tributaries

Portacaval Anastomoses



f. N. G.
©Nov

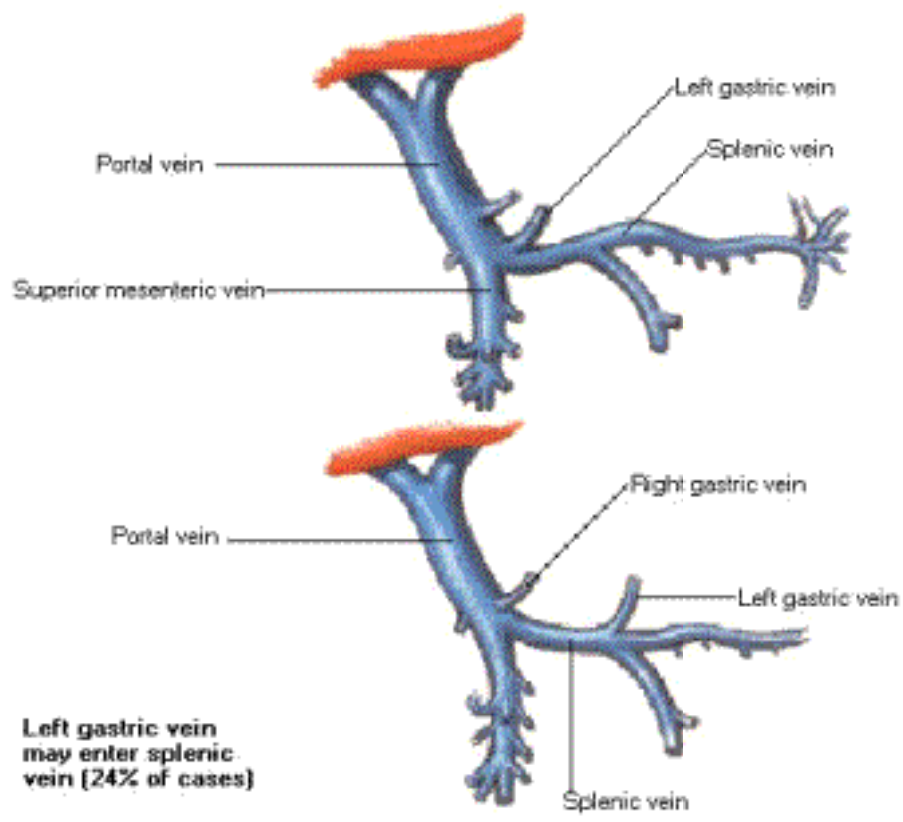
Typical Arrangement of Portal Vein



0 1 10

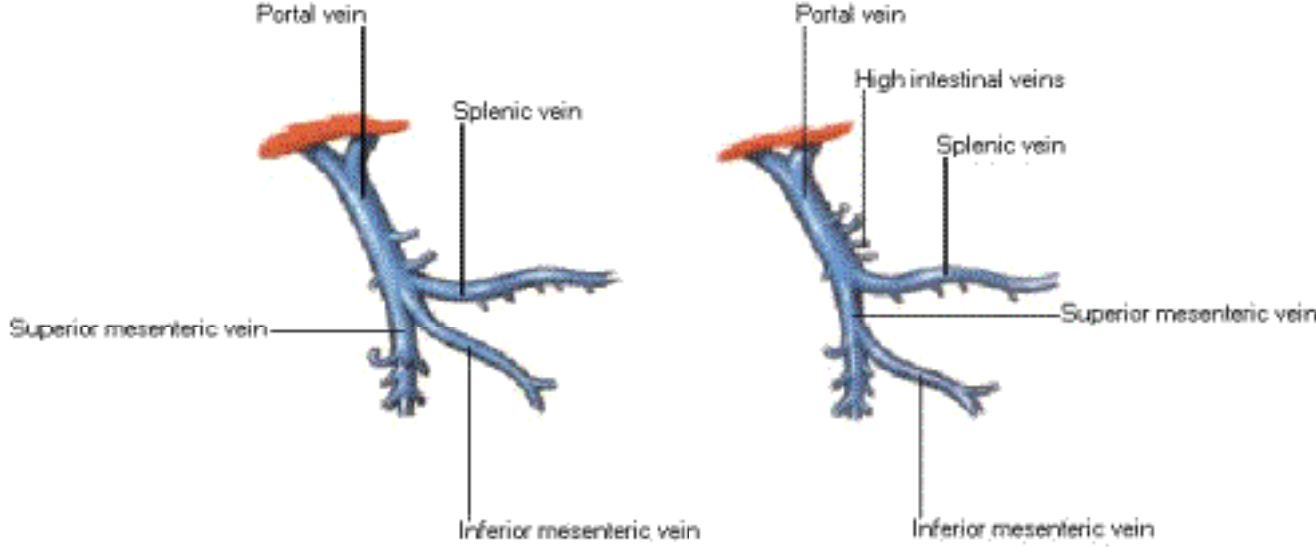
Variations of Portal Vein

Left gastric vein often enters junction of splenic and superior mesenteric veins



Left gastric vein may enter splenic vein (24% of cases)

Variations of Portal Vein [Continued]

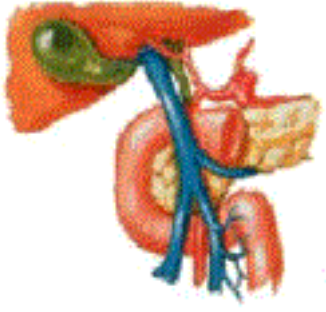


Inferior mesenteric vein may enter junction of splenic and superior mesenteric veins

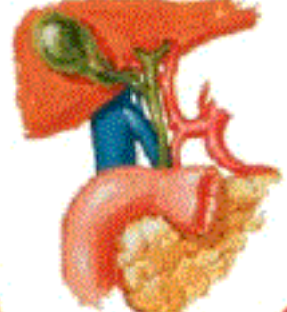
Inferior mesenteric vein may enter superior mesenteric vein

Anomalies of Portal Vein

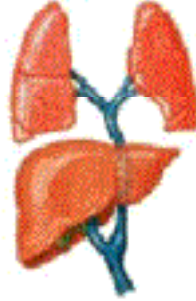
Portal vein anterior to head of pancreas and 1st part of duodenum



Portal vein may enter inferior vena cava (hepatic arteries enlarged)



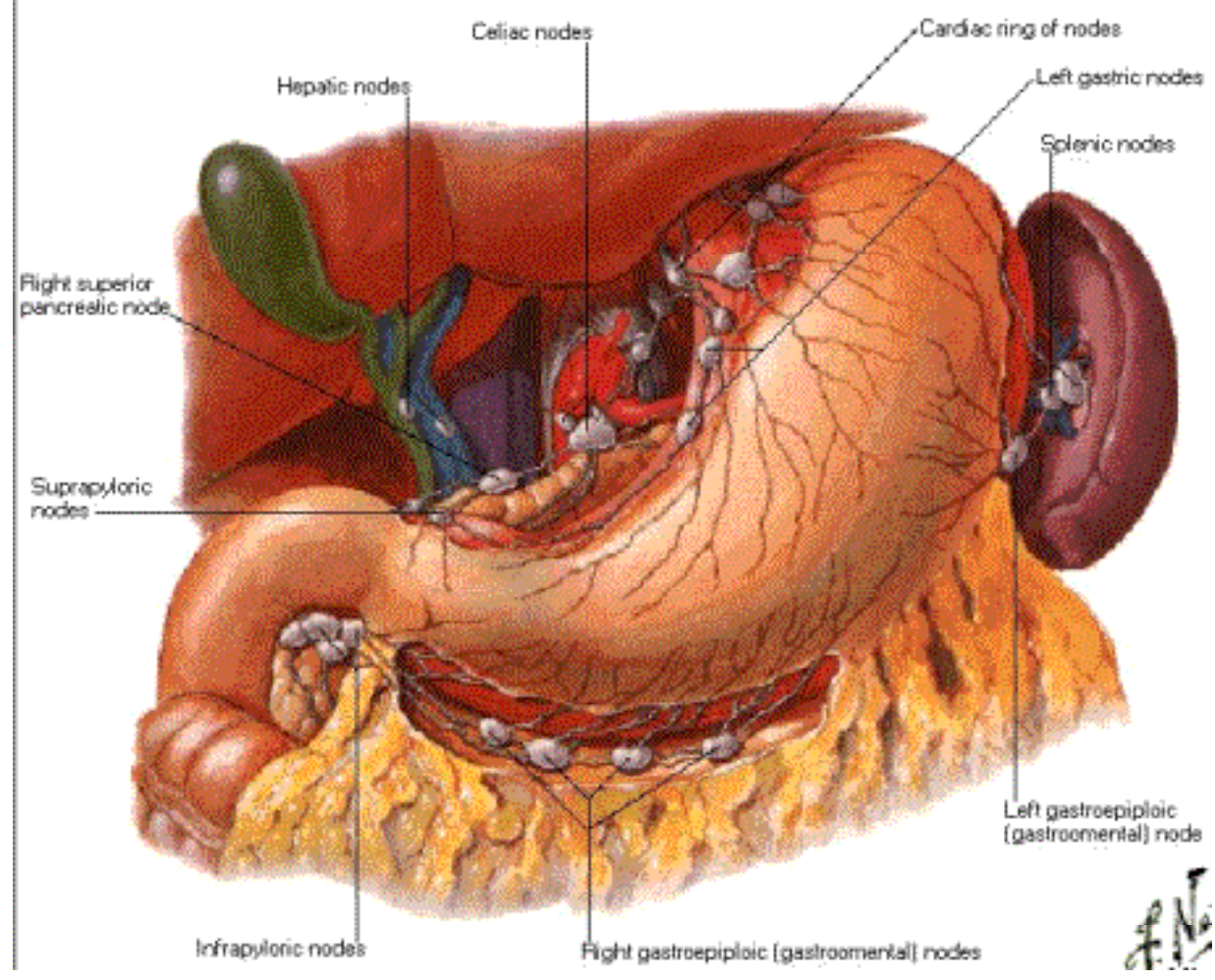
Pulmonary vein may enter portal vein



Congenital stricture of portal vein

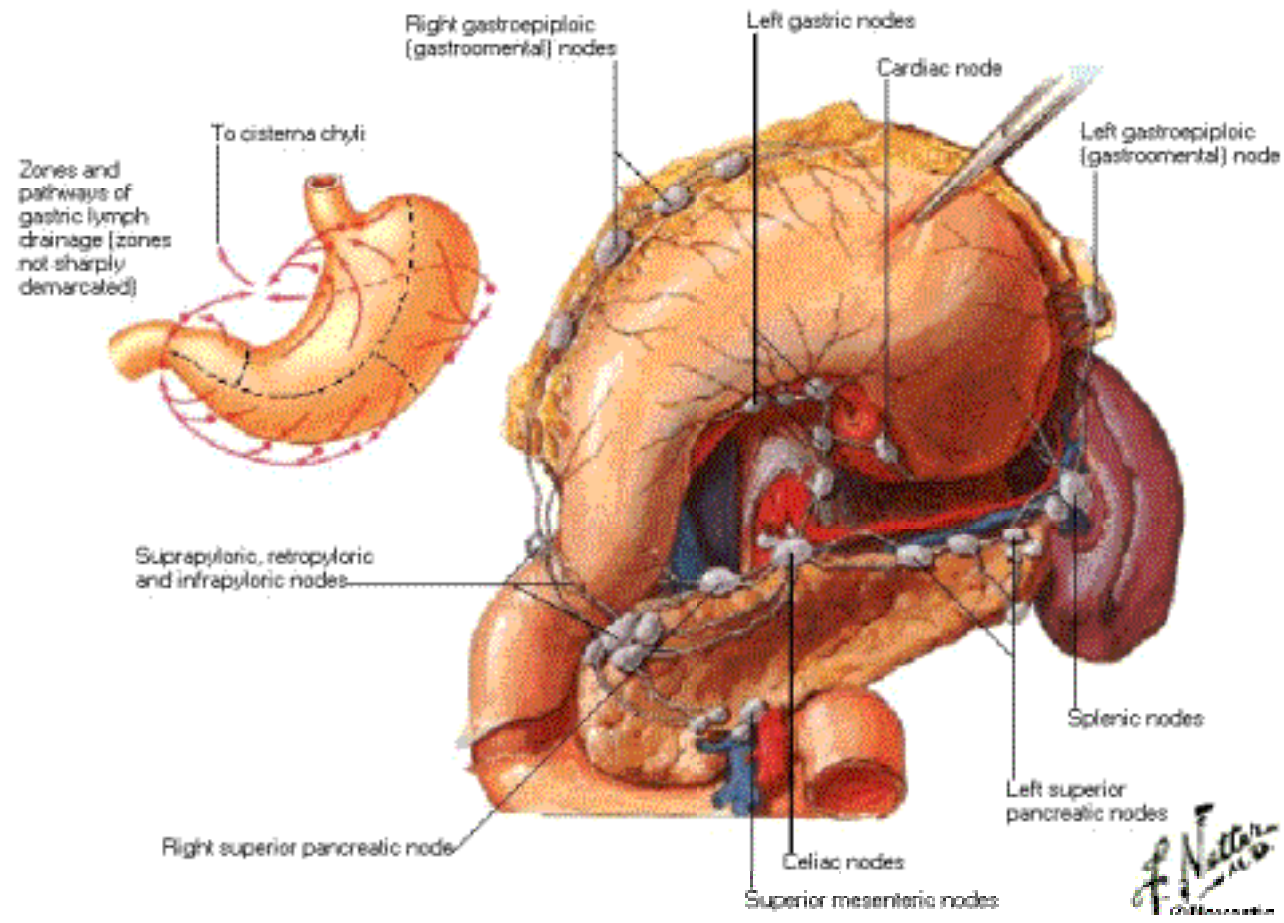


Lymph Vessels and Nodes of Stomach

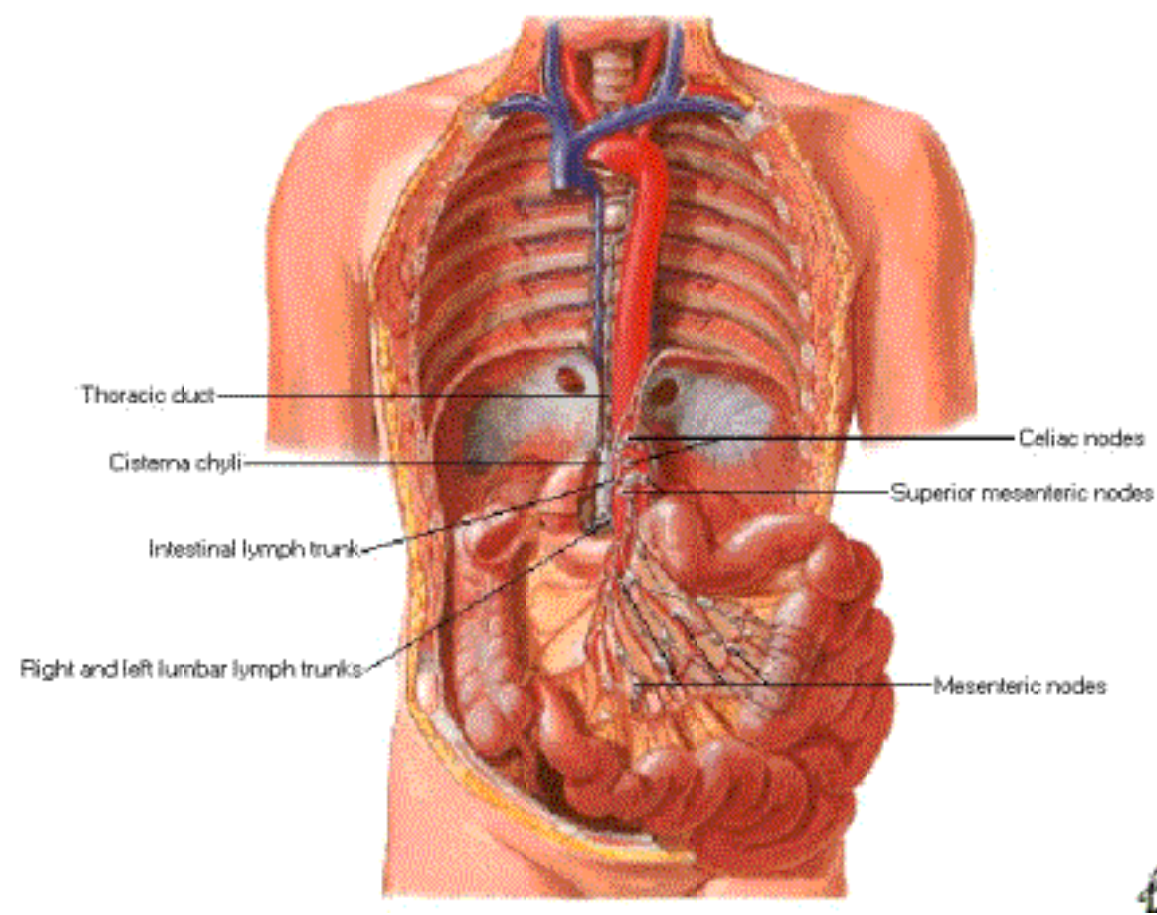


Lymph Vessels and Nodes of Stomach

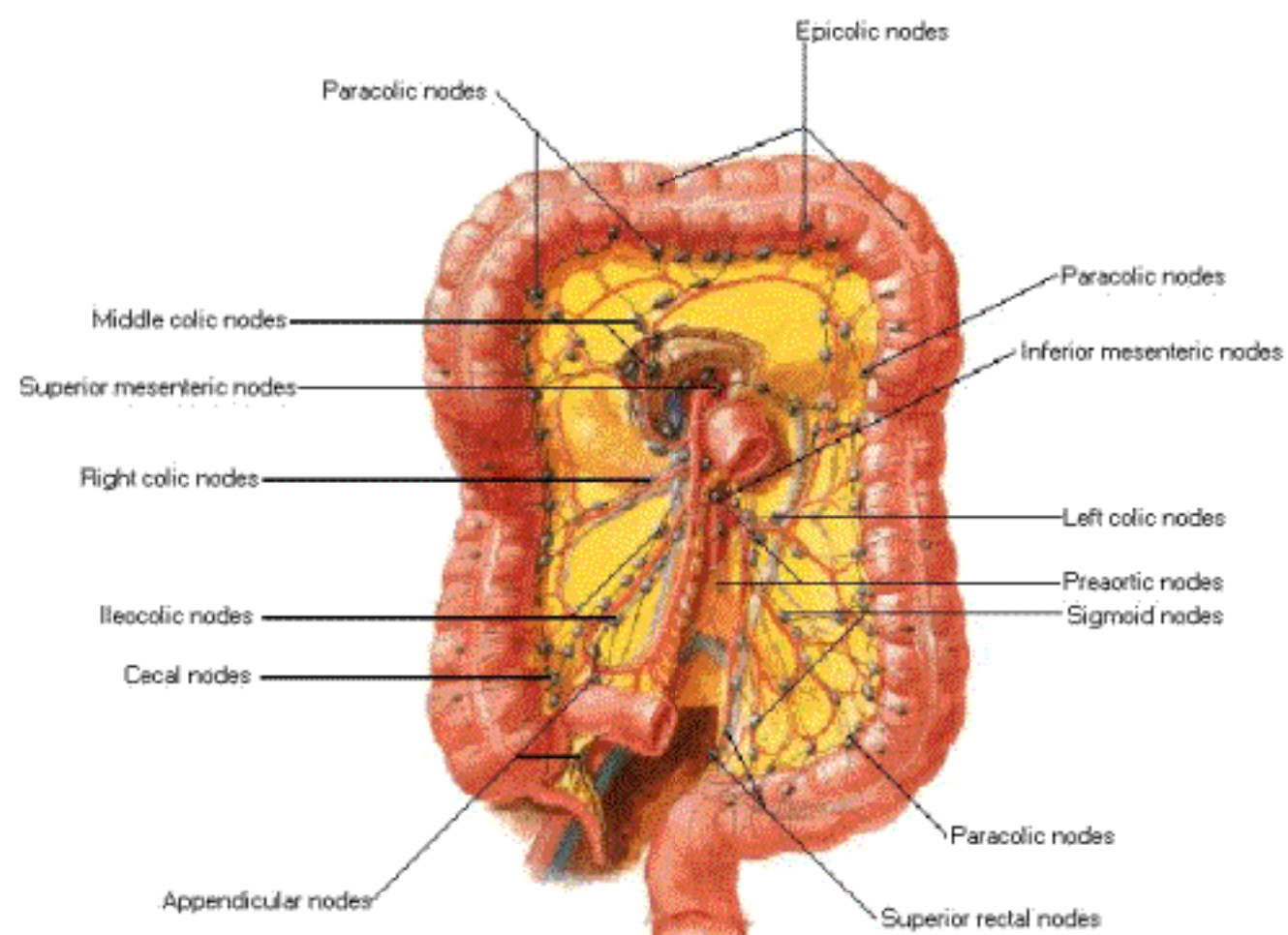
Stomach Reflected



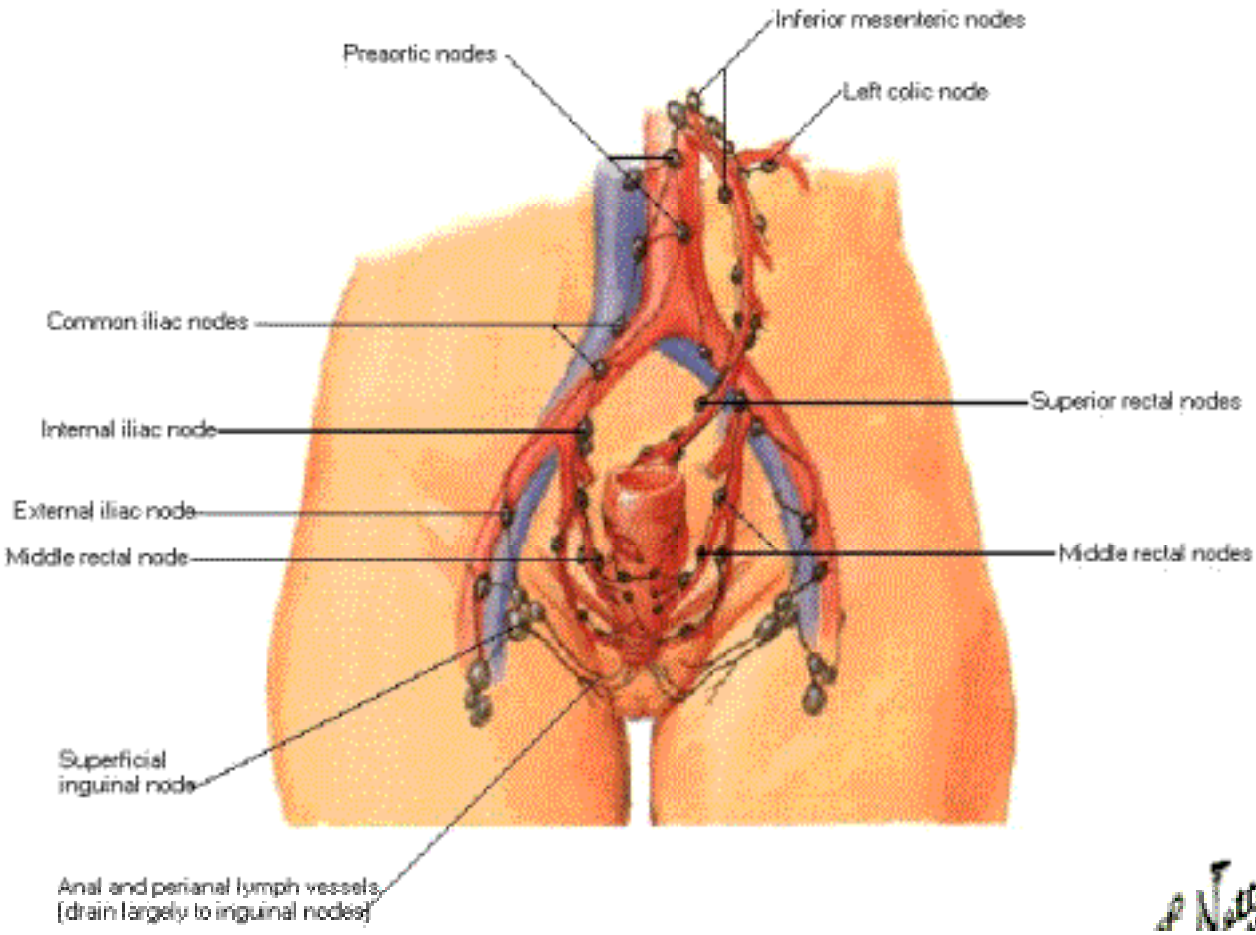
Lymph Vessels and Nodes of Small Intestine



Lymph Vessels and Nodes of Large Intestine



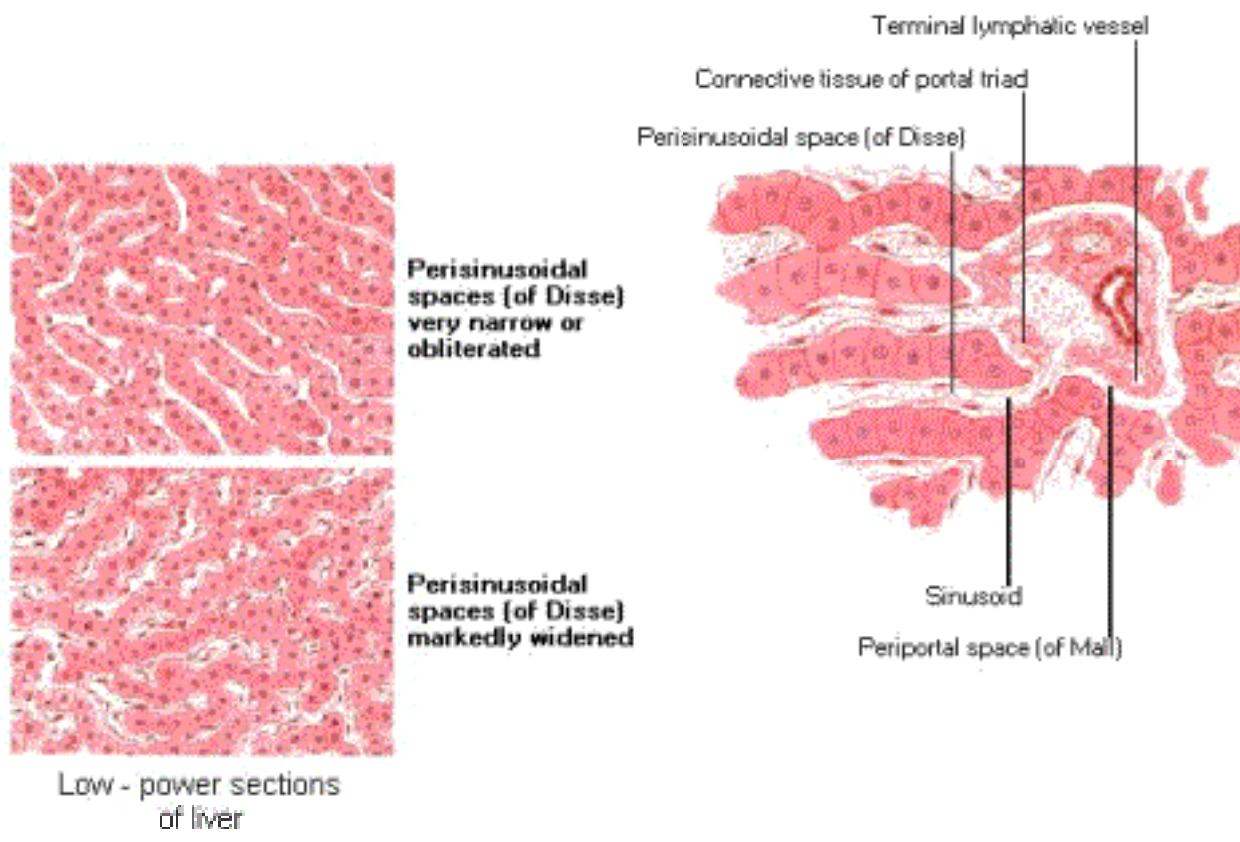
Lymph Vessels and Nodes of Large Intestine [Continued]



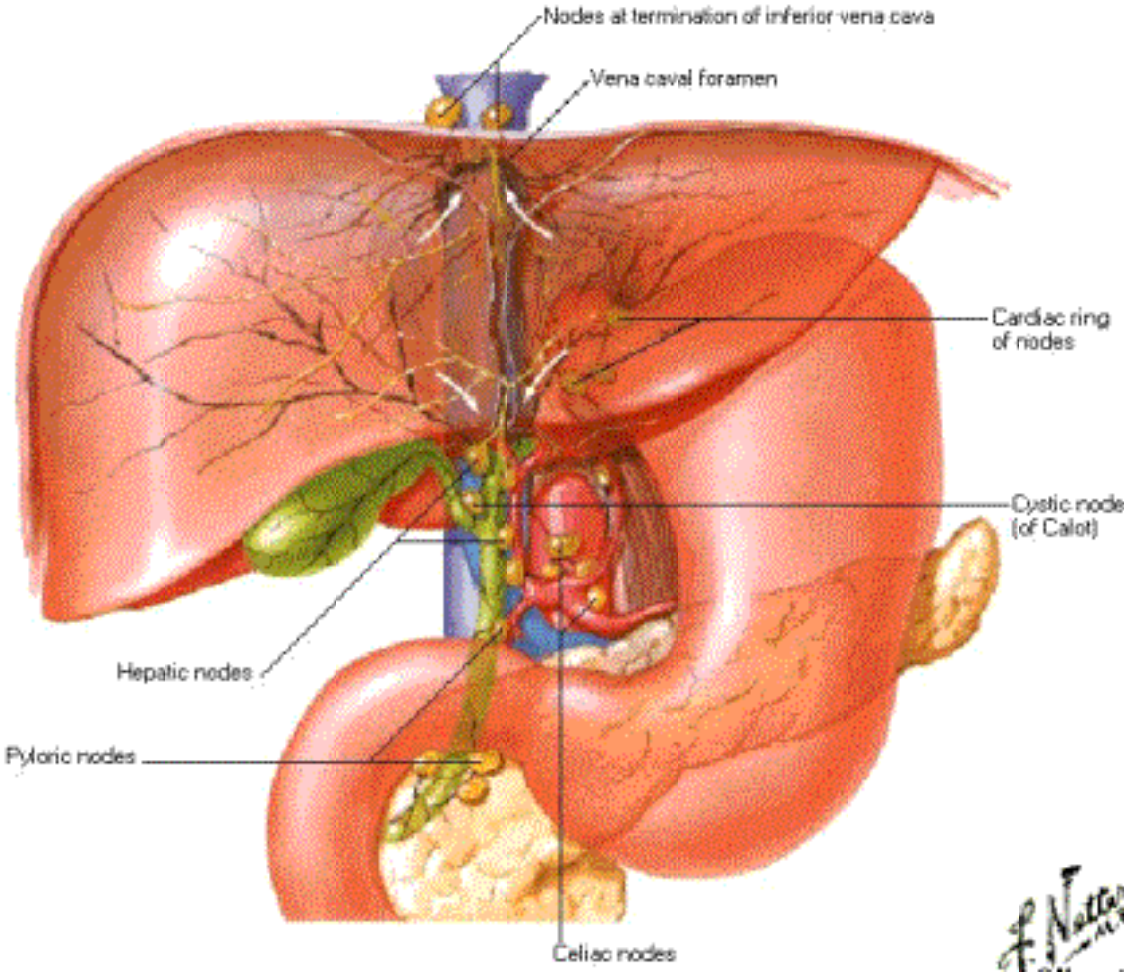
of Naga

Lymph Vessels and Nodes of Liver

Histology

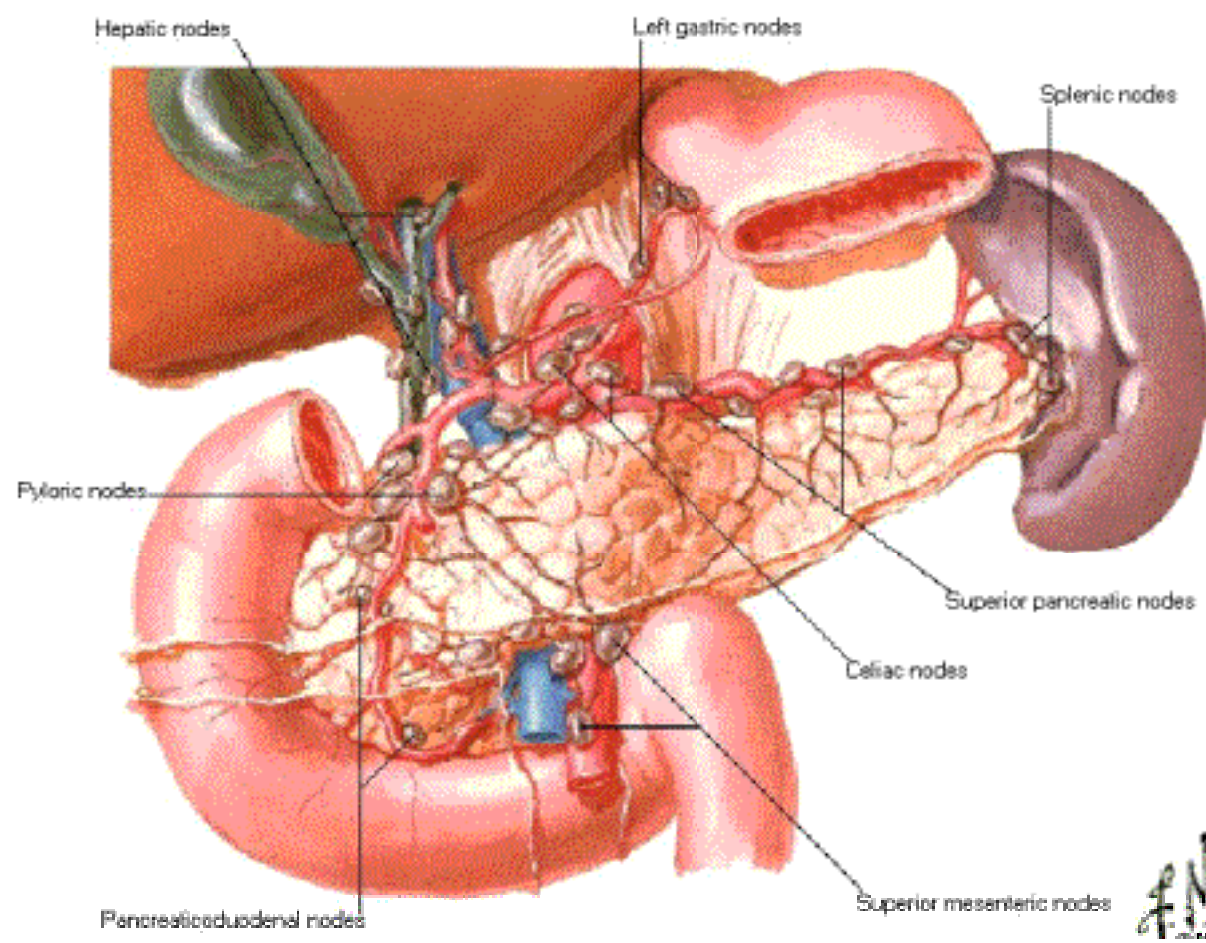


Lymph Vessels and Nodes of Liver



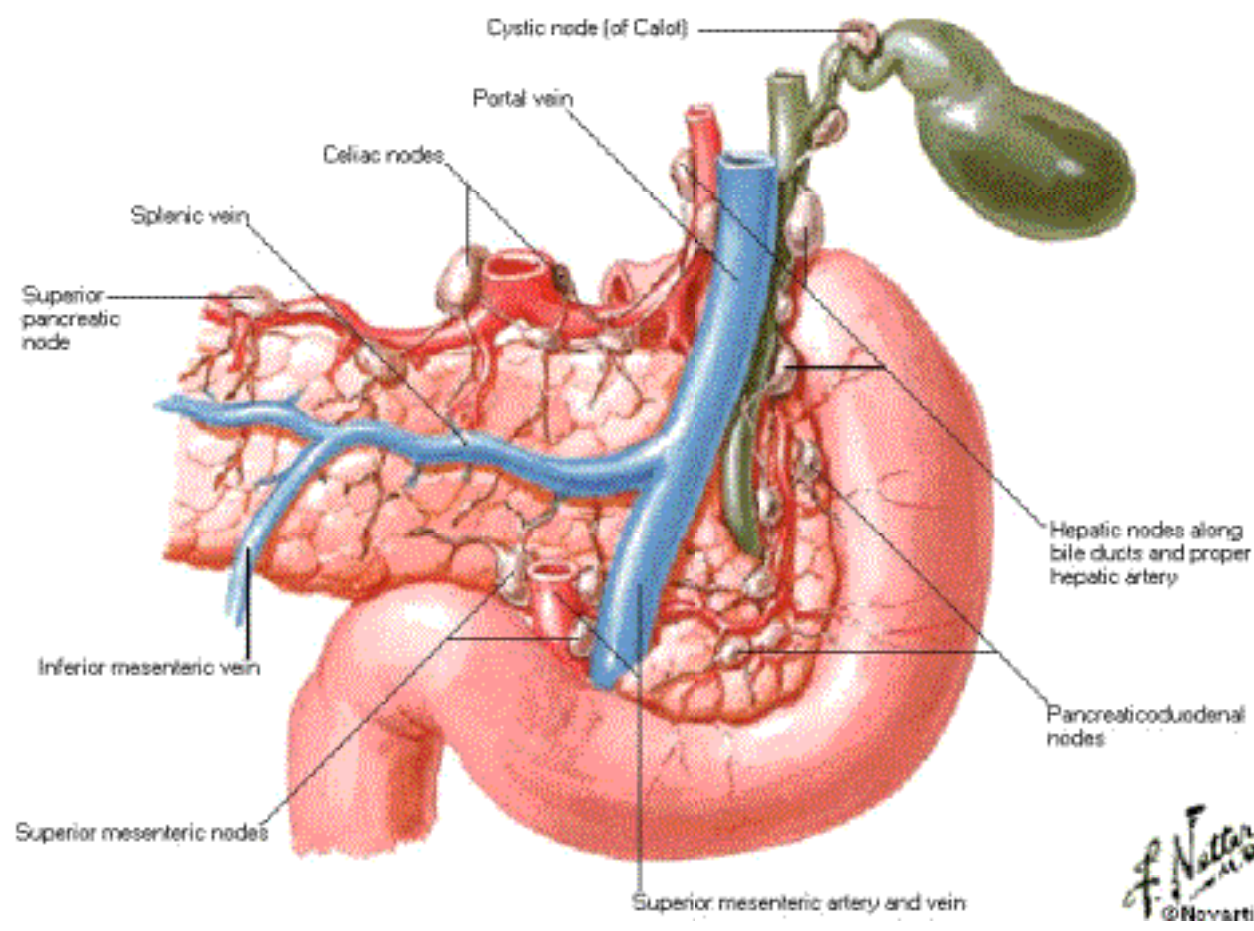
Lymph Vessels and Nodes of Pancreas

Anterior View

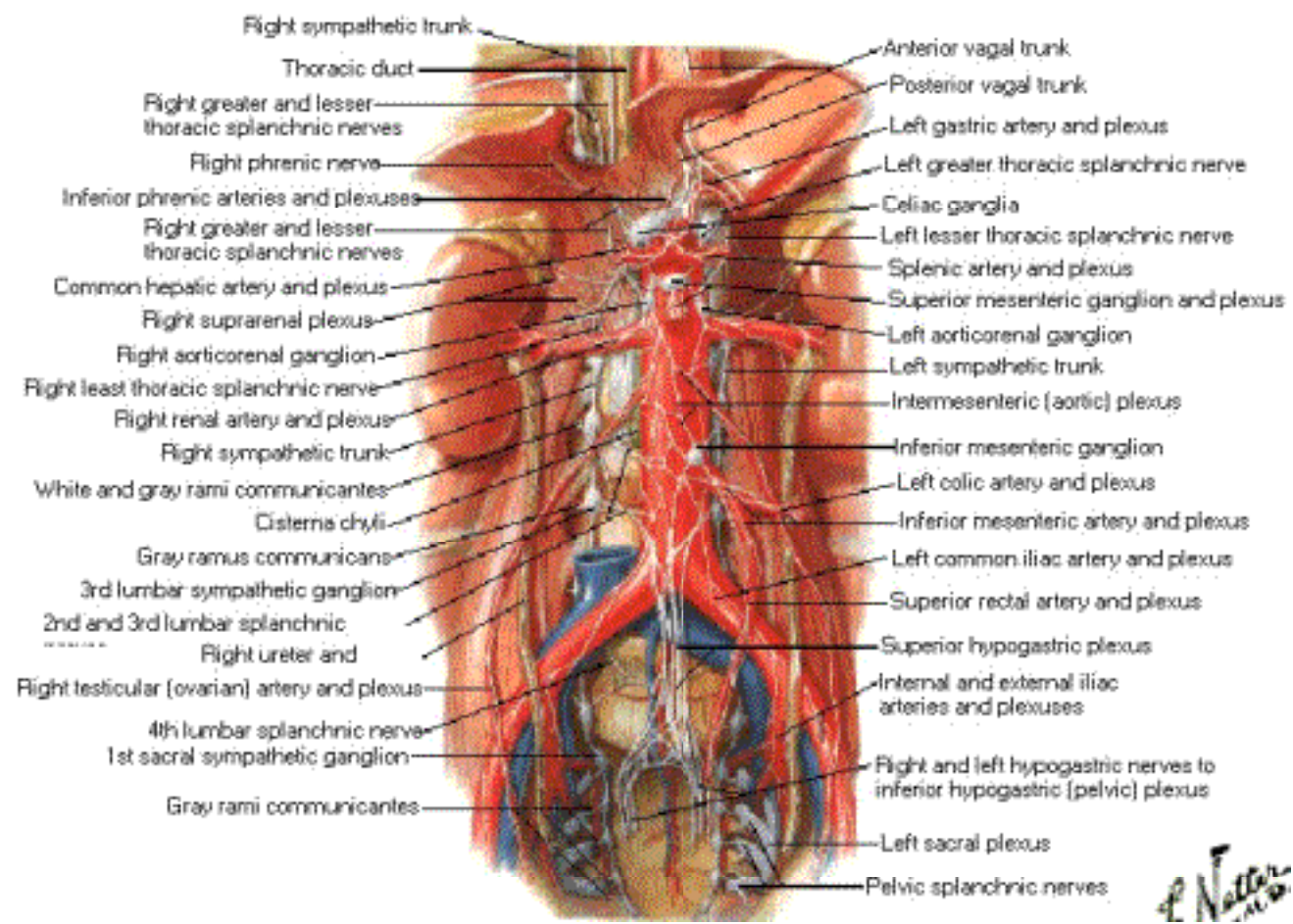


Lymph Vessels and Nodes of Pancreas

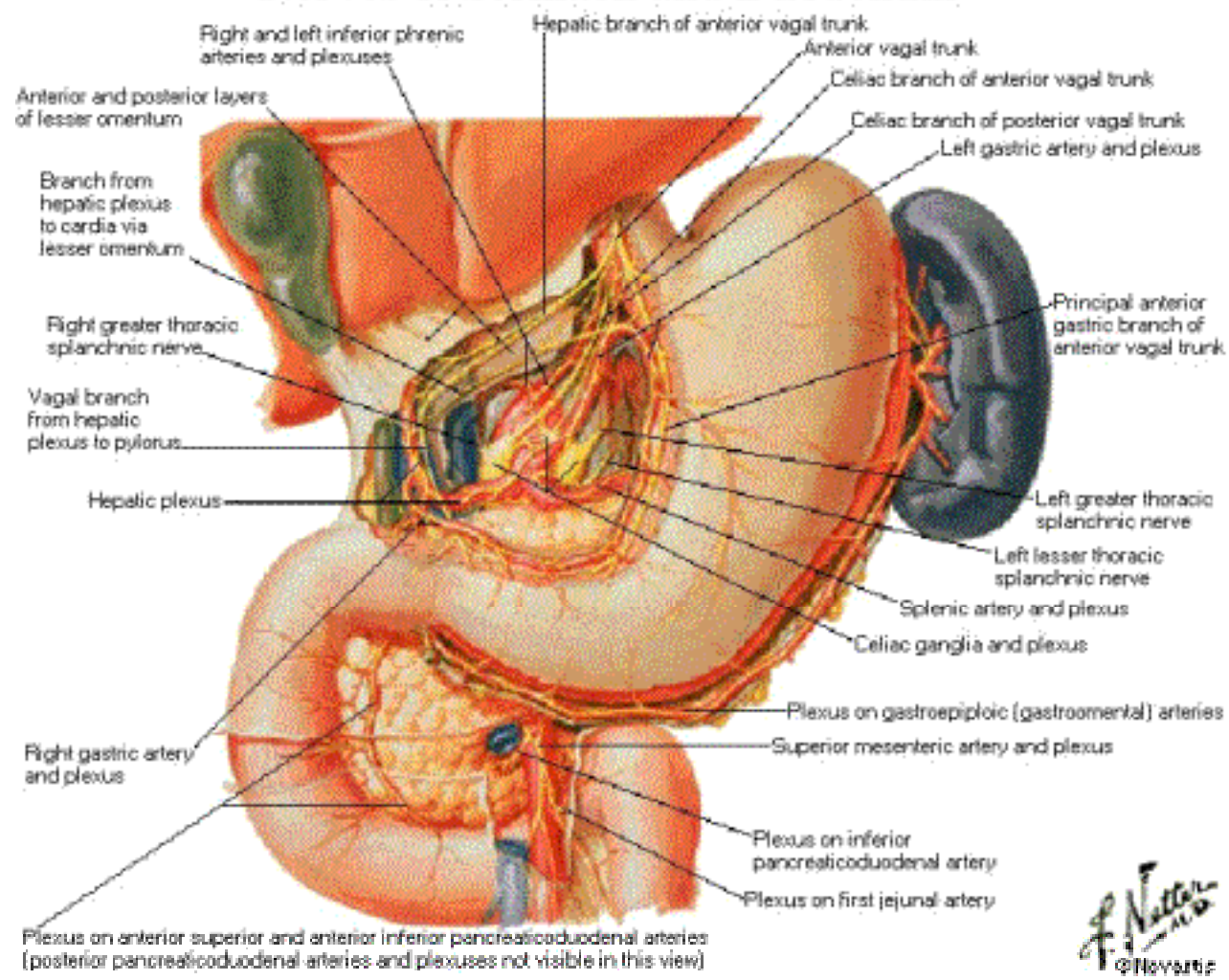
Posterior View



Autonomic Nerves and Ganglia of Abdomen

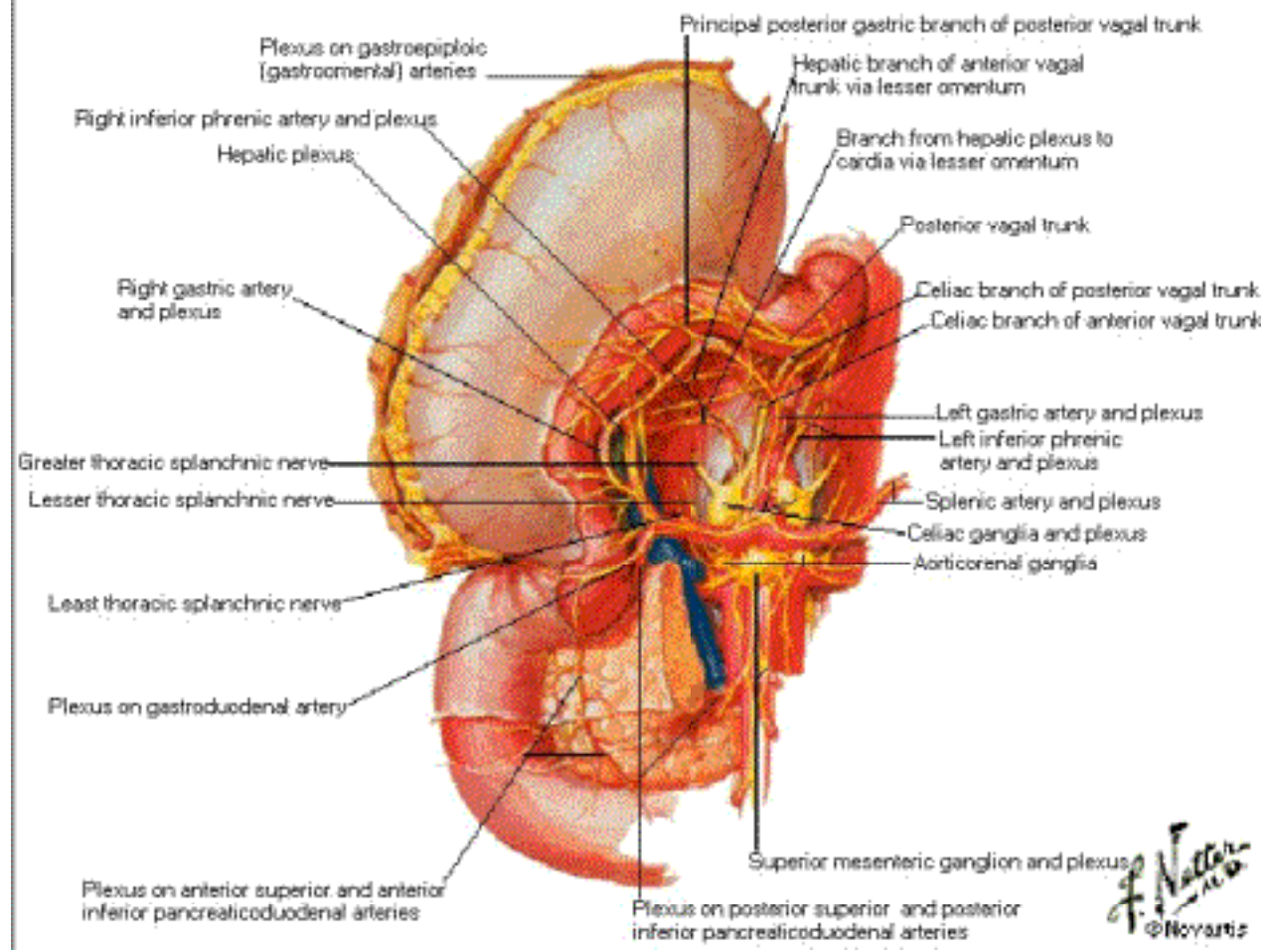


Nerves of Stomach and Duodenum



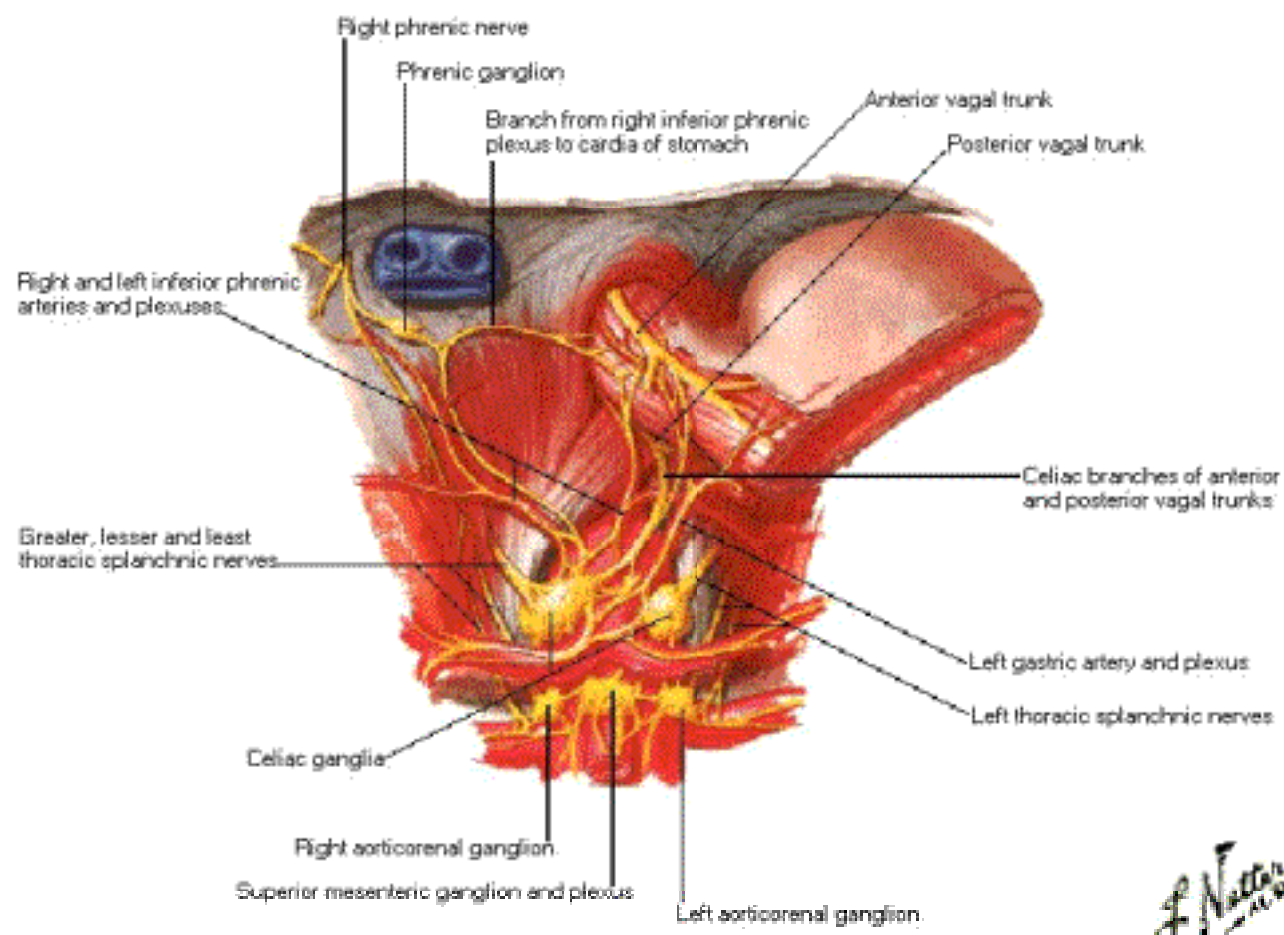
Nerves of Stomach and Duodenum

View with Stomach Reflected



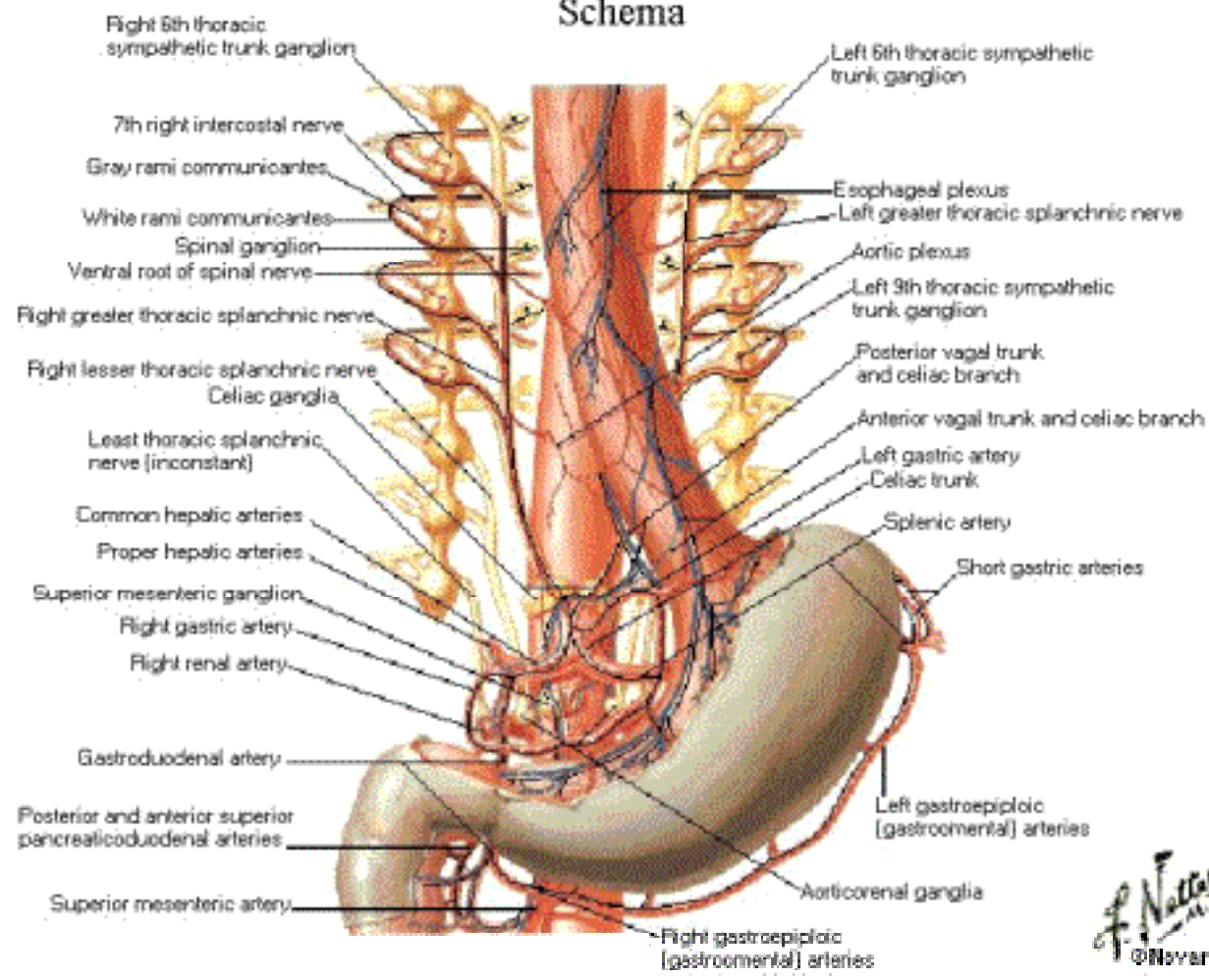
Nerves of Stomach and Duodenum

Hiatal Region



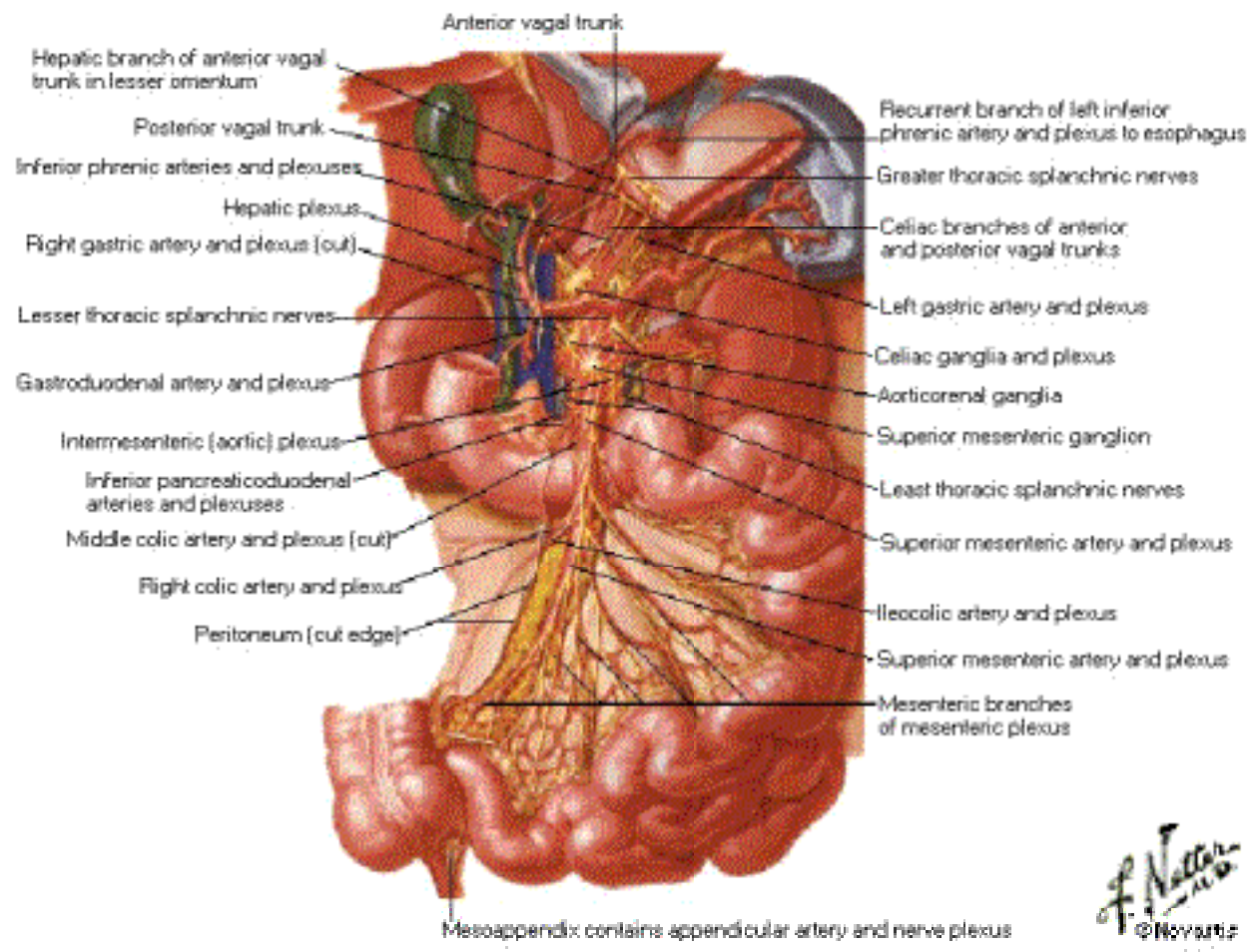
Innervation of Stomach and Duodenum

Schema

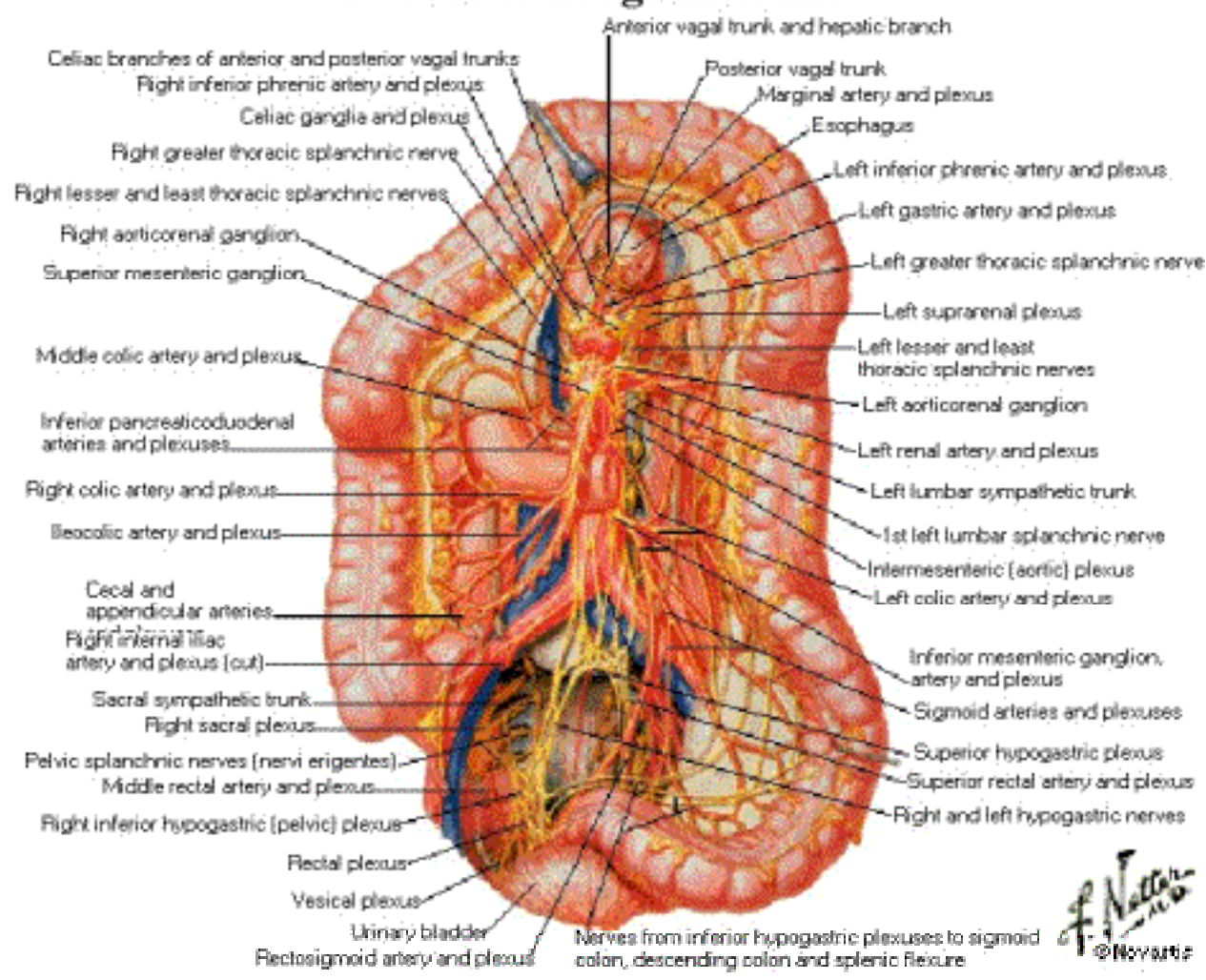


F. Natta
©Novar

Nerves of Small Intestine

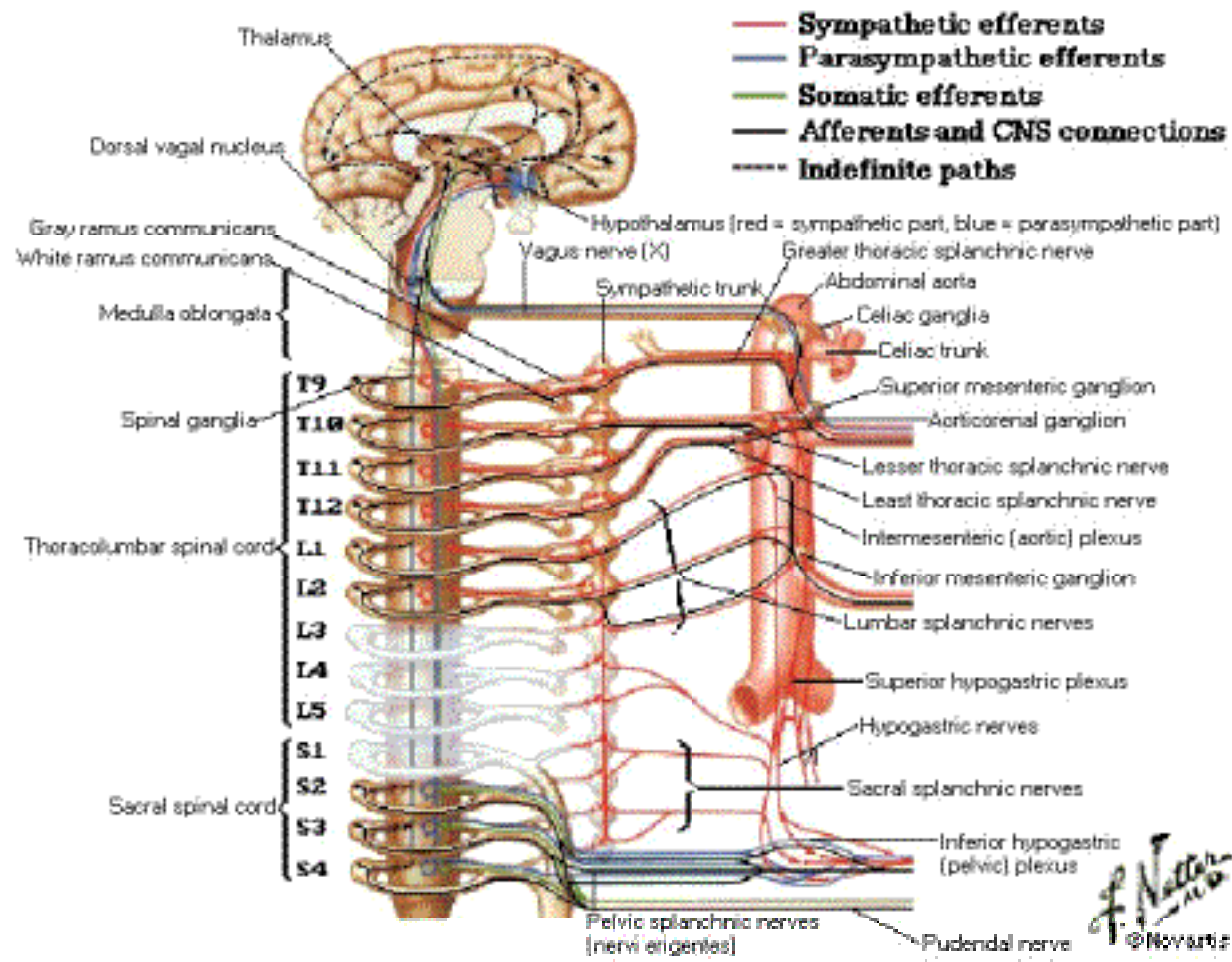


Nerves of Large Intestine



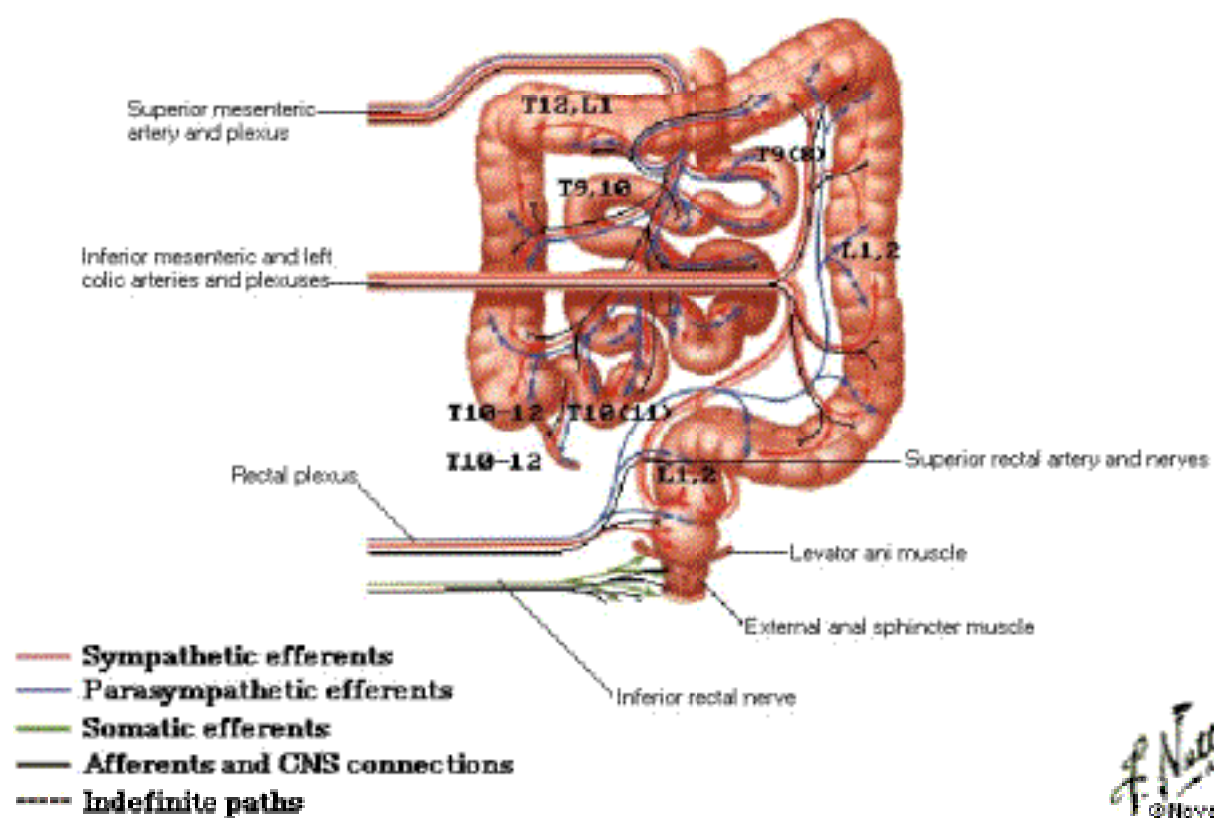
Innervation of Small and Large Intestines

Left Side of Schema



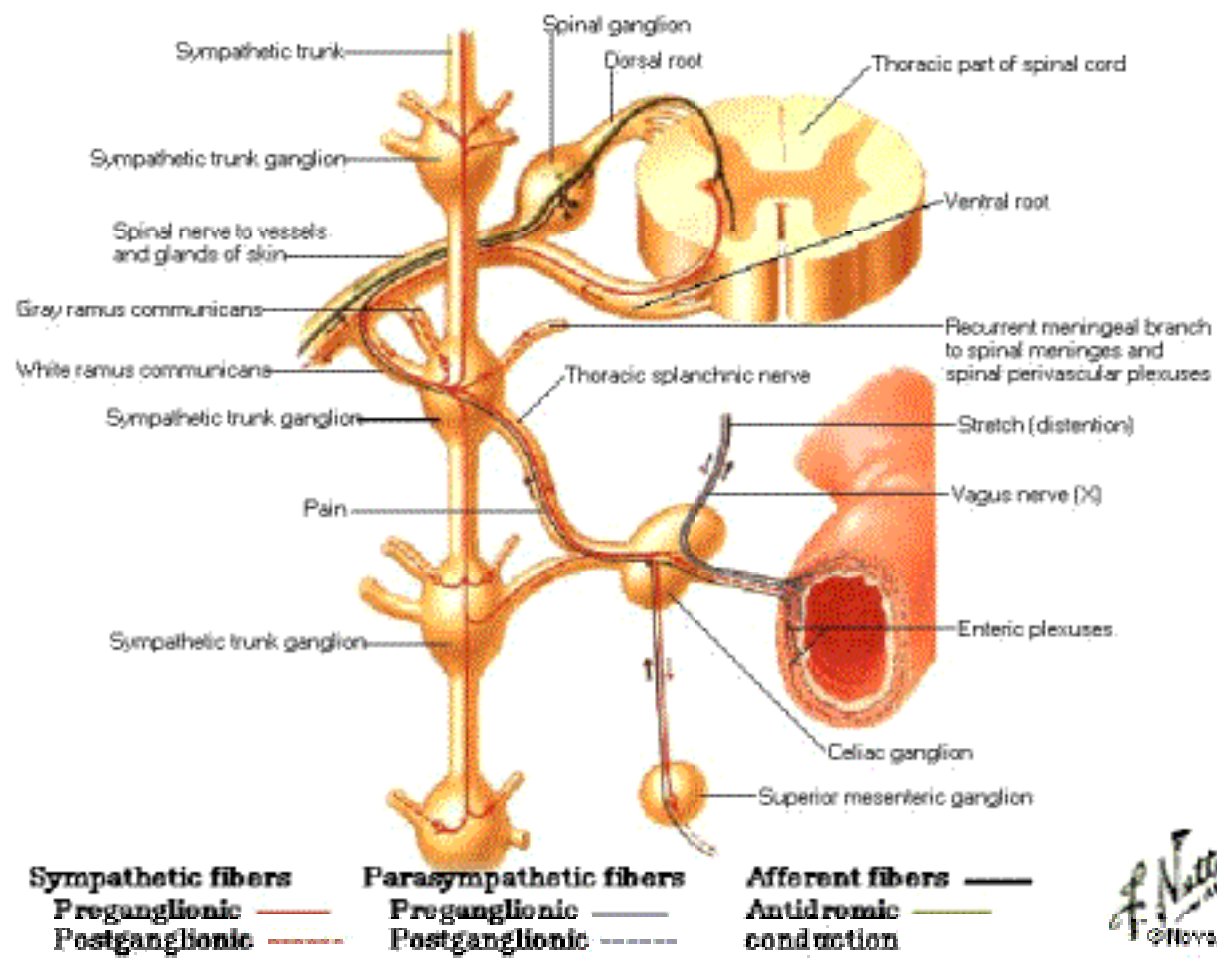
Innervation of Small and Large Intestines

Right Side of Schema

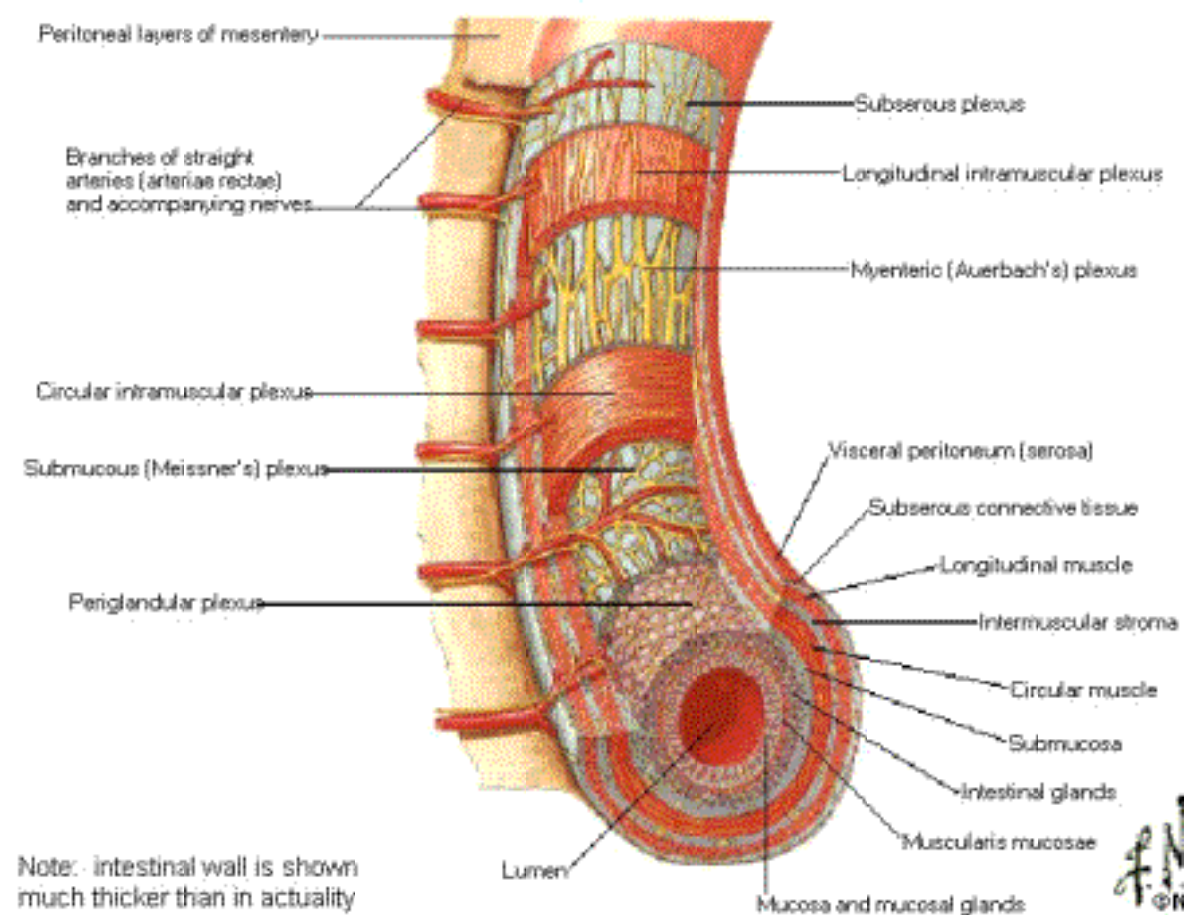


Autonomic Reflex Pathways

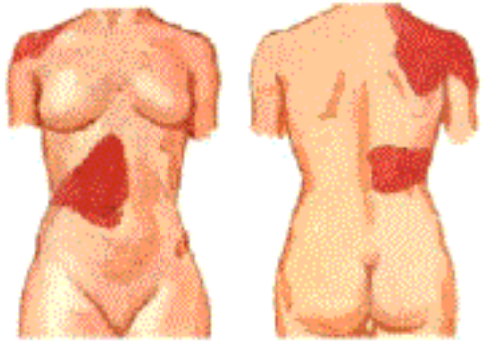
Schema



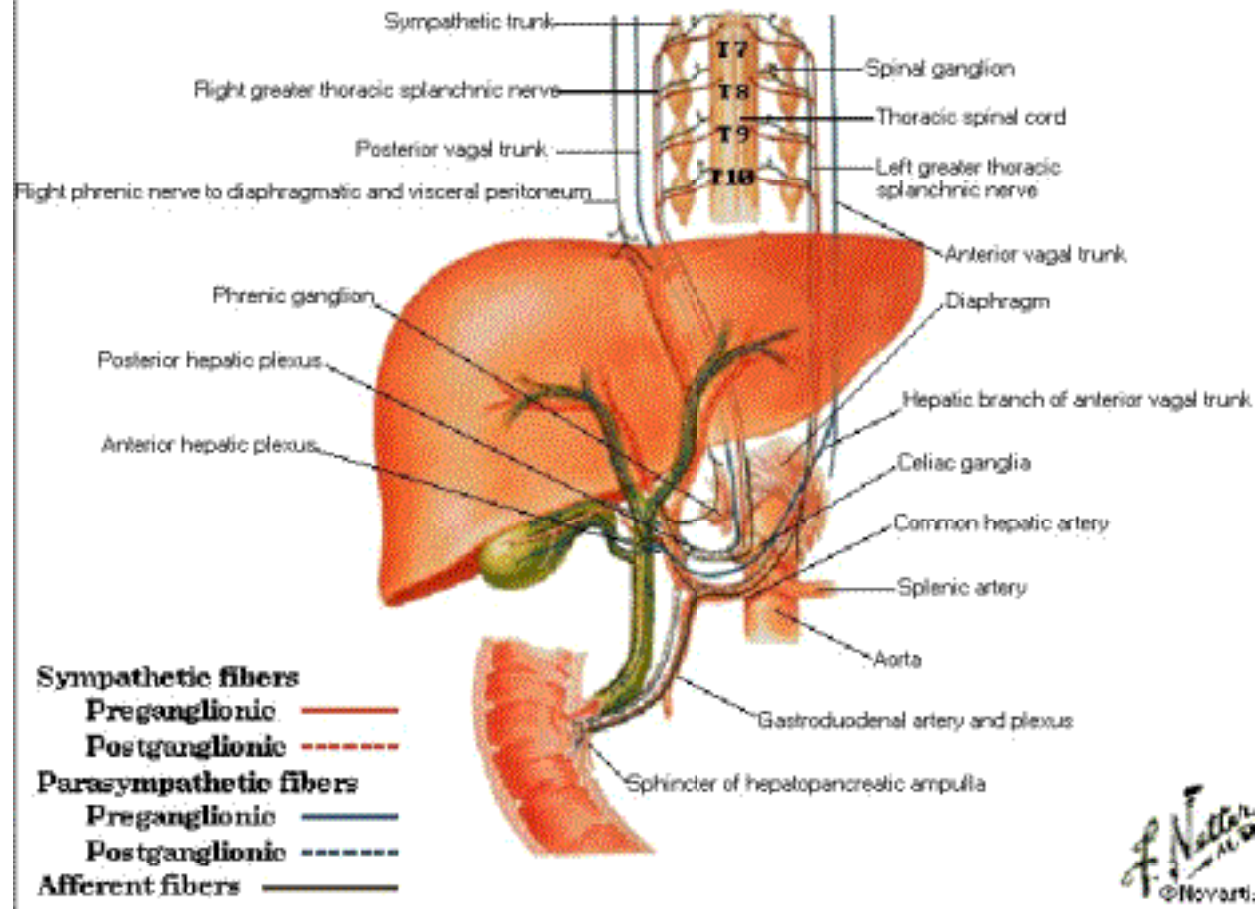
Intrinsic Autonomic Plexuses of Intestine Schema



Common Areas of Referred Pain in Biliary Disease



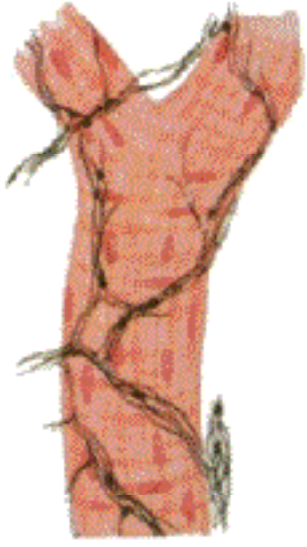
Innervation of Liver and Biliary Tract Schema



F. Netter
 © Novartis

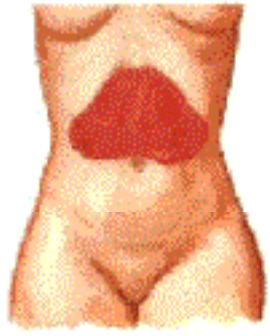Innervation of Liver

Nerve Fibers around Fine Branch of Hepatic Artery



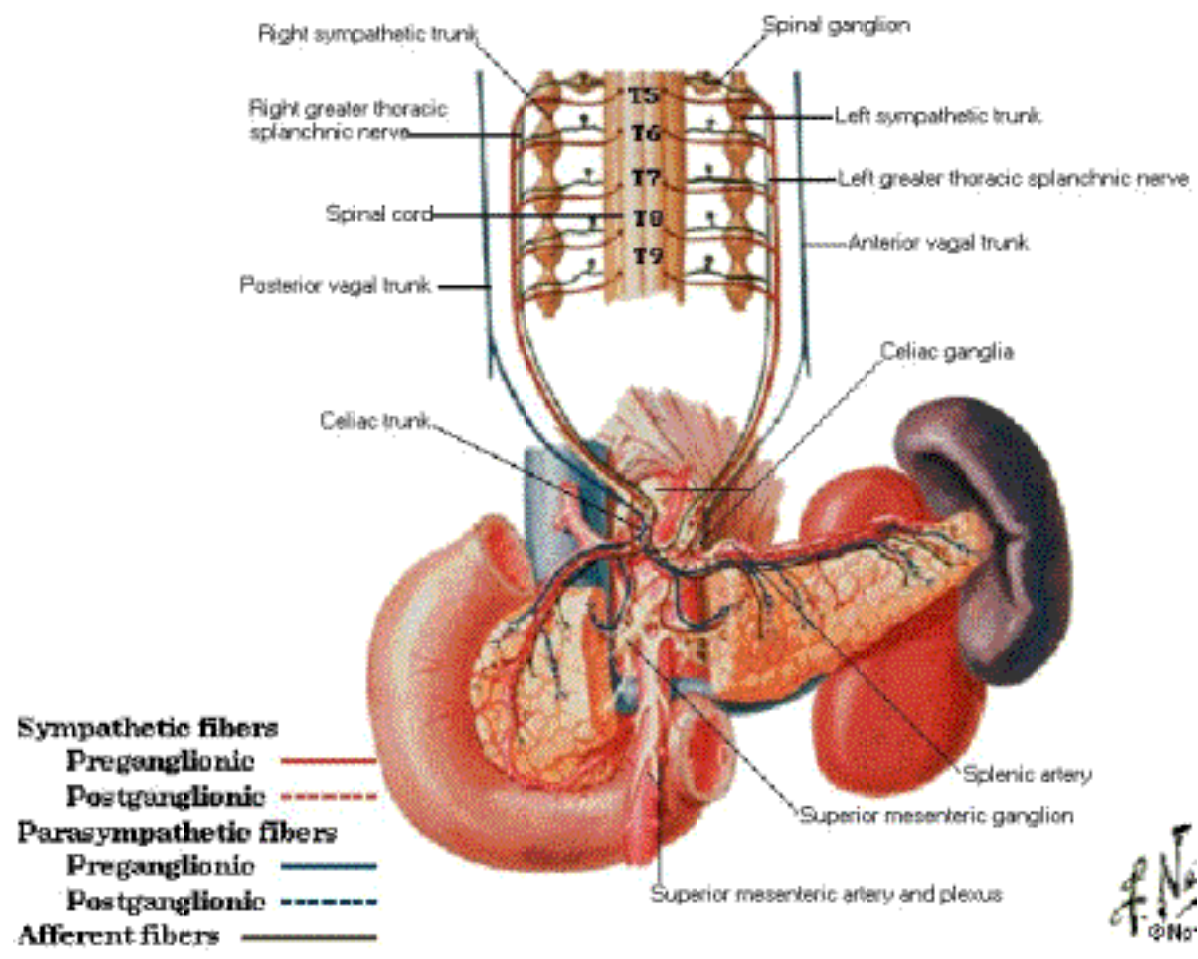
i@

Common Areas of Pancreatic Pain



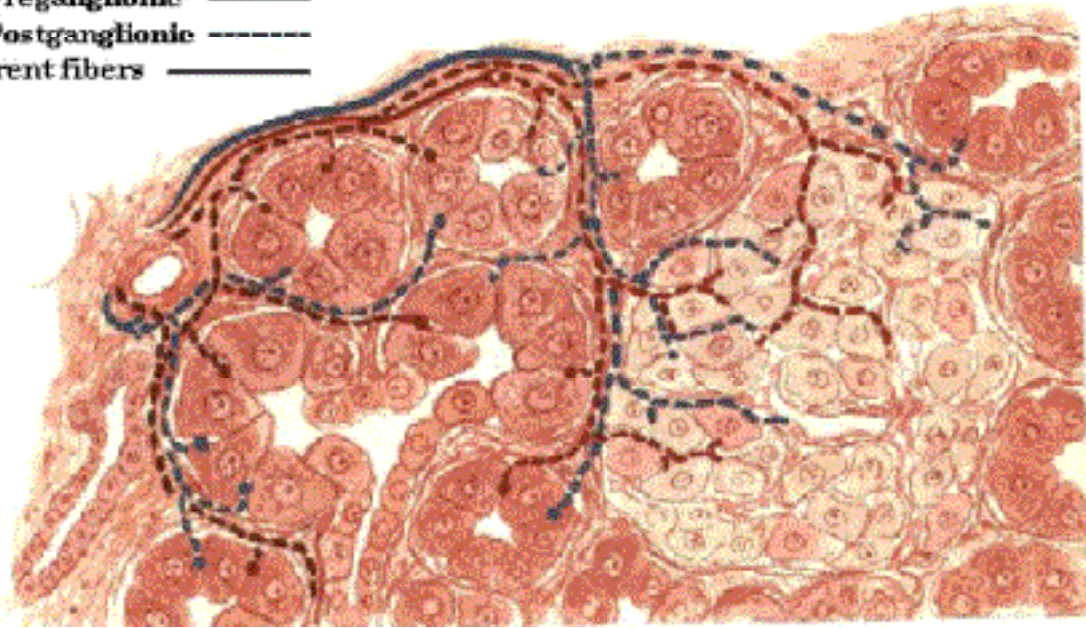
Innervation of Pancreas

Schema

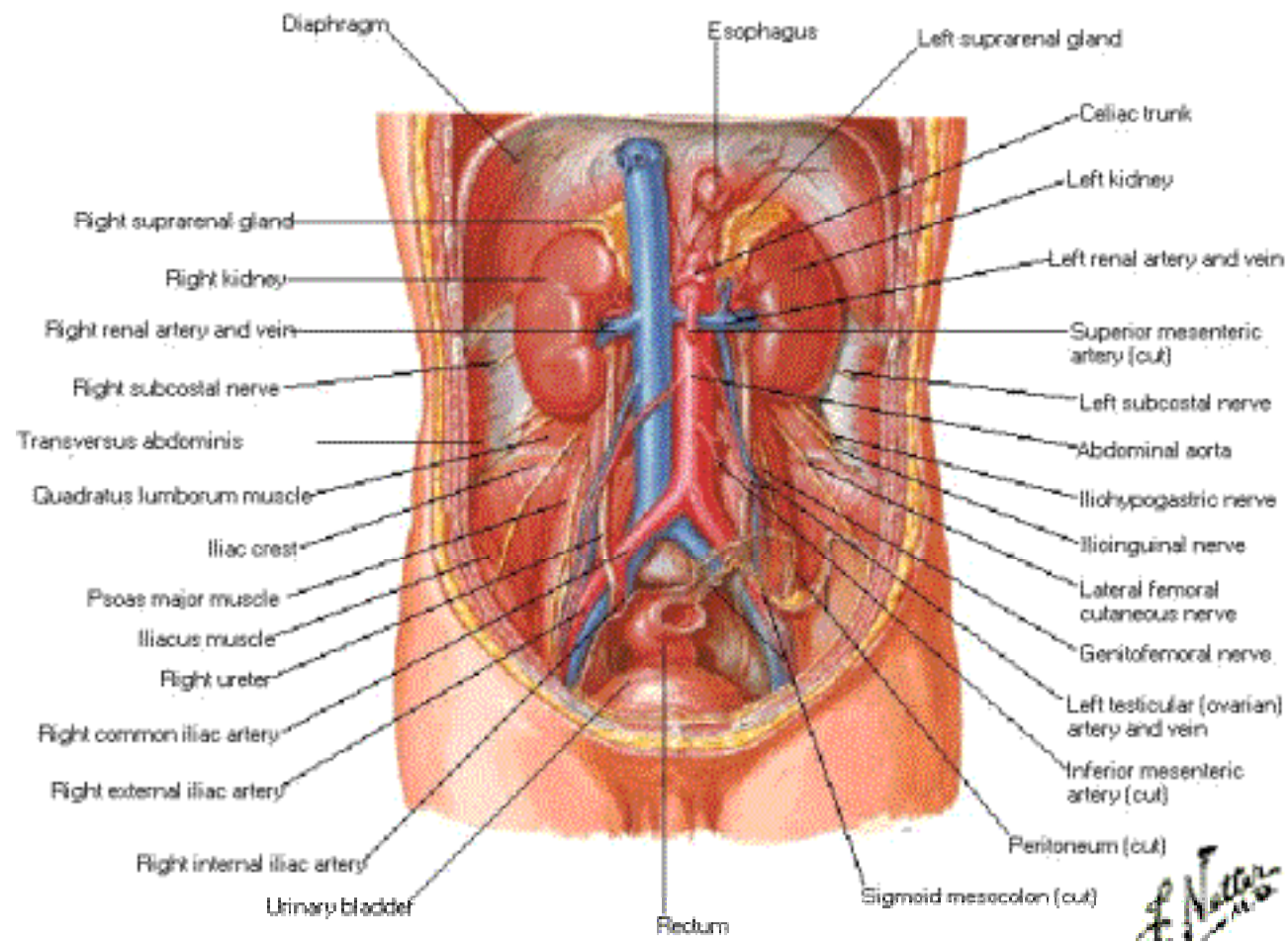


Schema of Intrinsic Nerve Supply of Pancreas

- Sympathetic fibers
 - Preganglionic ———
 - Postganglionic - - - - -
- Parasympathetic fibers
 - Preganglionic ———
 - Postganglionic - - - - -
- Afferent fibers ———

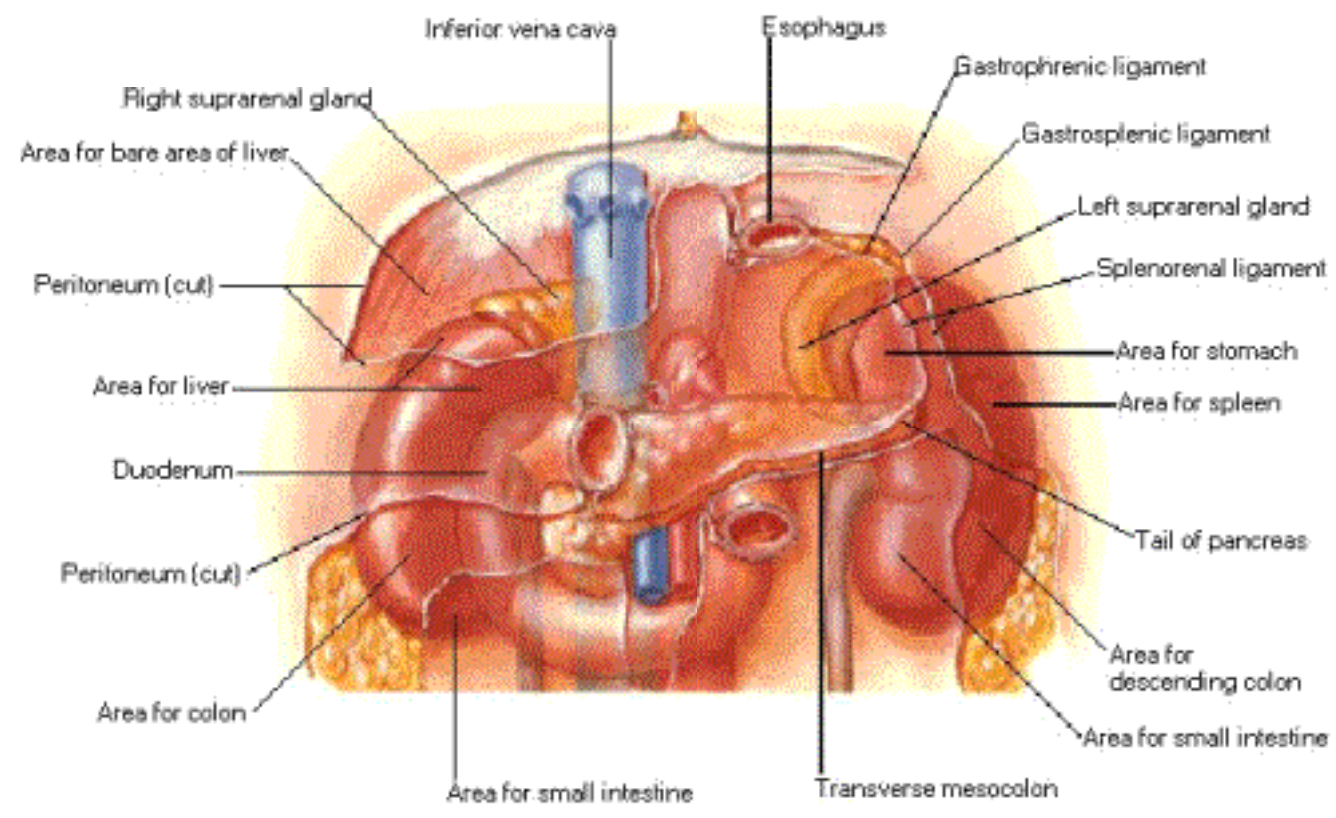


Kidneys in Situ Anterior View



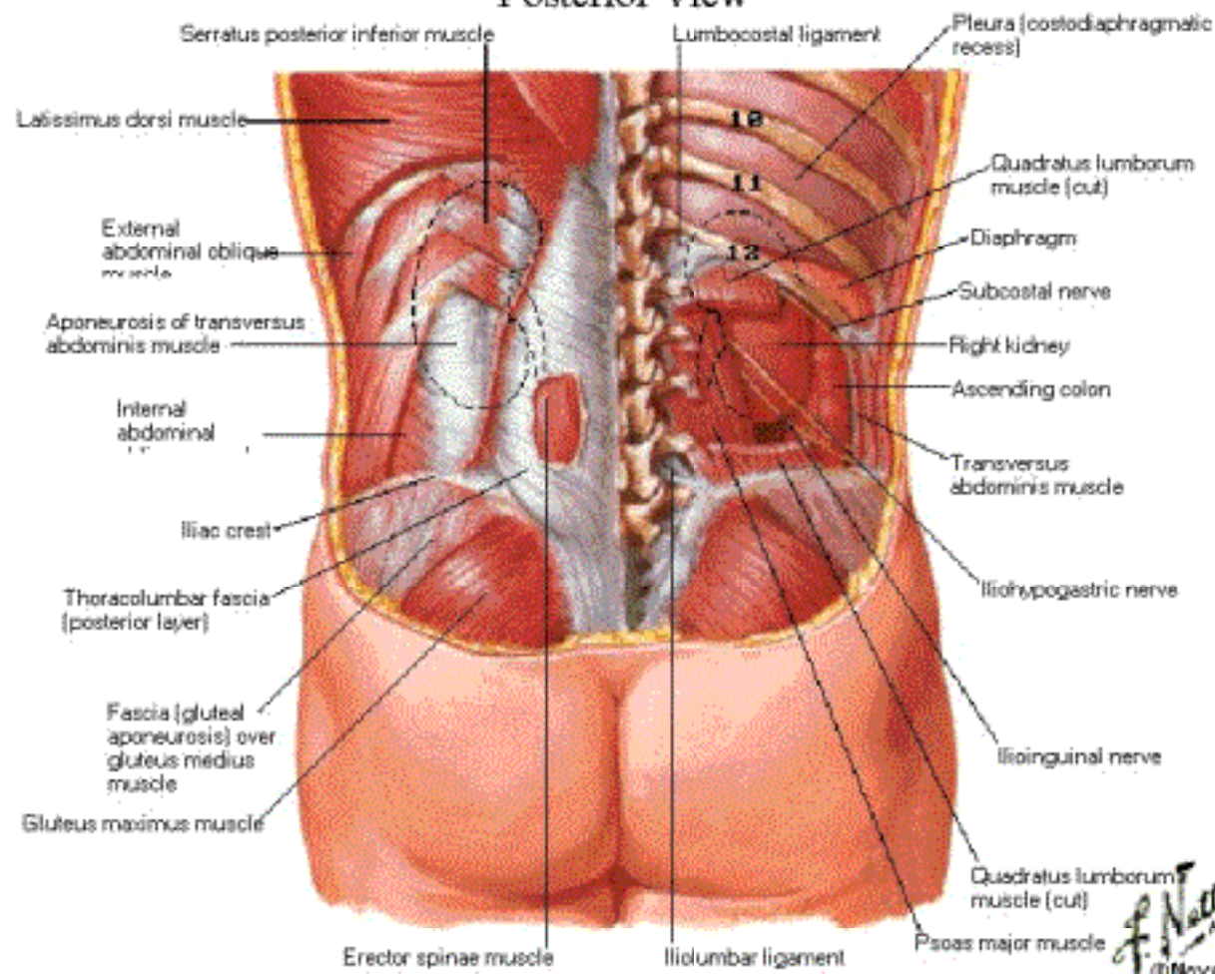
Kidneys in Situ

Anterior Relations of Kidneys



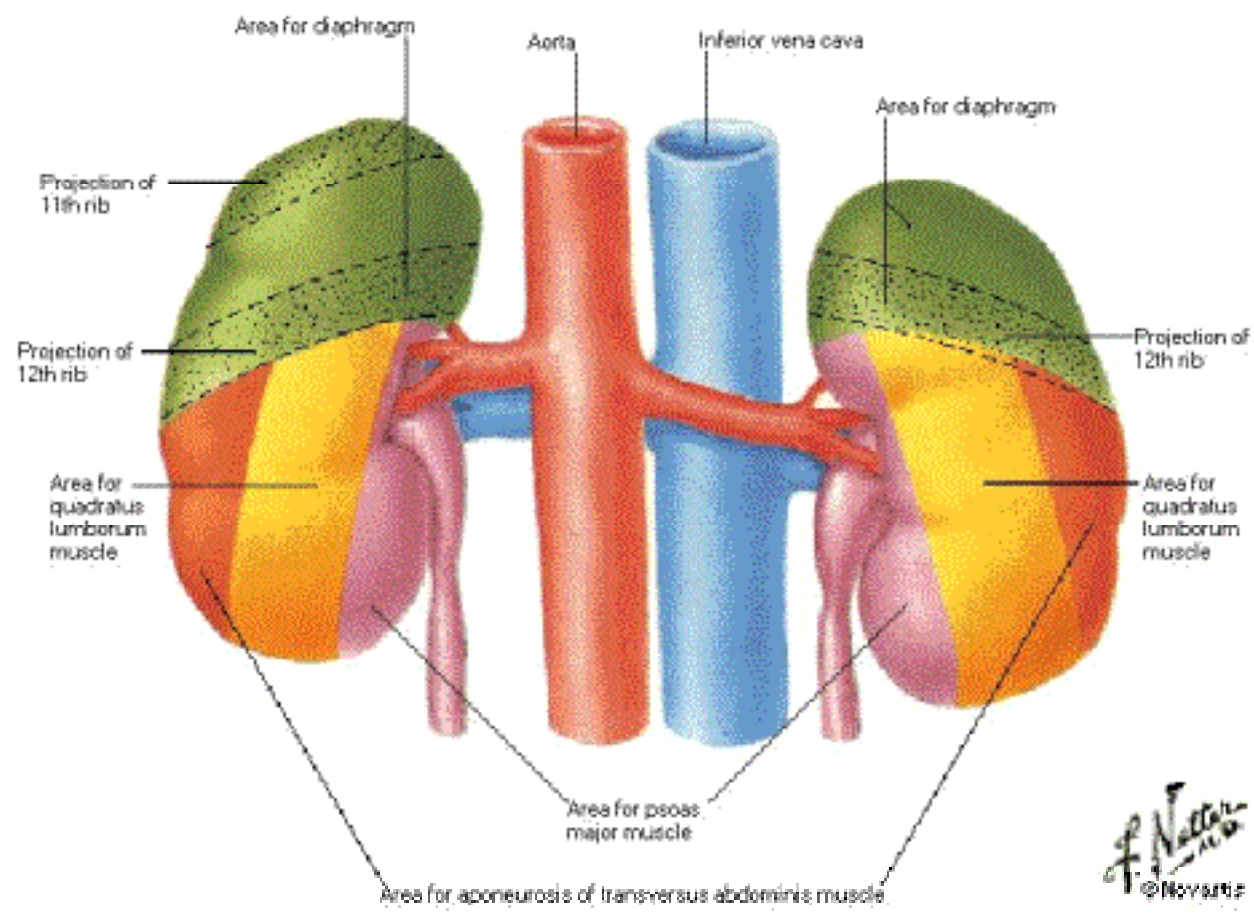
Kidneys in Situ

Posterior View

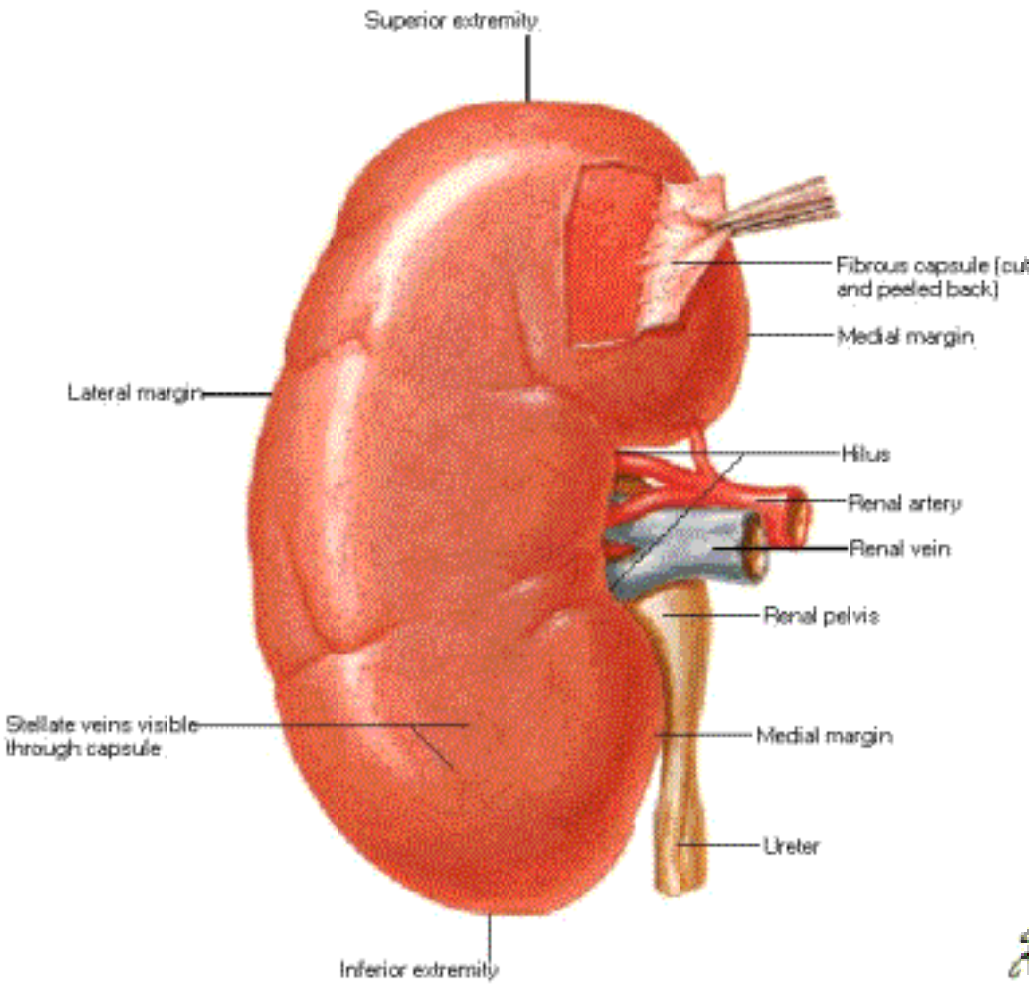


Kidneys in Situ

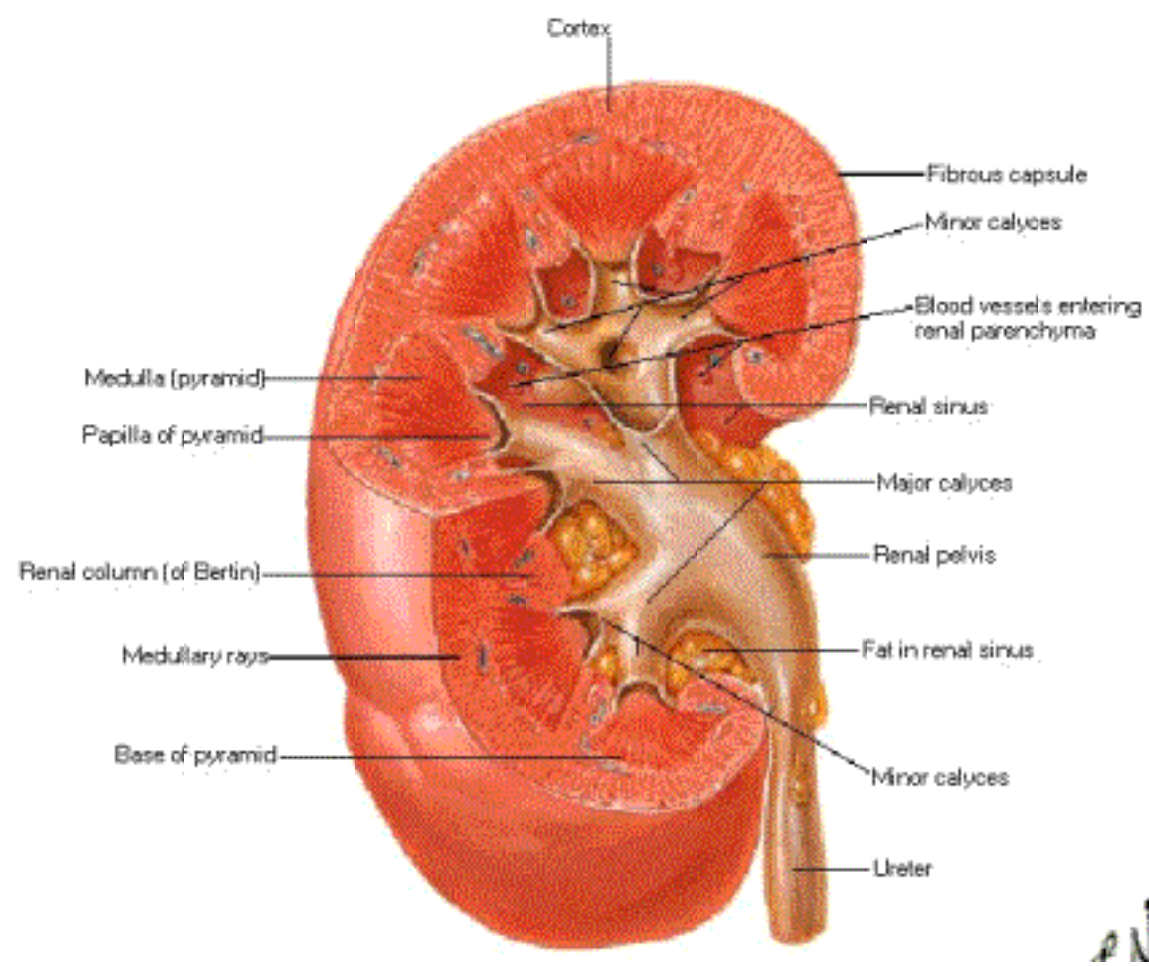
Posterior Relations of Kidneys



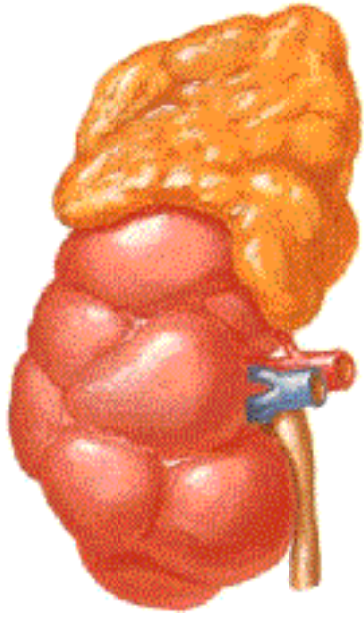Anterior Surface of Right Kidney



Right Kidney Sectioned in Several Planes

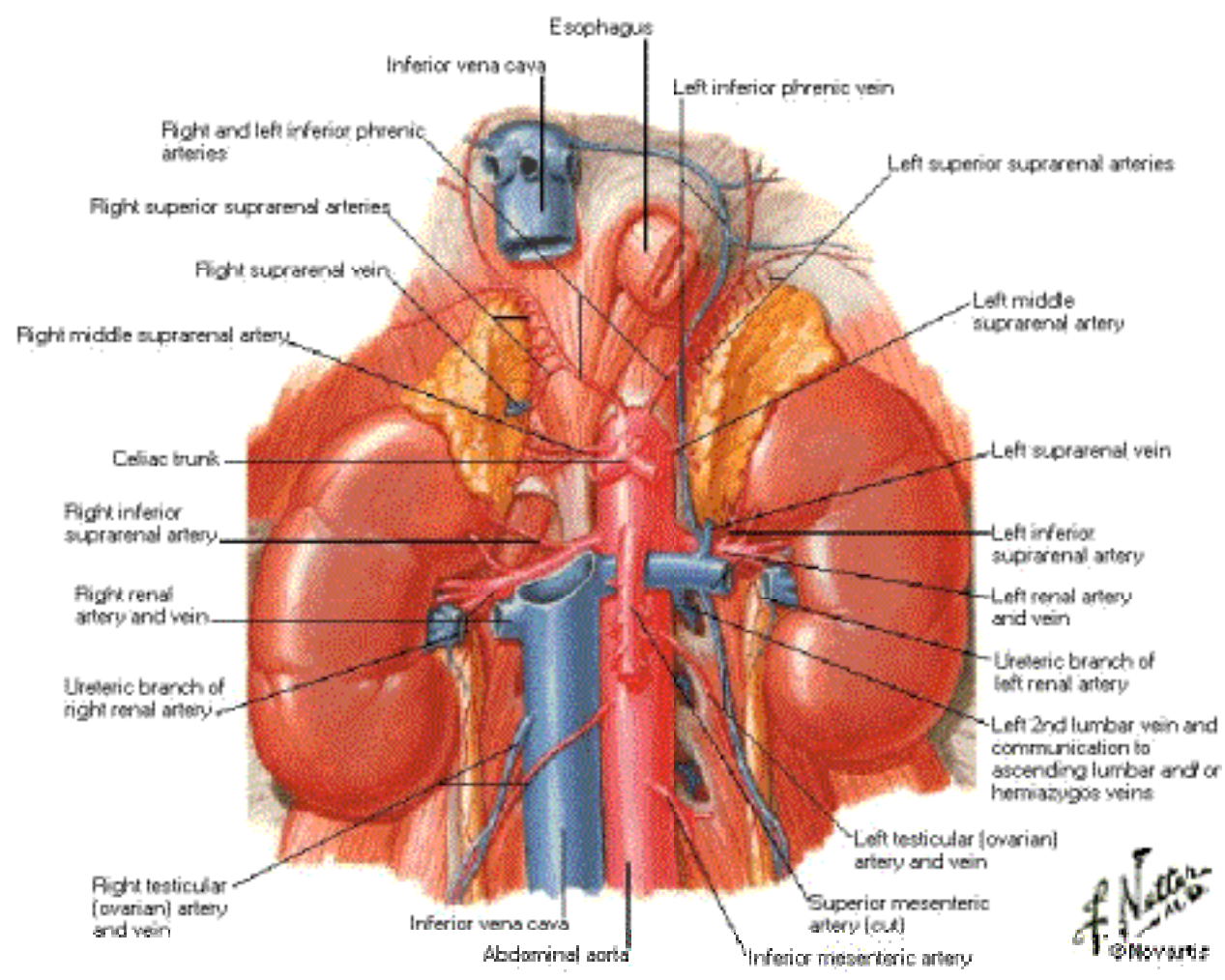


Suprarenal Gland and Lobulated Kidney of Infant



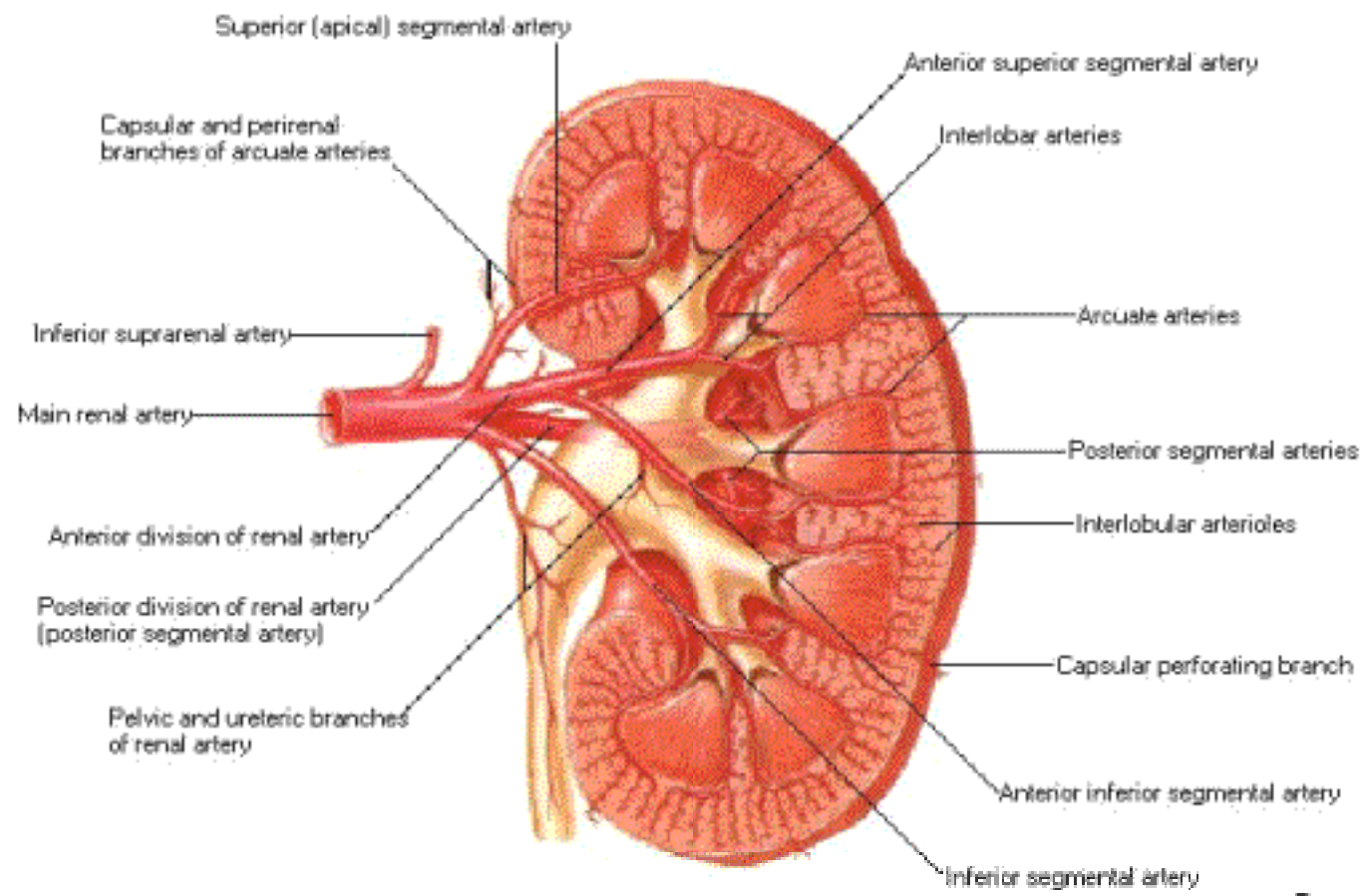
21

Renal Artery and Vein in Situ

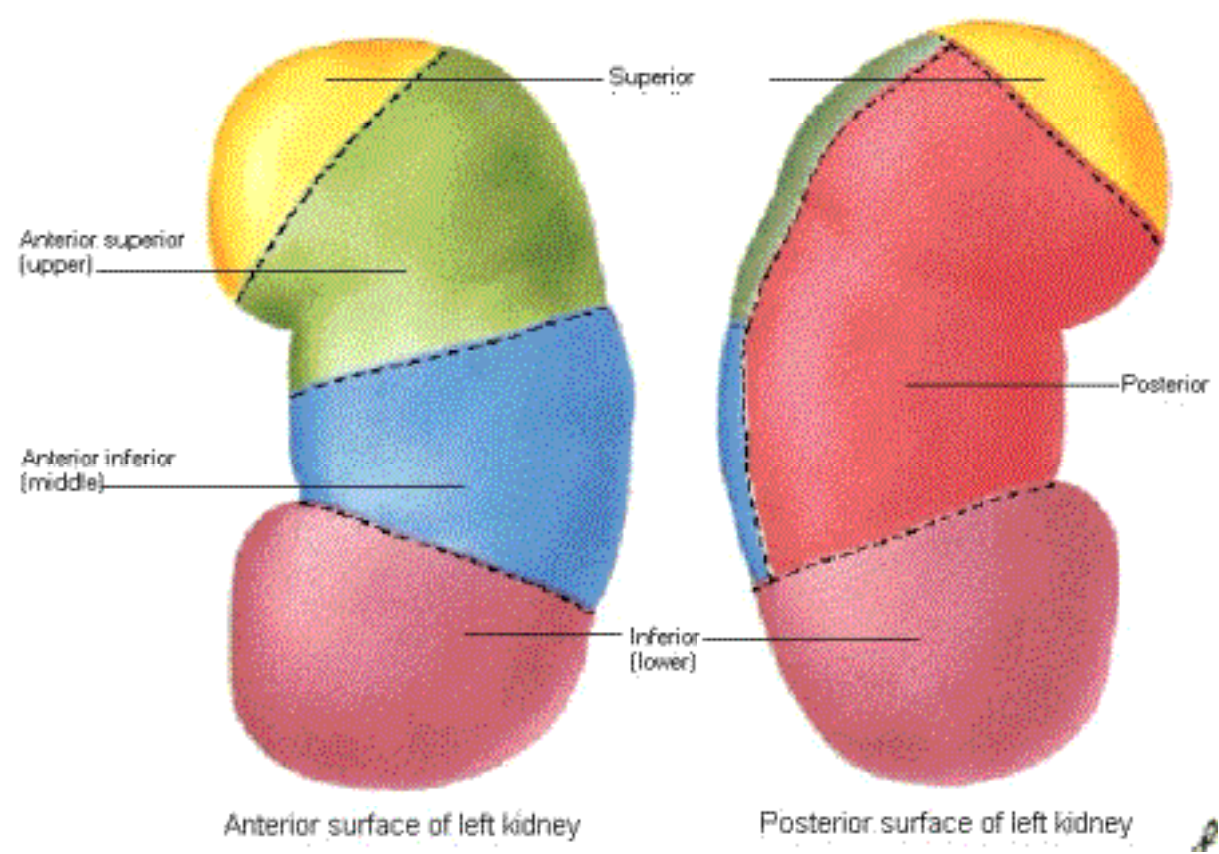


Intrarenal Arteries

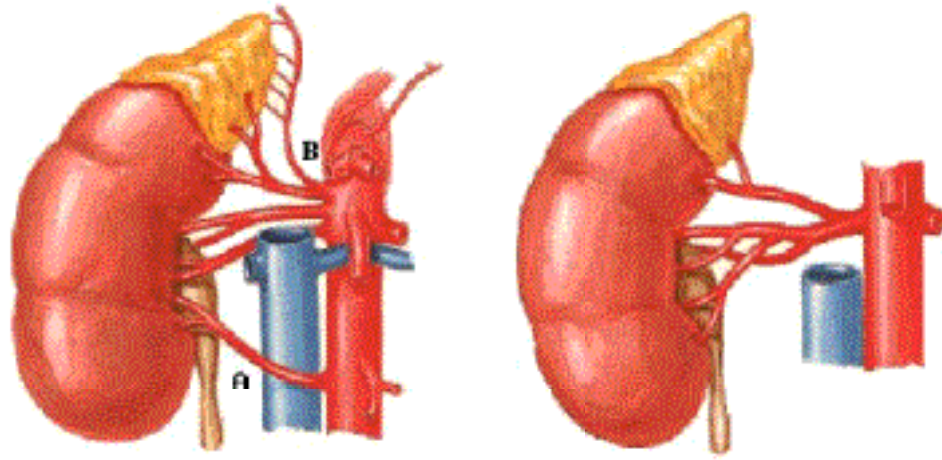
Frontal Section of Left Kidney - Anterior View



Vascular Renal Segments



Variations in Renal Artery

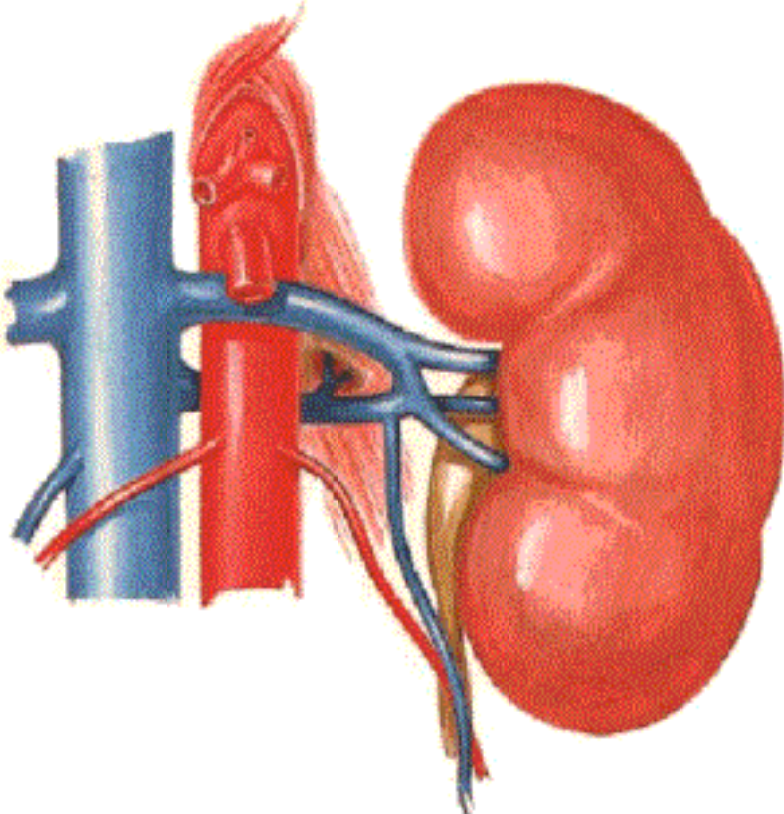


A) Low accessory right renal artery may pass in front of inferior vena cava instead of behind it

B) Inferior phrenic artery with suprarenal arteries may arise from renal artery

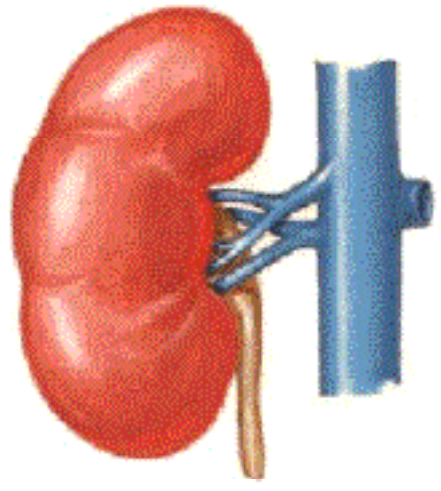
Proximal subdivision of renal artery

Variations in Renal Vein



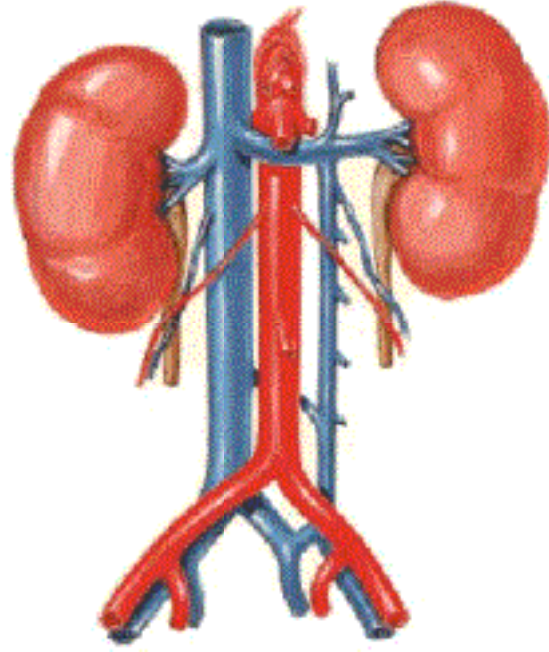
Double renal vein may form ring around aorta

Variations in Renal Vein [Continued]



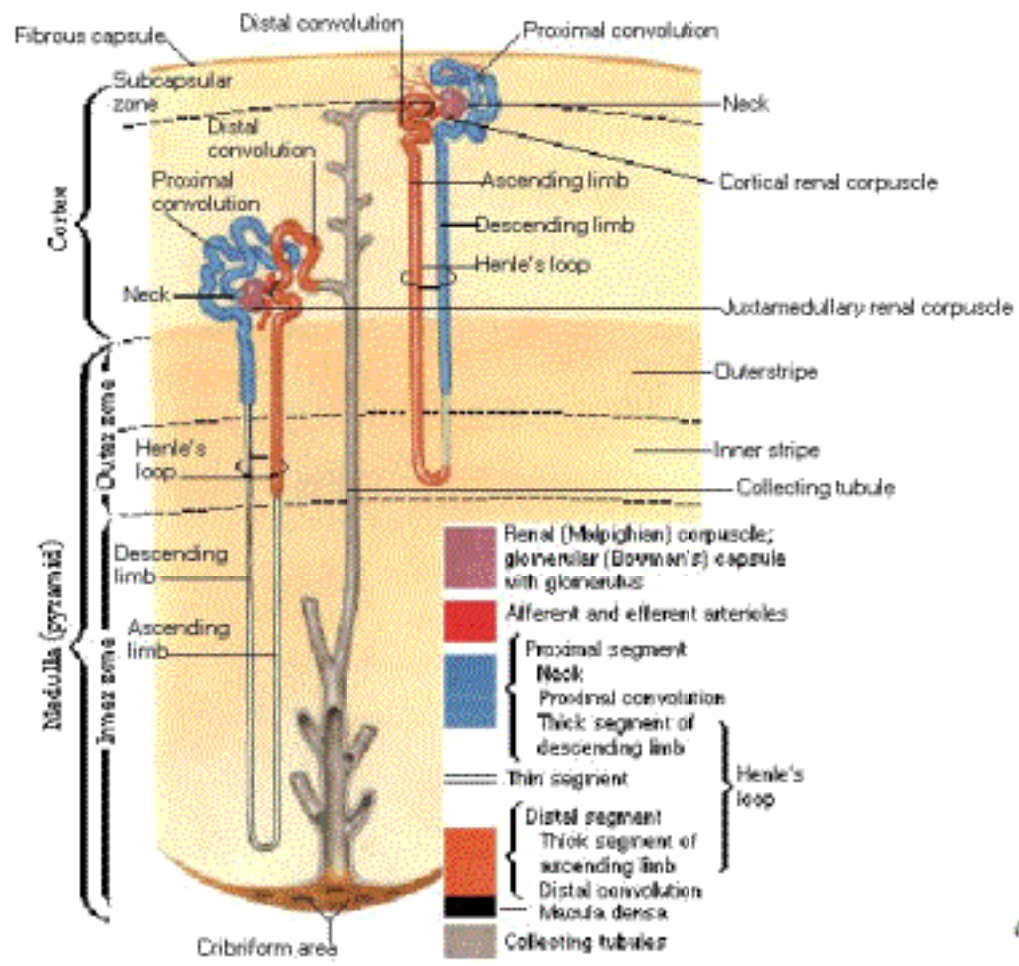
Multiple renal veins

Persistent left inferior vena cava
may join left renal vein

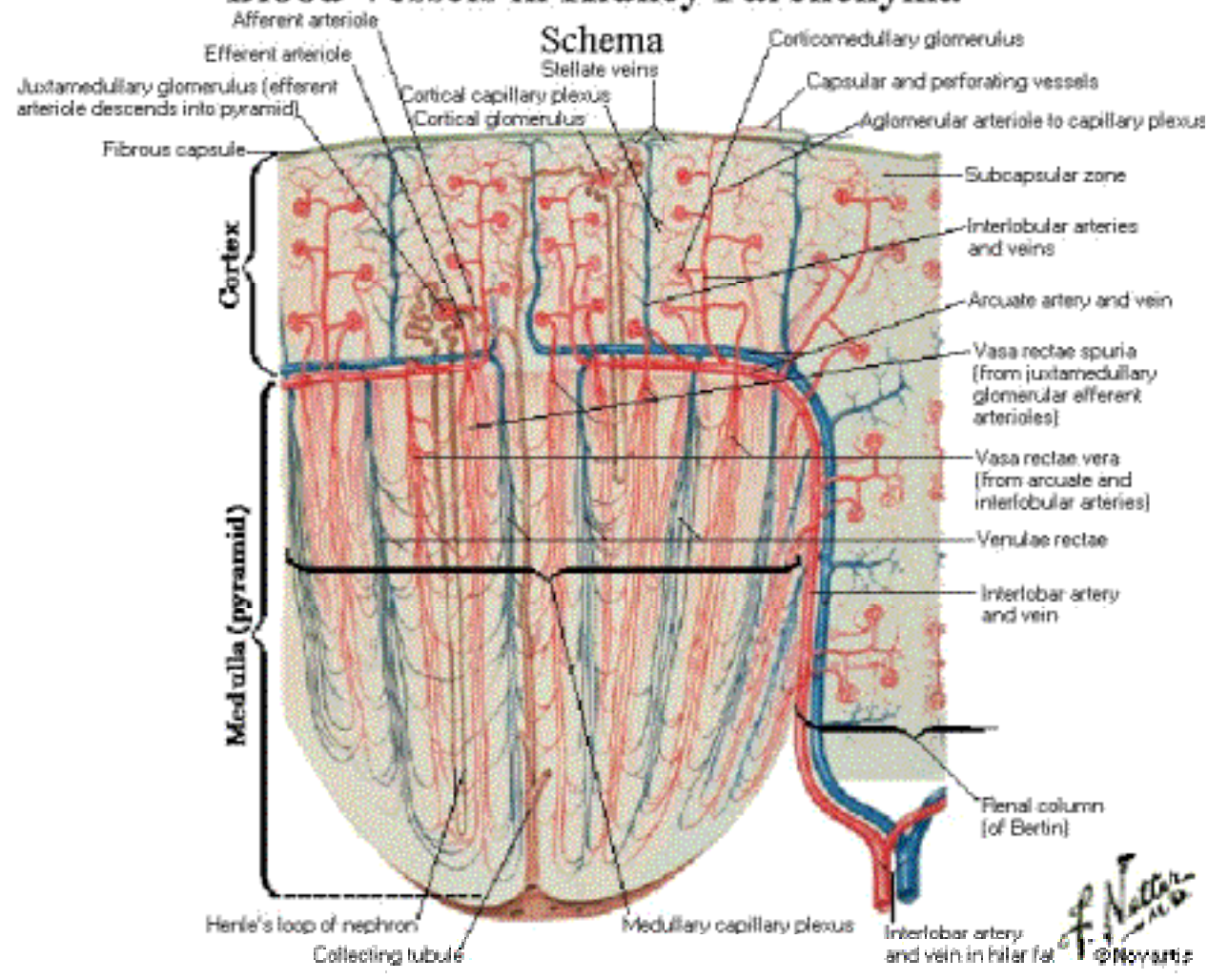


Nephron and Collecting Tubule

Schema

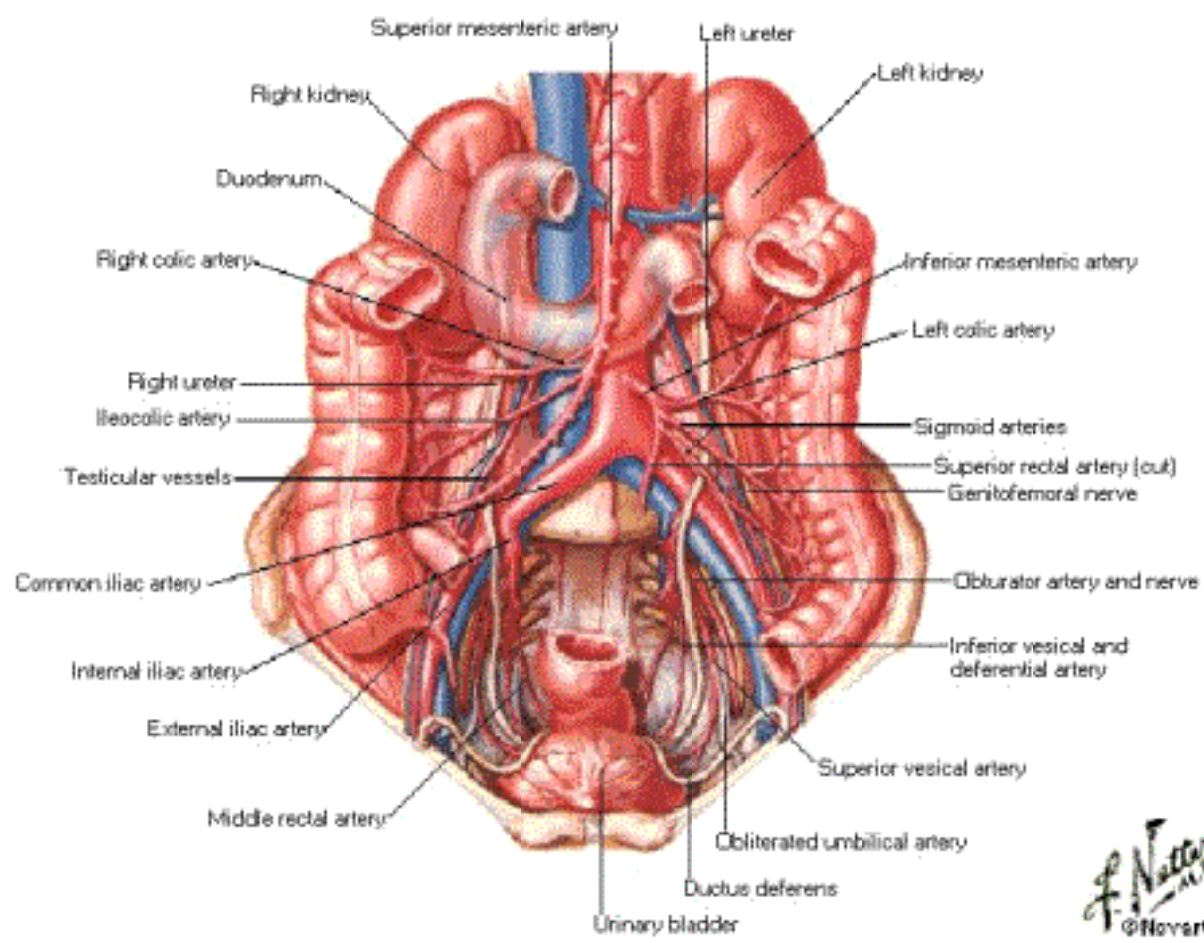


Blood Vessels in Kidney Parenchyma

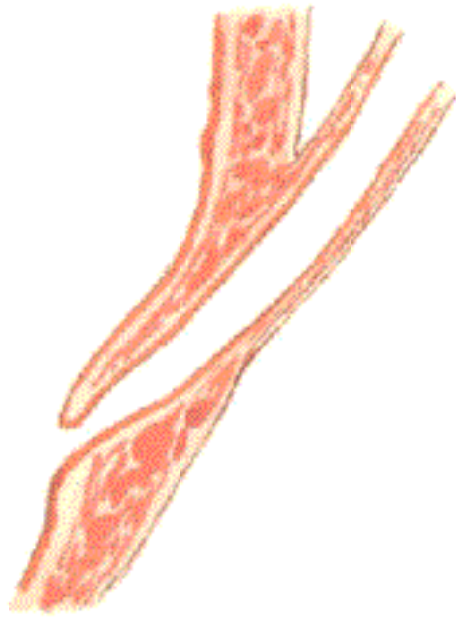

Ureters in Male

Anterior View

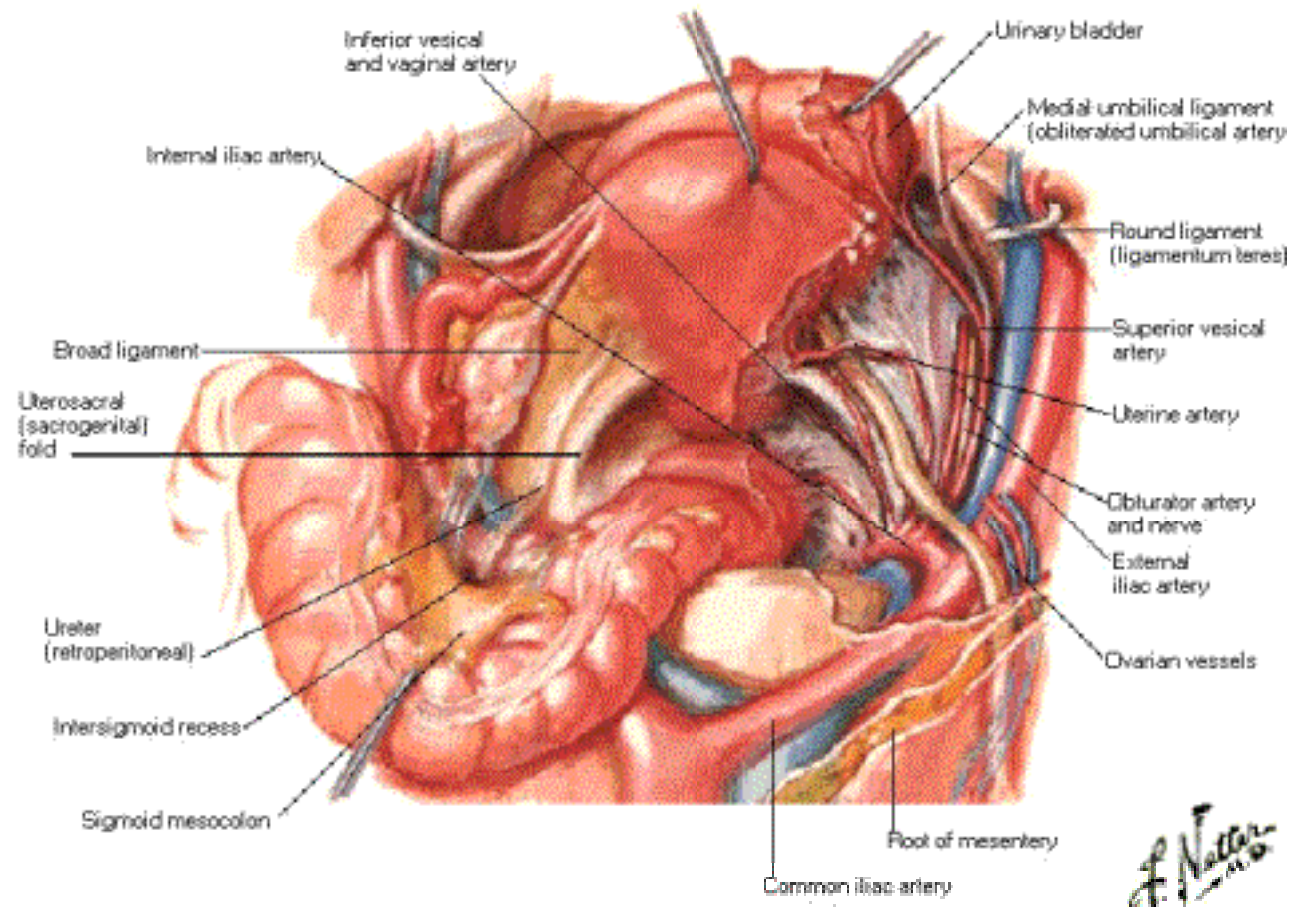


Diagonal Course of Ureter through Bladder Wall

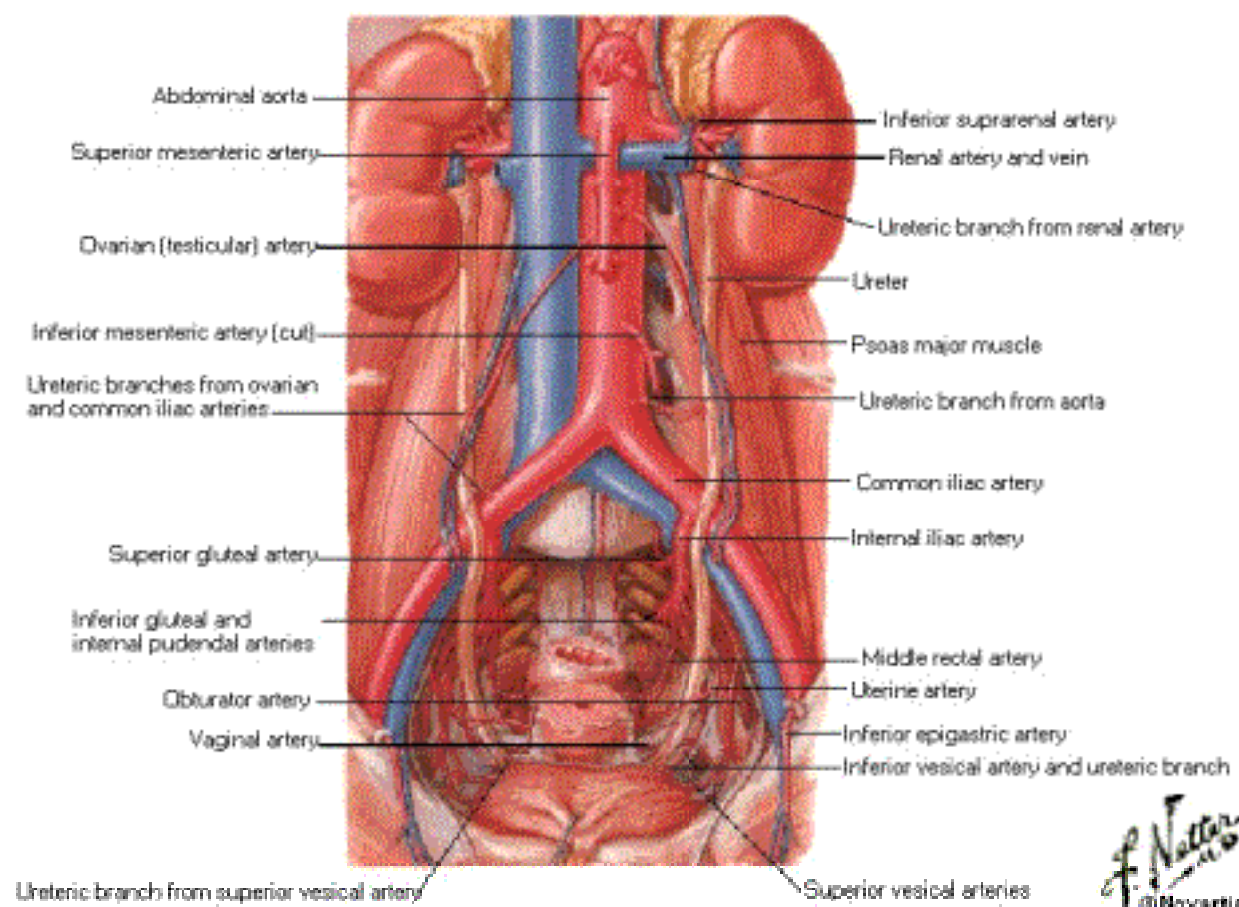


Ureters in Female

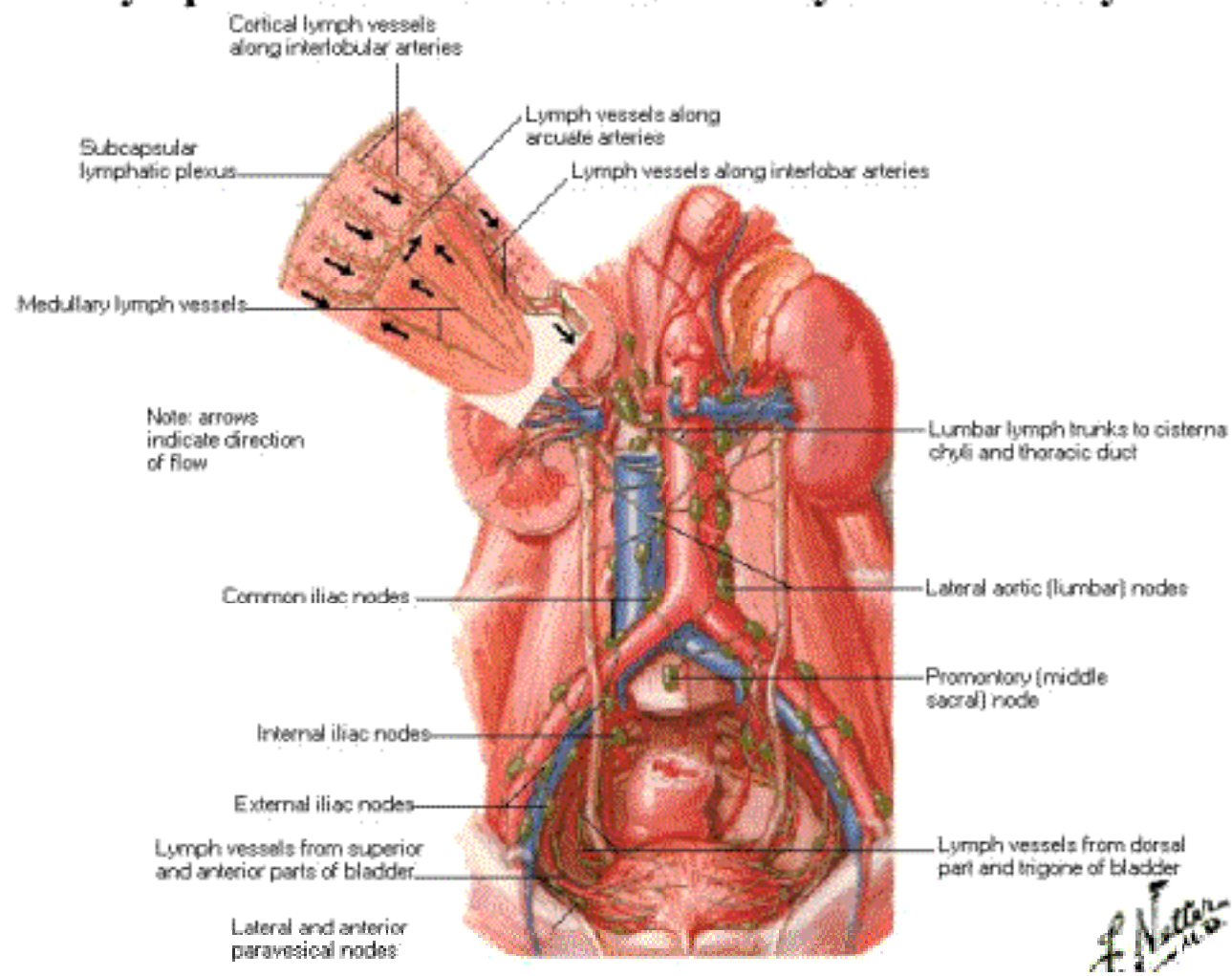
Superior View



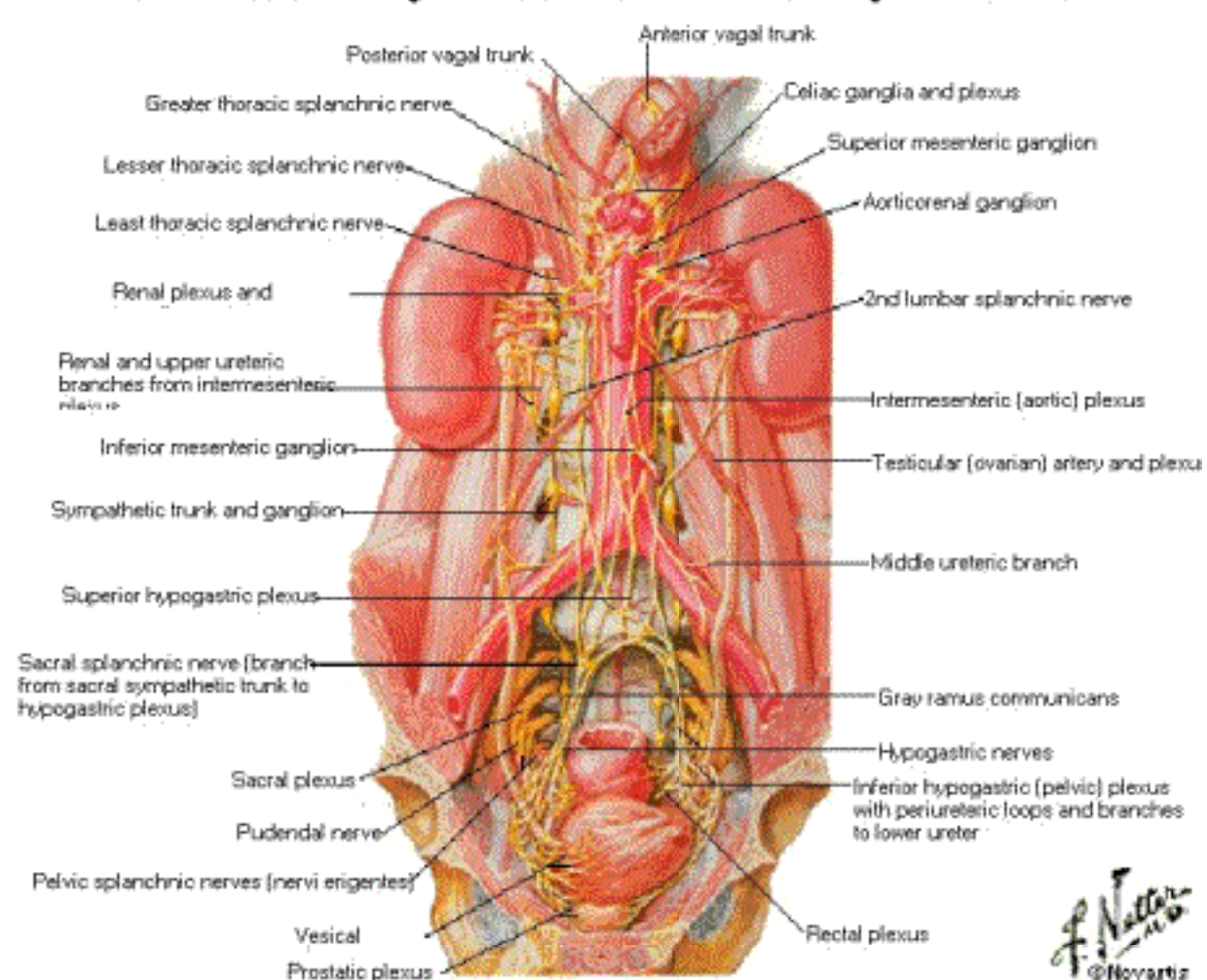
Arteries of Ureters and Urinary Bladder



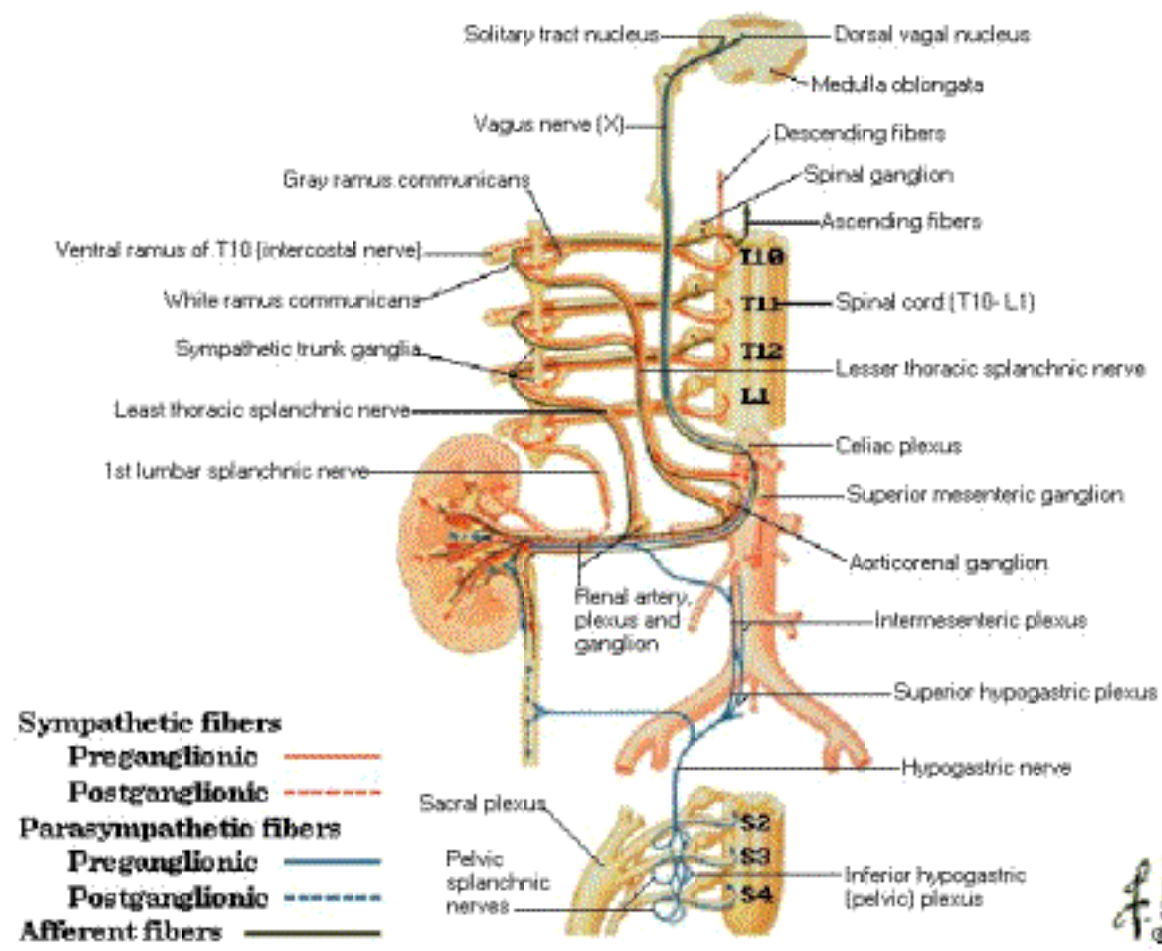
Lymph Vessels and Nodes of Kidneys and Urinary



Nerves of Kidneys, Ureters and Urinary Bladder



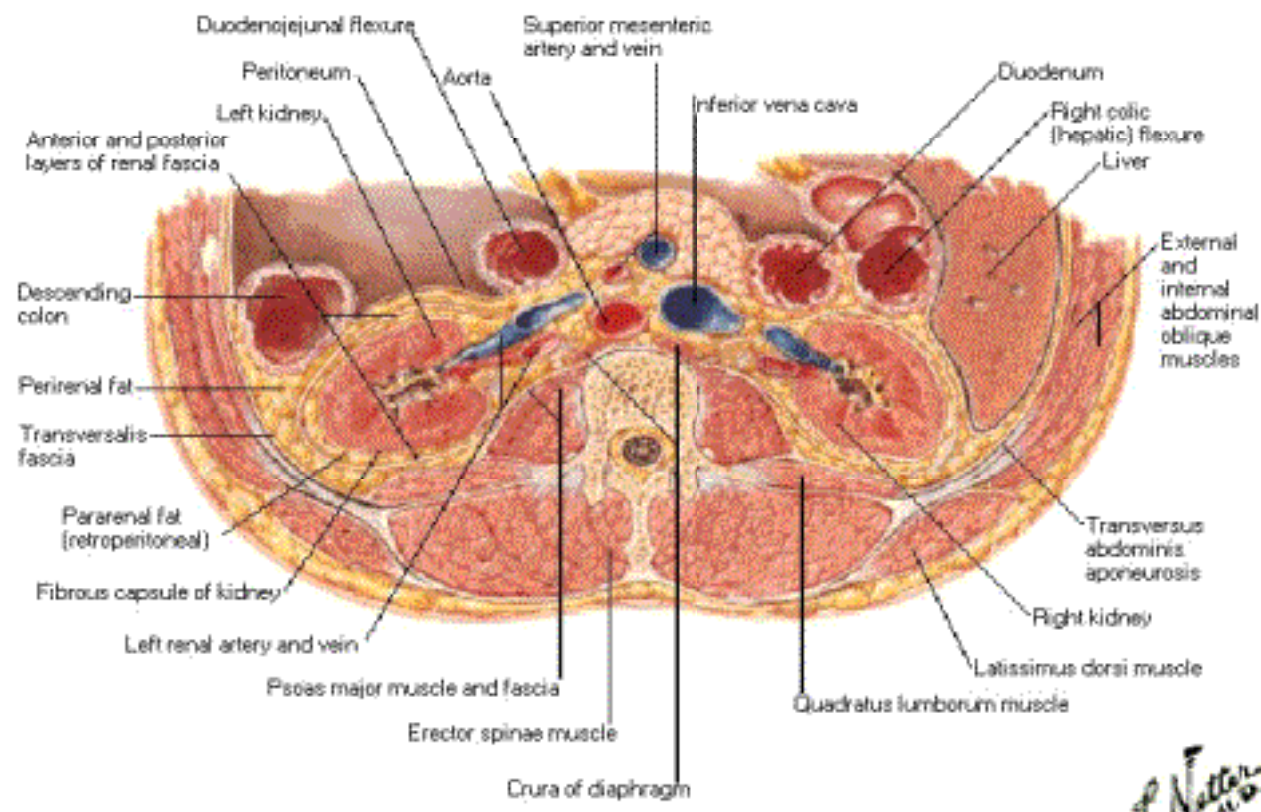
Innervation of Kidneys and Upper Ureters Schema



f.1

Renal Fascia

Transverse Section through 2nd Lumbar Vertebra

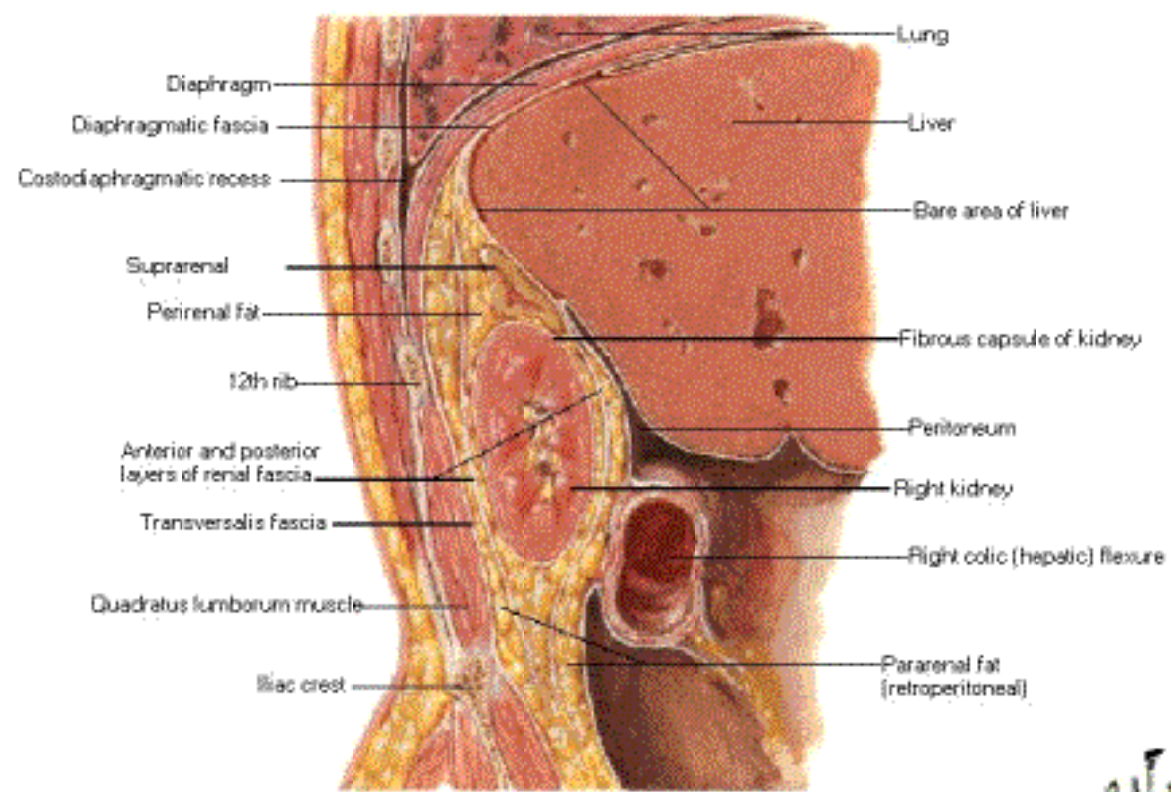


Demonstrates horizontal disposition of fascia

F. Netter M.D.
© Elsevier

Renal Fascia

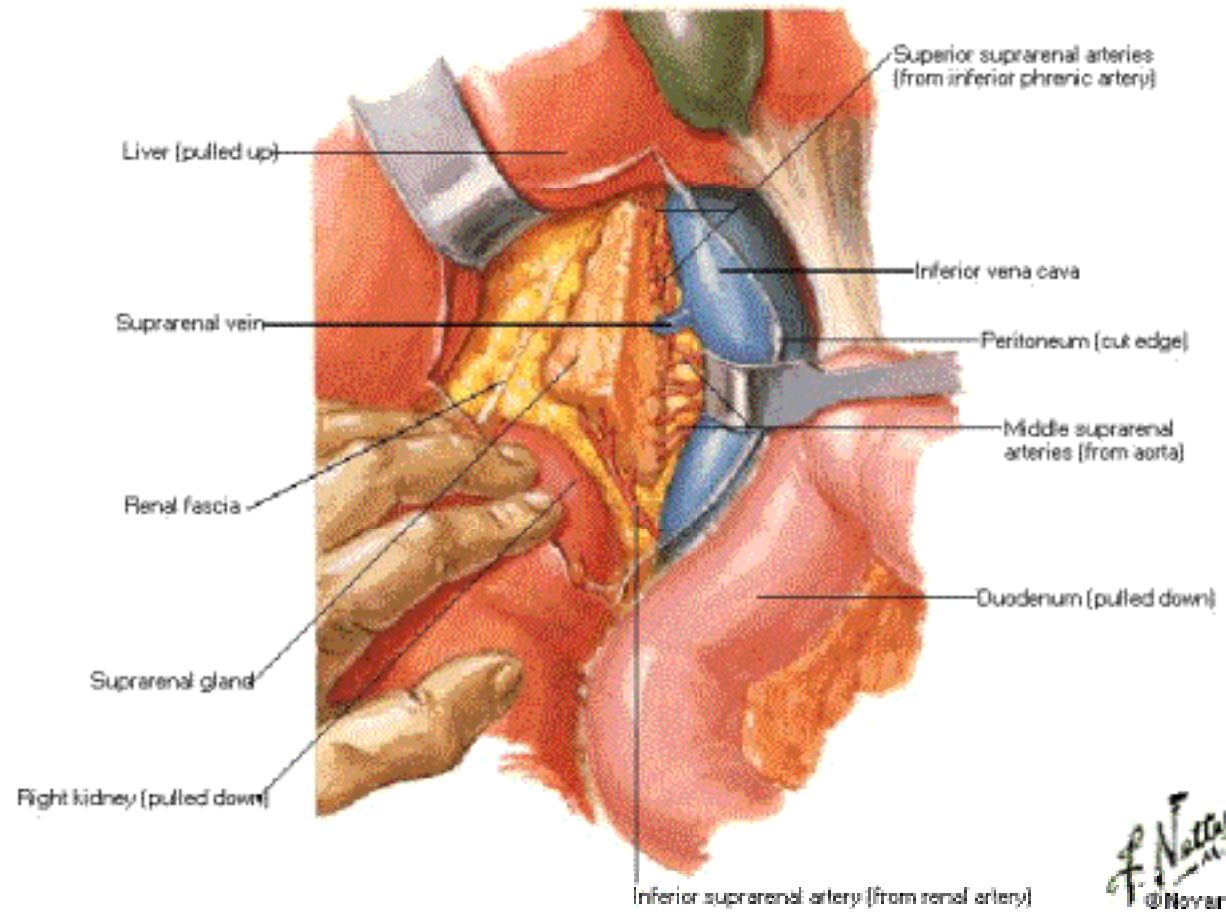
Sagittal Section through Right Kidney



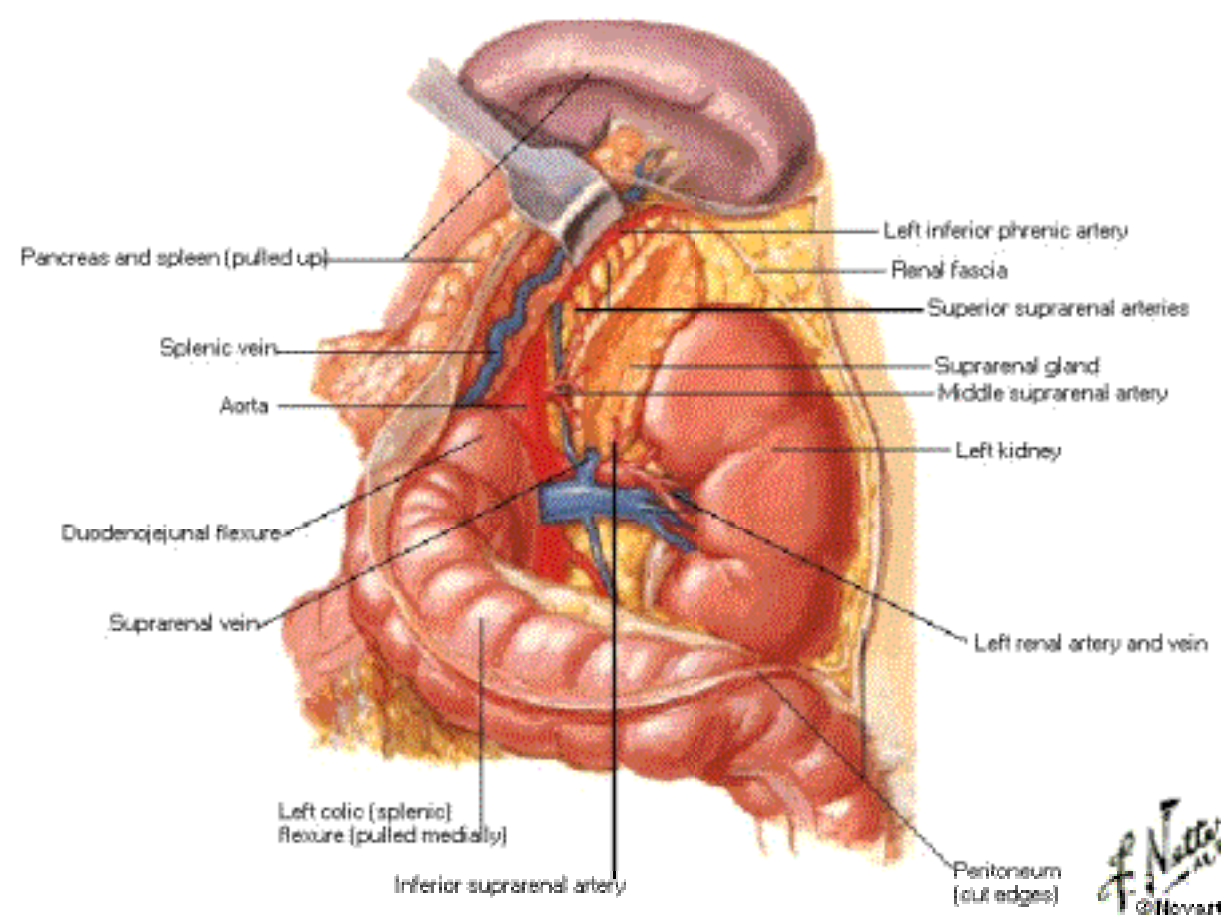
Demonstrates vertical disposition of renal fascia



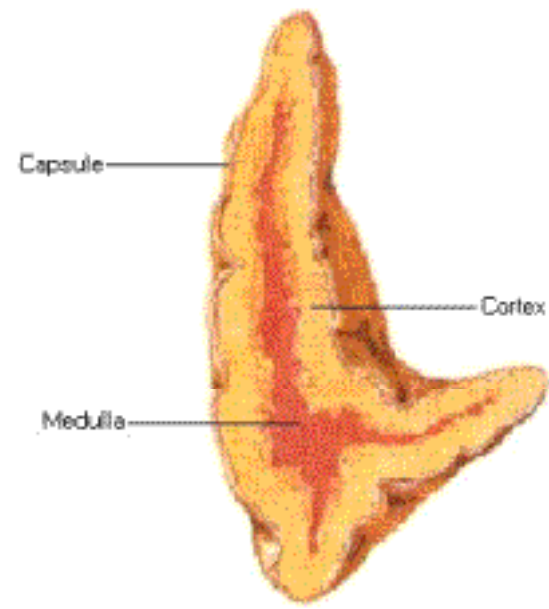
Arteries and Veins of Right Suprarenal Gland in Situ



Arteries and Veins of Left Suprarenal Gland in Situ

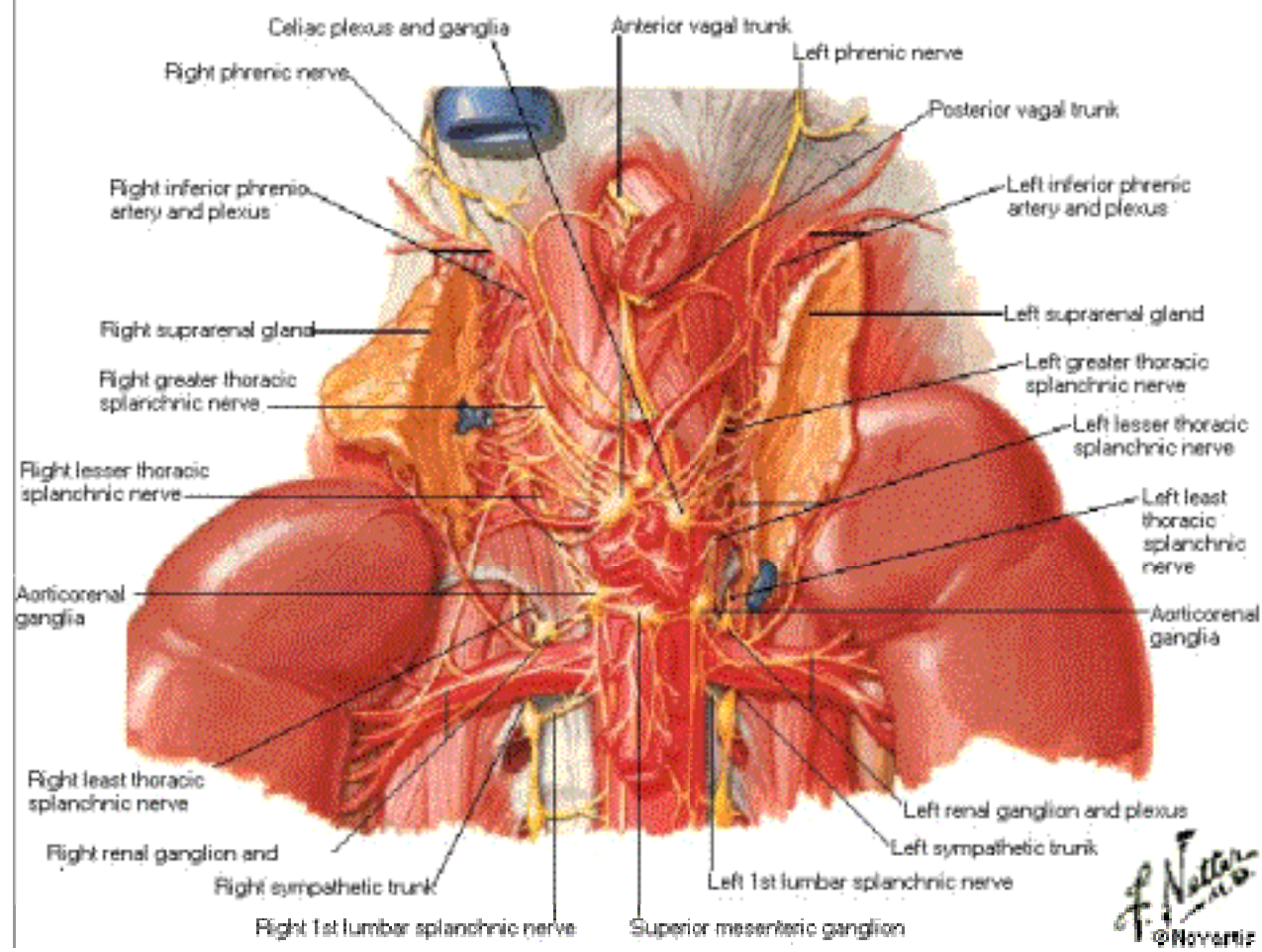


Cross Section through Suprarenal Gland



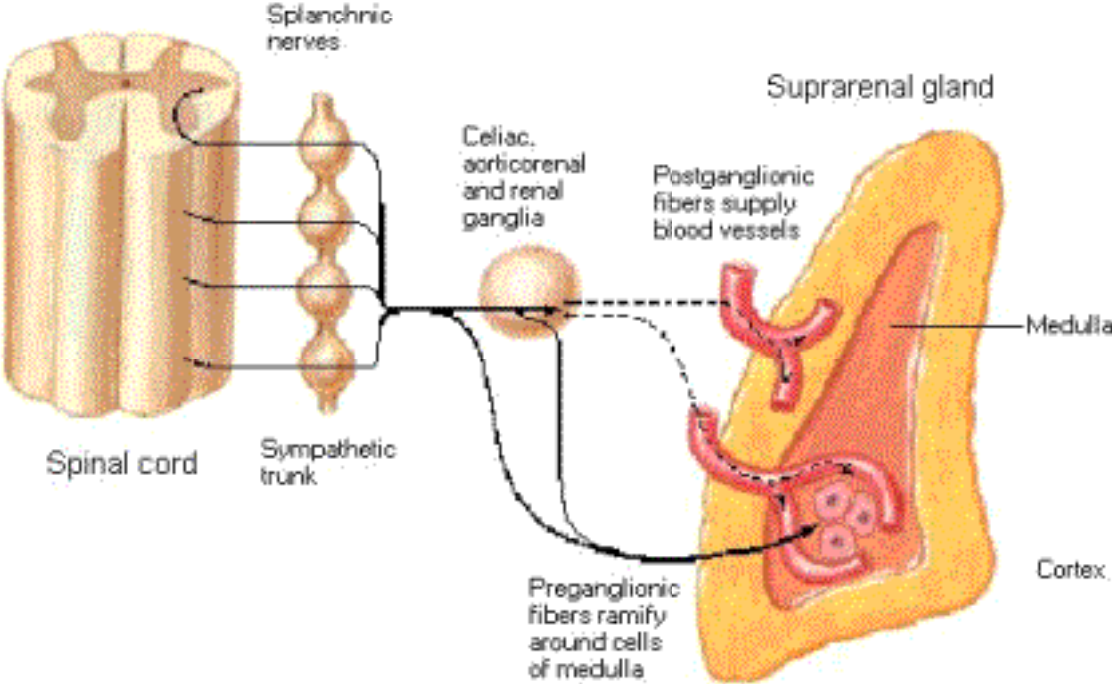
Nerves of Suprarenal Glands

Dissection



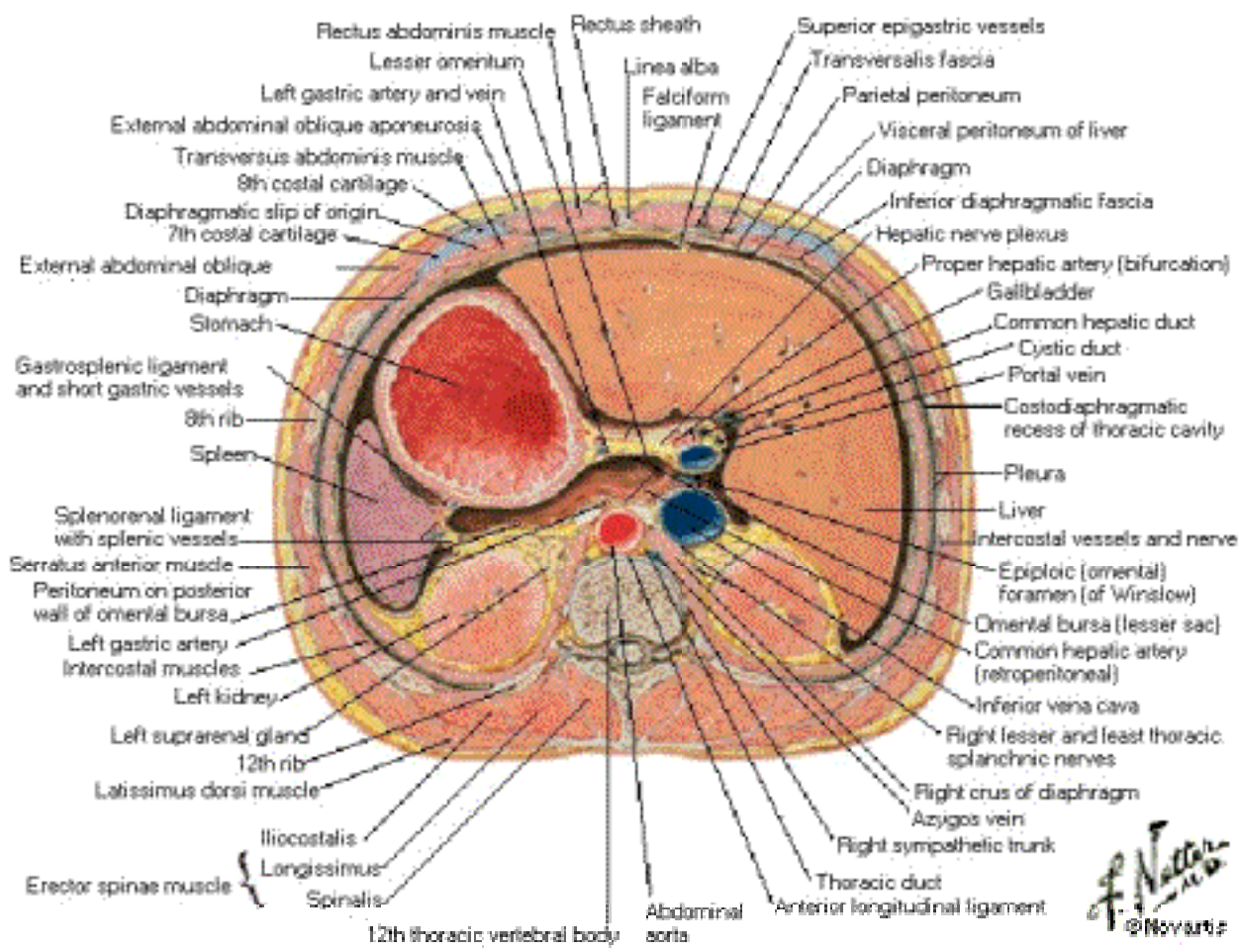
Nerves of Suprarenal Glands

Schema



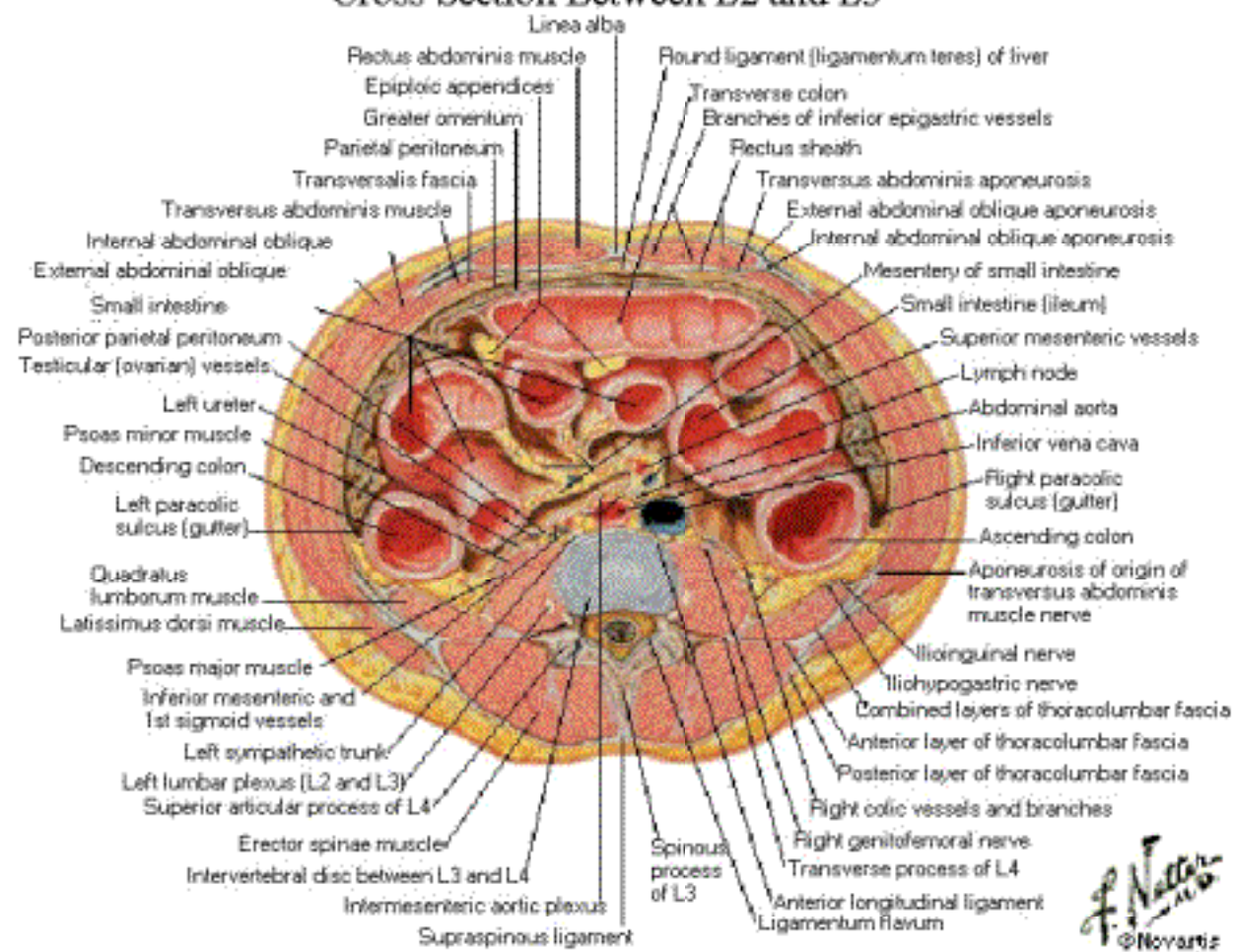
Abdominal Wall and Viscera

Cross Section at T12



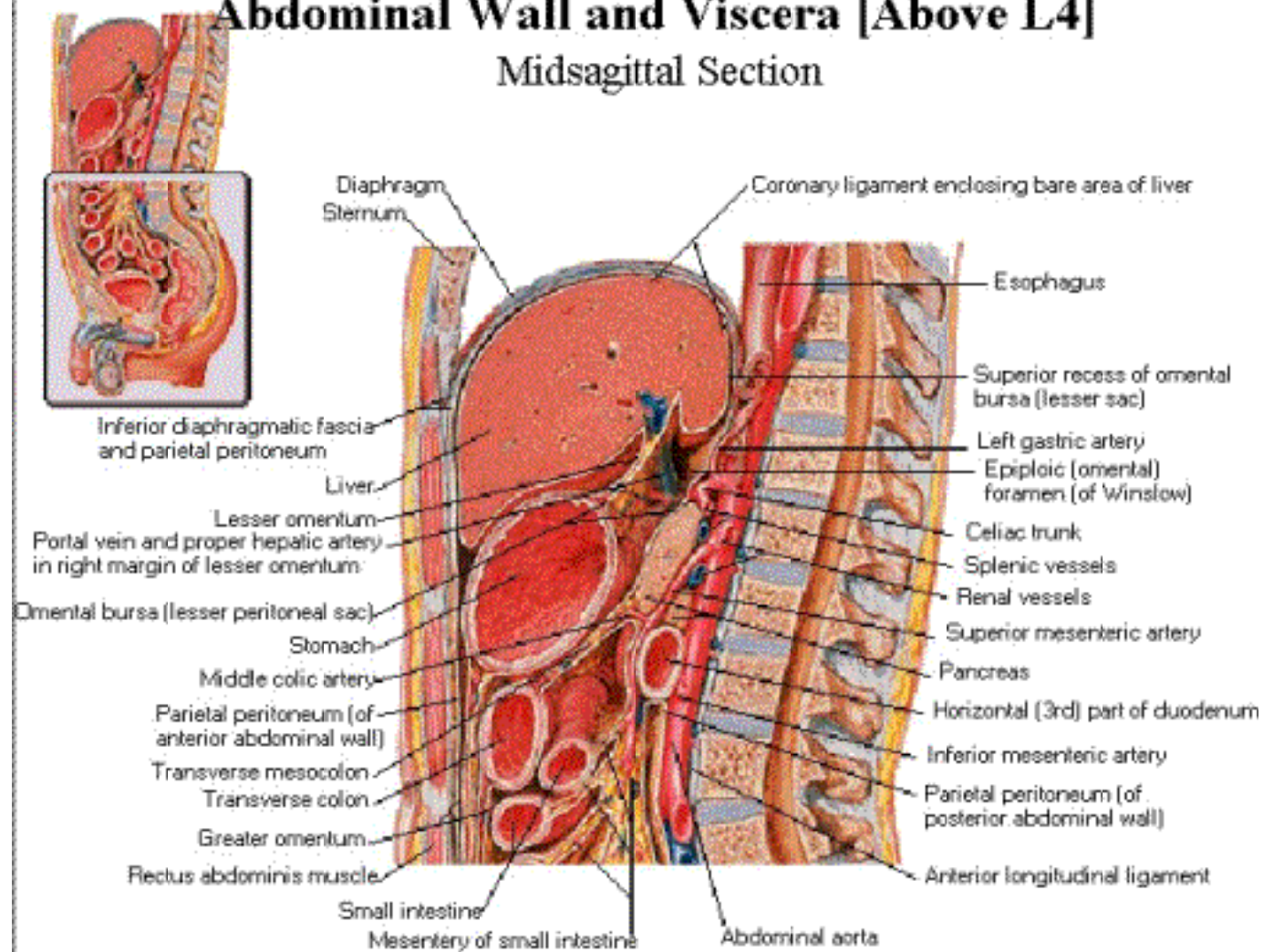
Abdominal Wall and Viscera

Cross Section Between L2 and L3



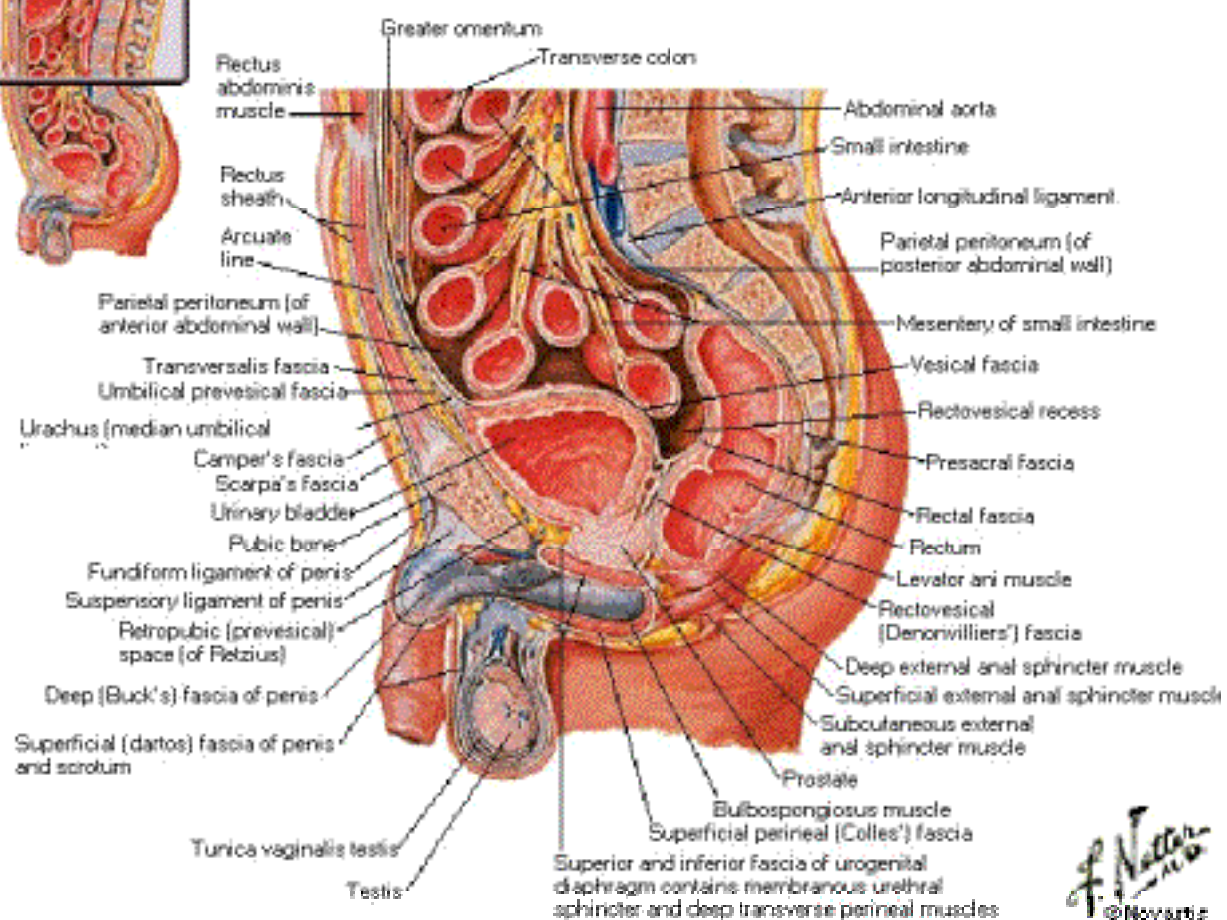
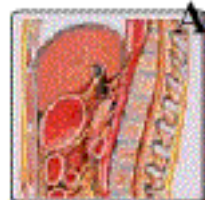Abdominal Wall and Viscera [Above L4]

Midsagittal Section



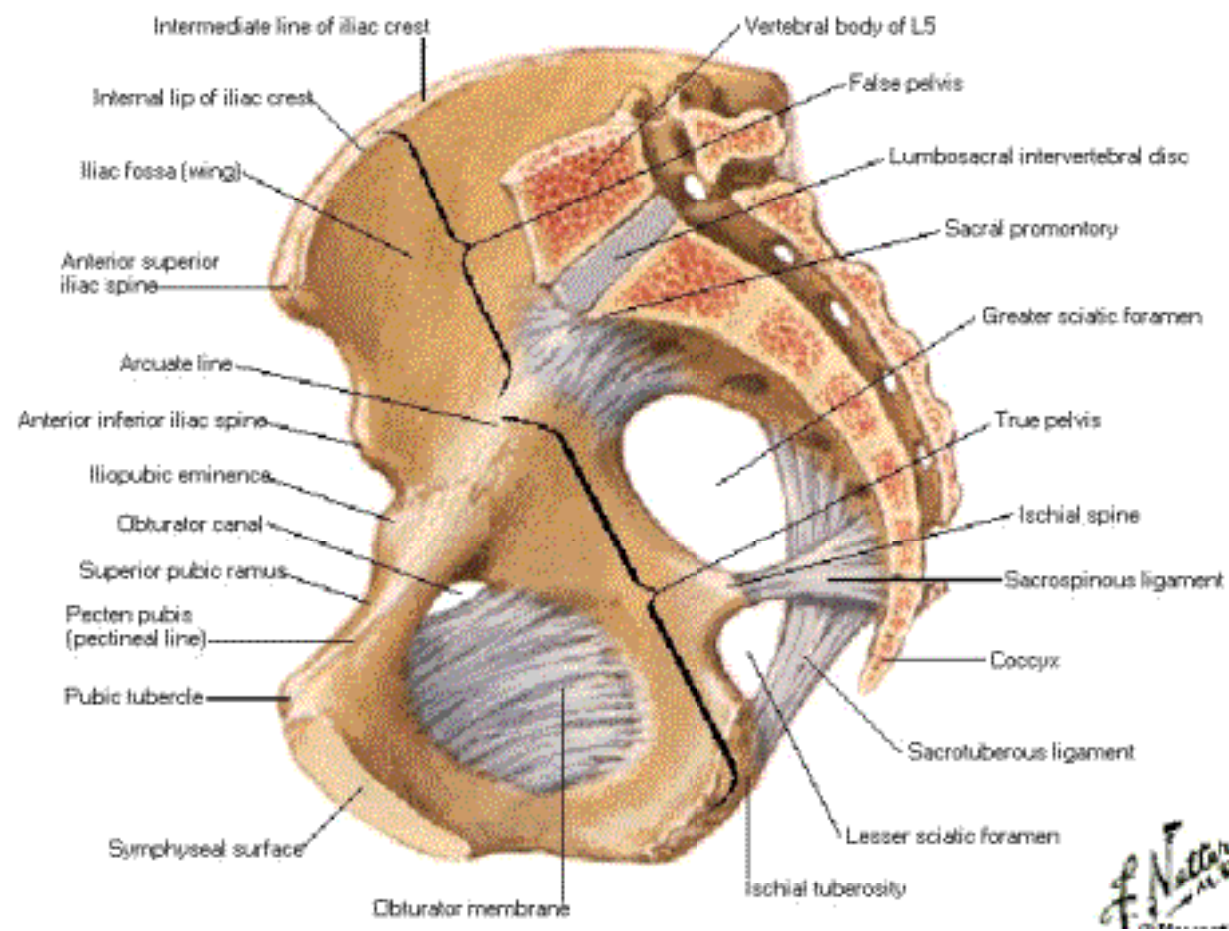
Abdominal Wall and Viscera [Below L4]

Midsagittal Section



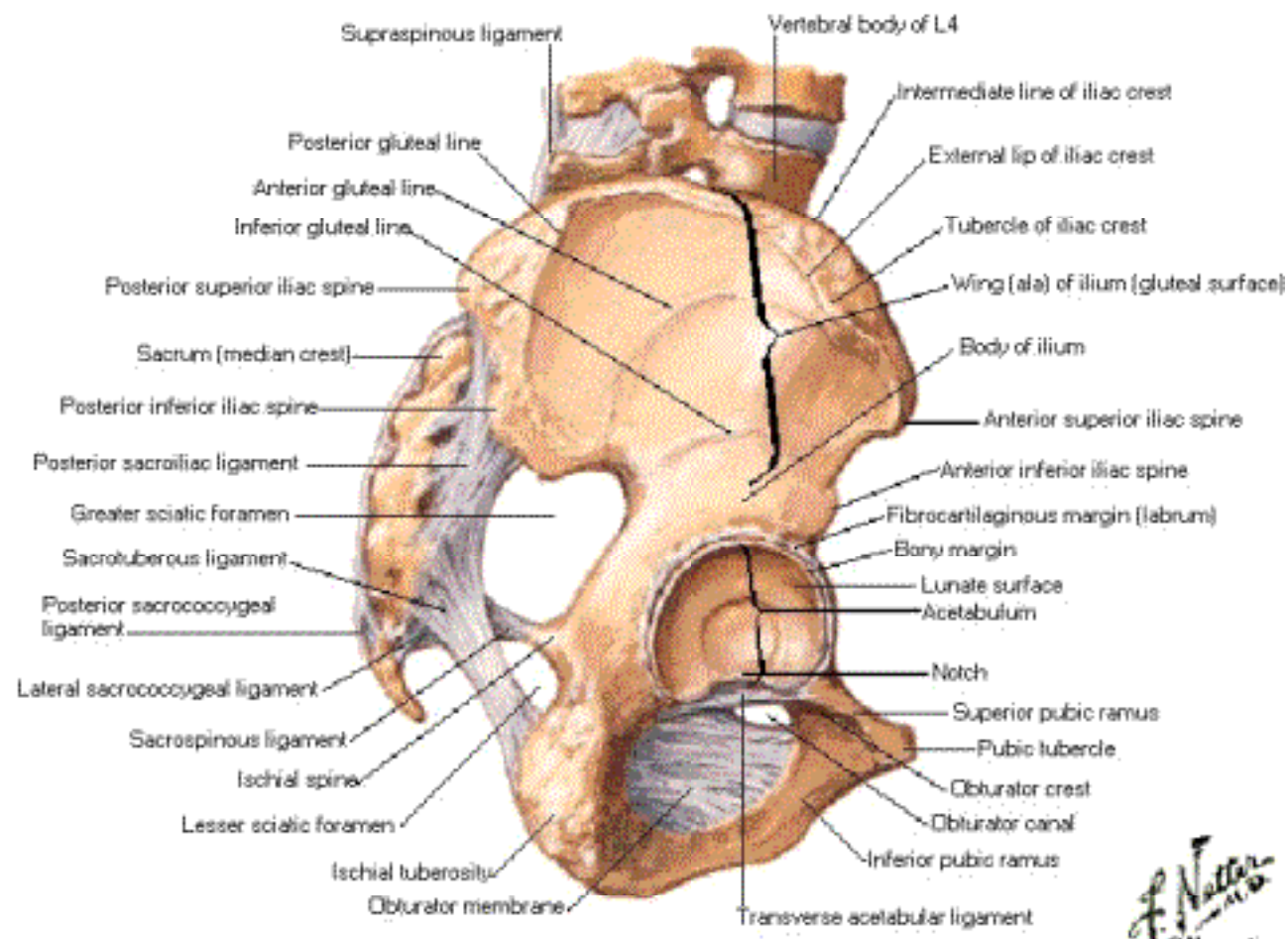
F. Netter M.D.
© 2005

Bones and Ligaments of Pelvis Midsagittal Section



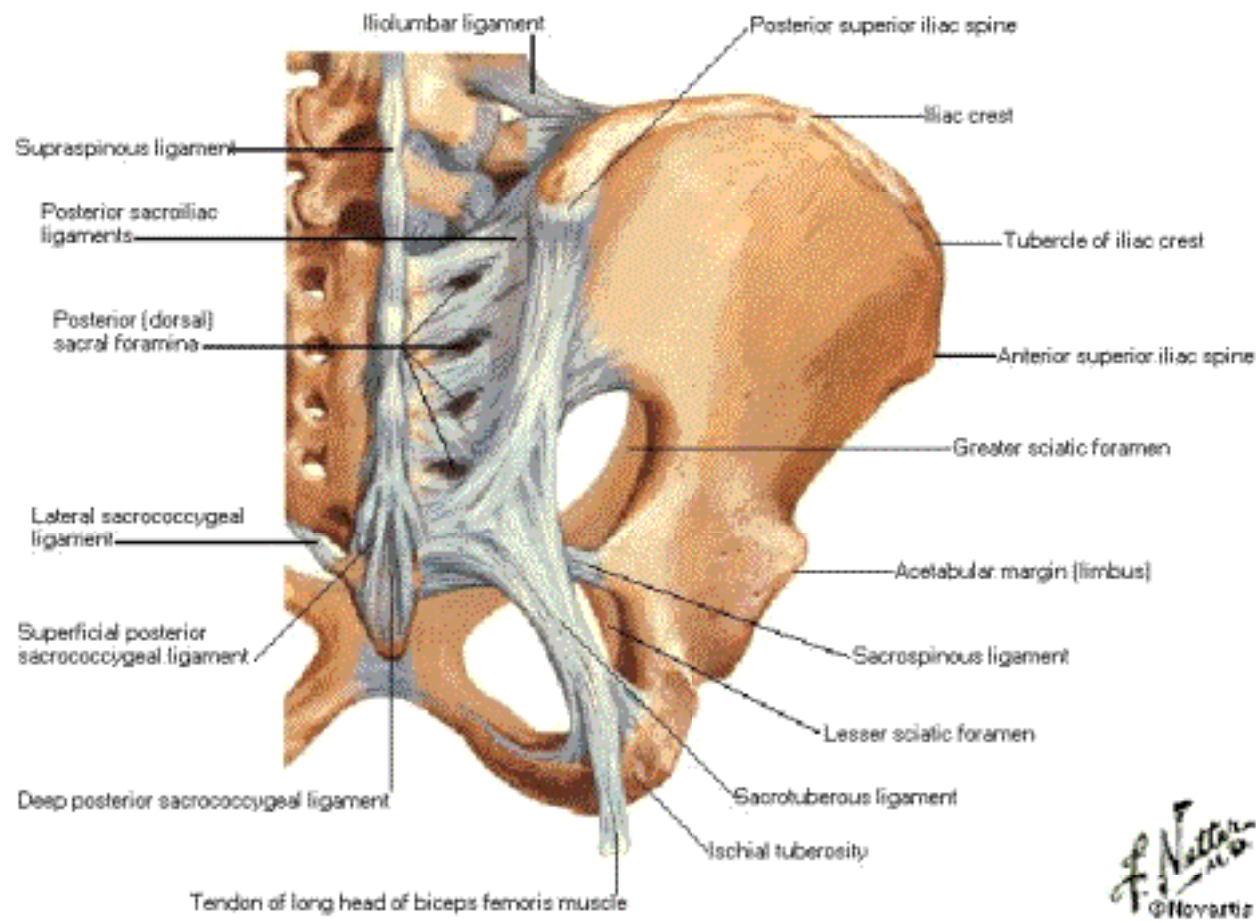
Bones and Ligaments of Pelvis

Lateral View



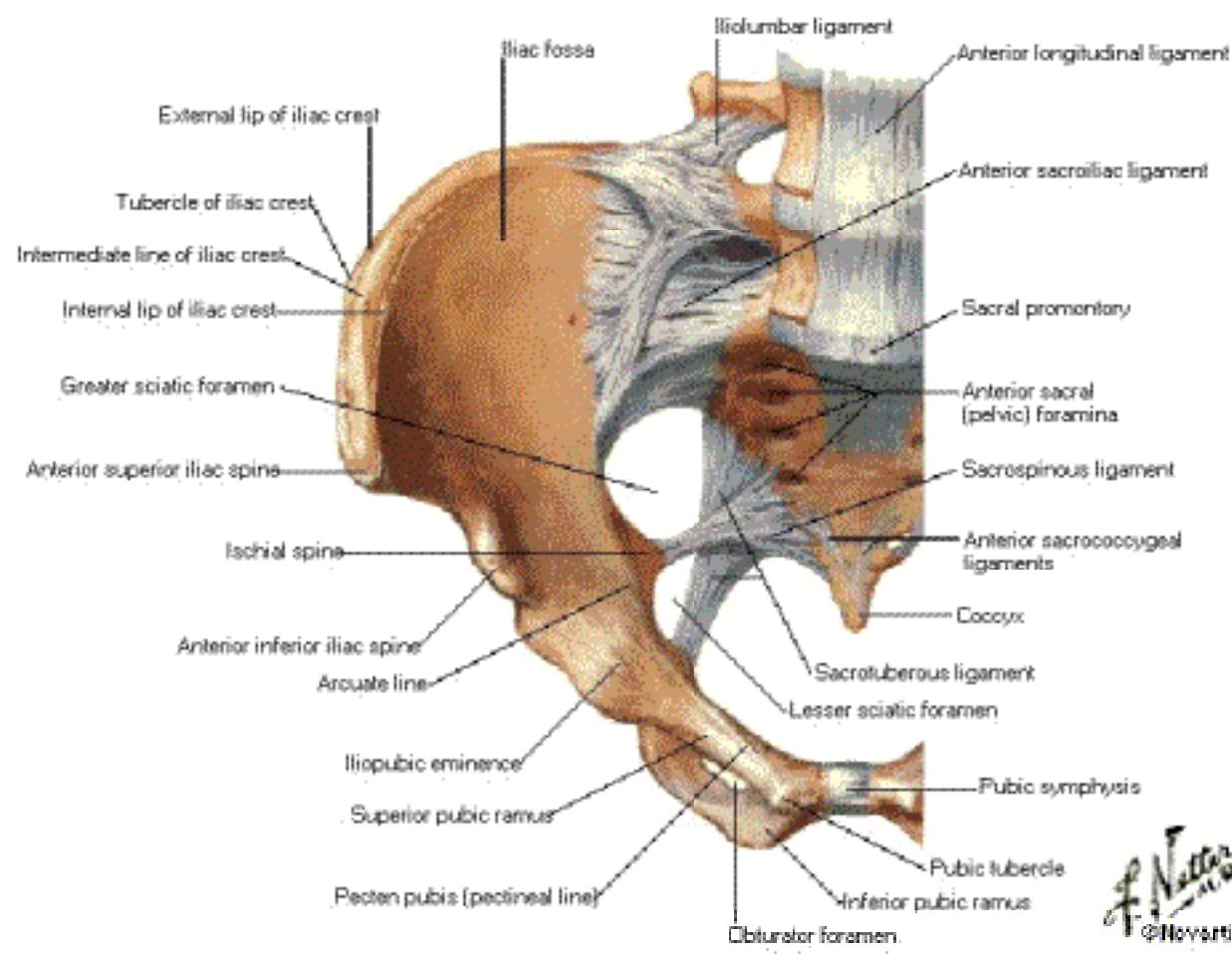
Bones and Ligaments of Pelvis

Posterior View



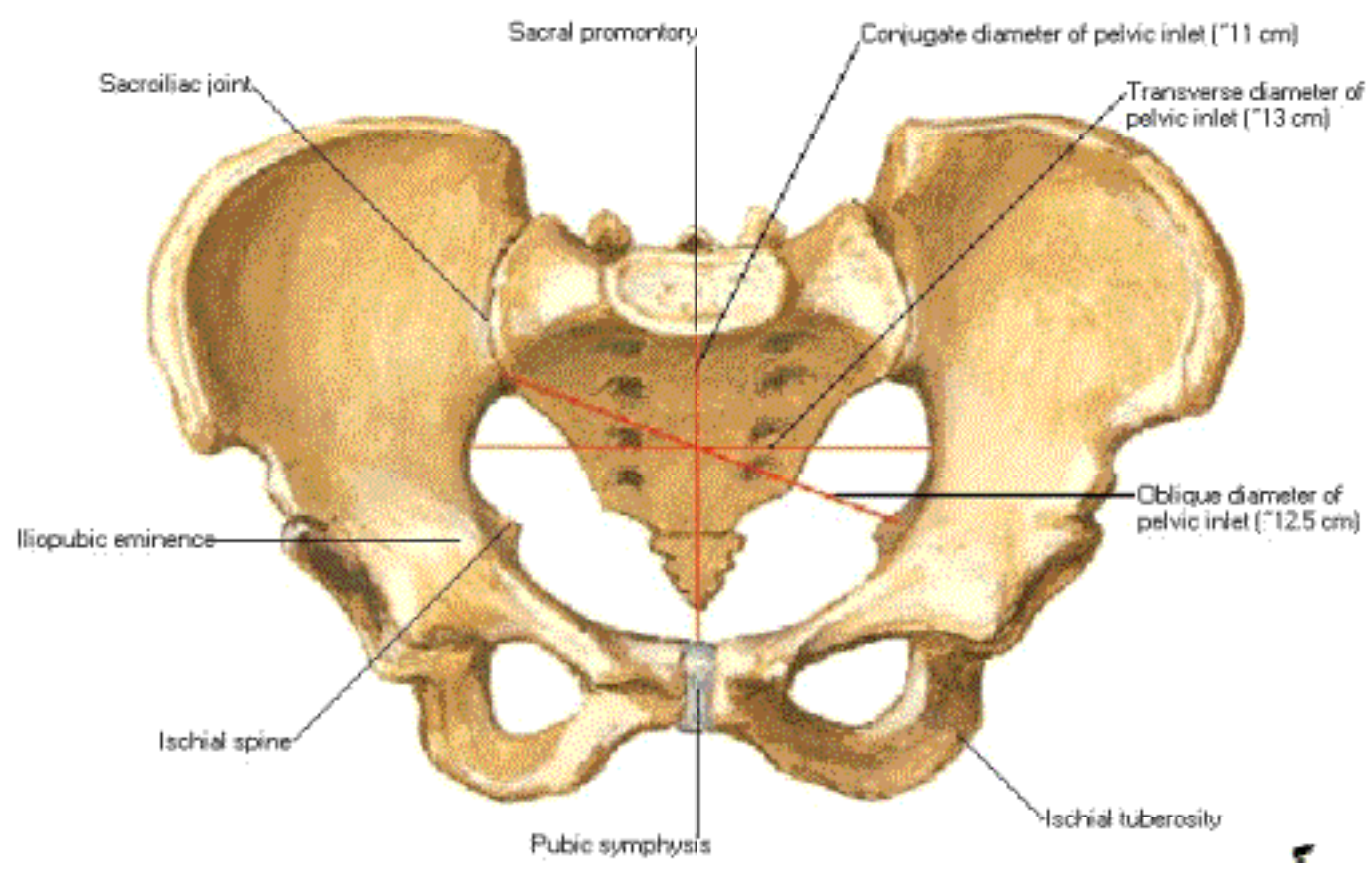
Bones and Ligaments of Pelvis

Anterior View



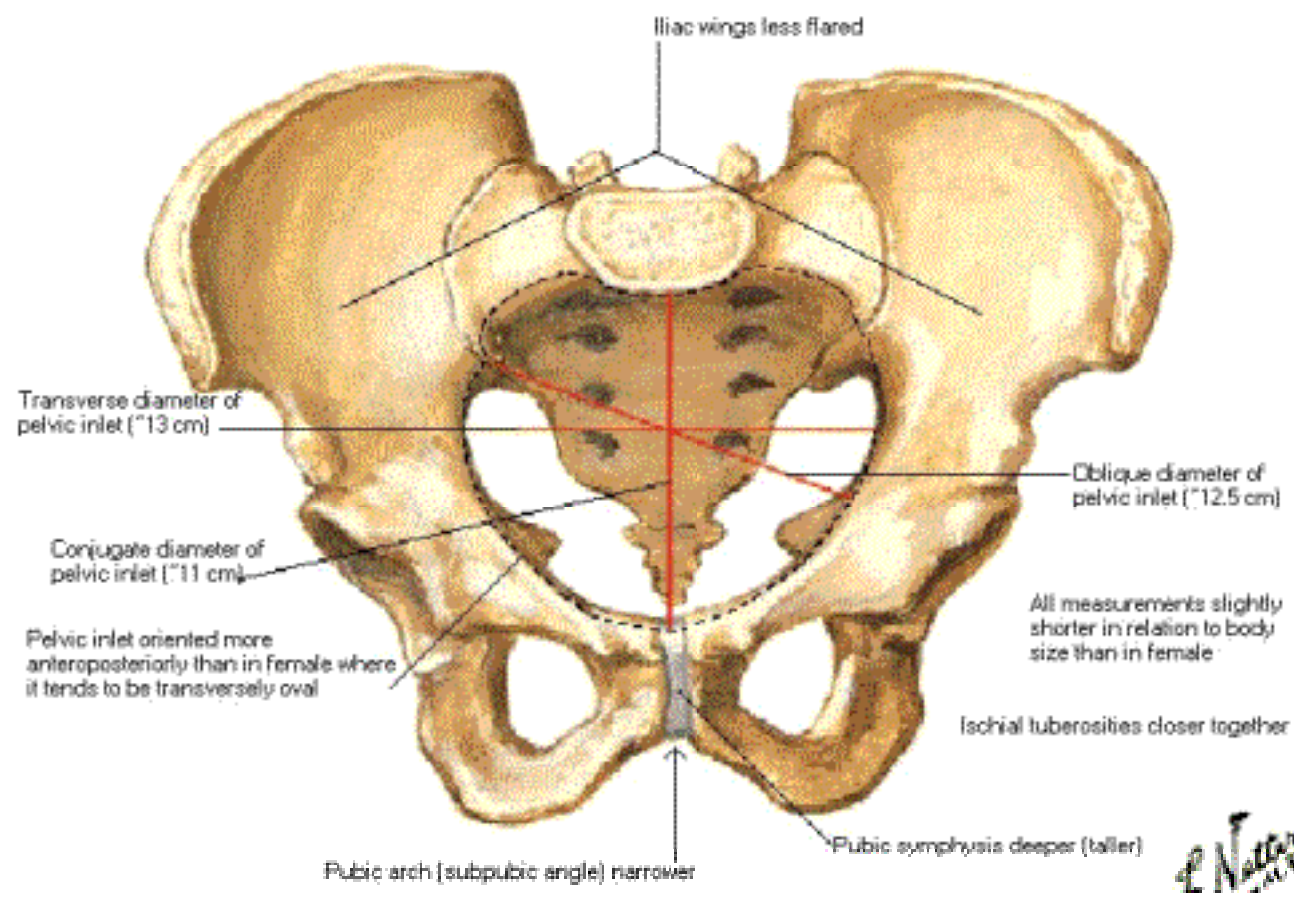
Female Pelvis

Measurements - Anterior View



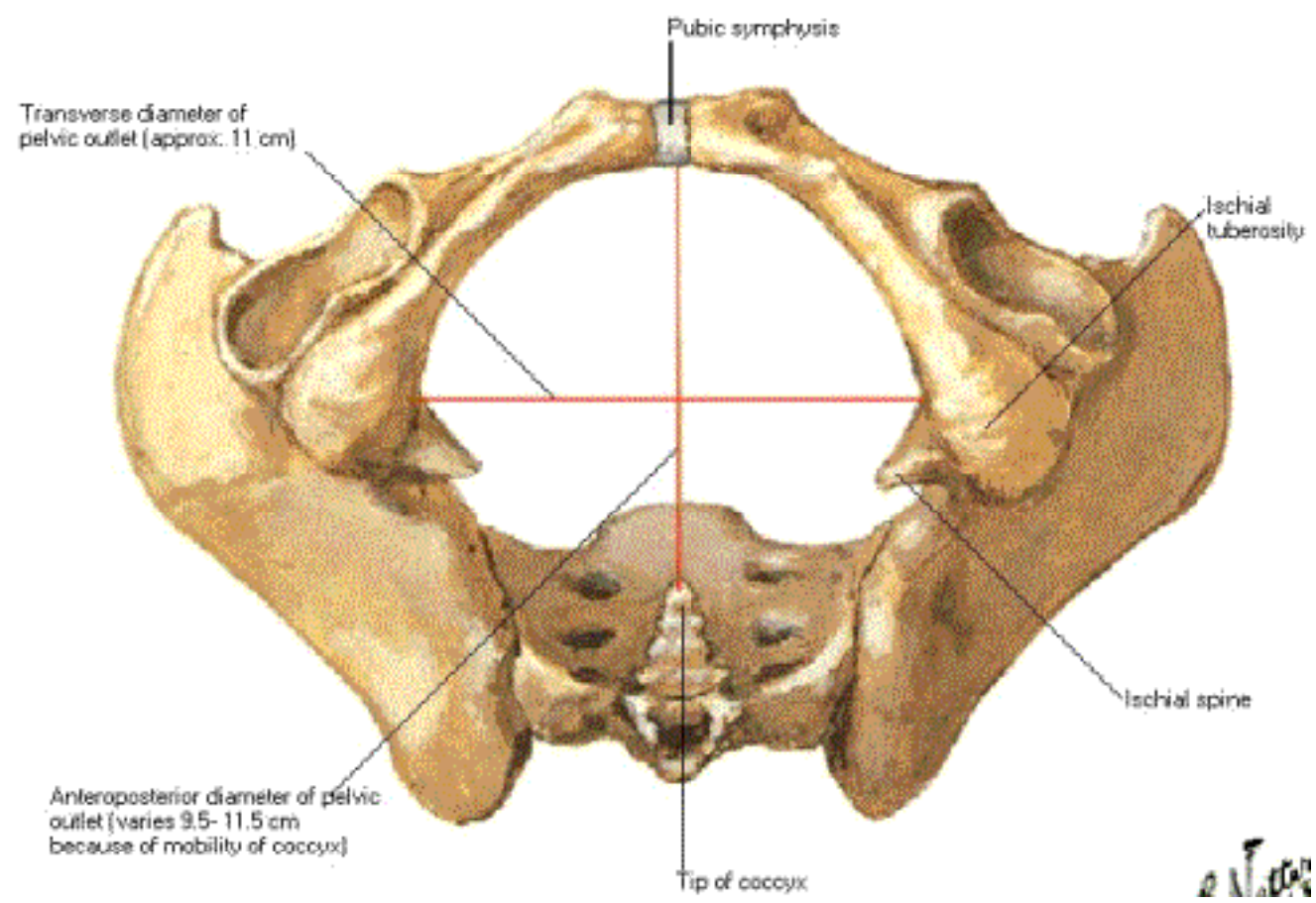
Male Pelvis

Measurements - Anterior View



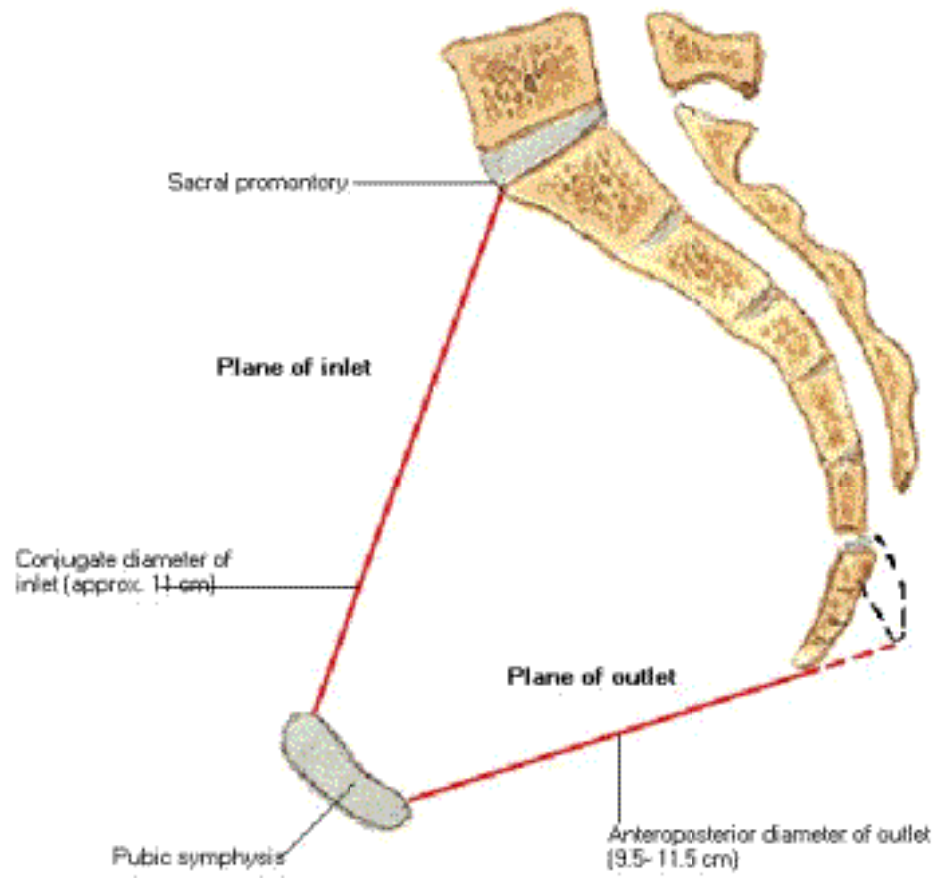
Female Pelvis

Measurements - Inferior View



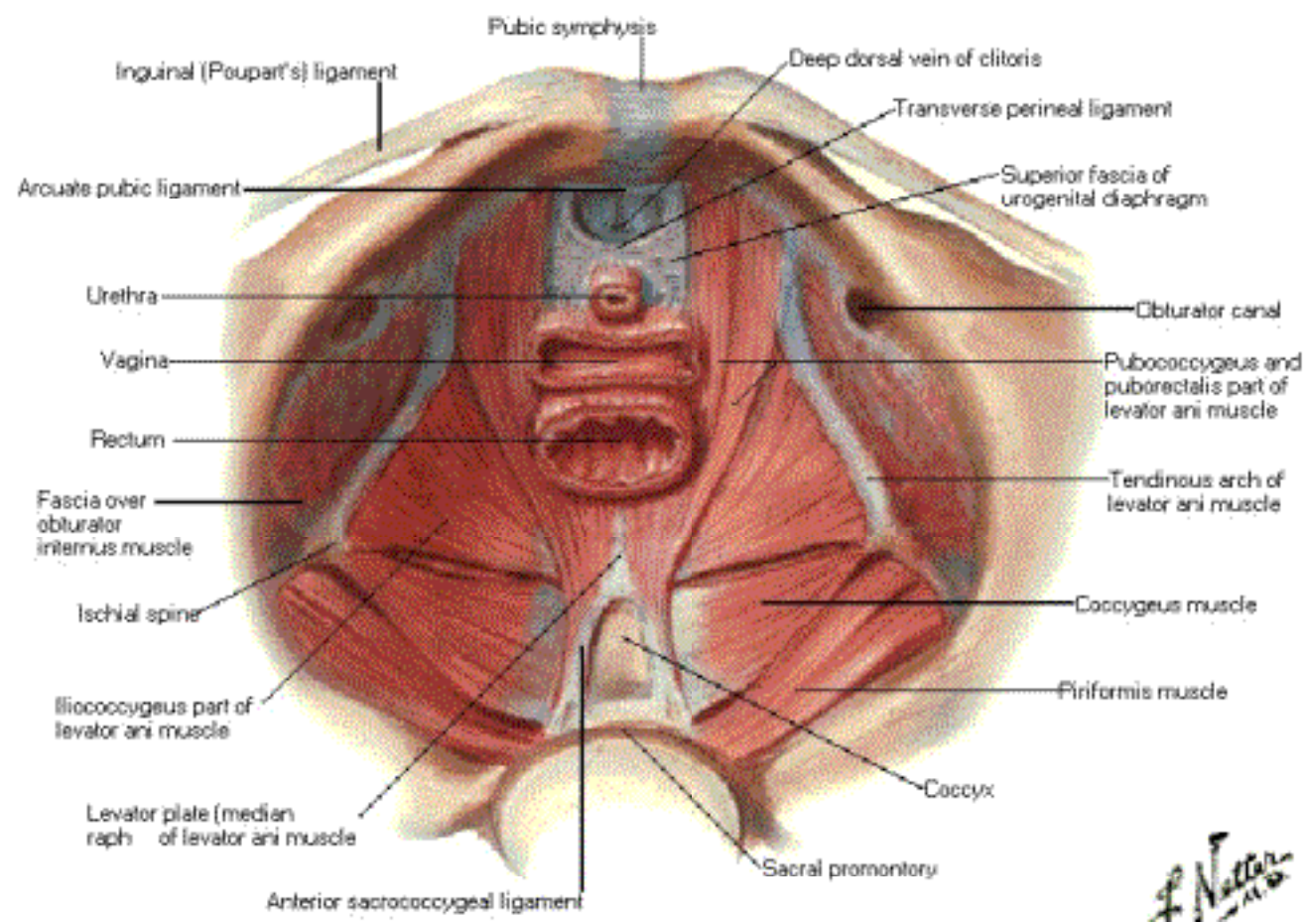
Female Pelvis

Measurements - Sagittal Section



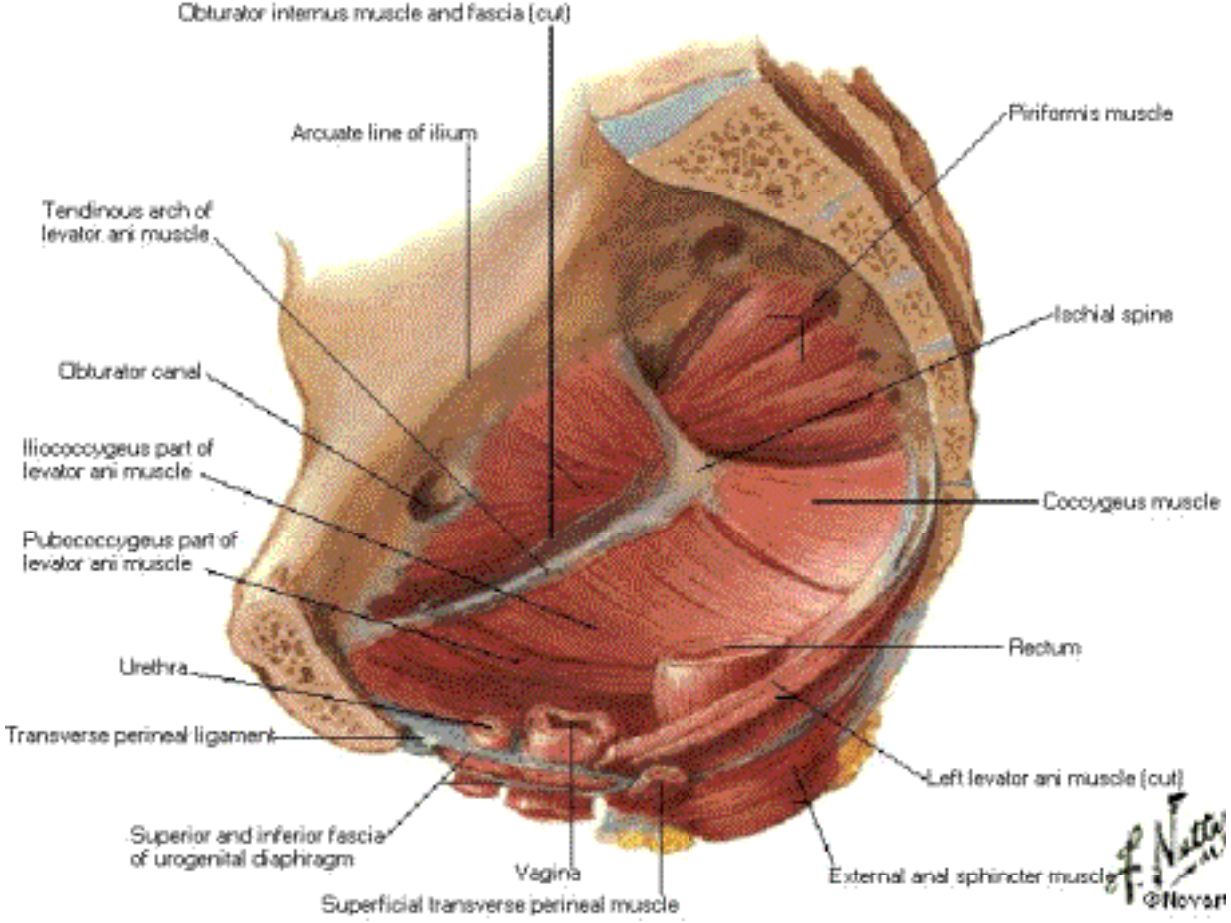
Pelvic Diaphragm of Female

Superior View

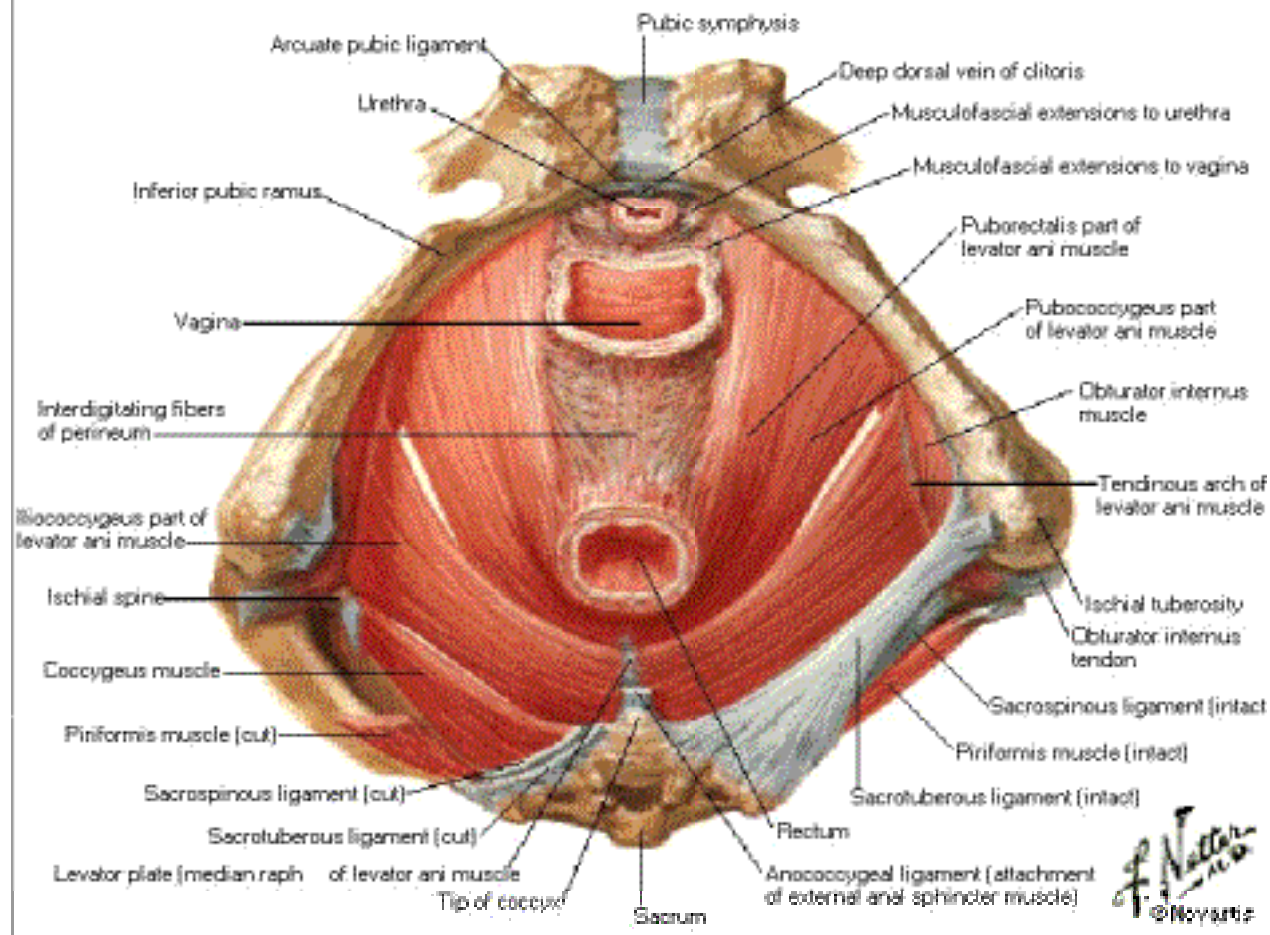


Pelvic Diaphragm of Female

Medial View

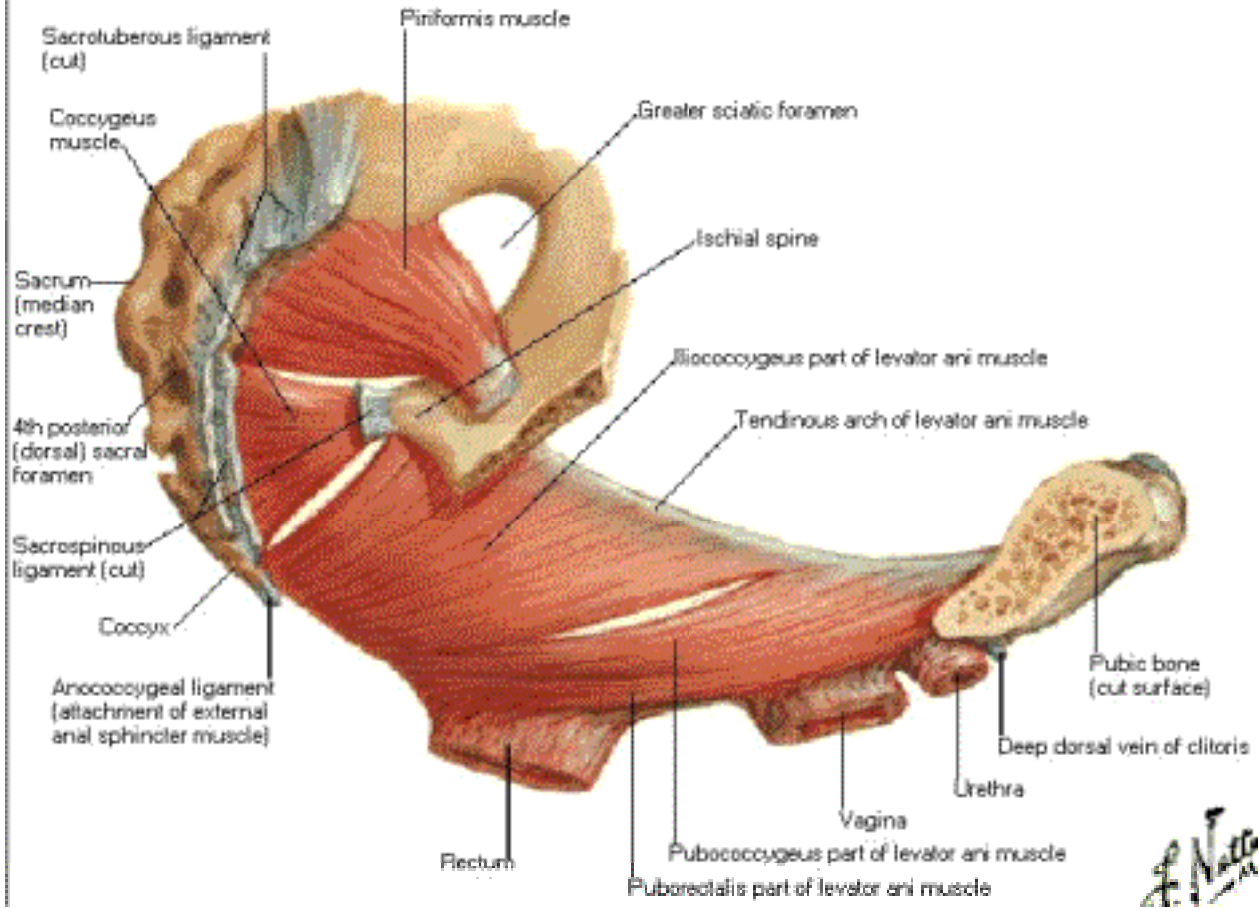


Pelvic Diaphragm of Female Inferior View



Pelvic Diaphragm of Female

Lateral View



Sacrotuberous ligament (cut)

Piniformis muscle

Coccygeus muscle

Greater sciatic foramen

Sacrum (median crest)

Ischial spine

4th posterior (dorsal) sacral foramen

Iliococcygeus part of levator ani muscle

Sacrospinous ligament (cut)

Tendinous arch of levator ani muscle

Coccyx

Anococcygeal ligament (attachment of external anal sphincter muscle)

Pubic bone (cut surface)

Rectum

Pubococcygeus part of levator ani muscle

Vagina

Urethra

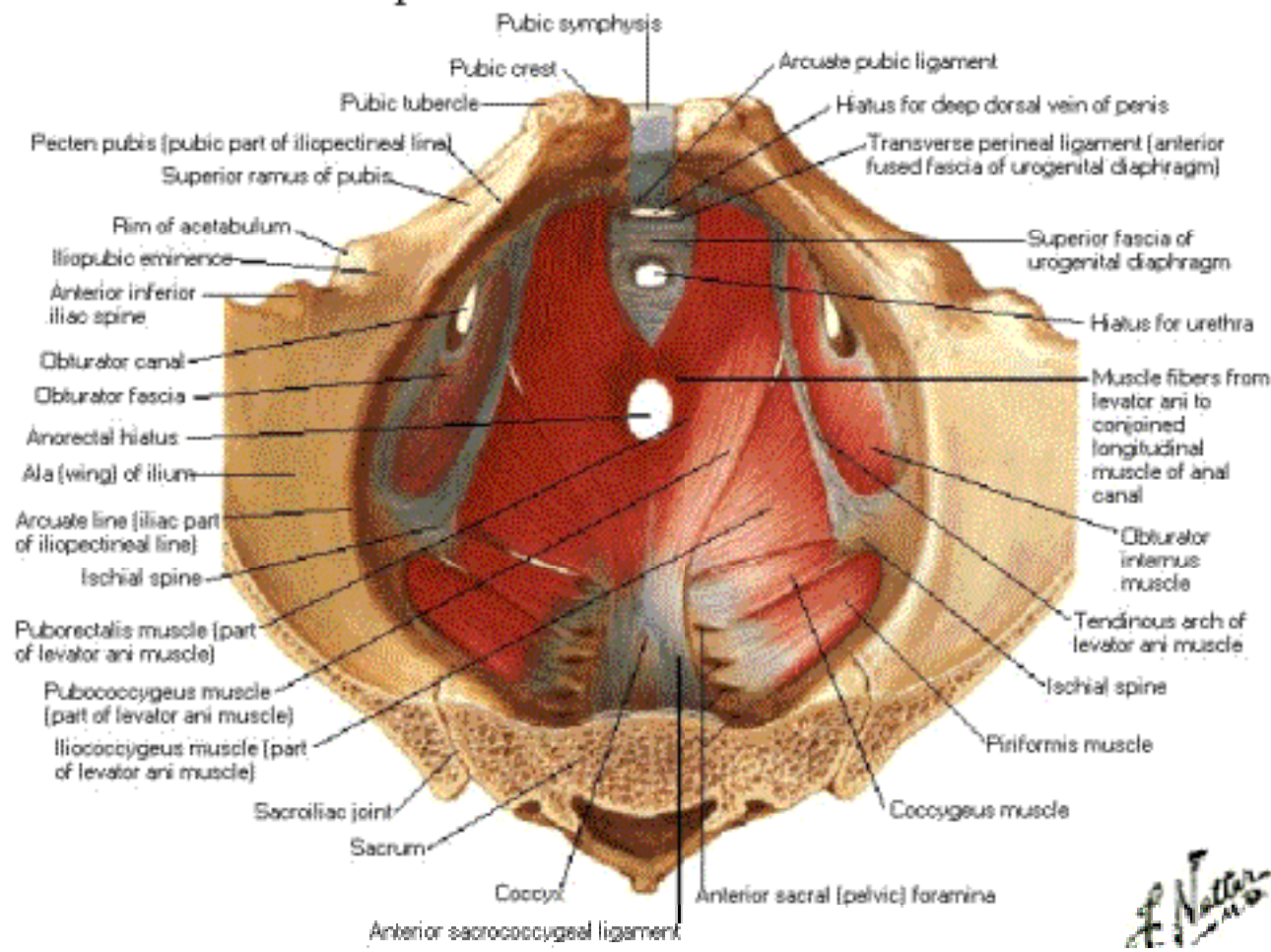
Deep dorsal vein of clitoris

Puborectalis part of levator ani muscle

F. Netter M.D.

Pelvic Diaphragm of Male

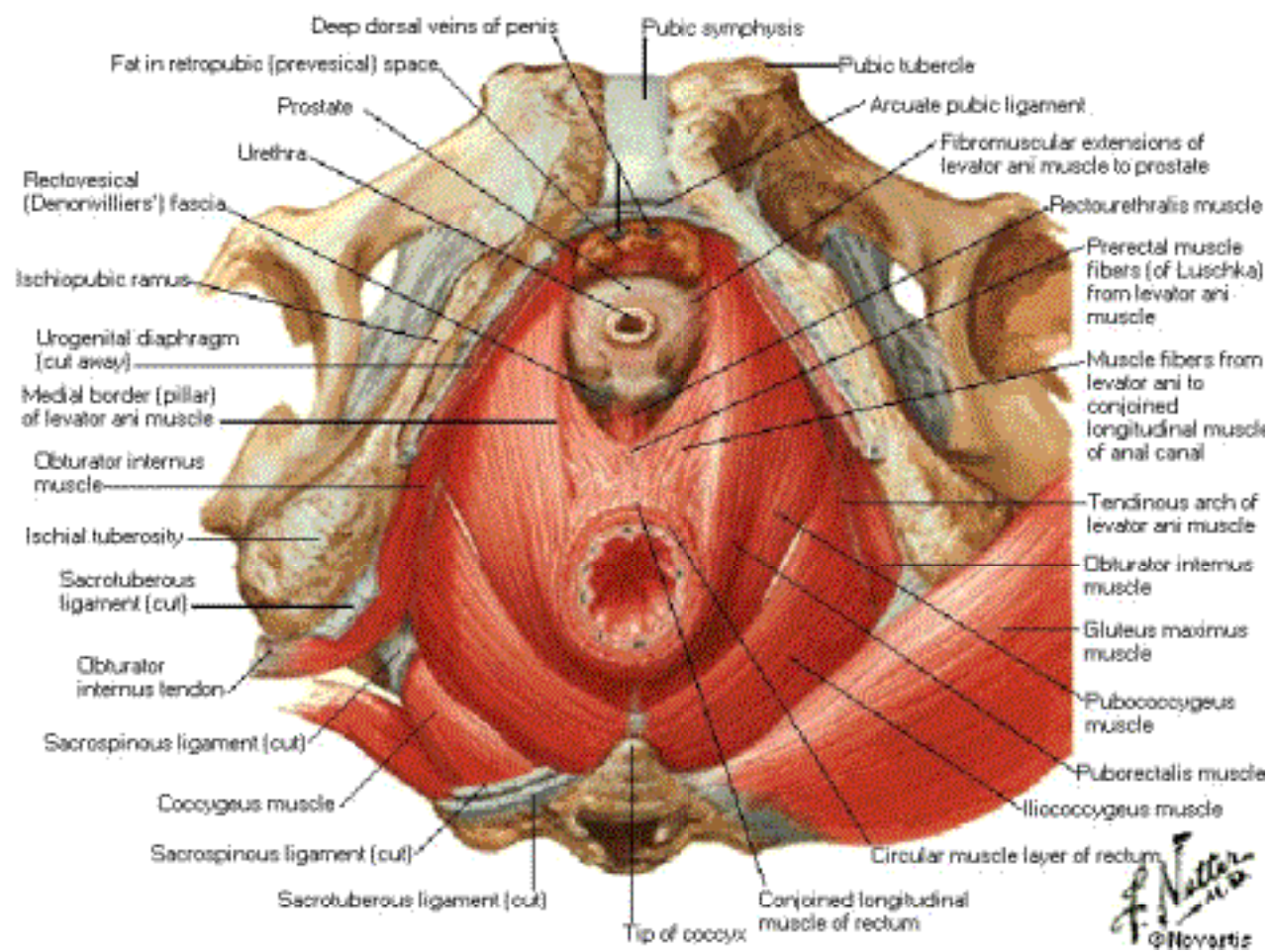
Superior View - Viscera Removed



F. Netter M.D.

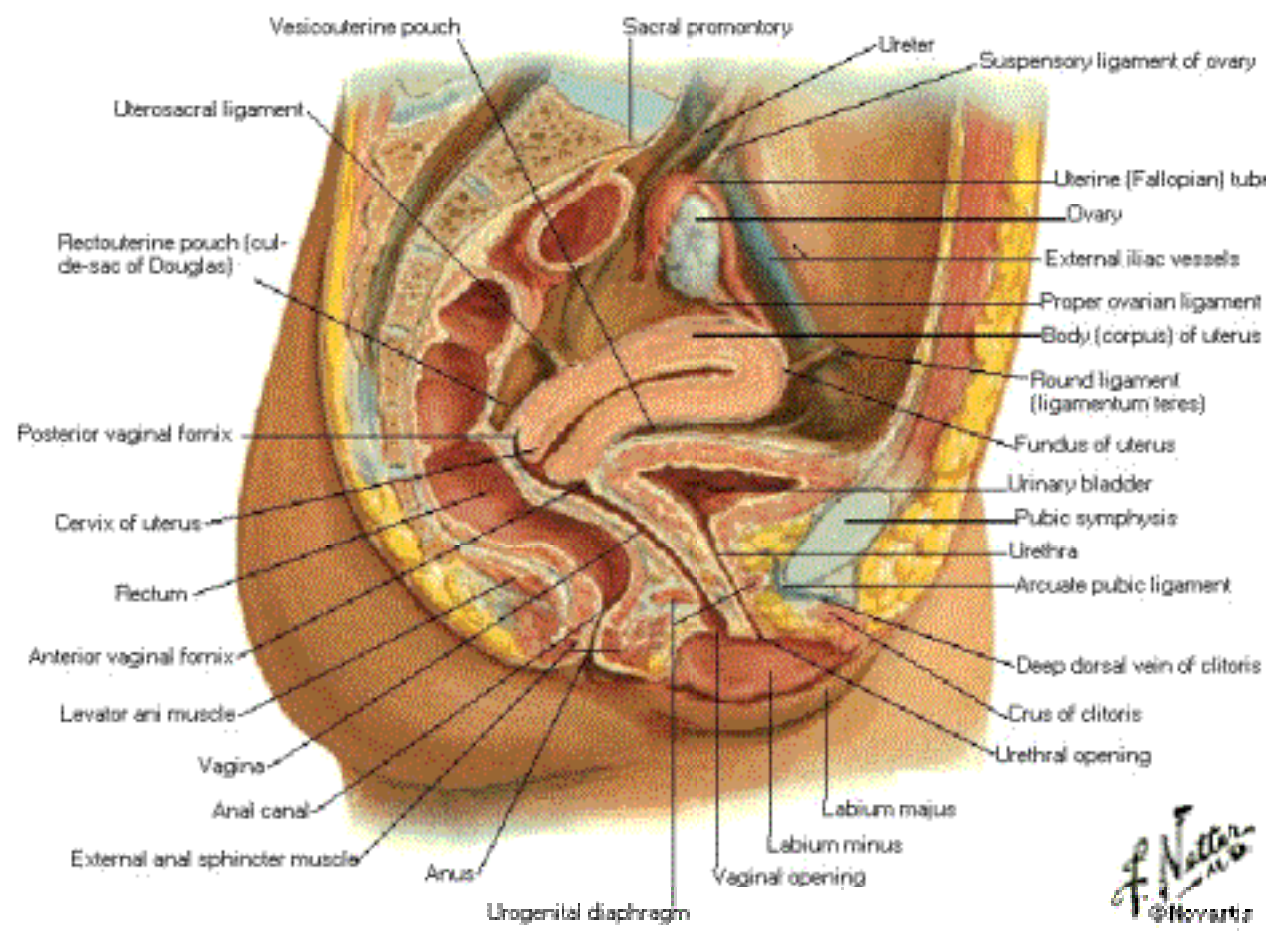
Pelvic Diaphragm of Male

Inferior View

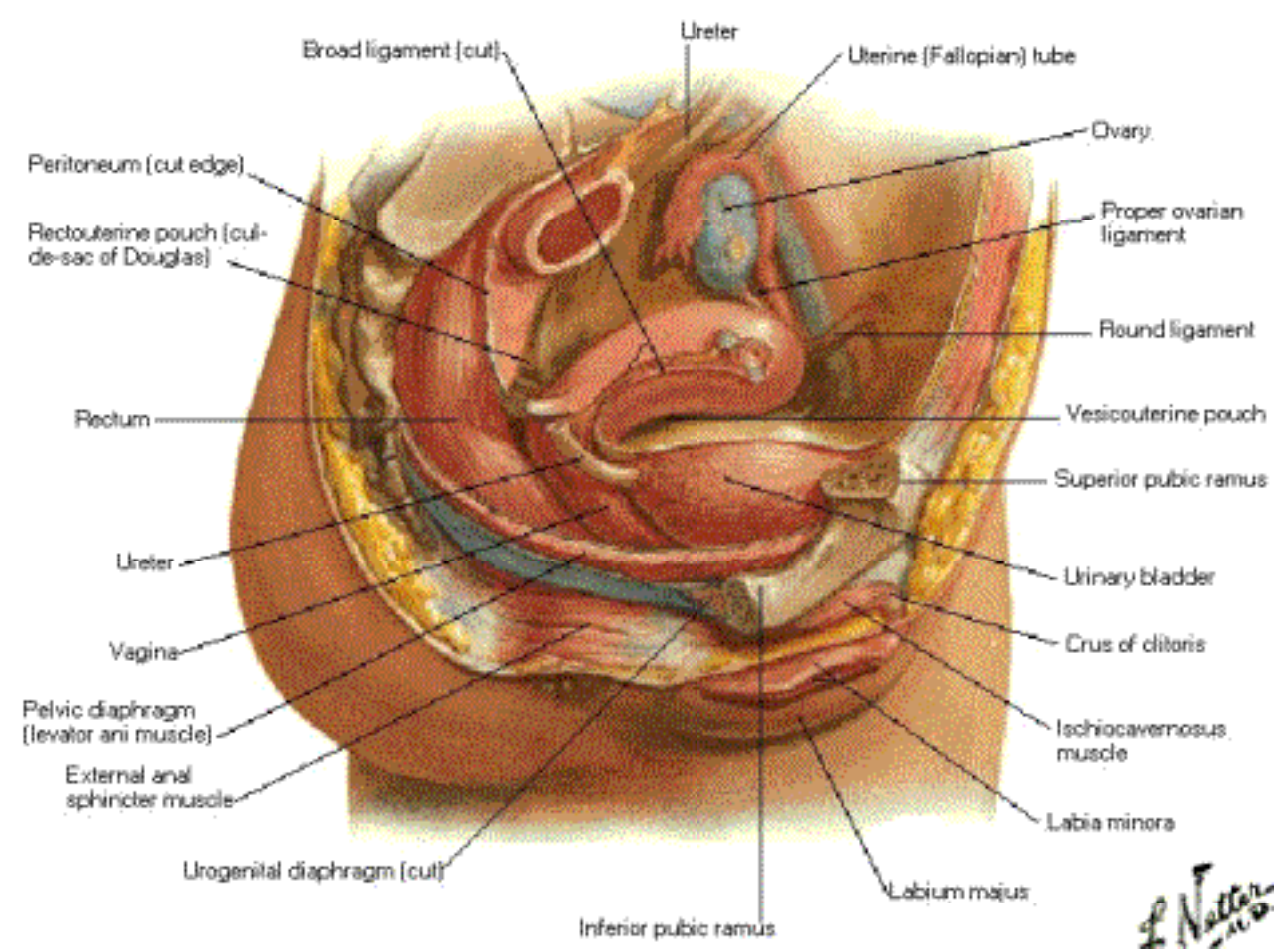


Pelvic Viscera and Perineum of Female

Midsagittal Section

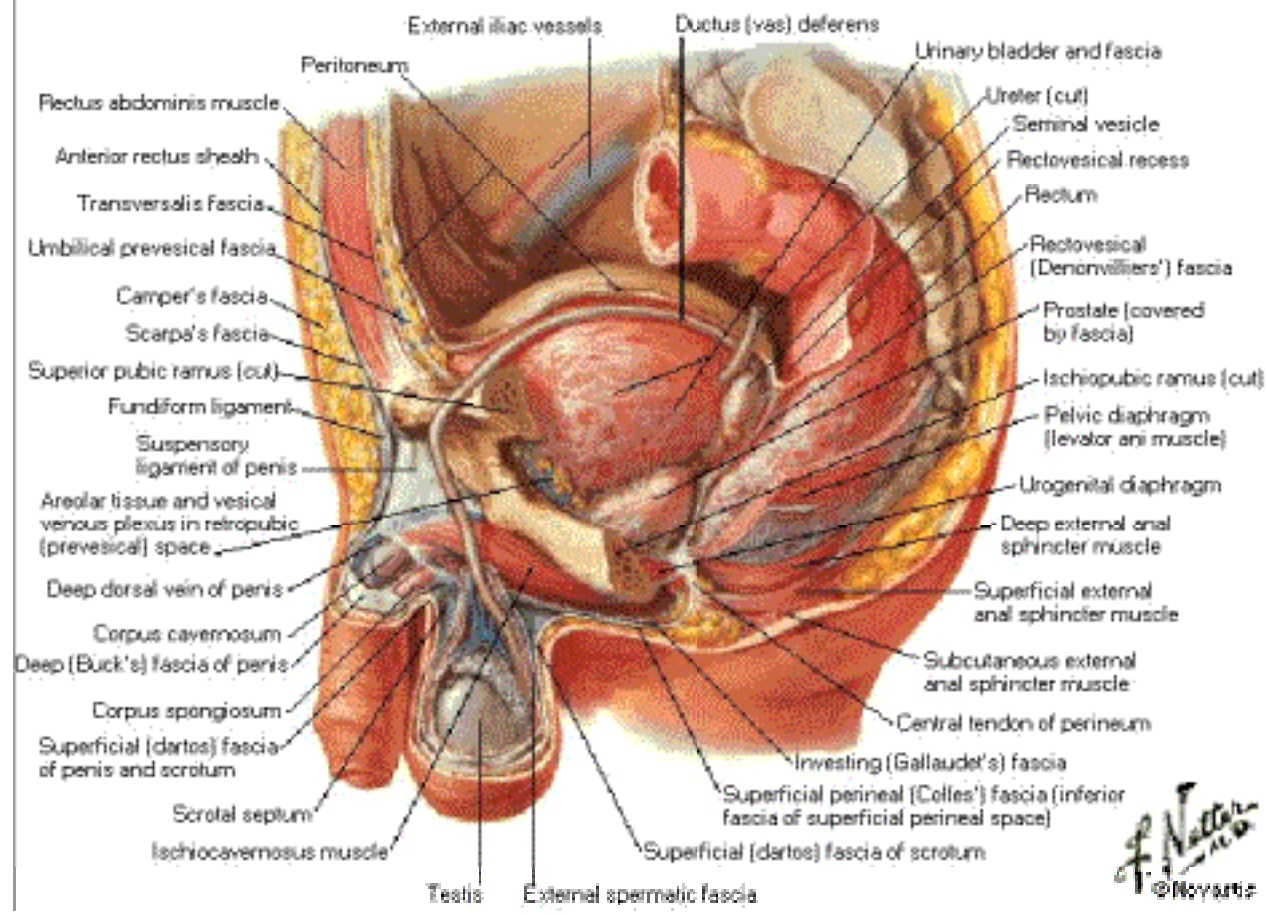


Pelvic Viscera and Perineum of Female Paramedian Sagittal Section



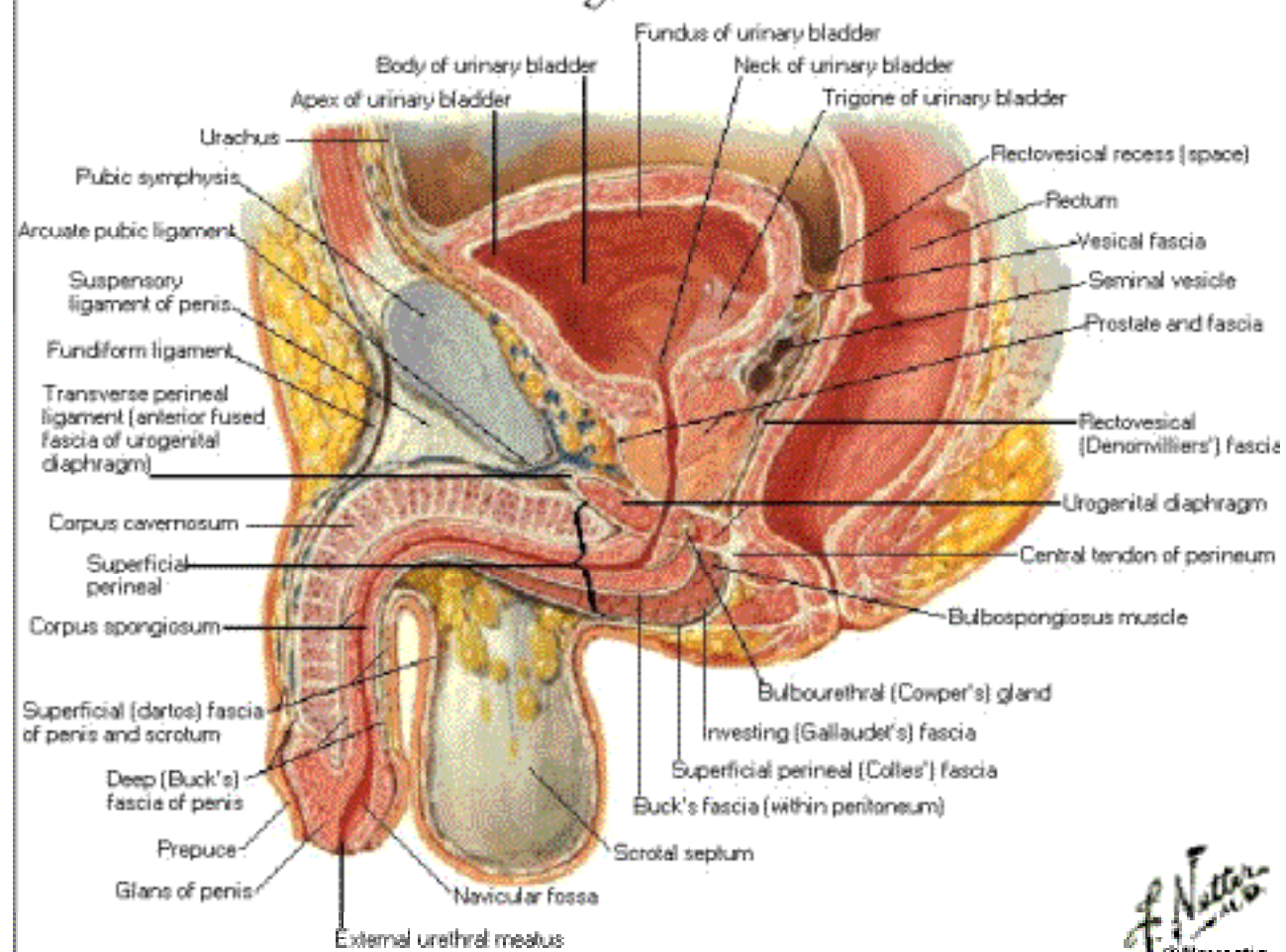
Pelvic Viscera and Perineum of Male

Paramedian Sagittal Section



Pelvic Viscera and Perineum of Male

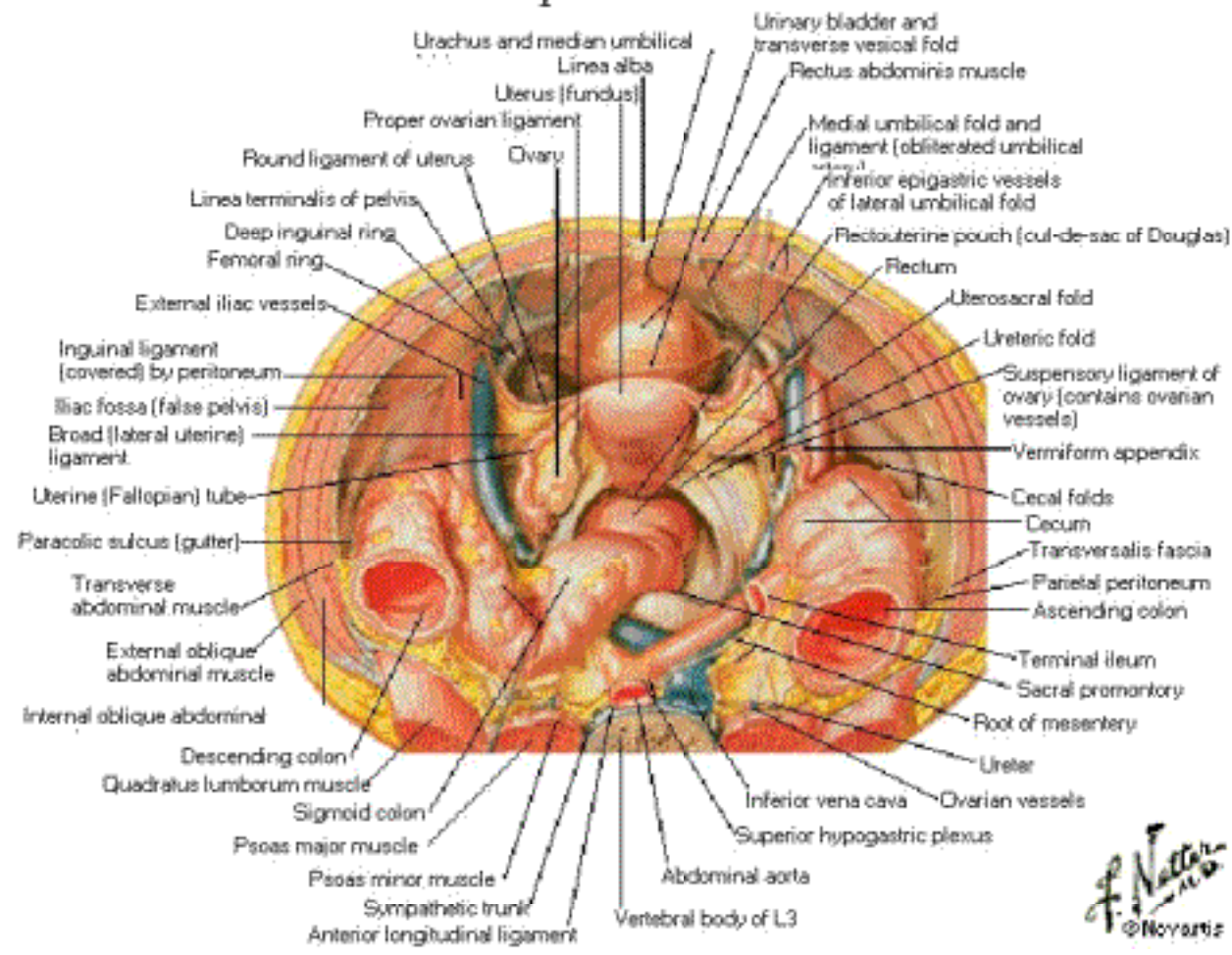
Midsagittal Section



F. Netter M.D.

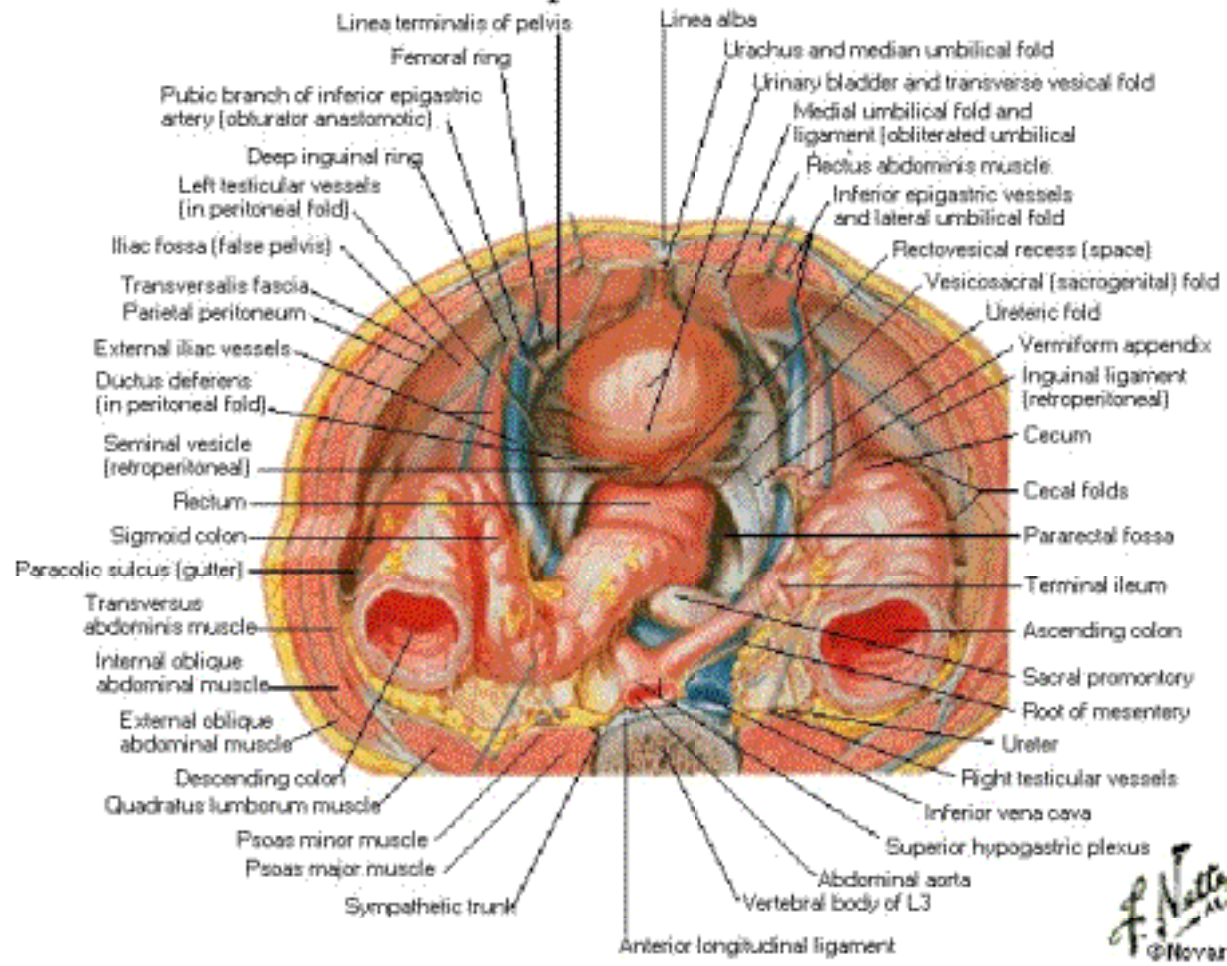
Pelvic Contents of Female

Superior View



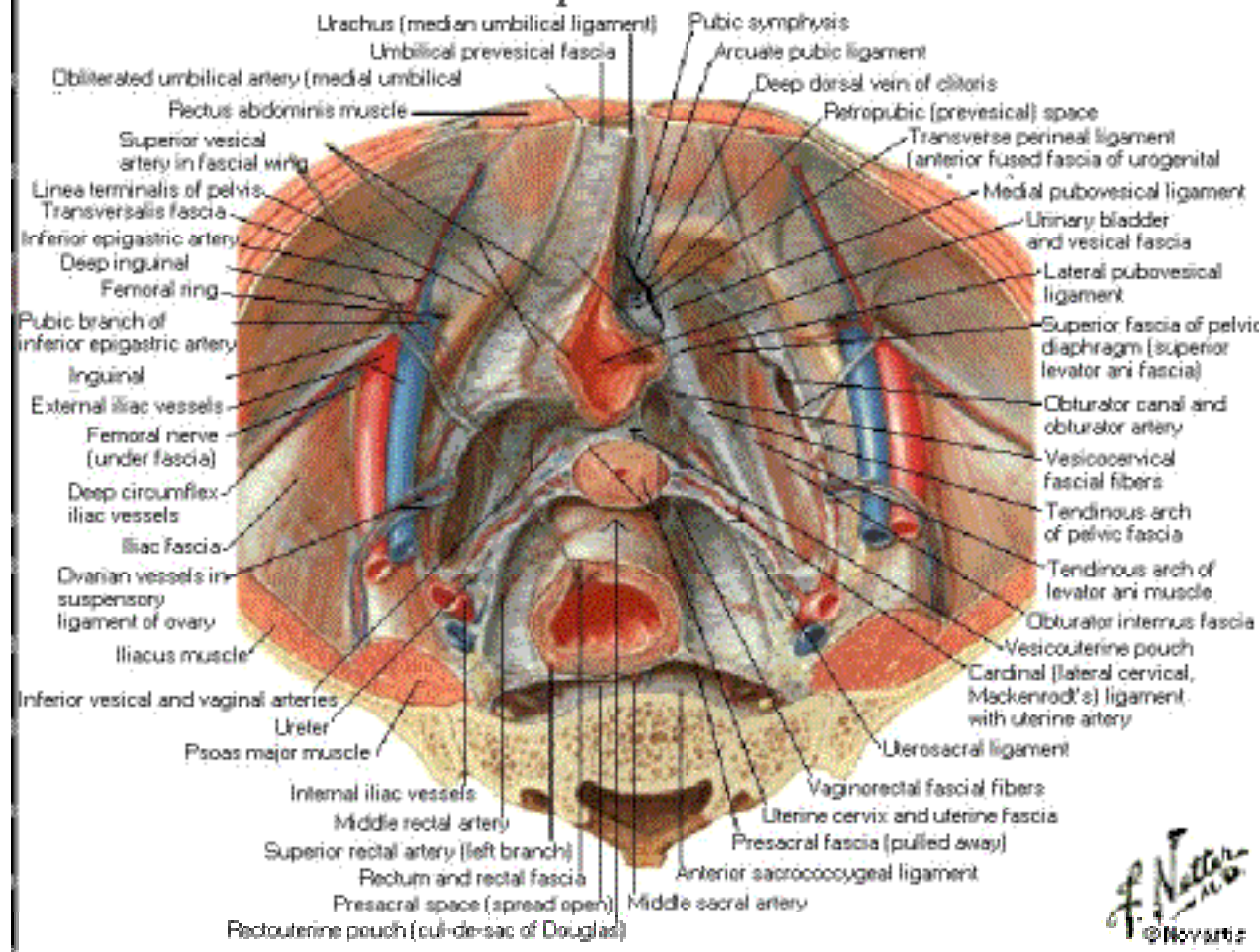
Pelvic Contents of Male

Superior View



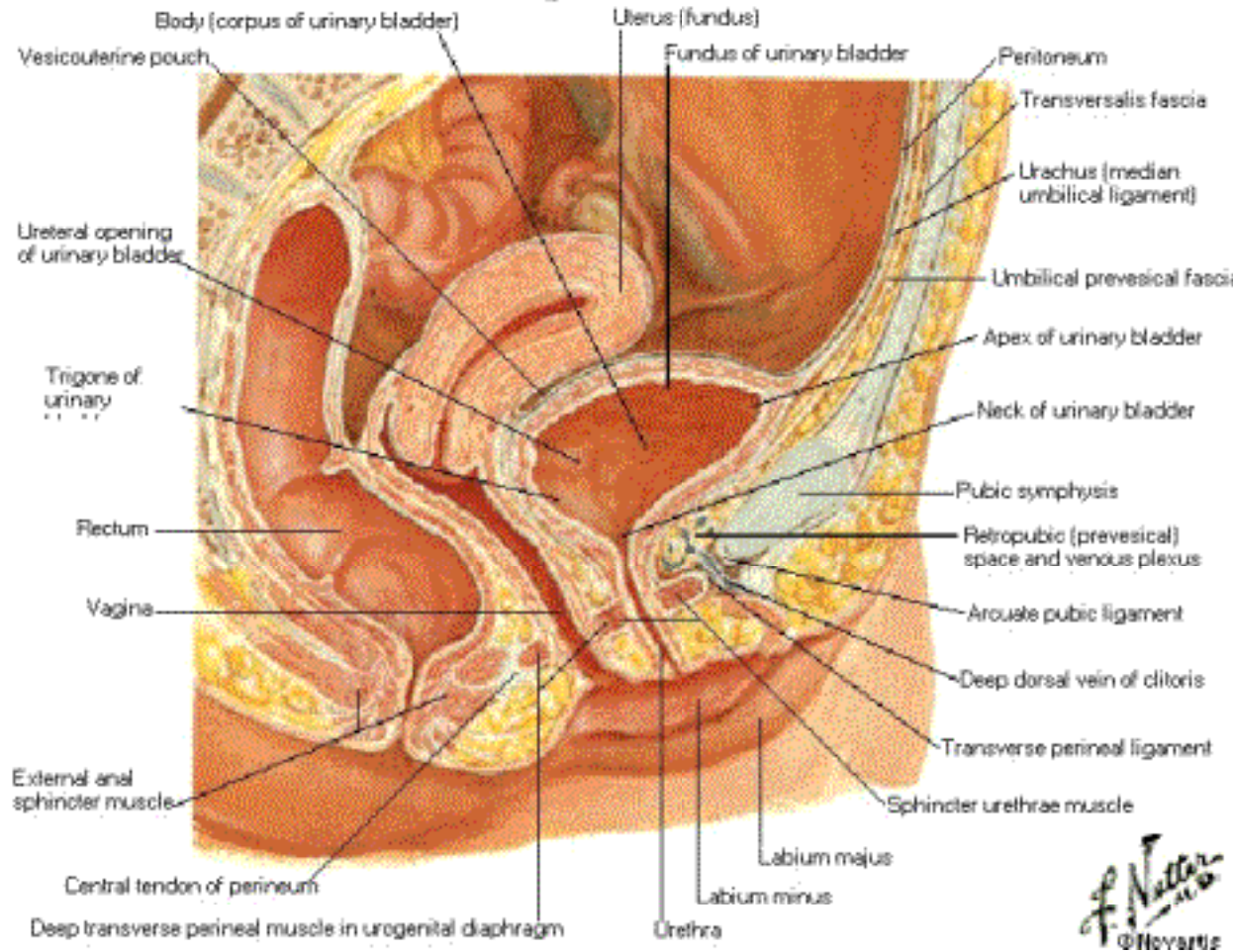
Endopelvic Fascia and Spaces of Female

Superior View



Urinary Bladder - Orientation and Supports

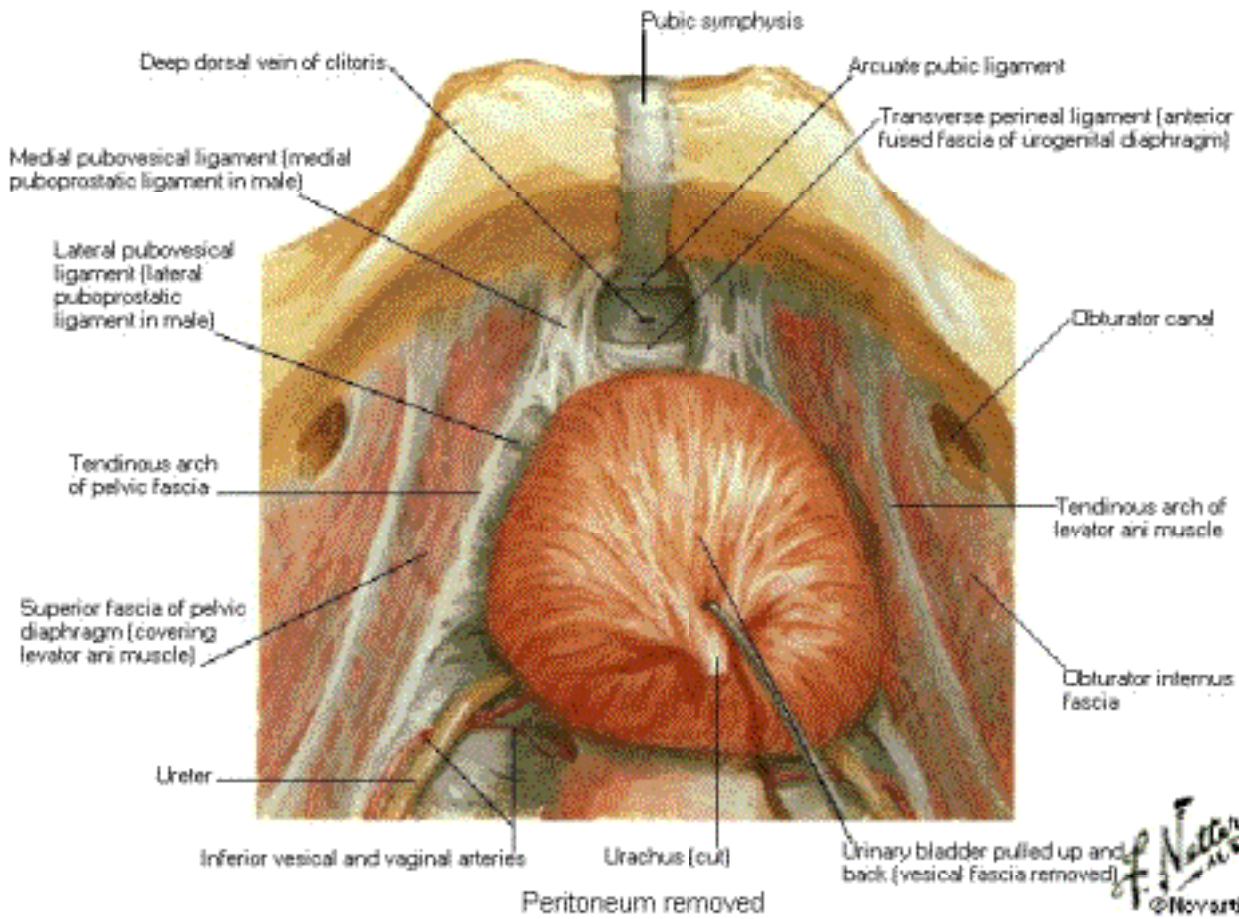
Midsagittal Section



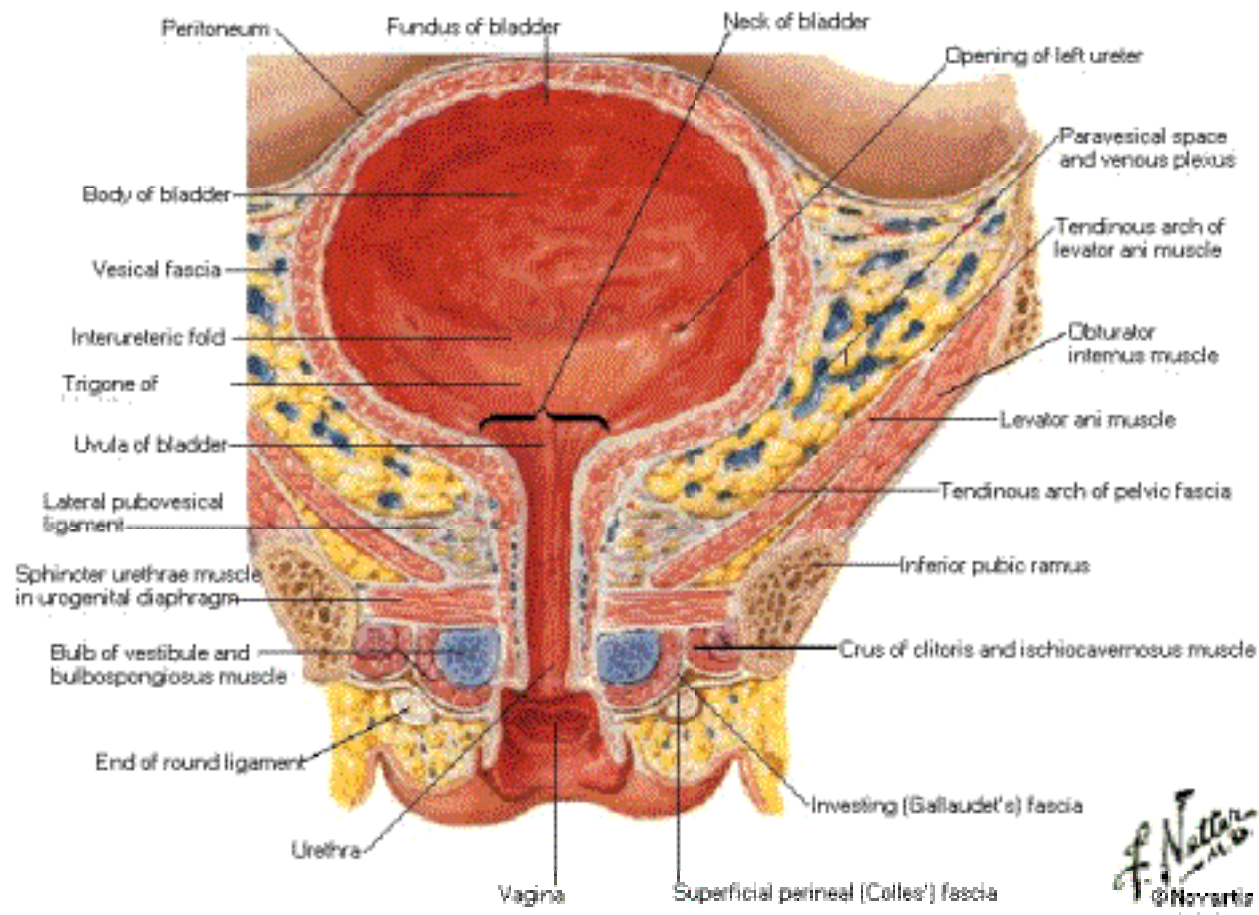
F. Netter M.D.
© Novartis

Urinary Bladder - Orientation and Supports

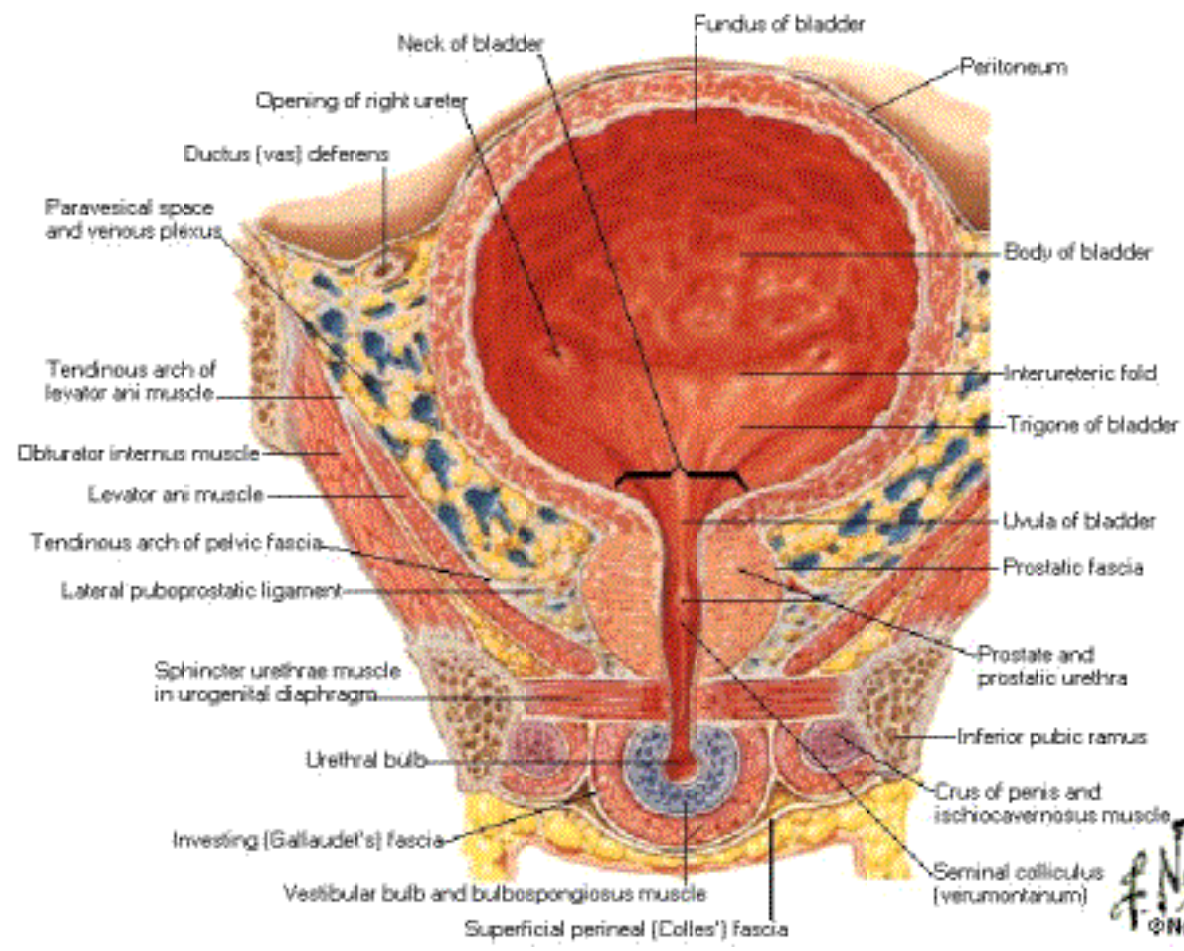
Superior View



Urinary Bladder of Female Frontal Section

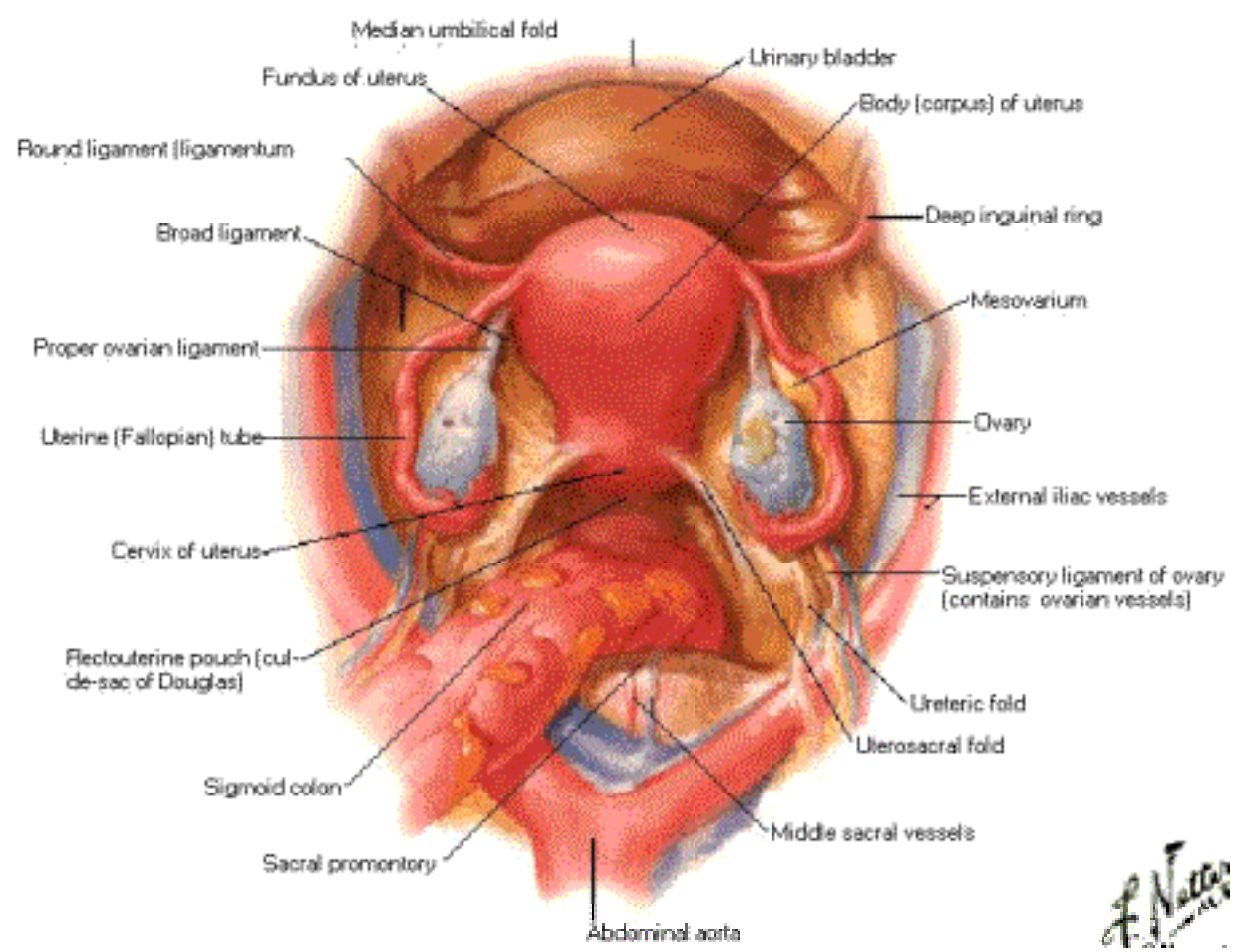


Urinary Bladder of Male Frontal Section



Pelvic Viscera of Female

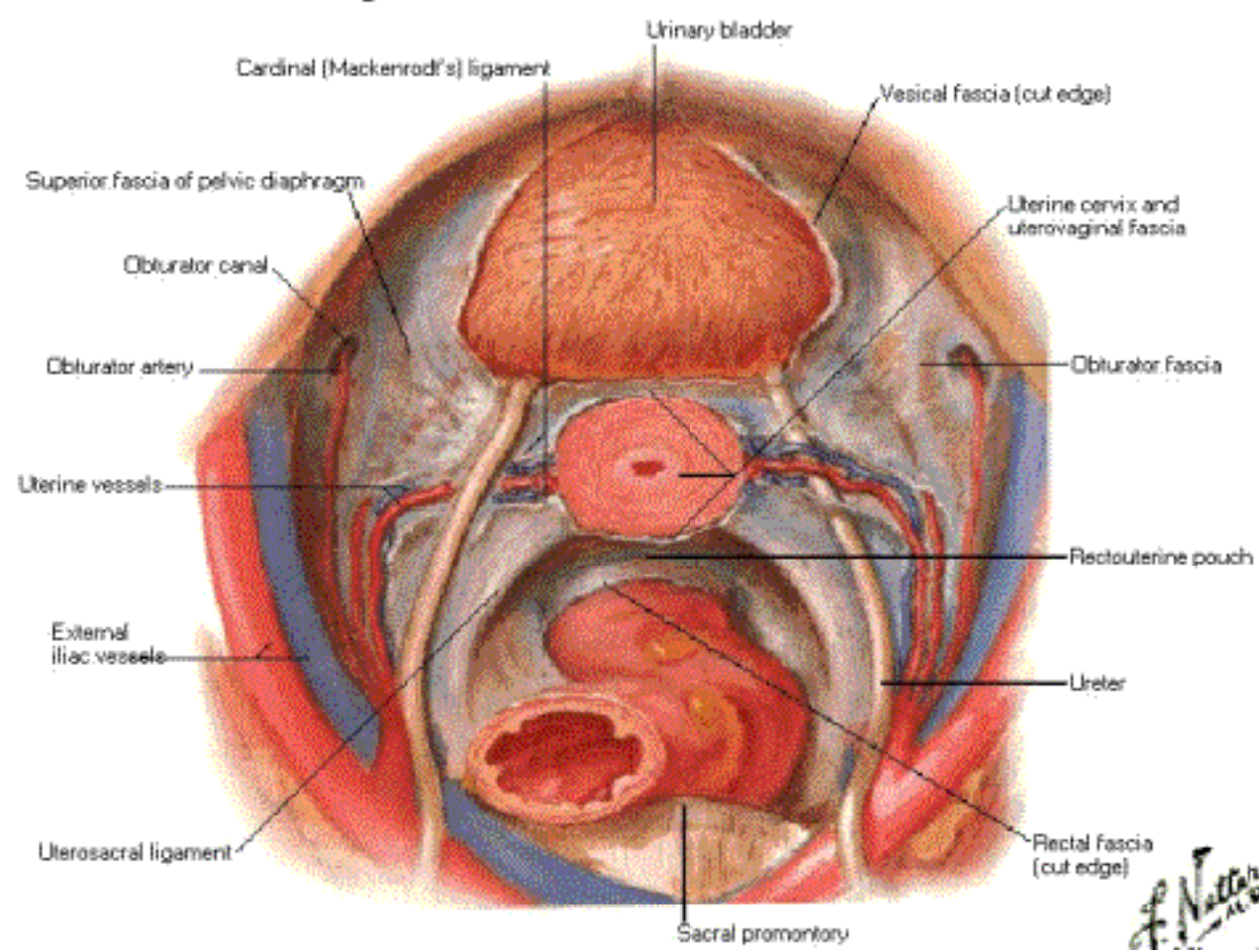
Superior View - Peritoneum Intact



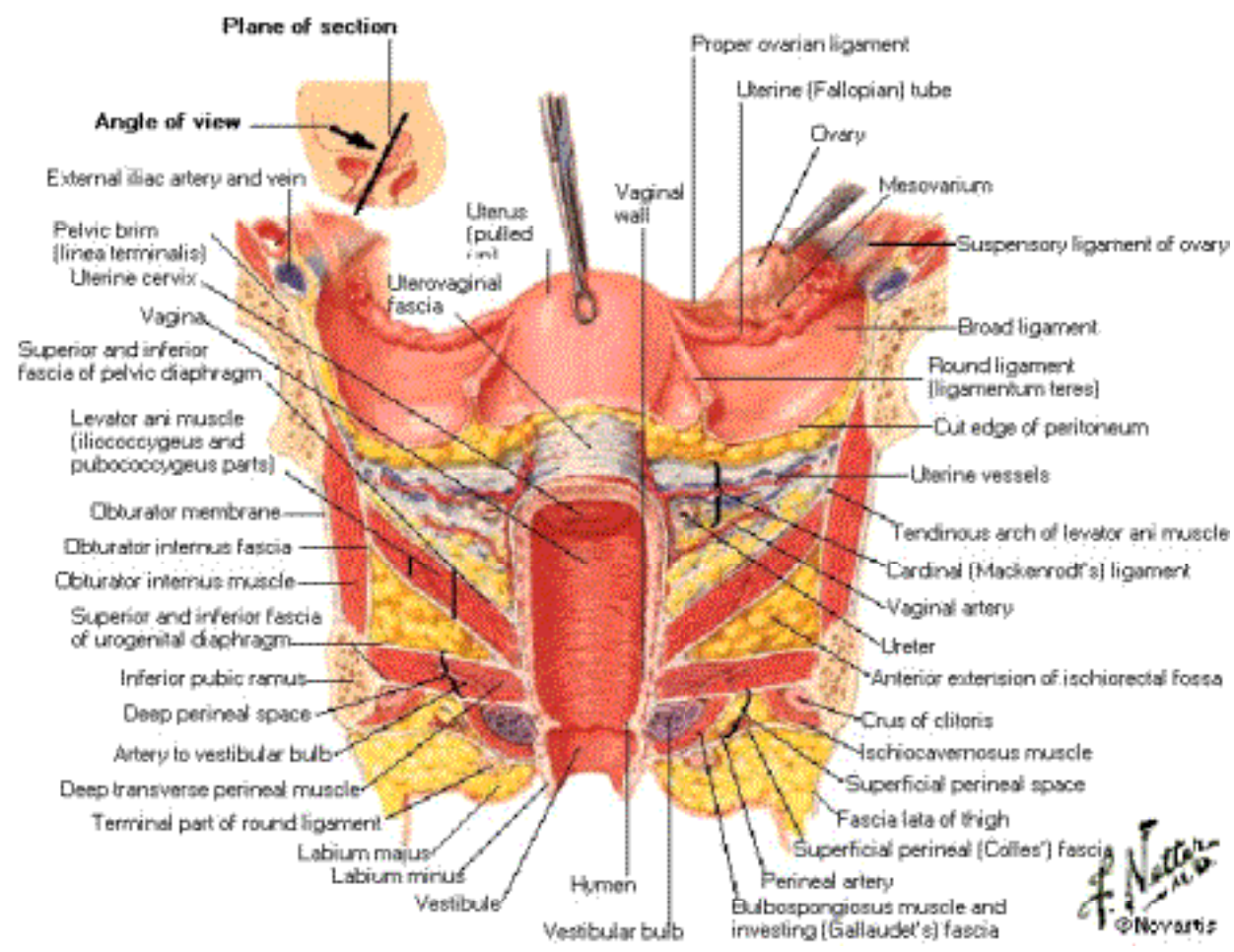
F. Netter

Pelvic Viscera of Female

Superior View - Peritoneum Removed

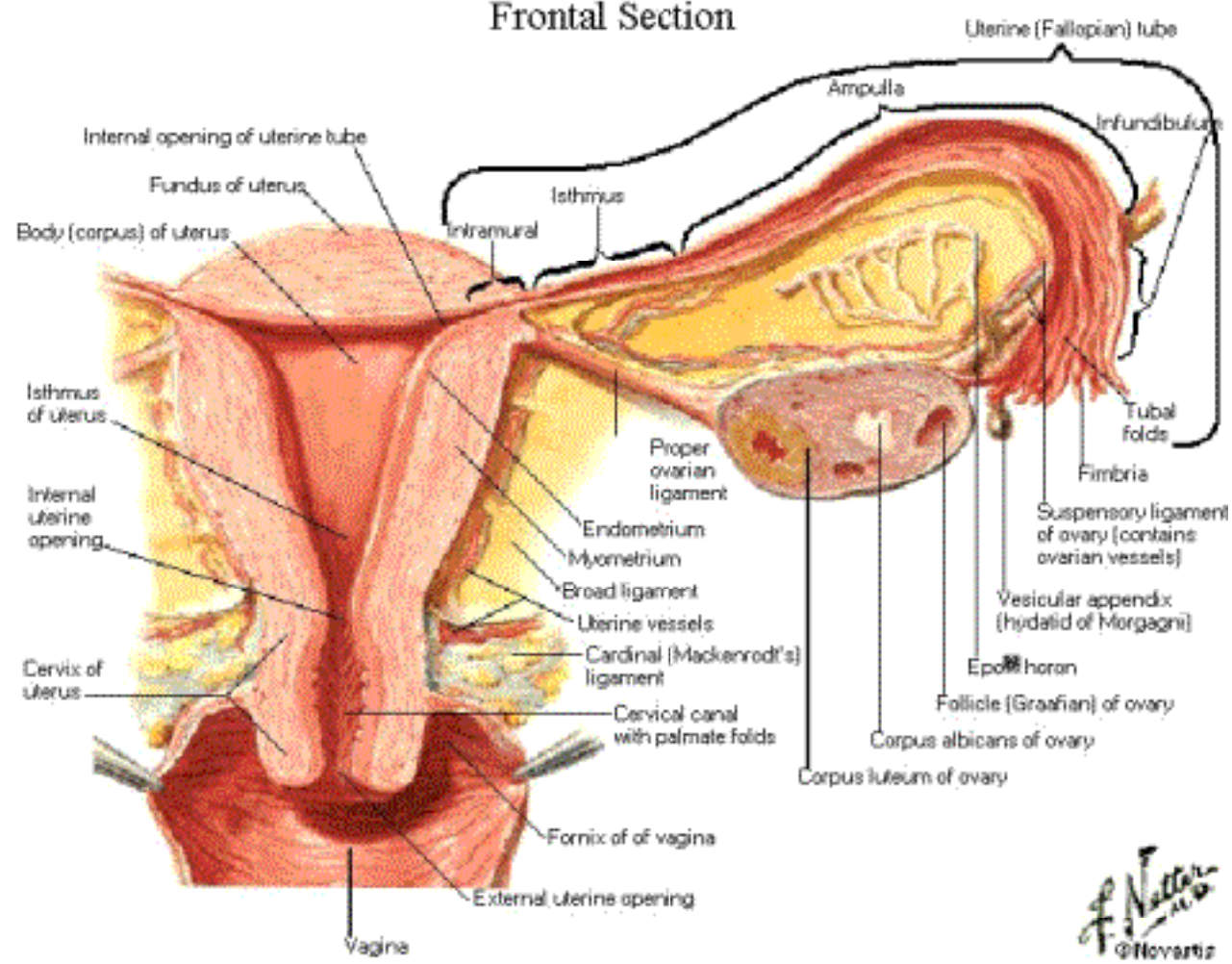


Uterus, Vagina and Supporting Structures



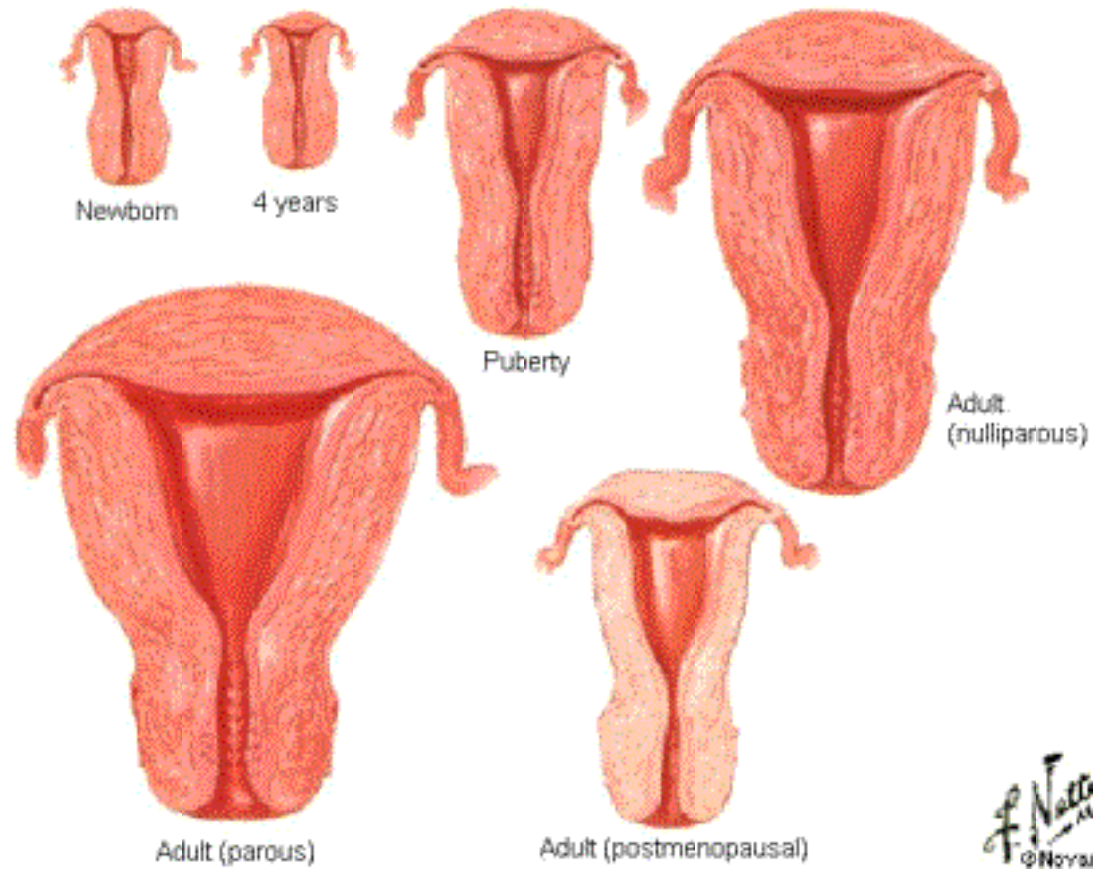
Uterus and Adnexa

Frontal Section



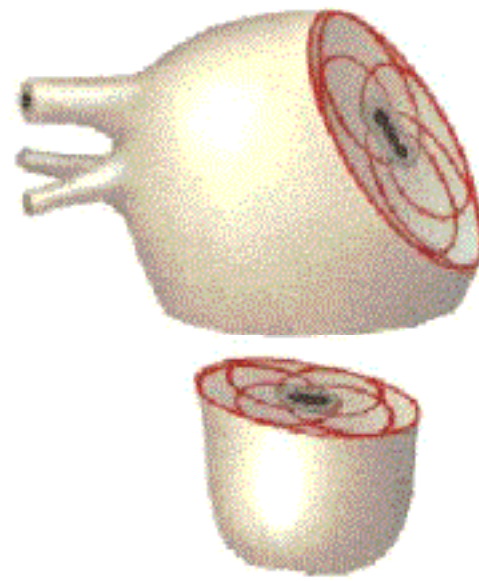
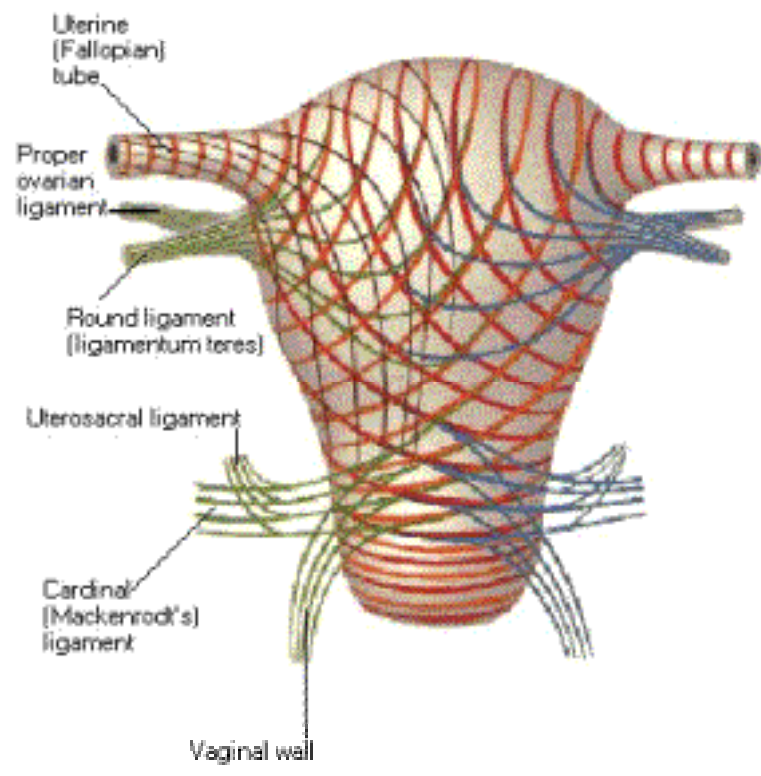
Uterus

Changes with Age



Uterus

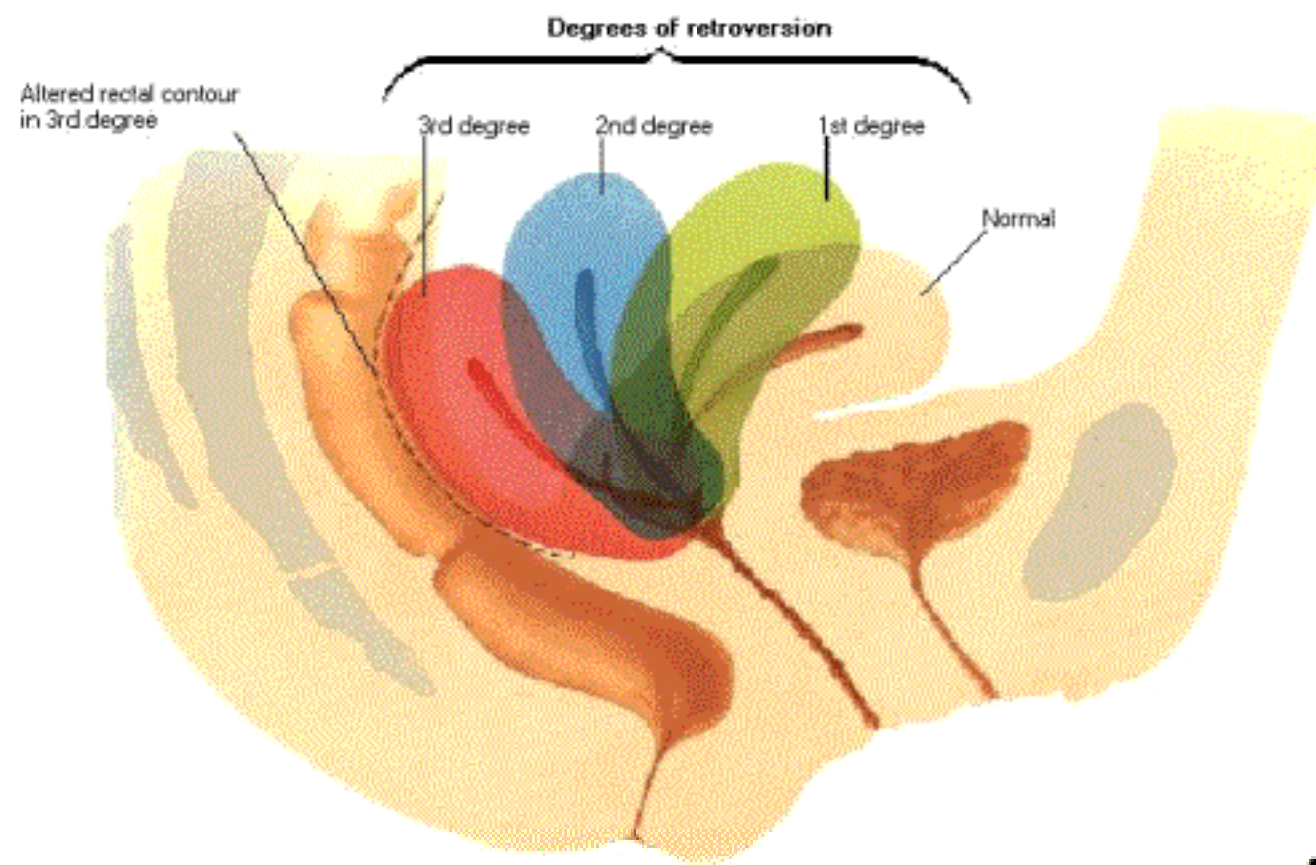
Schema of Musculature



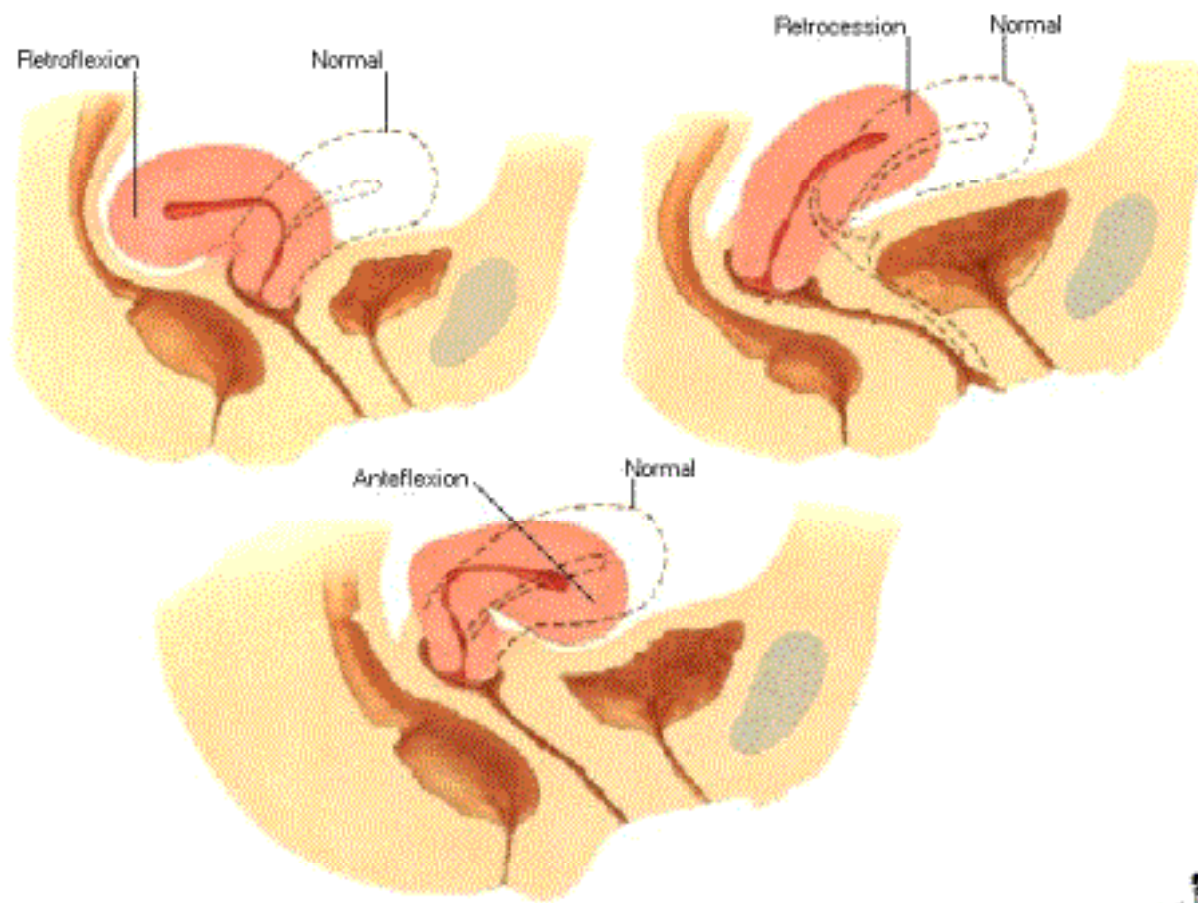
Spiral fibers pass deeply into wall and interface (schema)

Uterus

Variations in Position

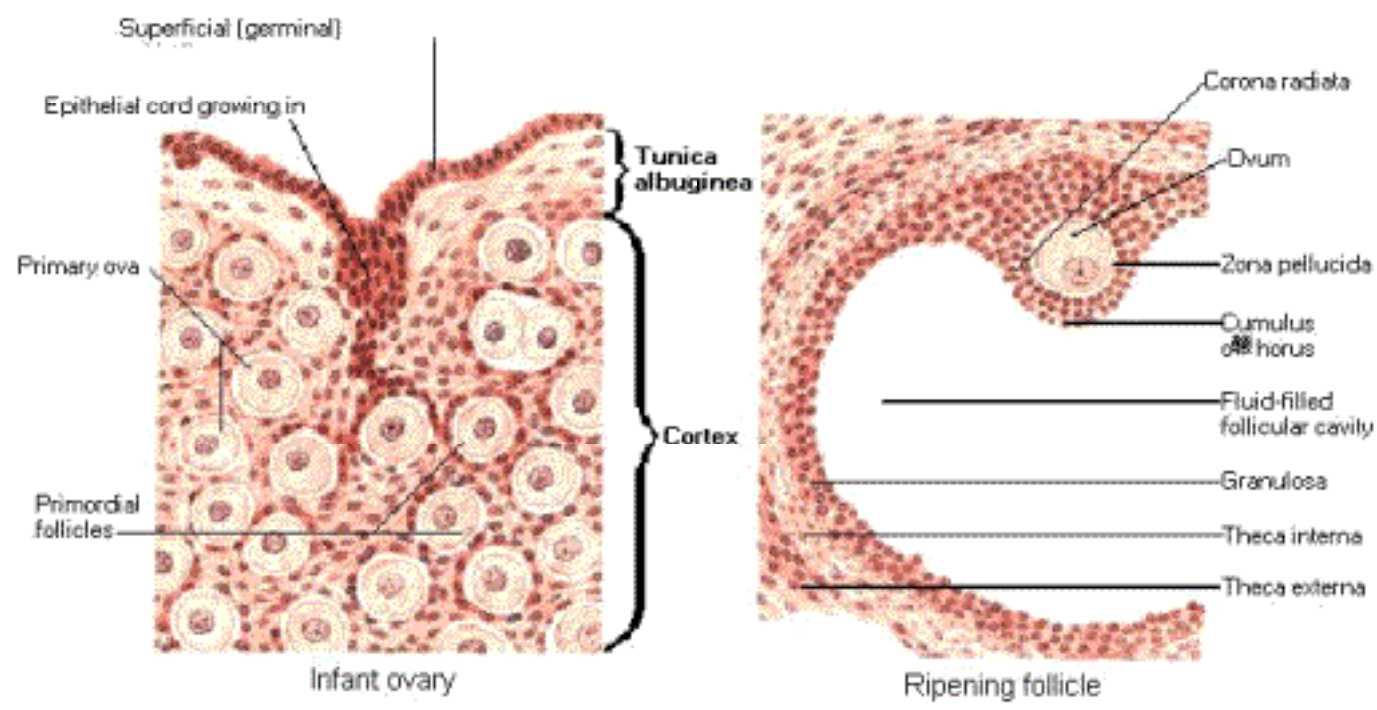


Uterus [Continued] Variations in Position

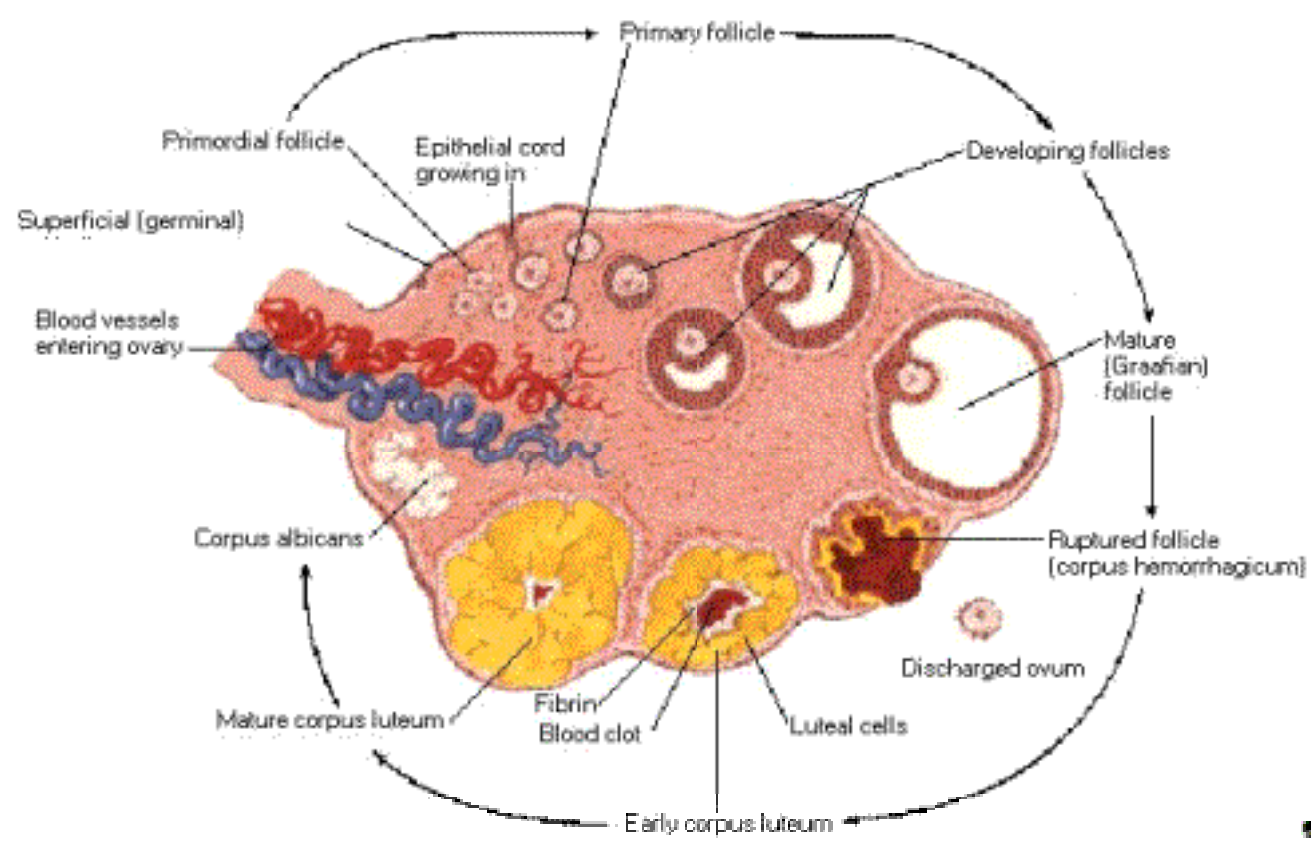


Infant Ovary and Ripening Follicle

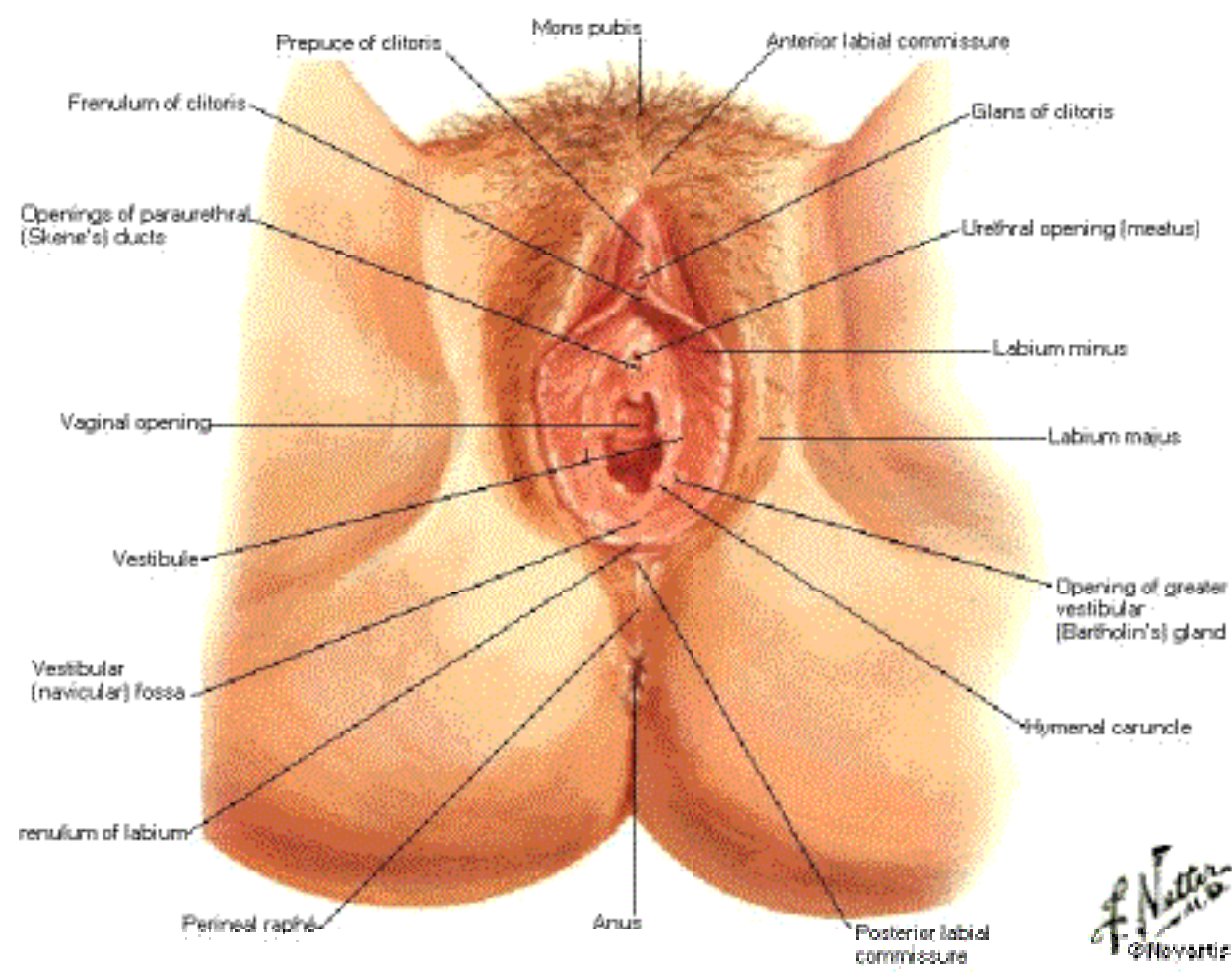
Histology



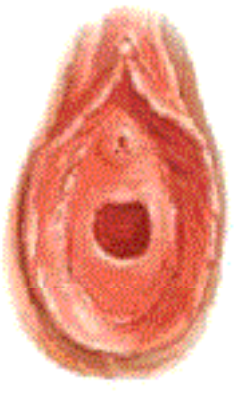Stages of Ovum and Follicle



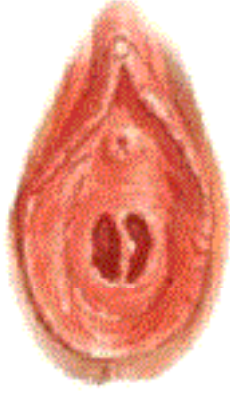Perineum and External Genitalia of Female



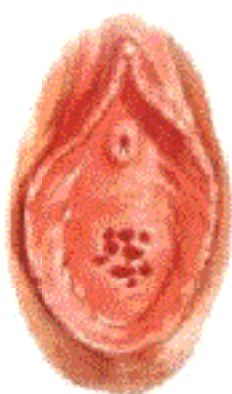Perineum and External Genitalia of Female [Continued]



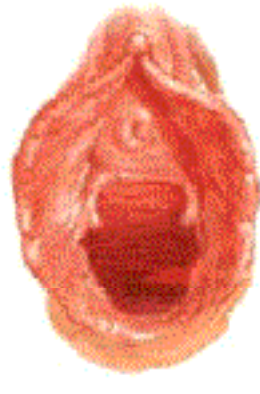Annular hymen



Septate hymen



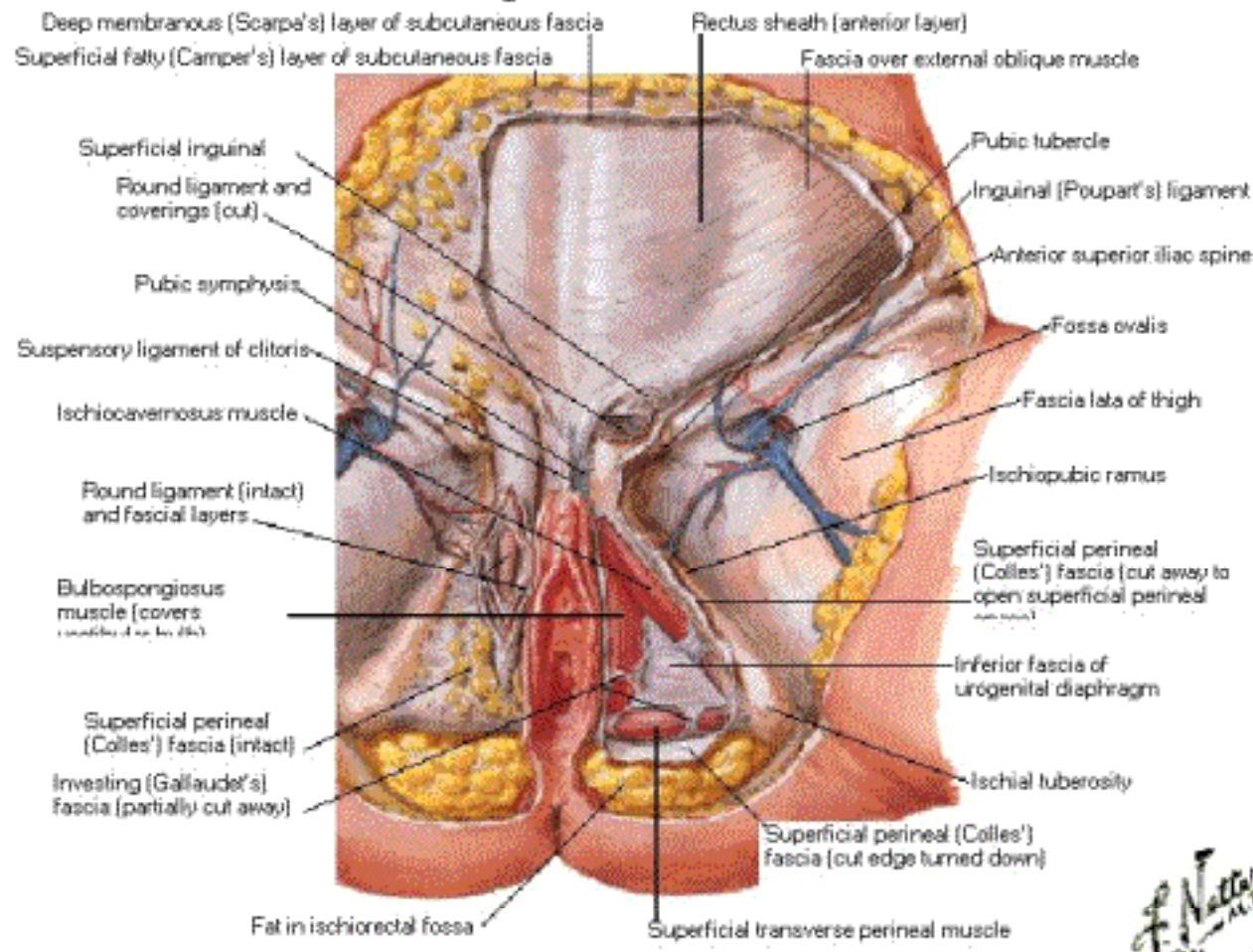
Cribriform hymen



Parous introitus

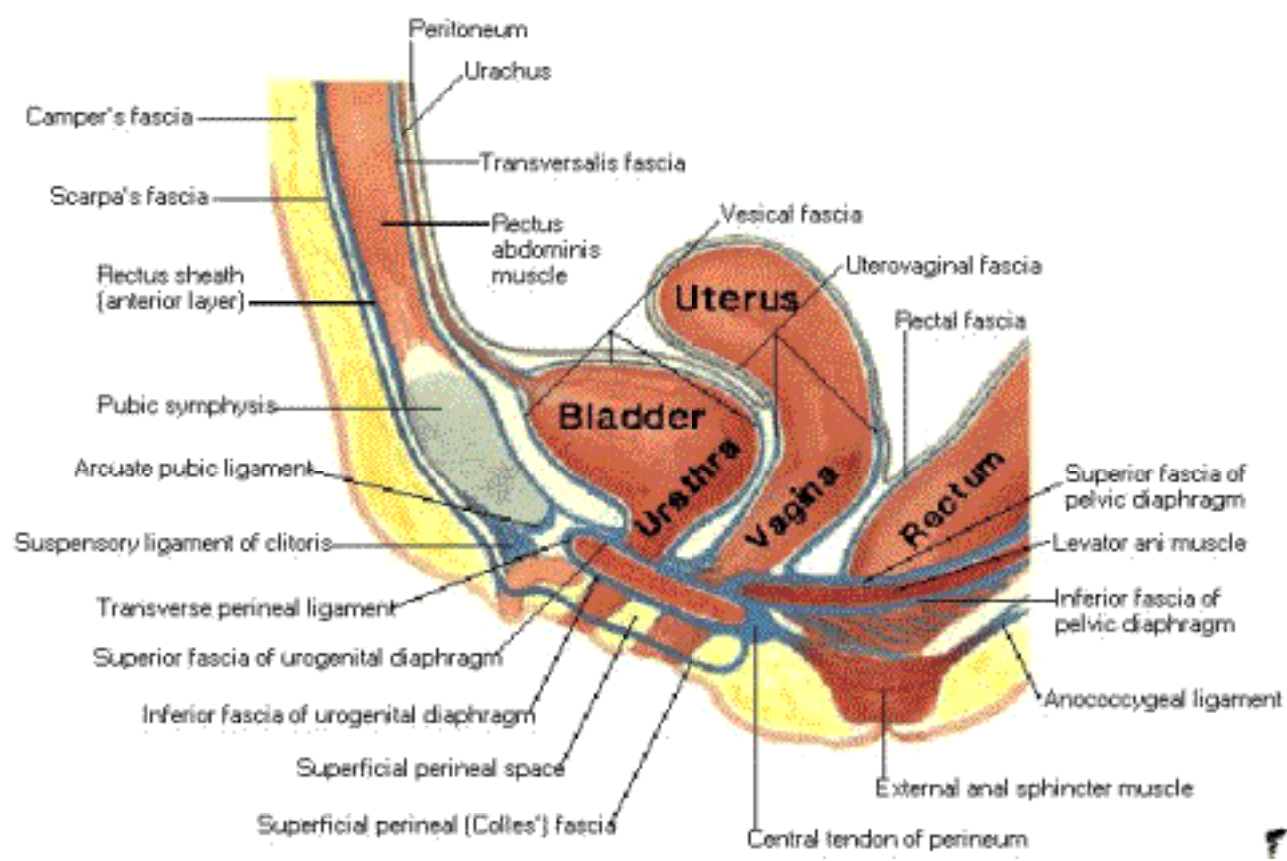
Perineum of Female

Superficial Dissection

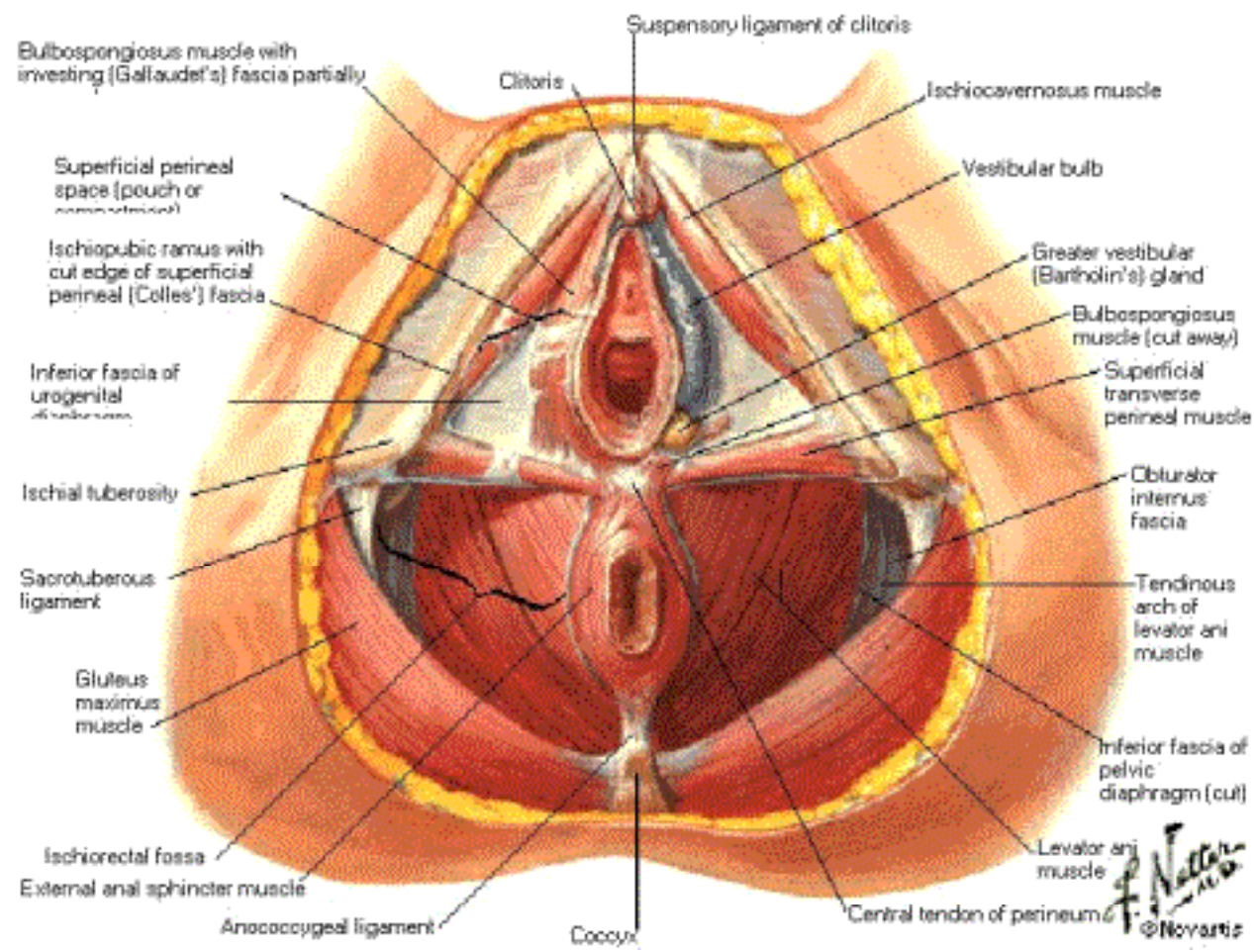


F. Netter

Perineum of Female Midsagittal Section

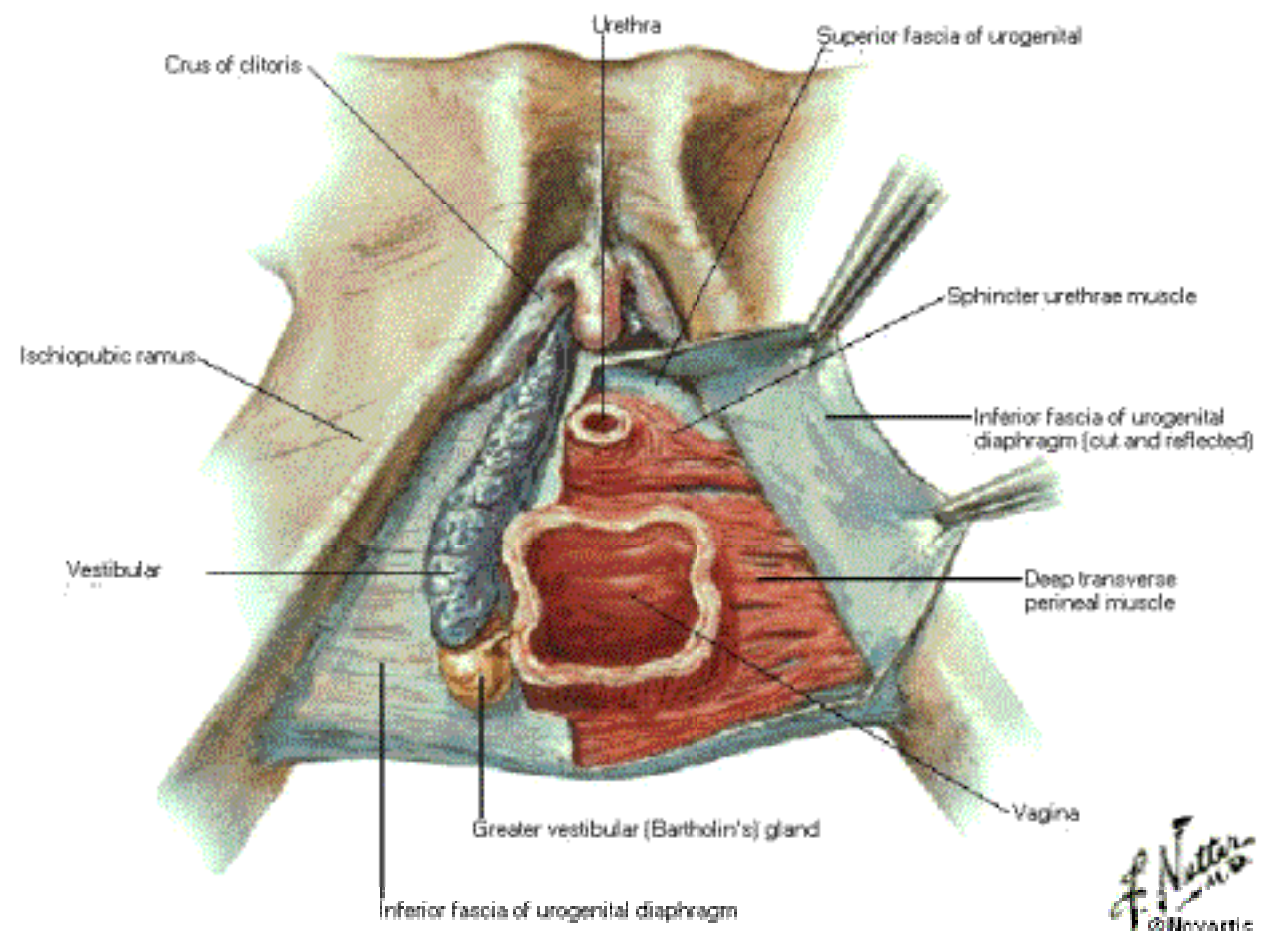


Perineum and Urogenital Diaphragm of Female

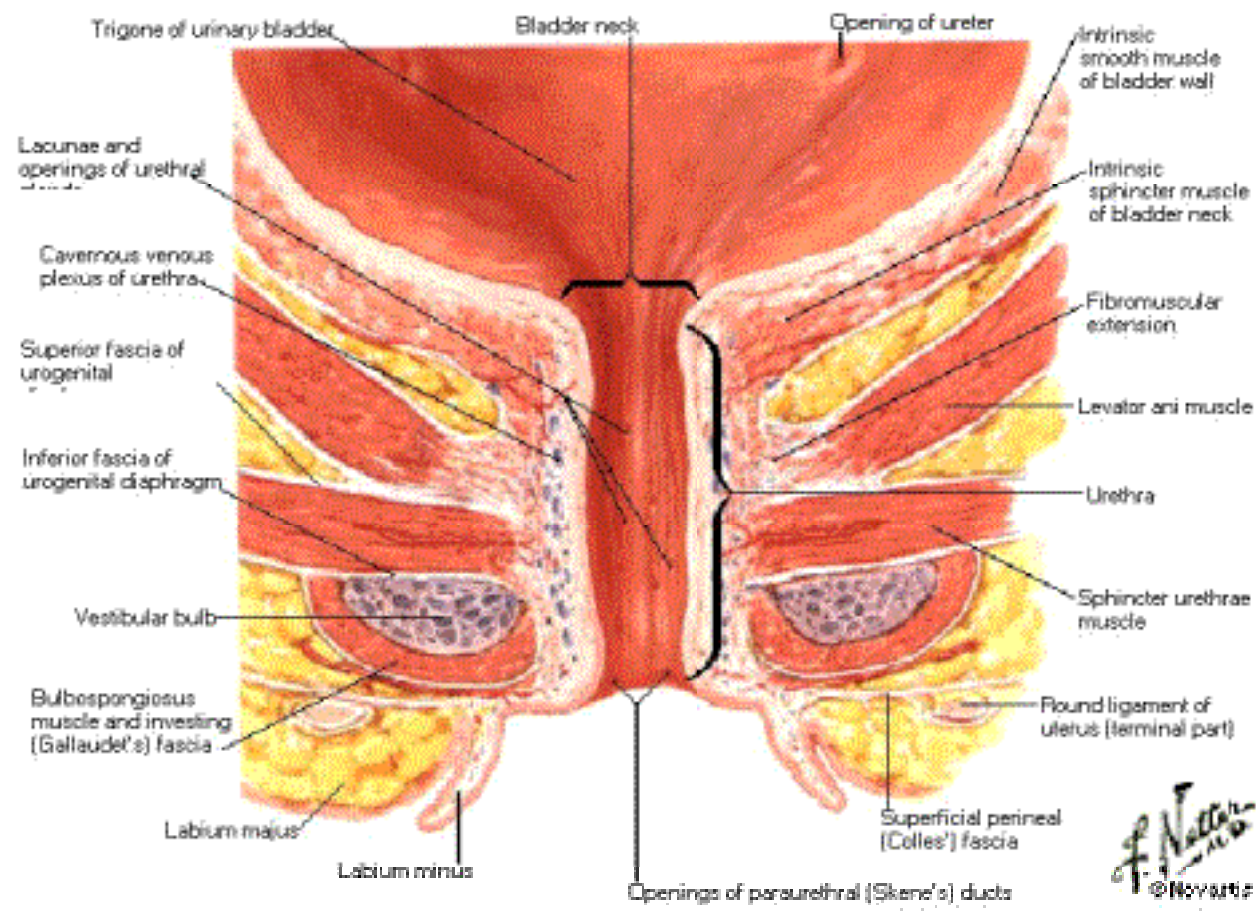


Perineum and Urogenital Diaphragm of Female

Deep Dissection

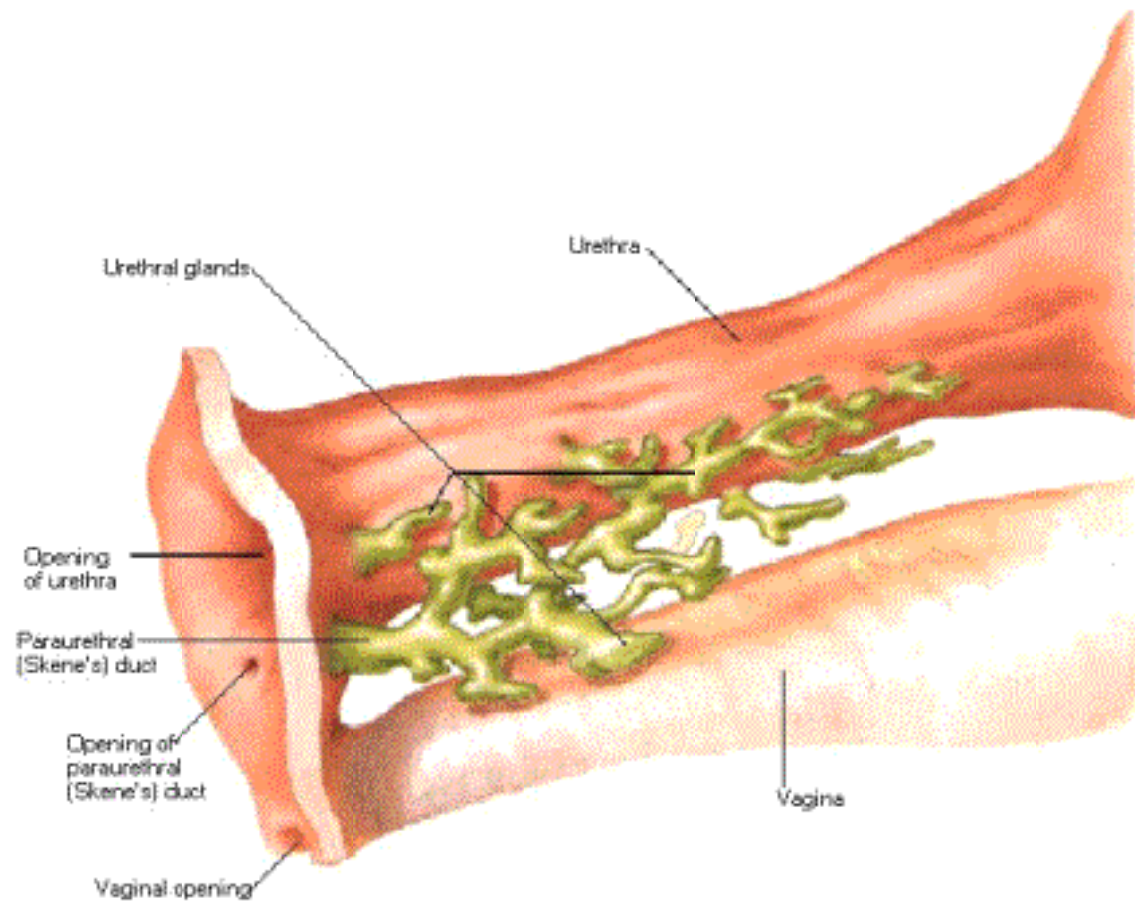


Urethra of Female Frontal Section



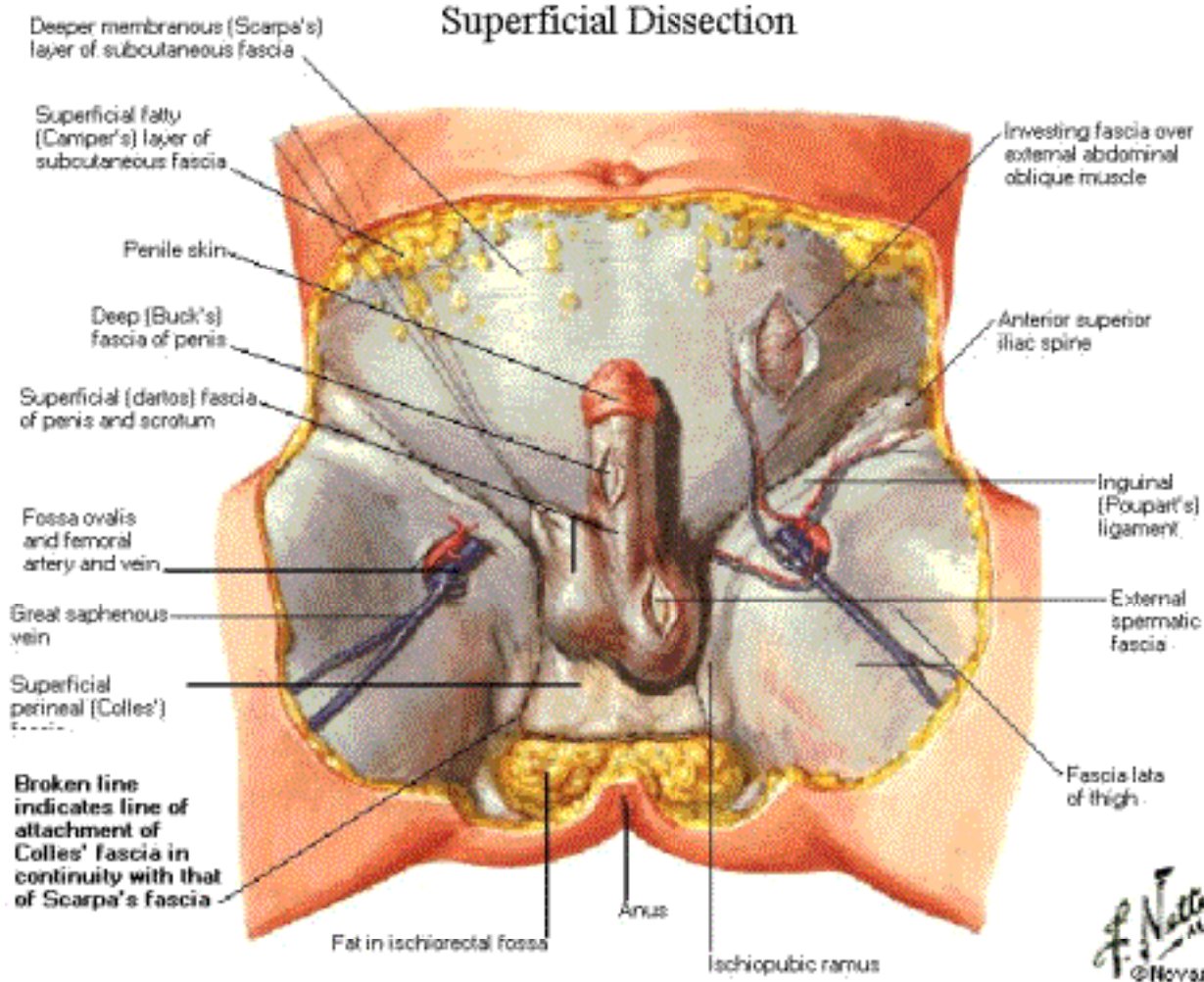
Urethra of Female

Schematic Reconstruction



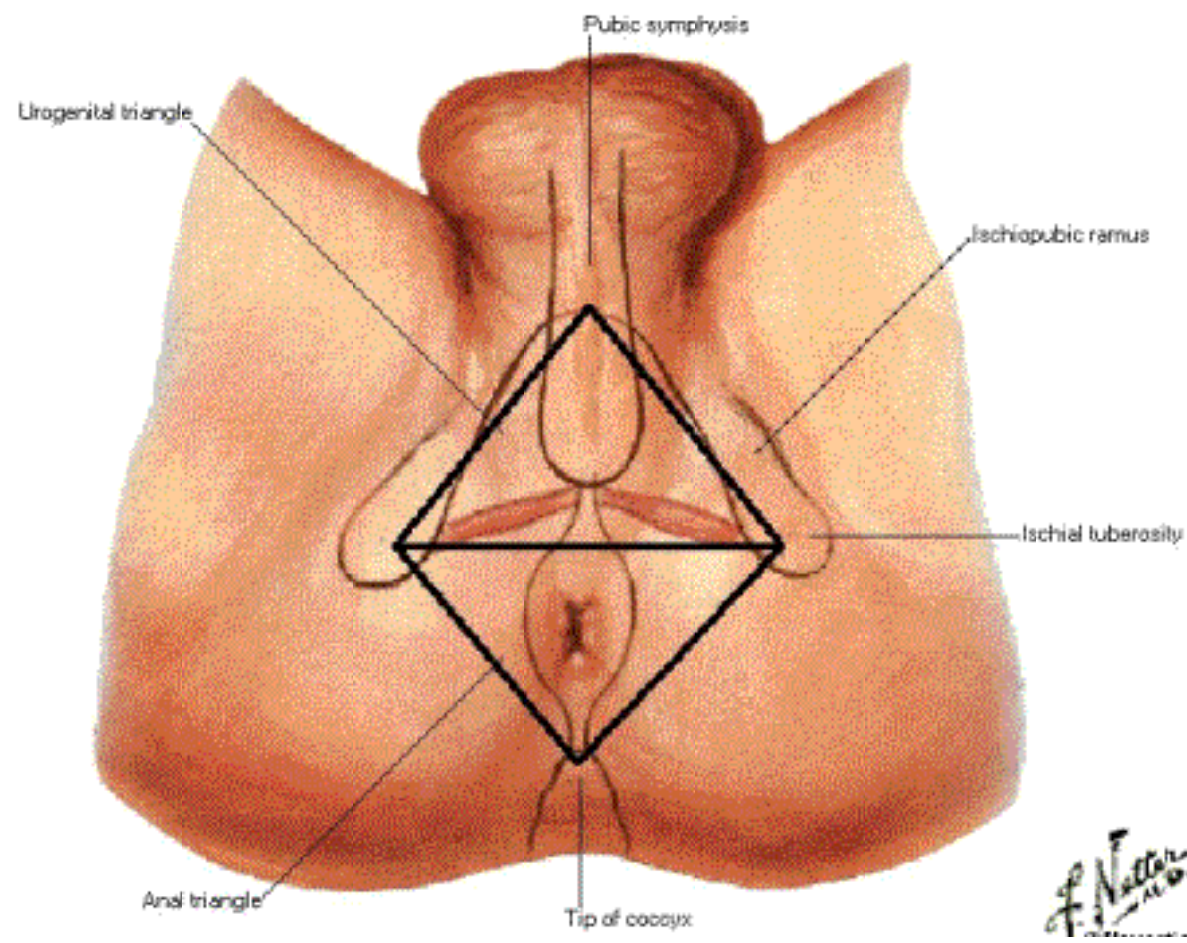
Perineum and External Genitalia of Male

Superficial Dissection



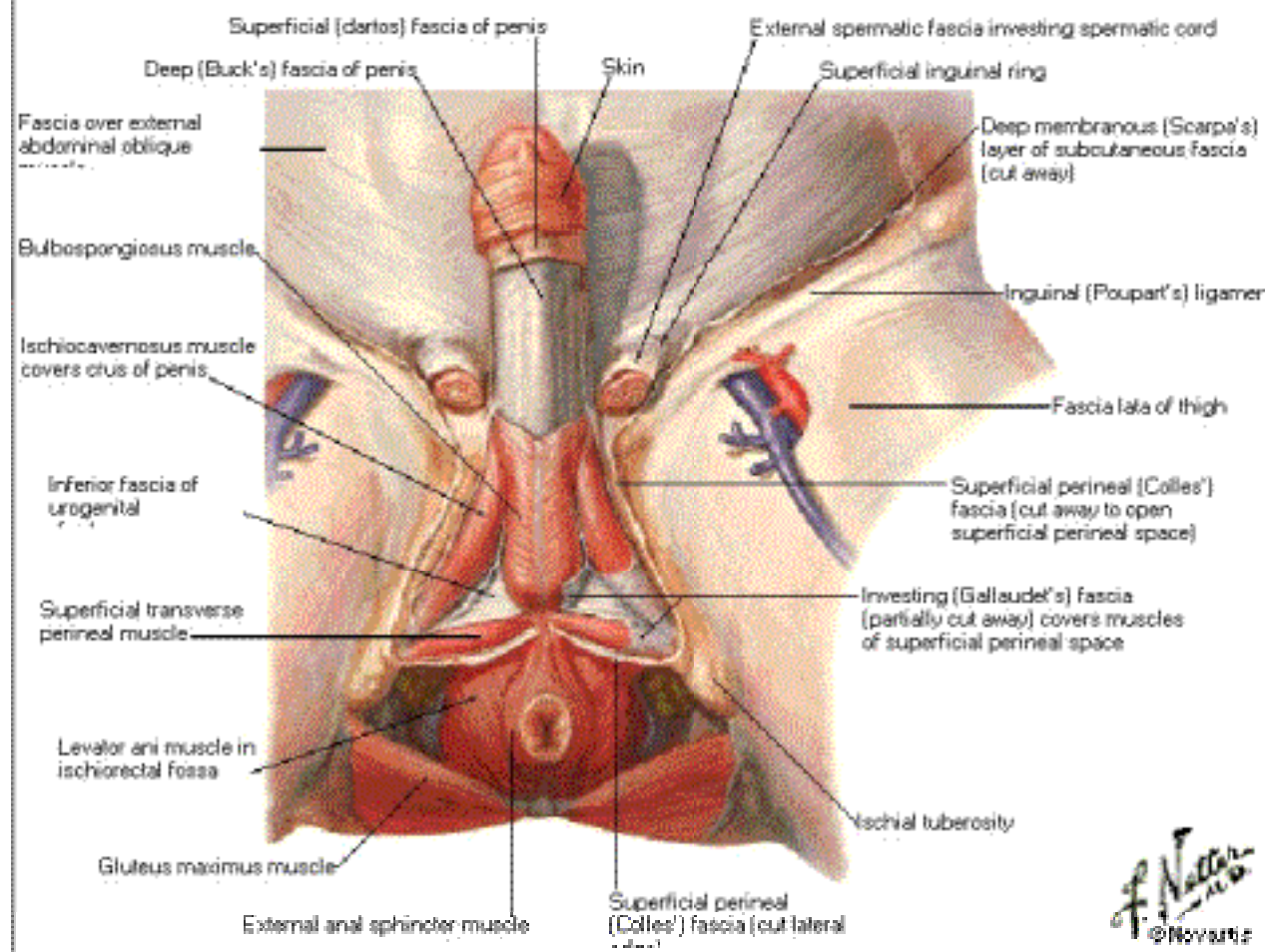
Perineum of Male

Regions [Triangles] and Surface Topography

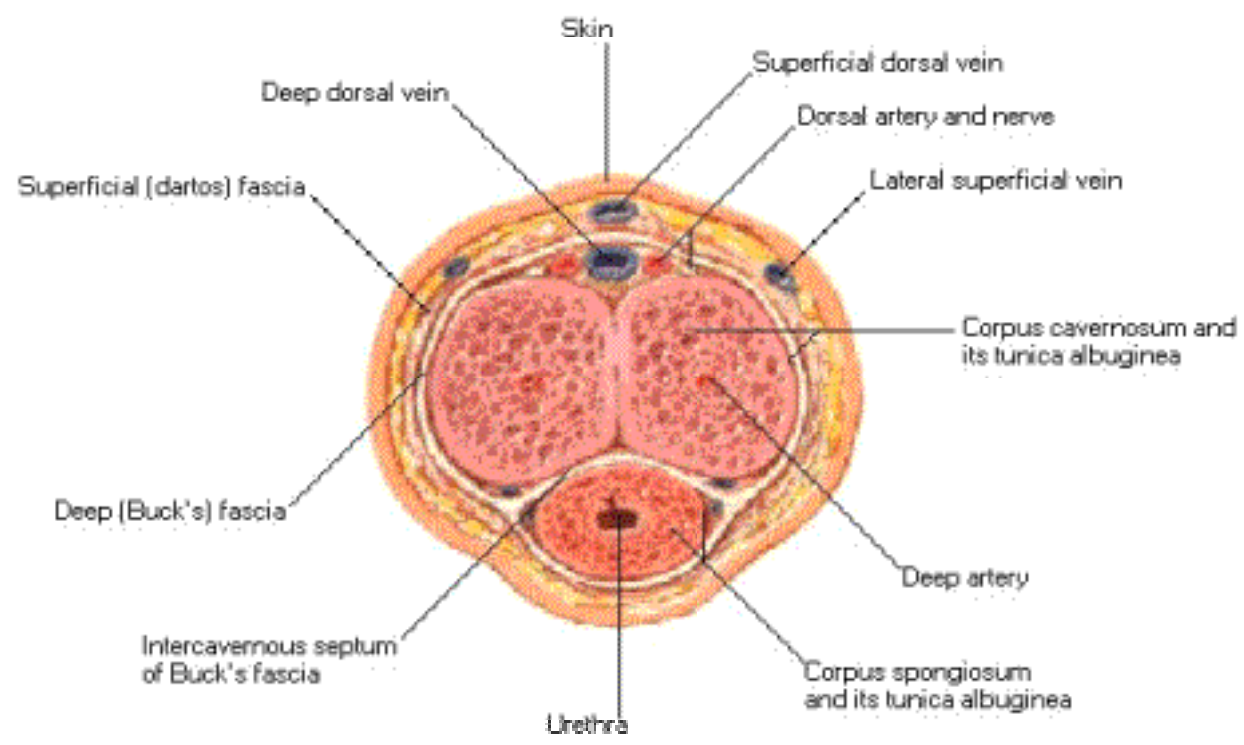


Perineum and External Genitalia of Male

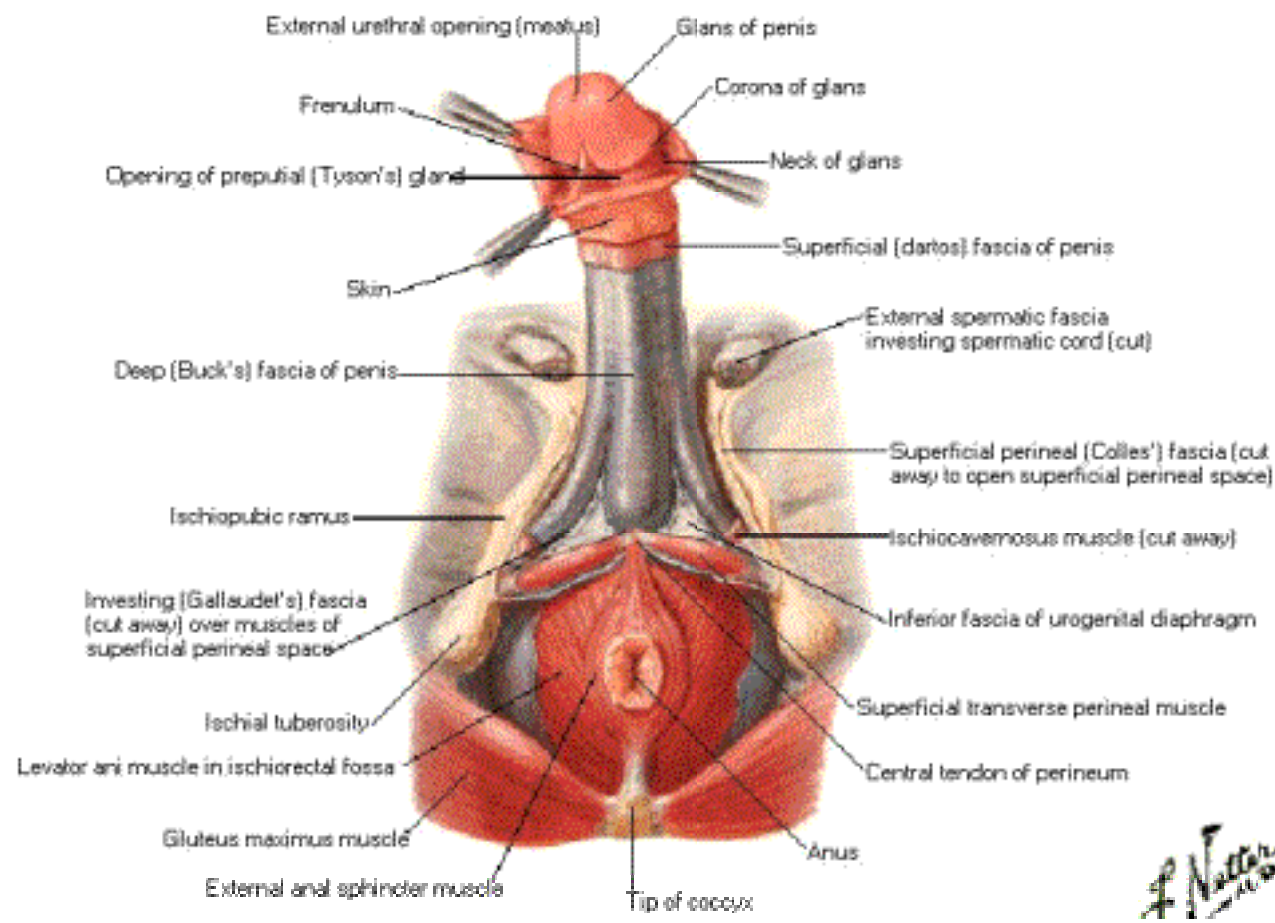
Deep Dissection



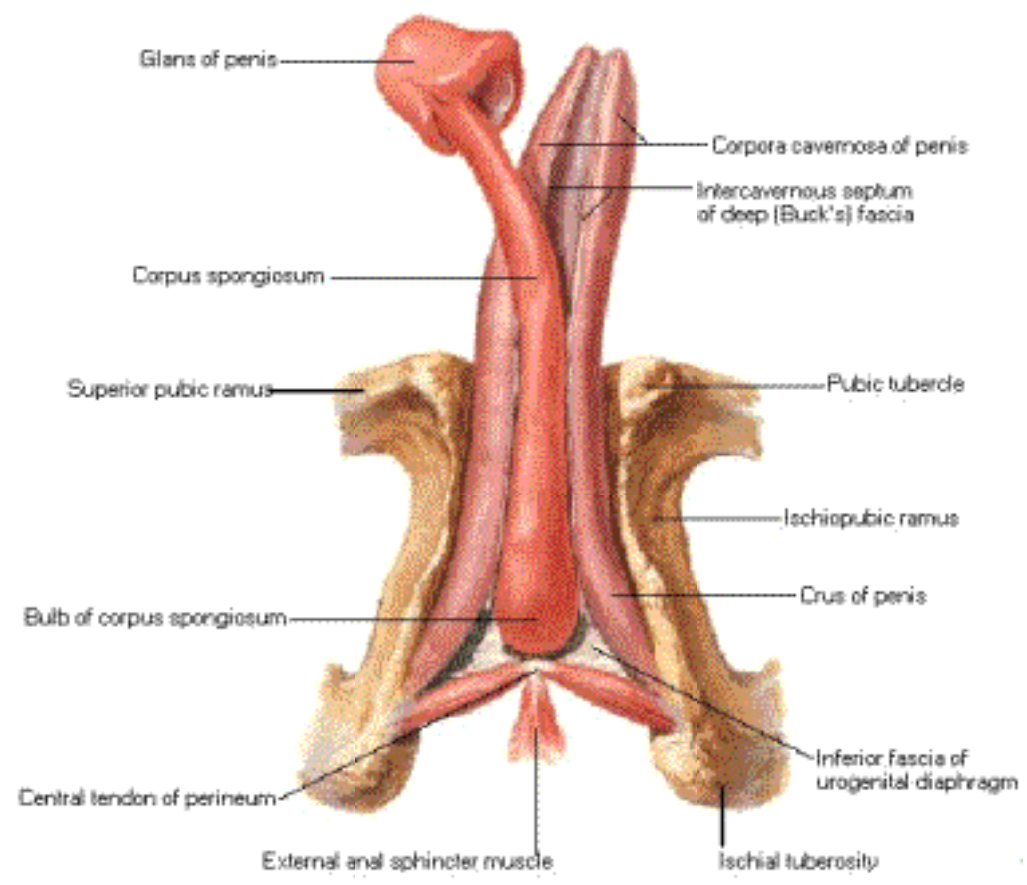
Section through Body of Penis



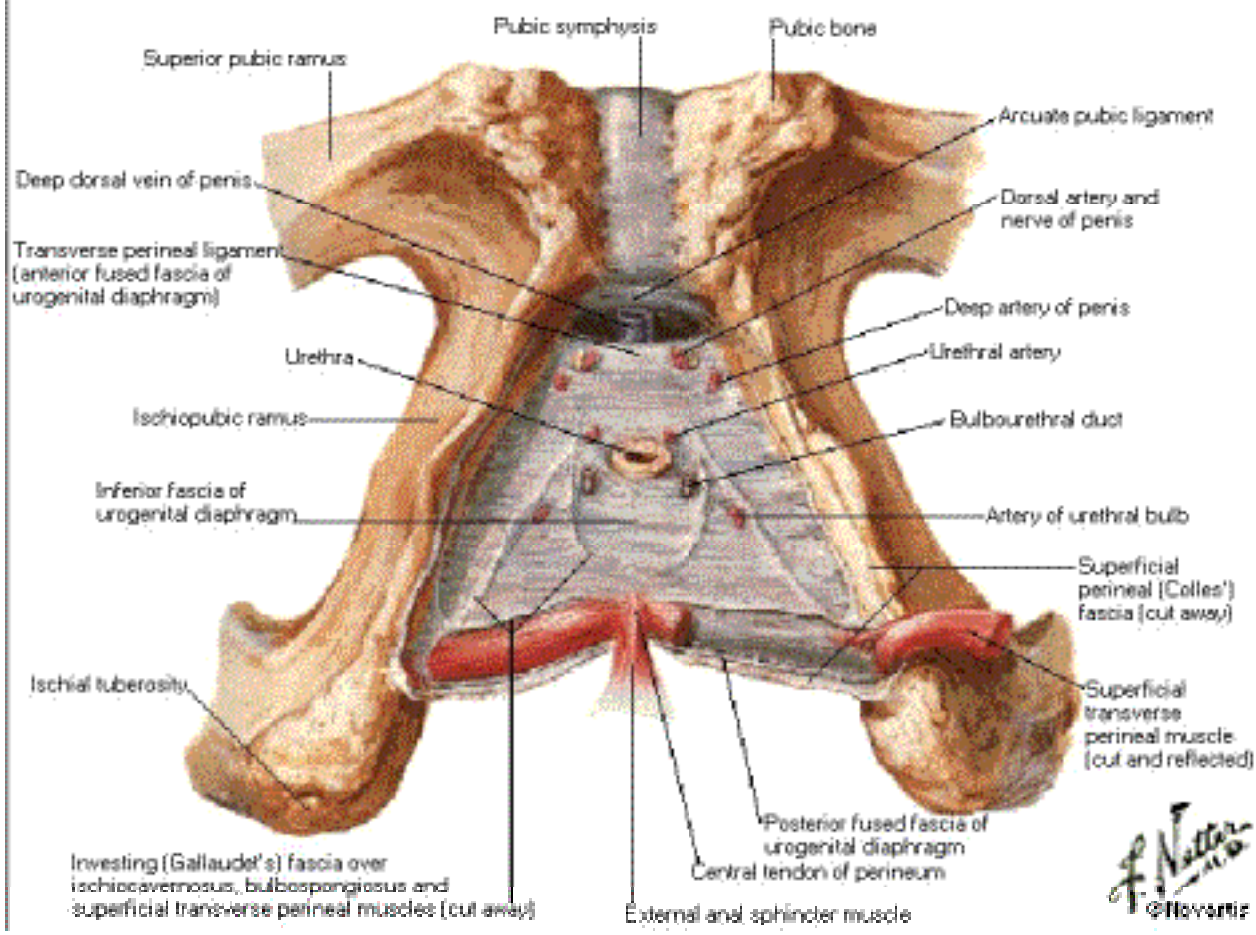
Penis



Penis [Continued]

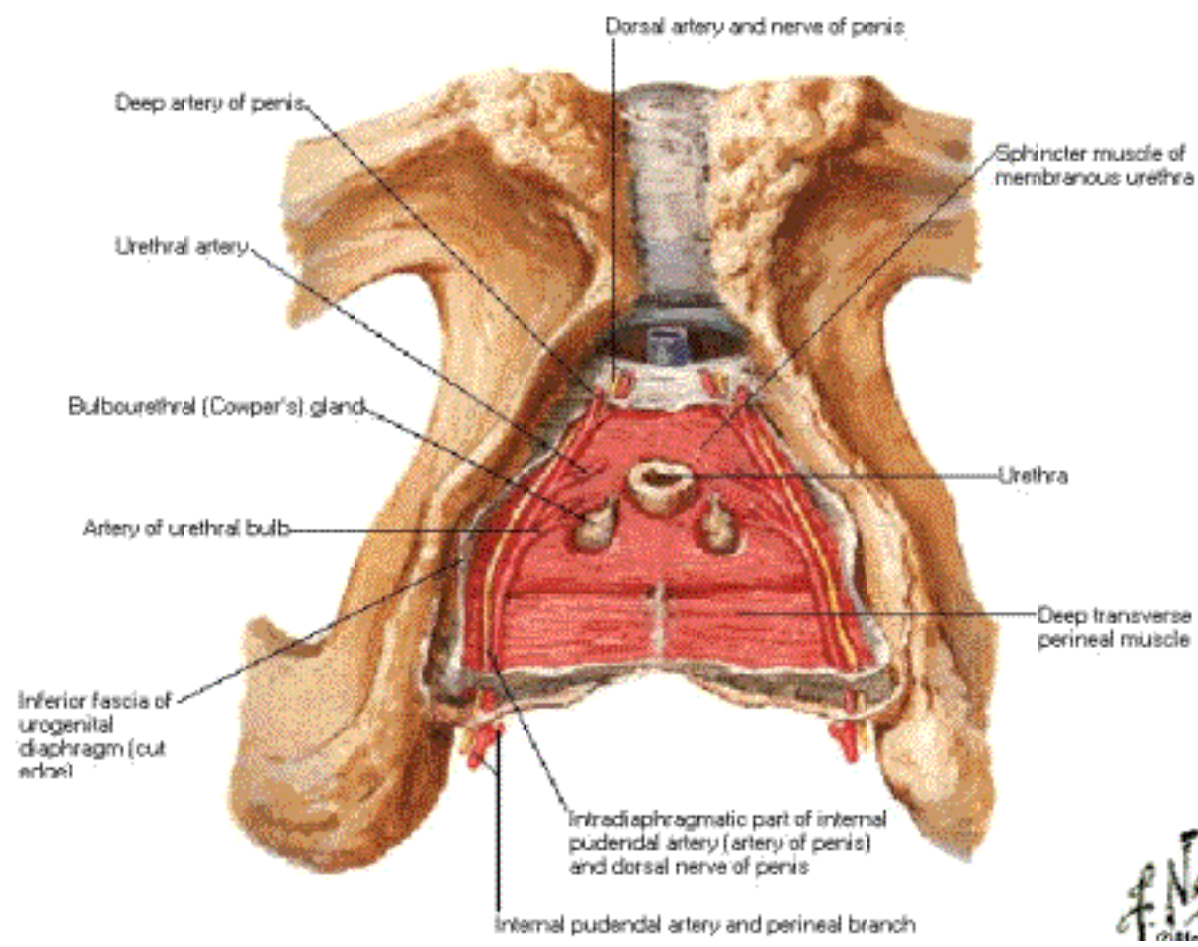


Urogenital Diaphragm of Male Dissection



Urogenital Diaphragm of Male

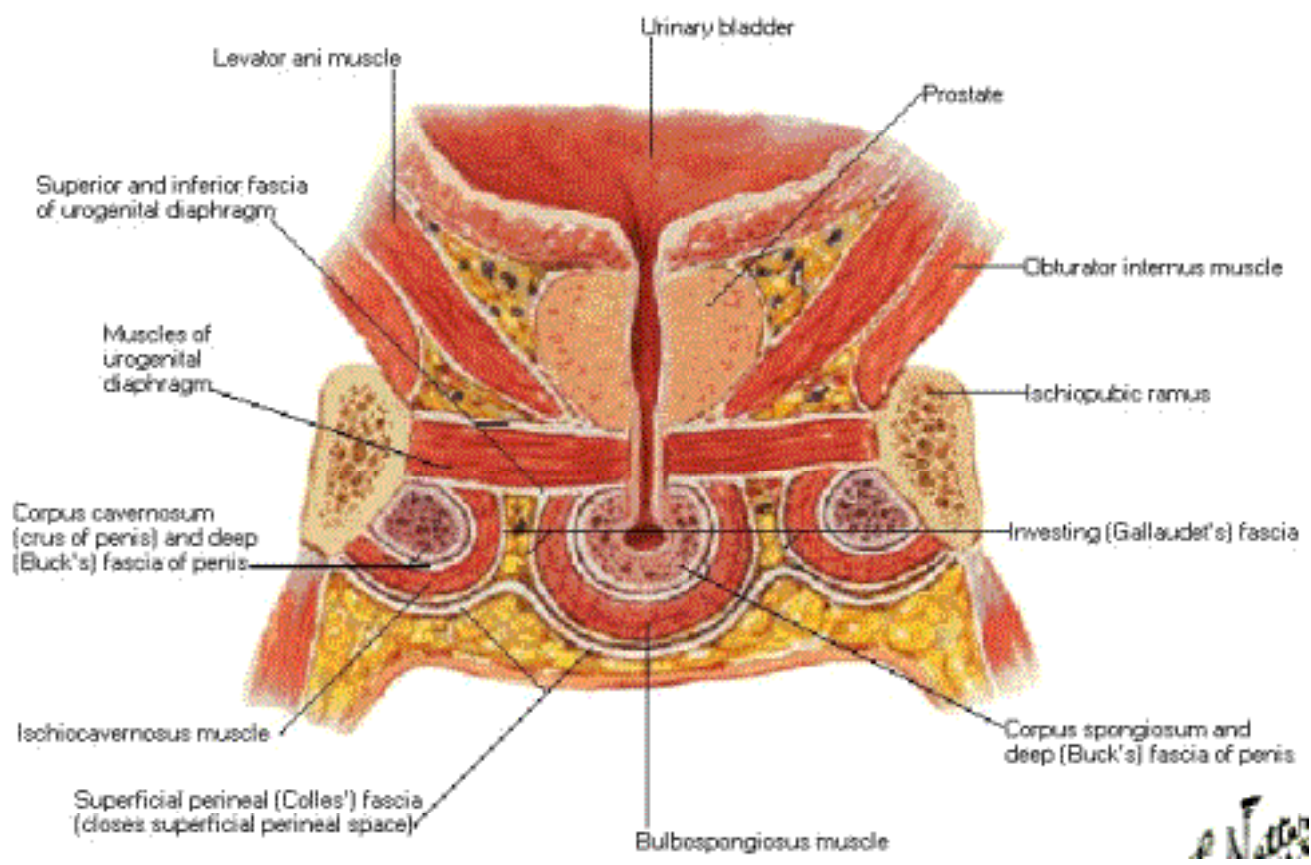
Deep Dissection



Handwritten signature

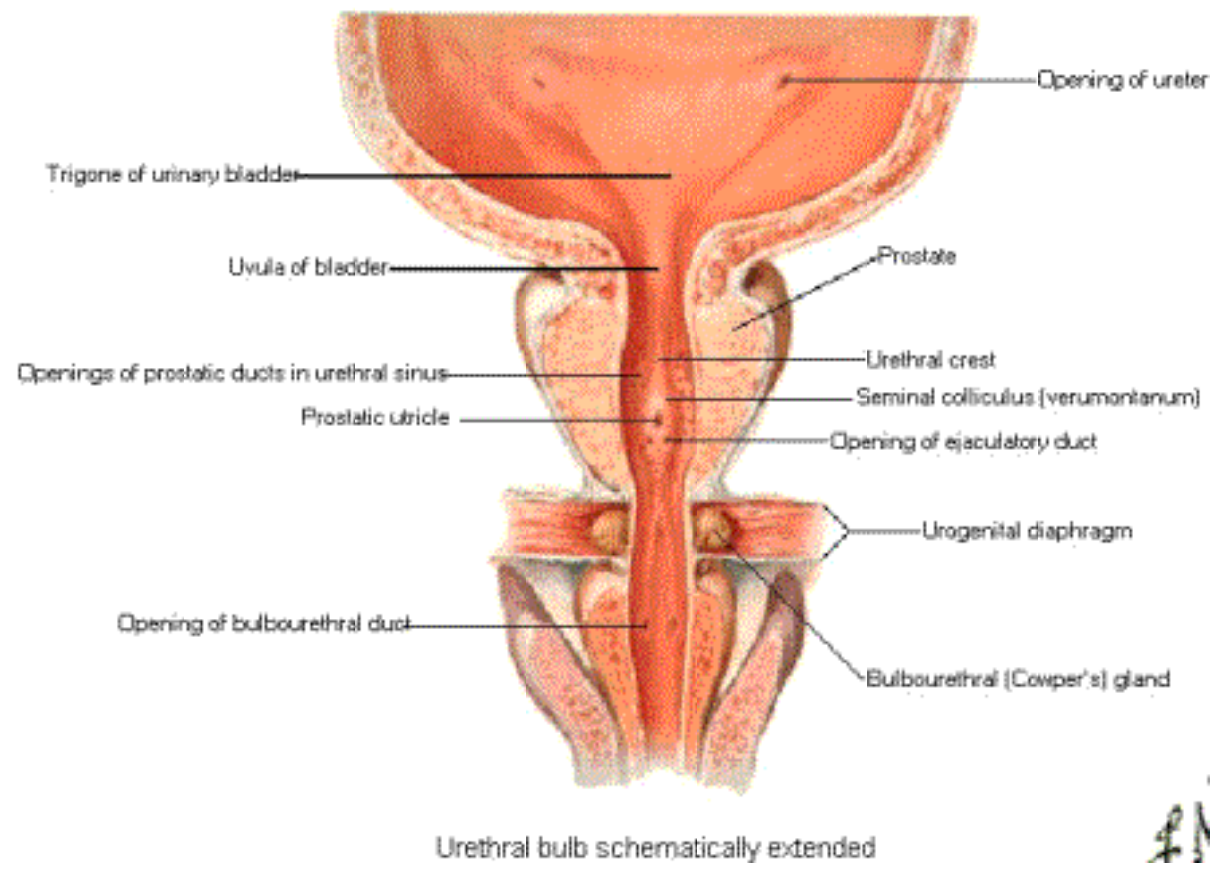
Urogenital Diaphragm of Male

Frontal Section - Schema



Prostate and Seminal Vesicles

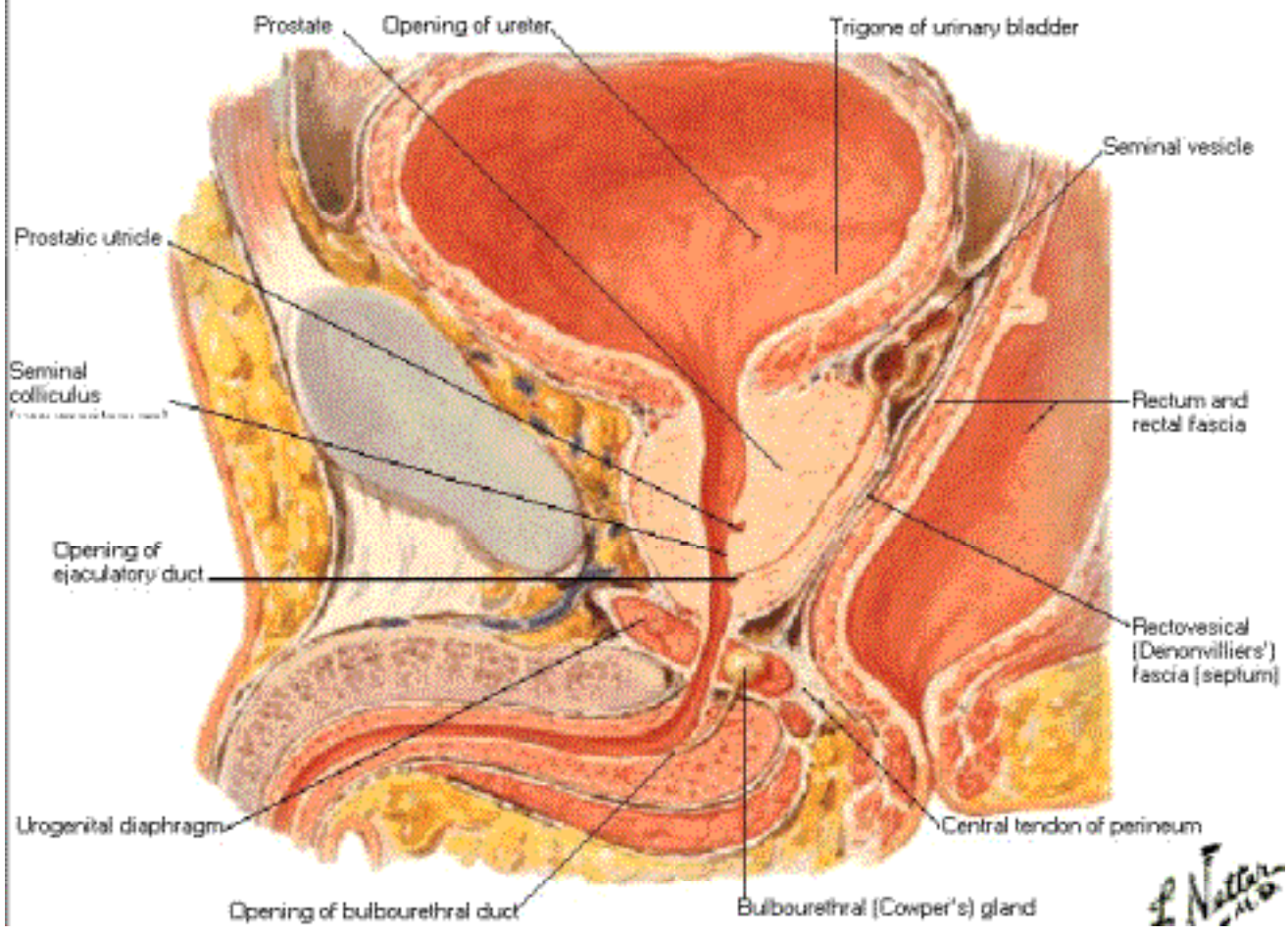
Frontal Section



41

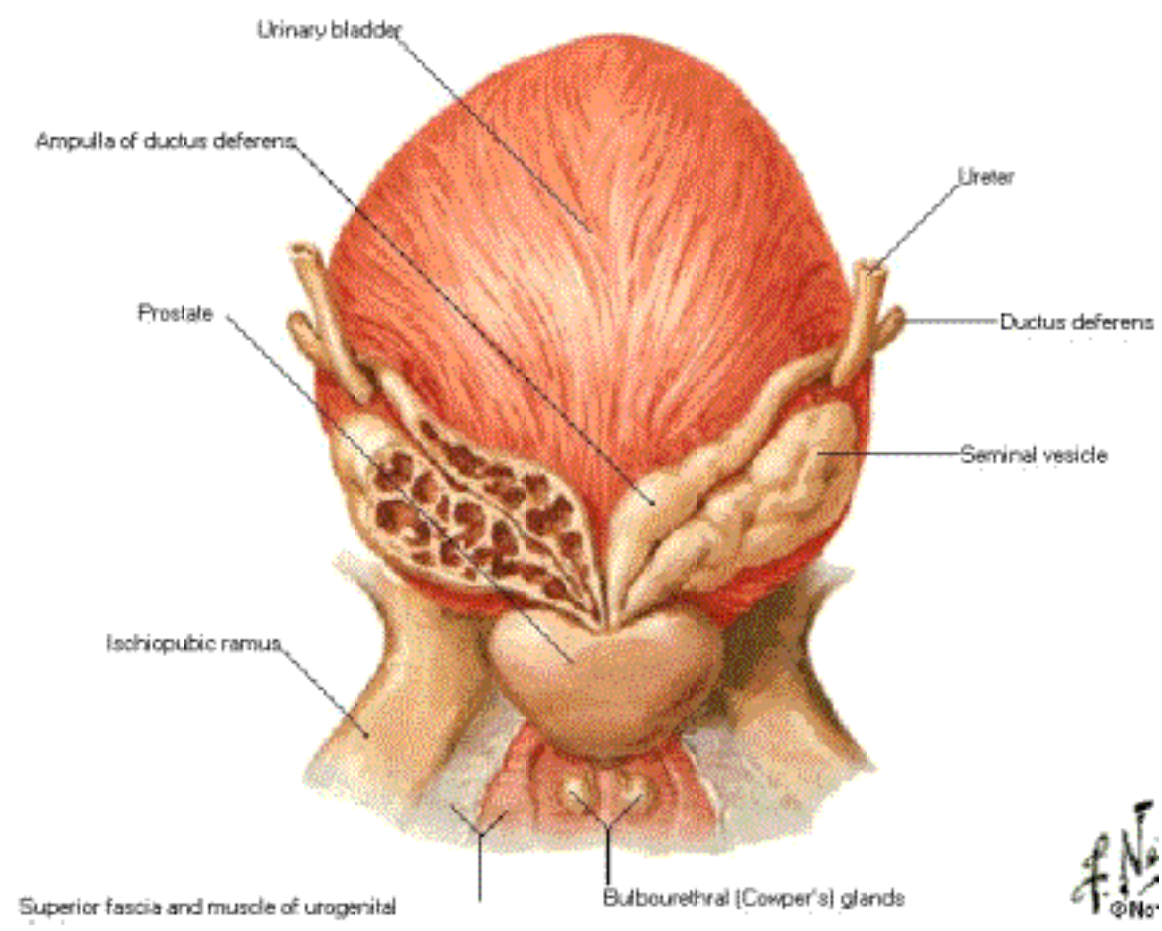
Prostate and Seminal Vesicles

Sagittal Section



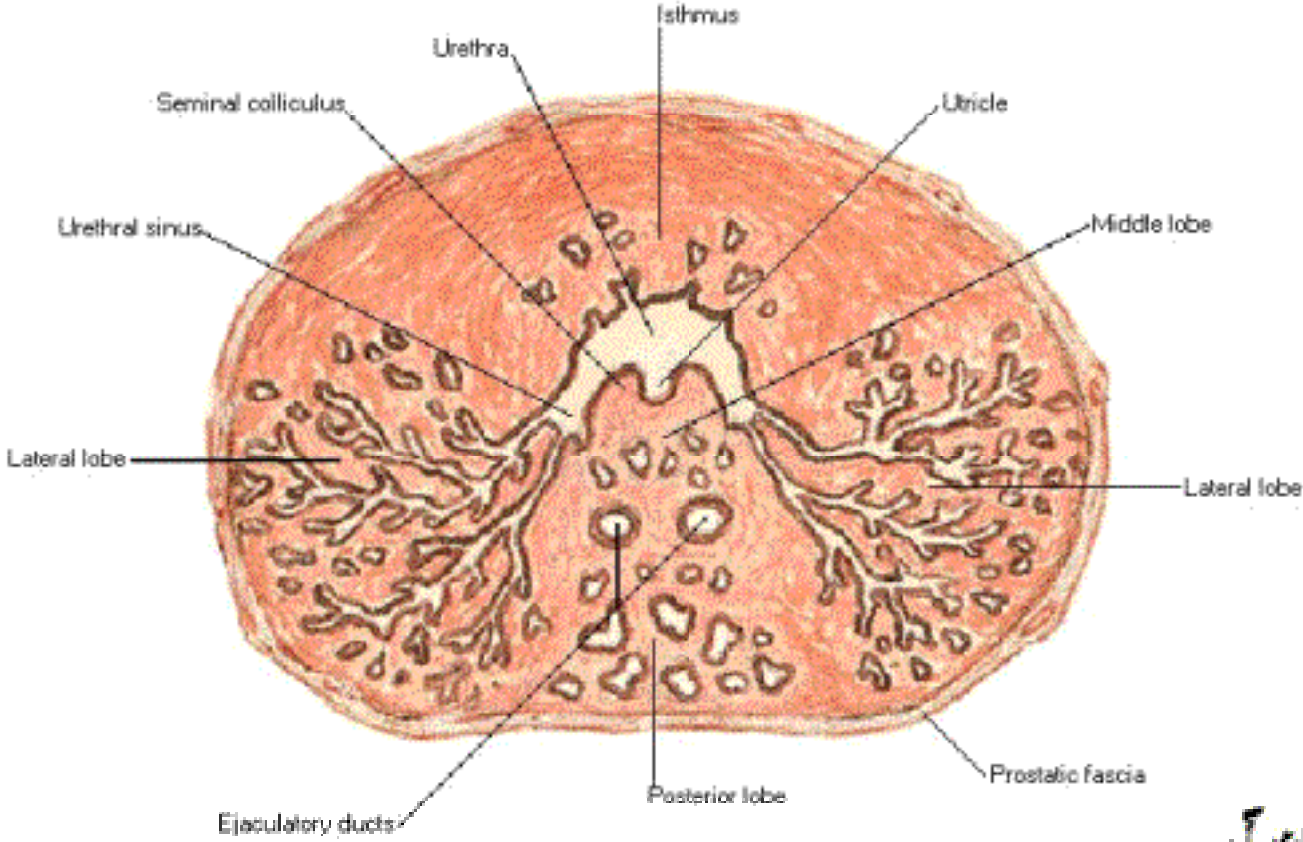
Prostate and Seminal Vesicles

Posterior View



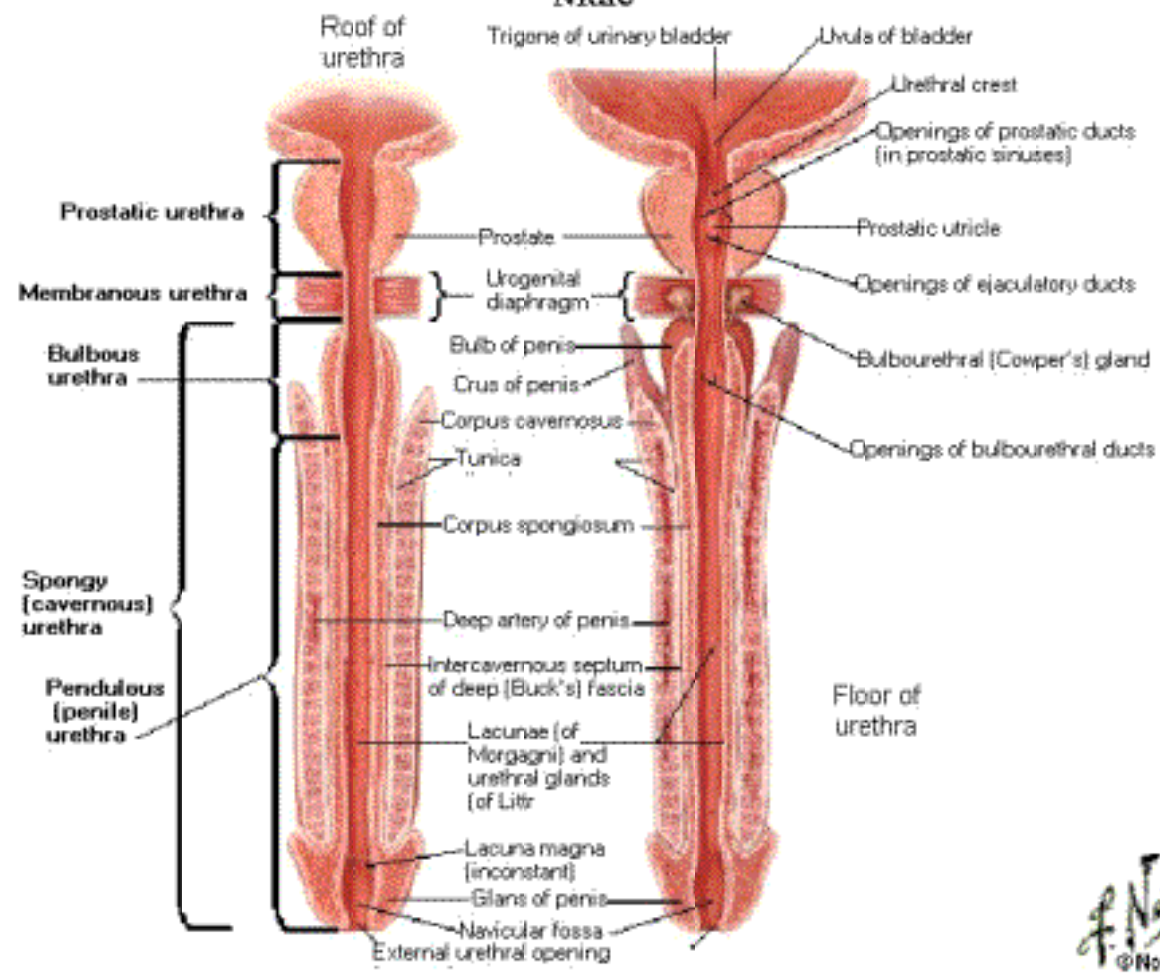
Prostate and Seminal Vesicles

Cross Section through Prostate



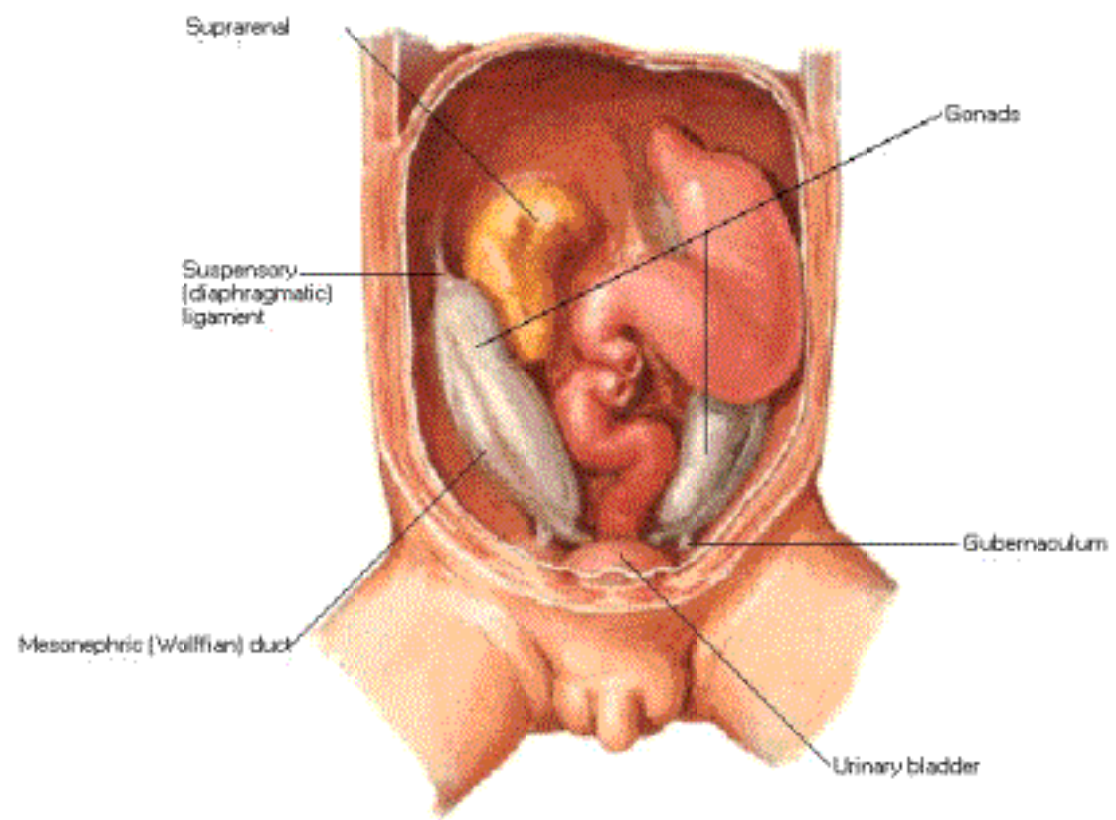
Urethra

Male



Descent of Testis

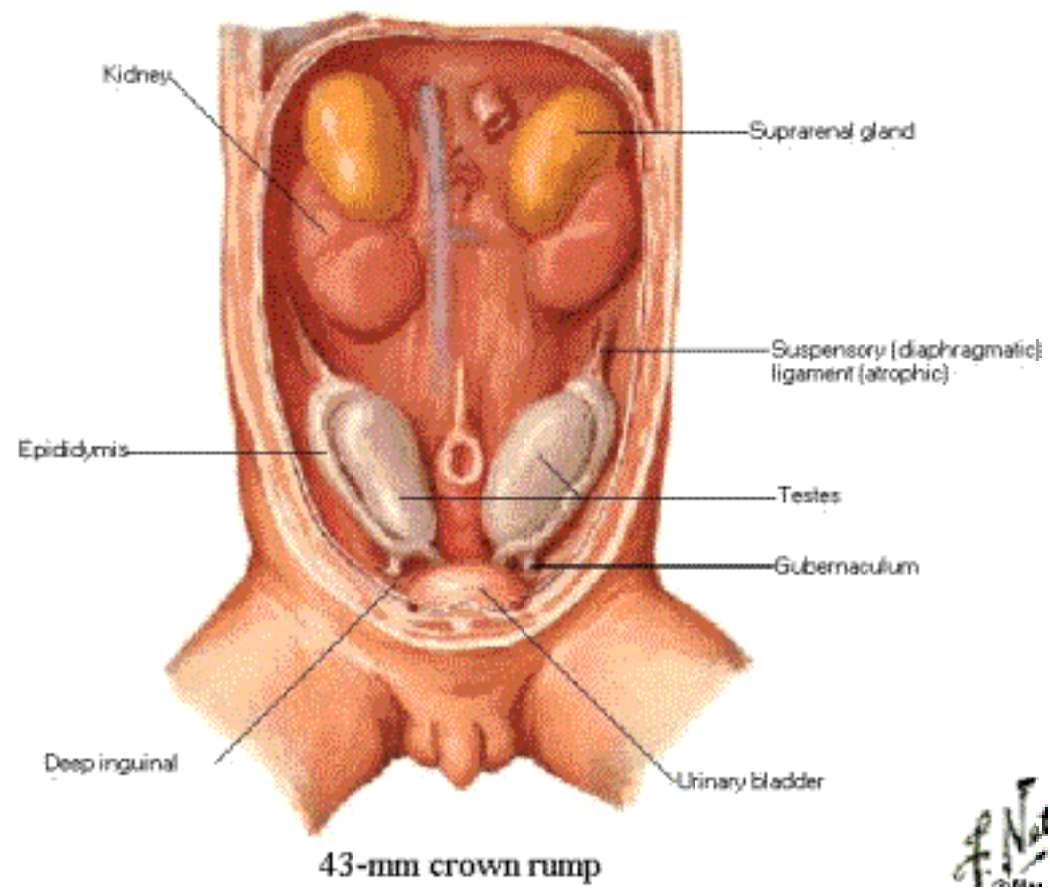
8 Weeks



22.5-mm crown rump

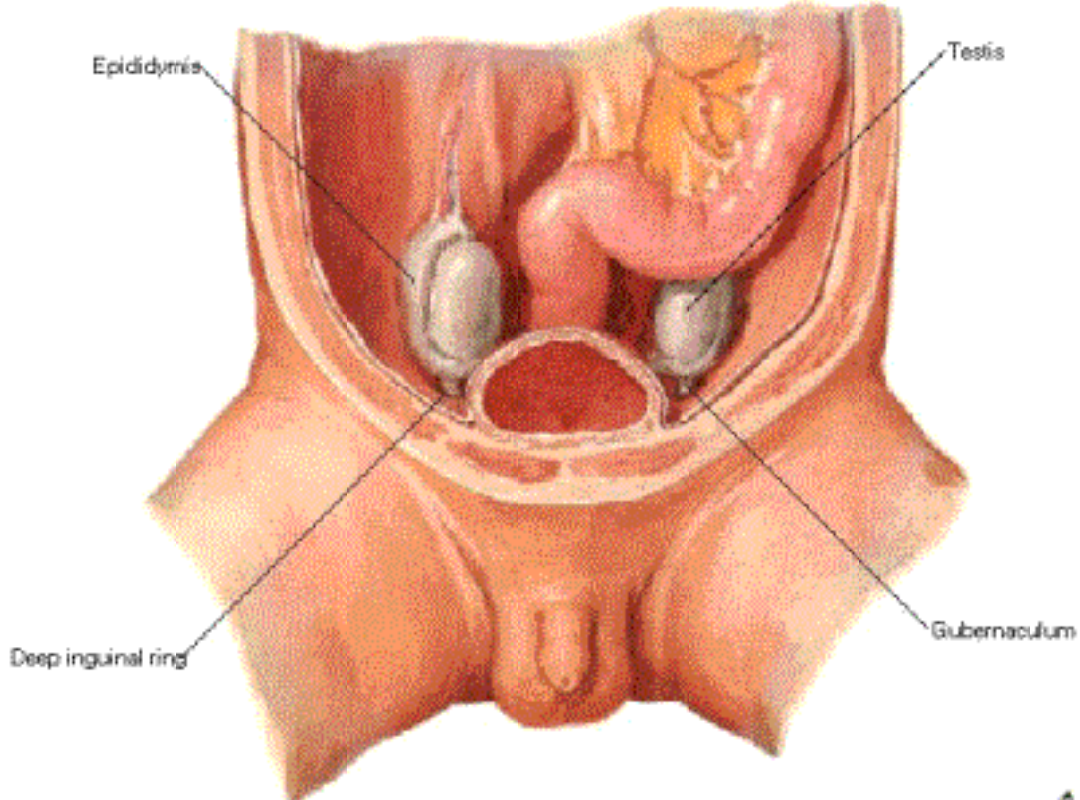
Descent of Testis

11 Weeks



Descent of Testis

4 Lunar Months

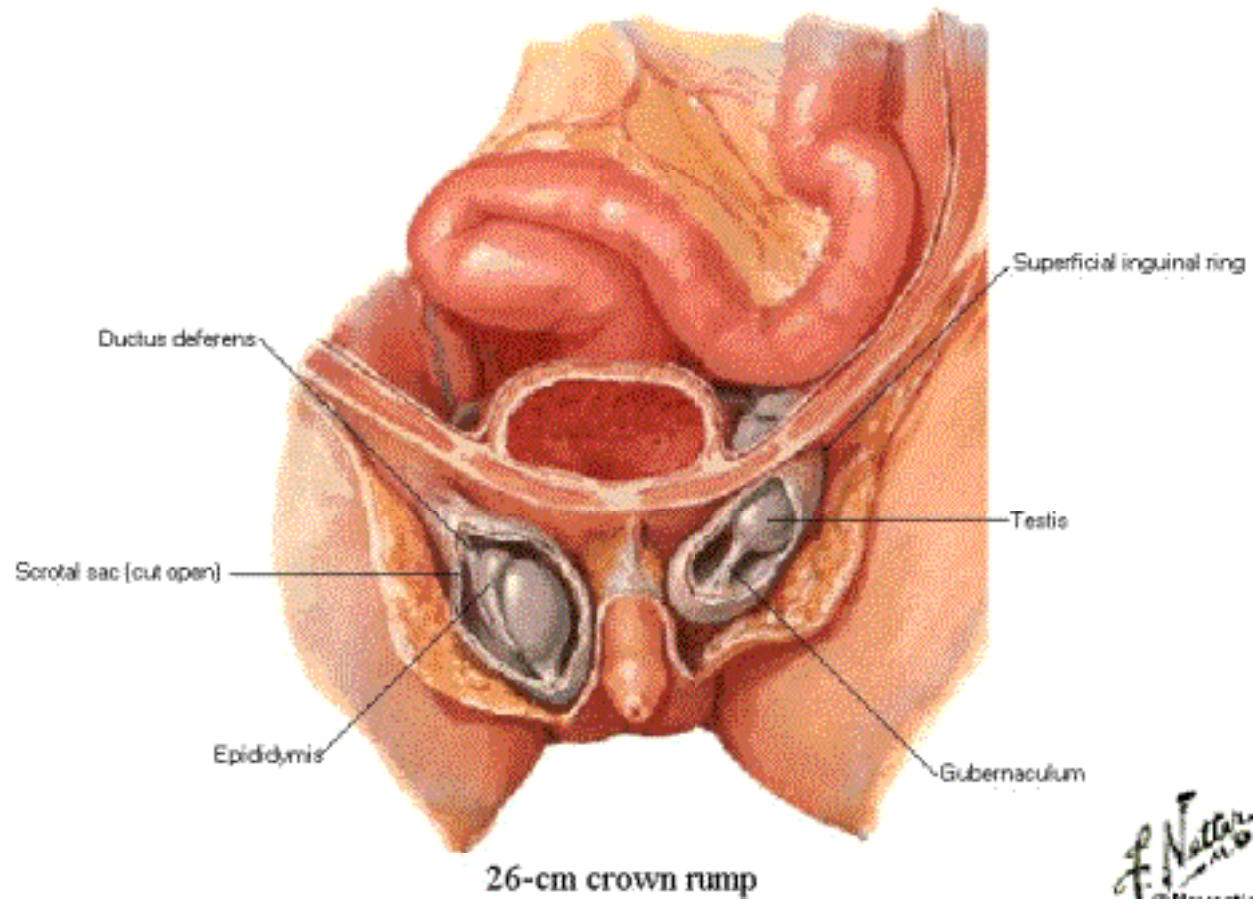


107-mm crown rump

for

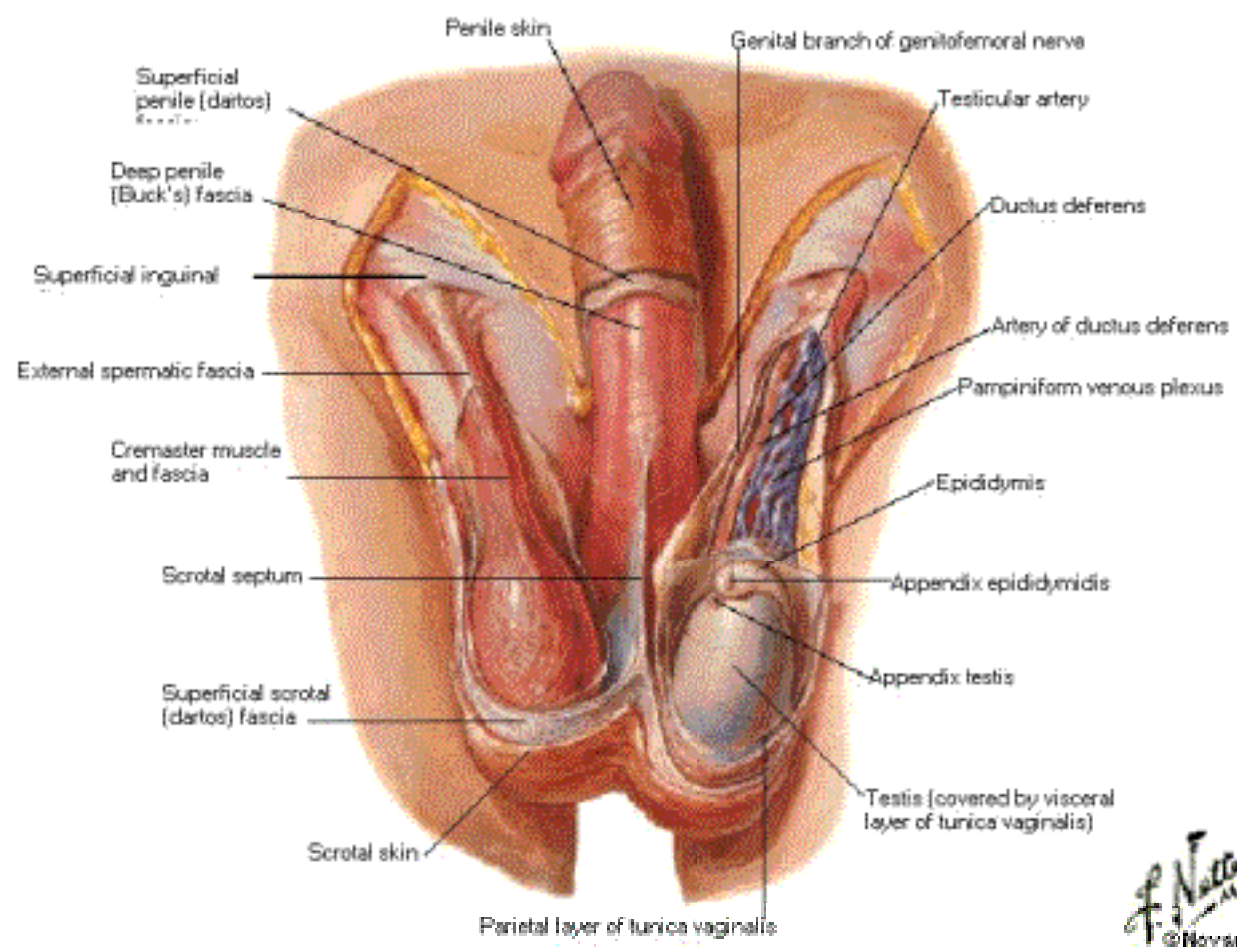
Descent of Testis

8 Lunar Months



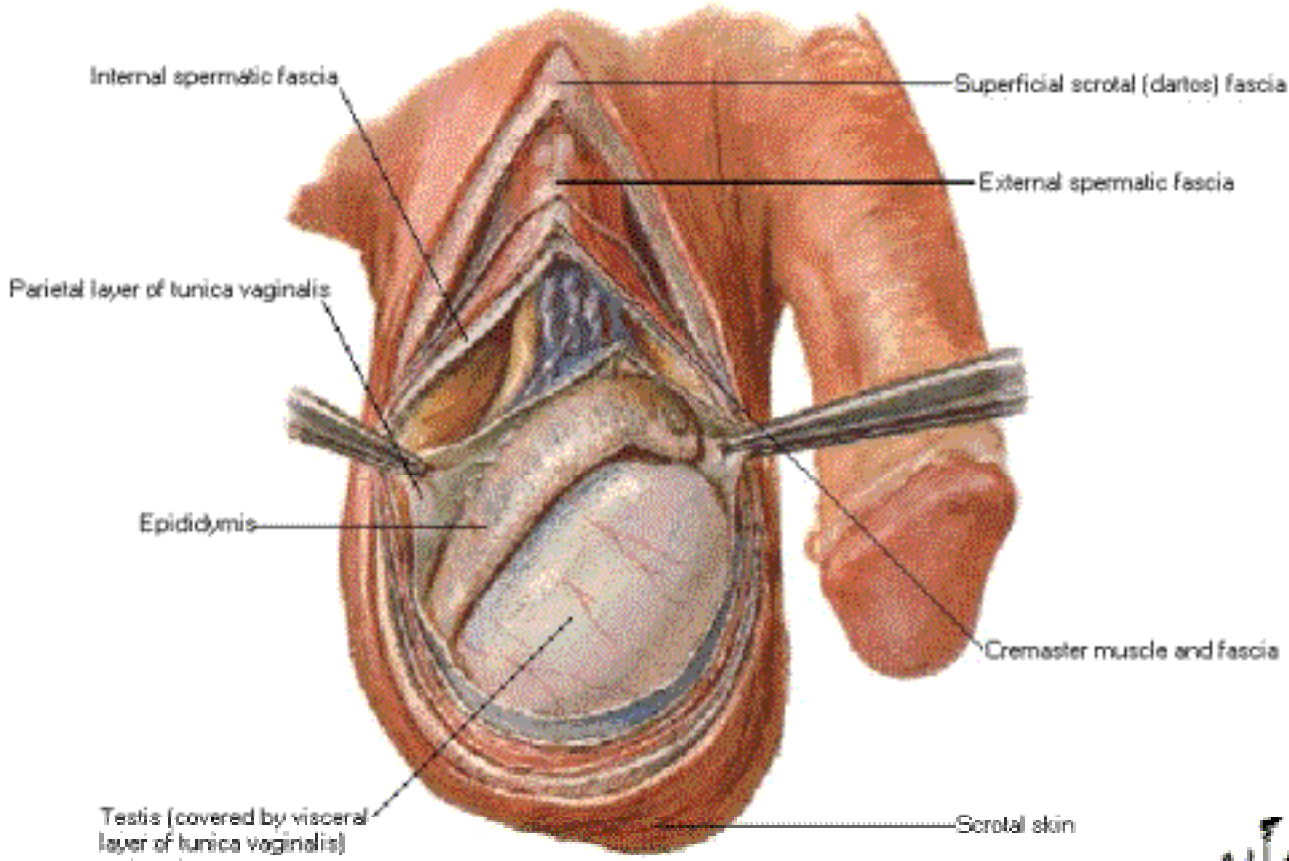
Scrotum and Contents

Anterior View



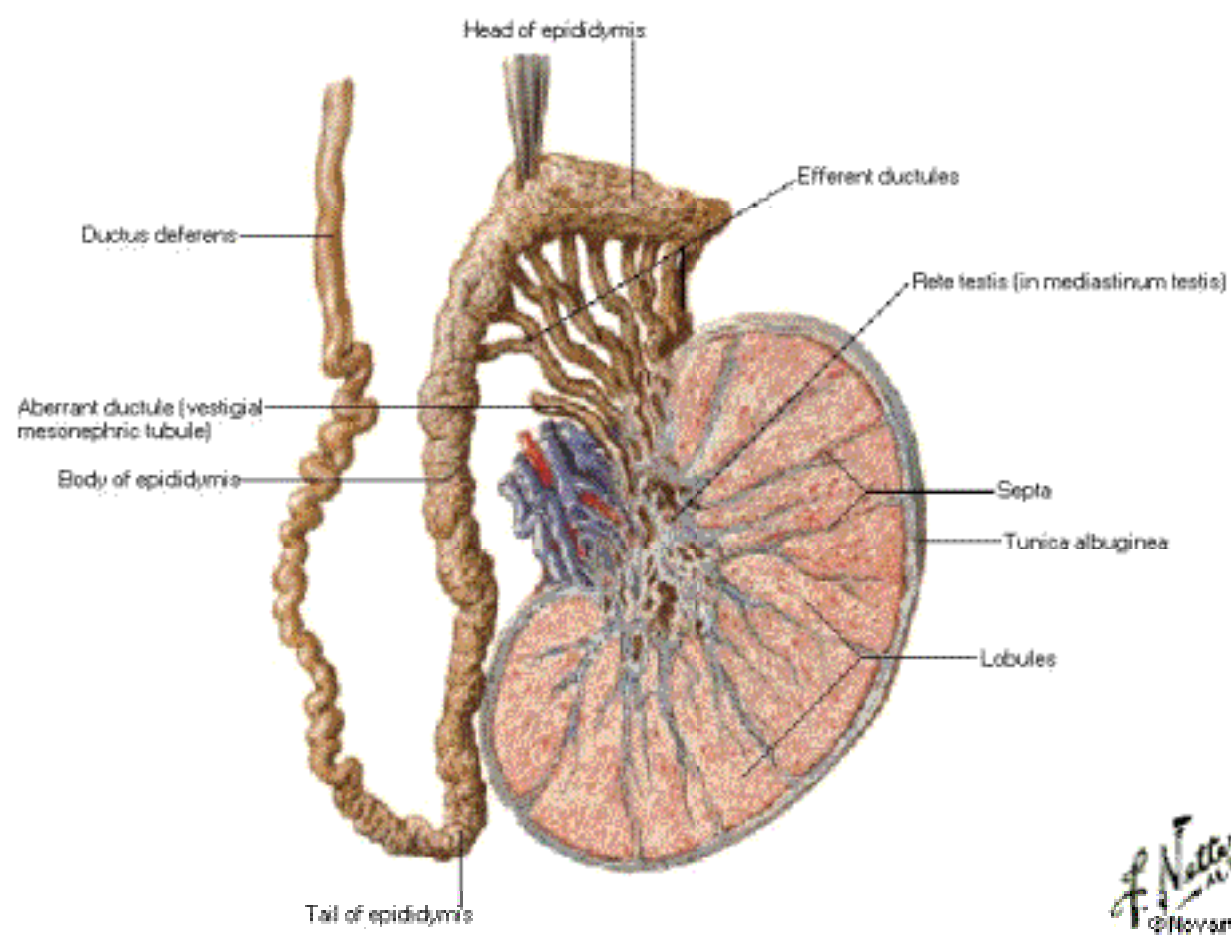
Scrotum and Contents

Lateral View



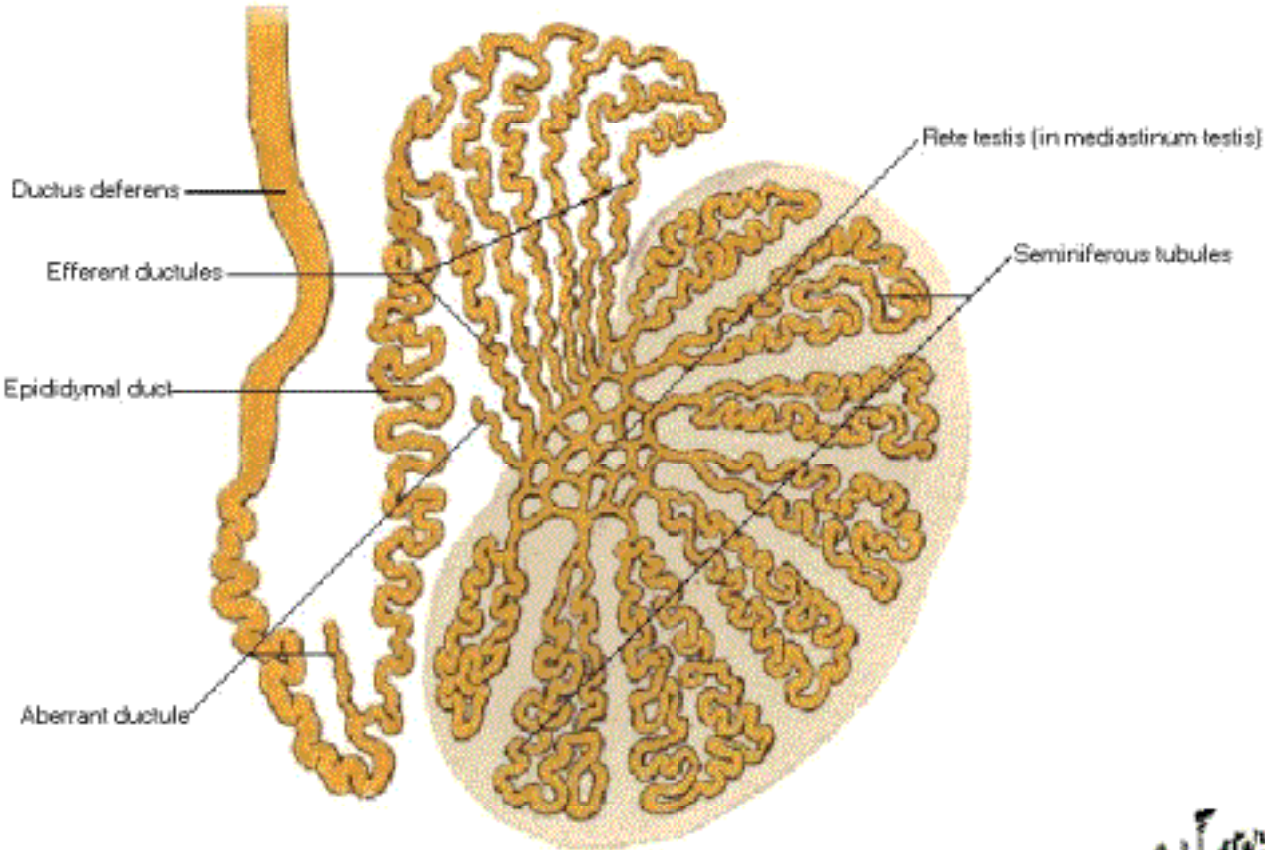
Testis, Epididymis and Ductus Deferens

Frontal Section



Testis, Epididymis and Ductus Deferens

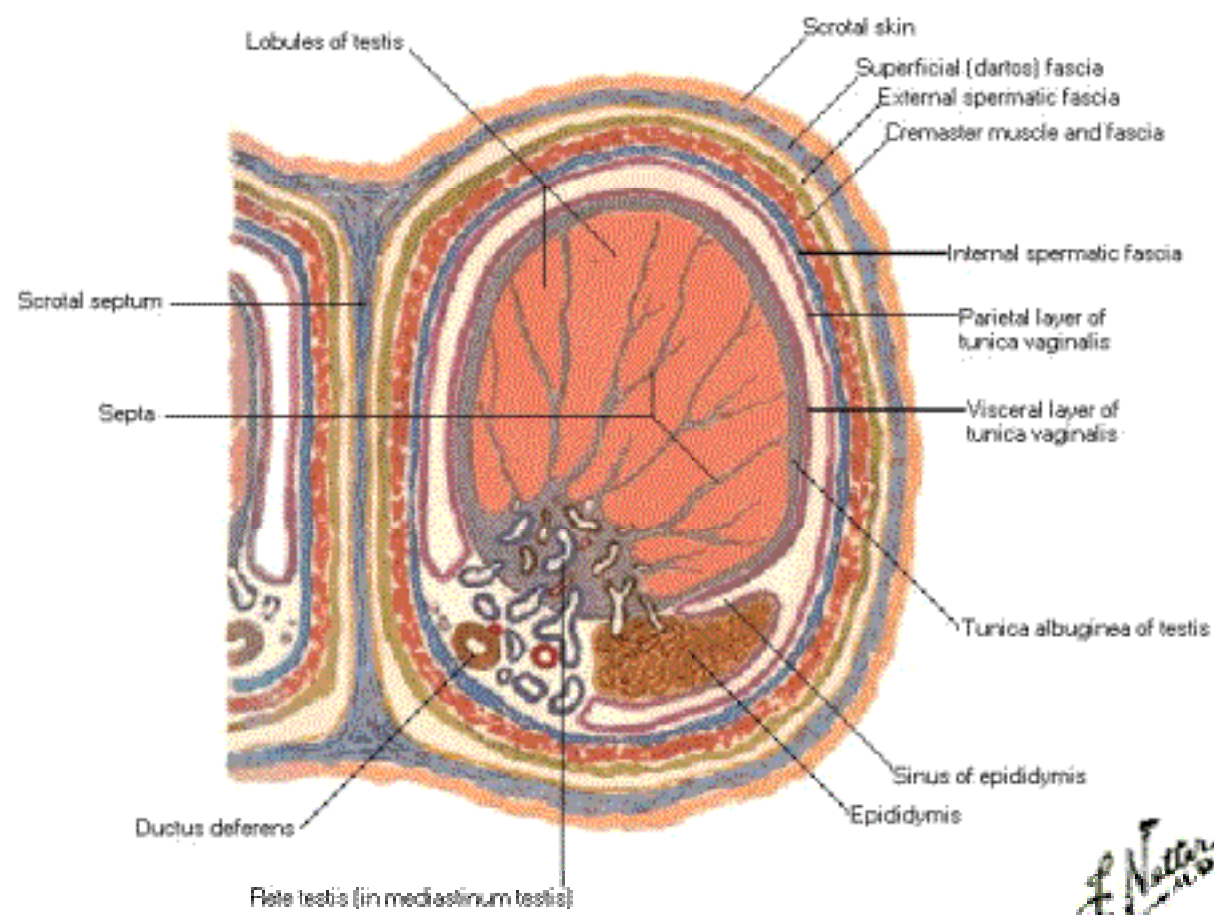
Schema



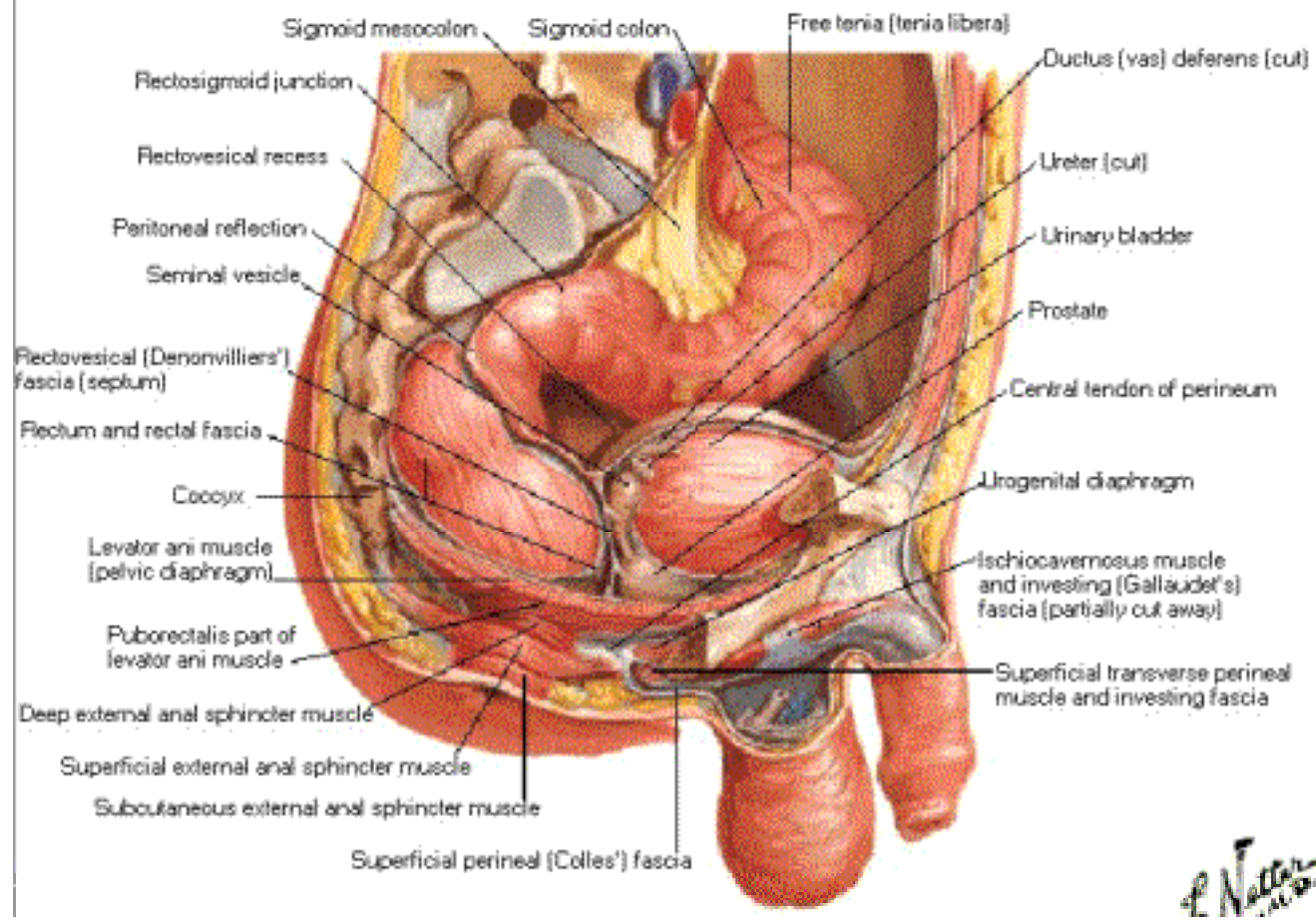
www.123rf.com

Testis, Epididymis and Ductus Deferens

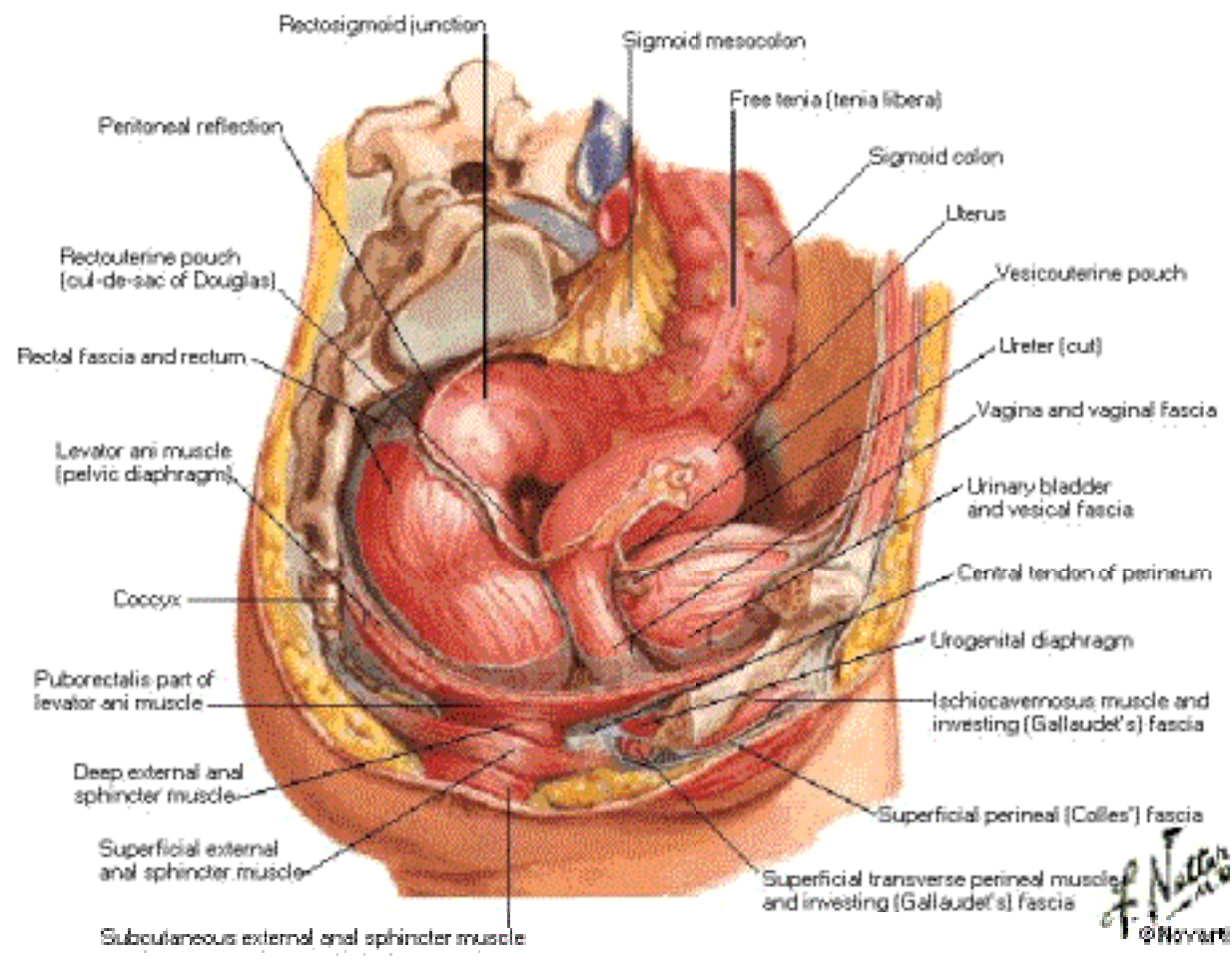
Cross Section



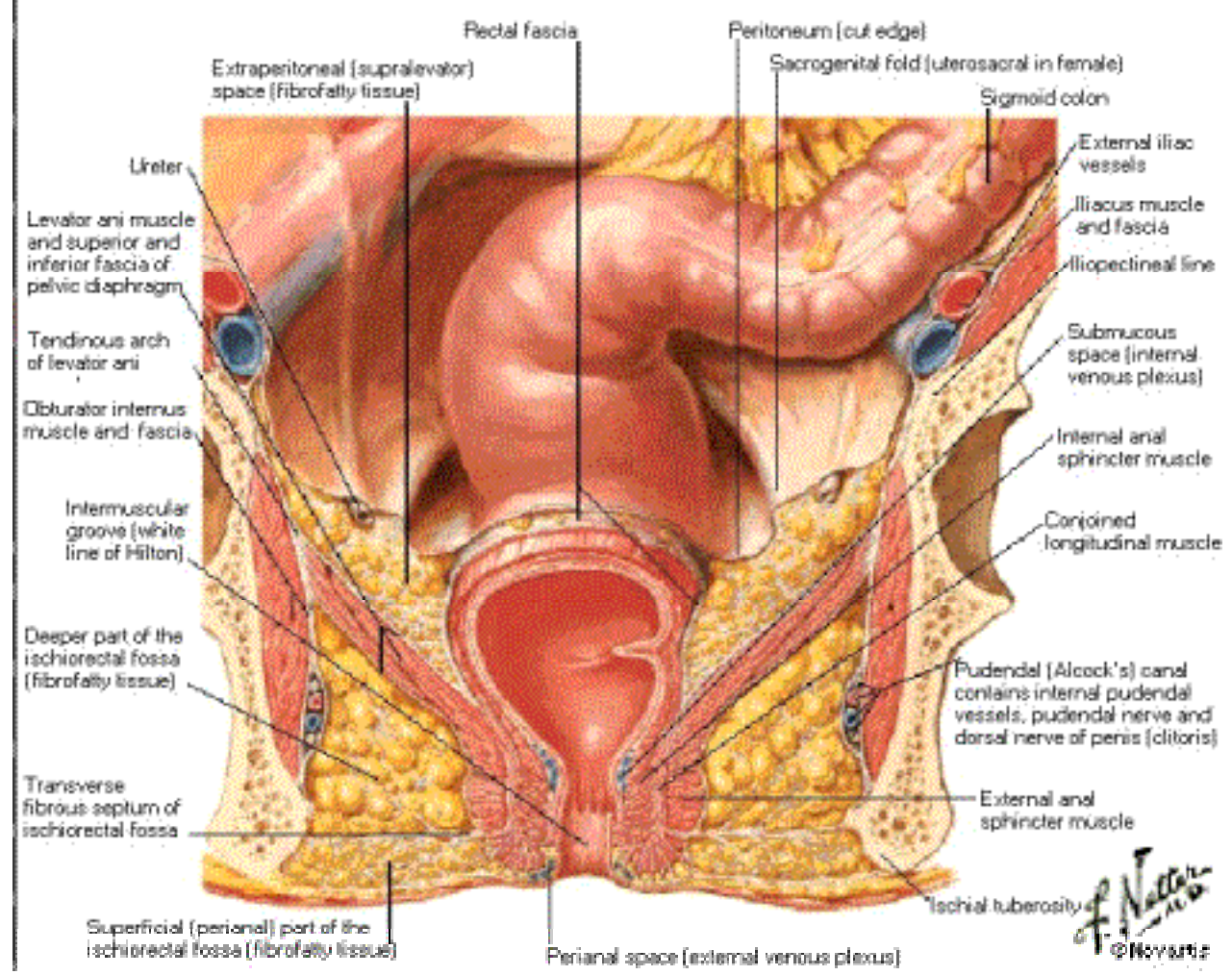
Rectum of Male in Situ



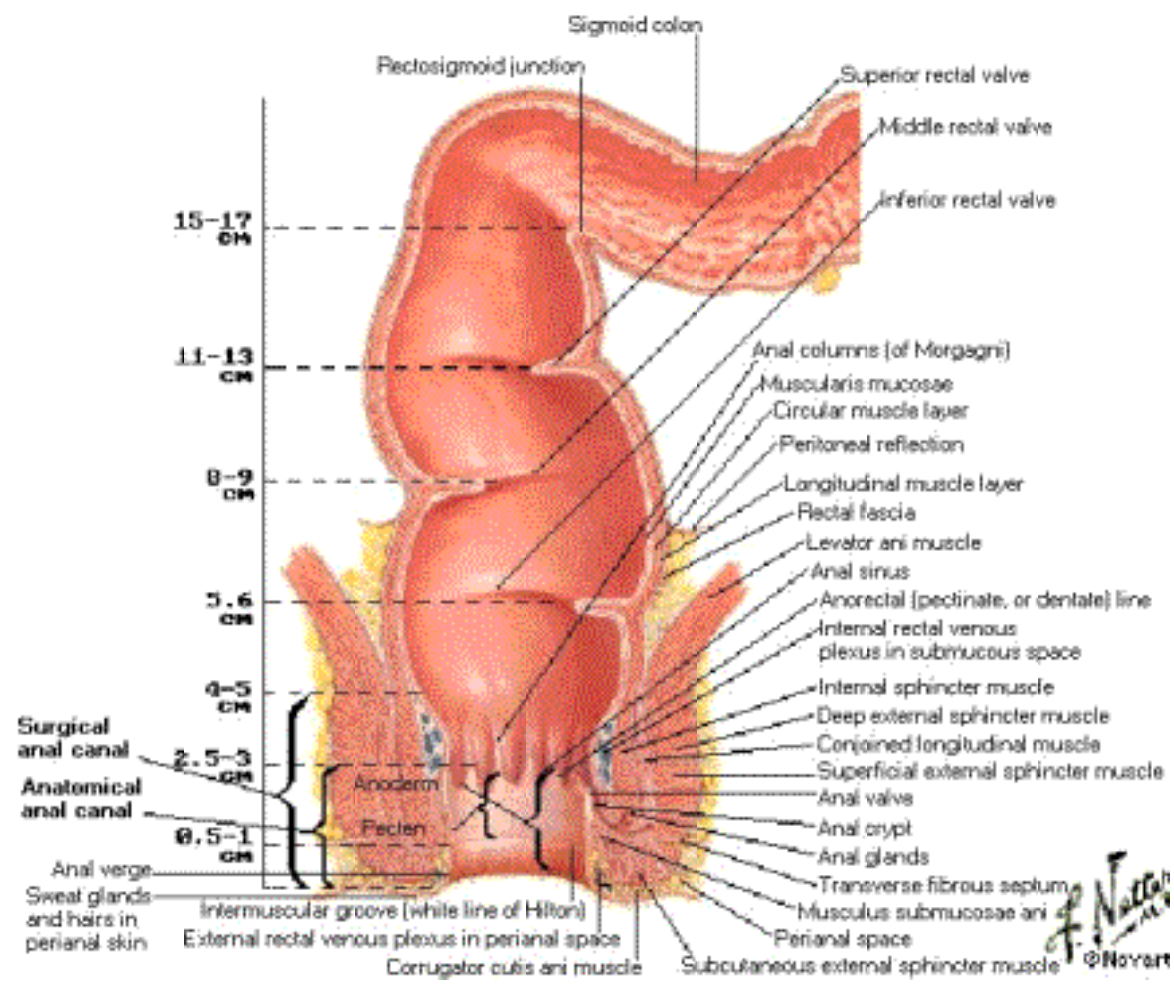
Rectum of Female in Situ



Ischiorectal Fossa

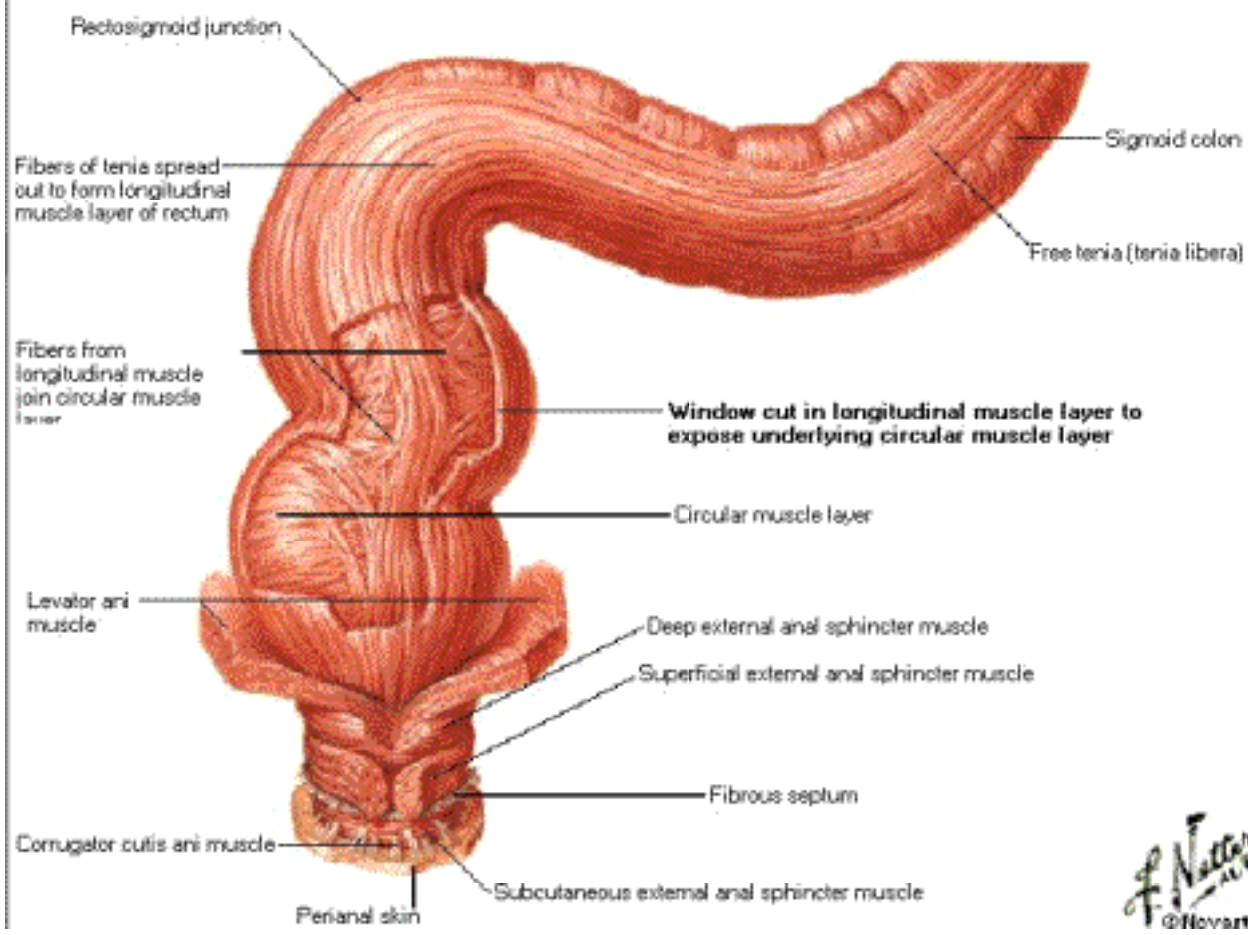


Rectum and Anal Canal

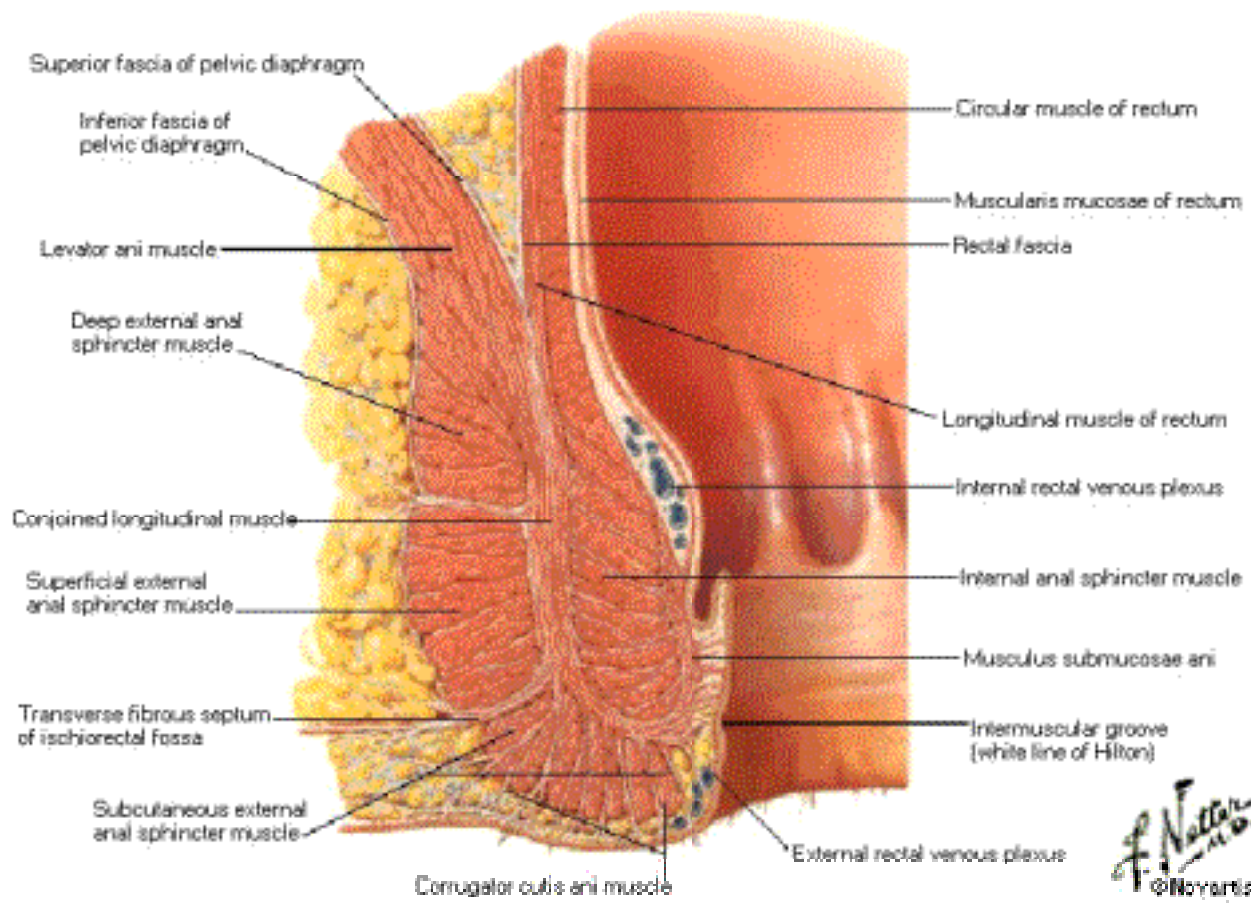


Anorectal Musculature

Anterior View

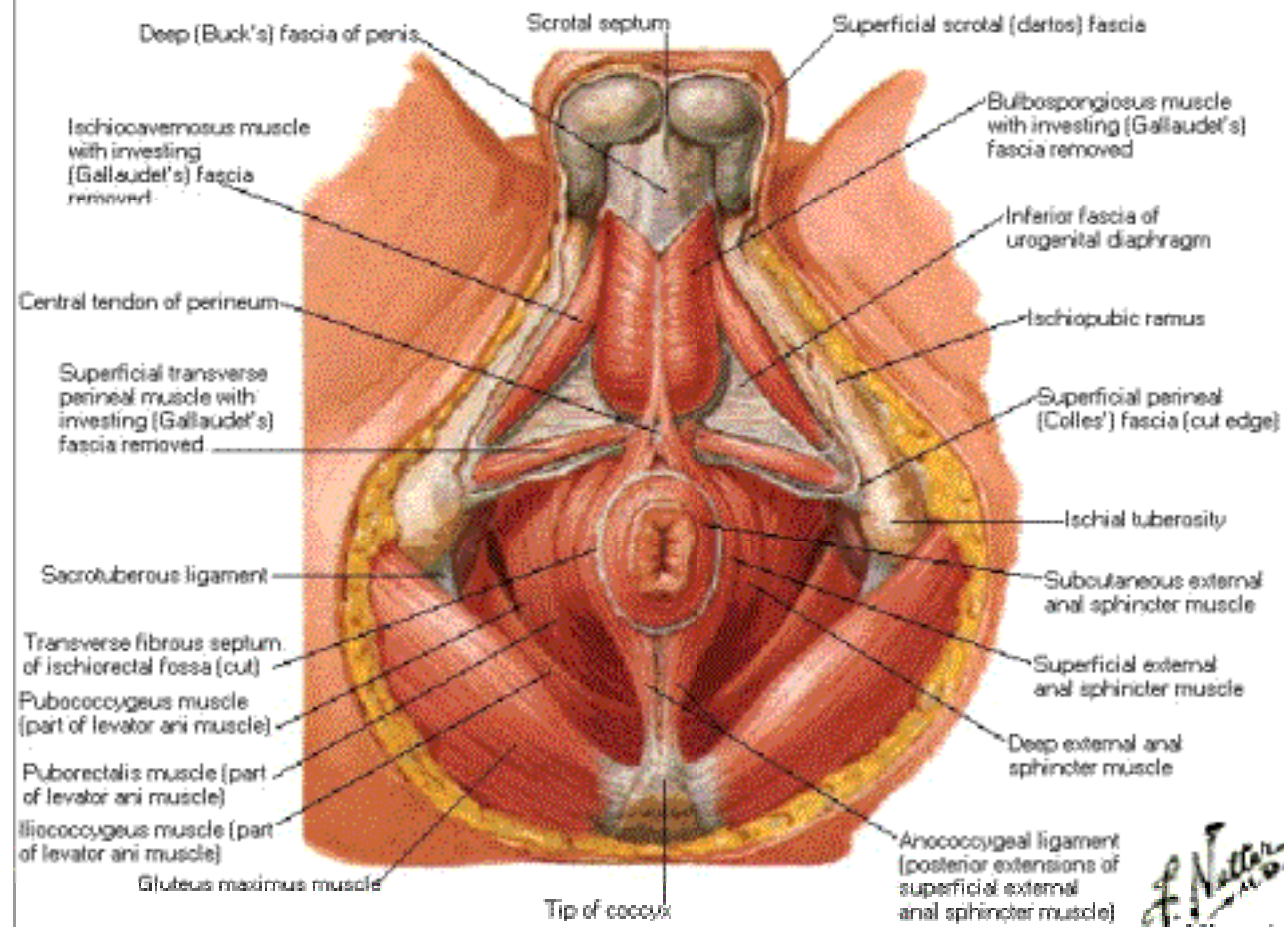


Anorectal Musculature Frontal Section



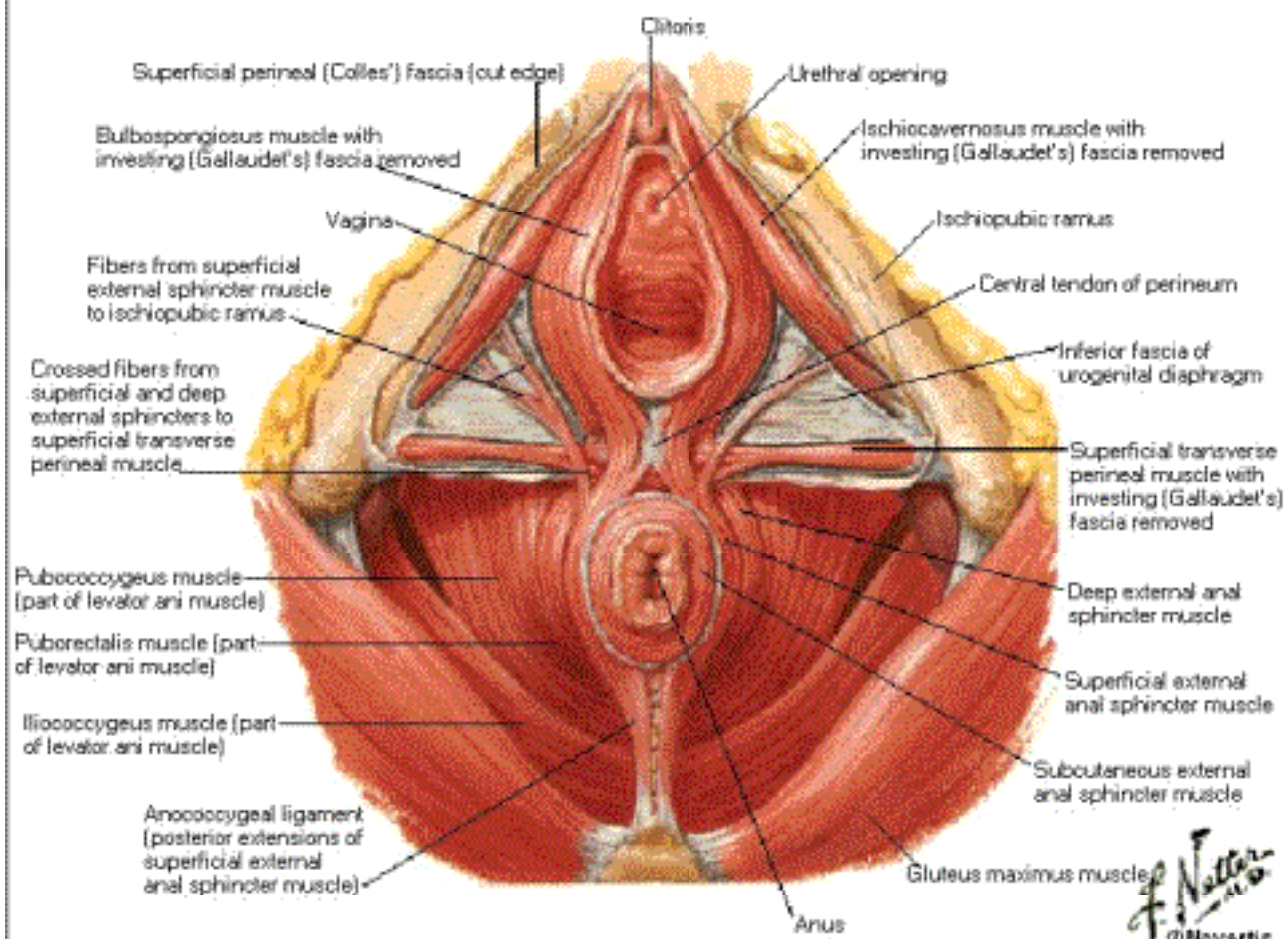
External Anal Sphincter Muscle of Male

Perineal View



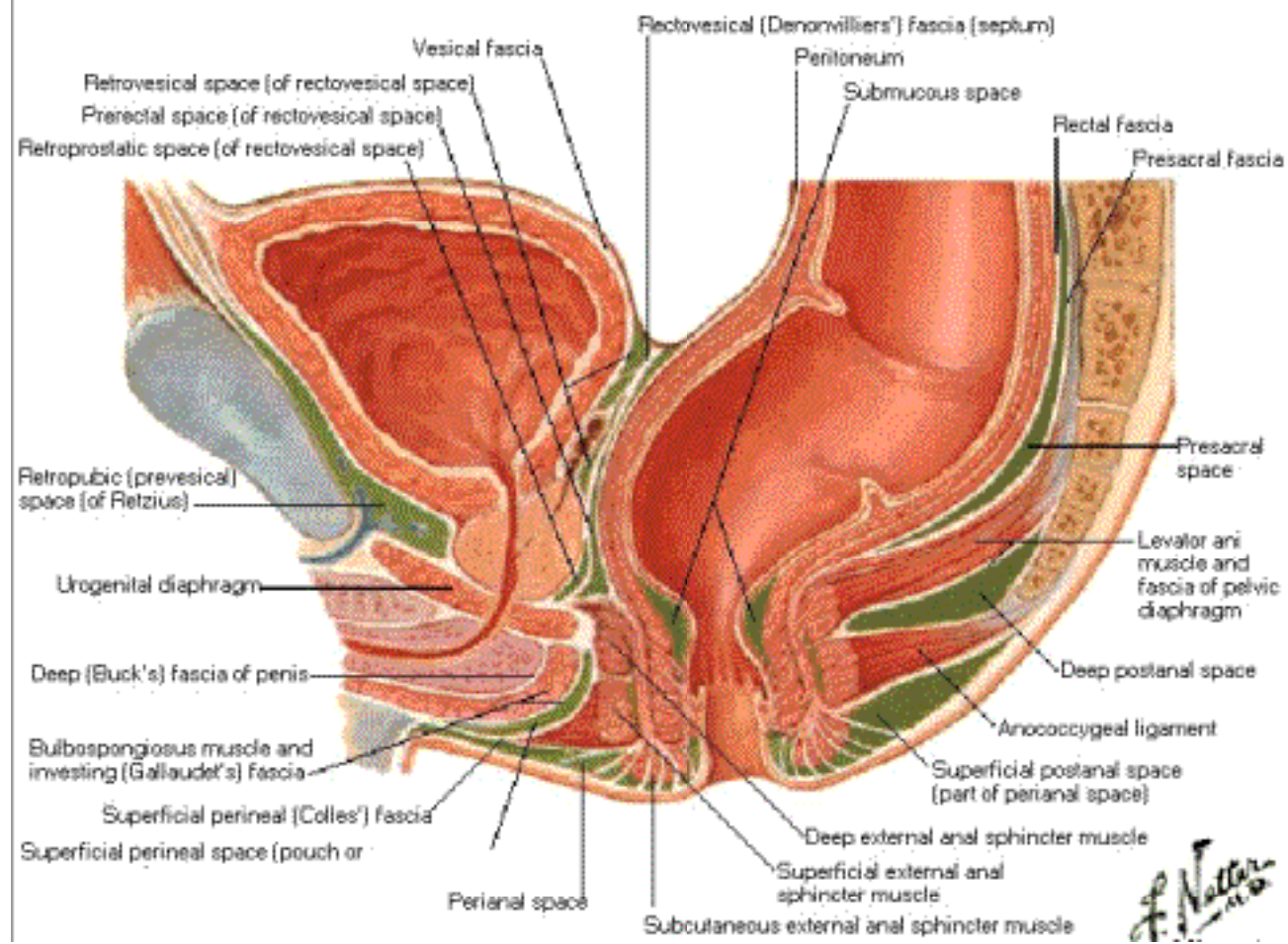
External Anal Sphincter Muscle of Female

Perineal View



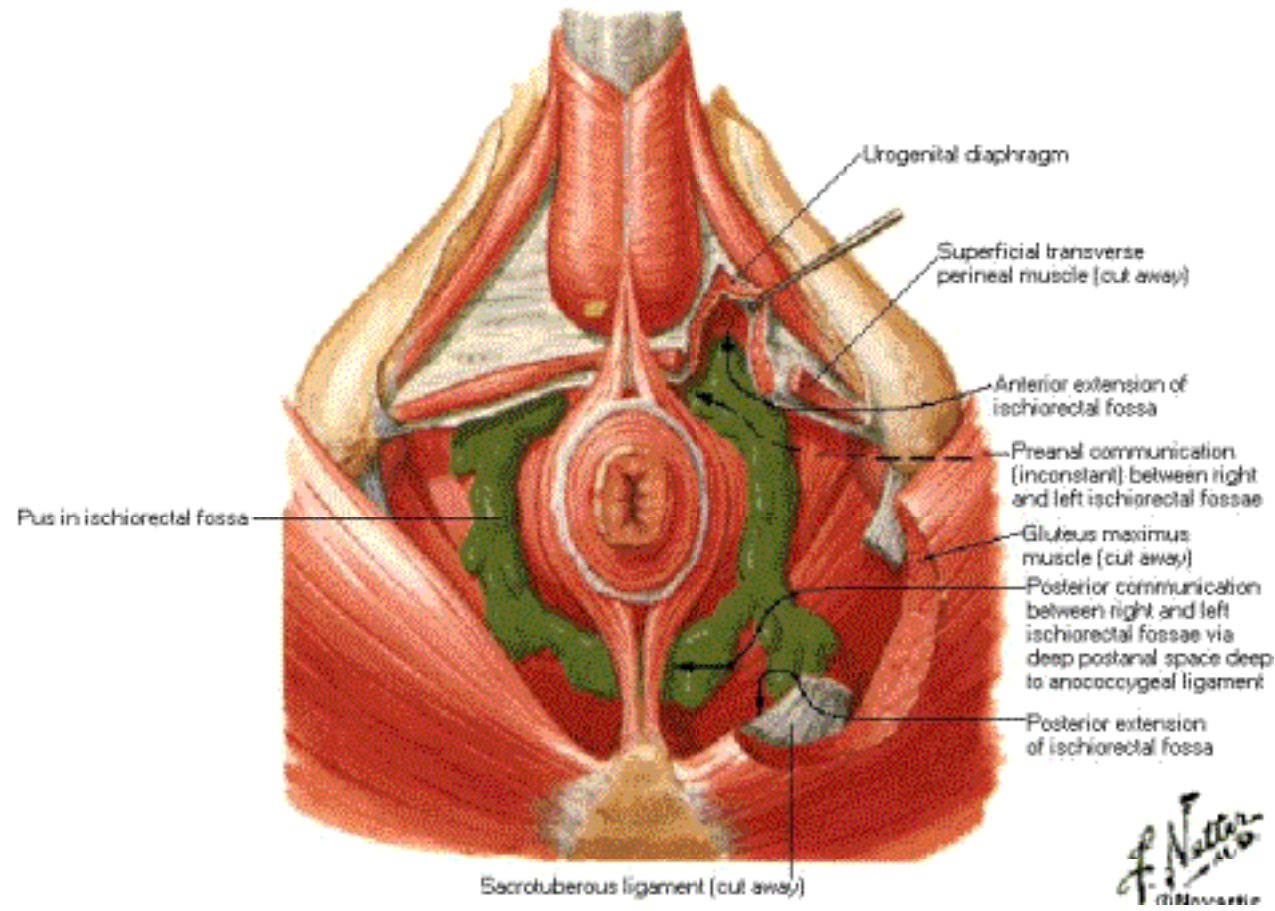
Perineopelvic Spaces

Sagittal Section

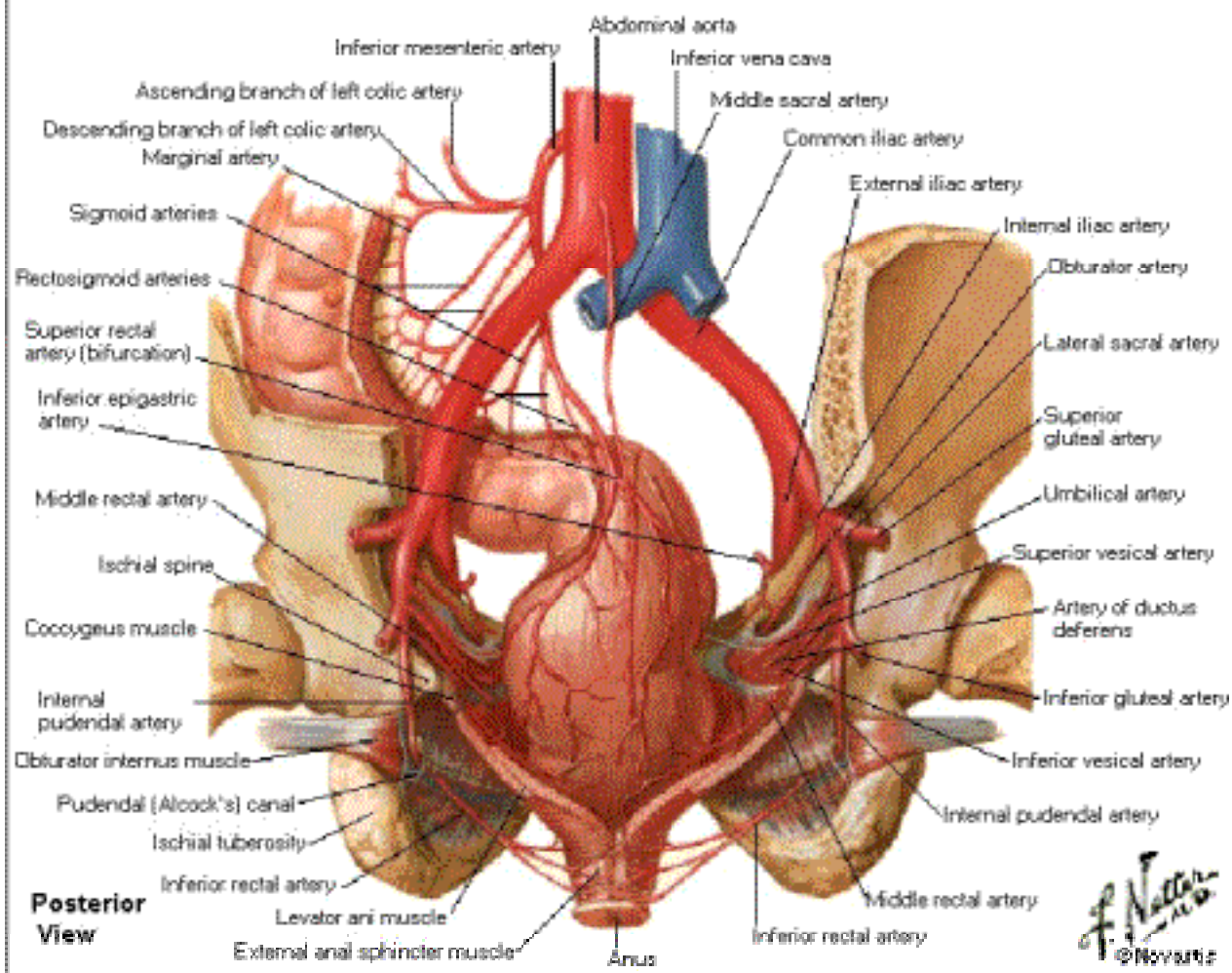


Perineopelvic Spaces

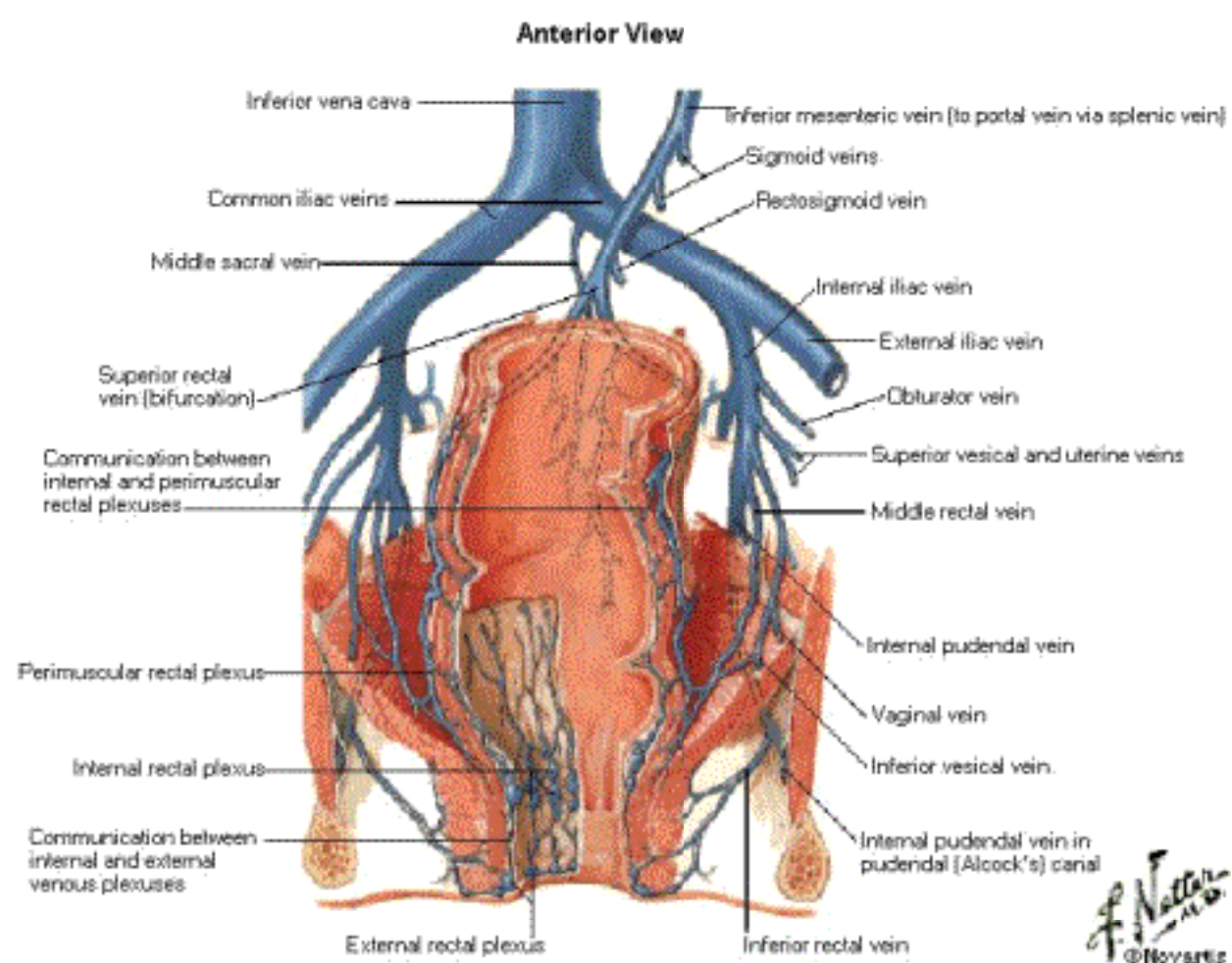
Perineal View



Arteries of Rectum and Anal Canal



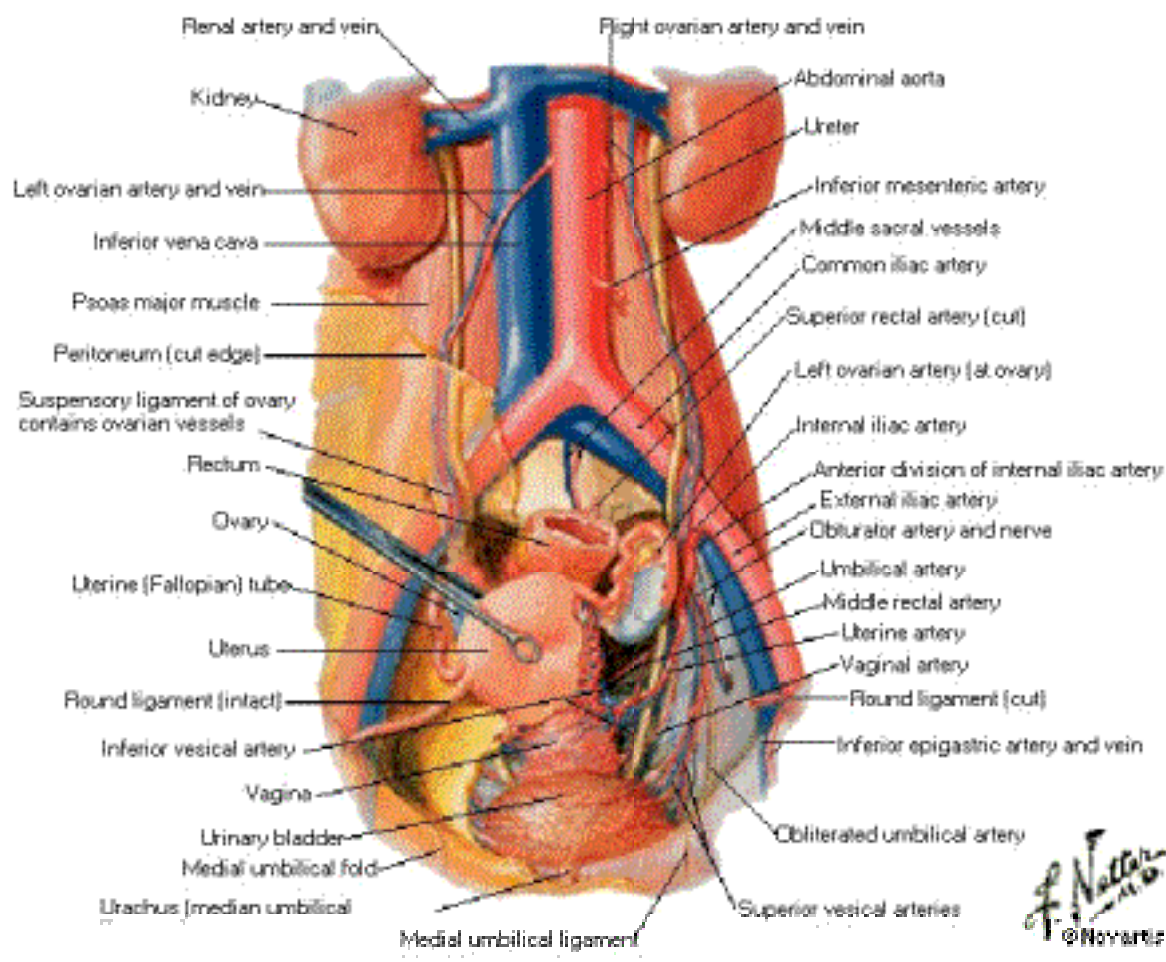
Veins of Rectum and Anal Canal



Arteries and Veins of Pelvic Organs

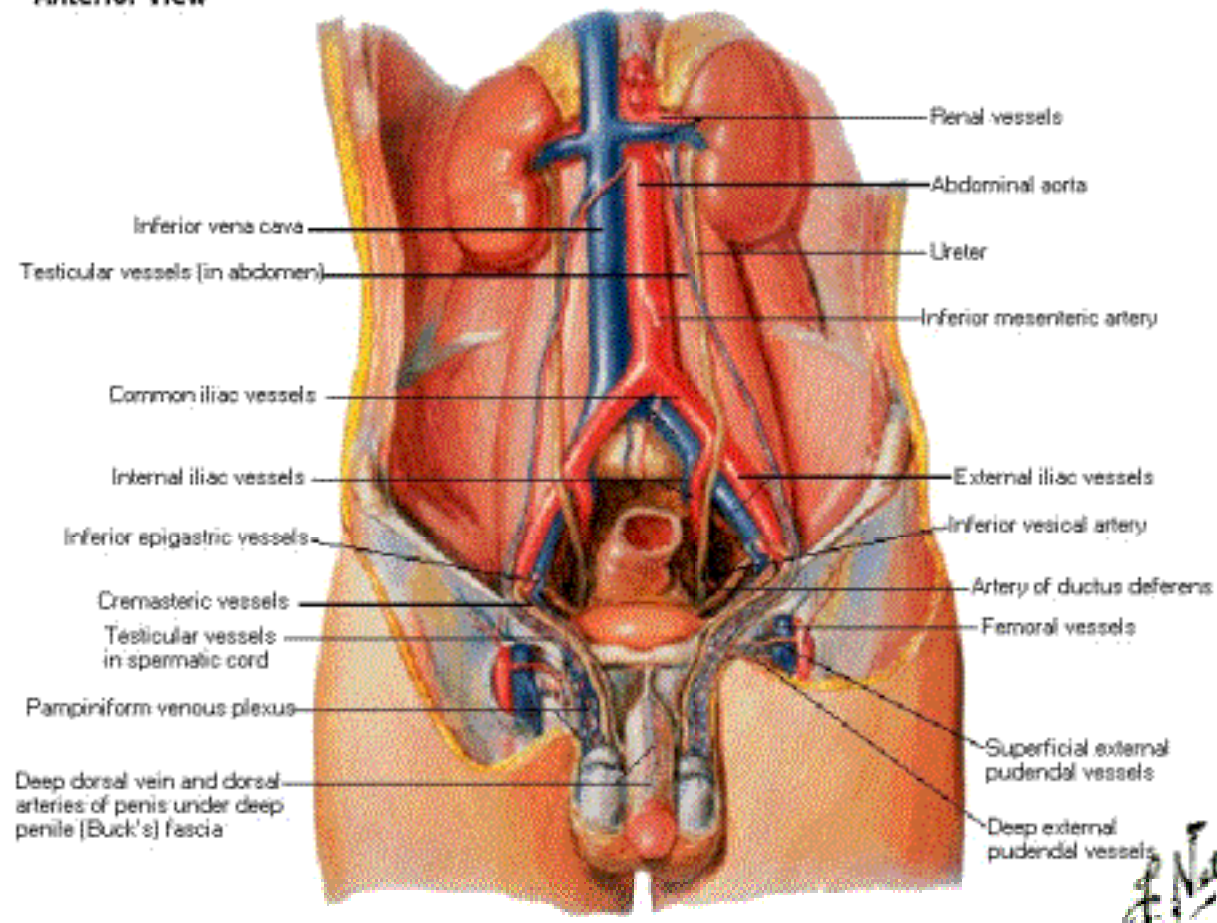
Anterior View

Female



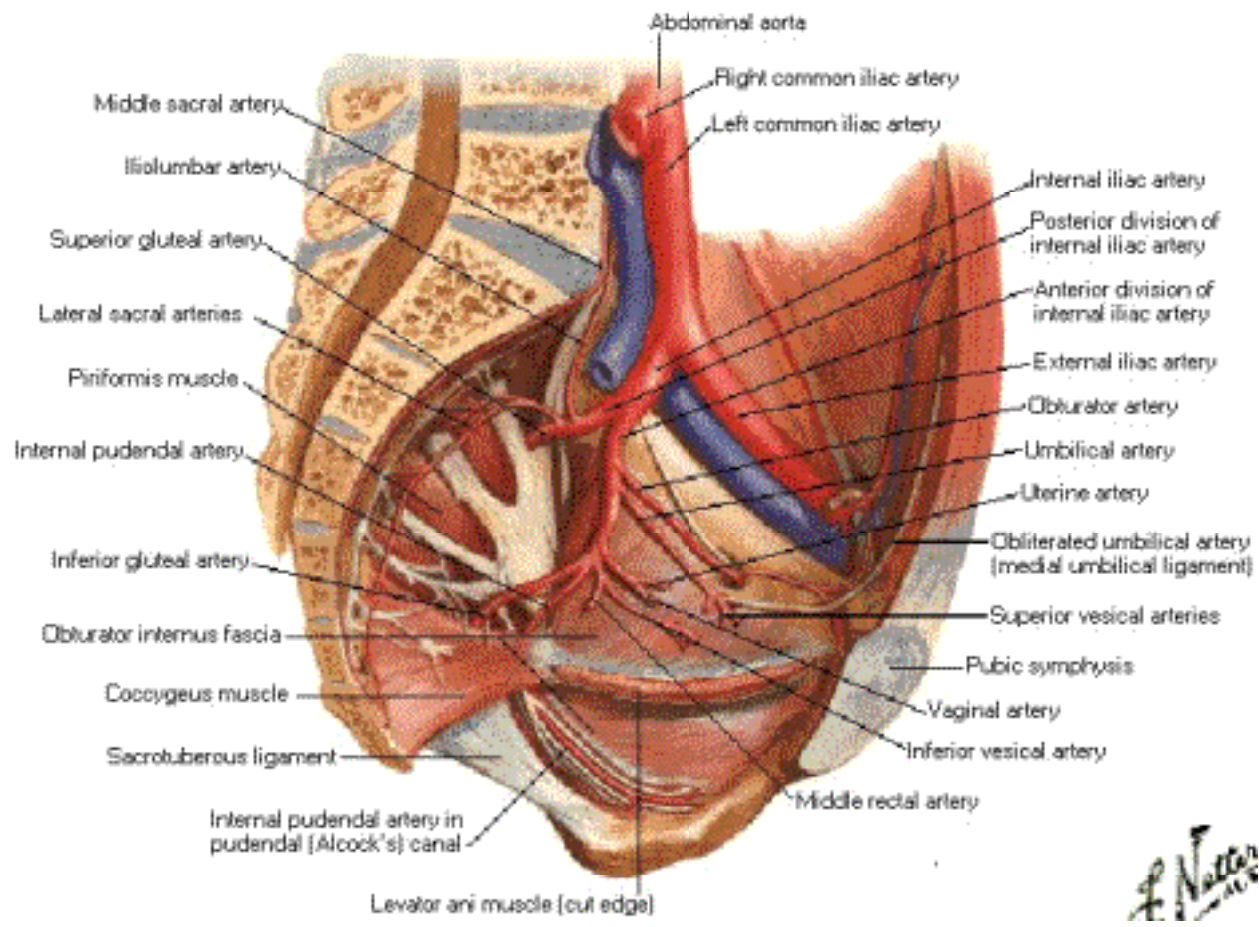
Arteries and Veins of Testis

Anterior View



Arteries and Veins of Pelvis

Female - Sagittal Section

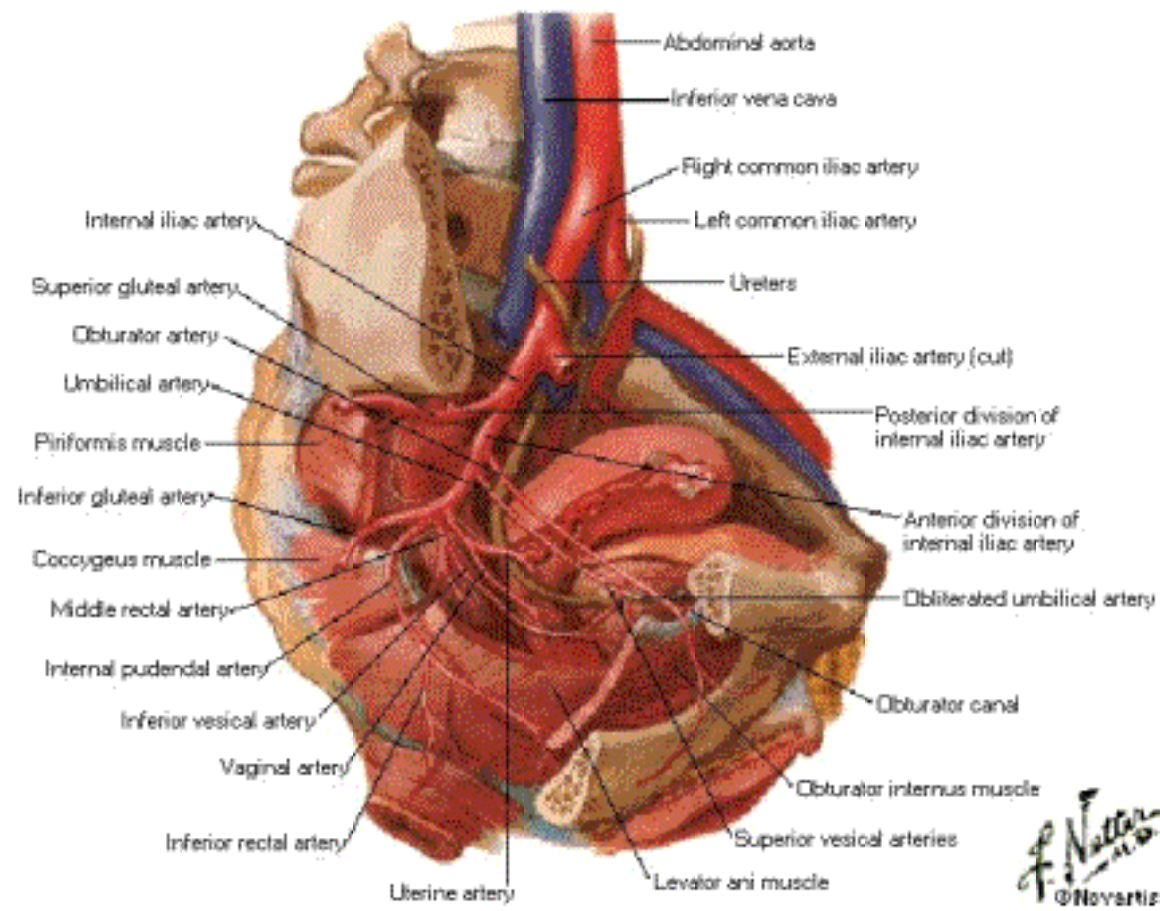


F. Netter M.D.

Arteries and Veins of Pelvis

Female - Right Paramedian Section

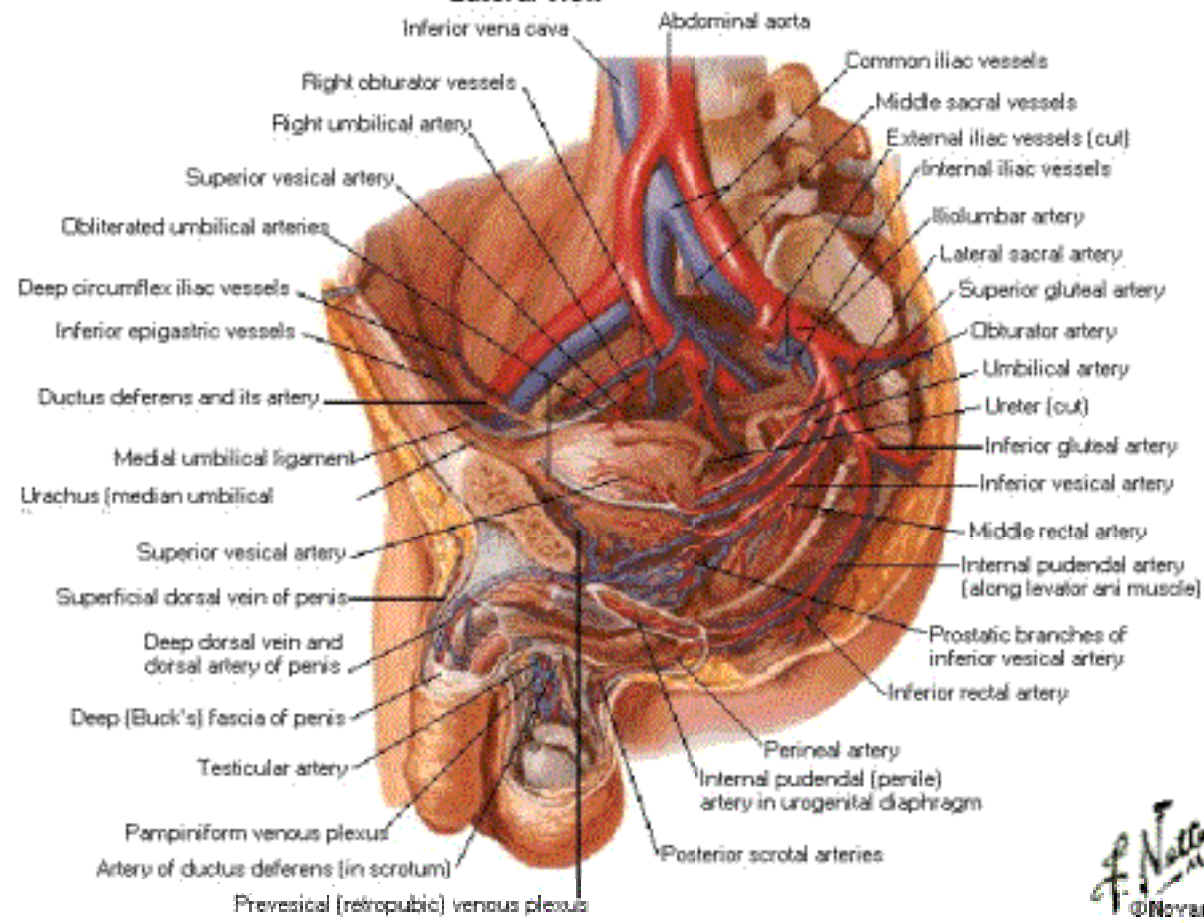
Lateral View



Arteries and Veins of Pelvis

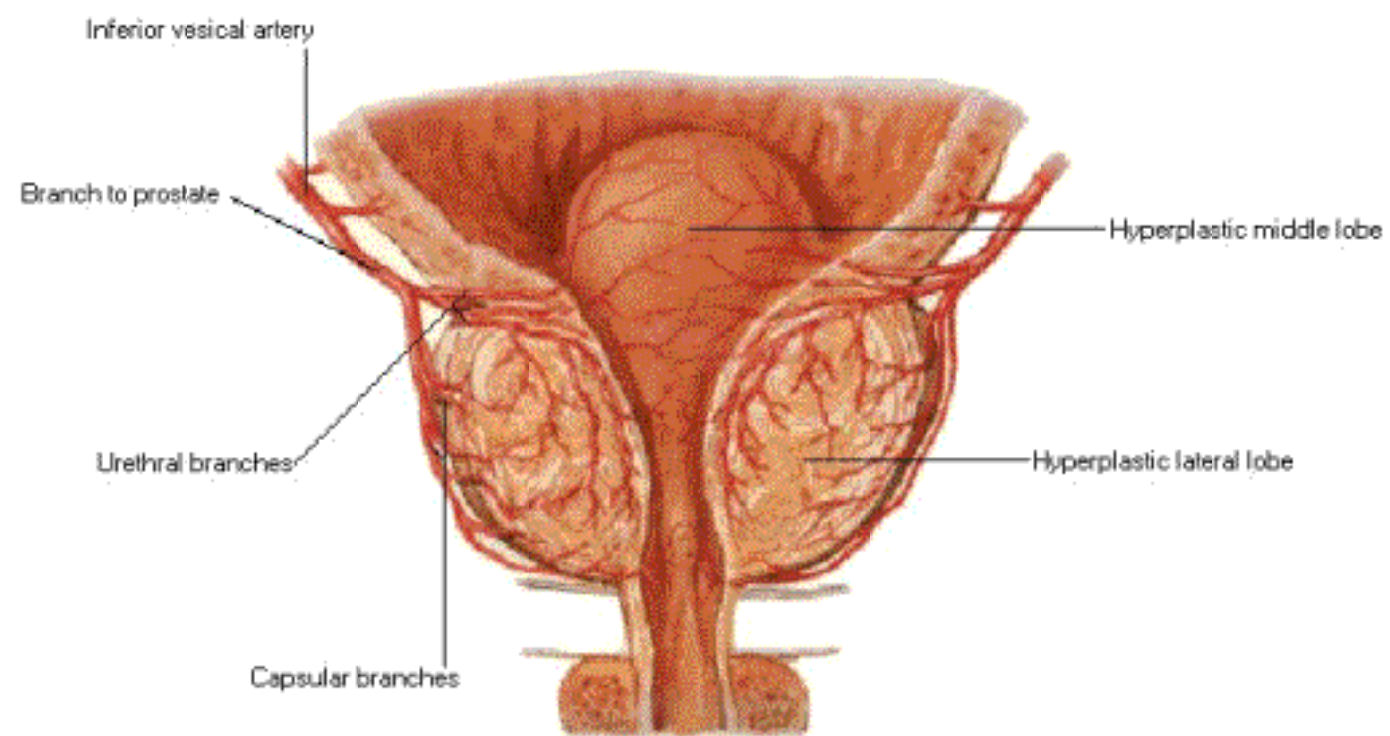
Male - Left Paramedian Section

Lateral View



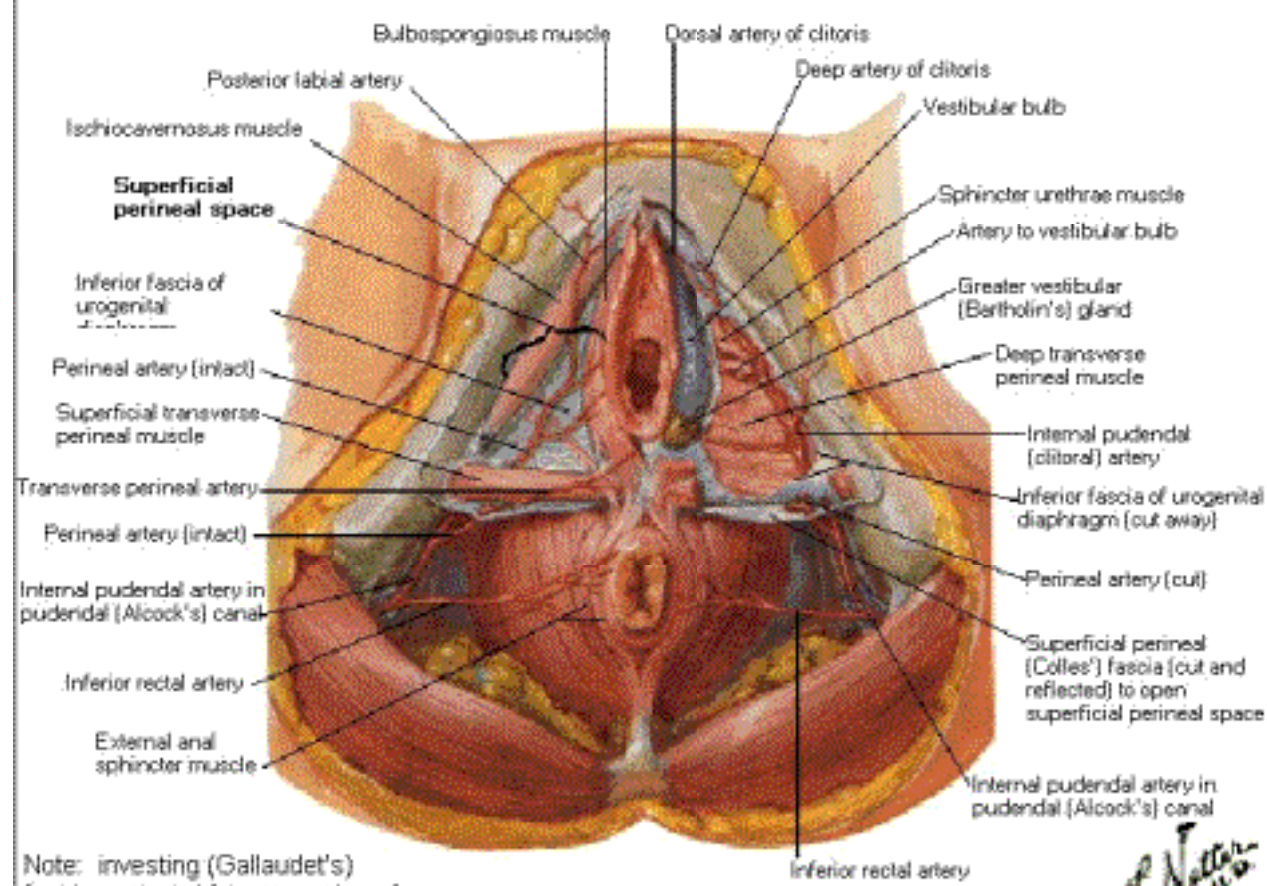
F. N. N. N.
©Novart

Arterial Supply of Prostate



Arteries and Veins of Perineum

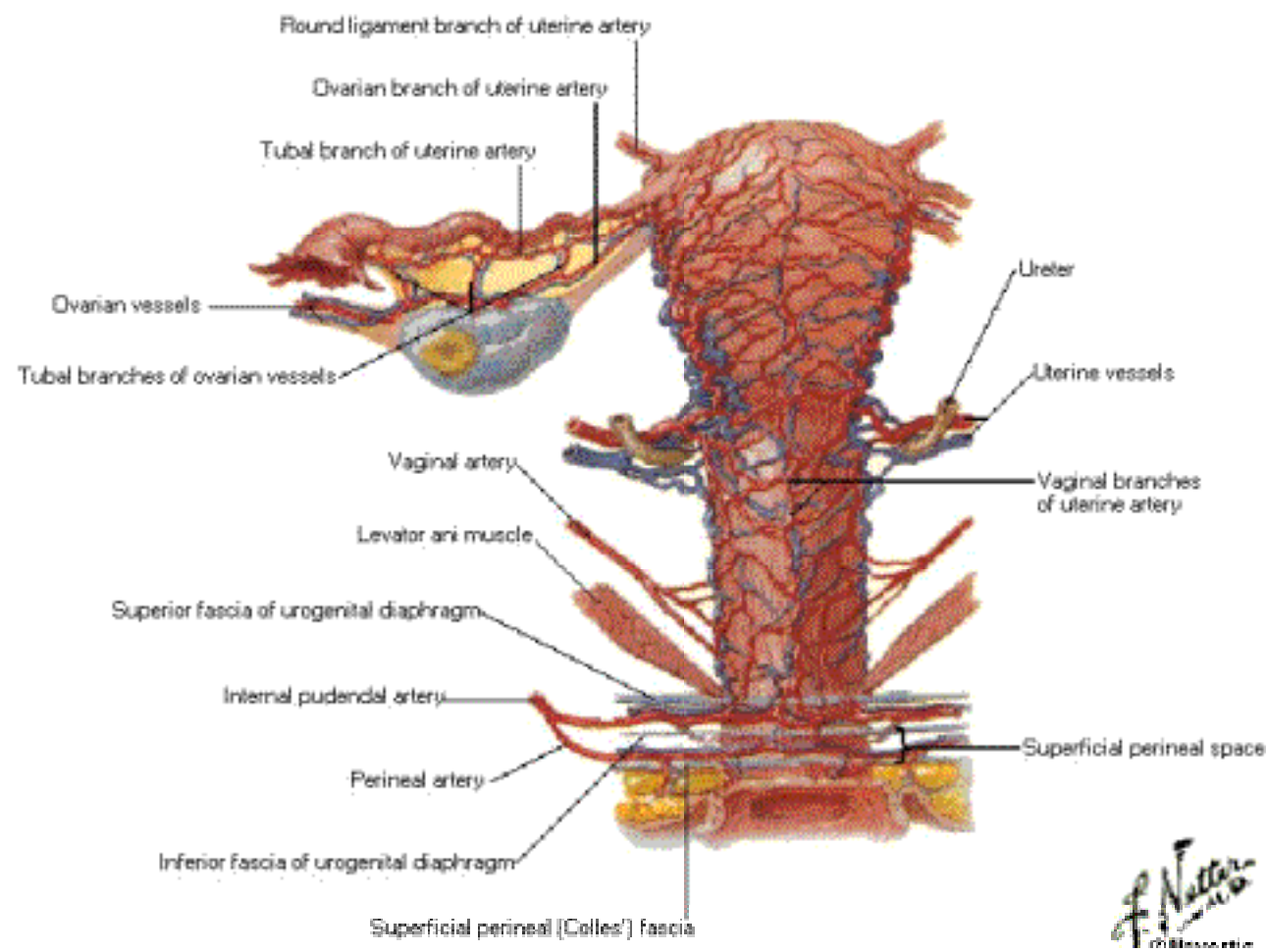
Female



Note: investing (Gallaudet's) fascia removed from muscles of superficial perineal space

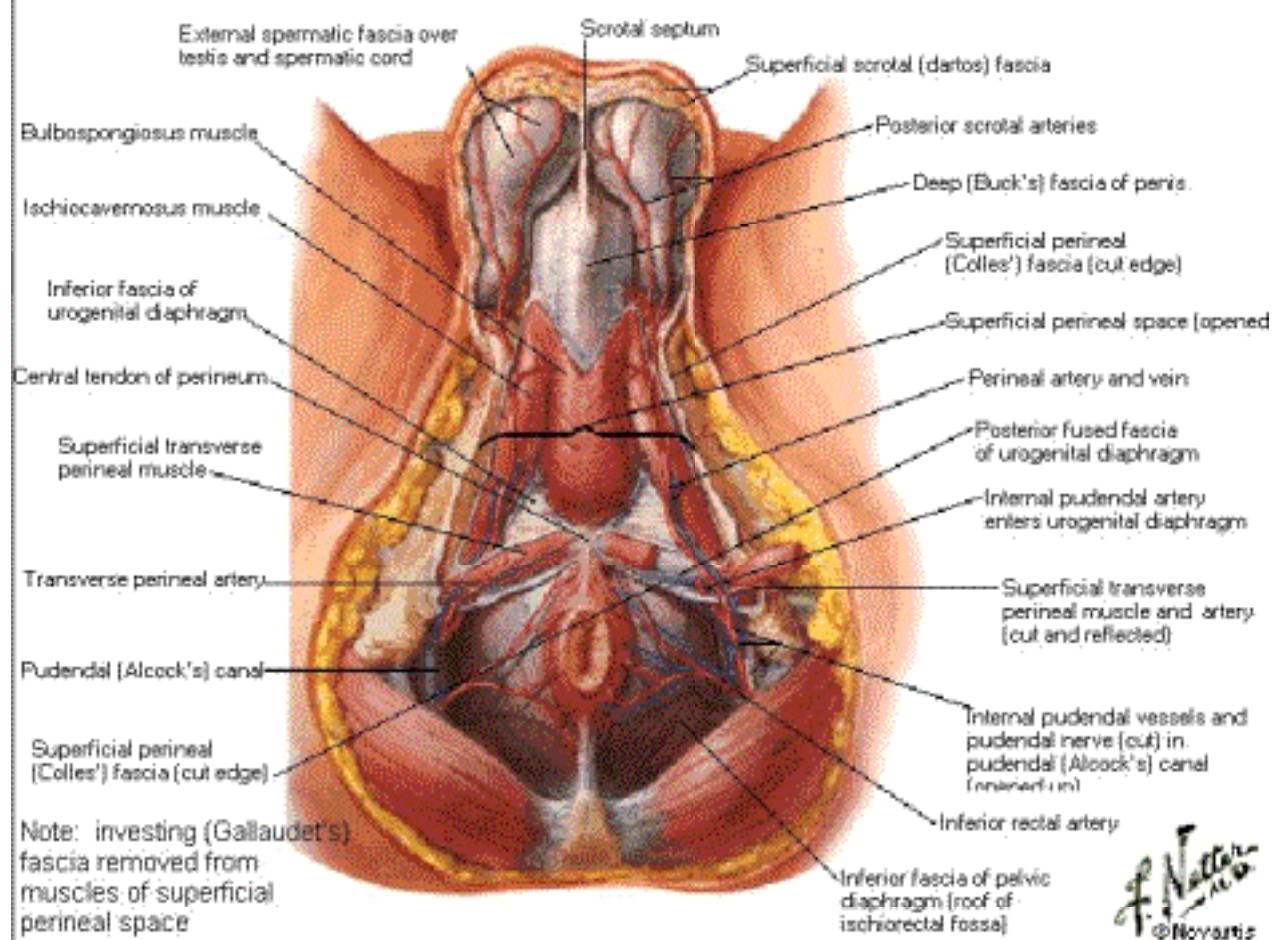
F. Netter M.D.
© 1996

Arteries and Veins of Uterus



Arteries and Veins of Perineum

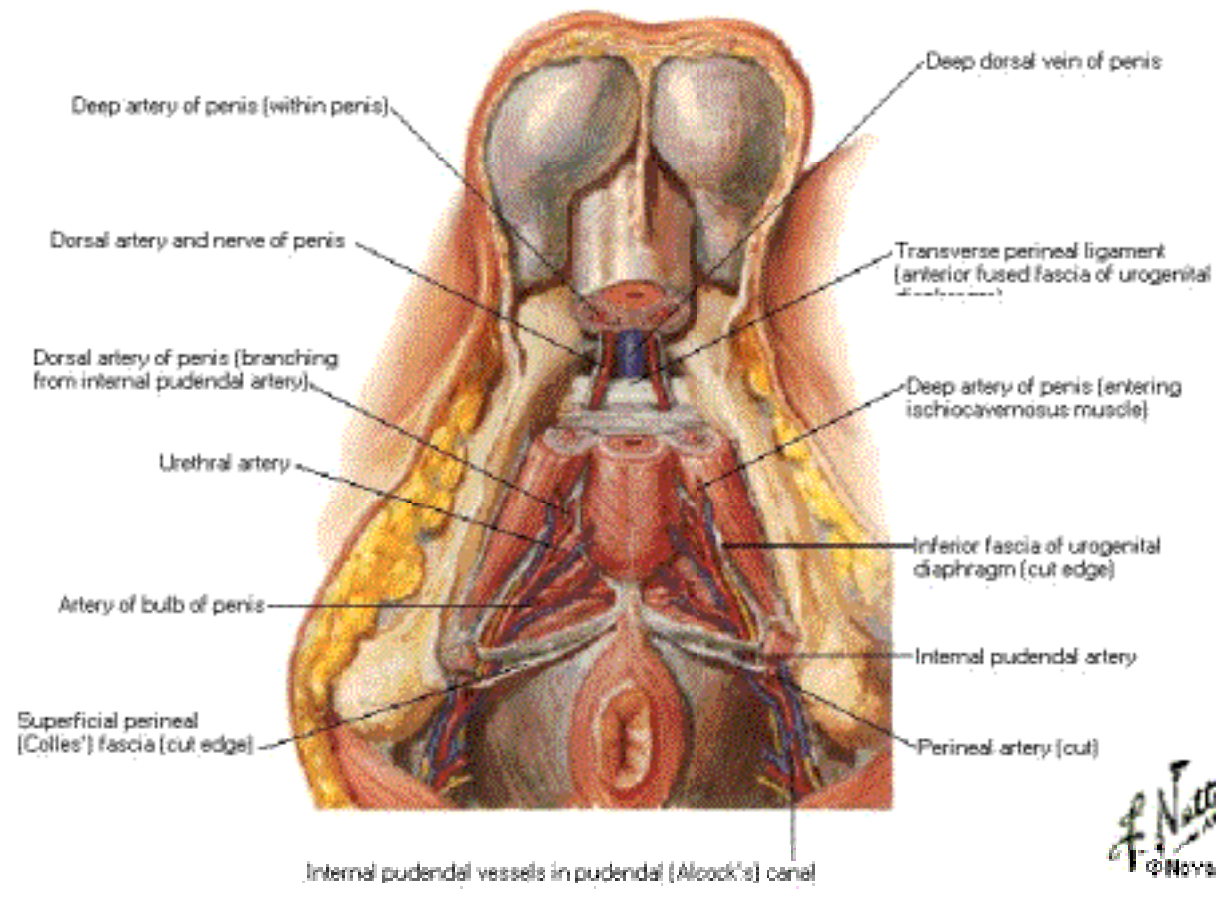
Male



F. Netter M.D.
© Novartis

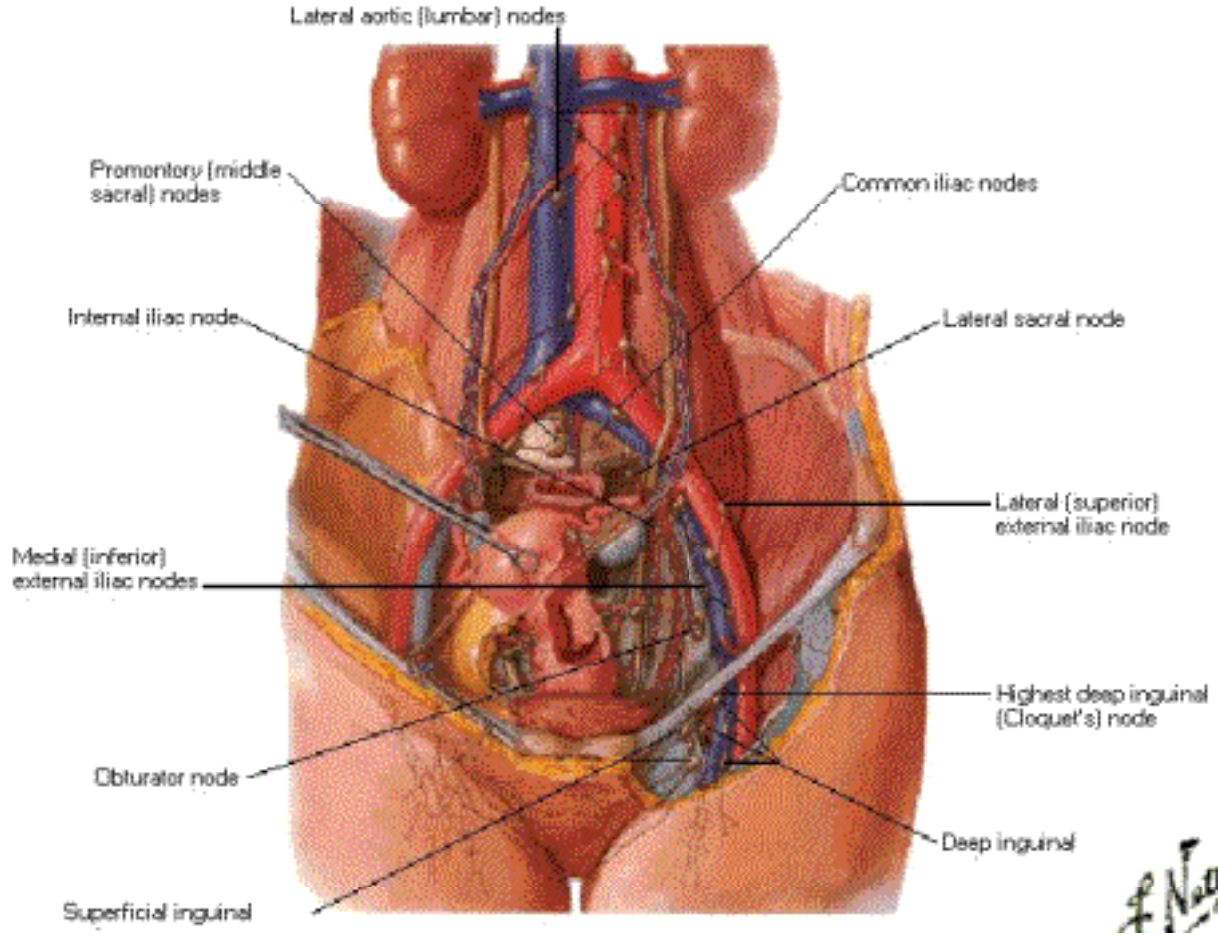
Arteries and Veins of Perineum [Continued]

Male



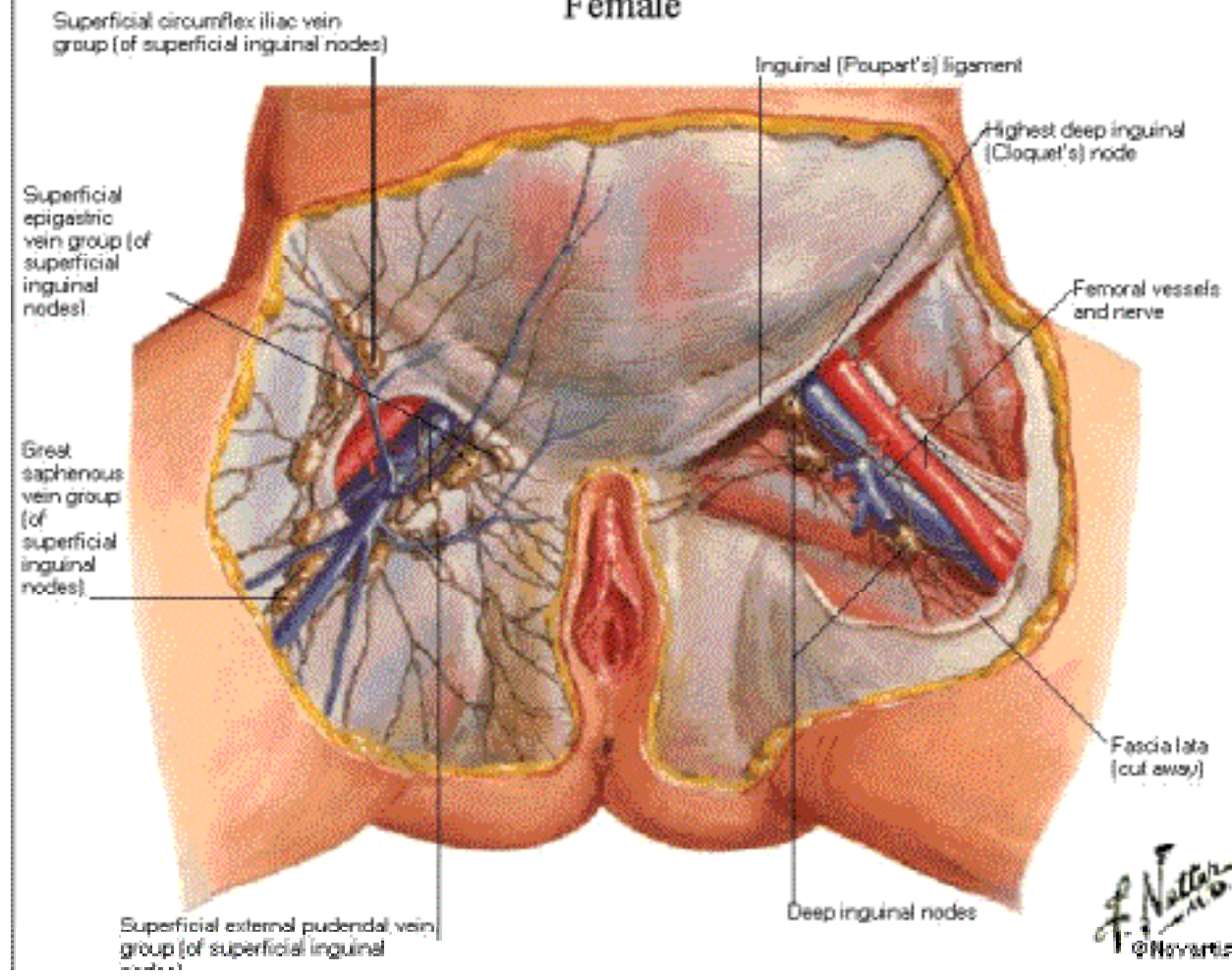
Lymph Vessels and Nodes of Pelvis and Genitalia

Female



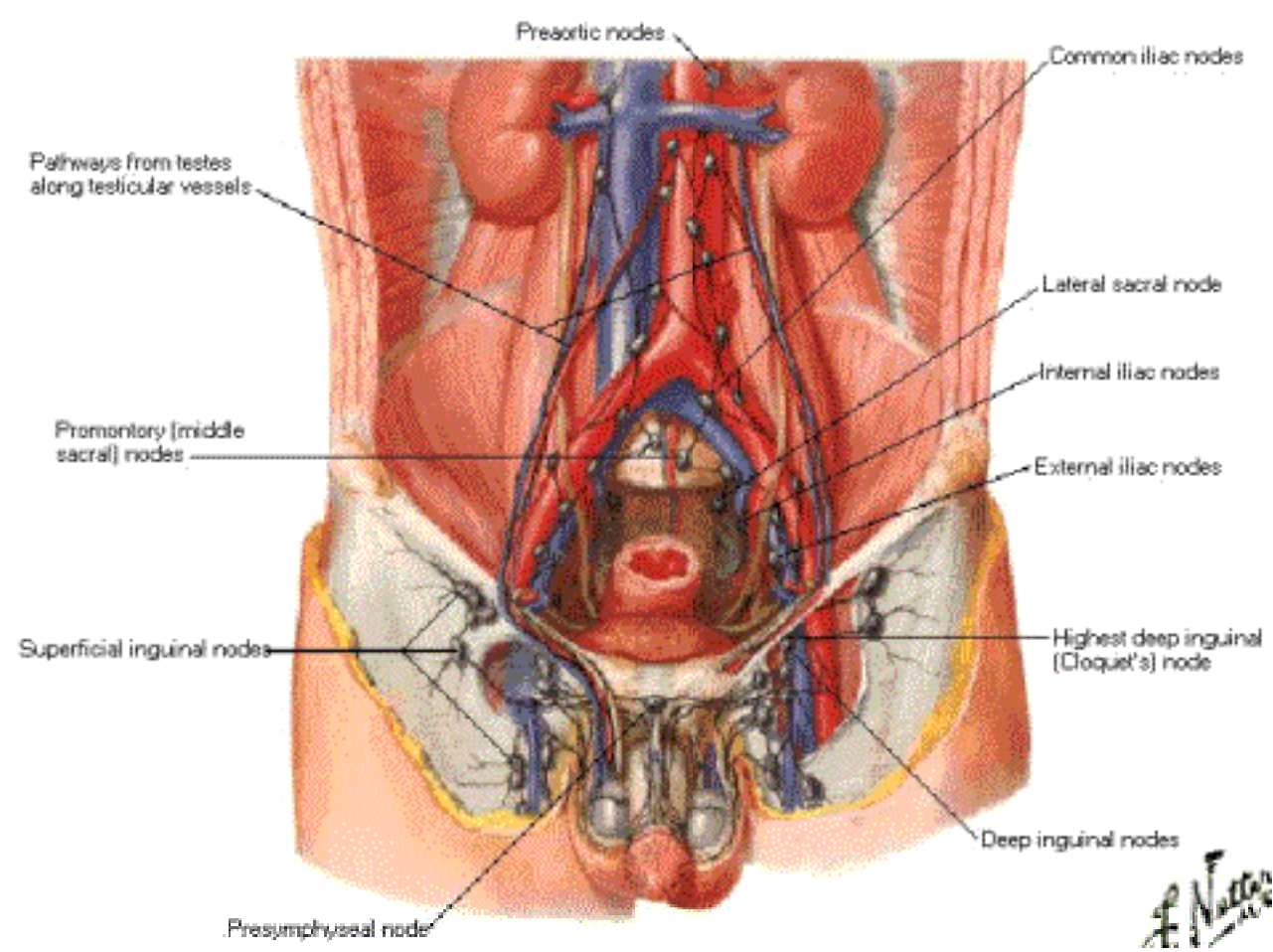
Lymph Vessels and Nodes of Perineum

Female

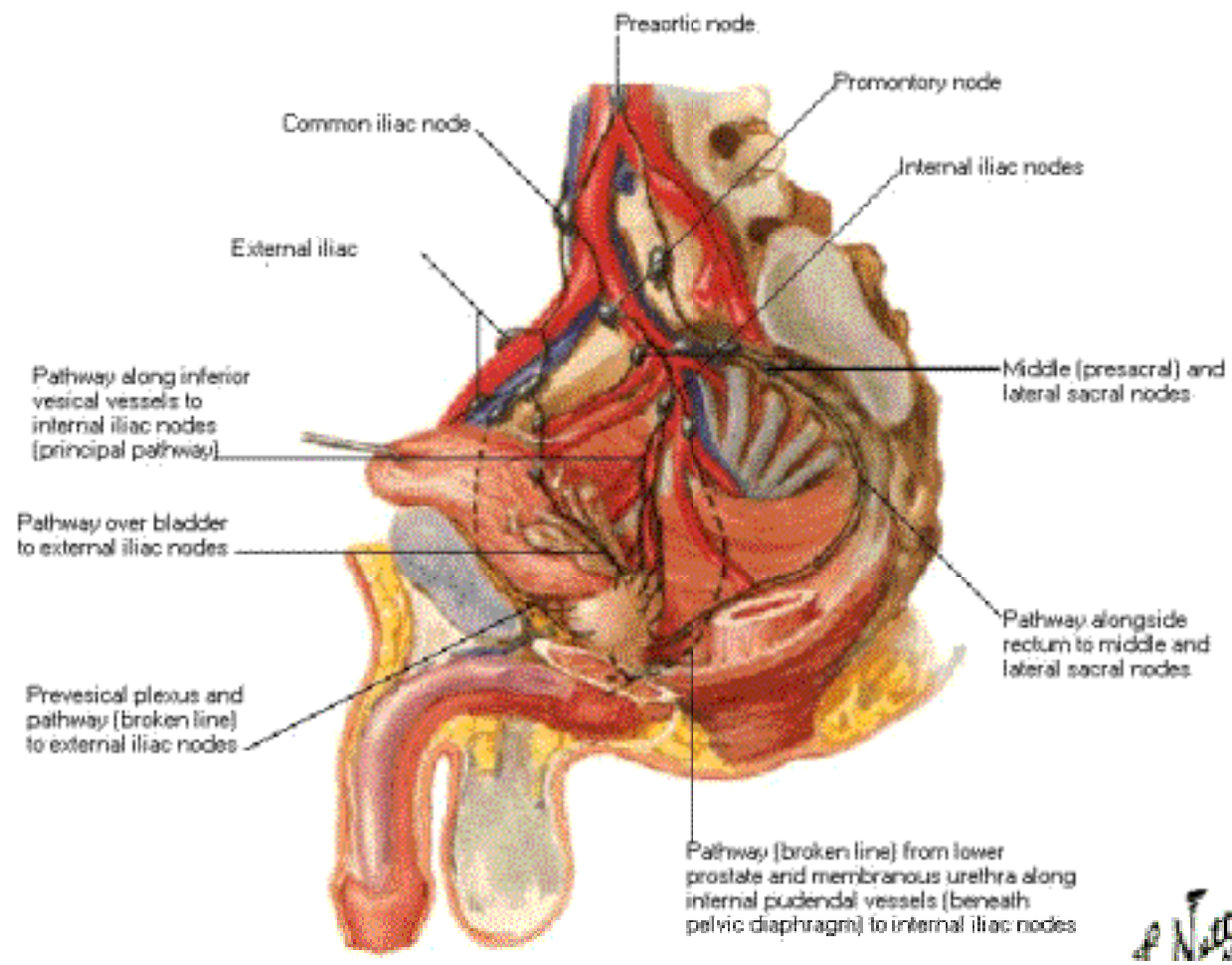


Lymph Vessels and Nodes of Pelvis and Genitalia

Male

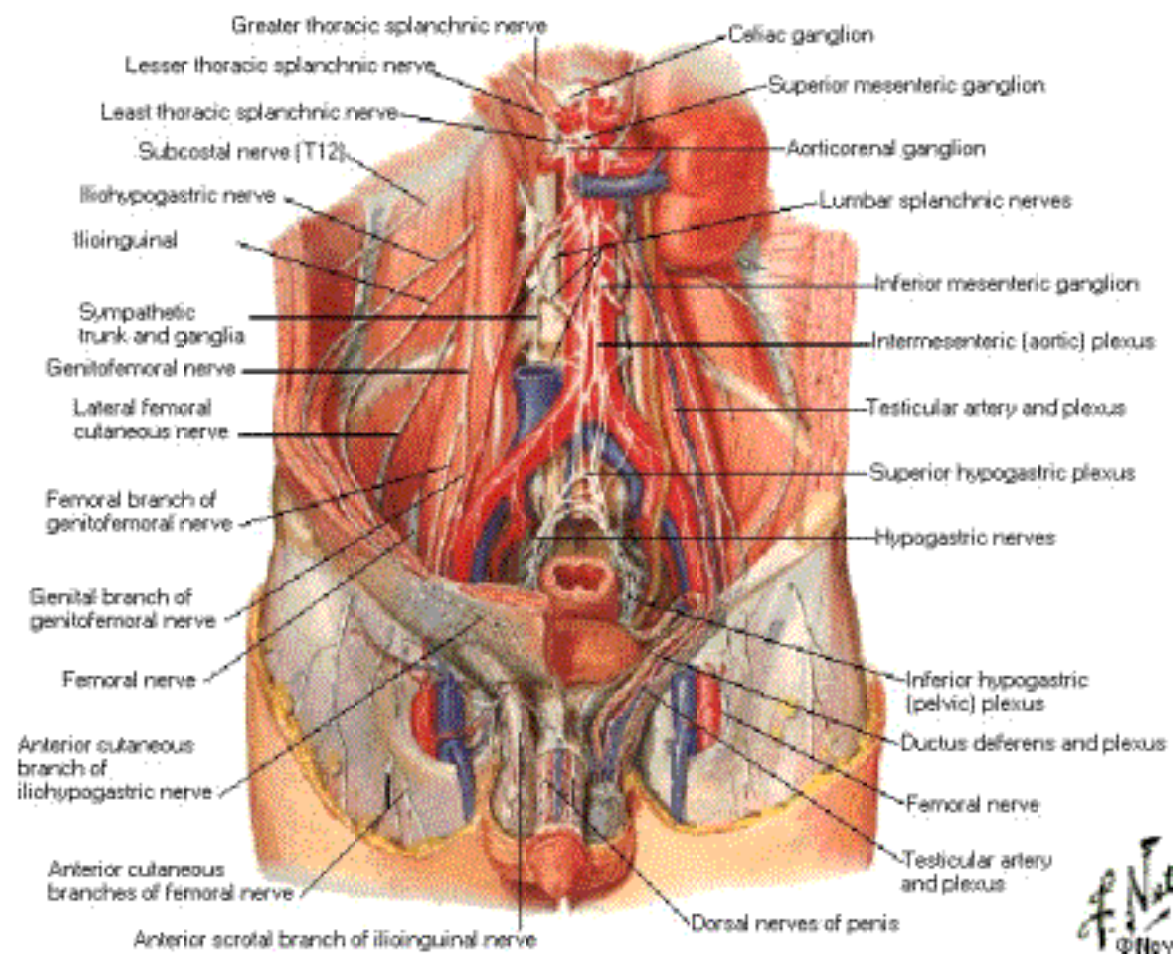


Lymphatic Drainage from Prostate



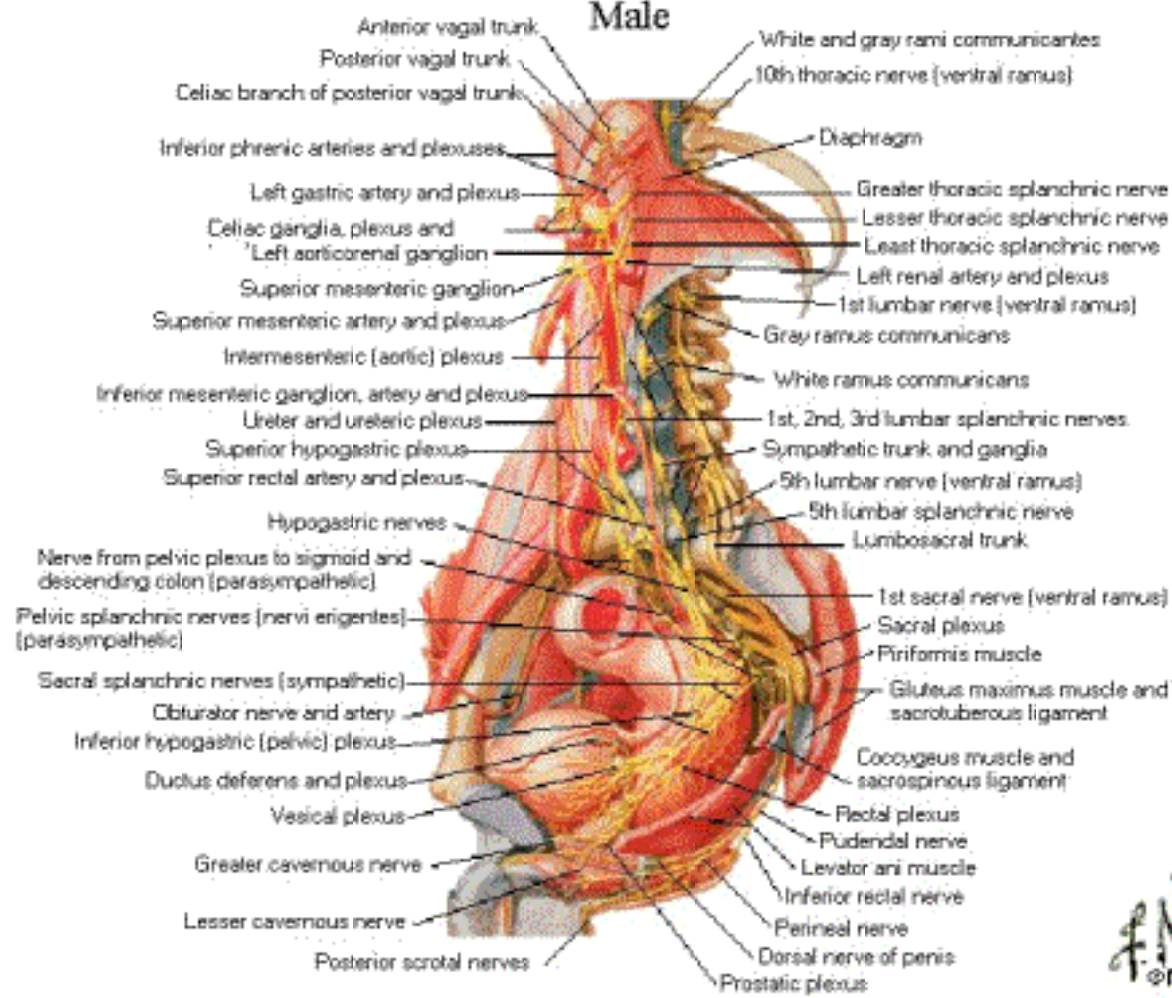
Nerves of External Genitalia

Male



Nerves of Pelvic Viscera

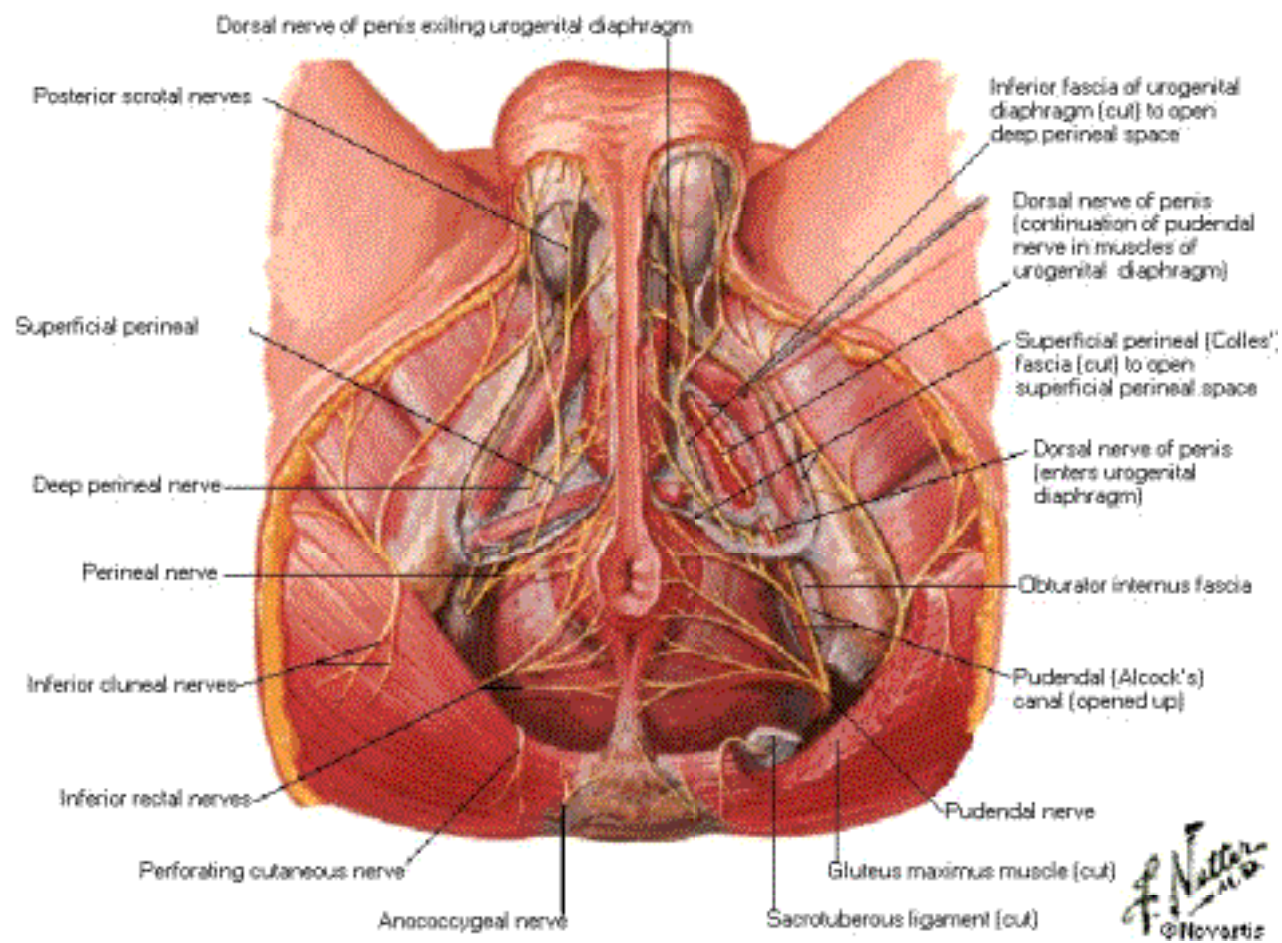
Male



F.N.
© NC

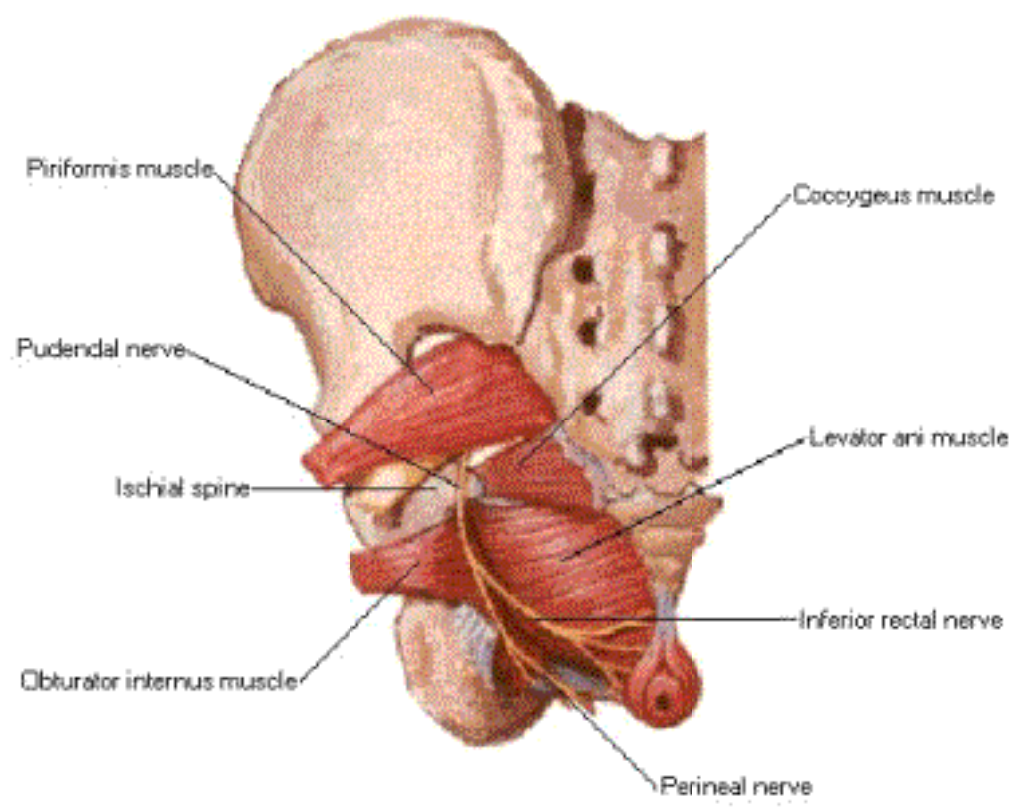
Nerves of Perineum

Male - Perineal View

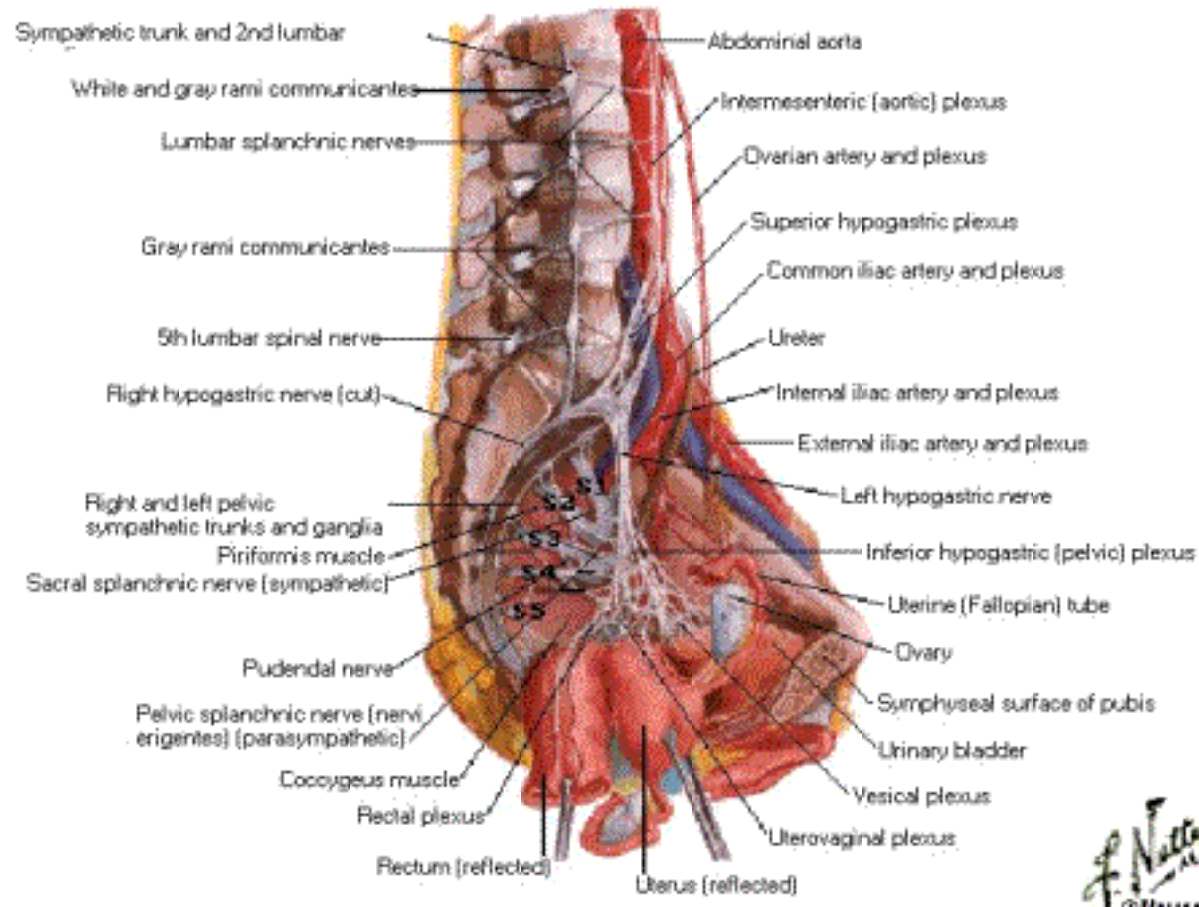


Nerves of Perineum

Male - Inferior View



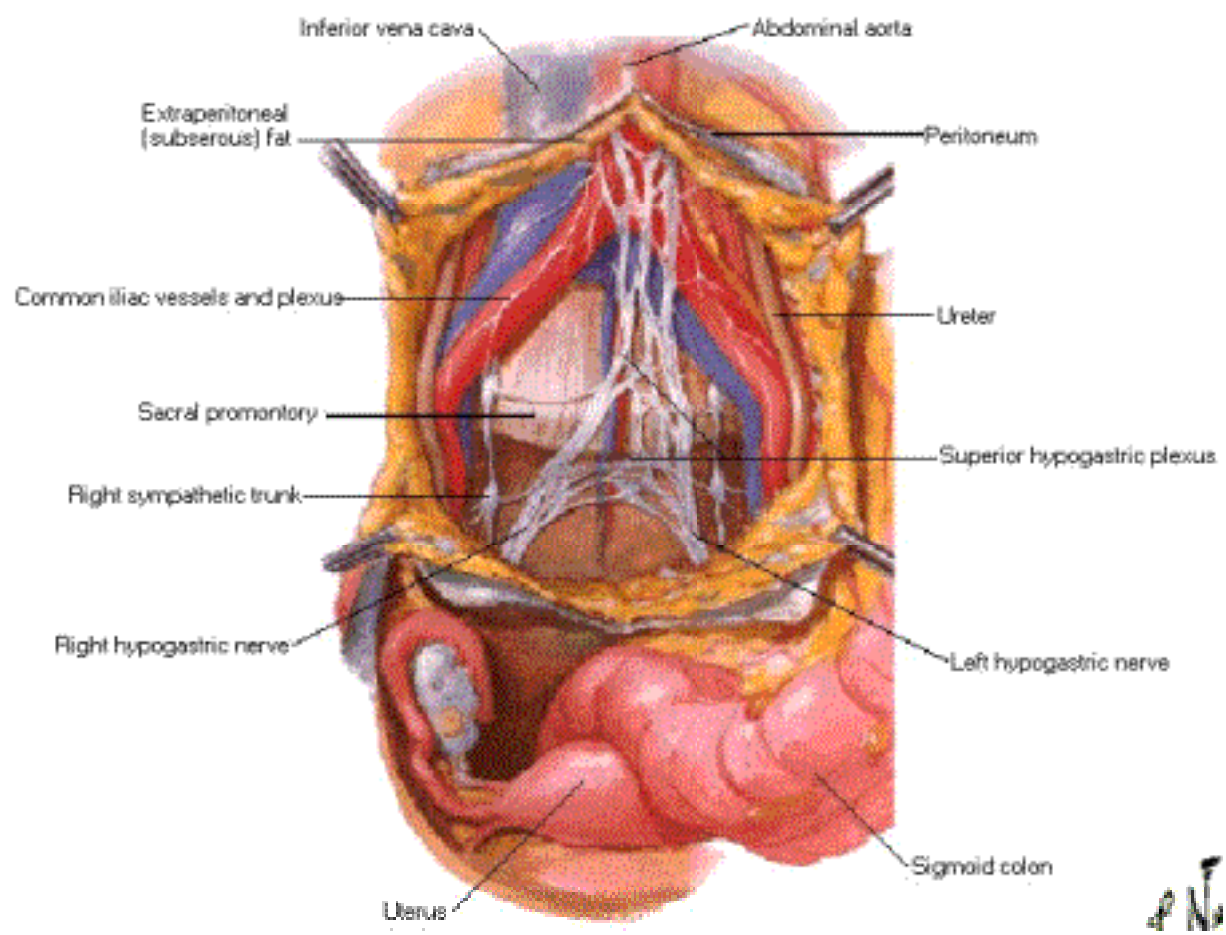
Nerves of Pelvic Viscera Female - Sagittal Section



F. Netto

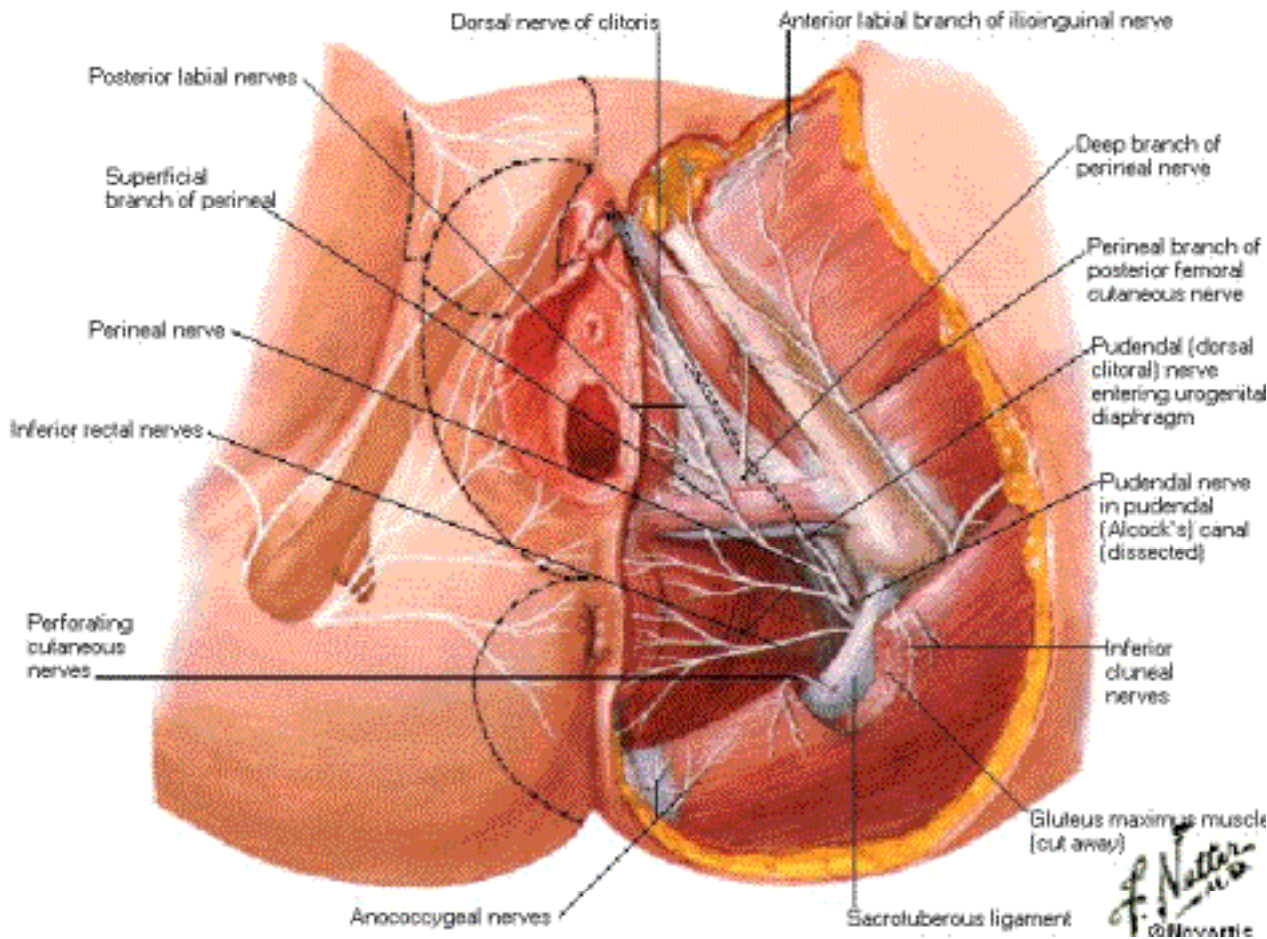
Nerves of Pelvic Viscera

Female - Superior View

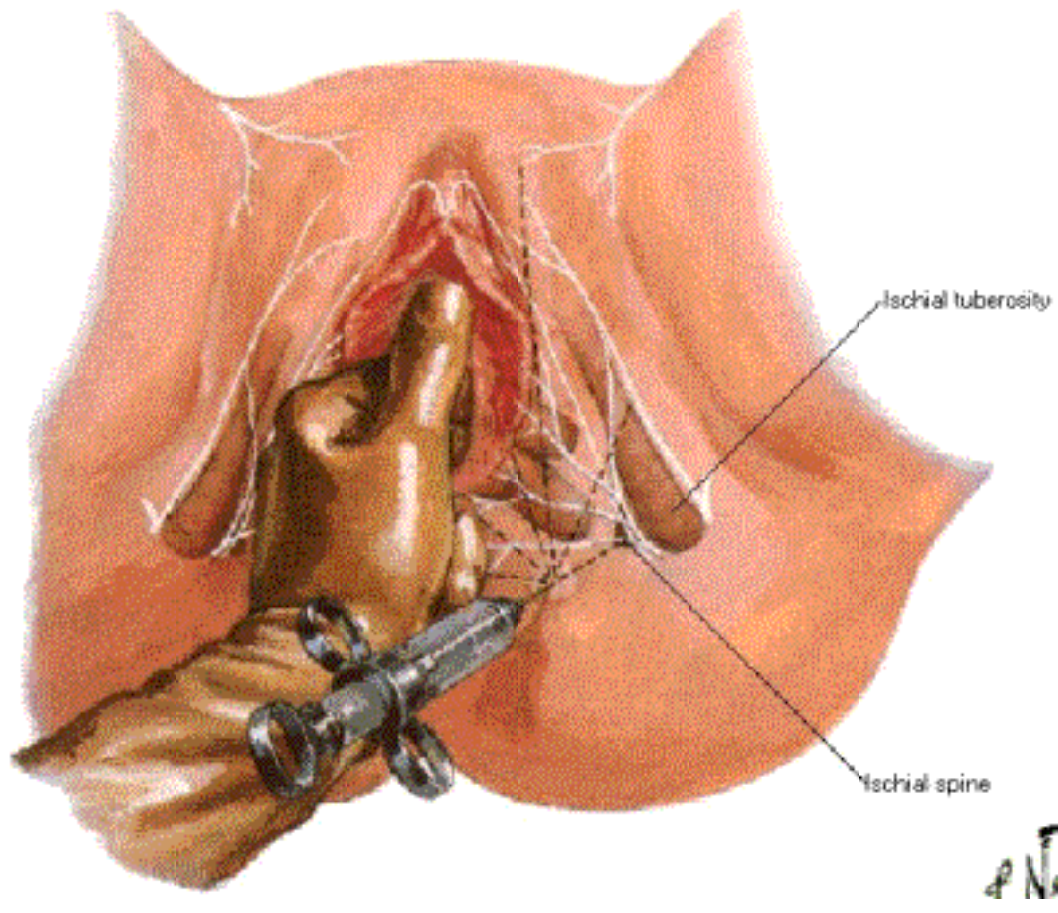


Nerves of Perineum and External Genitalia

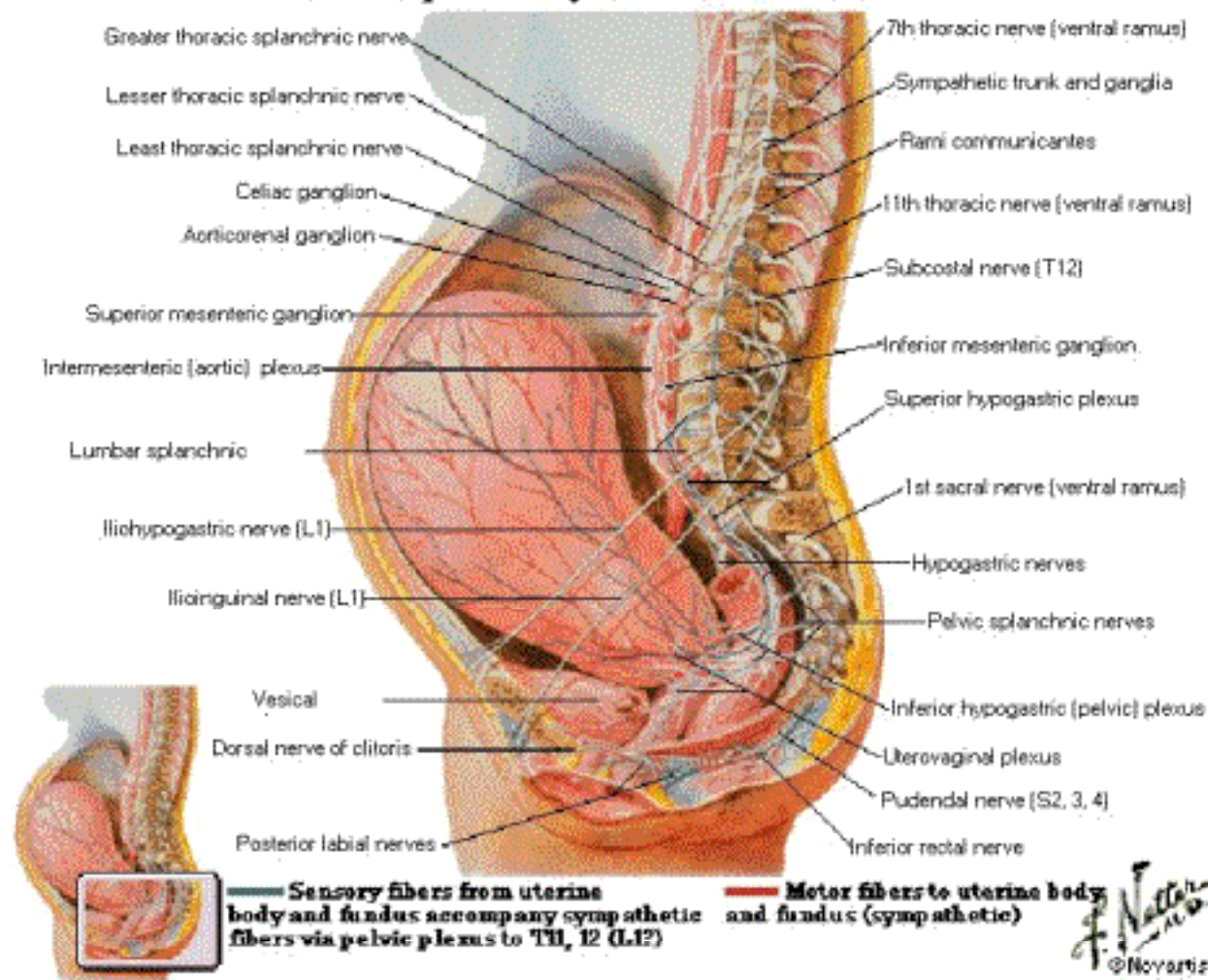
Female



Block Anesthesia of Perineal Area
Primarily Pudendal Nerve

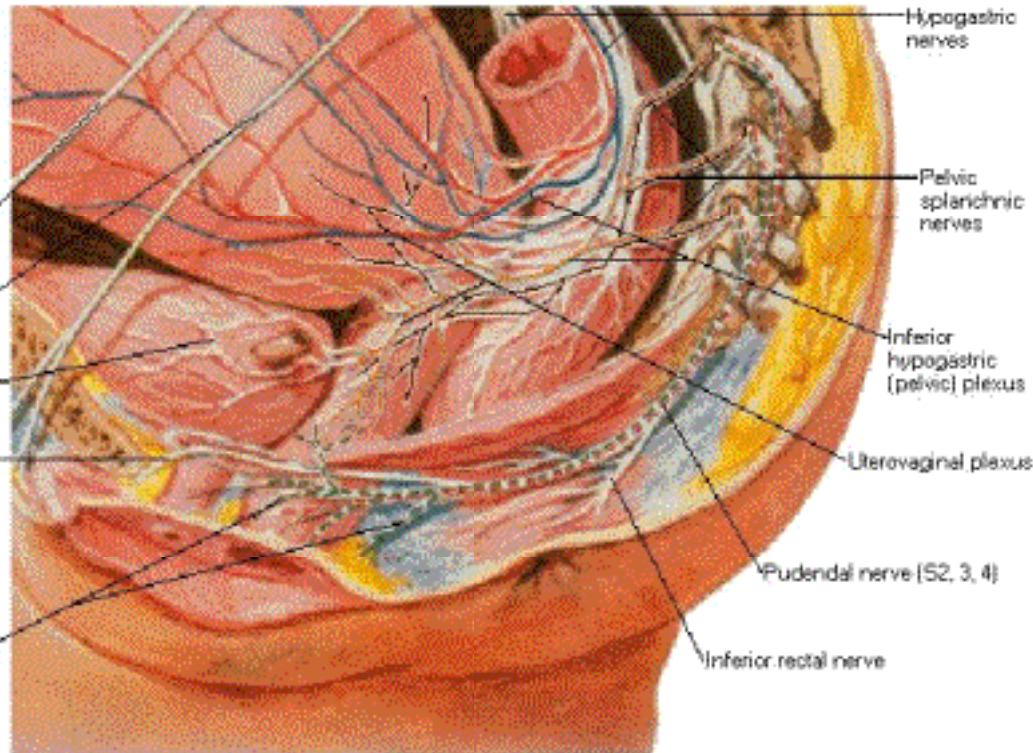
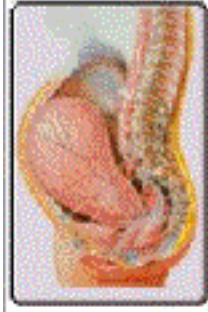

Neuropathways in Parturition



Neuropathways in Parturition

Pelvic Area Enlarged

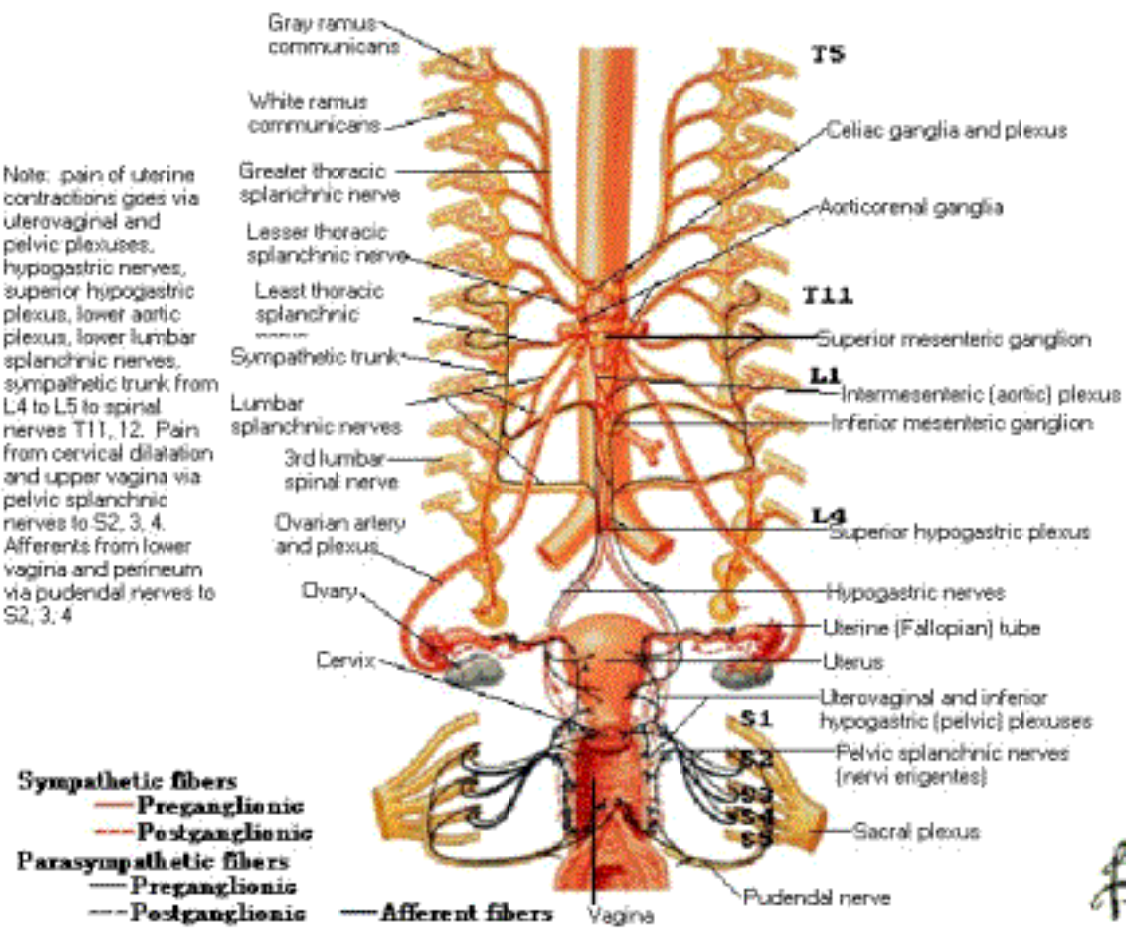


- Sensory fibers from uterine body and fundus accompany sympathetic fibers via pelvic plexus to T11, 12 (L1?)
- Sensory fibers from cervix and upper vagina accompany pelvic splanchnic nerves (parasympathetic) to S2, 3, 4
- Motor fibers to lower uterine segment, cervix and upper vagina (parasympathetic)
- Sensory fibers from lower vagina and perineum accompany somatic fibers via pudendal nerve to S2, 3, 4
- Motor fibers to lower vagina and perineum via pudendal nerve (somatic)

F. Netter M.D.
© 1996

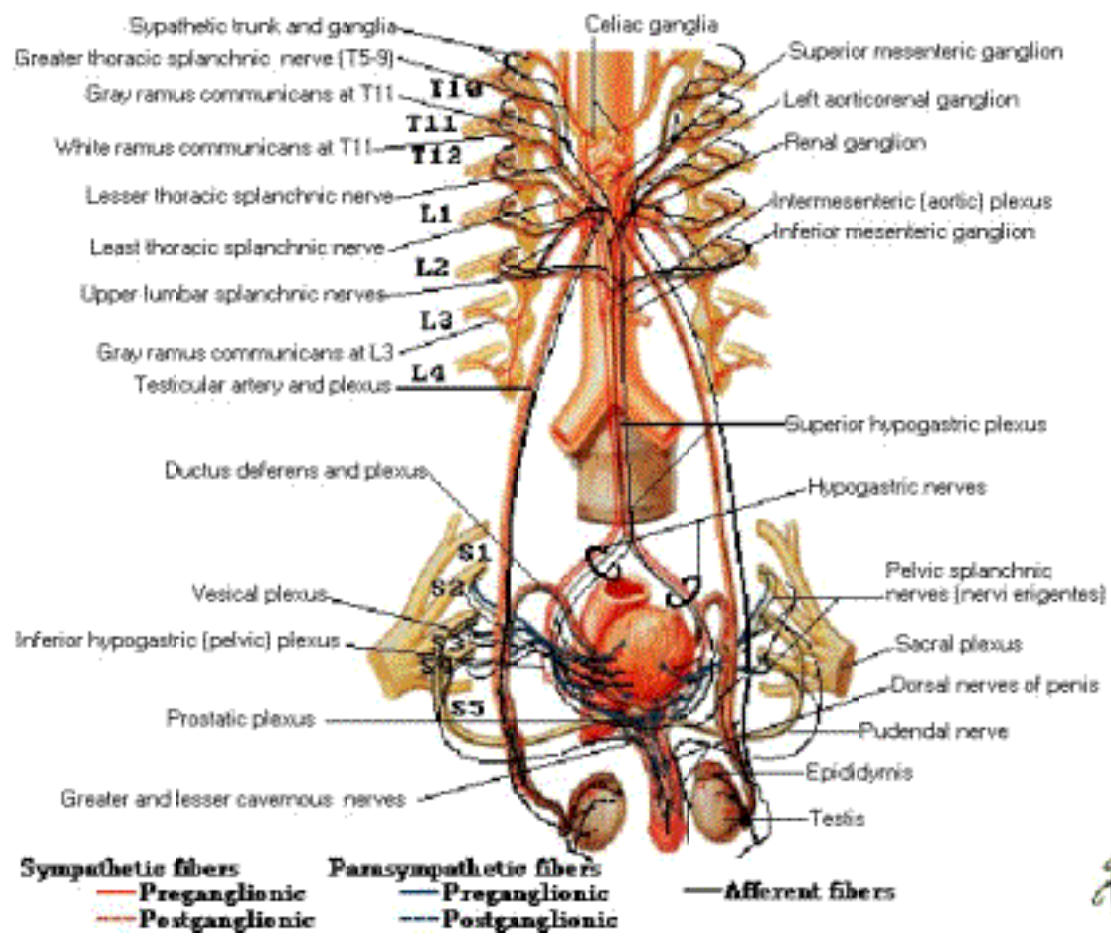
Innervation of Female Reproductive Organs Schema

Note: pain of uterine contractions goes via uterovaginal and pelvic plexuses, hypogastric nerves, superior hypogastric plexus, lower aortic plexus, lower lumbar splanchnic nerves, sympathetic trunk from L4 to L5 to spinal nerves T11, 12. Pain from cervical dilation and upper vagina via pelvic splanchnic nerves to S2, 3, 4. Afferents from lower vagina and perineum via pudendal nerves to S2, 3, 4.

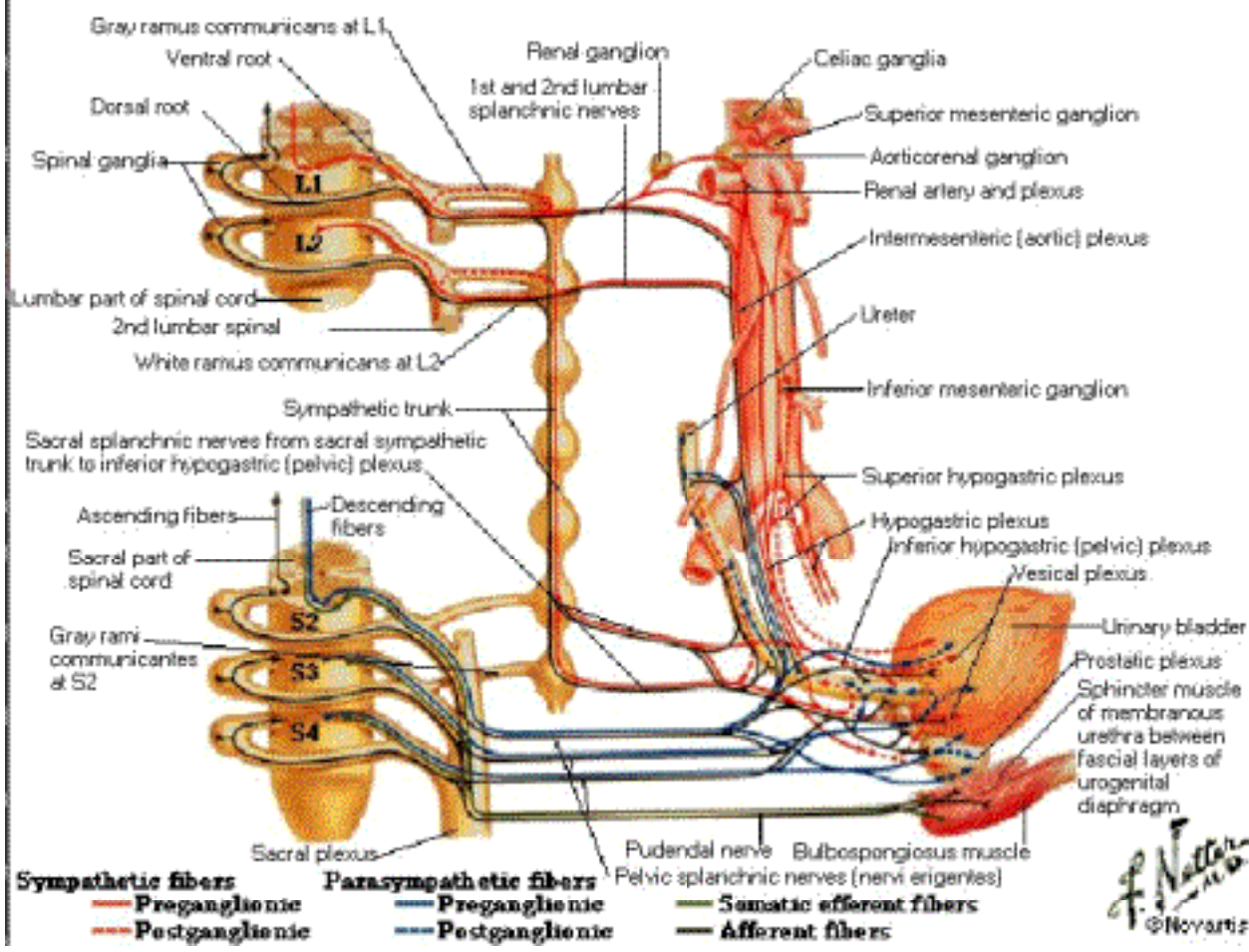


Innervation of Male Reproductive Organs

Schema

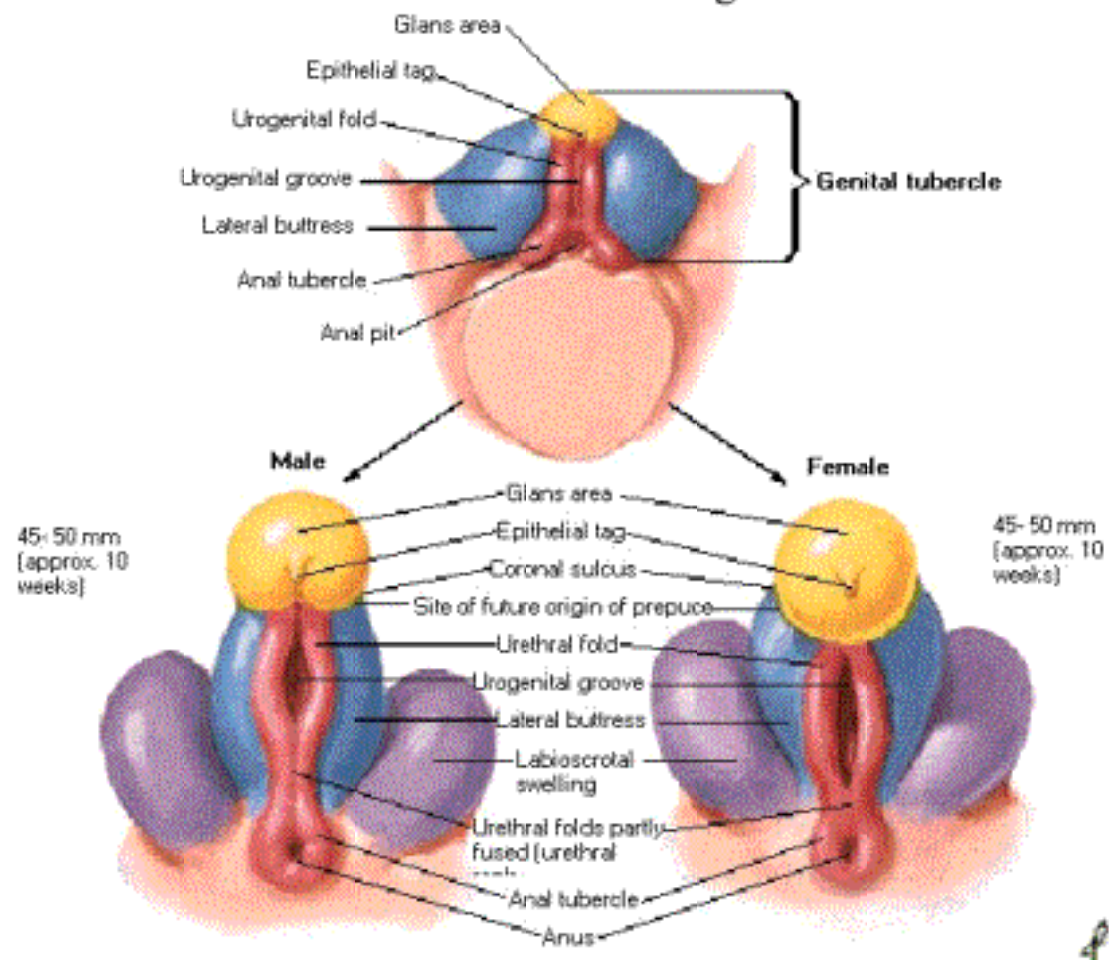


Innervation of Urinary Bladder and Lower Ureter Schema



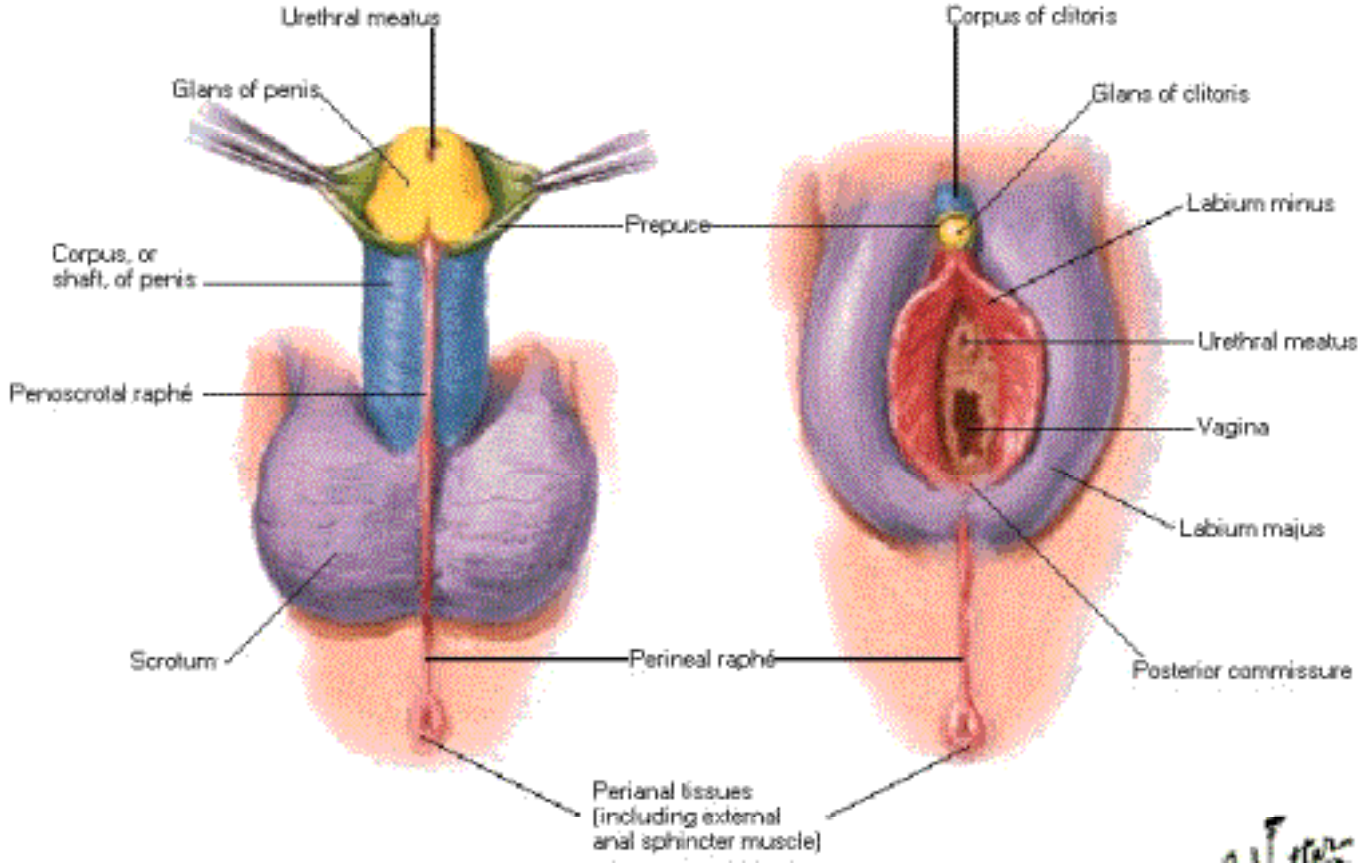
Homologues of External Genitalia

Undifferentiated Stage



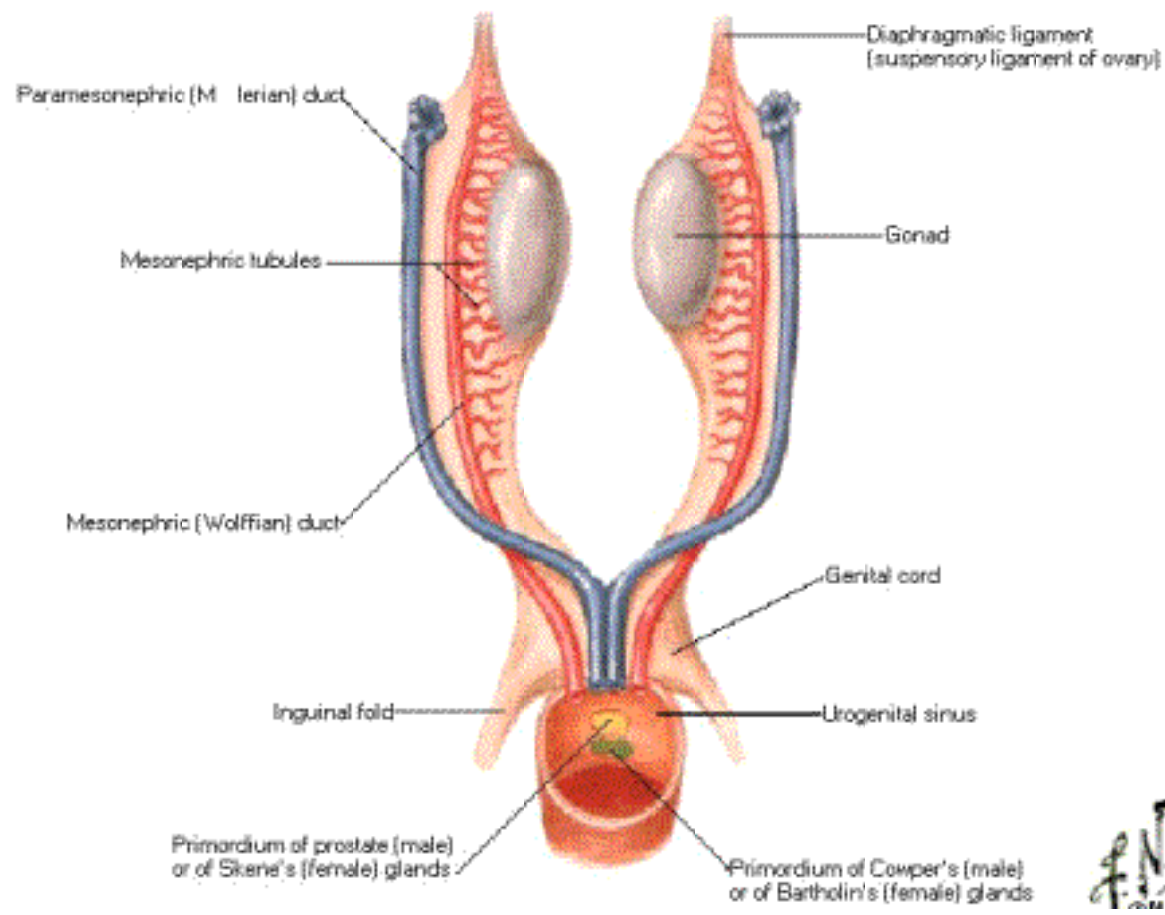
Homologues of External Genitalia

Fully Developed Male and Female



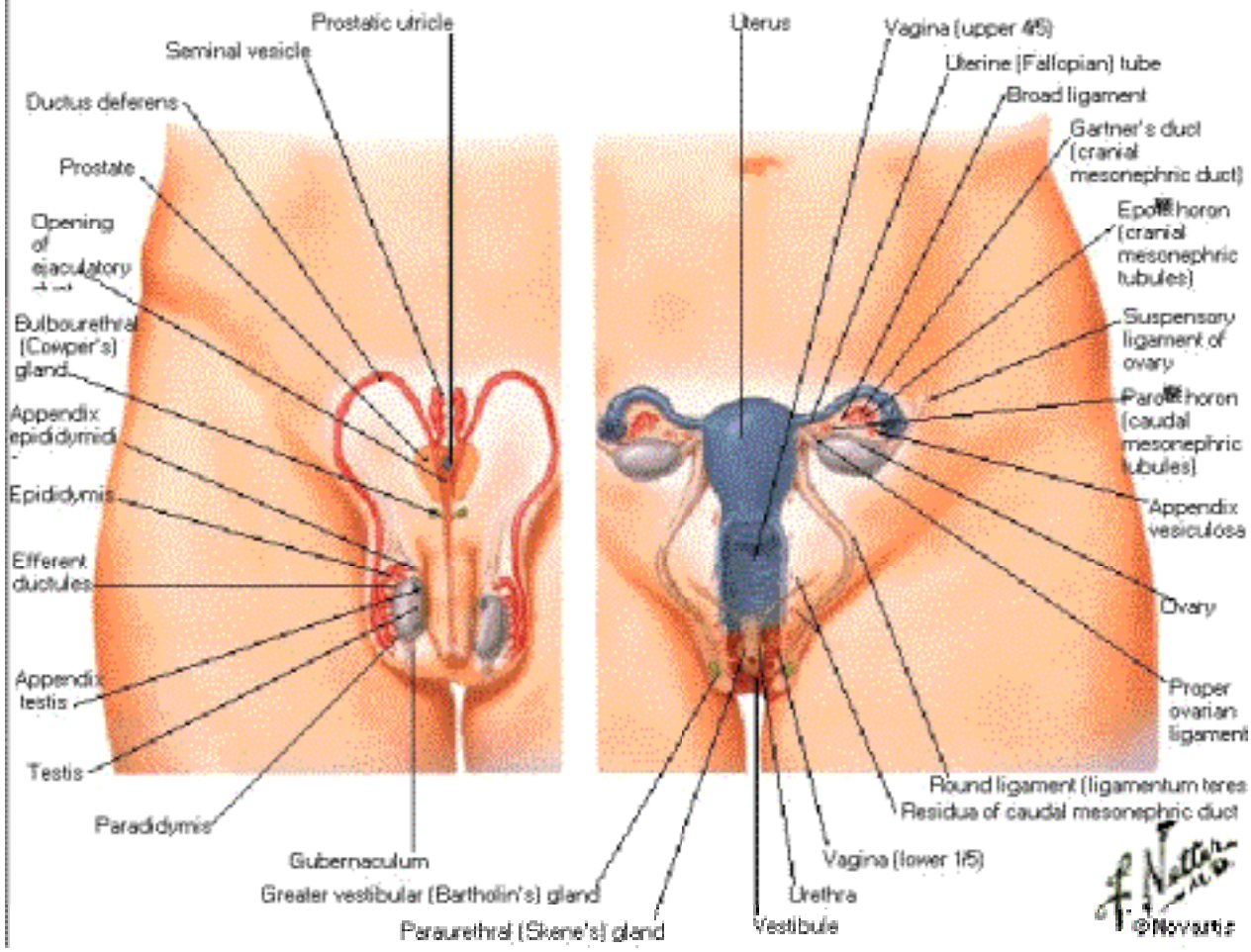
Homologues of Internal Genitalia

Undifferentiated Stage

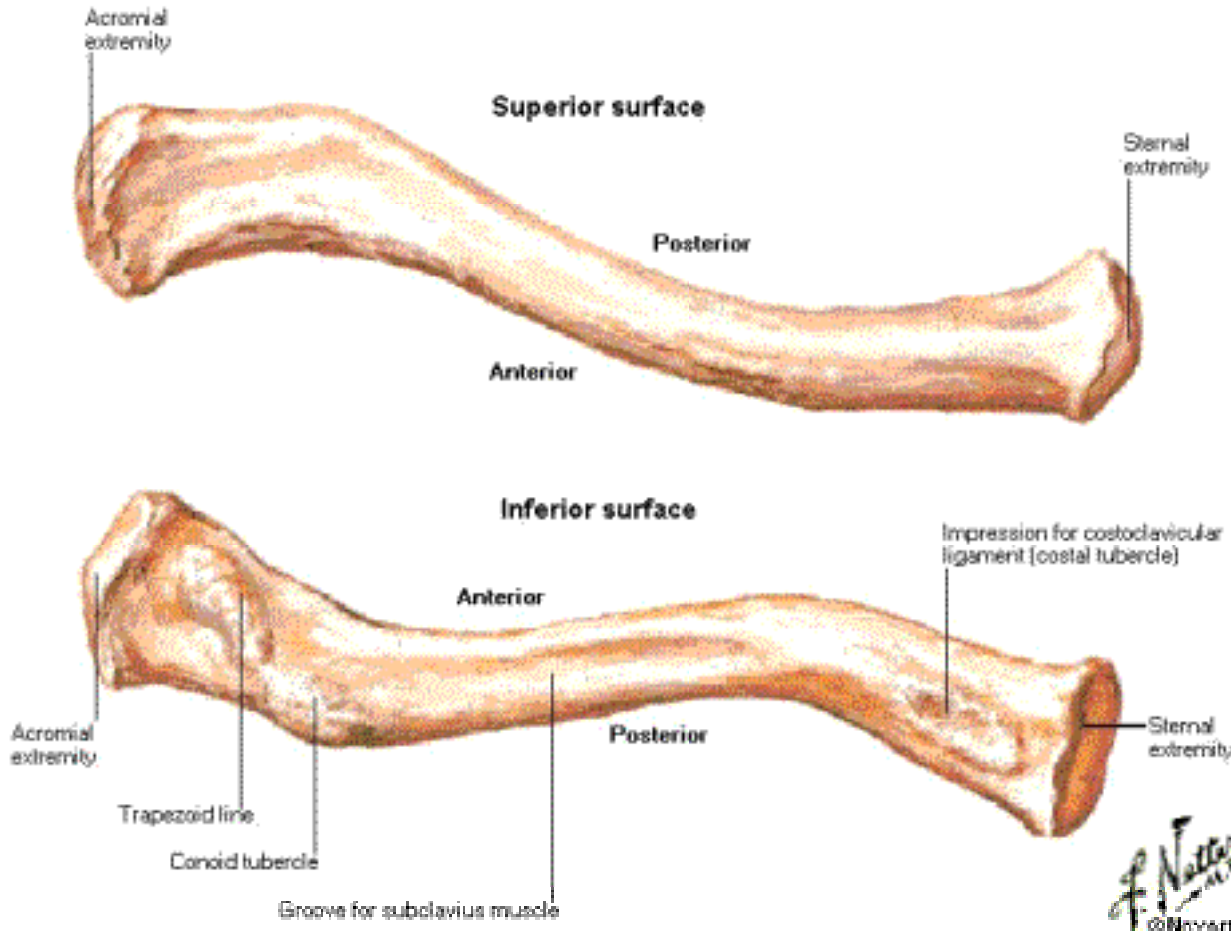


Homologues of Internal Genitalia

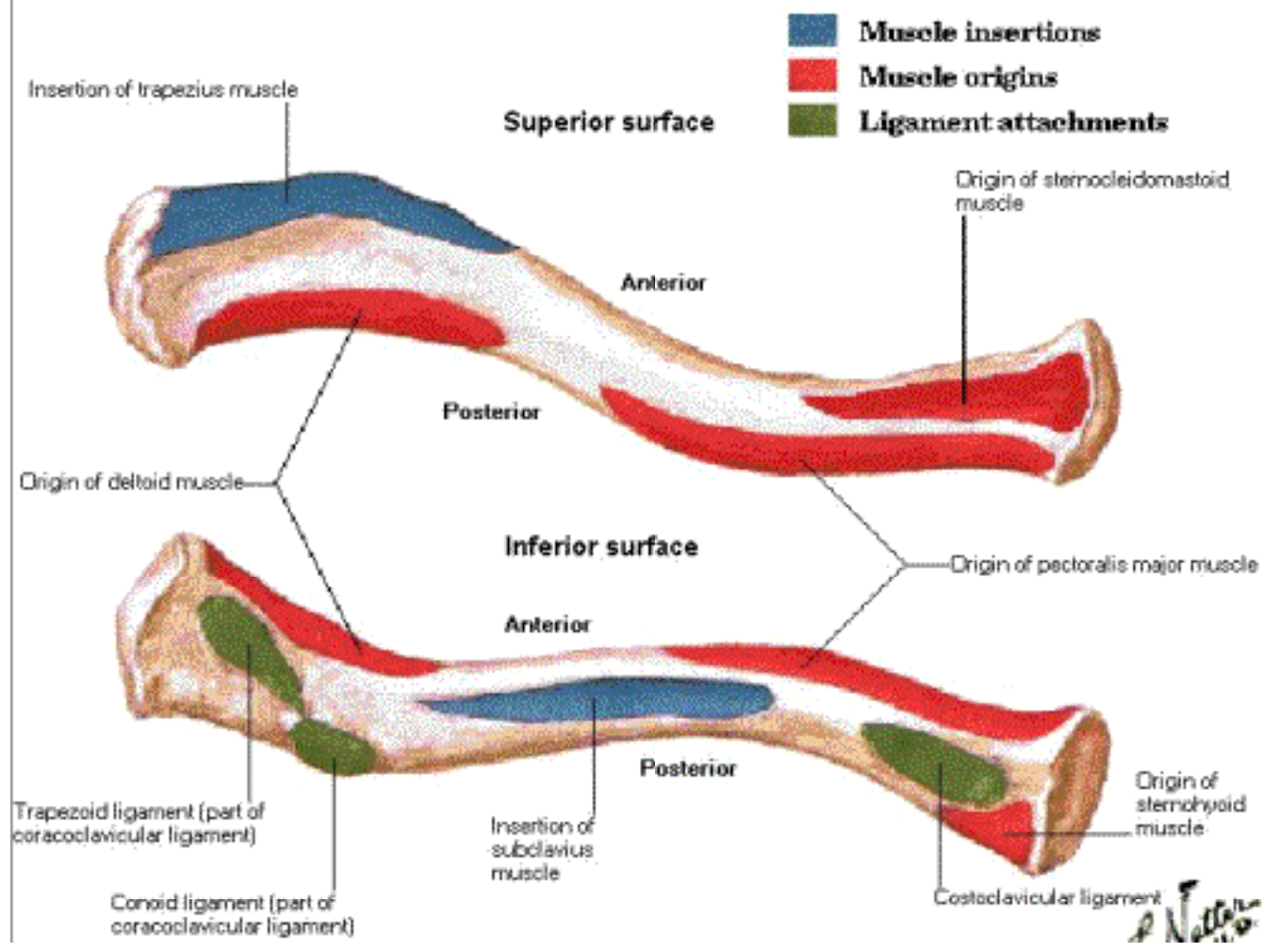
Fully Developed Male and Female



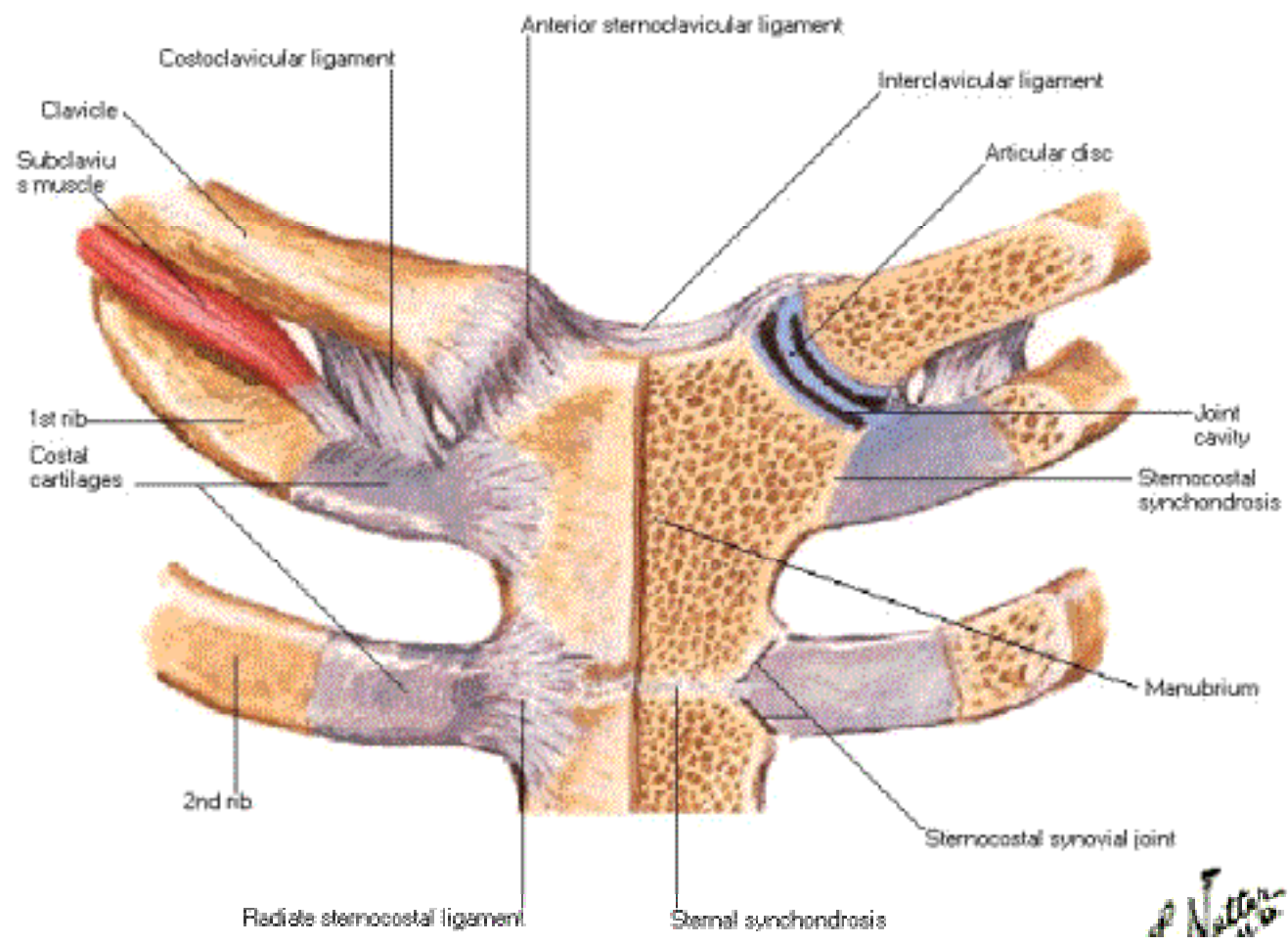
Right Clavicle - Features



Right Clavicle - Muscle Attachments

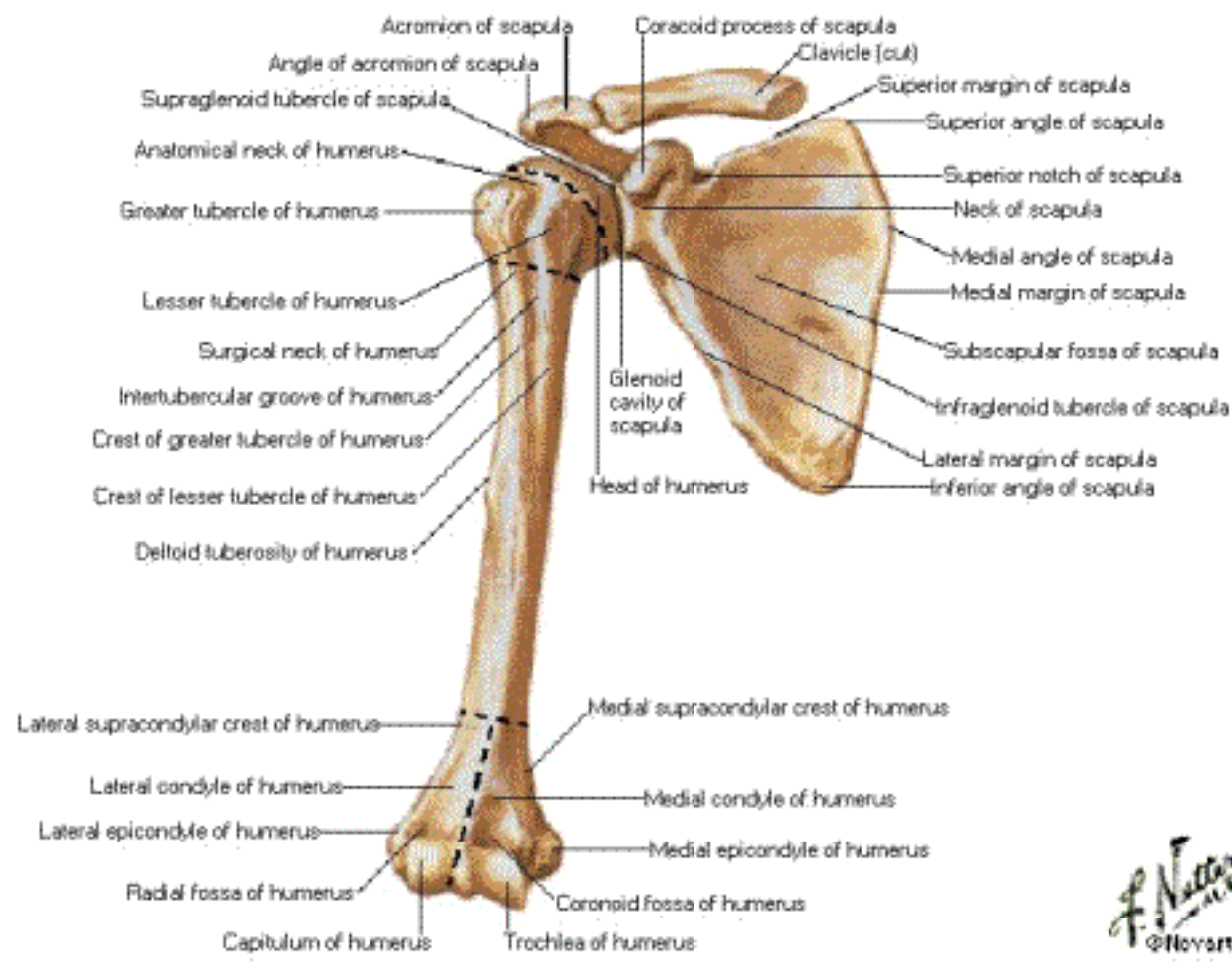


Sternoclavicular Joint



Humerus and Scapula

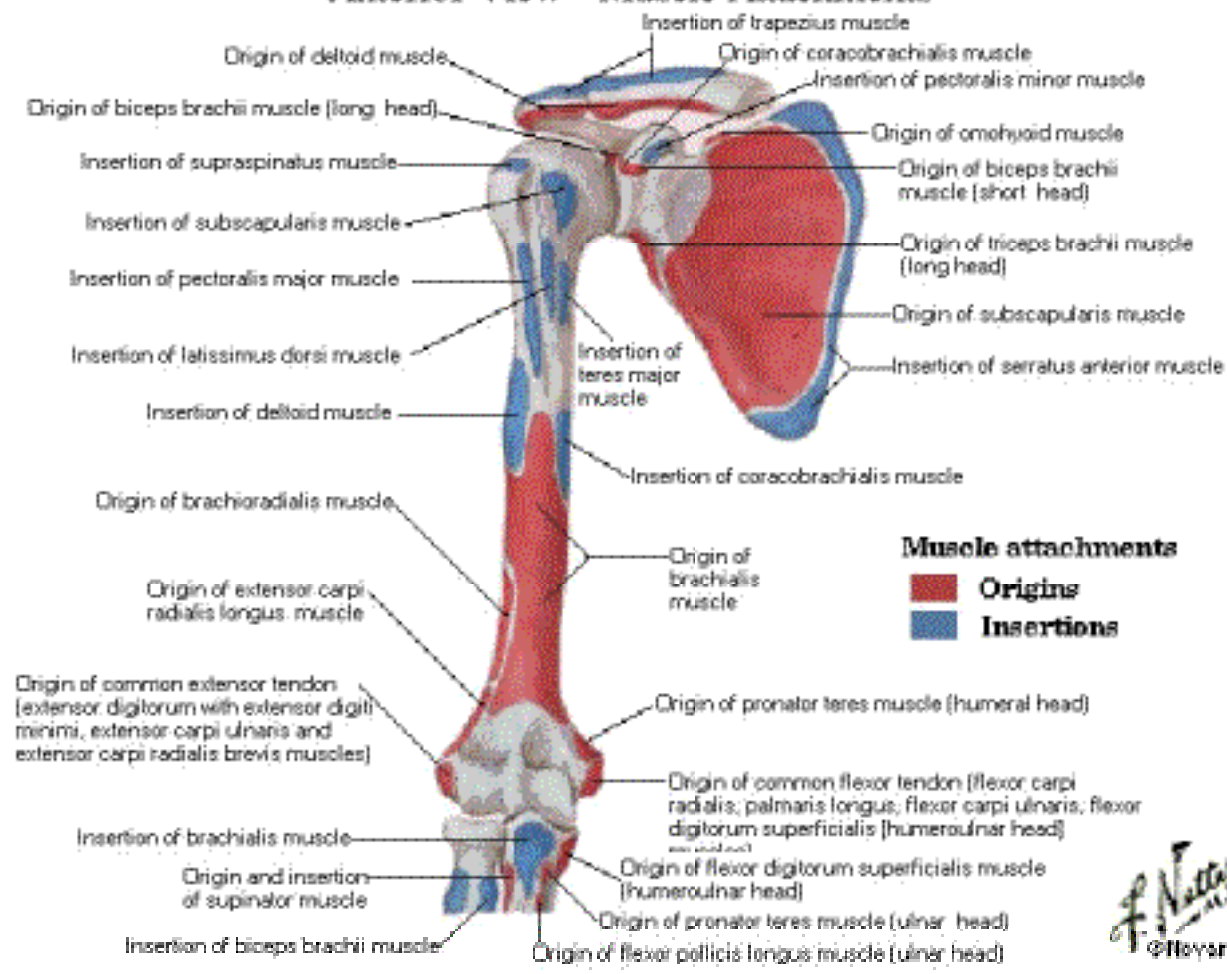
Anterior View - Features



F. Netter
© Novart

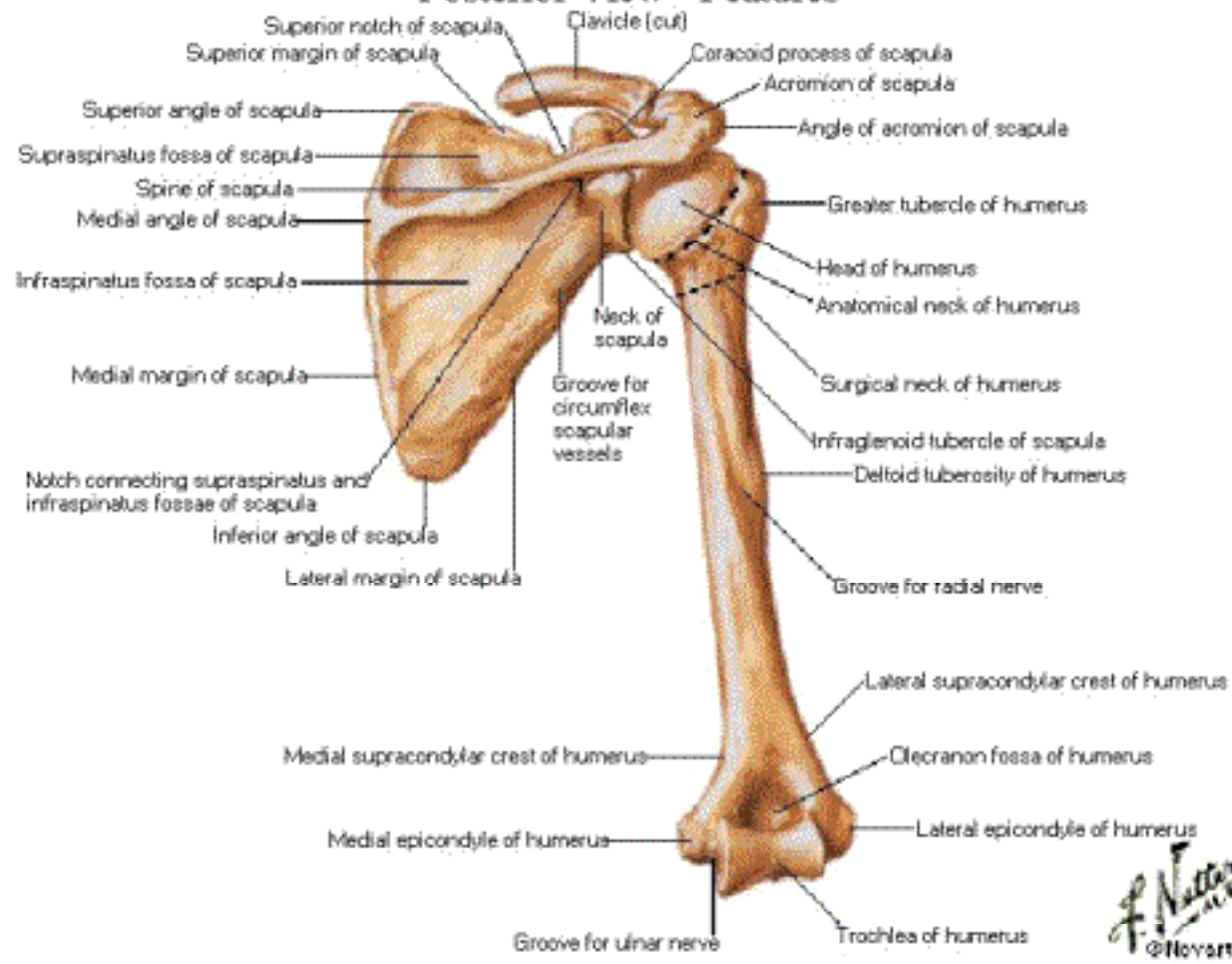
Humerus and Scapula

Anterior View - Muscle Attachments



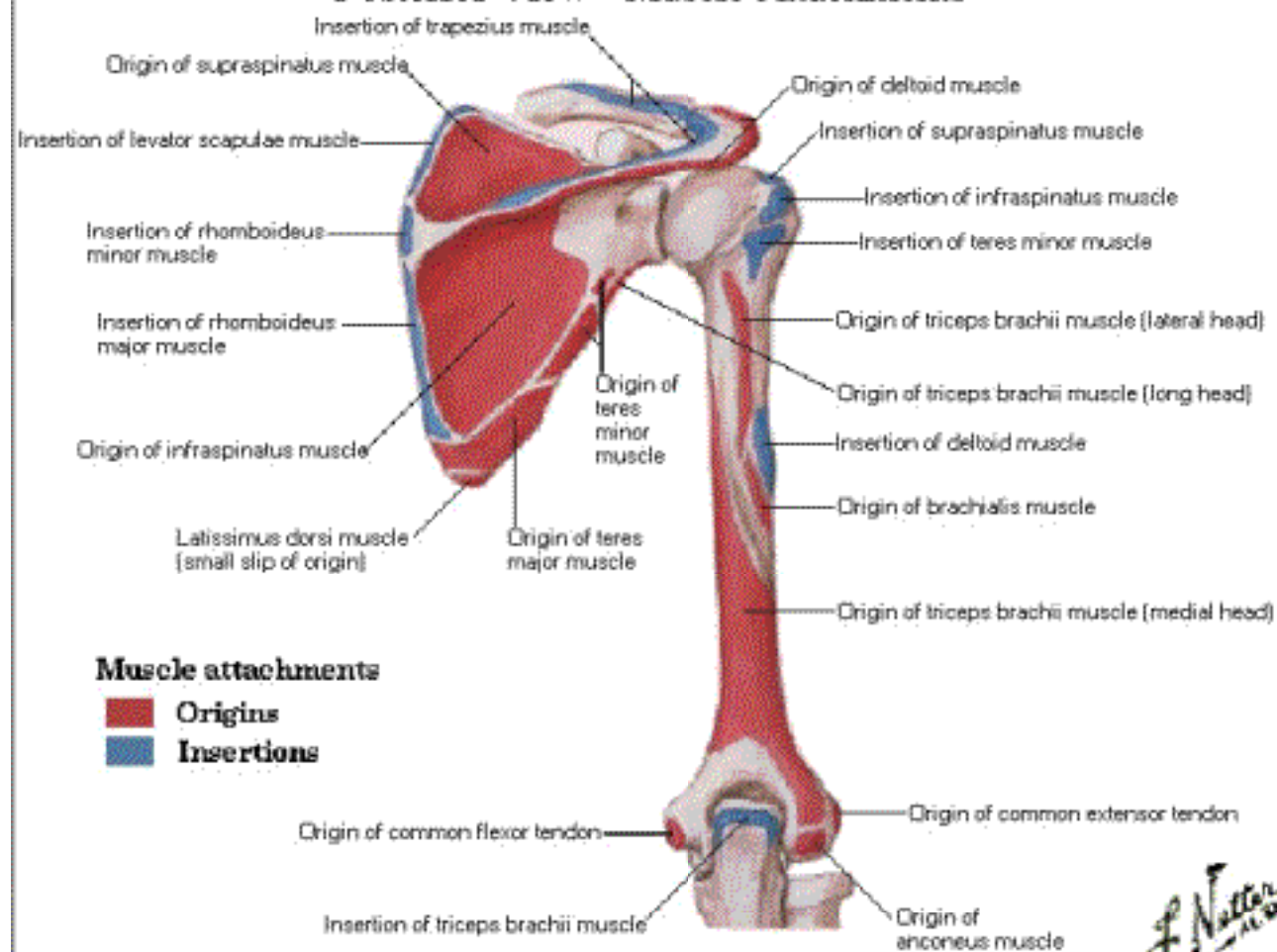
Humerus and Scapula

Posterior View - Features



Humerus and Scapula

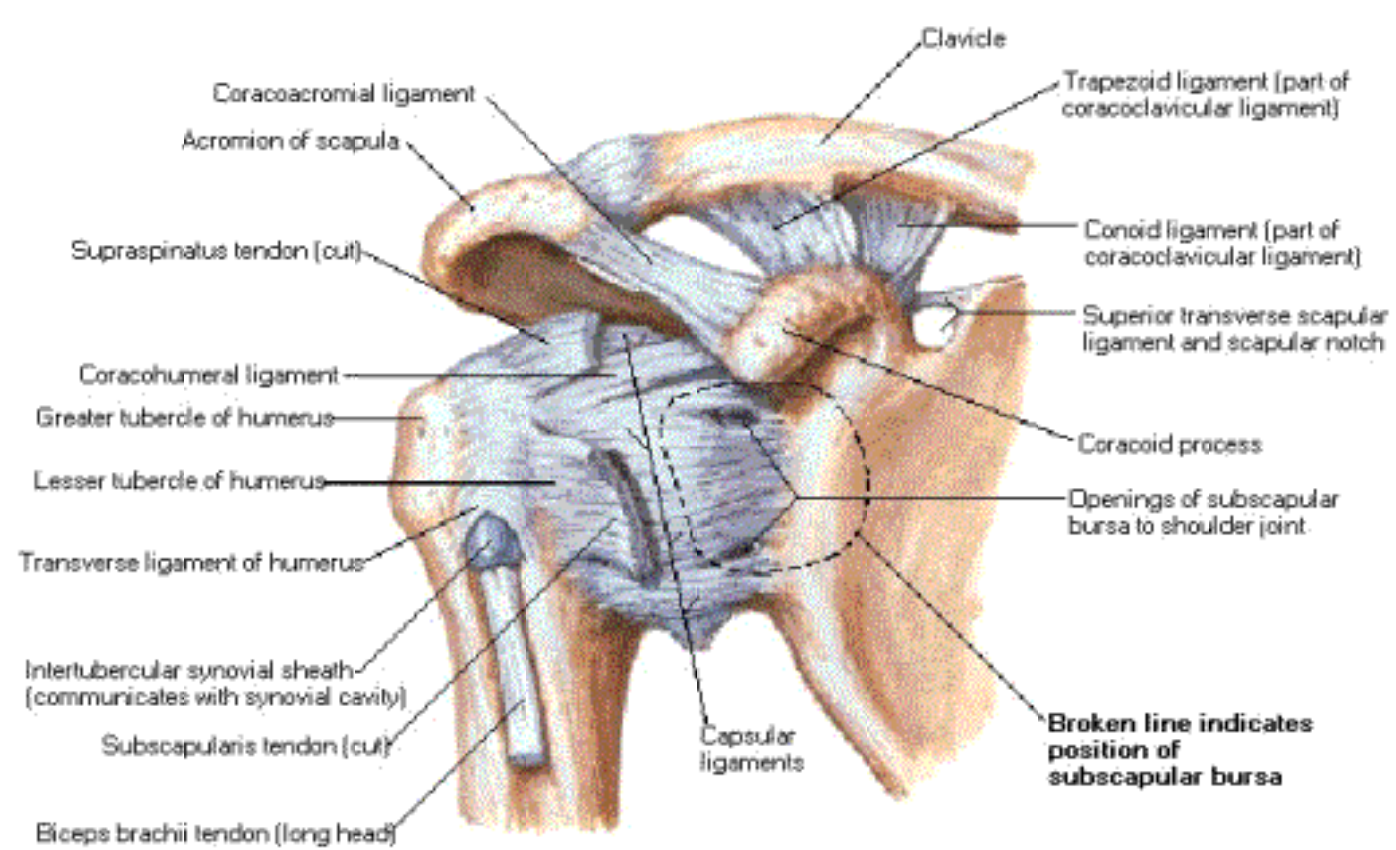
Posterior View - Muscle Attachments



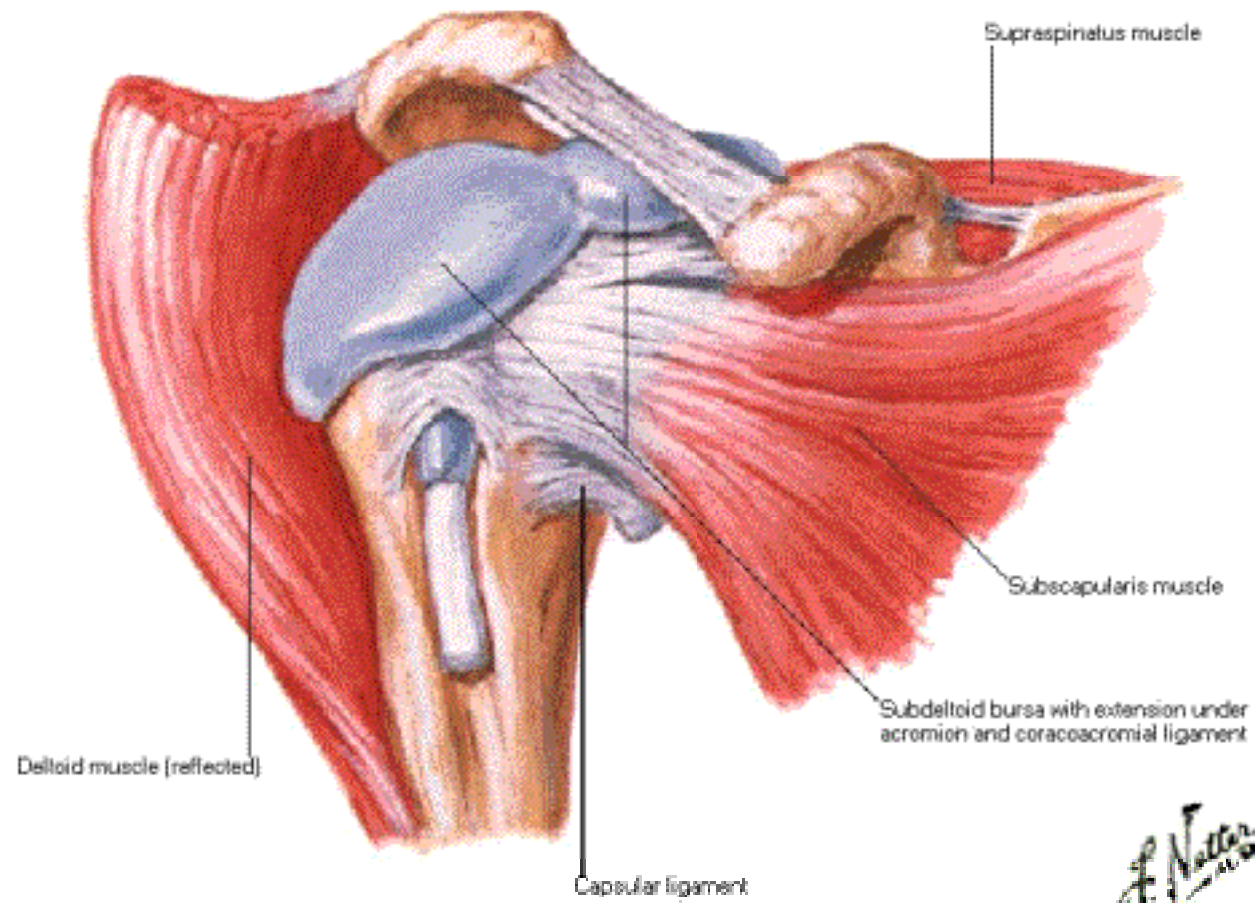
F. Netter M.D.

Glenohumeral Joint

Anterior View - Tendons and Ligaments

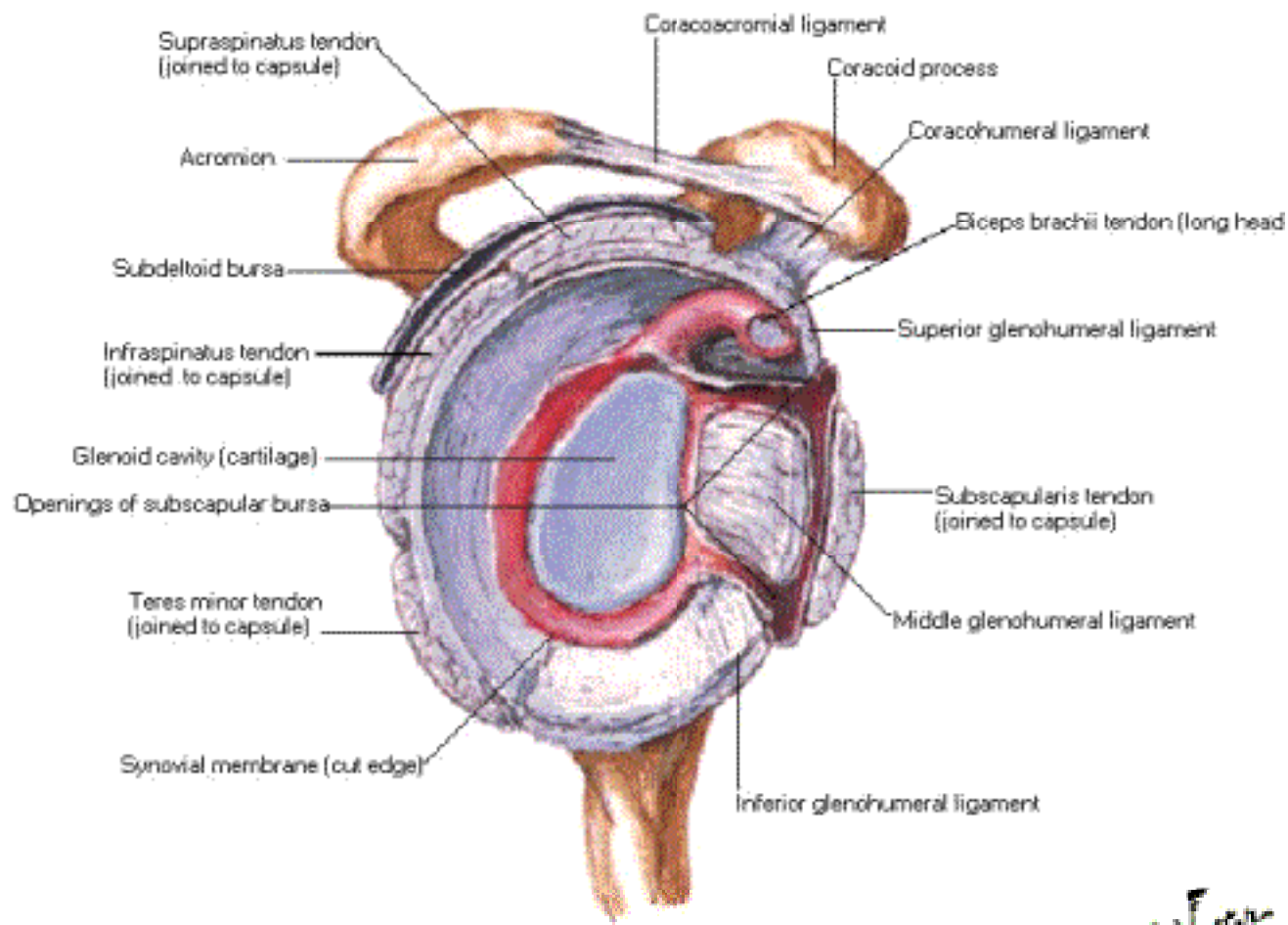


Glenohumeral Joint
Anterior View - Supporting Muscles



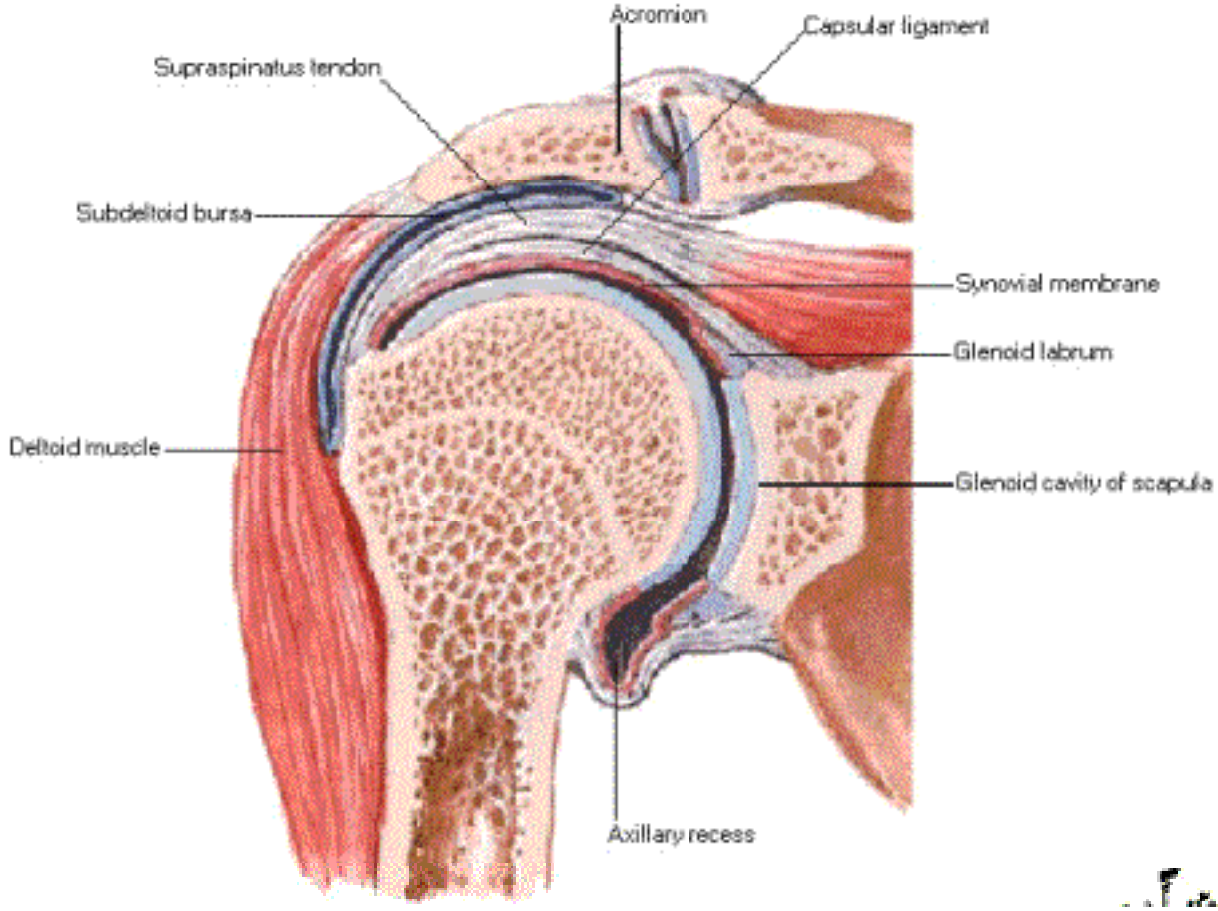
Glenohumeral Joint [Opened]

Lateral View



Glenohumeral Joint

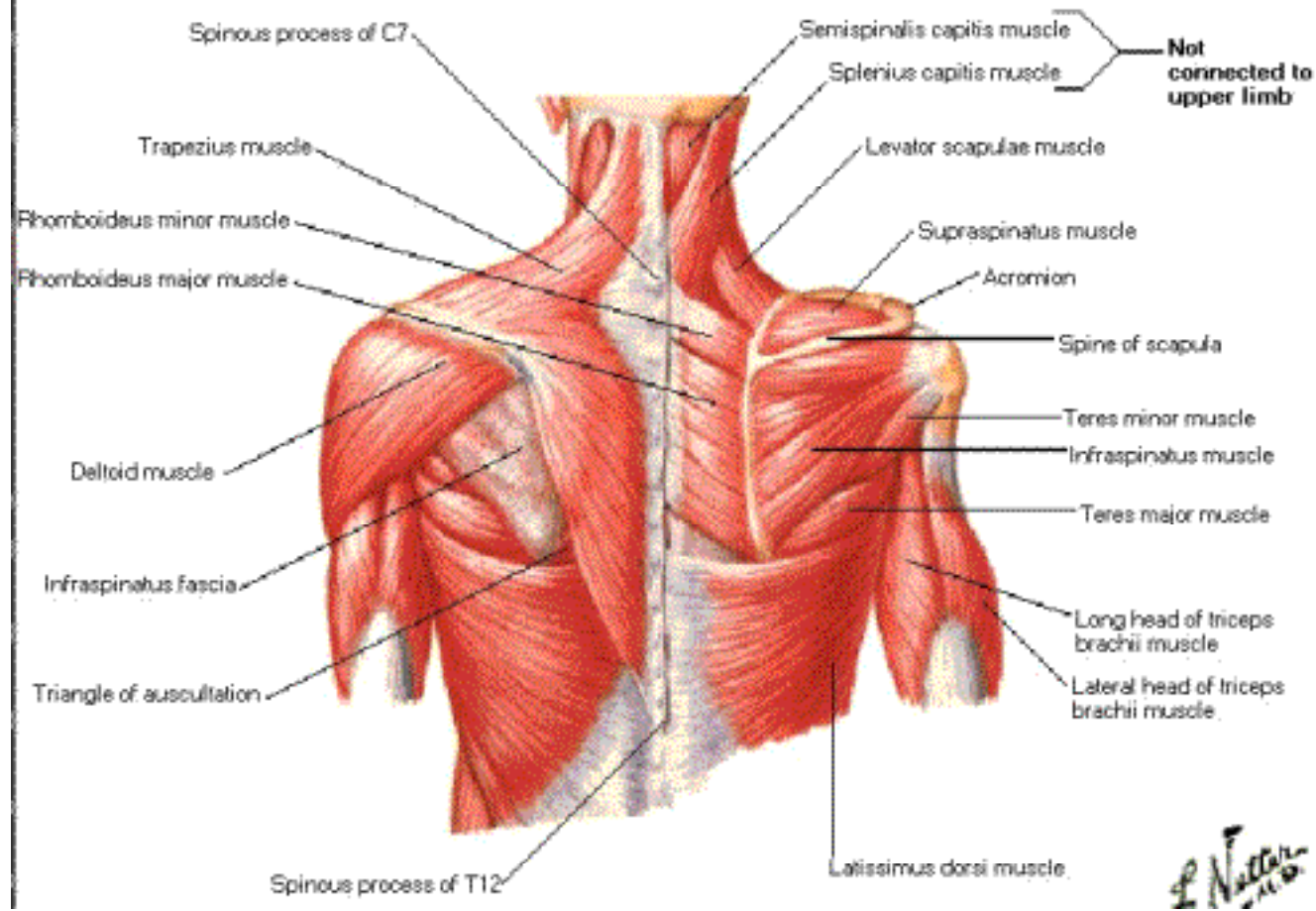
Coronal Section through Joint.



... 2 ...

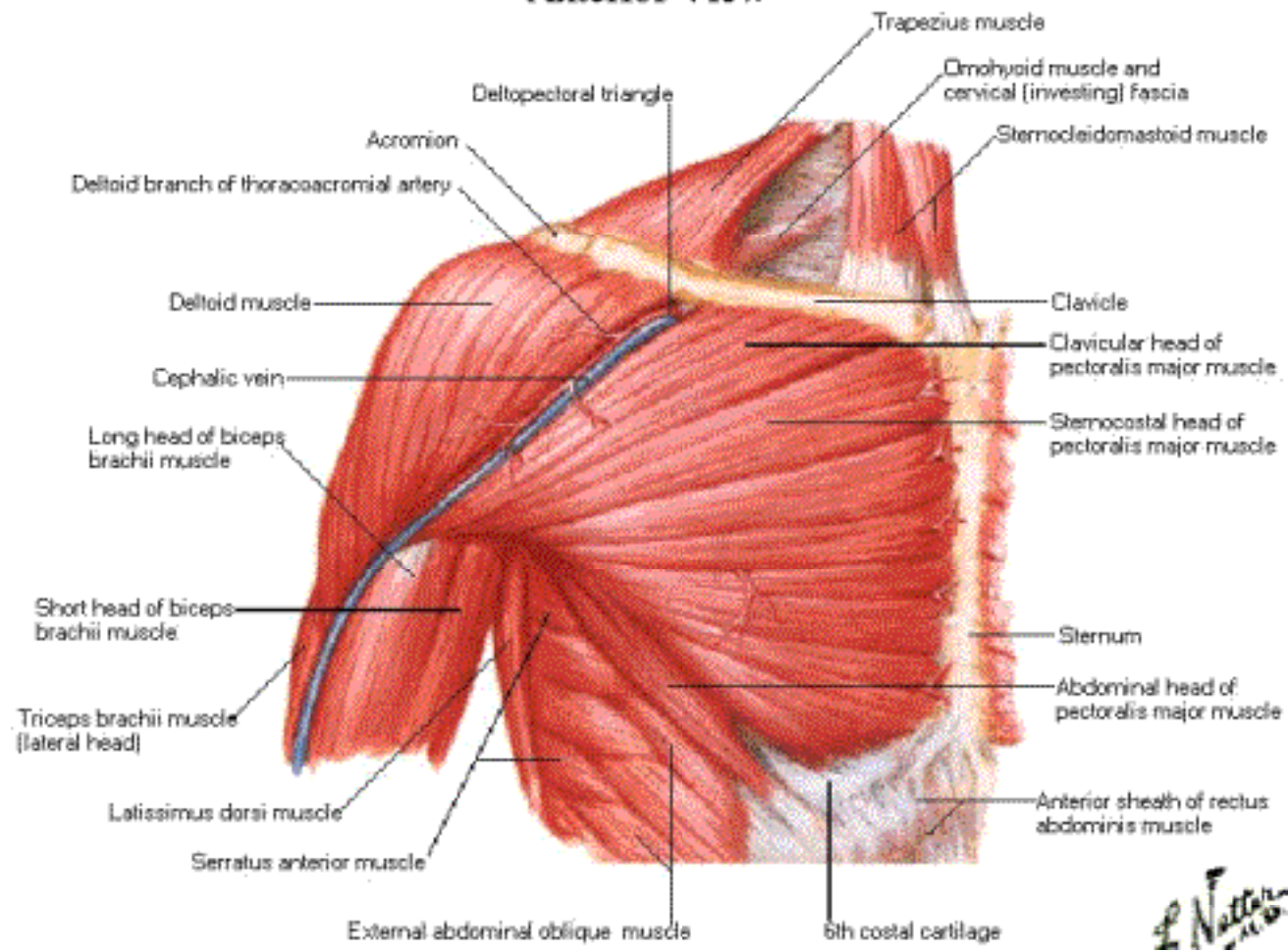
Muscles of Shoulder

Posterior View



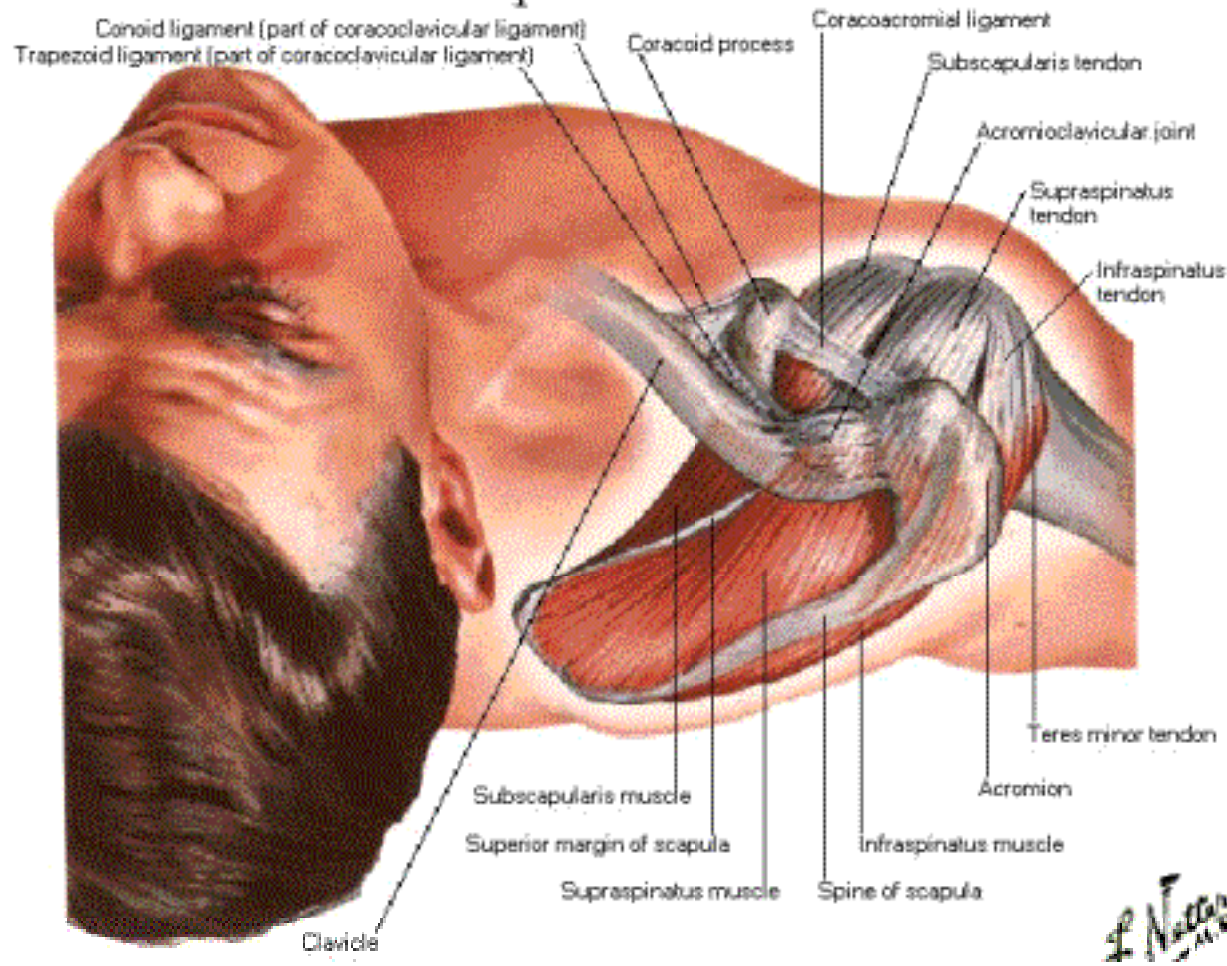
Muscles of Shoulder

Anterior View



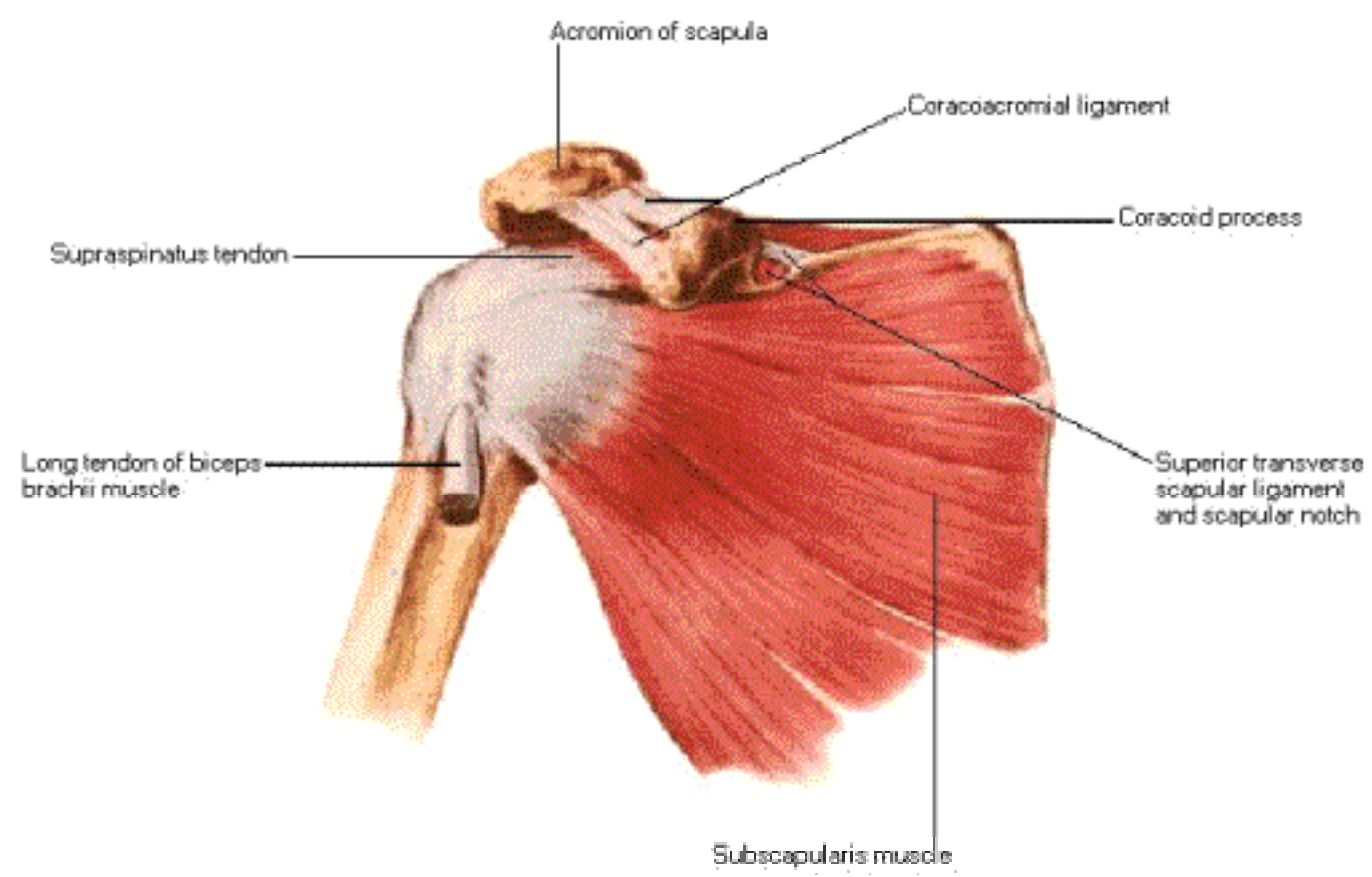
Muscles of Rotator Cuff

Superior View



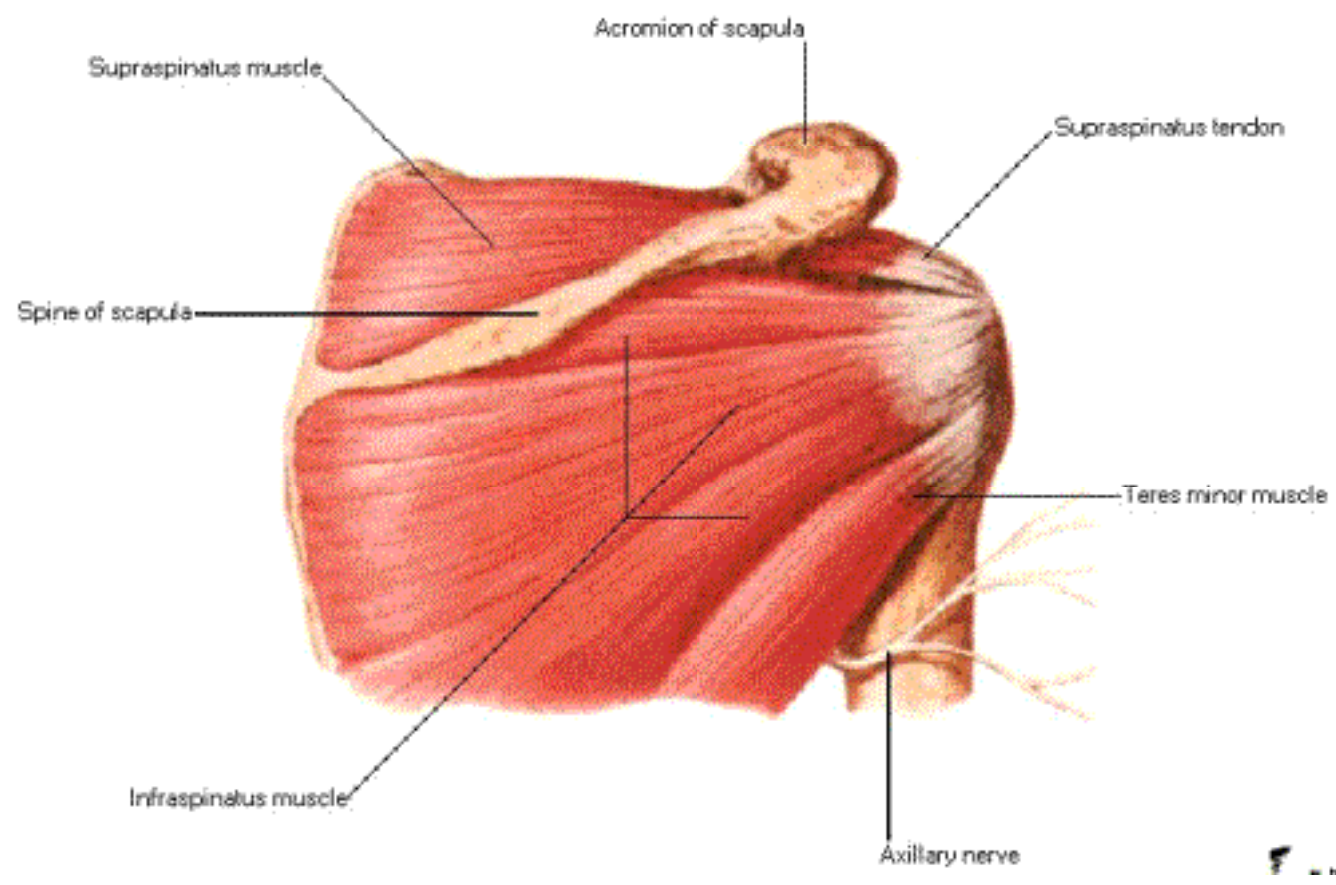
Muscles of Rotator Cuff

Anterior View



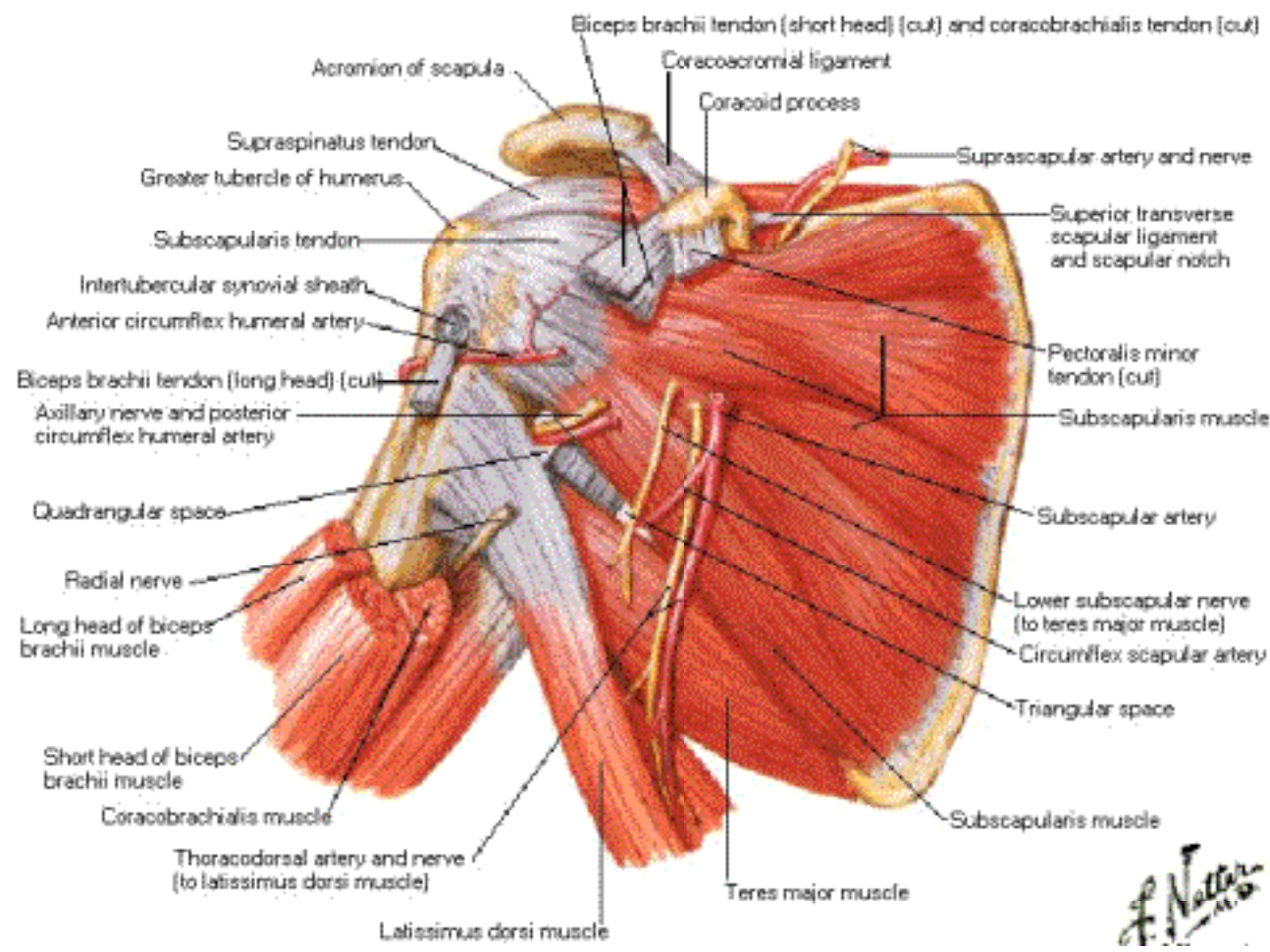
Muscles of Rotator Cuff

Posterior View



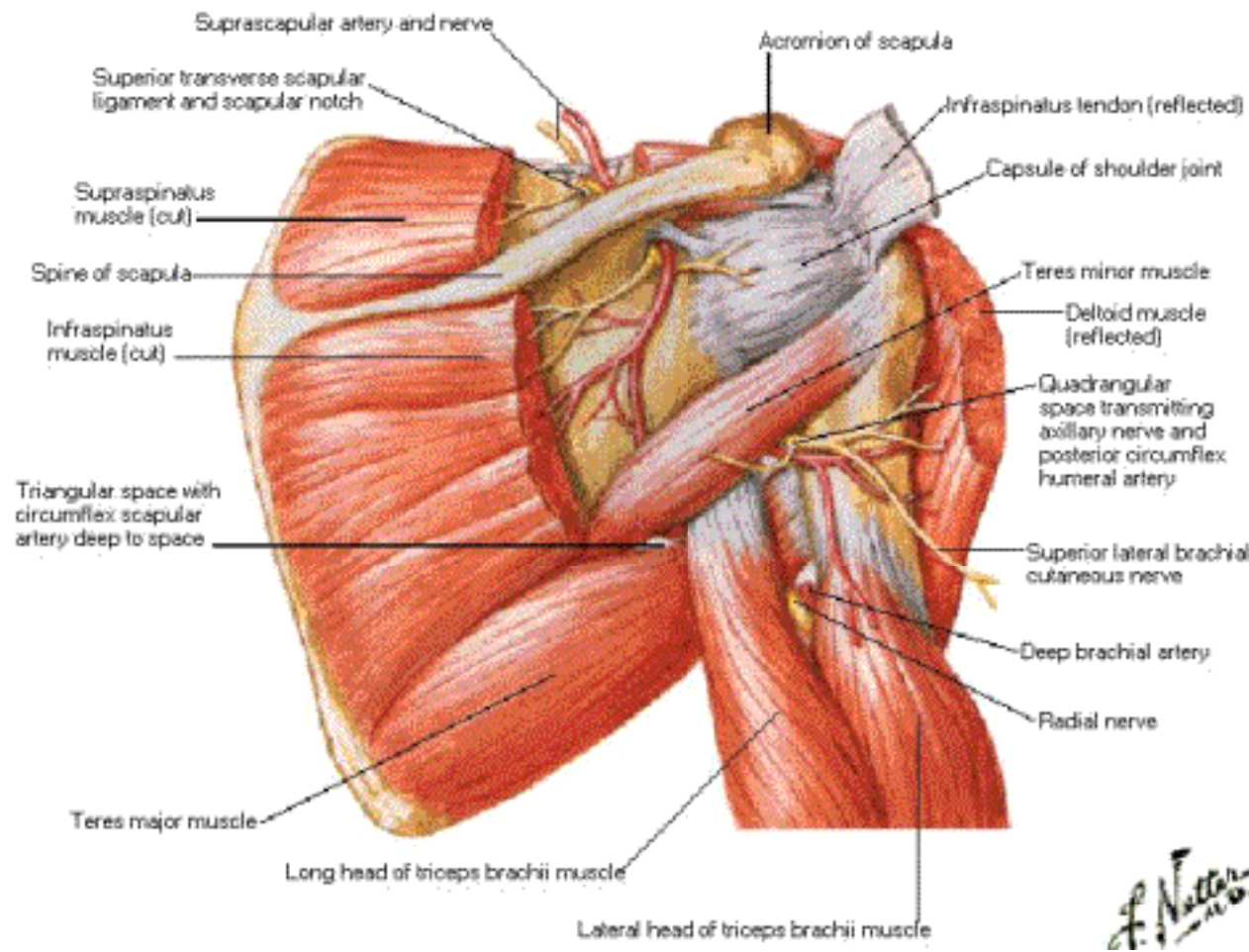
Scapulohumeral Dissection

Anterior View

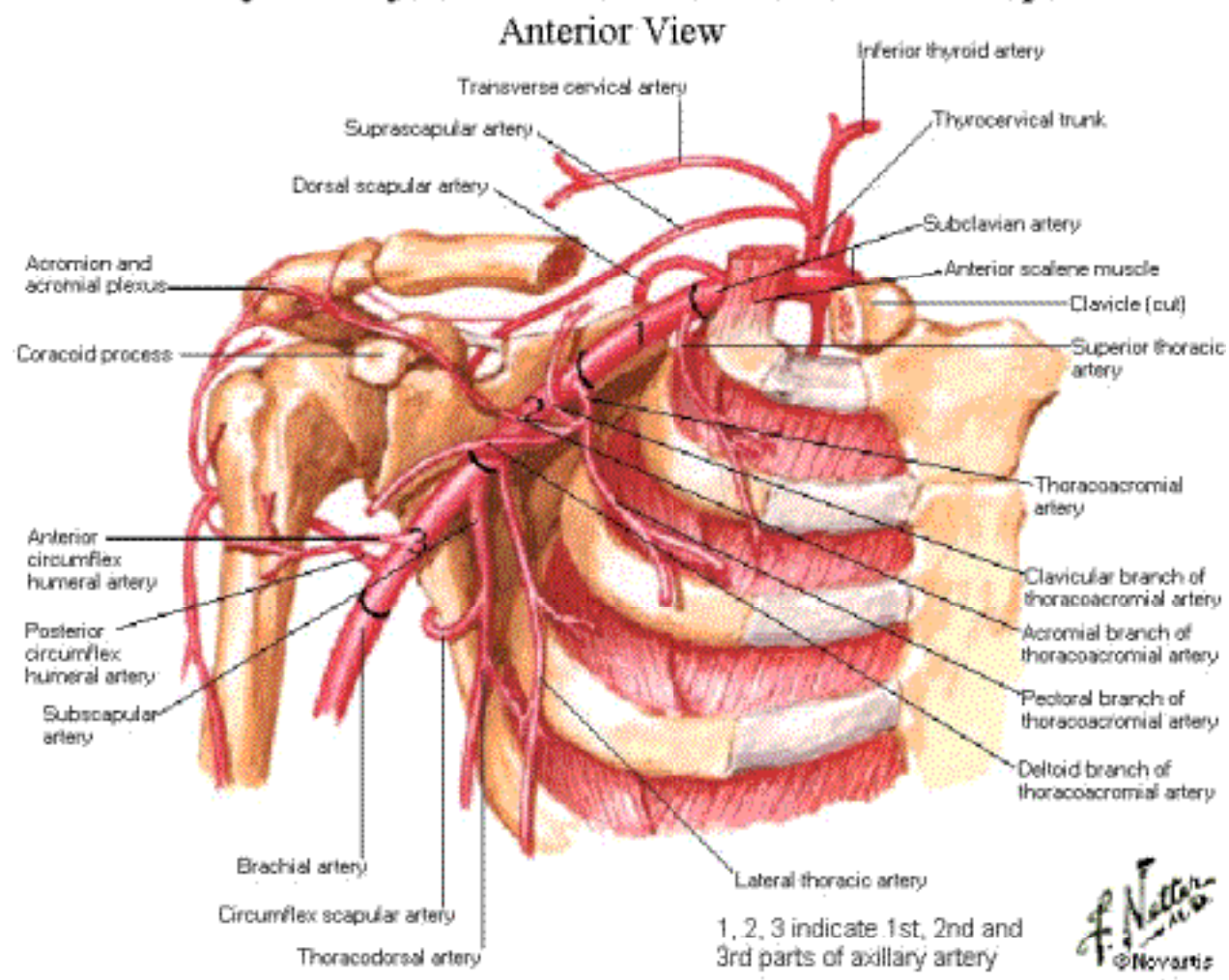


Scapulohumeral Dissection

Posterior View

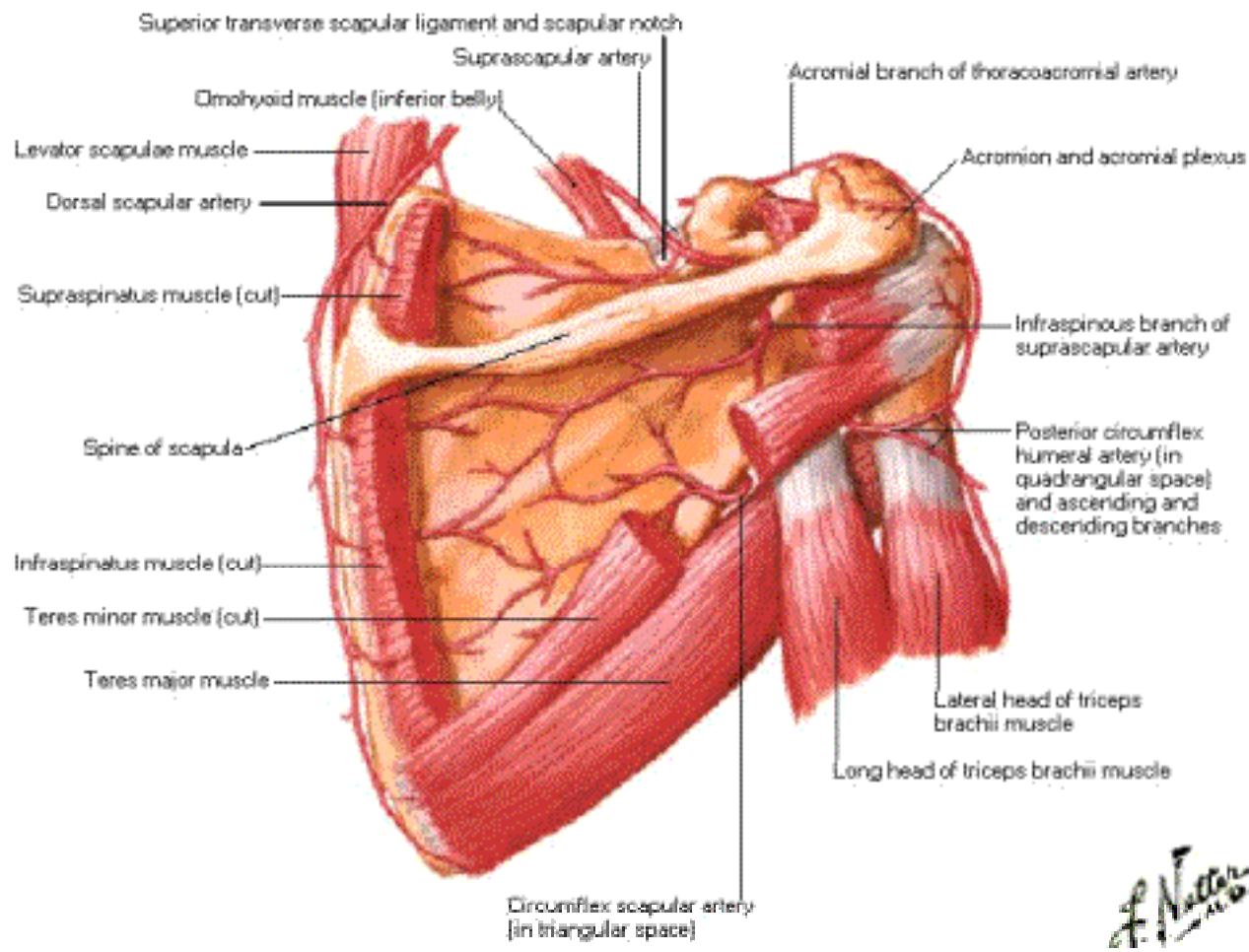


Axillary Artery and Anastomoses Around Scapula



Axillary Artery and Anastomoses Around Scapula

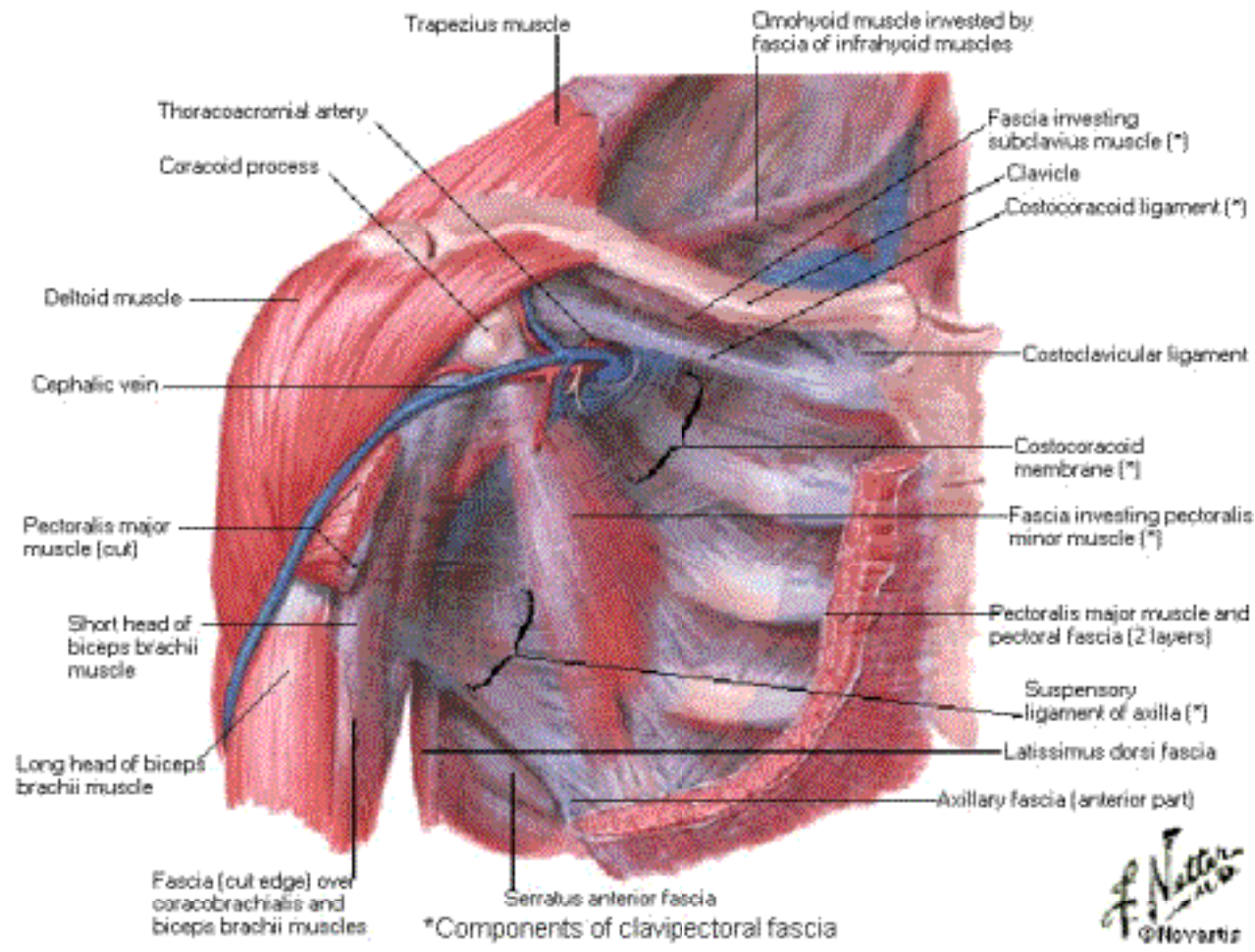
Posterior View



F. Netter
2016

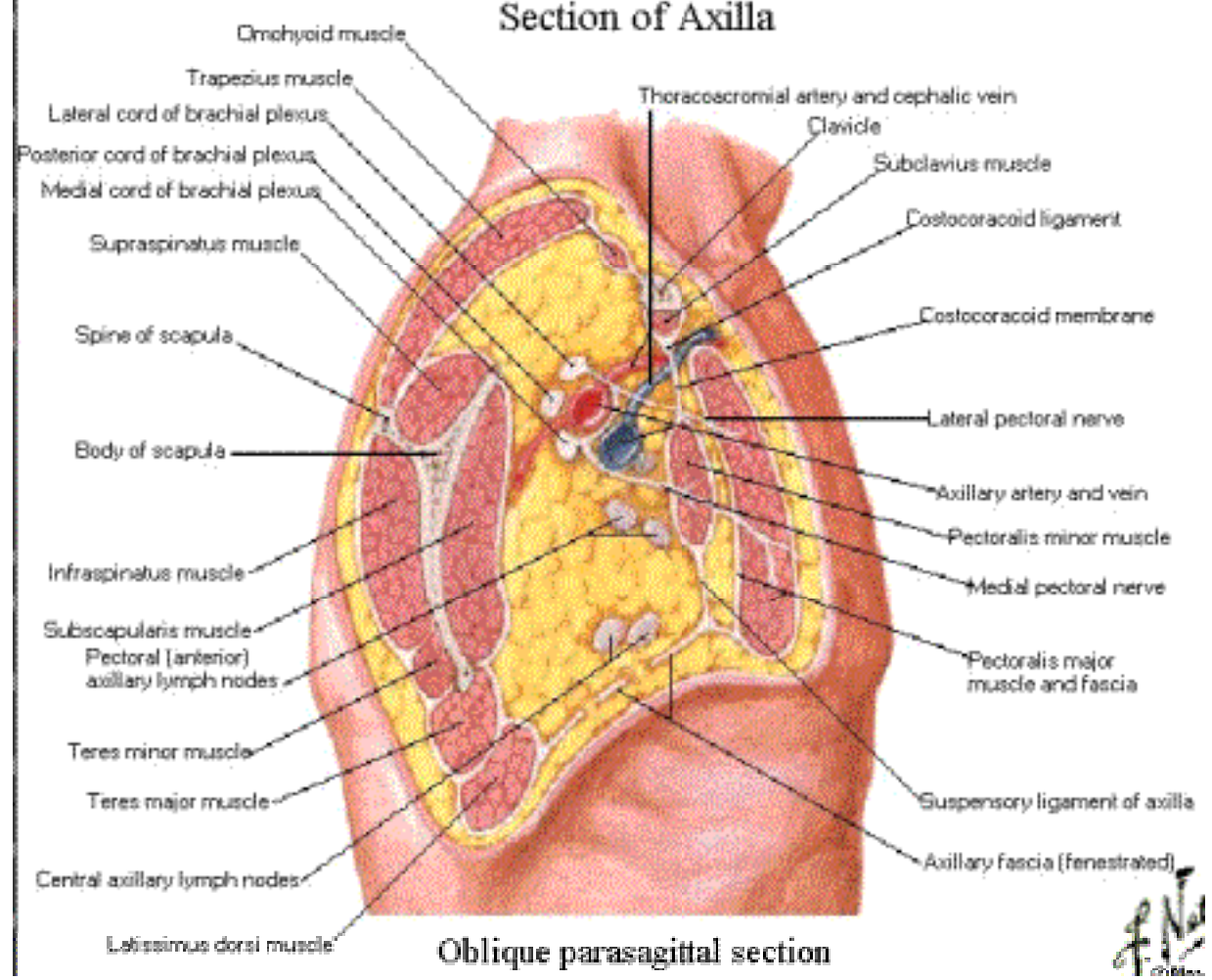
Pectoral, Clavipectoral and Axillary Fasciae

Anterior View



Pectoral, Clavipectoral and Axillary Fasciae

Section of Axilla

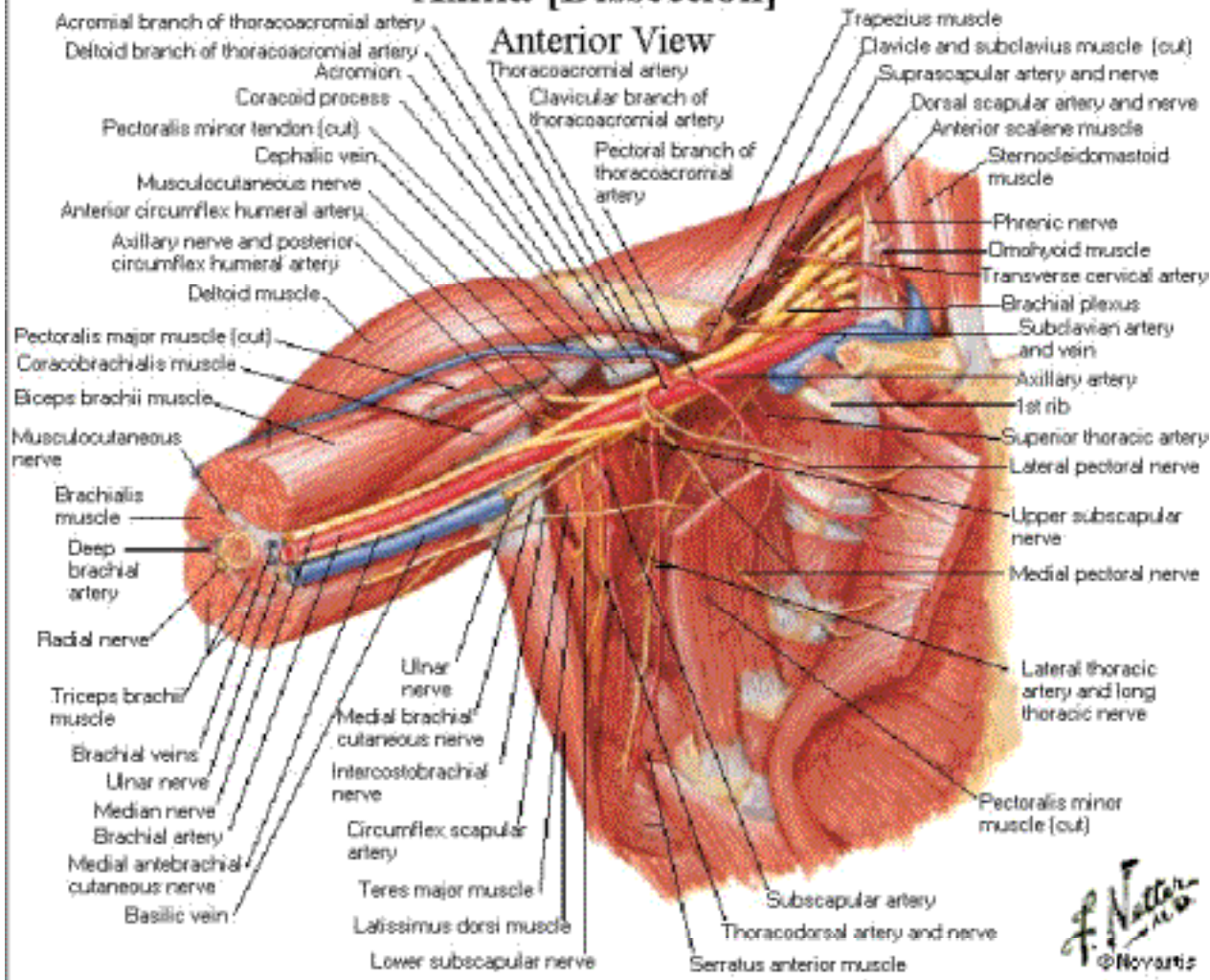


Oblique parasagittal section

F.N.
© 2015

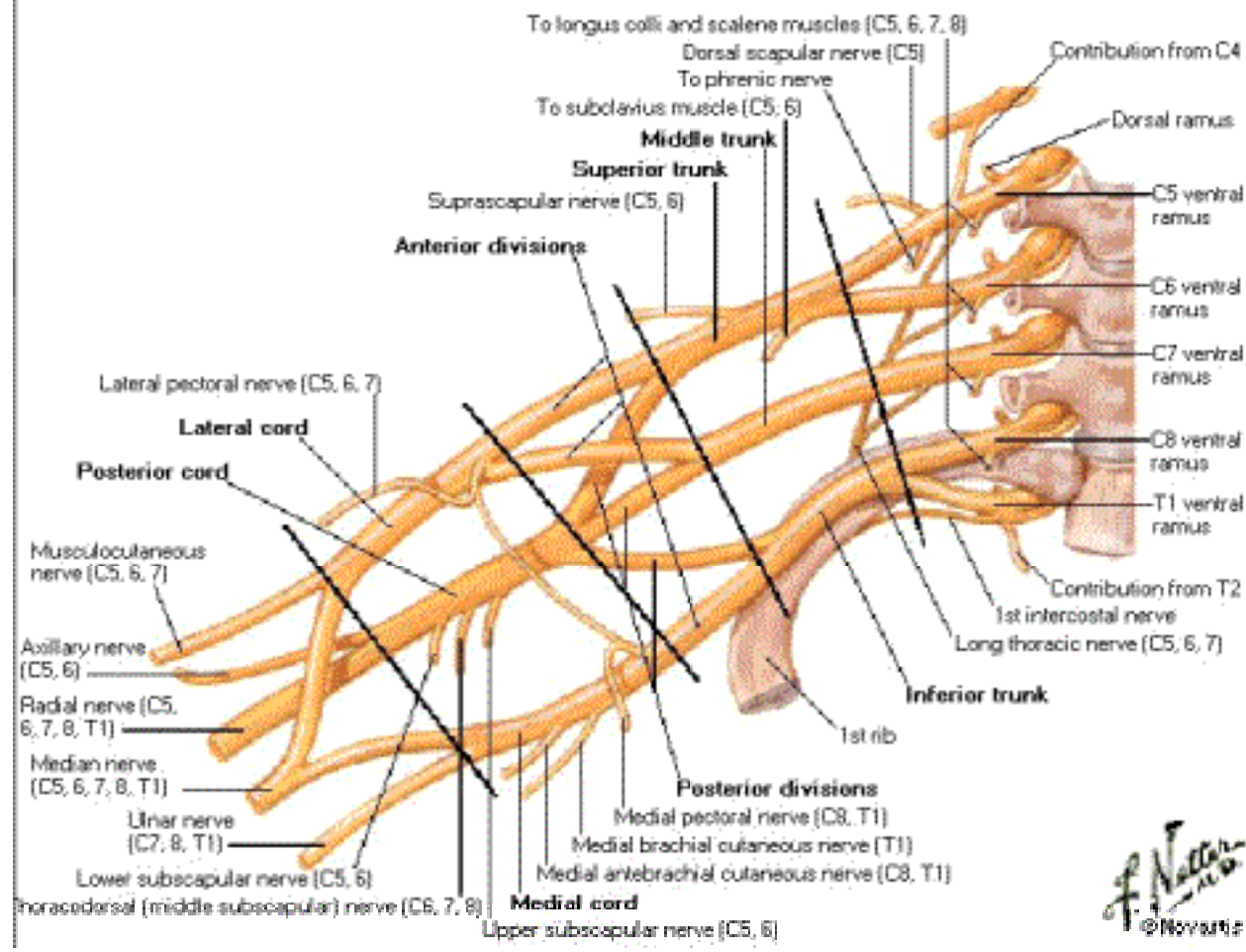
Axilla [Dissection]

Anterior View



Brachial Plexus

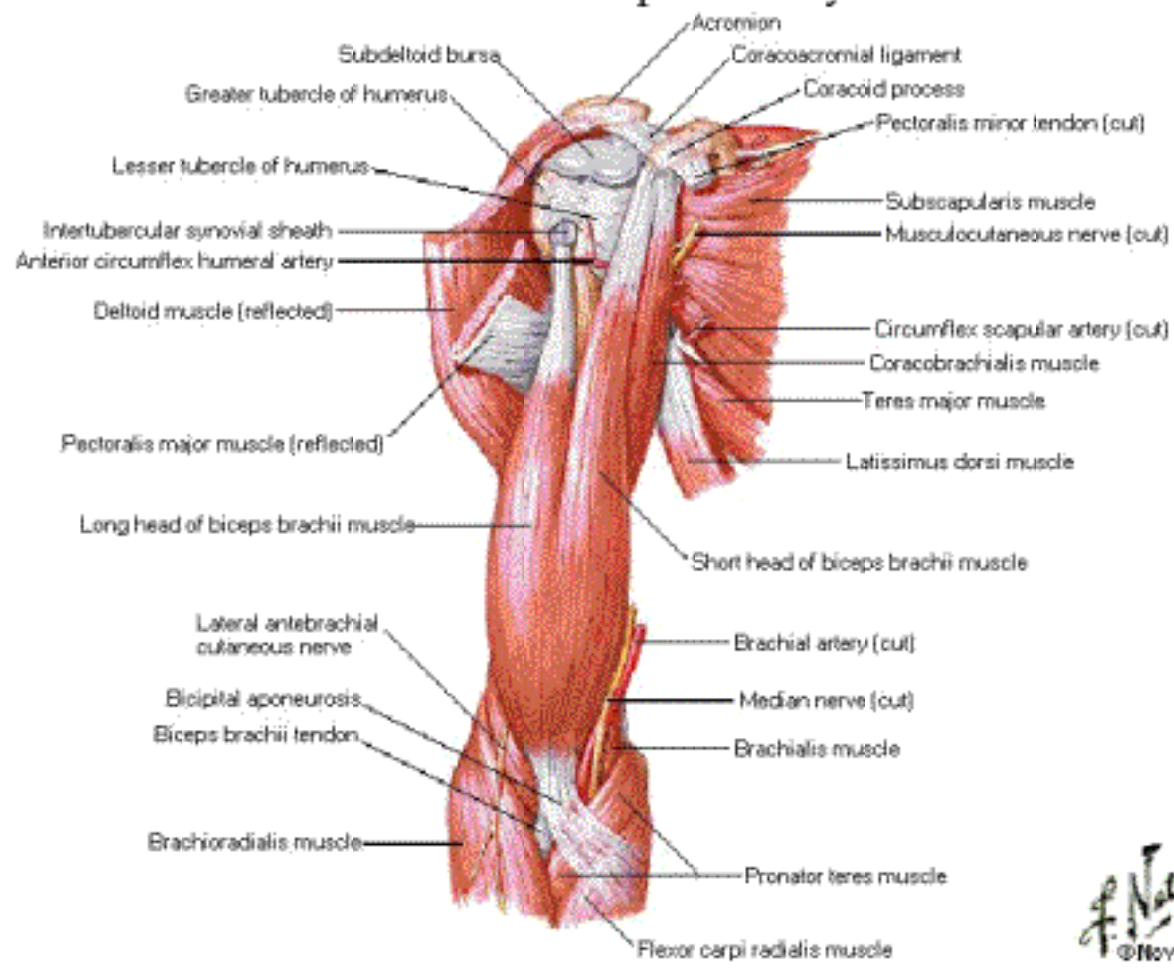
Schema



F. Nasser
© 2015

Muscles of Arm

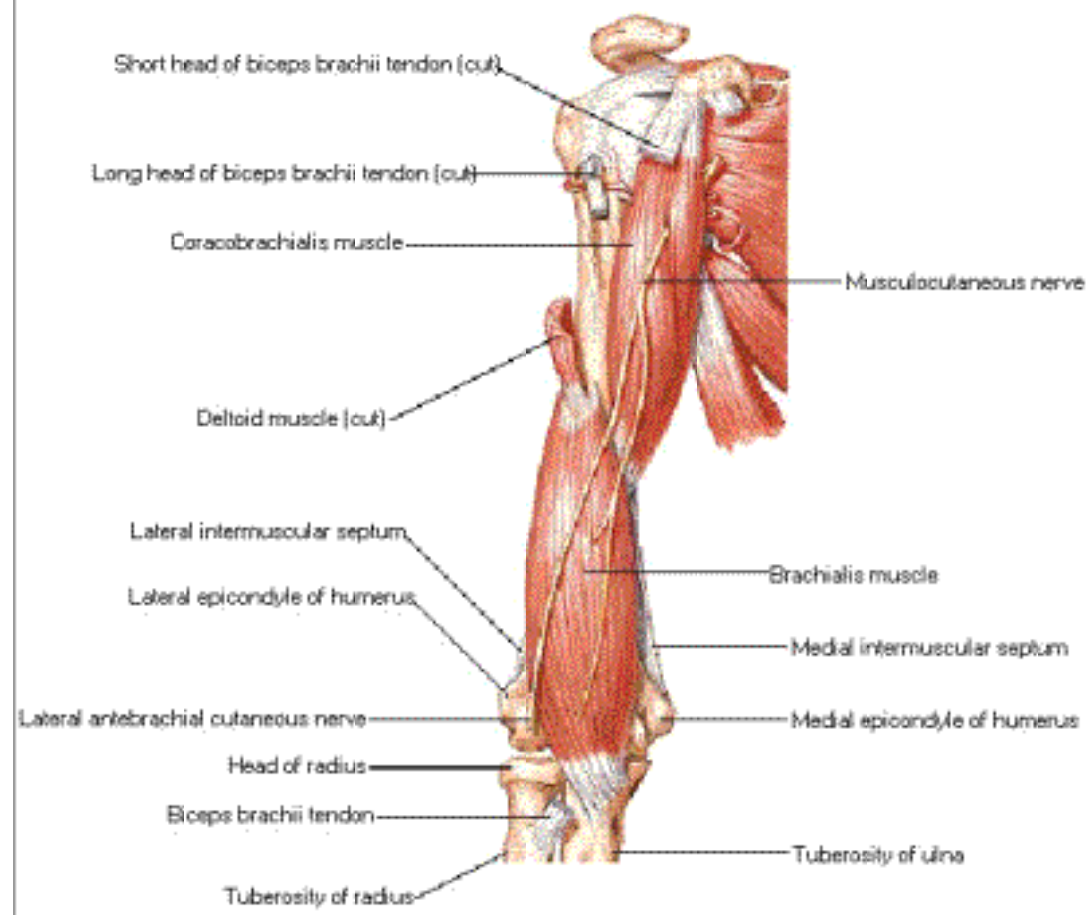
Anterior View - Superficial Layer



f. Net
©Nov

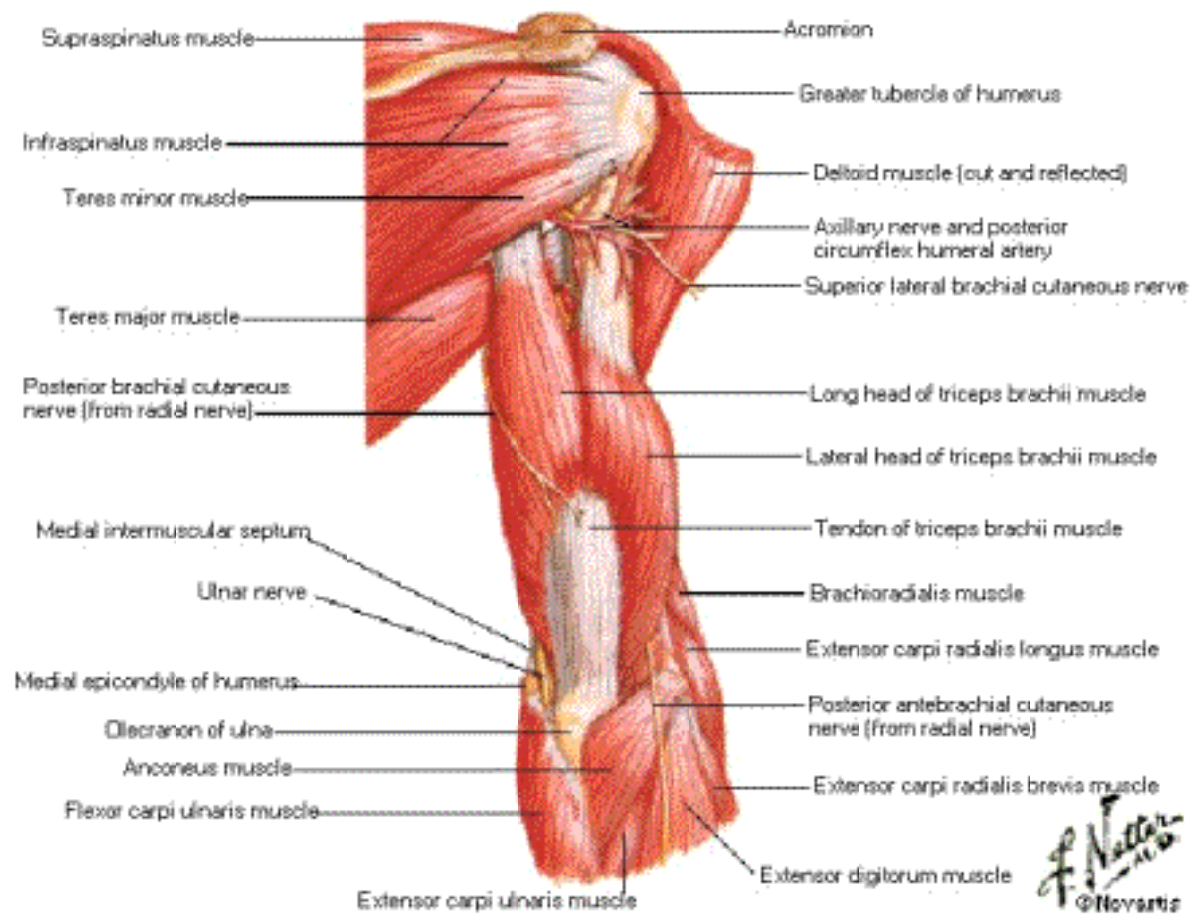
Muscles of Arm

Anterior View - Deep Layer



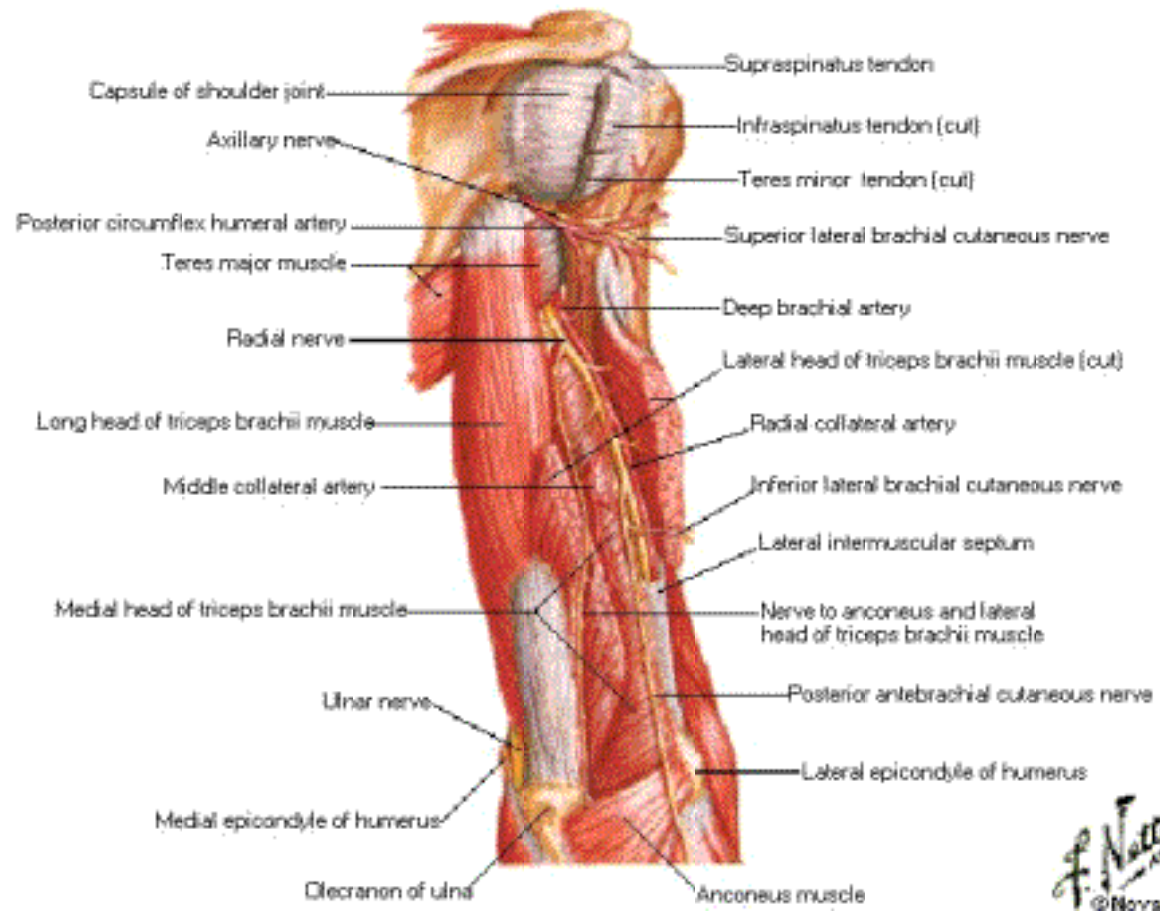
Muscles of Arm

Posterior View - Superficial Layer

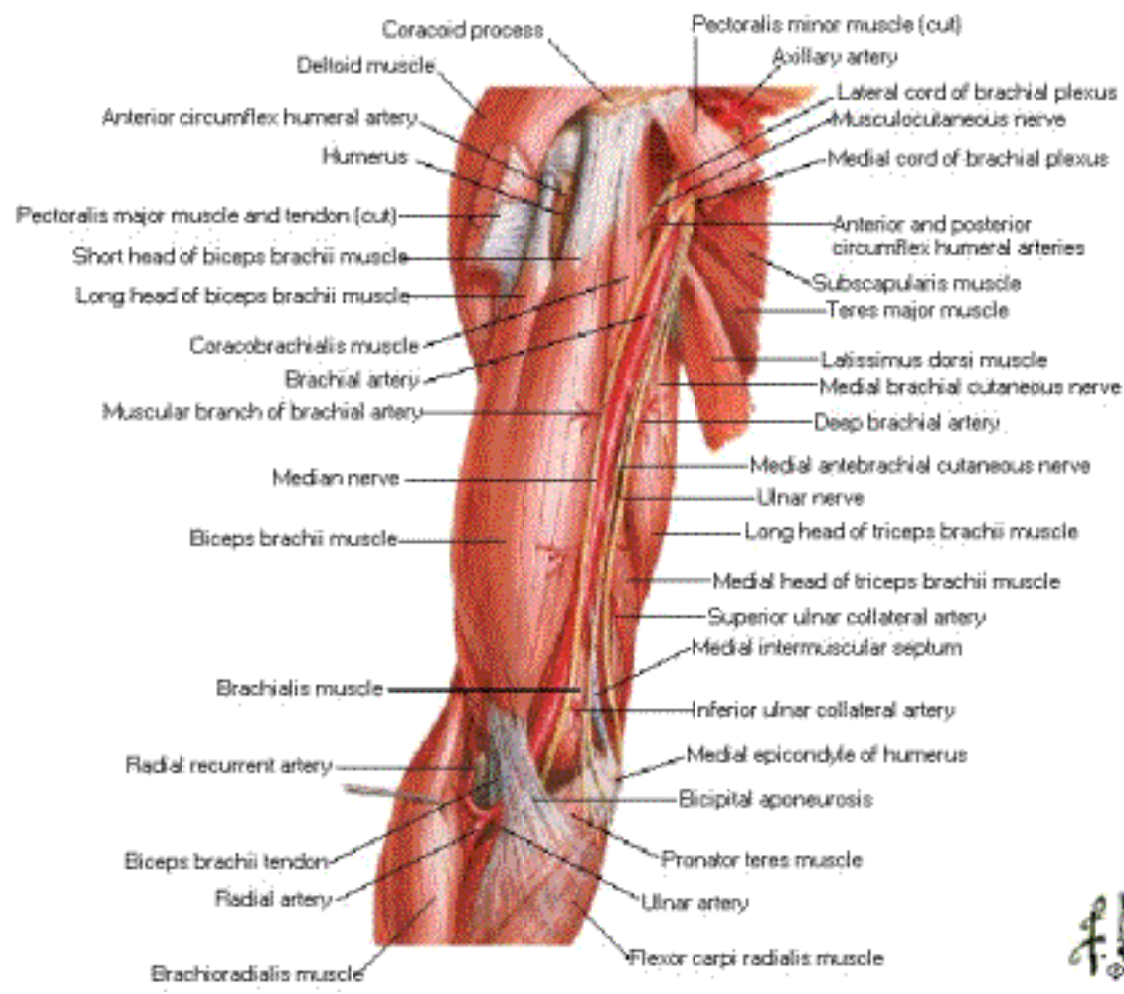


Muscles of Arm

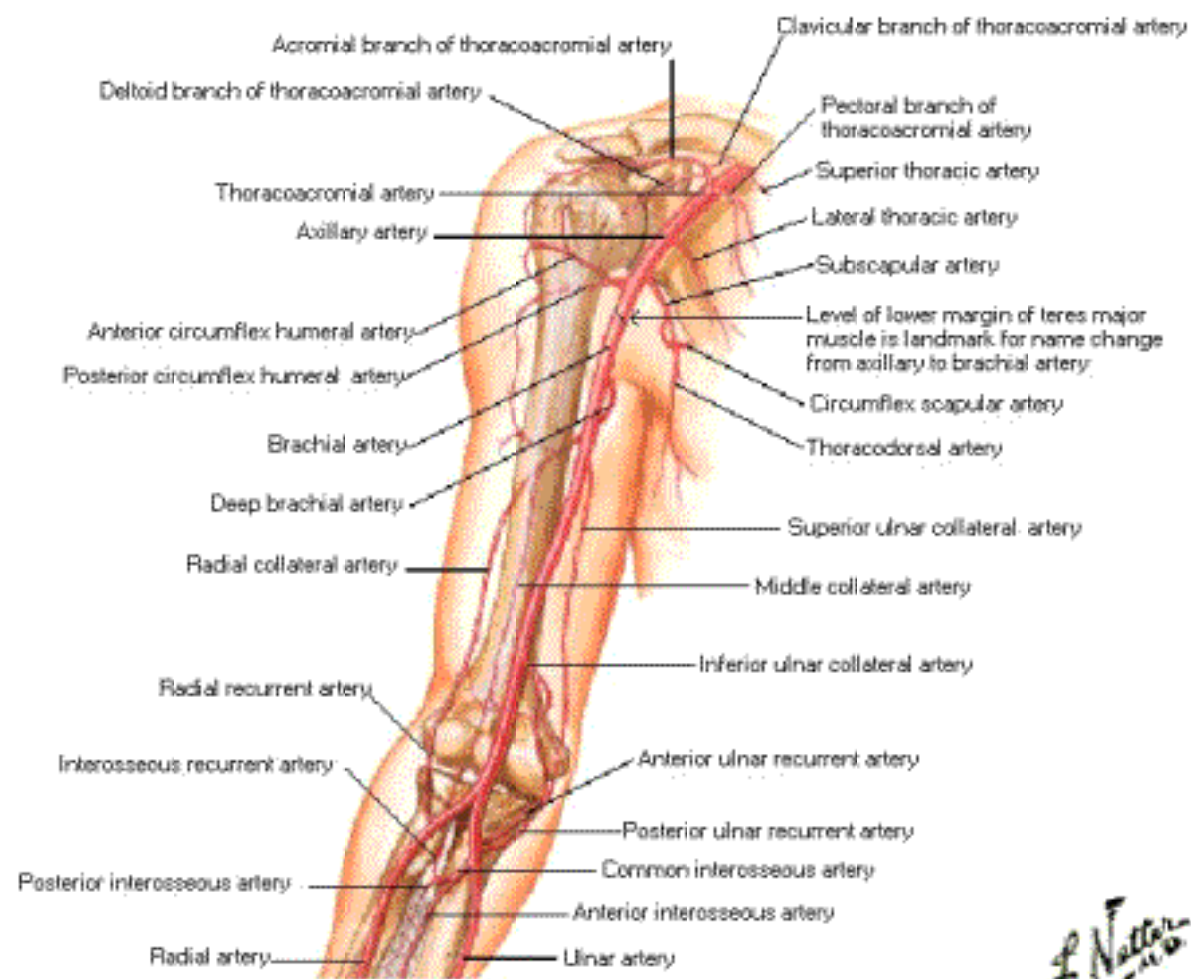
Posterior View - Deep Layer



Brachial Artery in Situ



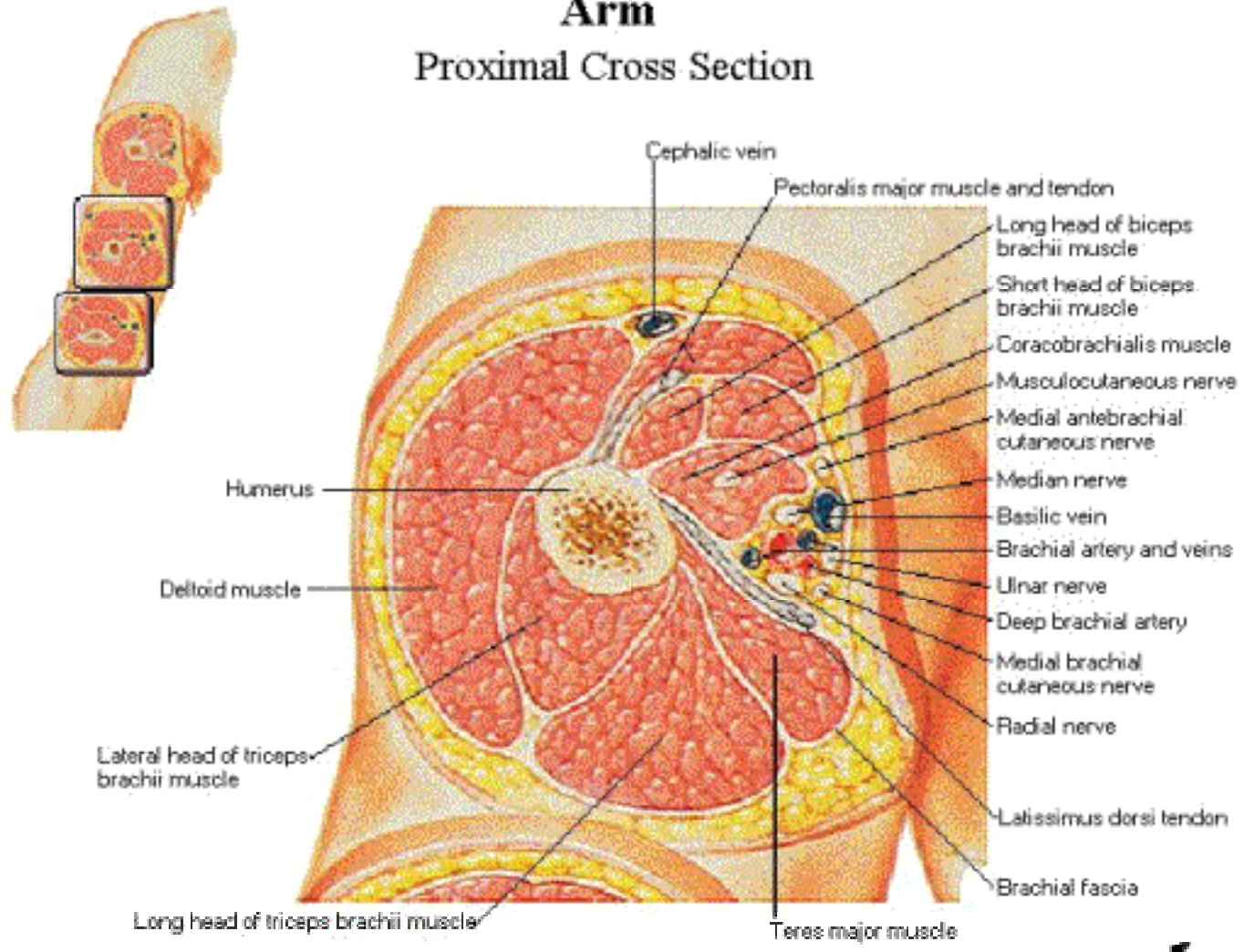
Brachial Artery and Anastomoses Around Elbow



F. Nasser

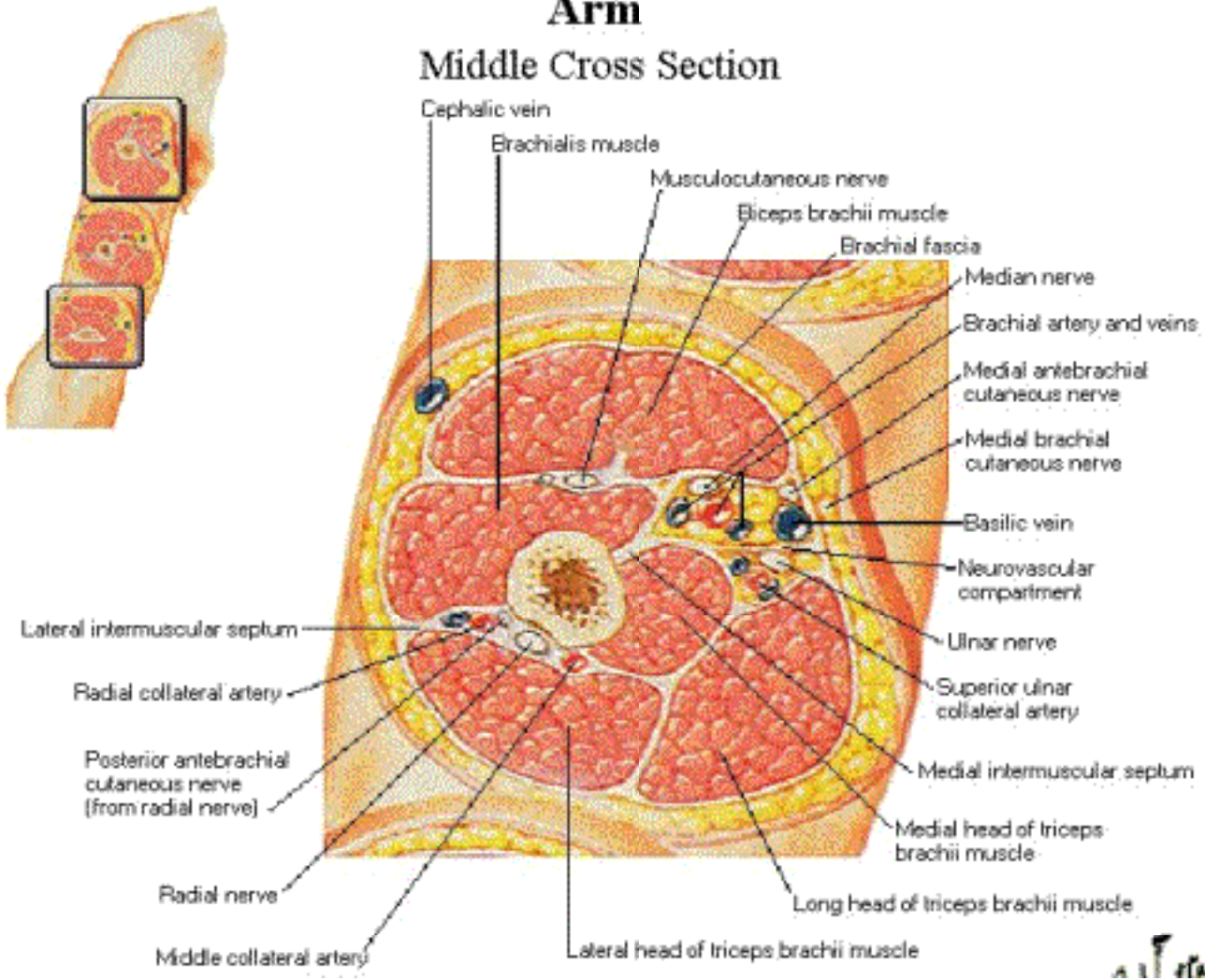
Arm

Proximal Cross Section



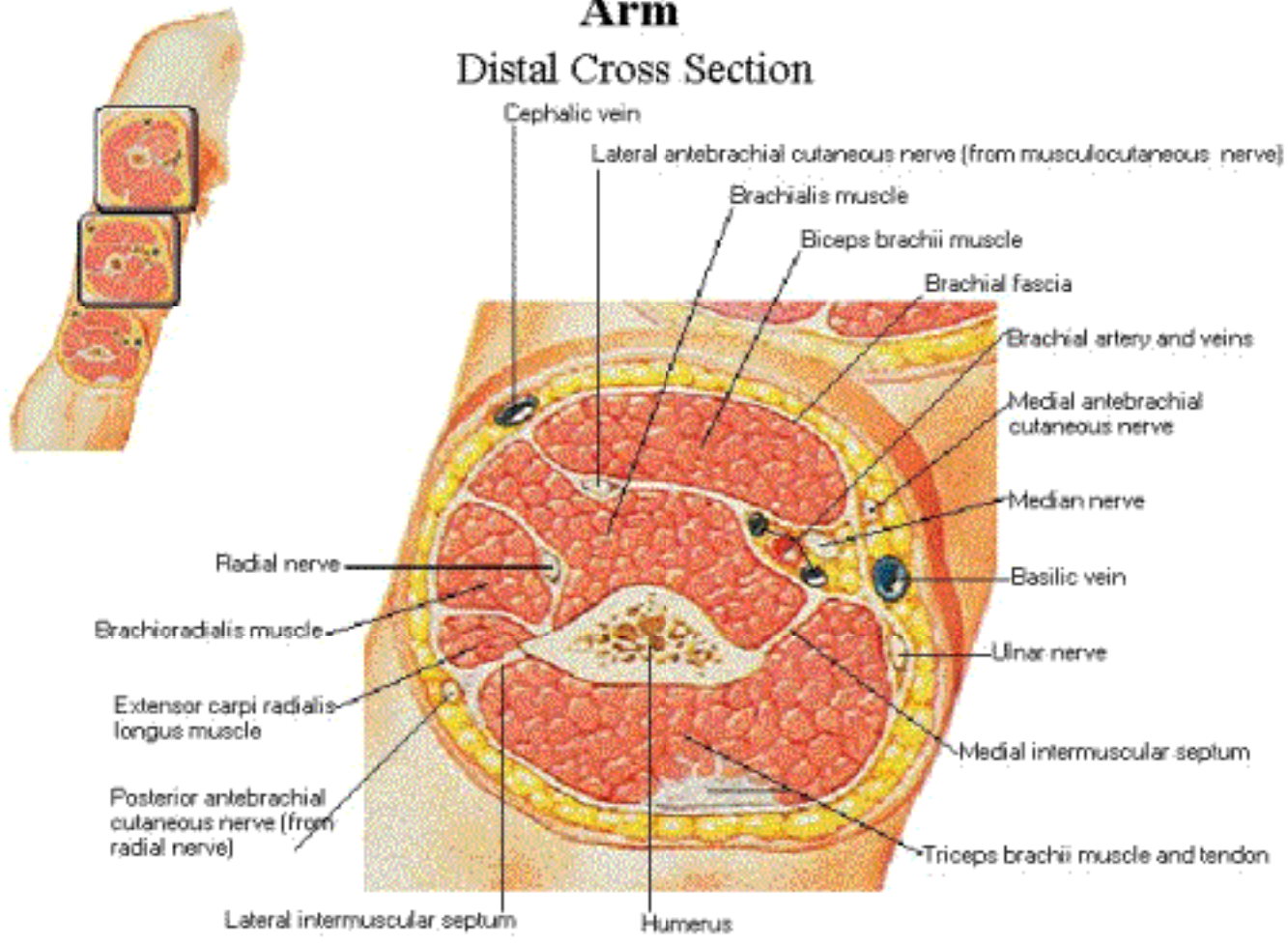
Arm

Middle Cross Section



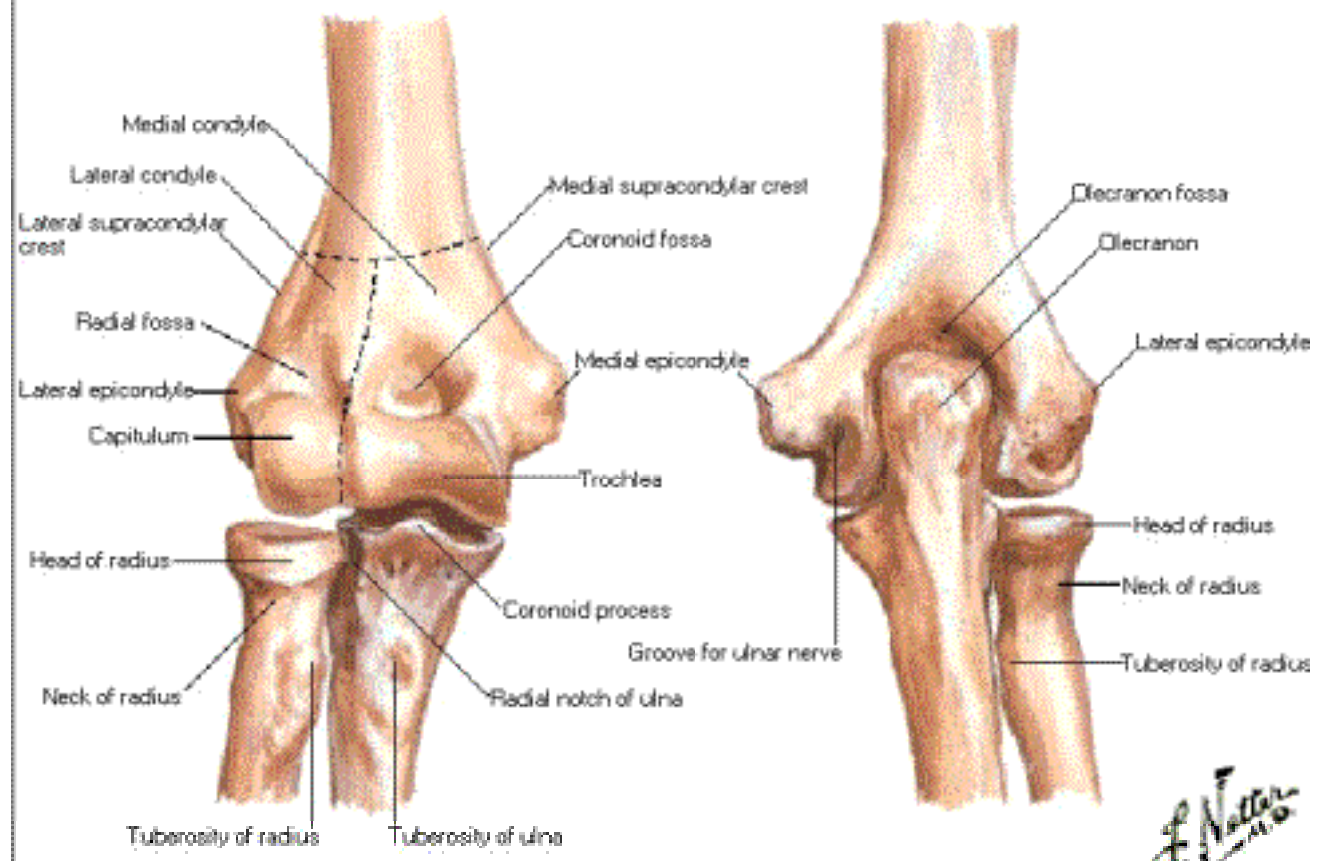
Arm

Distal Cross Section



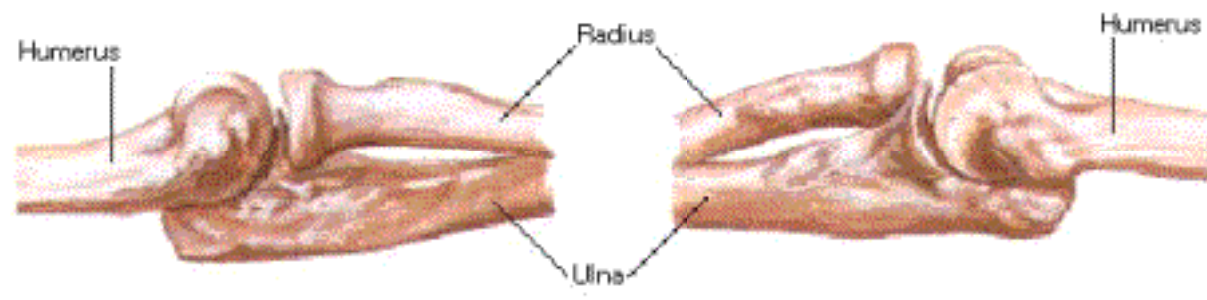
Bones of Elbow in Extension

Anterior and Posterior Views



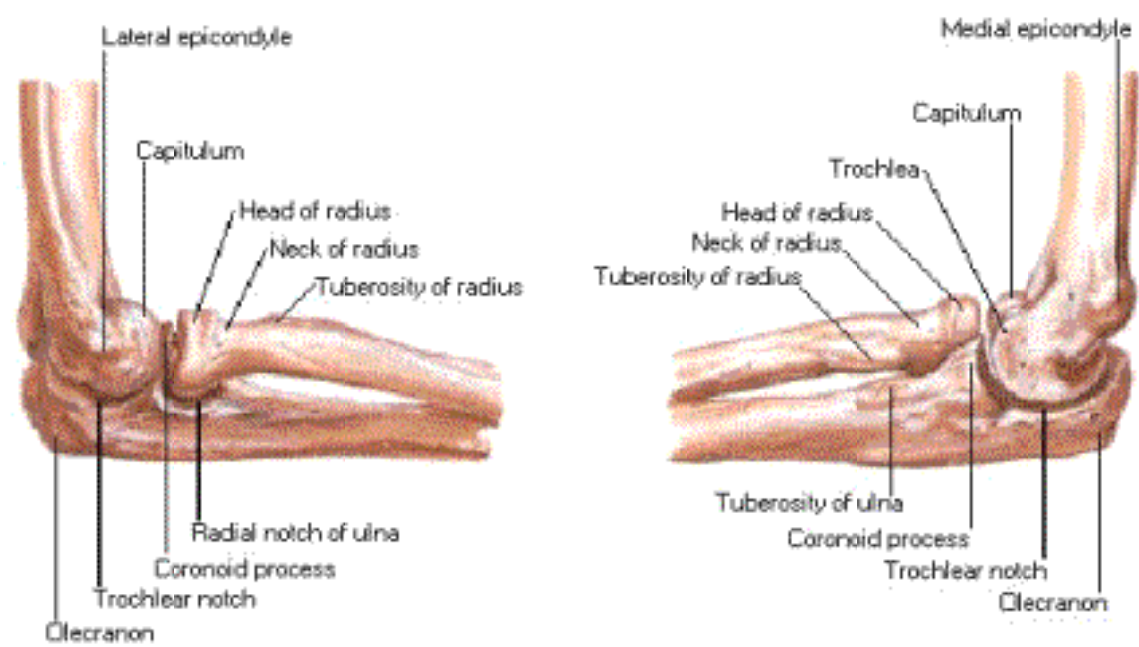
Bones of Elbow in Extension

Lateral and Medial Views

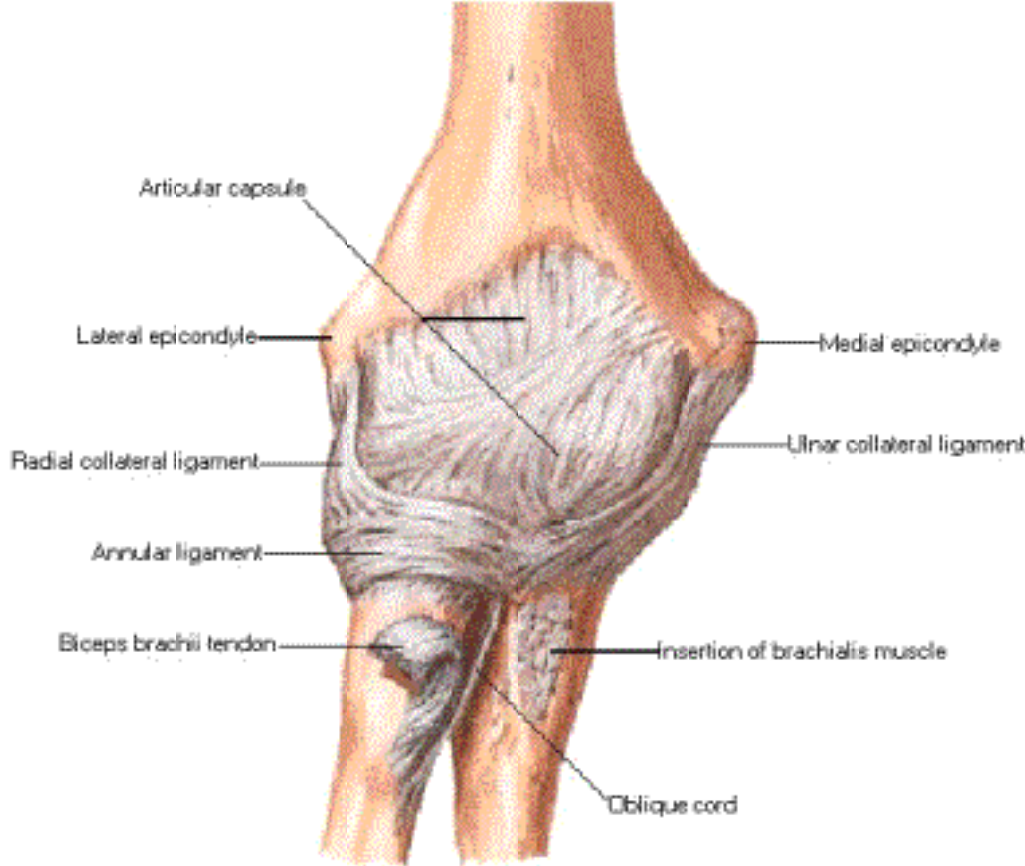


Bones of Elbow in 90° Flexion

Lateral and Medial Views

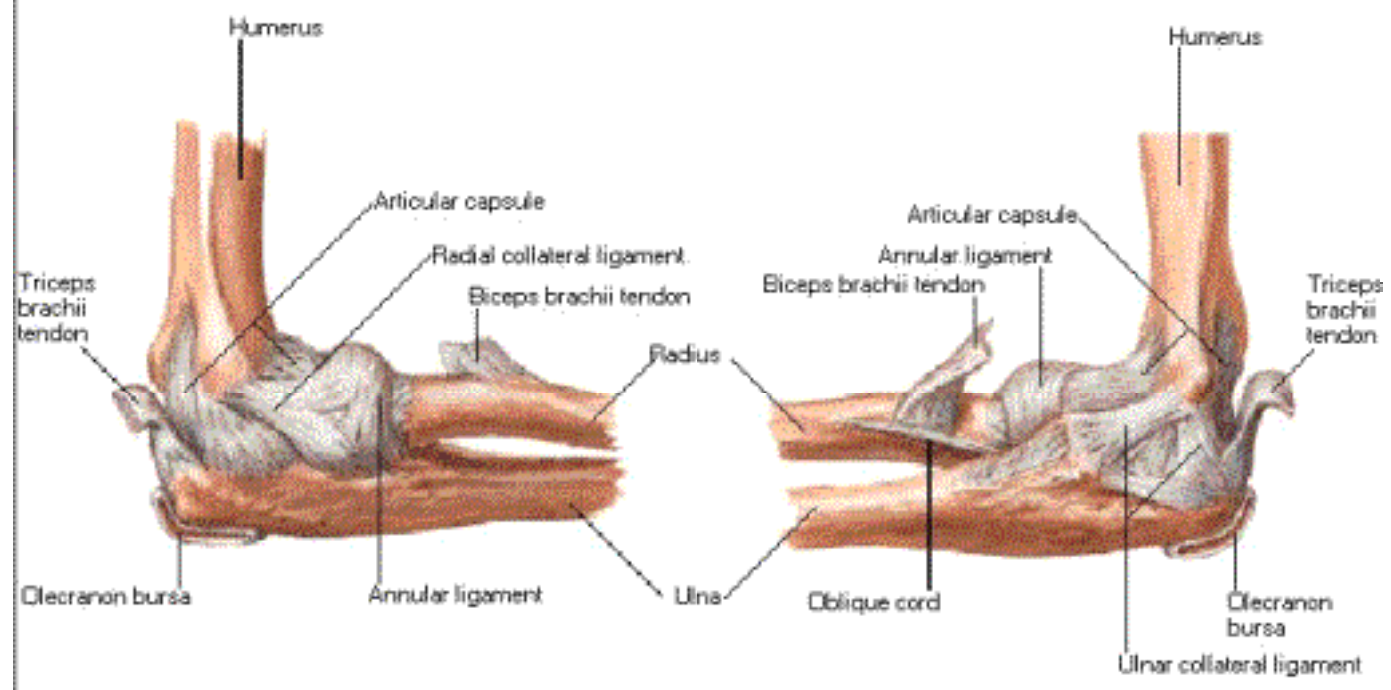


Ligaments of Elbow
Right Elbow - Anterior View



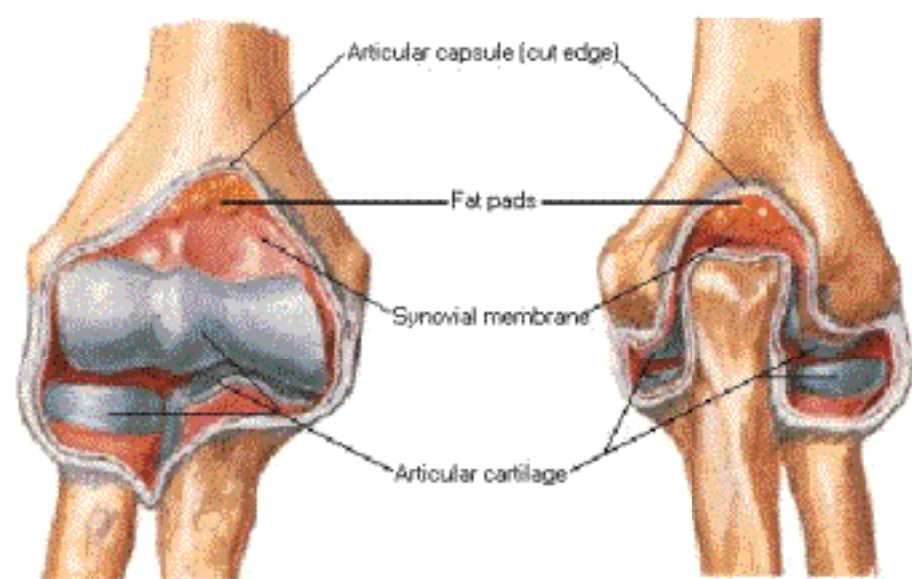
Ligaments of Elbow in 90° Flexion

Lateral and Medial Views



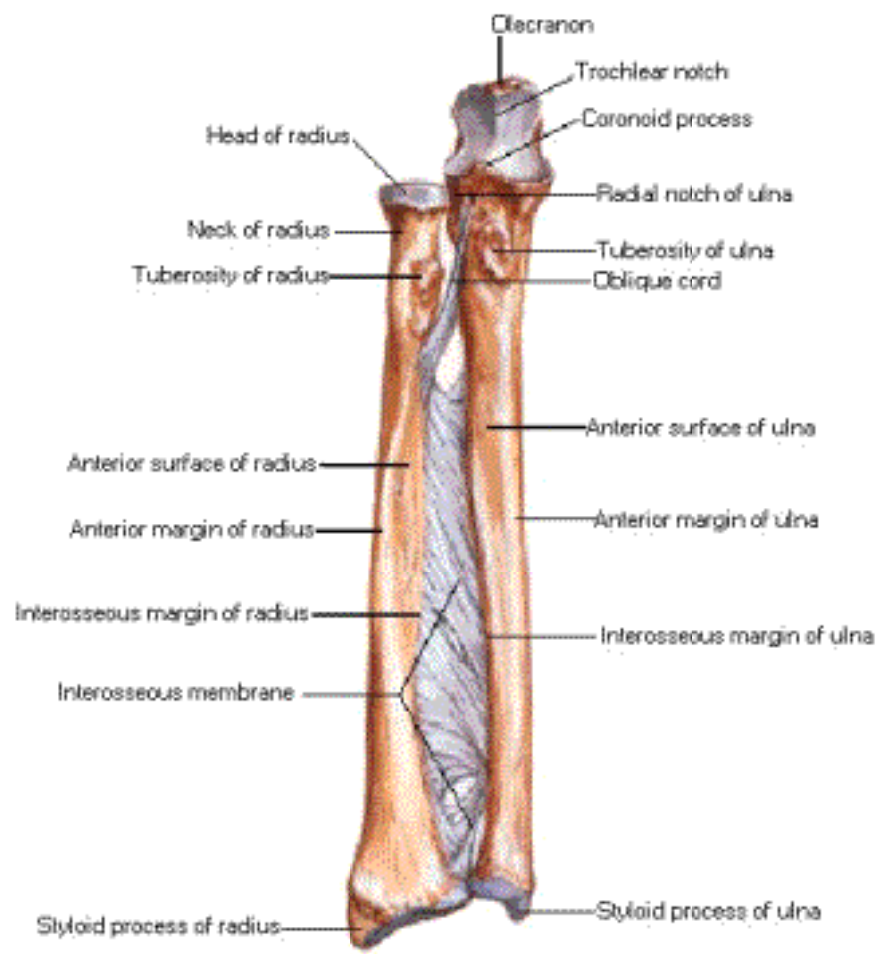
Elbow Joint [Opened]

Anterior and Posterior Views



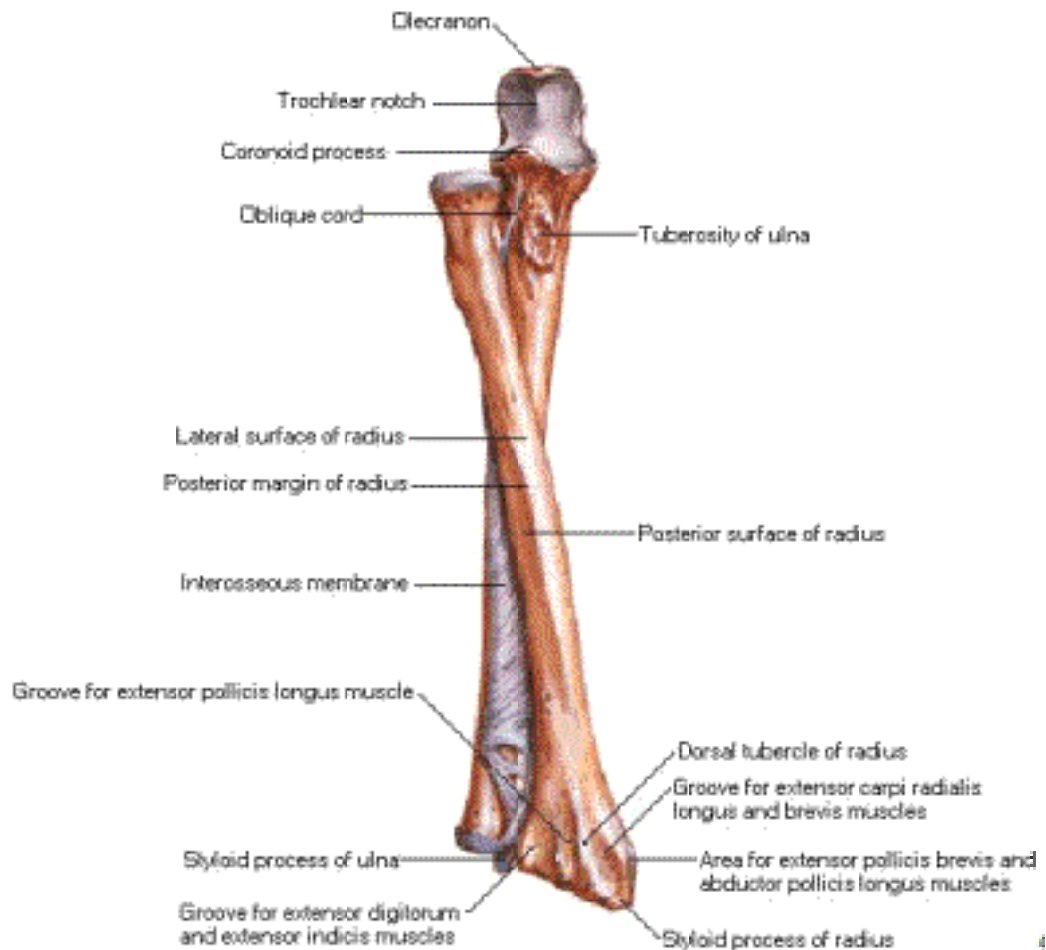
Right Radius and Ulna in Supination

Anterior View



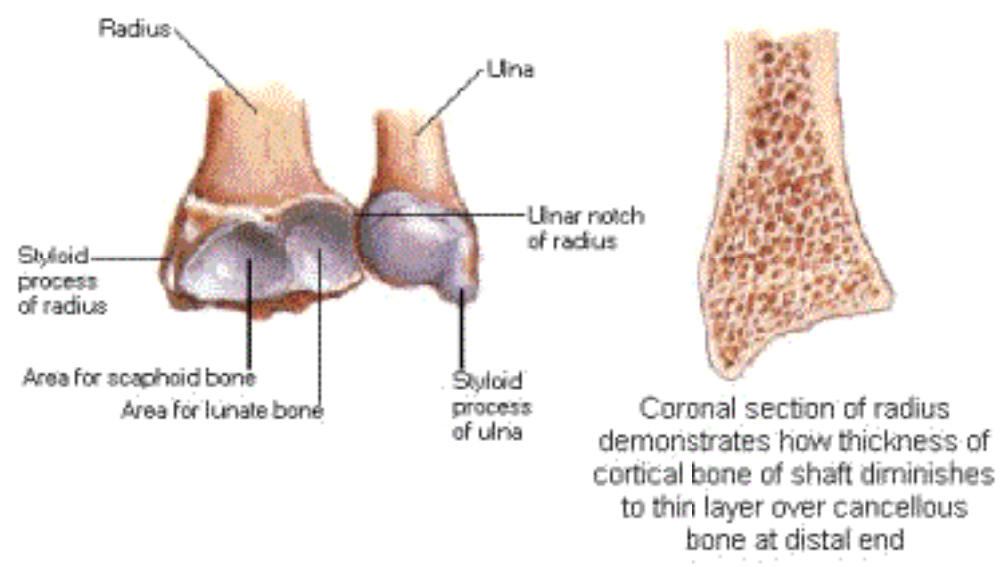
Right Radius and Ulna in Pronation

Anterior View



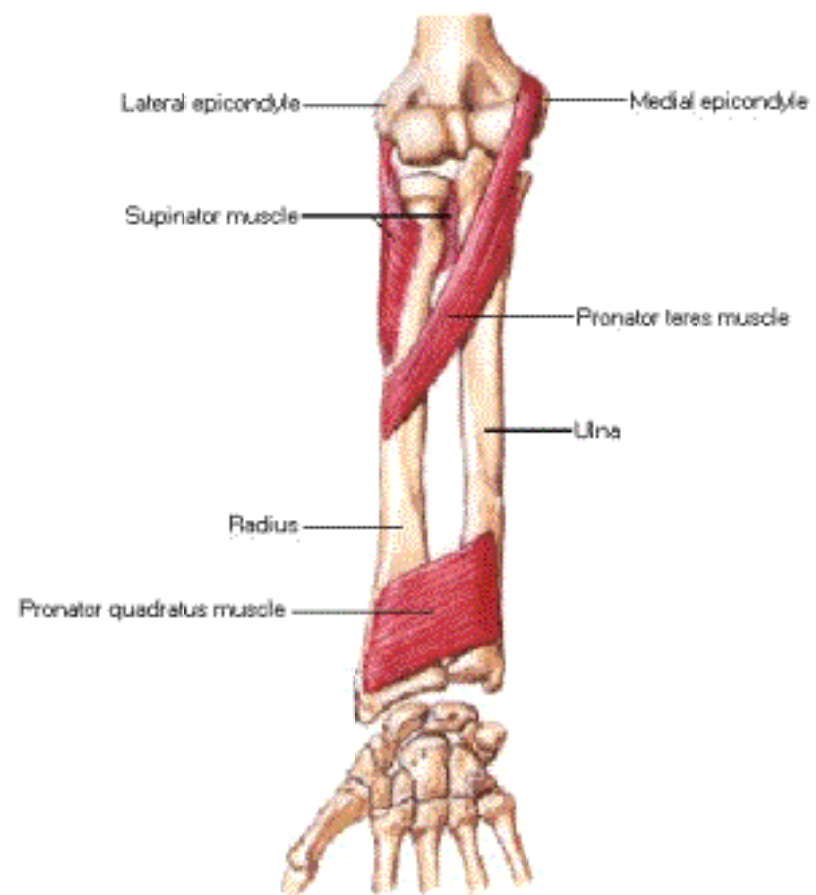
Bones of Forearm

Carpal Articular Surface and Section of Radius



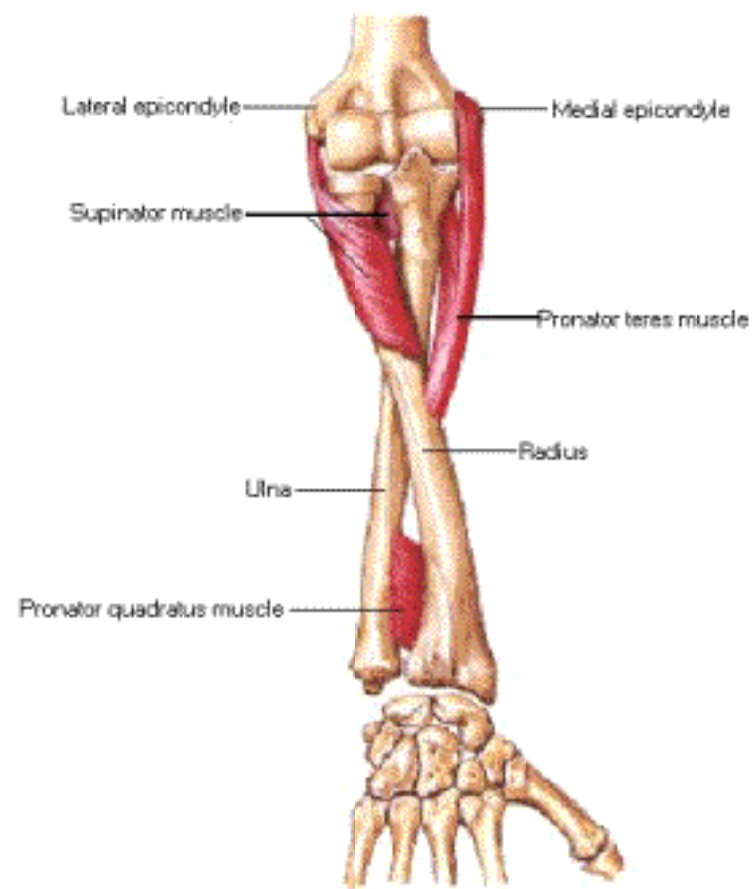
Individual Muscles of Forearm

Rotators of Radius - Supination



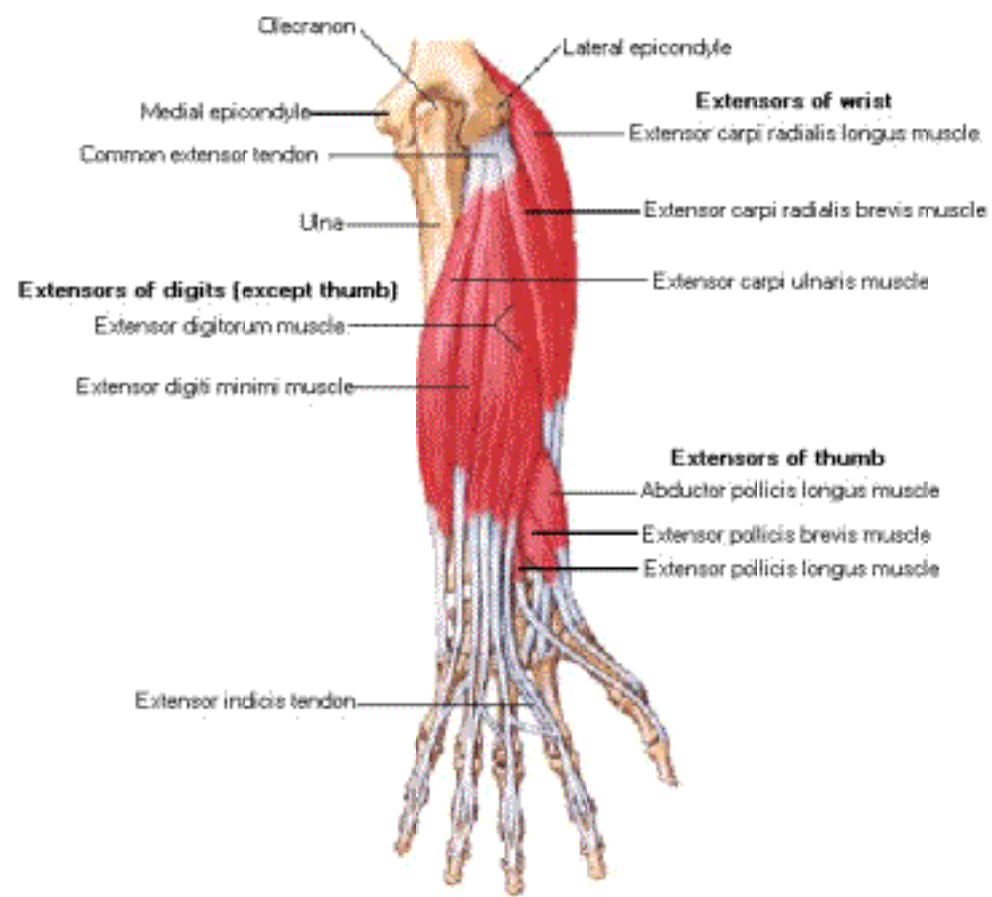
Individual Muscles of Forearm

Rotators of Radius - Pronation



Individual Muscles of Forearm

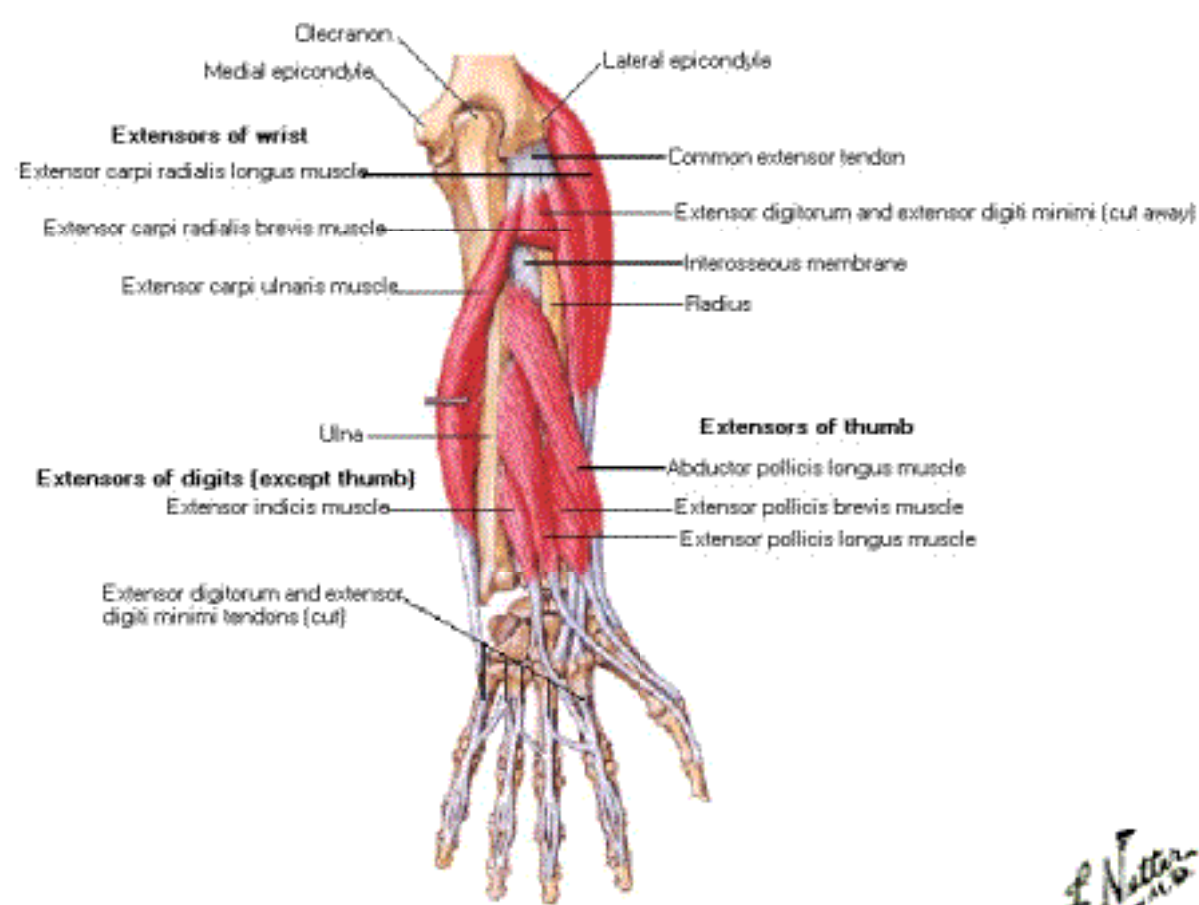
Extensors of Wrist and Digits



Note: anconeus muscle not shown because it is extensor of elbow

Individual Muscles of Forearm [Continued]

Extensors of Wrist and Digits

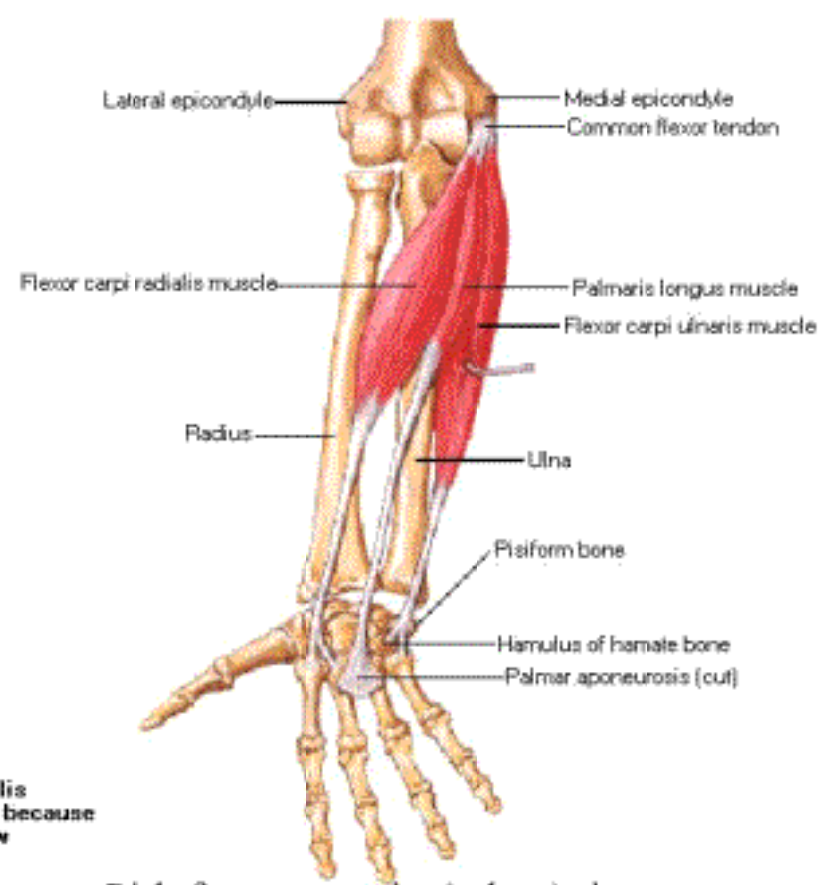


Note: anconeus muscle not shown because it is extensor of elbow

F. Netter M.D.
© 1989

Individual Muscles of Forearm

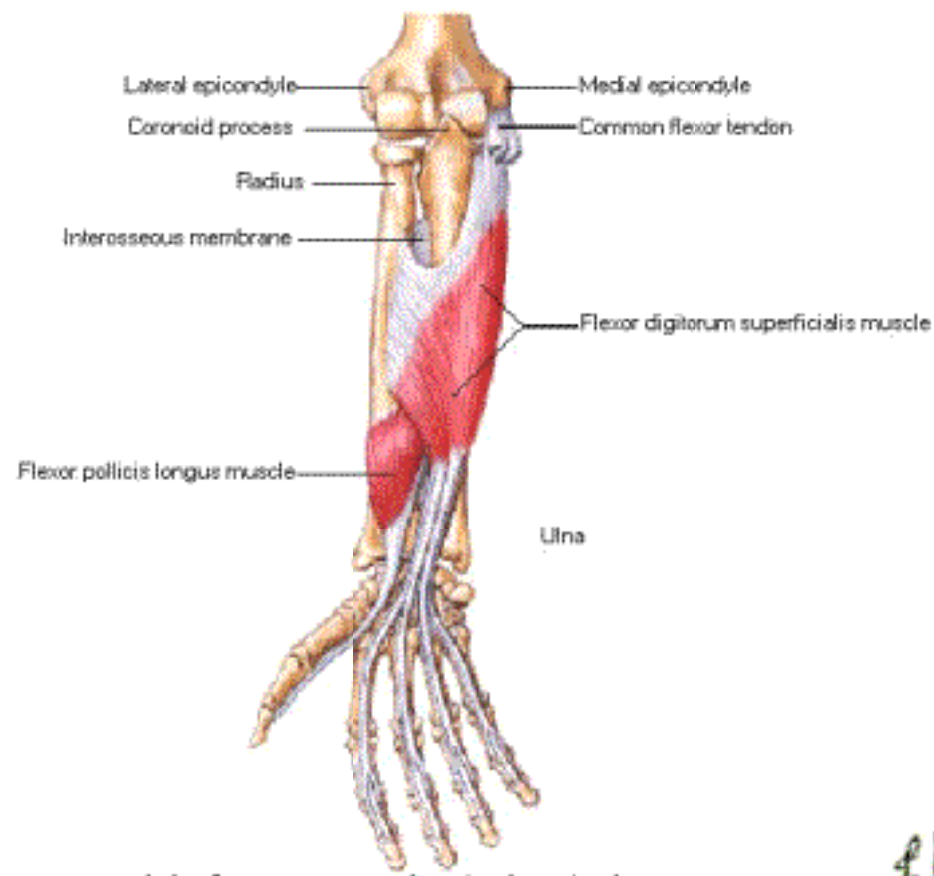
Flexors of Wrist



Right forearm: anterior (palmar) view

Individual Muscles of Forearm

Flexors of Digits

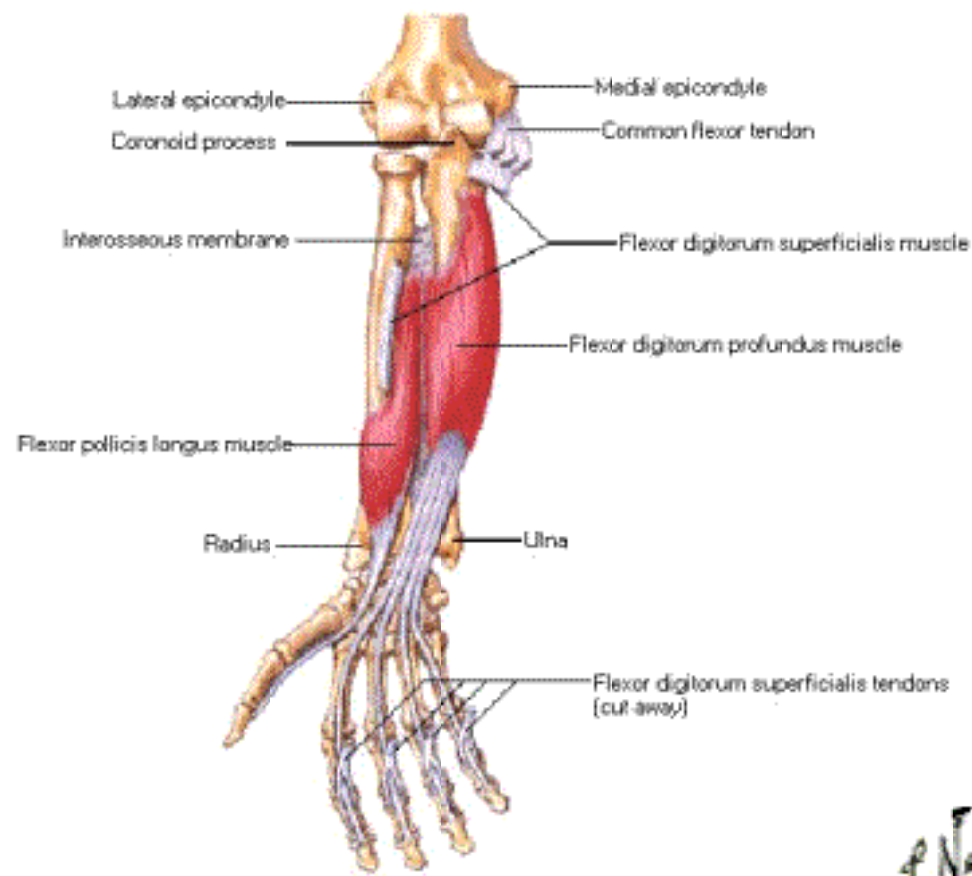


Right forearm: anterior (palmar) view



Individual Muscles of Forearm [Continued]

Flexors of Digits

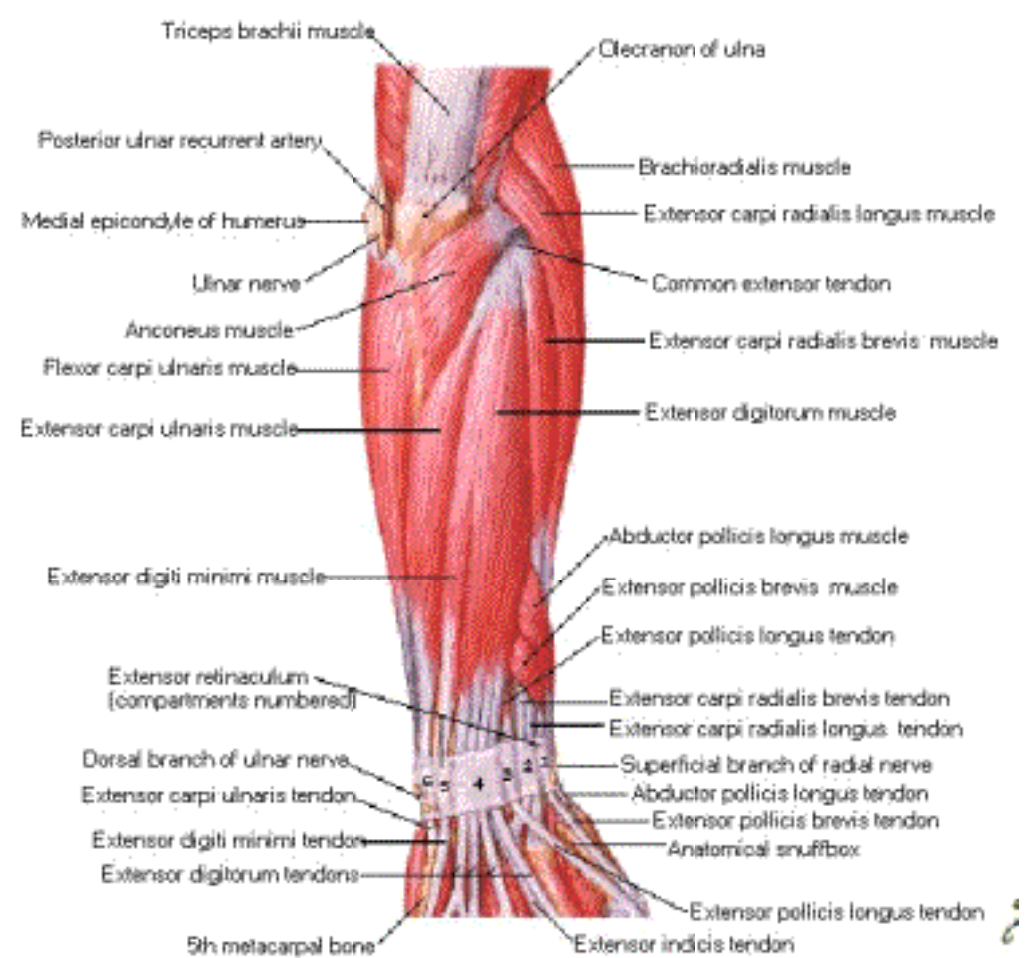


Right forearm: anterior (palmar) view



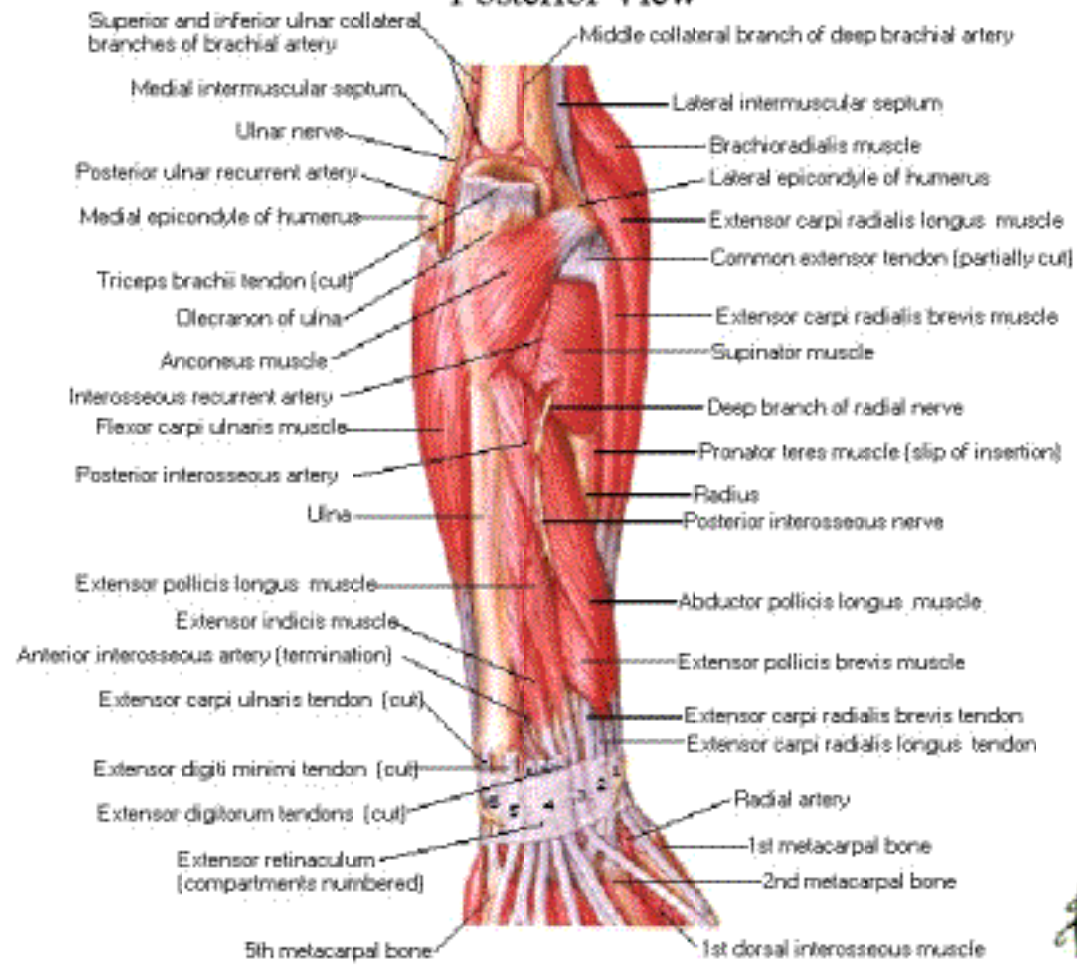
Muscles of Forearm [Superficial Layer]

Posterior View



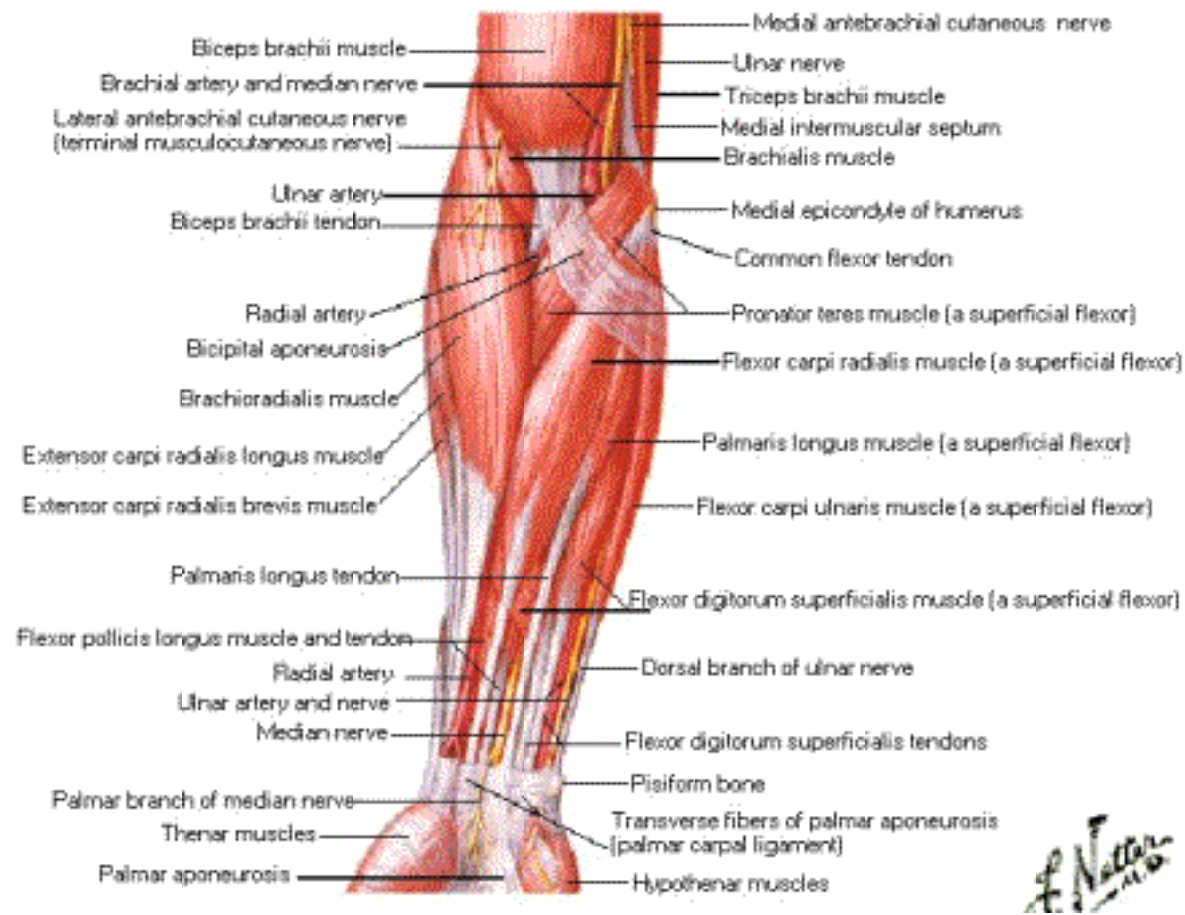
Muscles of Forearm [Deep Layer]

Posterior View



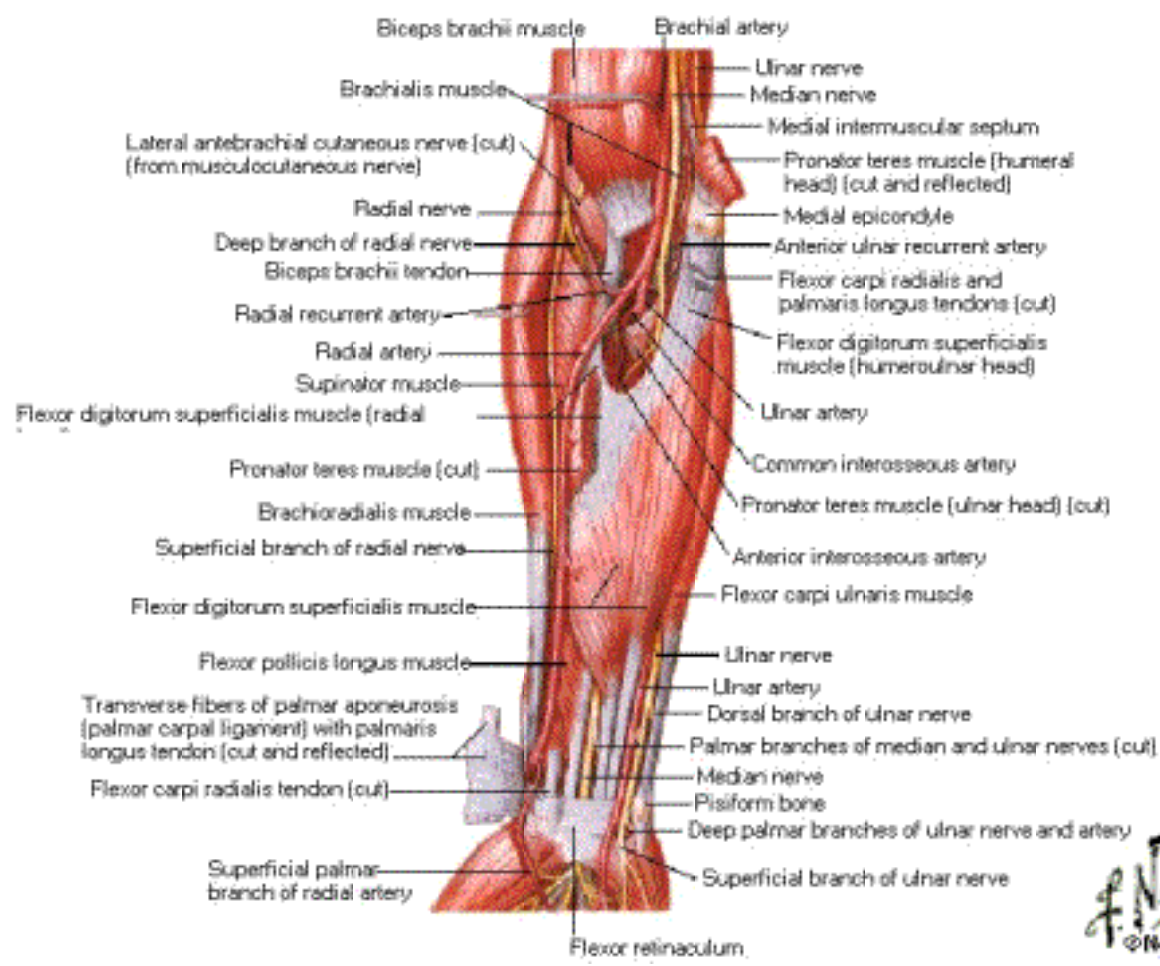
Muscles of Forearm [Superficial Layer]

Anterior View



Muscles of Forearm [Intermediate Layer]

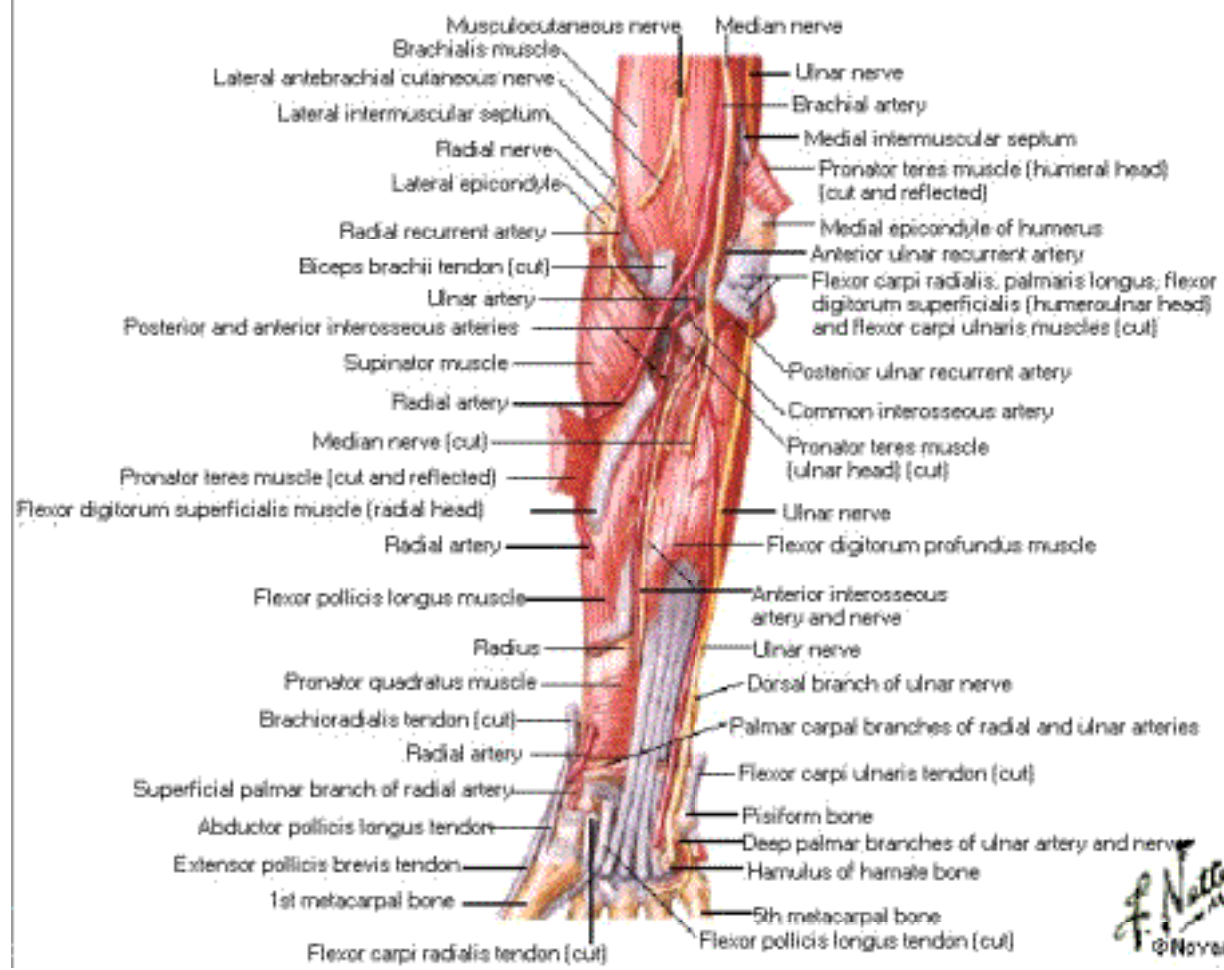
Anterior View



F.N.
©19c

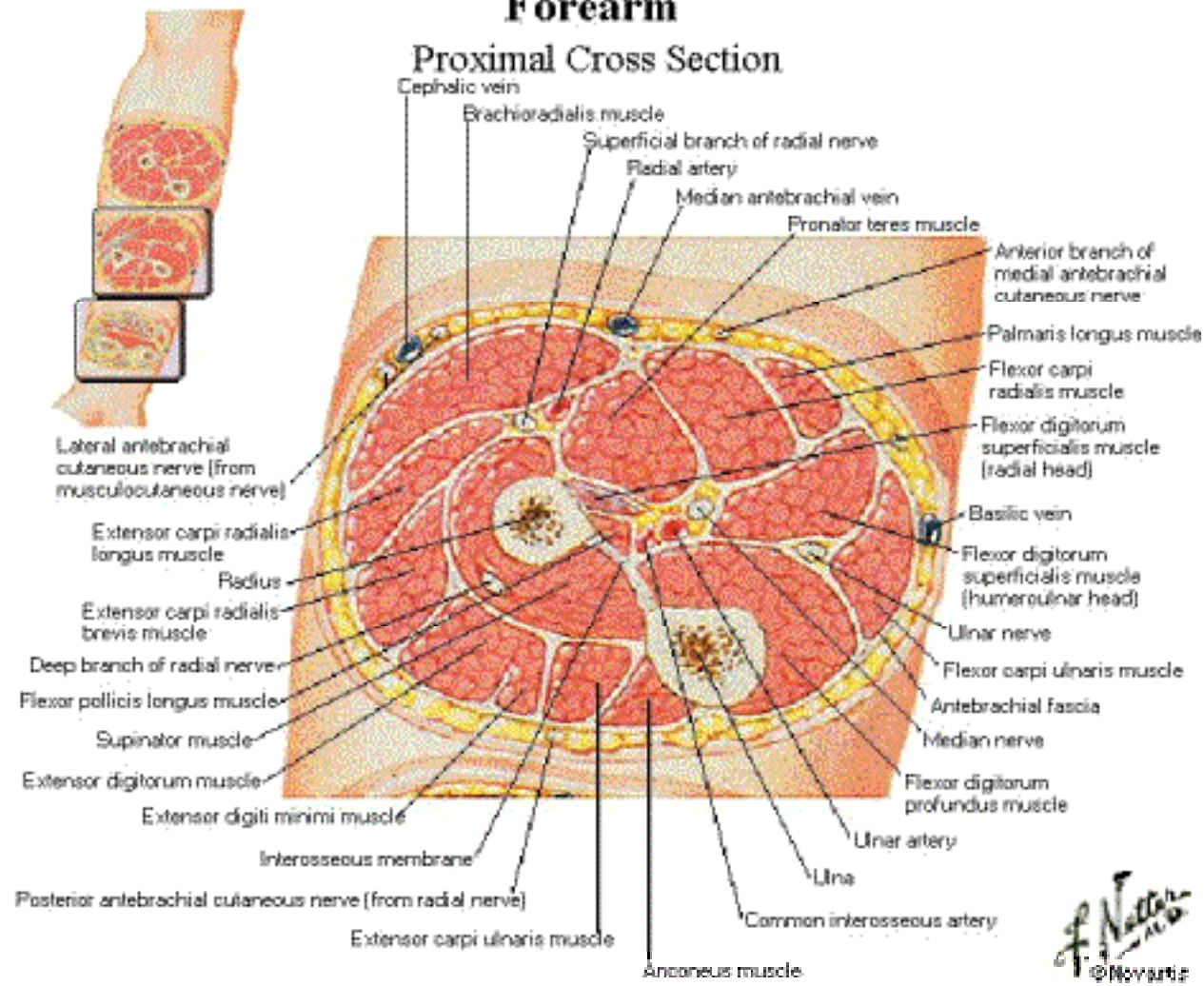
Muscles of Forearm [Deep Layer]

Anterior View



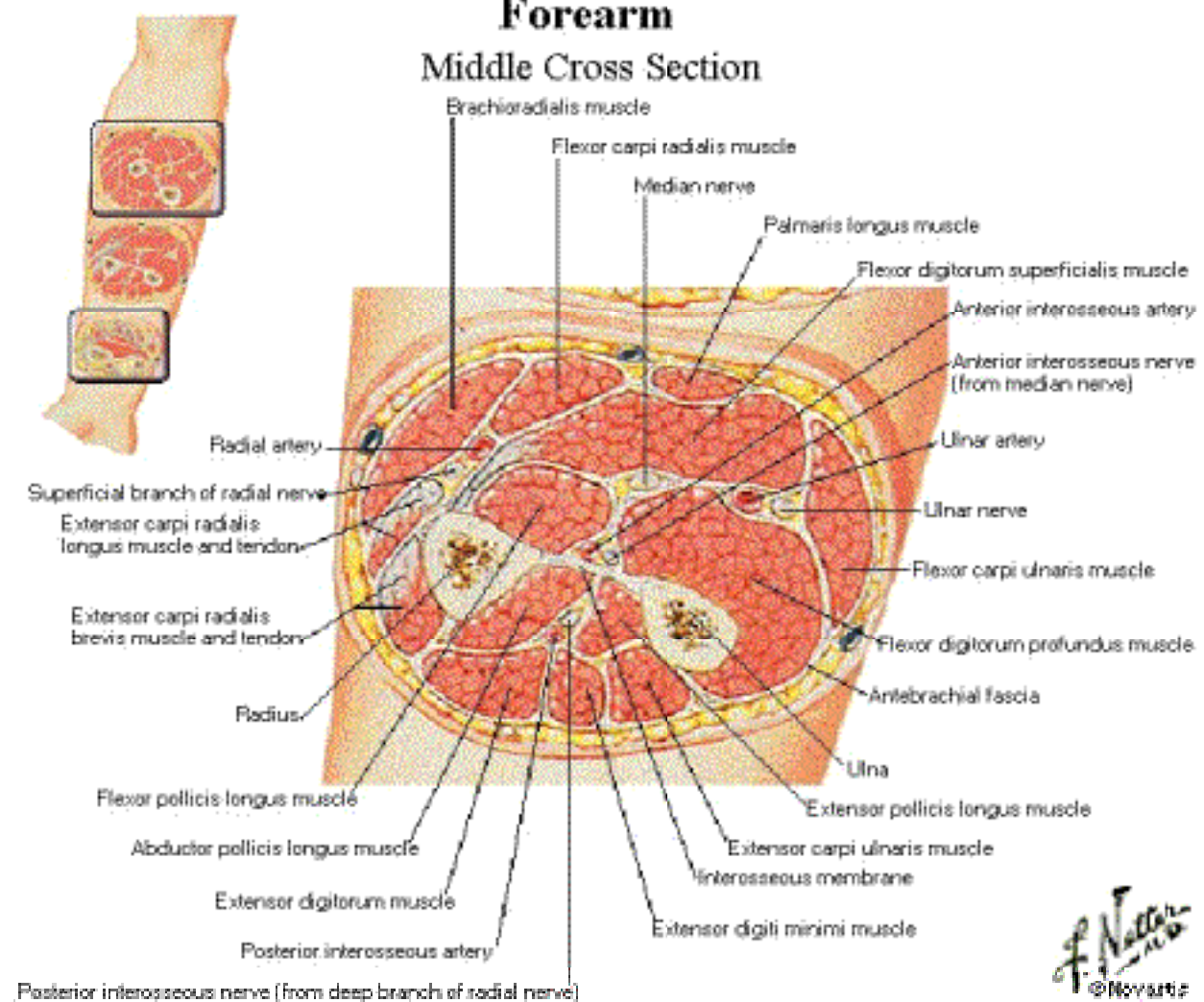
Forearm

Proximal Cross Section



Forearm

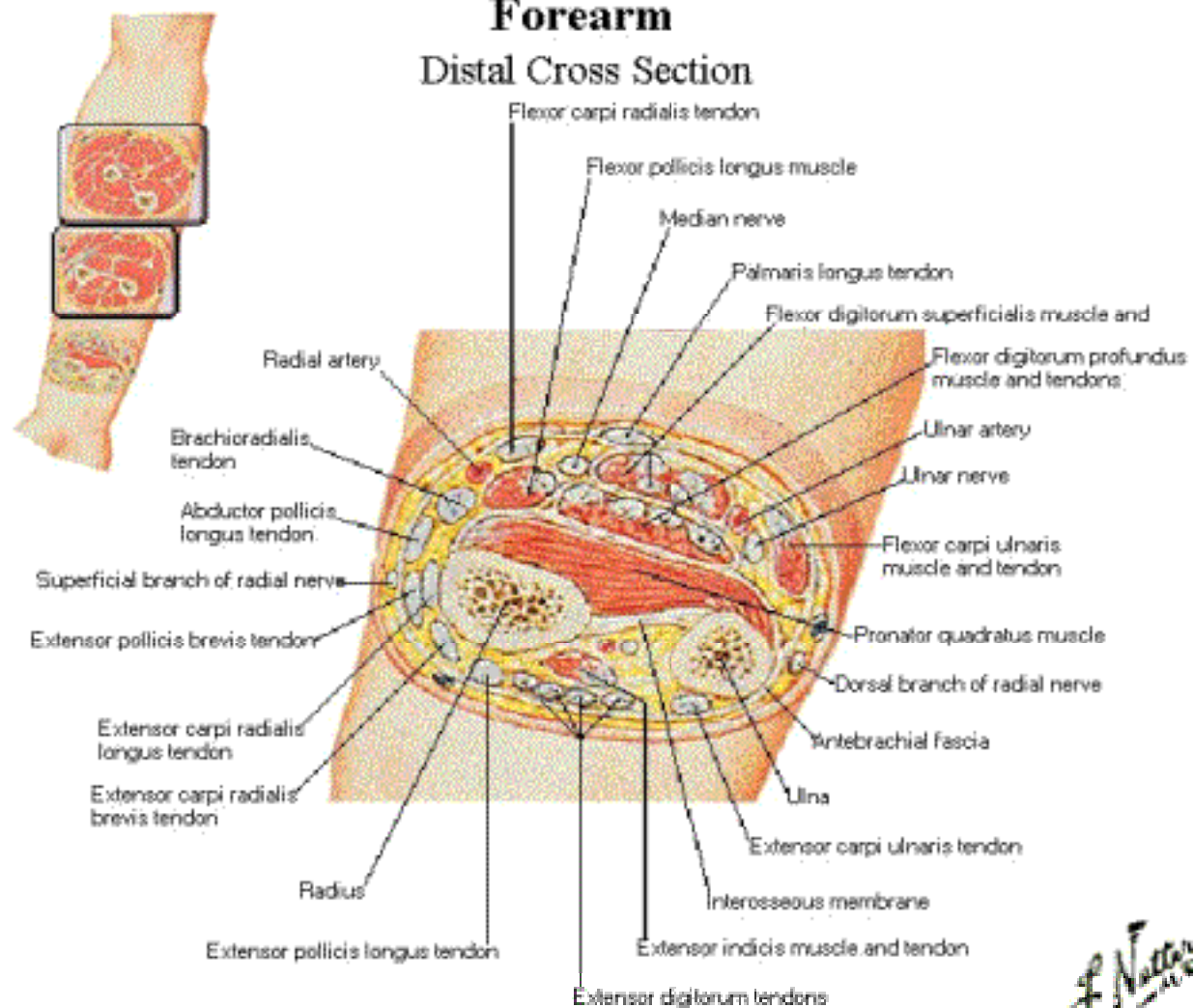
Middle Cross Section



F. Netter M.D.
© 2005 Novartis

Forearm

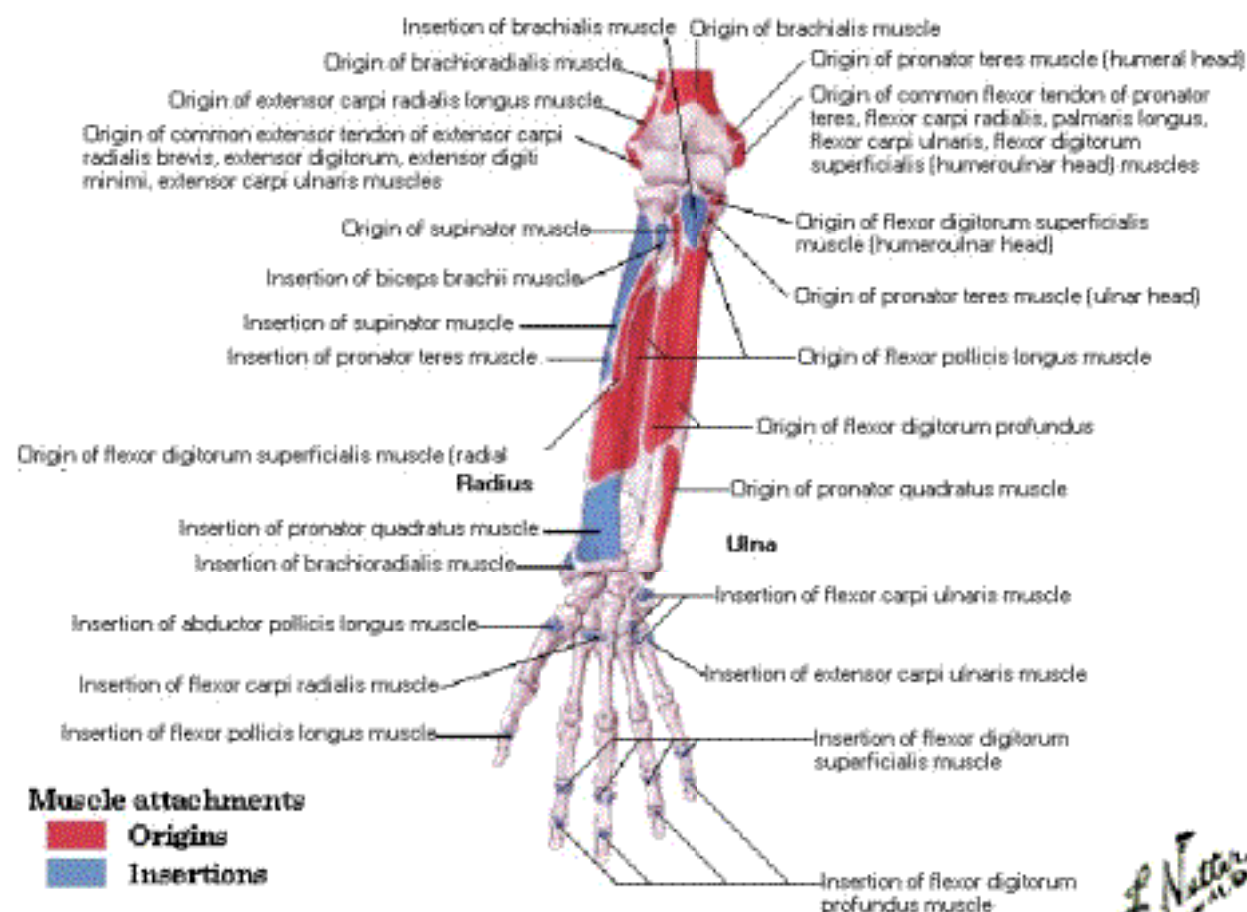
Distal Cross Section



A. Nasser

Bony Attachments of Muscles of Forearm

Anterior View



Muscle attachments

- Origins
- Insertions

Note: attachments of intrinsic muscles of hand not shown

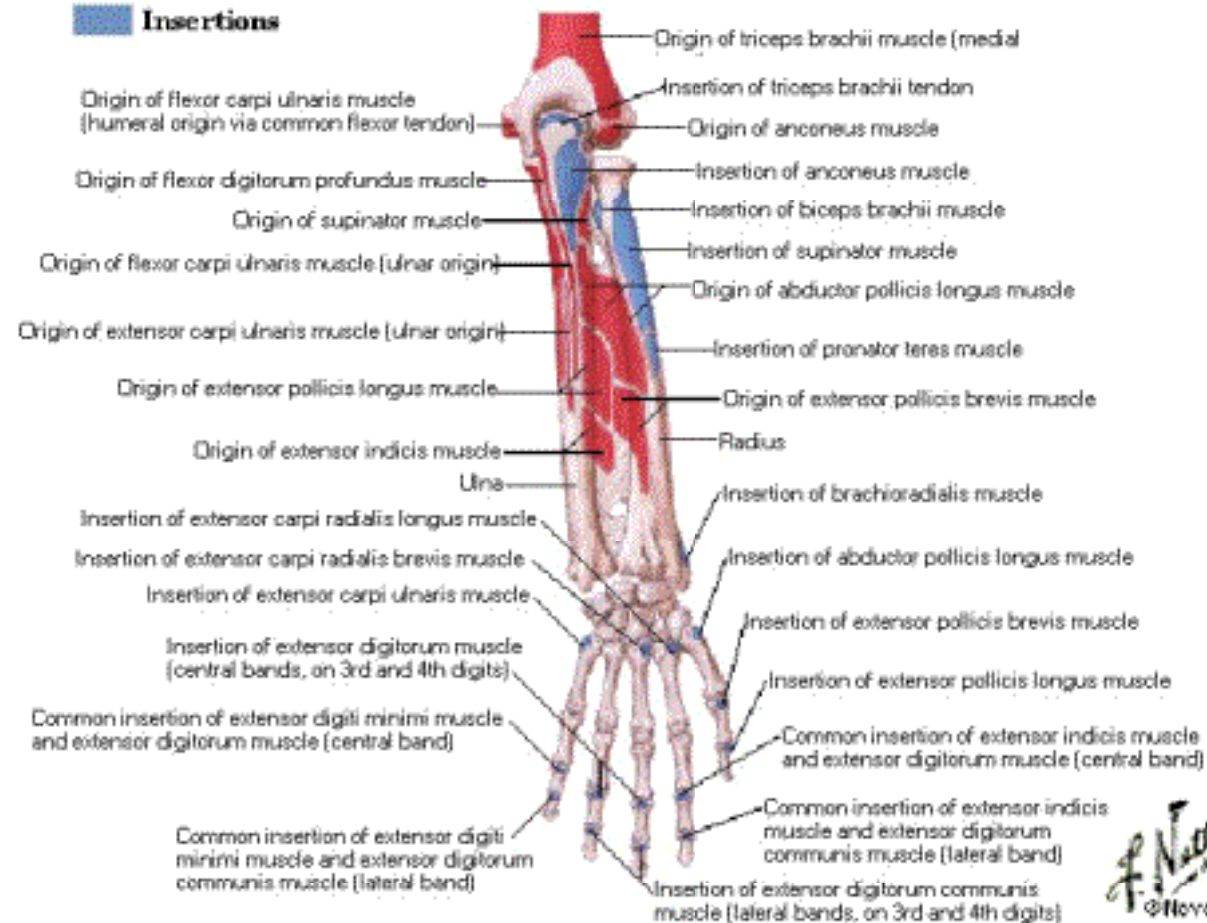
F. Netter M.D.
© Novartis

Bony Attachments of Muscles of Forearm

Muscle attachments

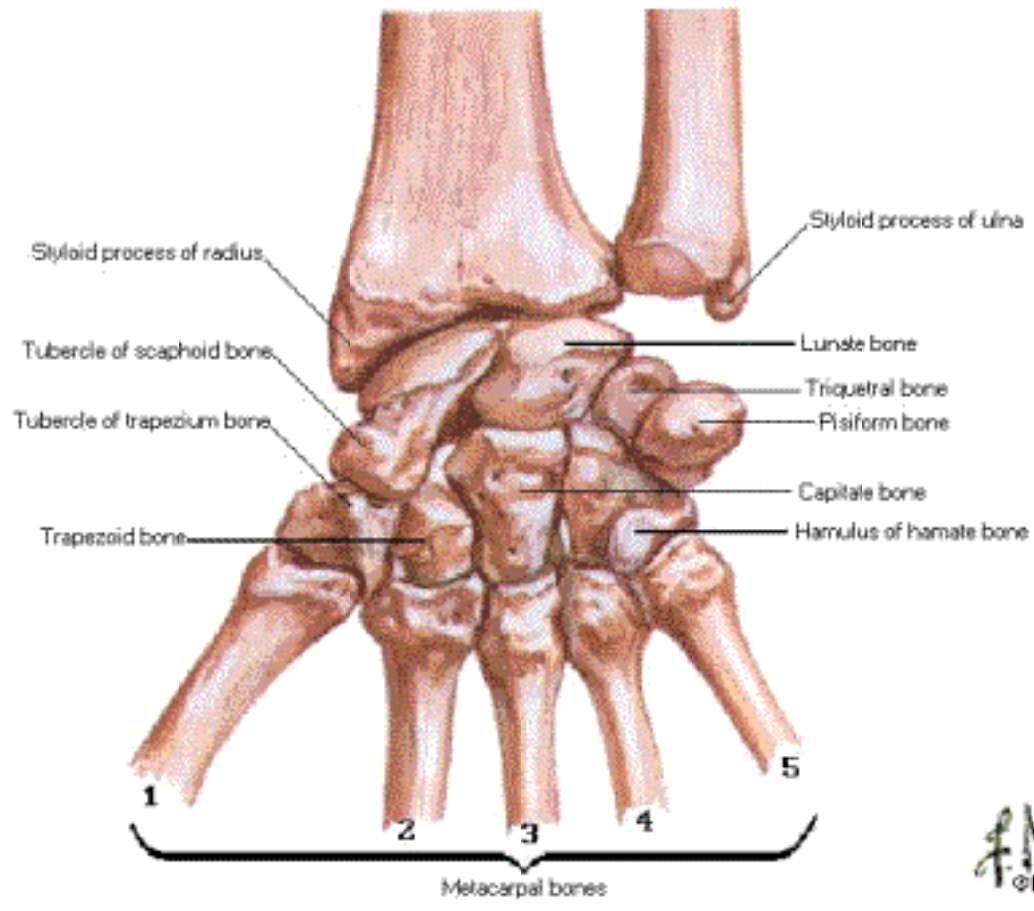
- **Origins**
- **Insertions**

Posterior View



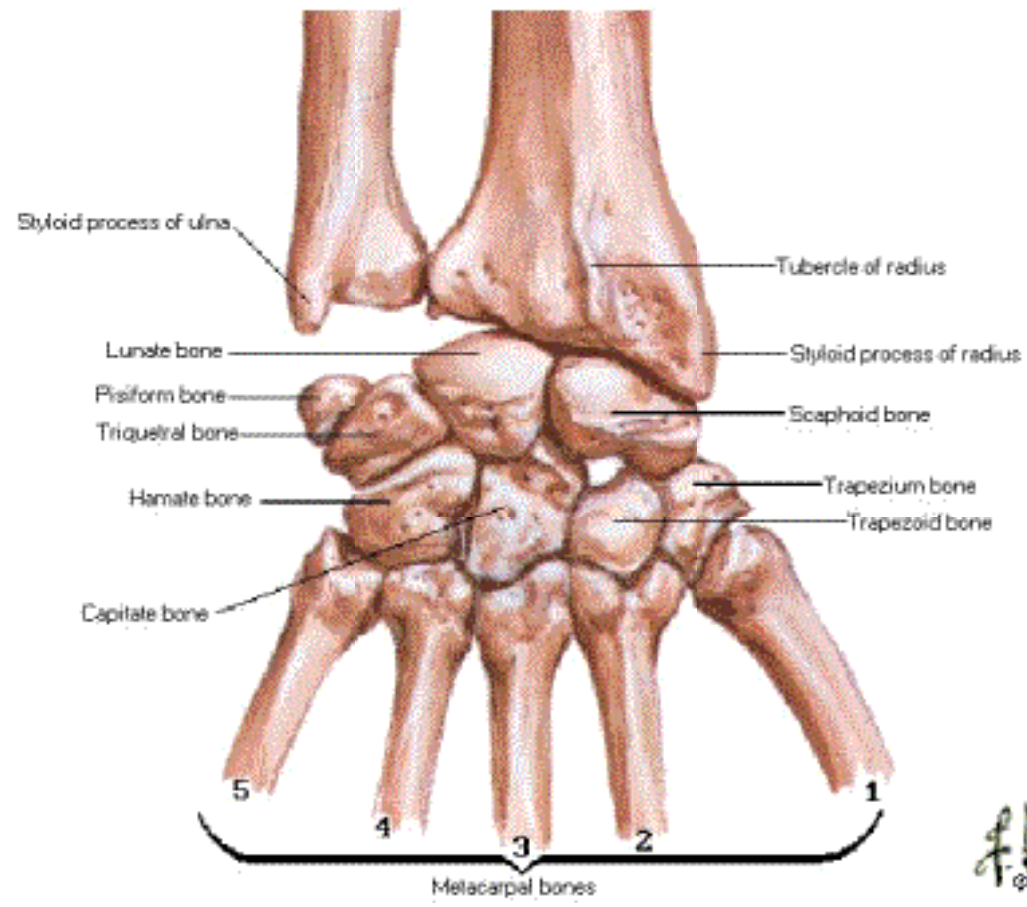
Carpal Bones

Anterior [Palmar] View



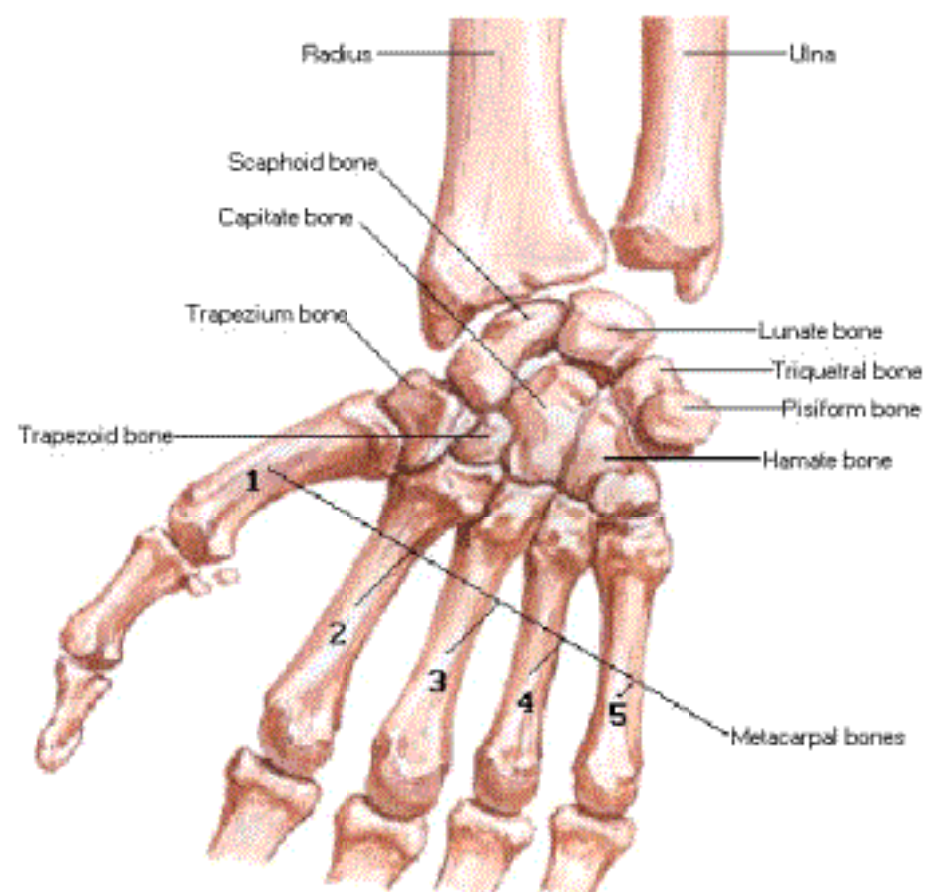
Carpal Bones

Posterior [Dorsal] View



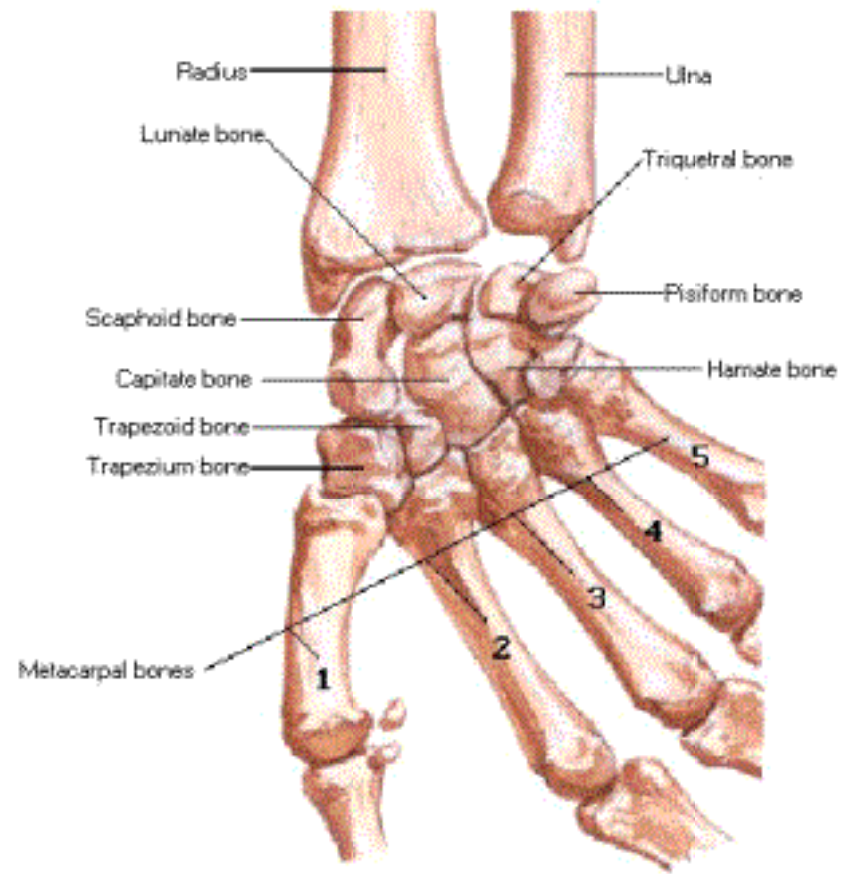
Movements of Wrist

Hand in Abduction - Anterior [Palmar] View



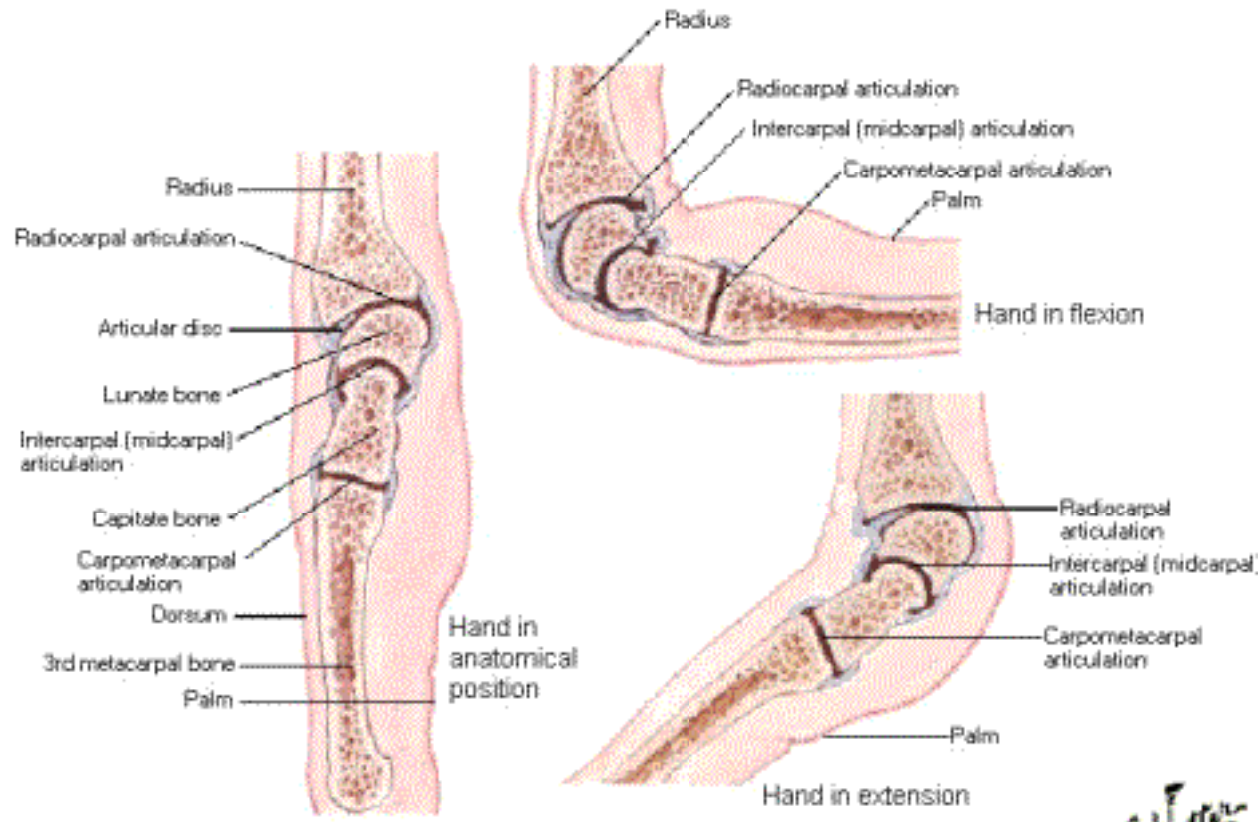
Movements of Wrist

Hand in Adduction - Anterior [Palmar] View



Movements of Wrist

Sagittal Sections

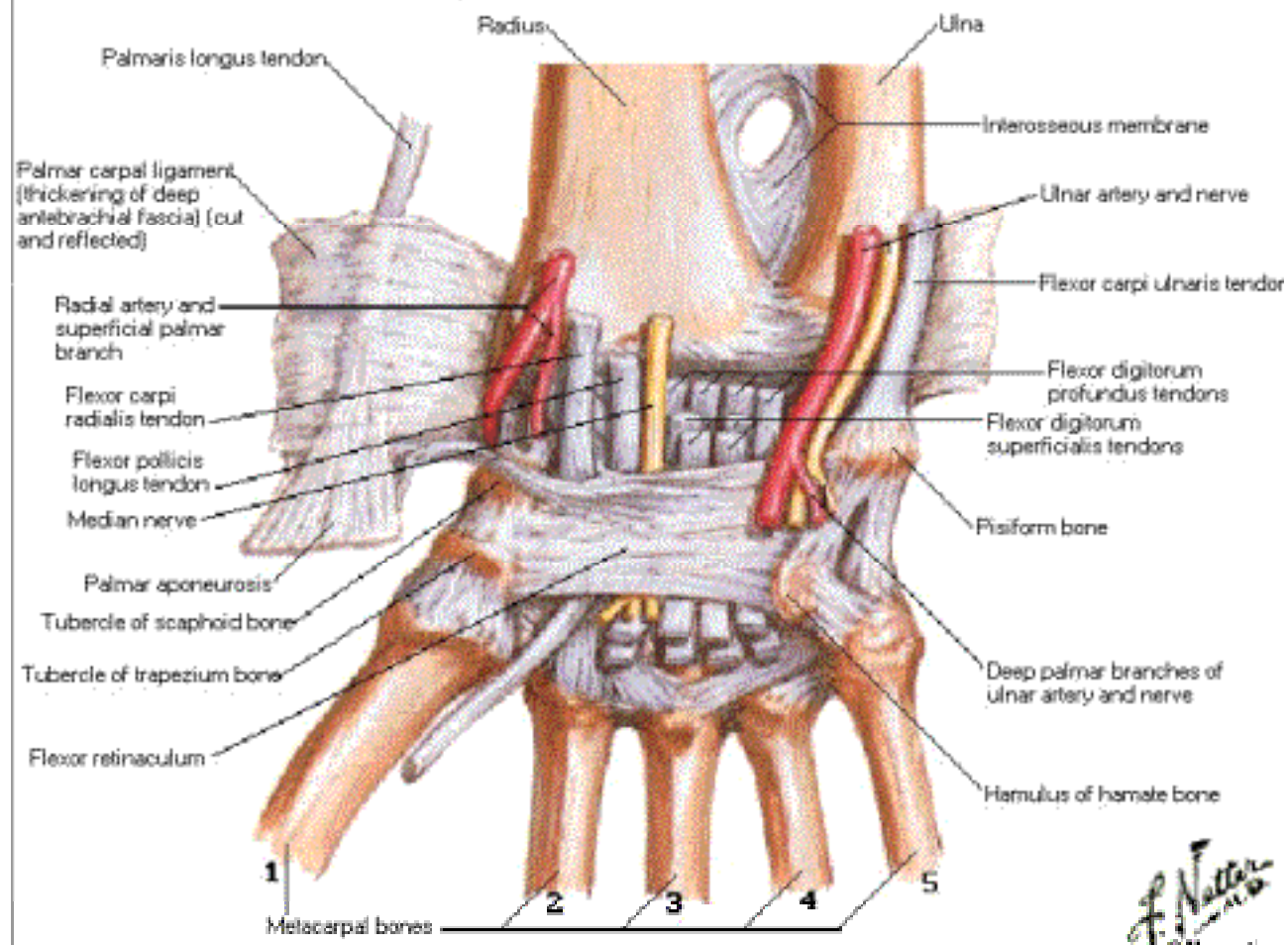


Sagittal sections through wrist and middle finger

F. Netter M.D.
© Novartis

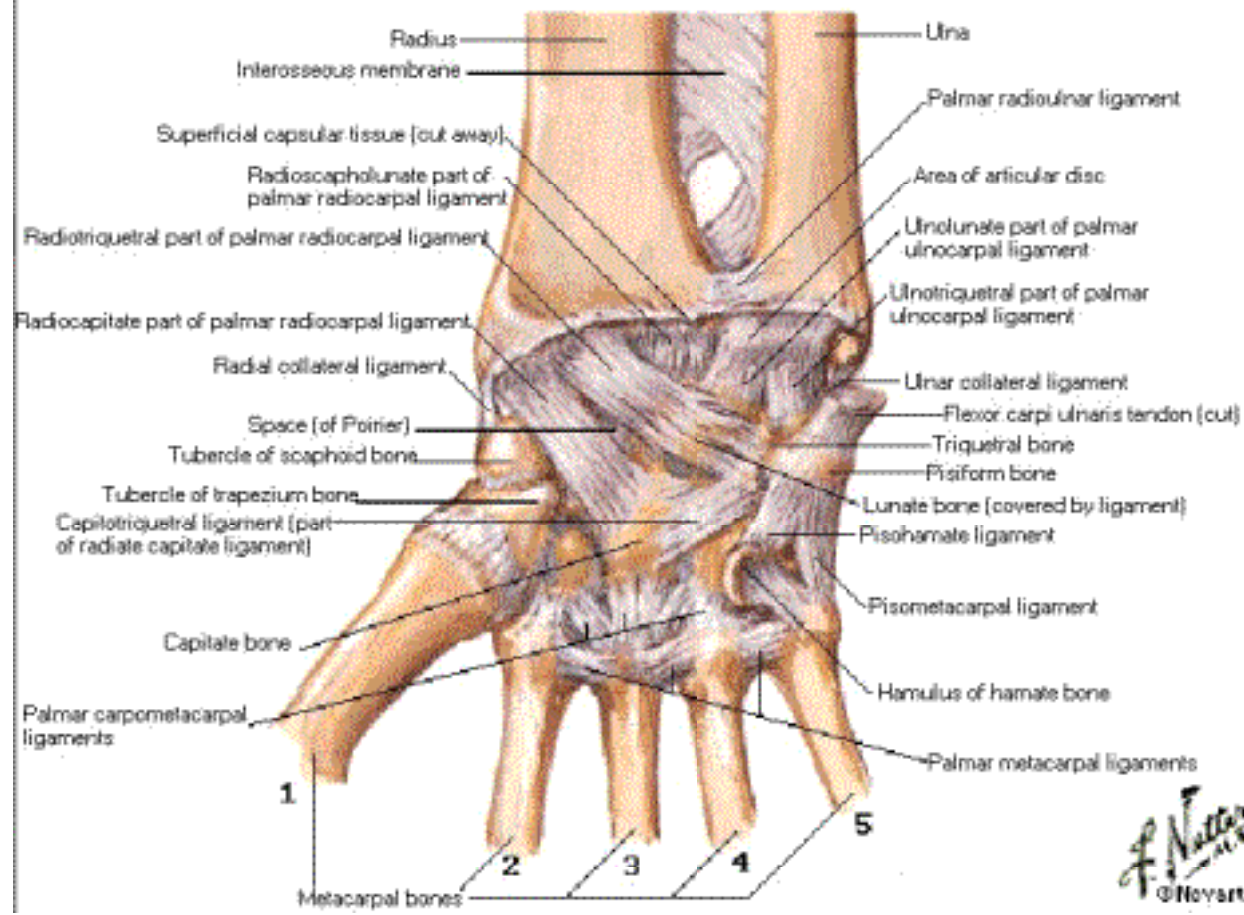
Ligaments of Wrist

Carpal Tunnel - Palmar View

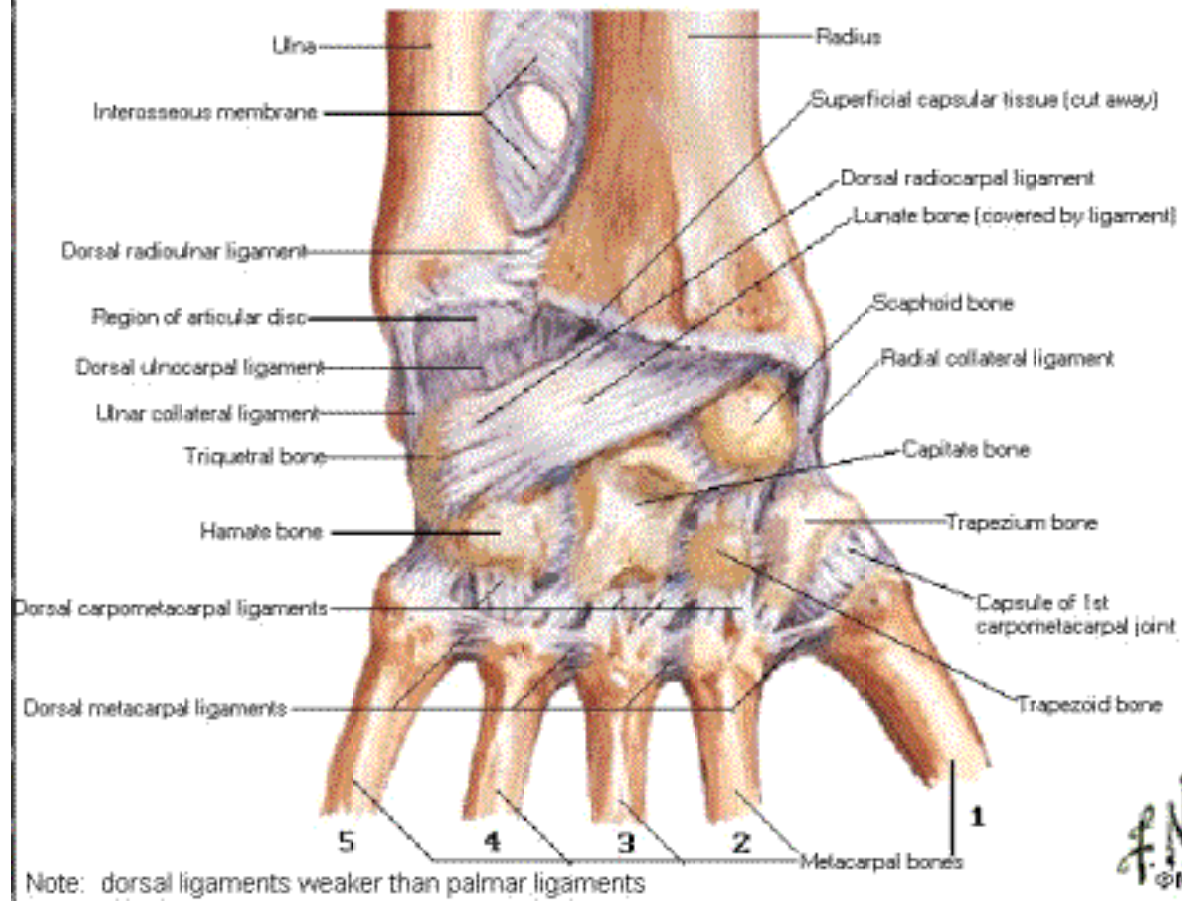


Ligaments of Wrist

Flexor Retinaculum Removed - Palmar View

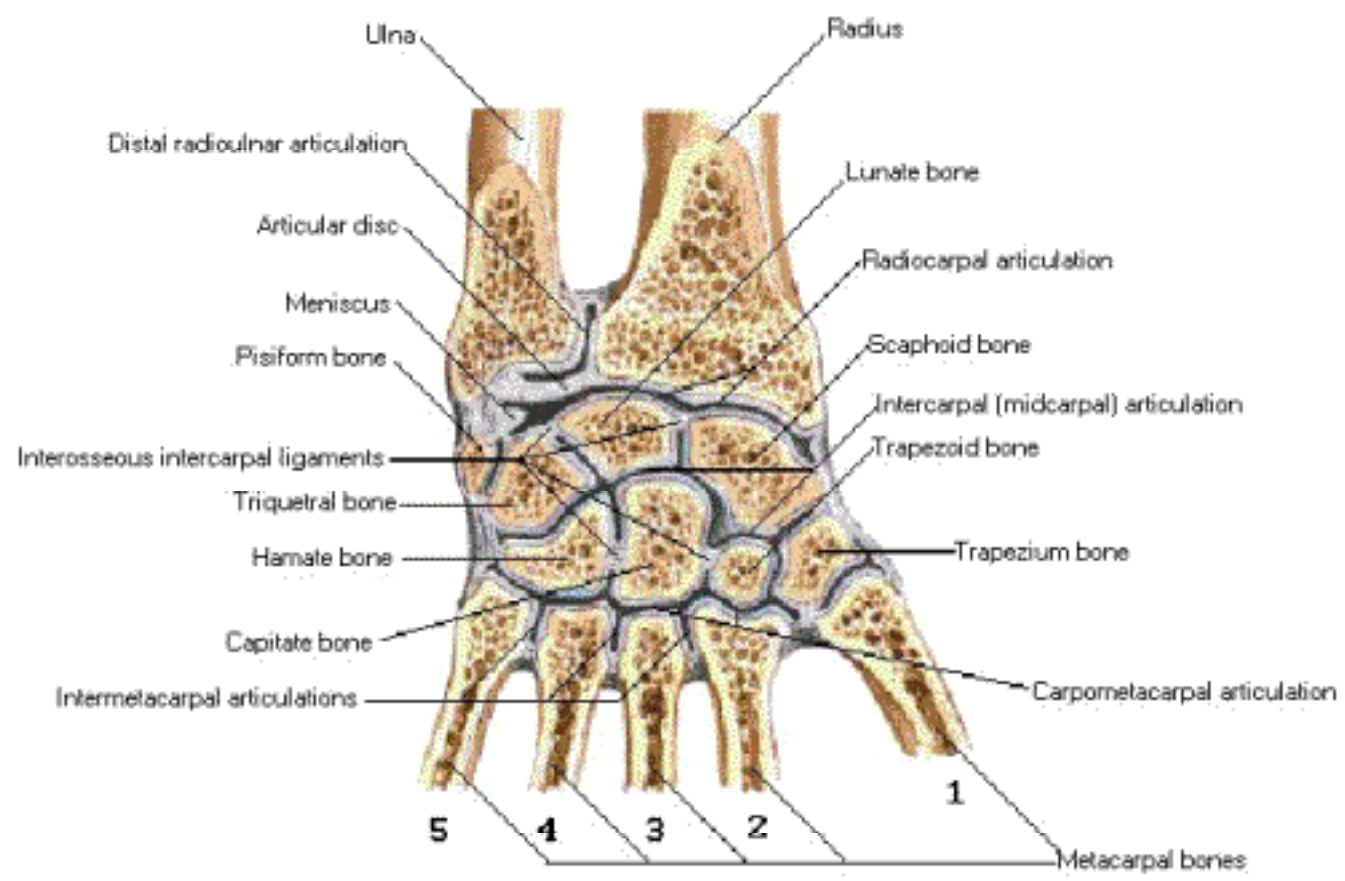


Ligaments of Wrist Posterior [Dorsal] View



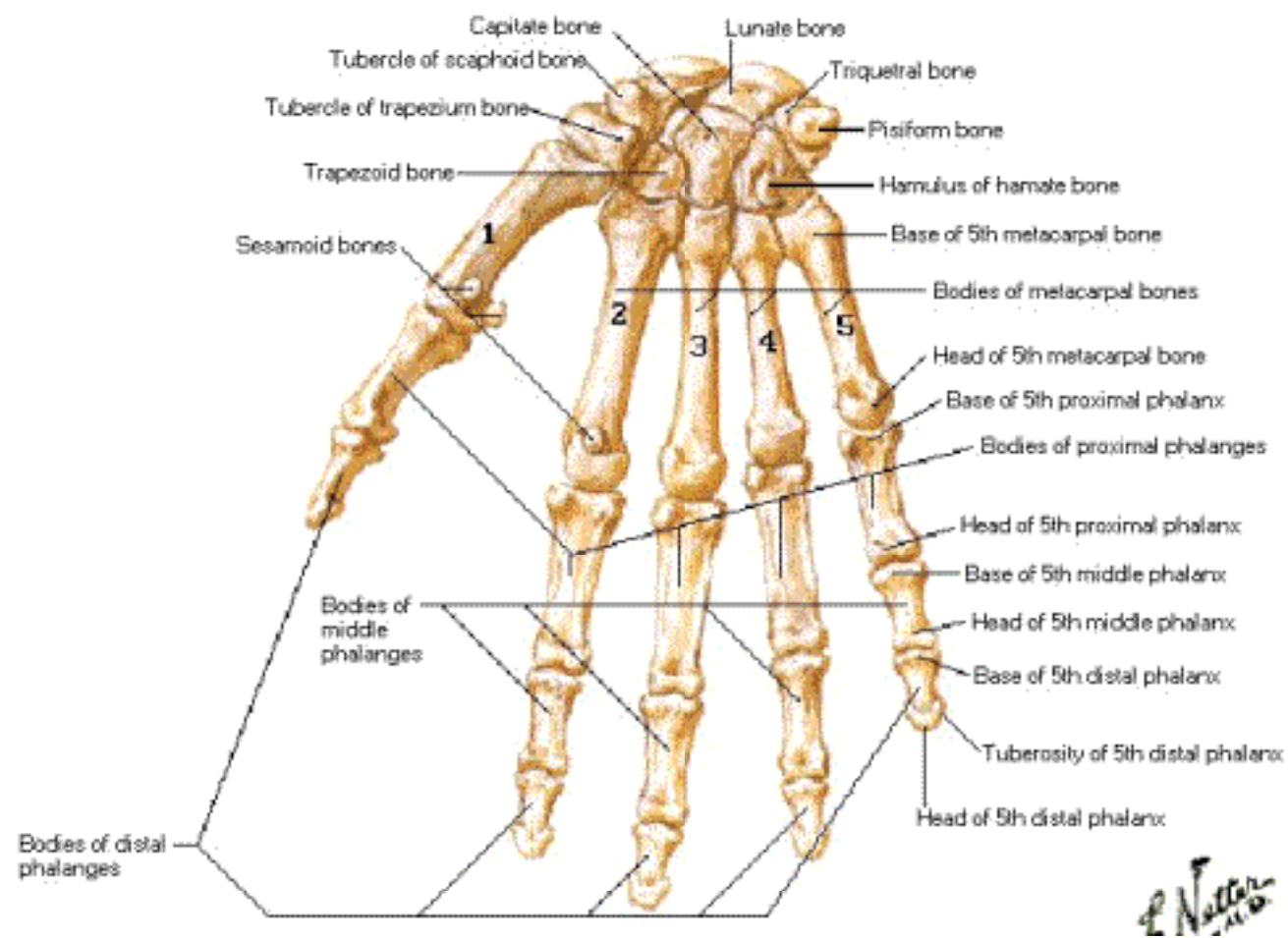
Ligaments of Wrist

Coronal Section - Dorsal View



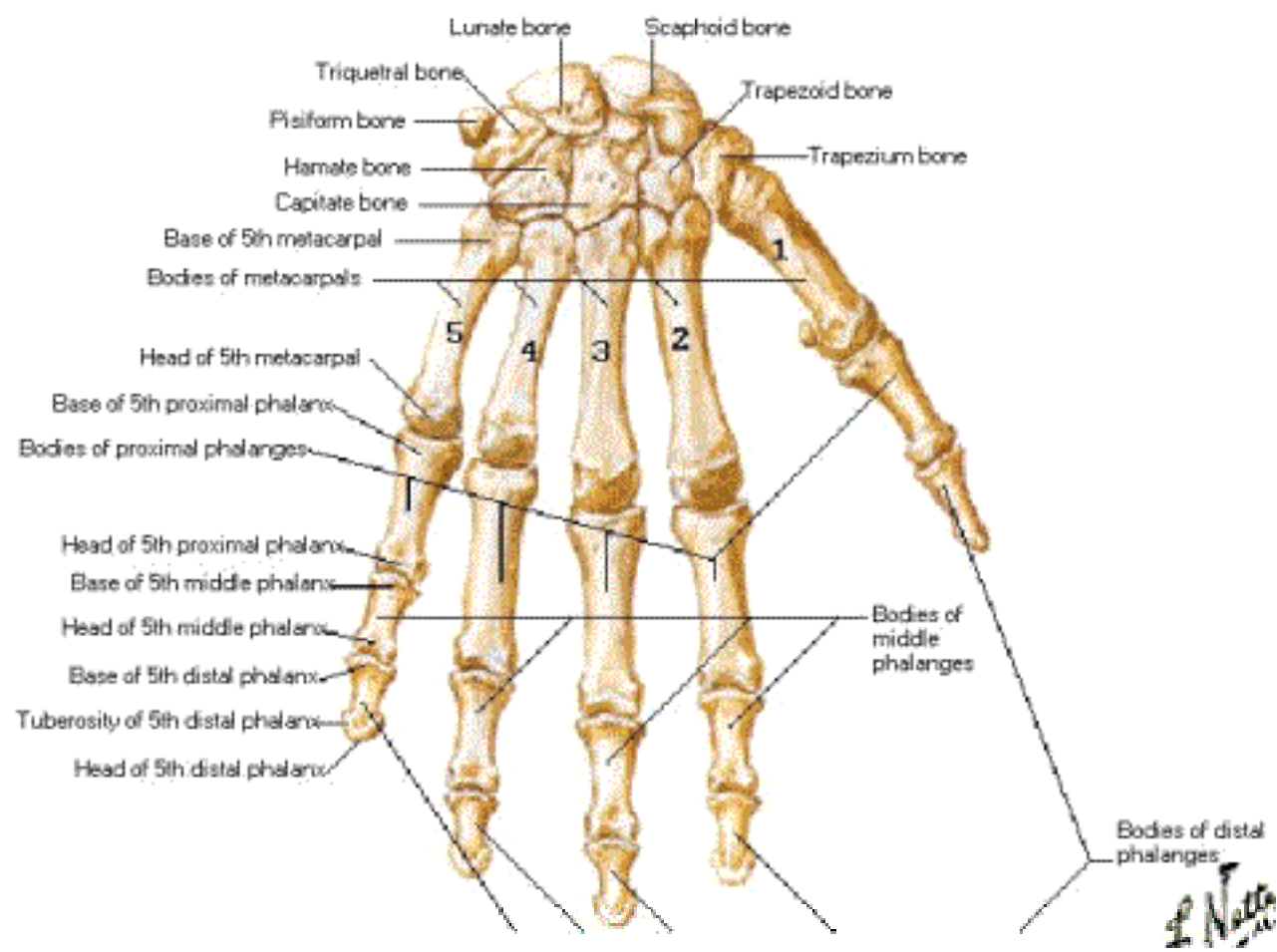
Bones of Right Wrist and Hand

Anterior [Palmar] View



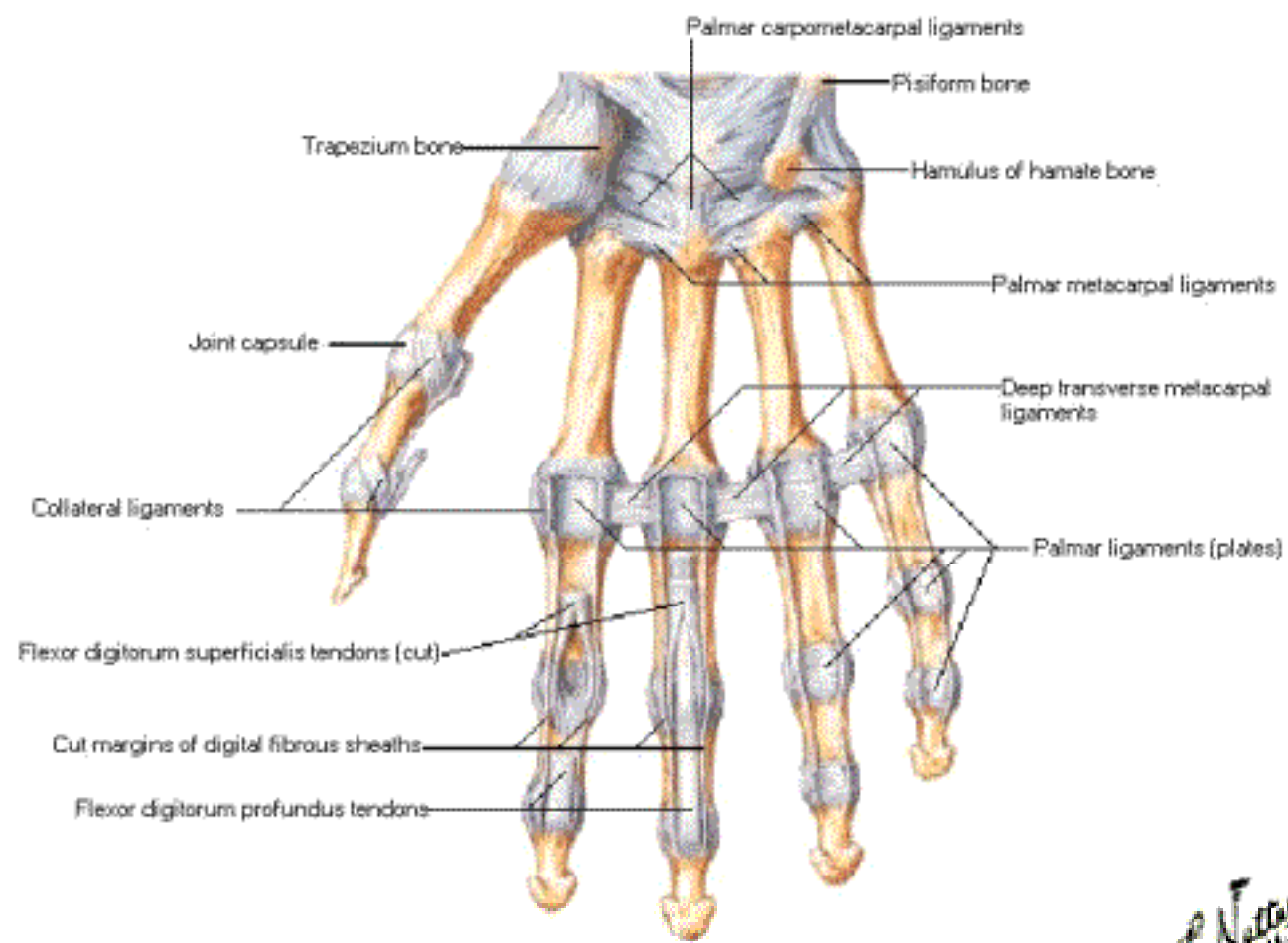
Bones of Right Wrist and Hand

Posterior [Dorsal] View



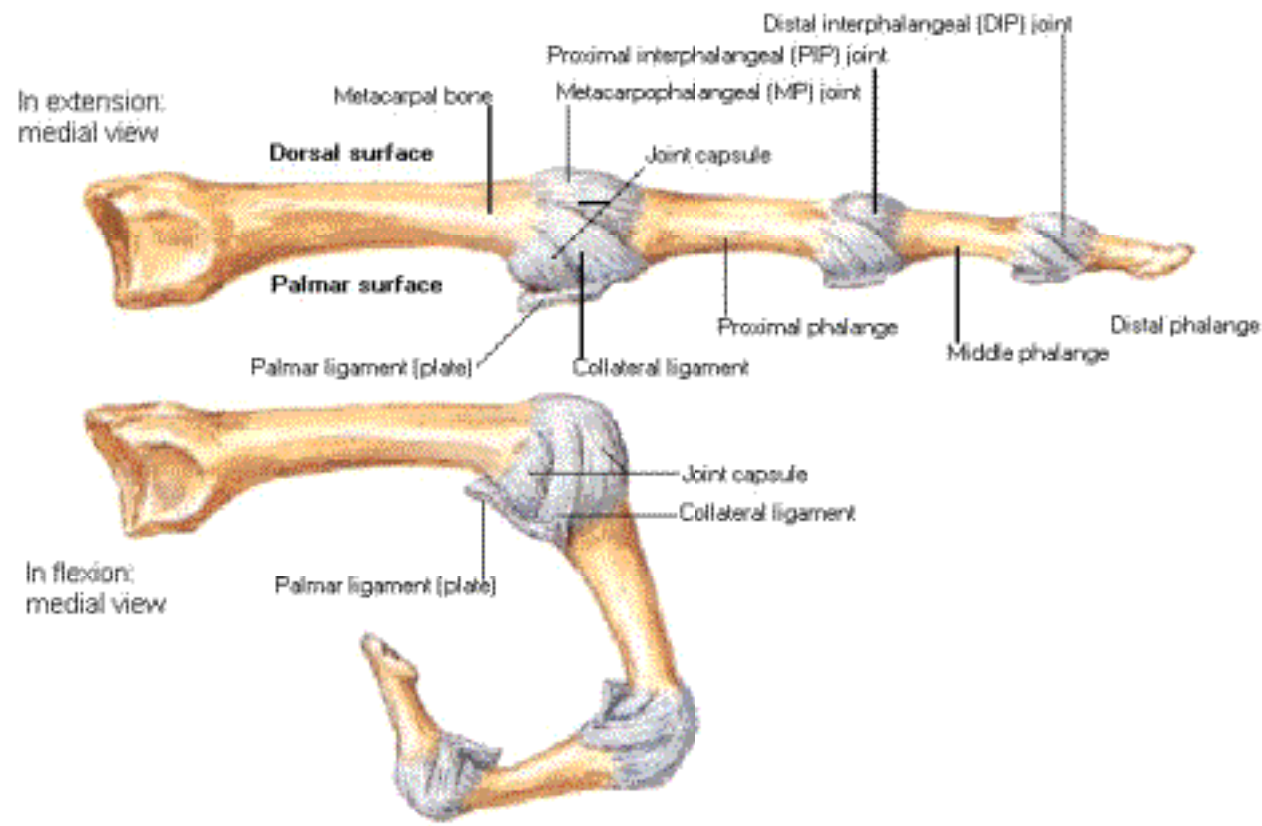
Metacarpophalangeal and Interphalangeal Ligaments

Palmar View



Metacarpophalangeal and Interphalangeal Ligaments

Medial Views

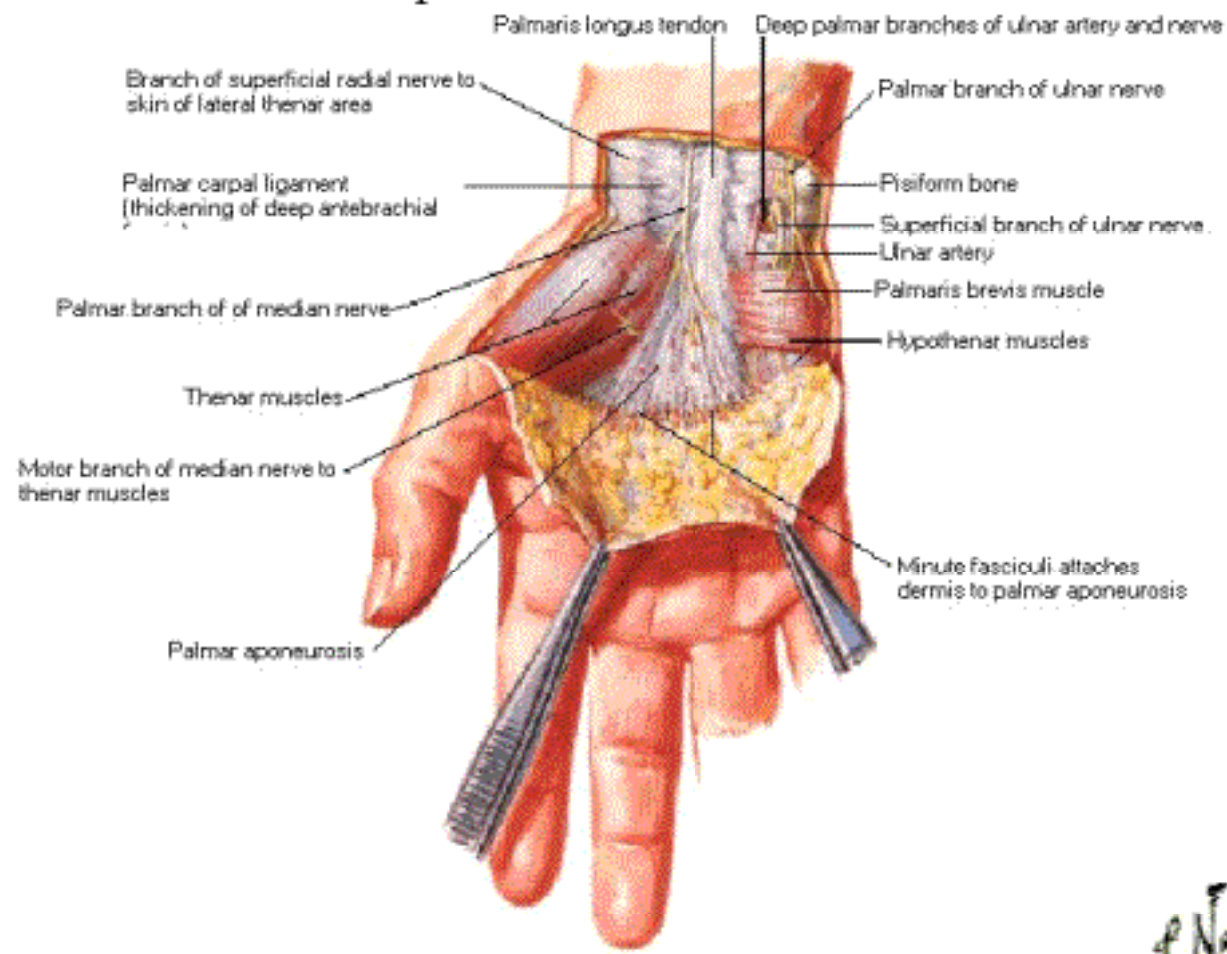


Note: ligaments of metacarpophalangeal and interphalangeal joints are similar

F. Netter M.D.

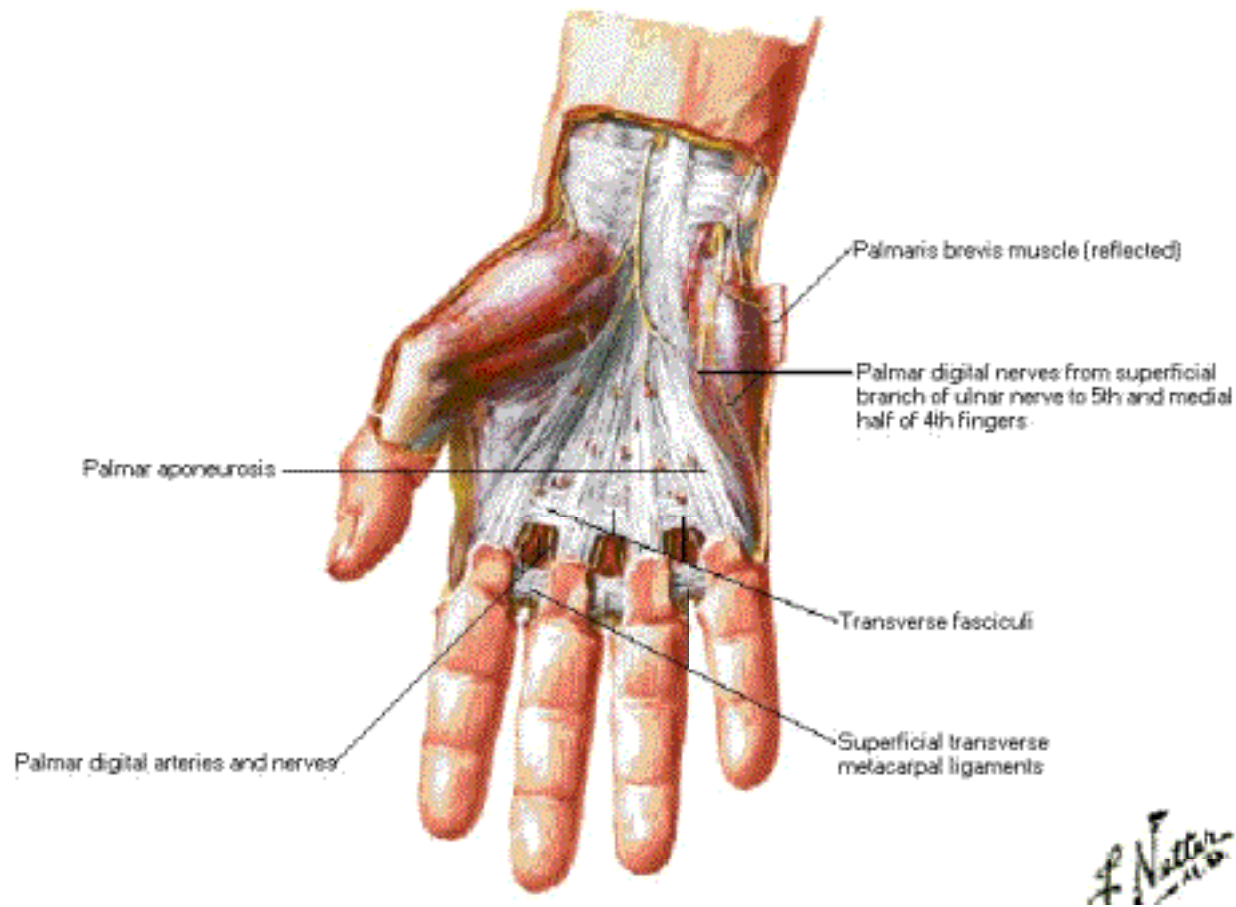
Wrist and Hand

Superficial Palmar Dissections



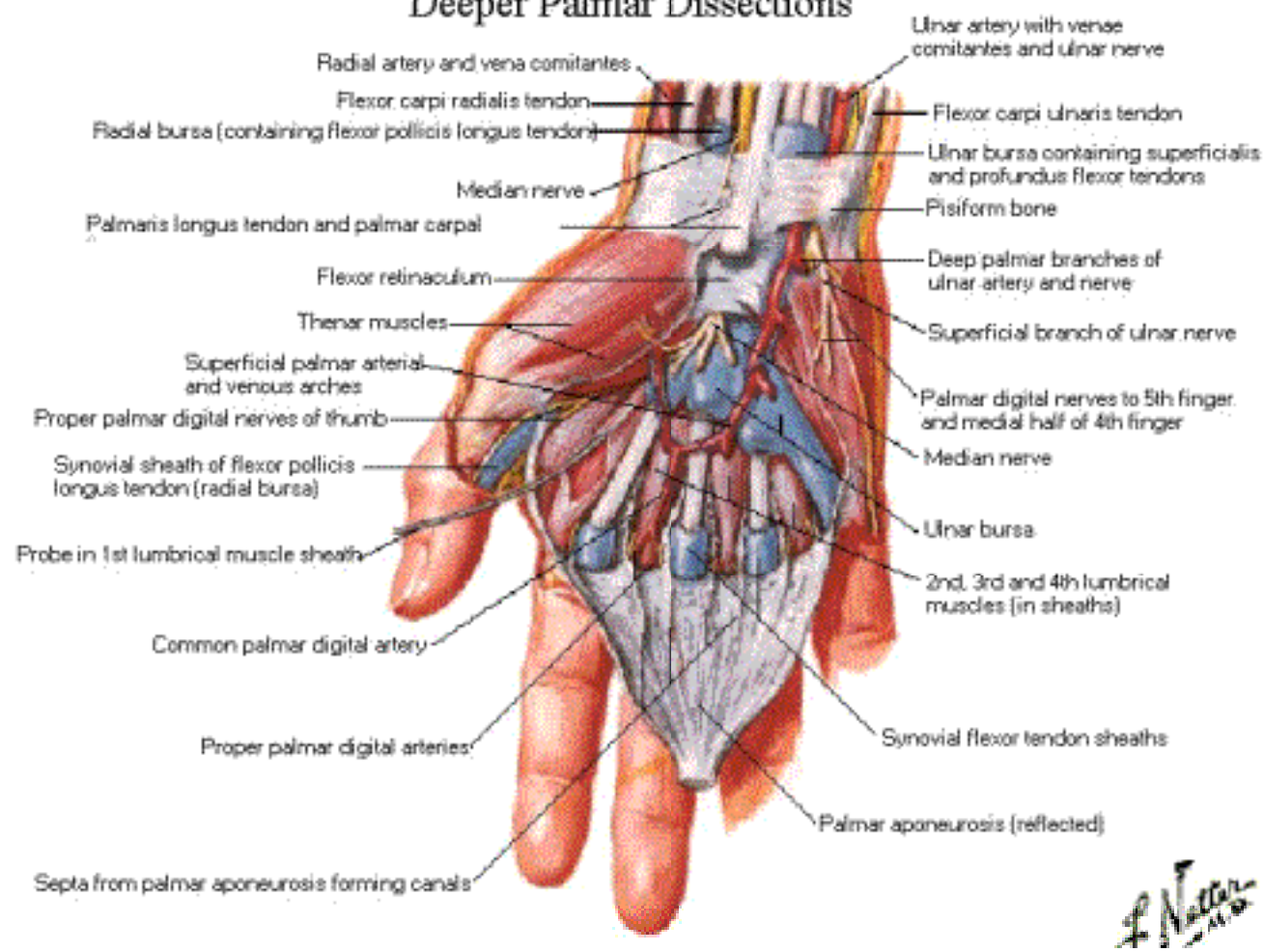
Wrist and Hand

Superficial Palmar Dissections [Continued]



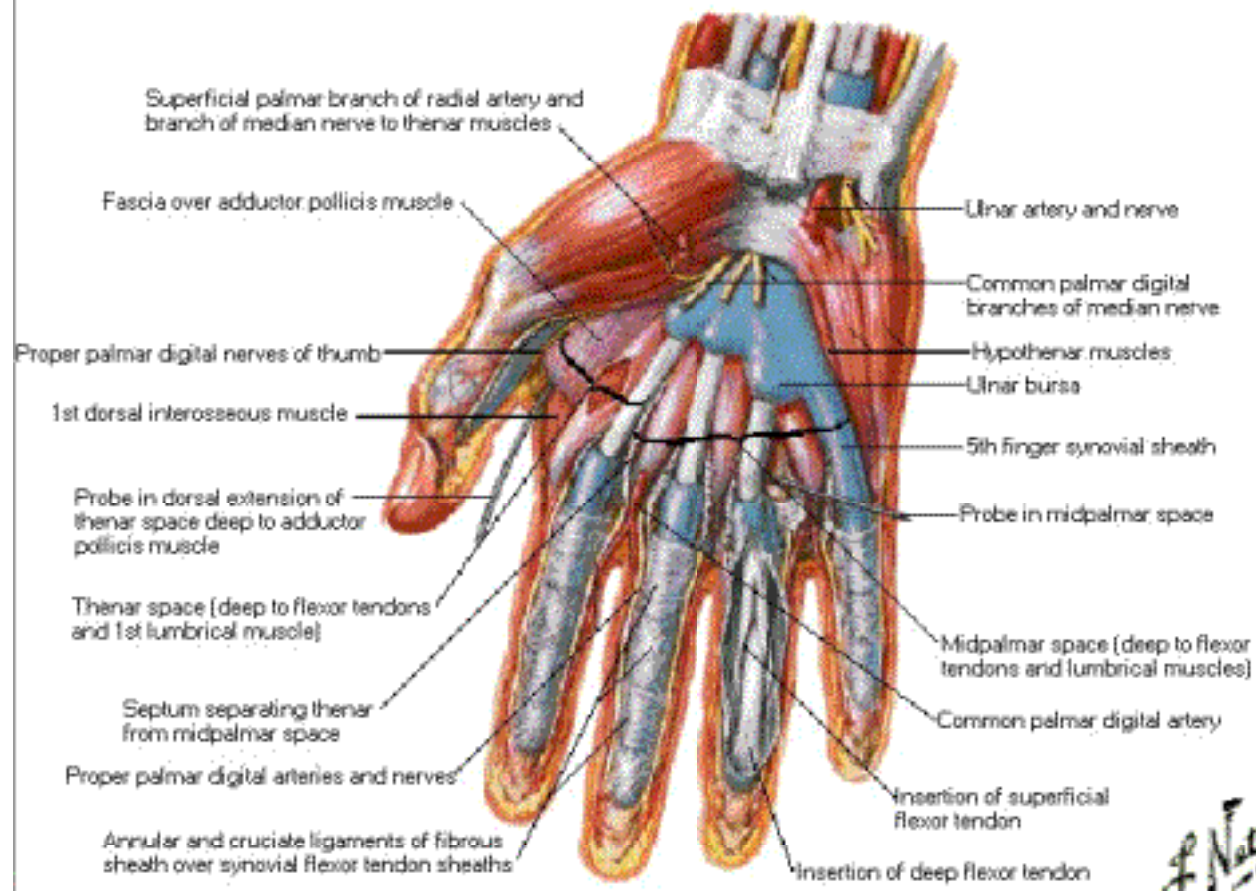
Wrist and Hand

Deeper Palmar Dissections



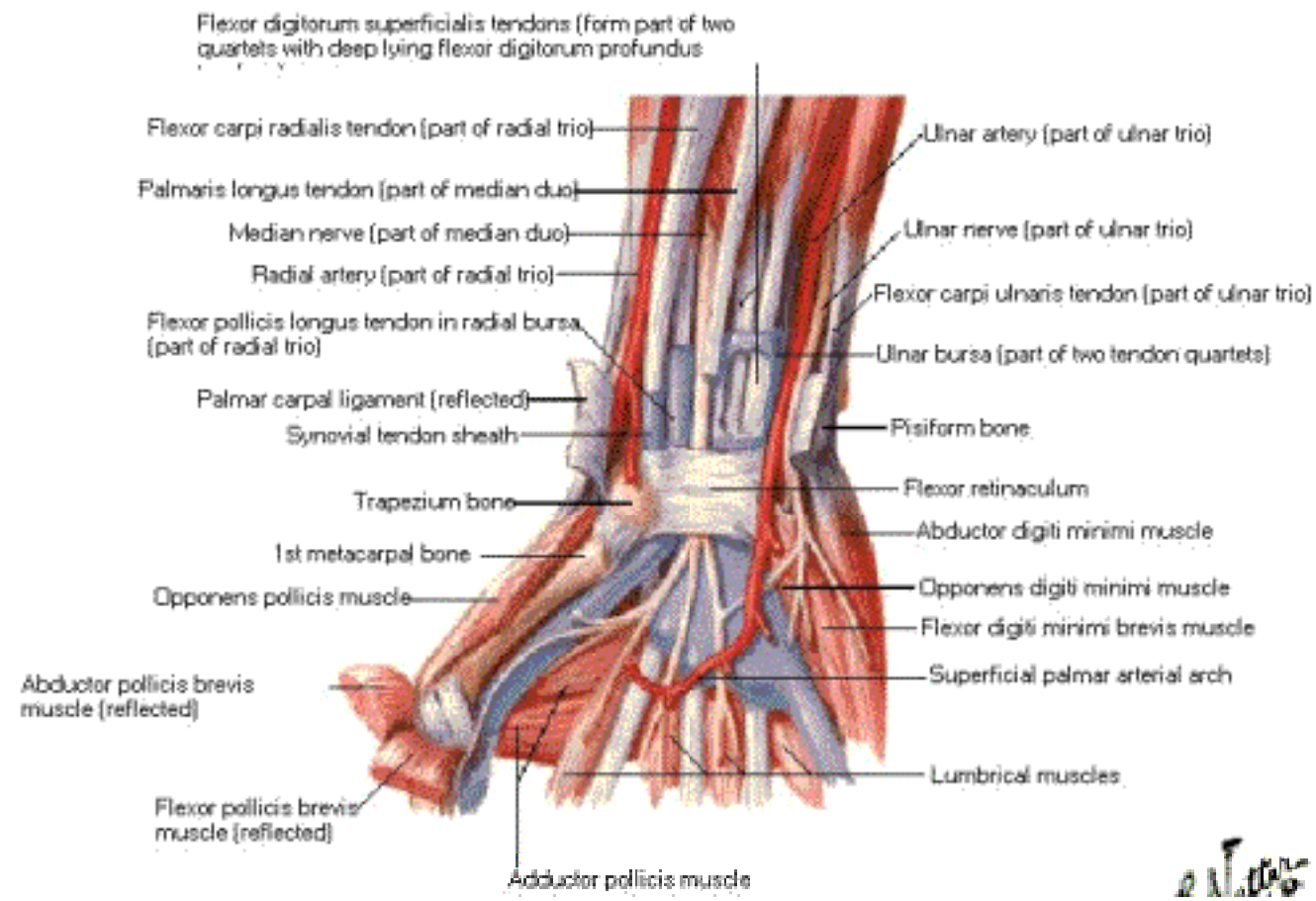
Wrist and Hand

Deeper Palmar Dissections [Continued]



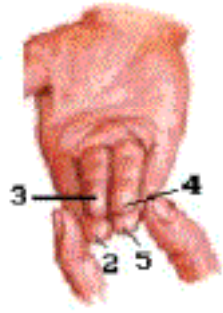
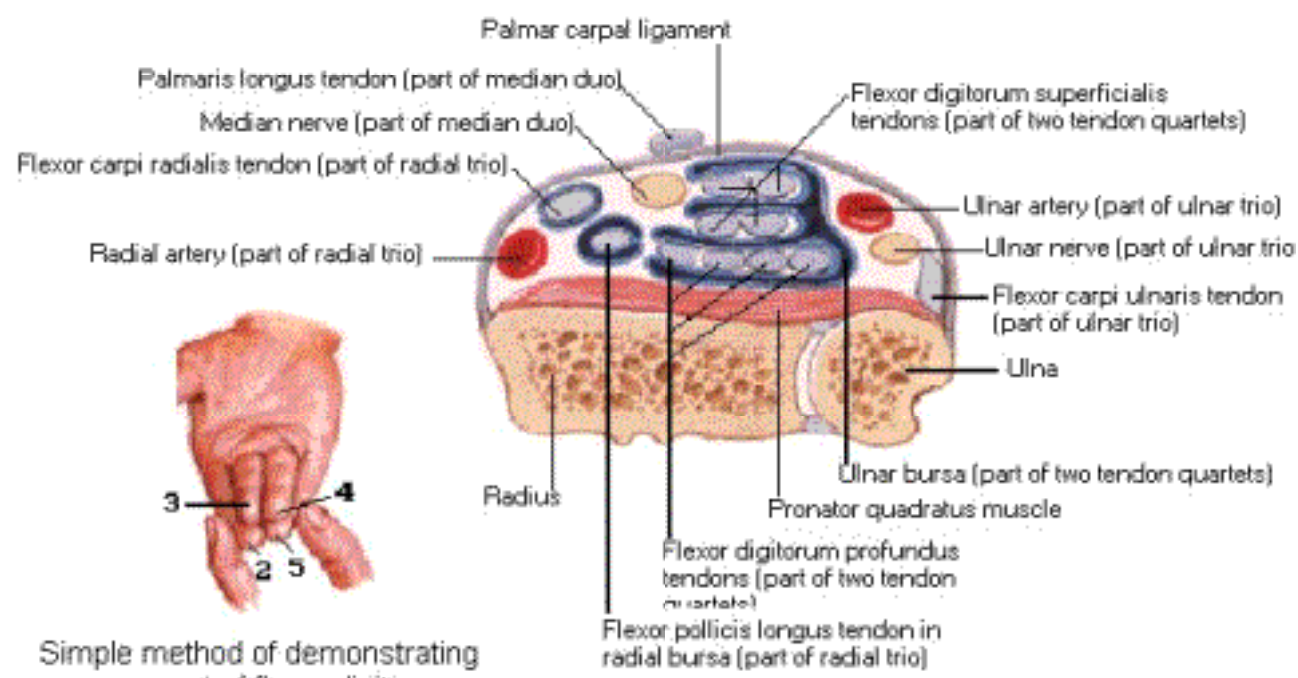
Flexor Tendons, Arteries and Nerves at Wrist

Palmar View



Flexor Tendons, Arteries and Nerves at Wrist

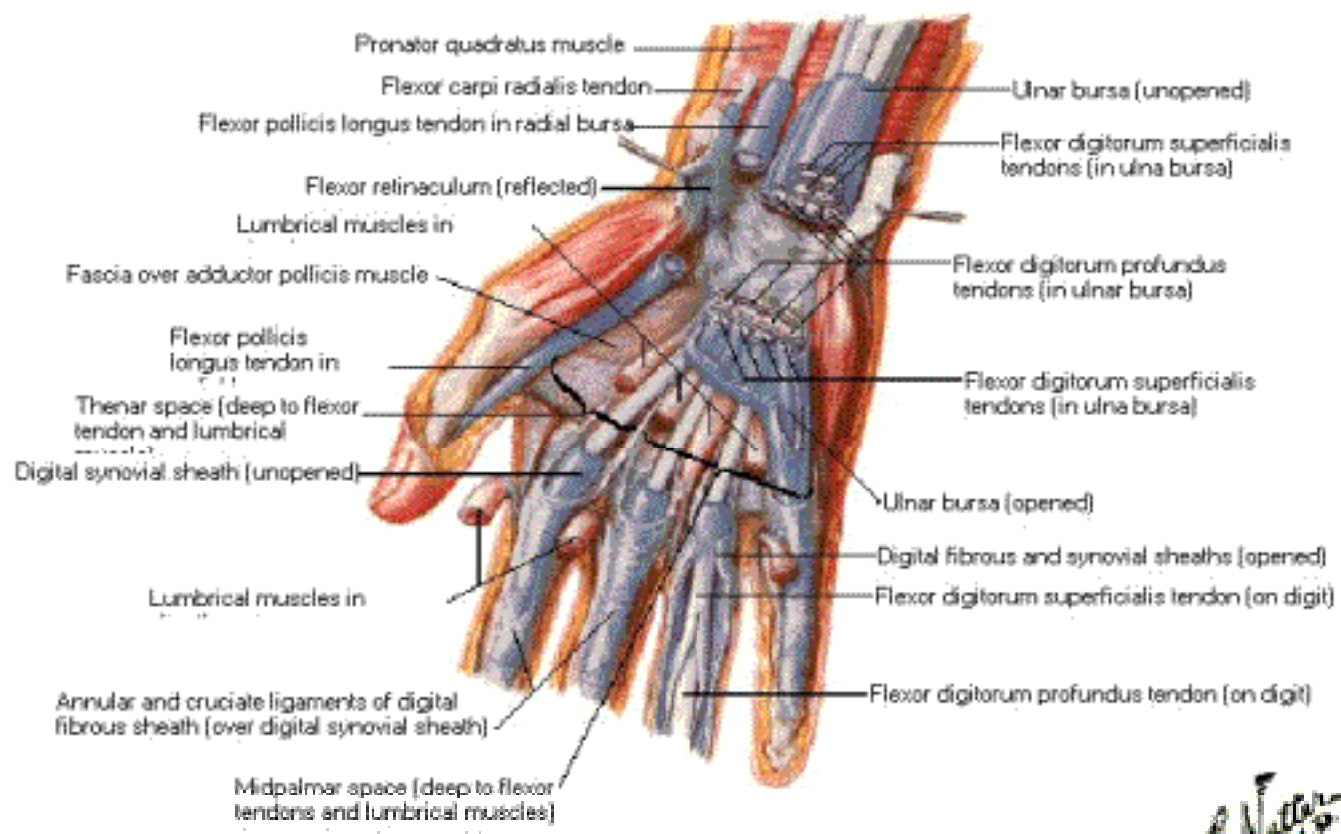
Cross Section



Simple method of demonstrating arrangement of flexor digitorum superficialis tendons at wrist

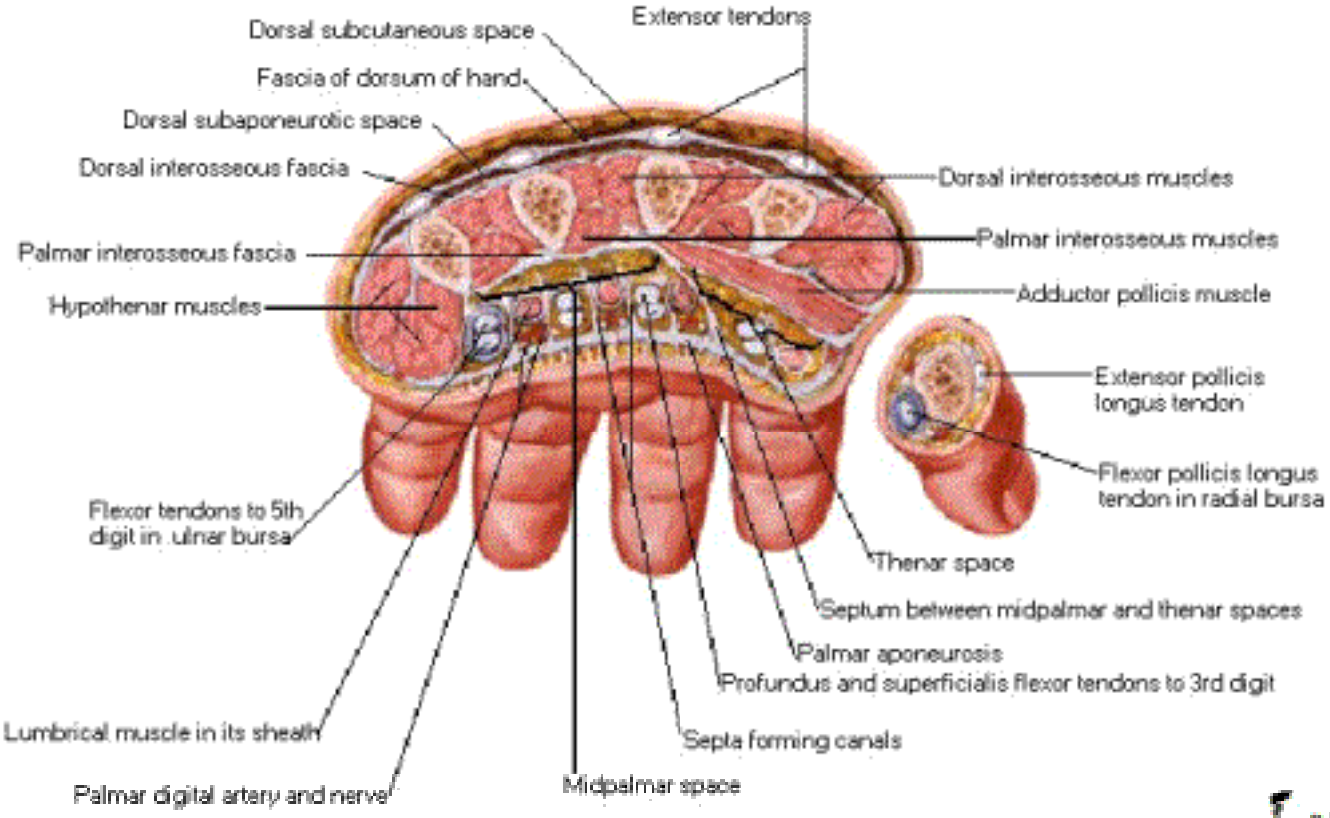
Bursae, Spaces and Tendon Sheaths of Hand

Palmar View

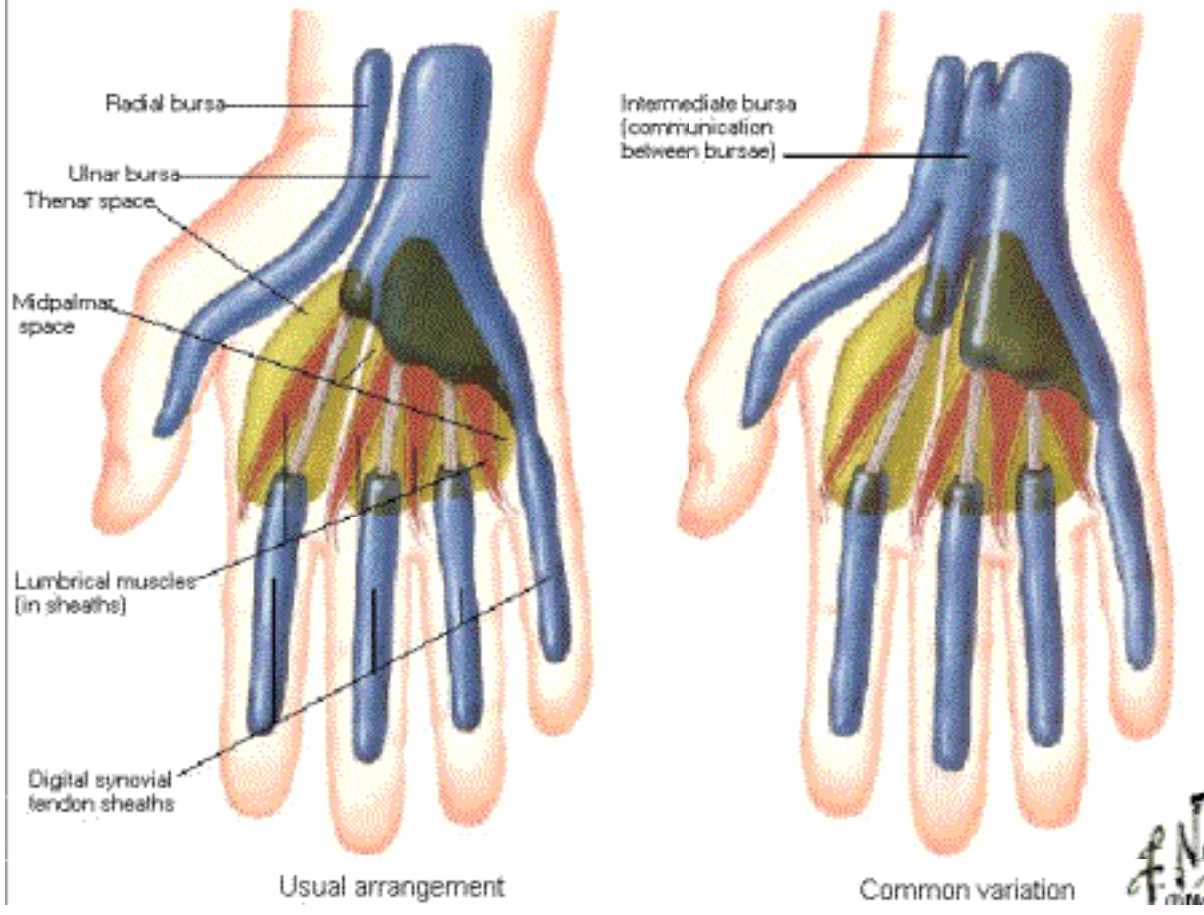


Bursae, Spaces and Tendon Sheaths of Hand

Cross Section

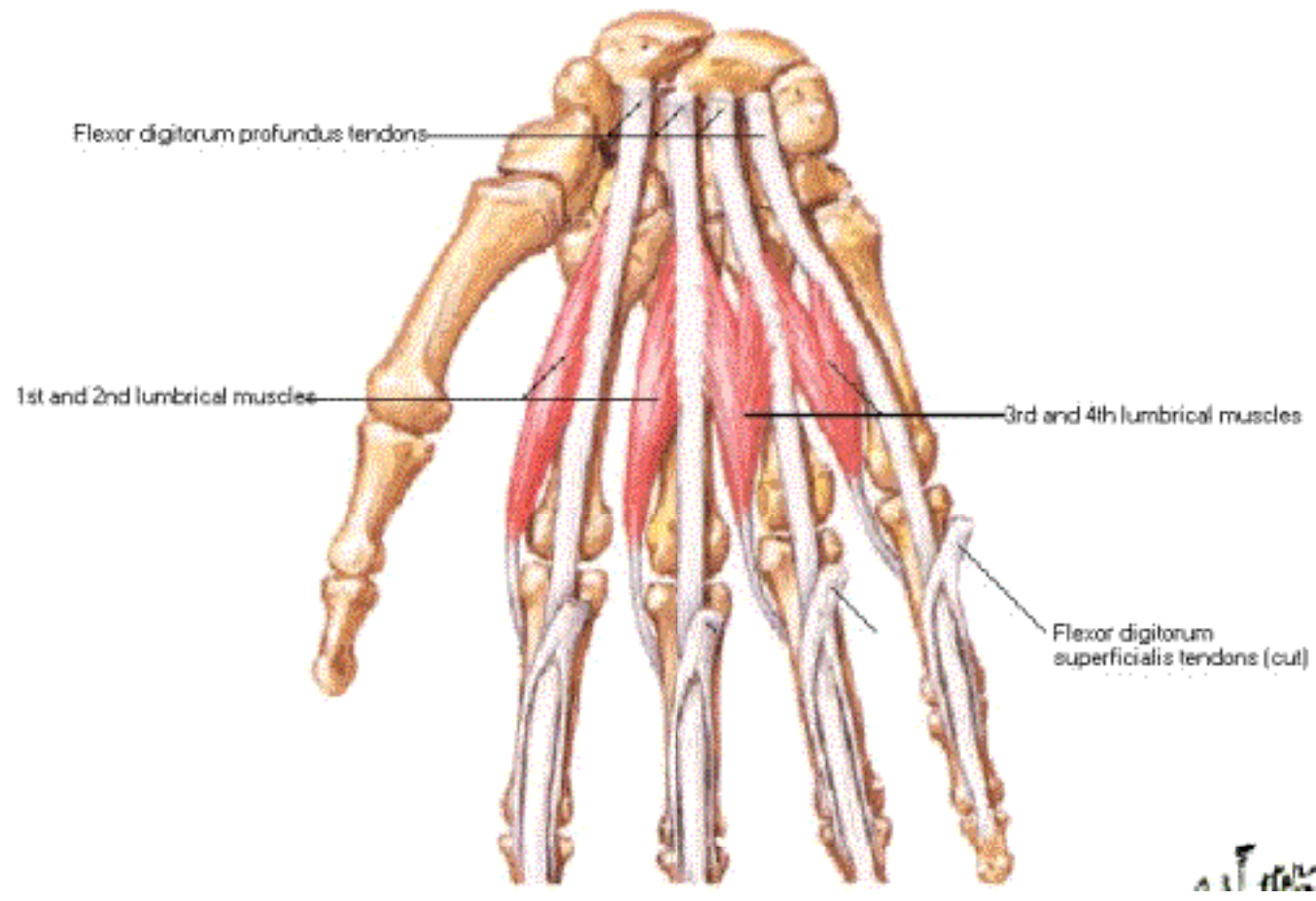


Lumbrical Muscles and Bursae, Spaces and Sheaths Schema



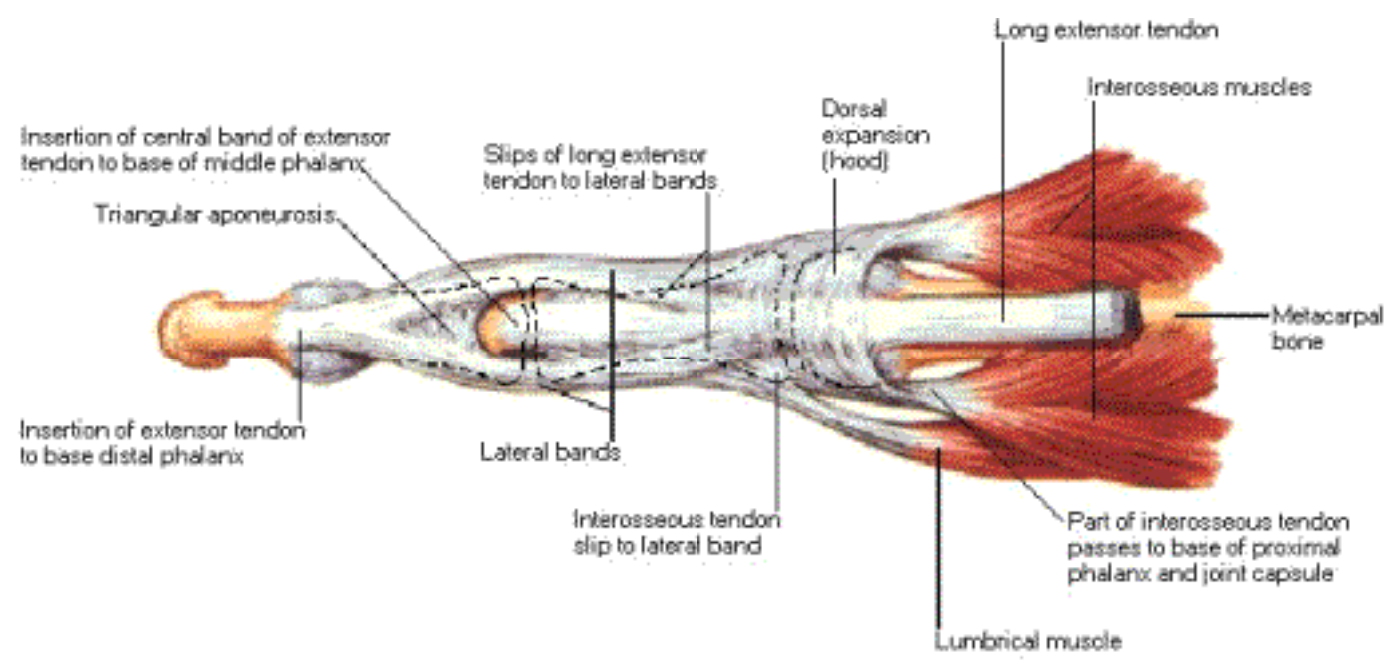
Lumbrical Muscles

Schema



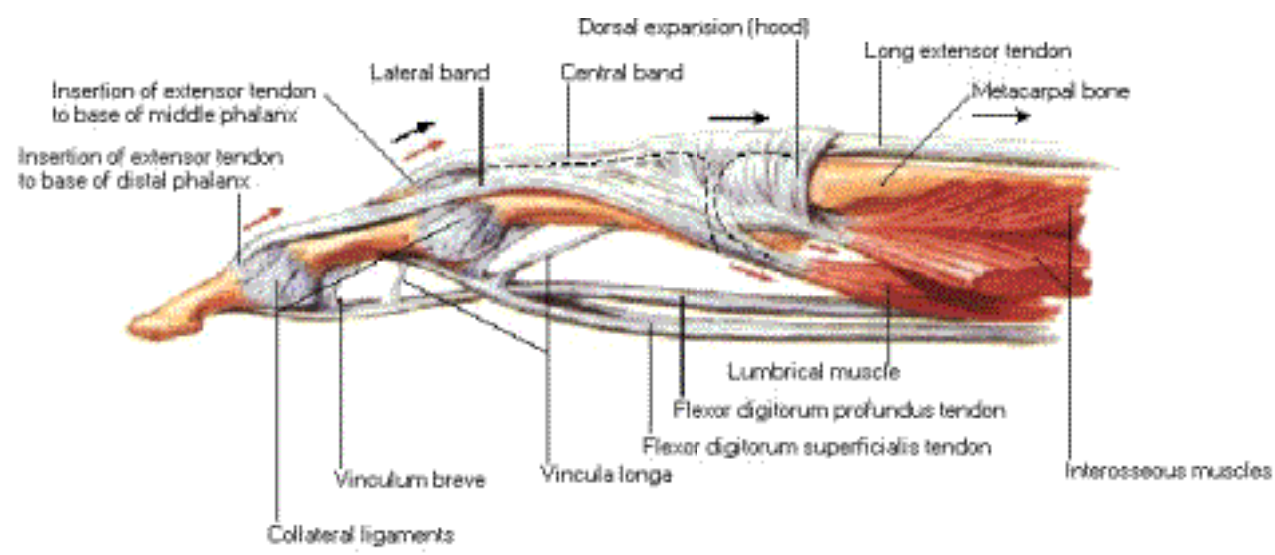
Flexor and Extensor Tendons in Fingers

Posterior [Dorsal] View



Flexor and Extensor Tendons in Fingers

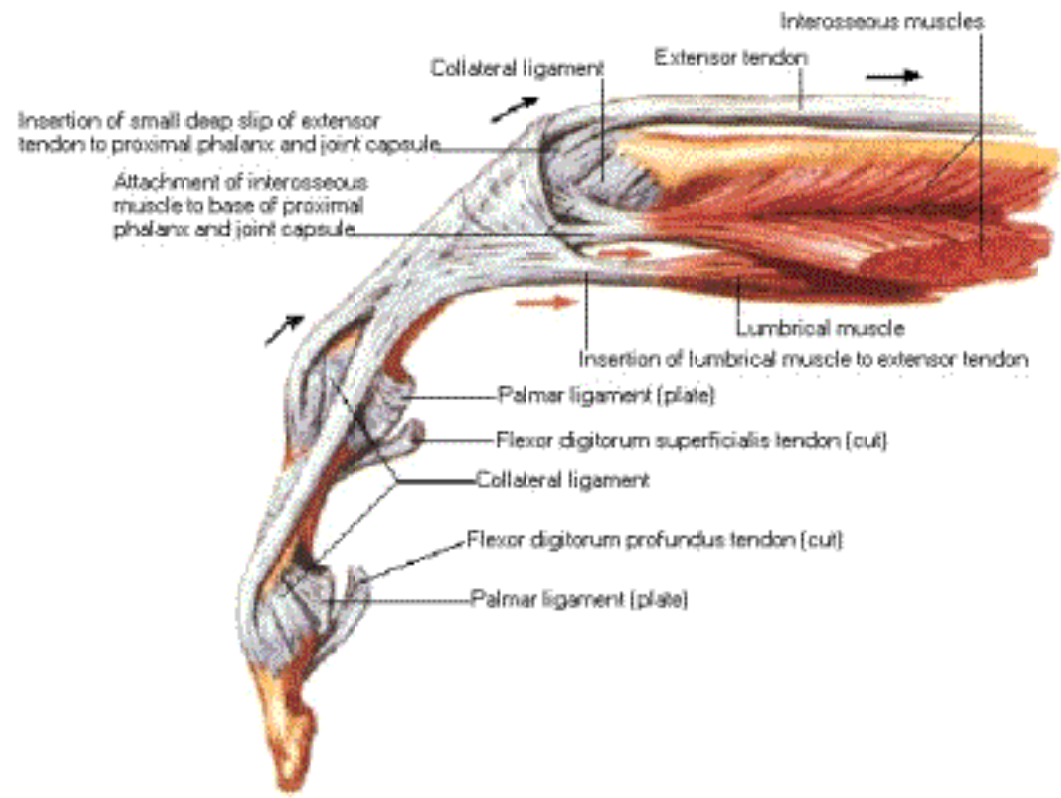
Extended - Lateral View



Note: black arrows indicate pull of long extensor tendon; red arrows indicate pull of interosseous and lumbrical muscles

F. Netter
1972

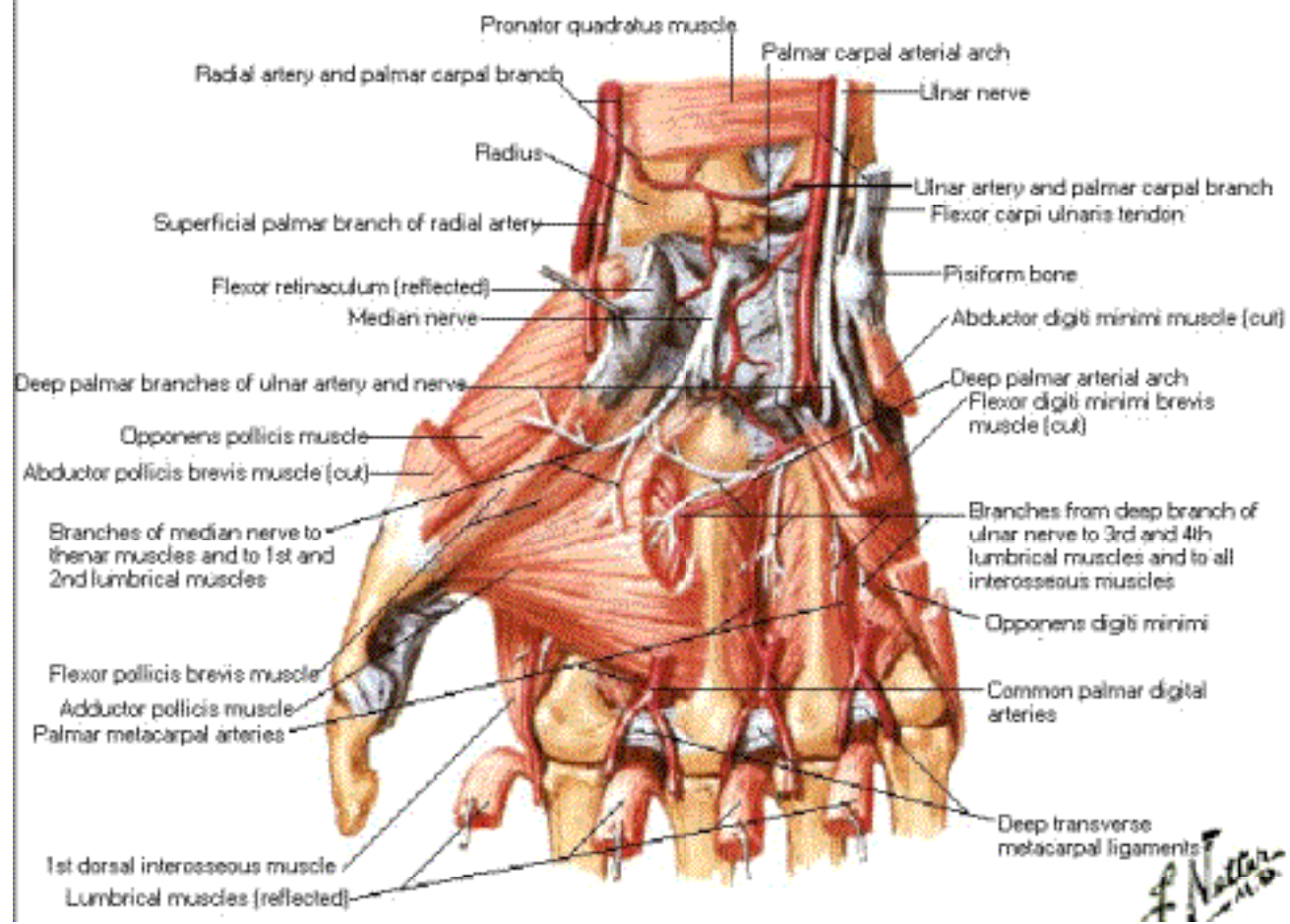
Flexor and Extensor Tendons in Fingers Flexed - Lateral View



Note: black arrows indicate pull of long extensor tendon; red arrows indicate pull of interosseous and lumbrical muscles

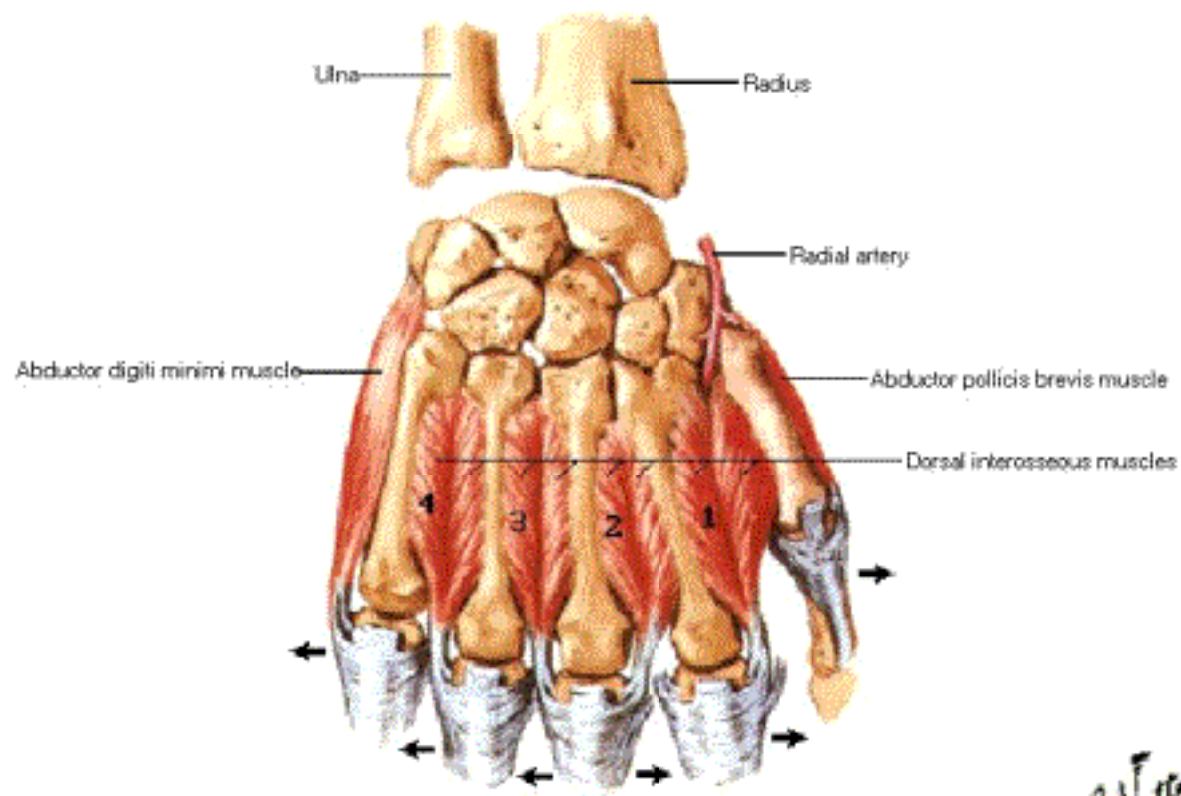
Intrinsic Muscles of Hand

Anterior [Palmar] View



Intrinsic Muscles of Hand

Posterior [Dorsal] View

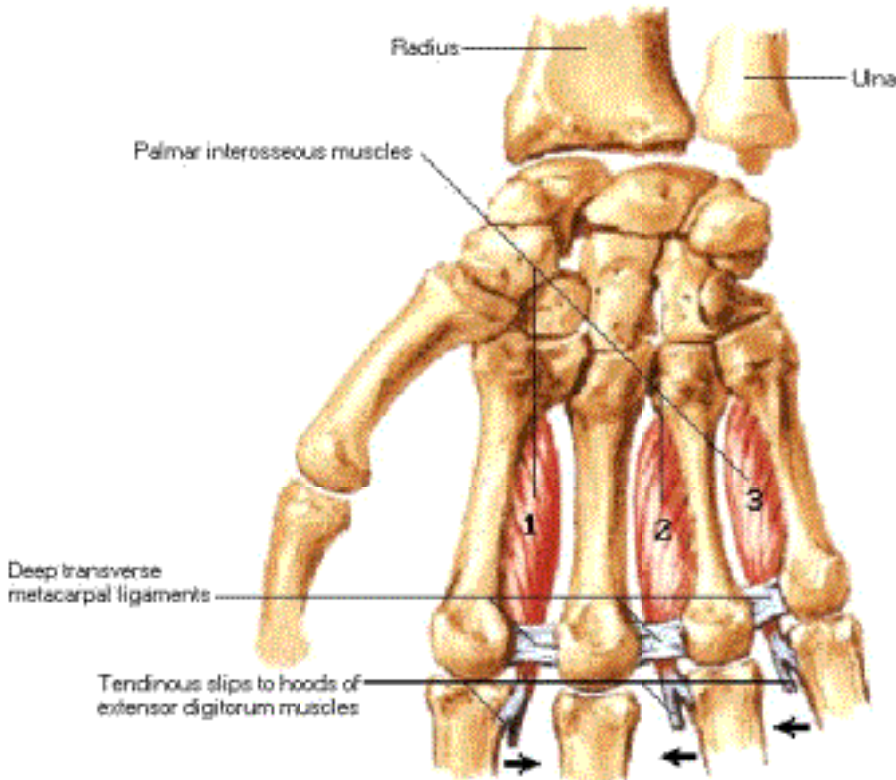


Note: arrows indicate action of muscles

F. Netter

Intrinsic Muscles of Hand

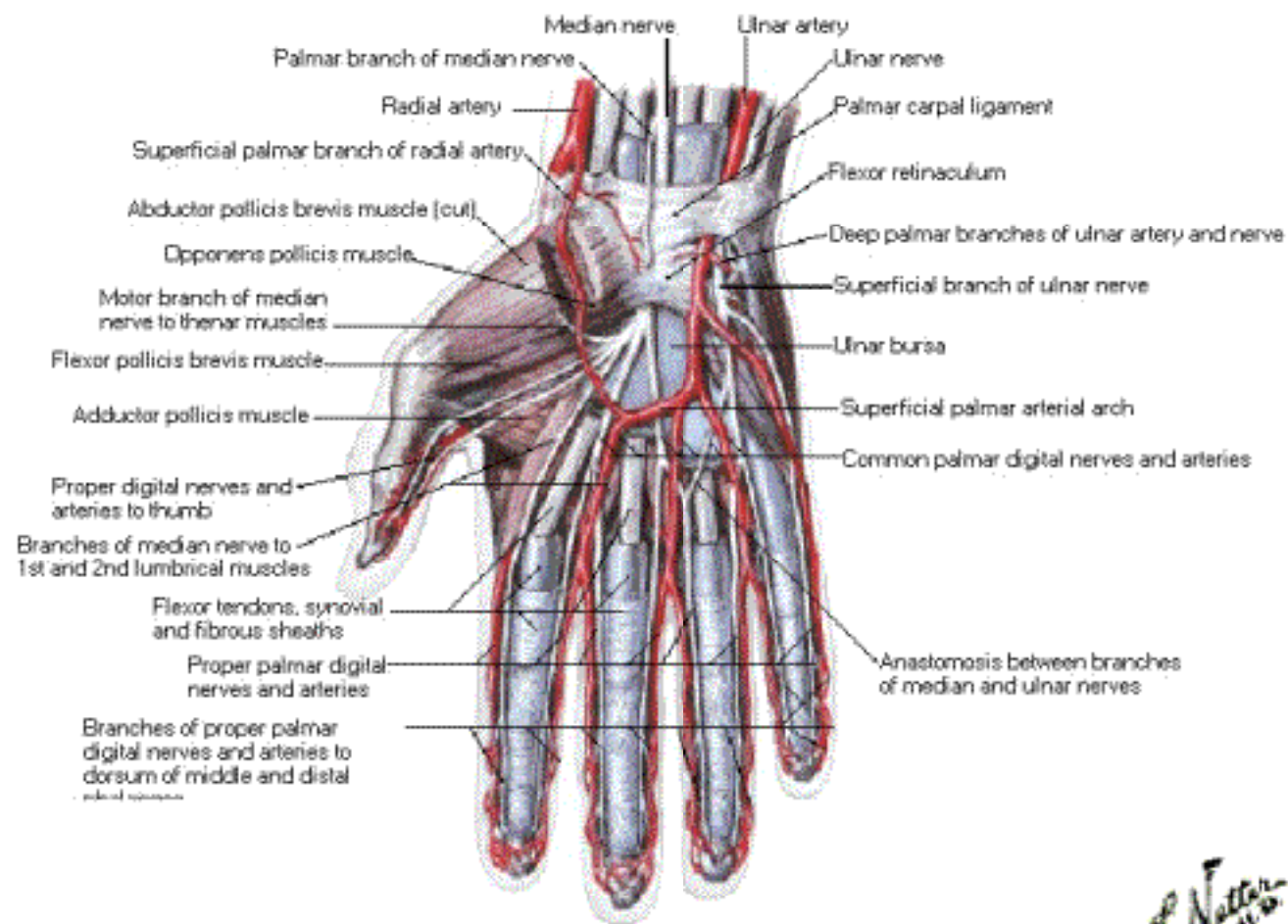
Deep Anterior [Palmar] View



Note: arrows indicate action of muscles

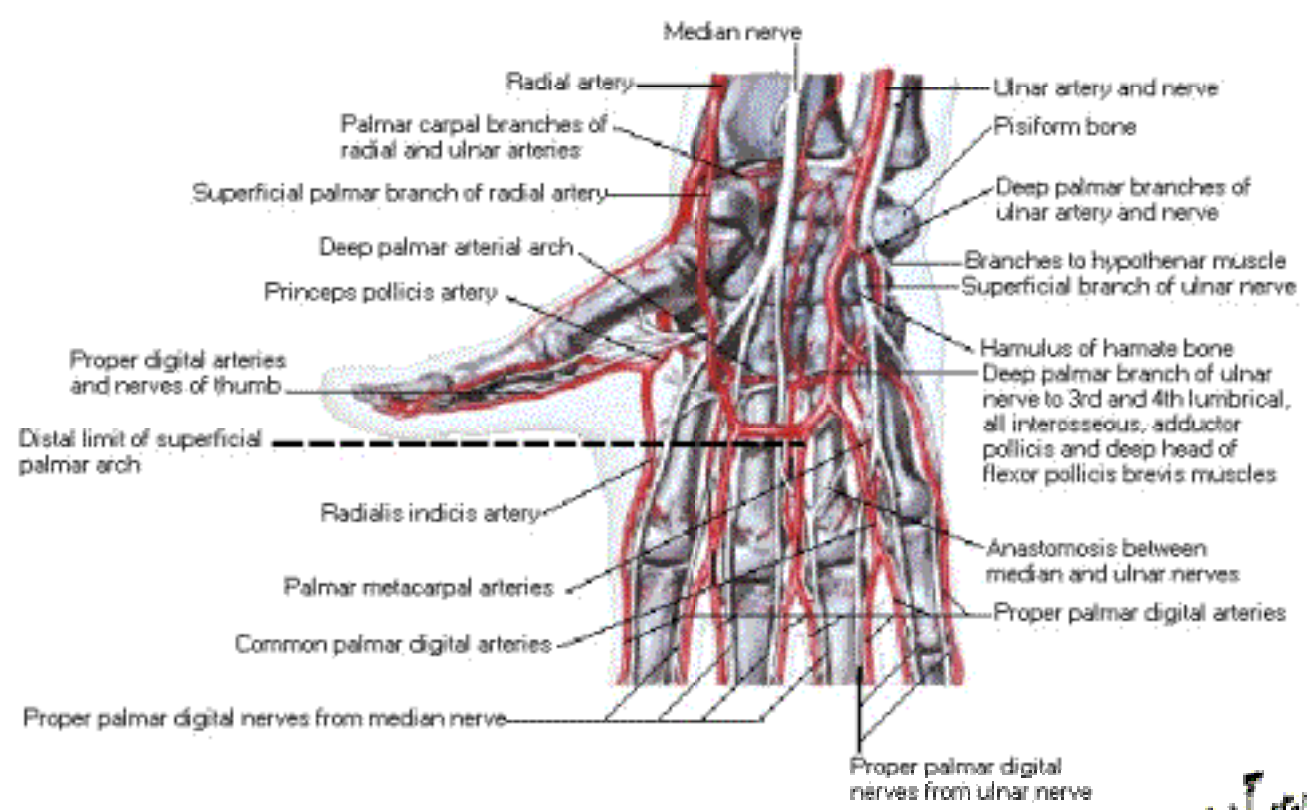
Arteries and Nerves of Hand

Palmar View

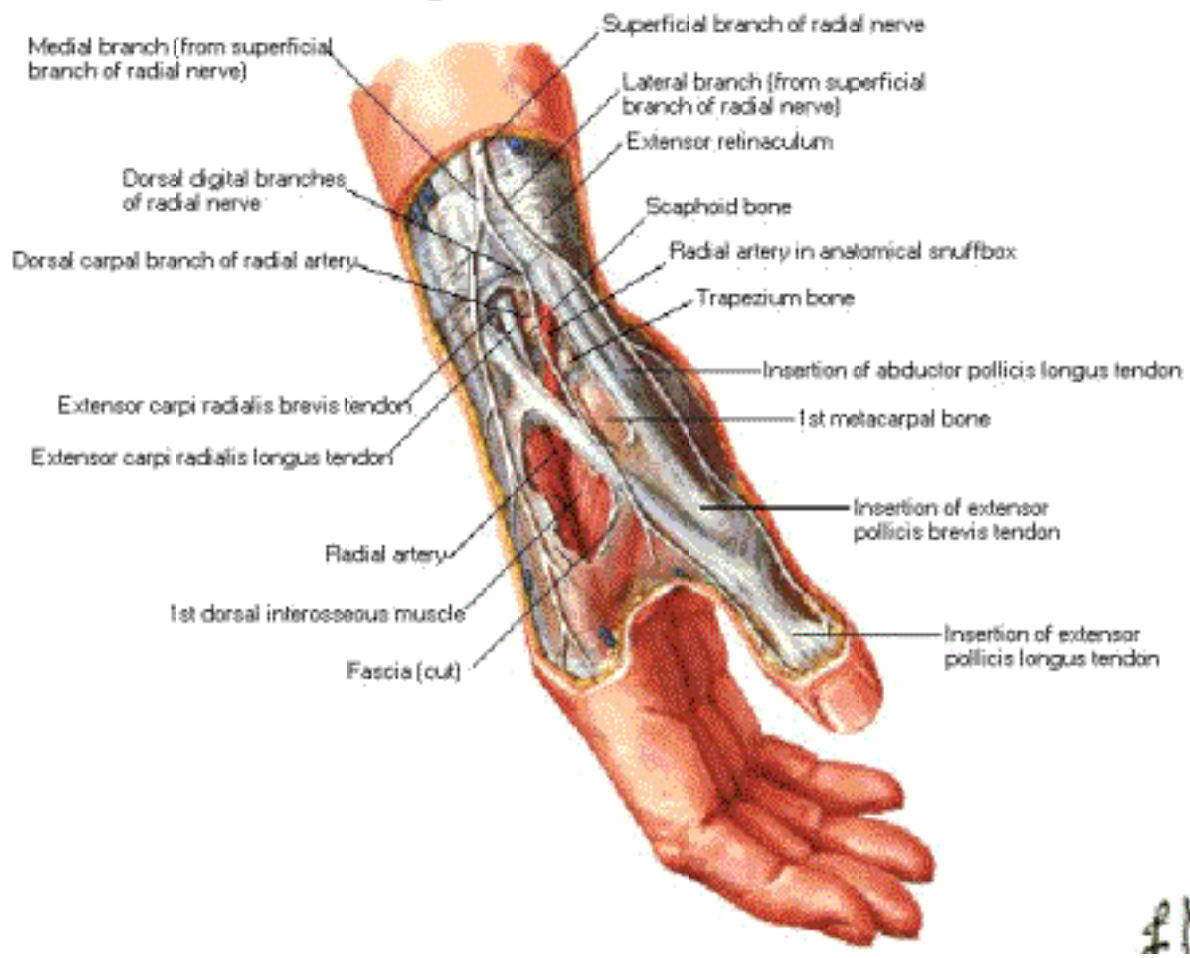


Arteries and Nerves of Hand

Deep Palmar View

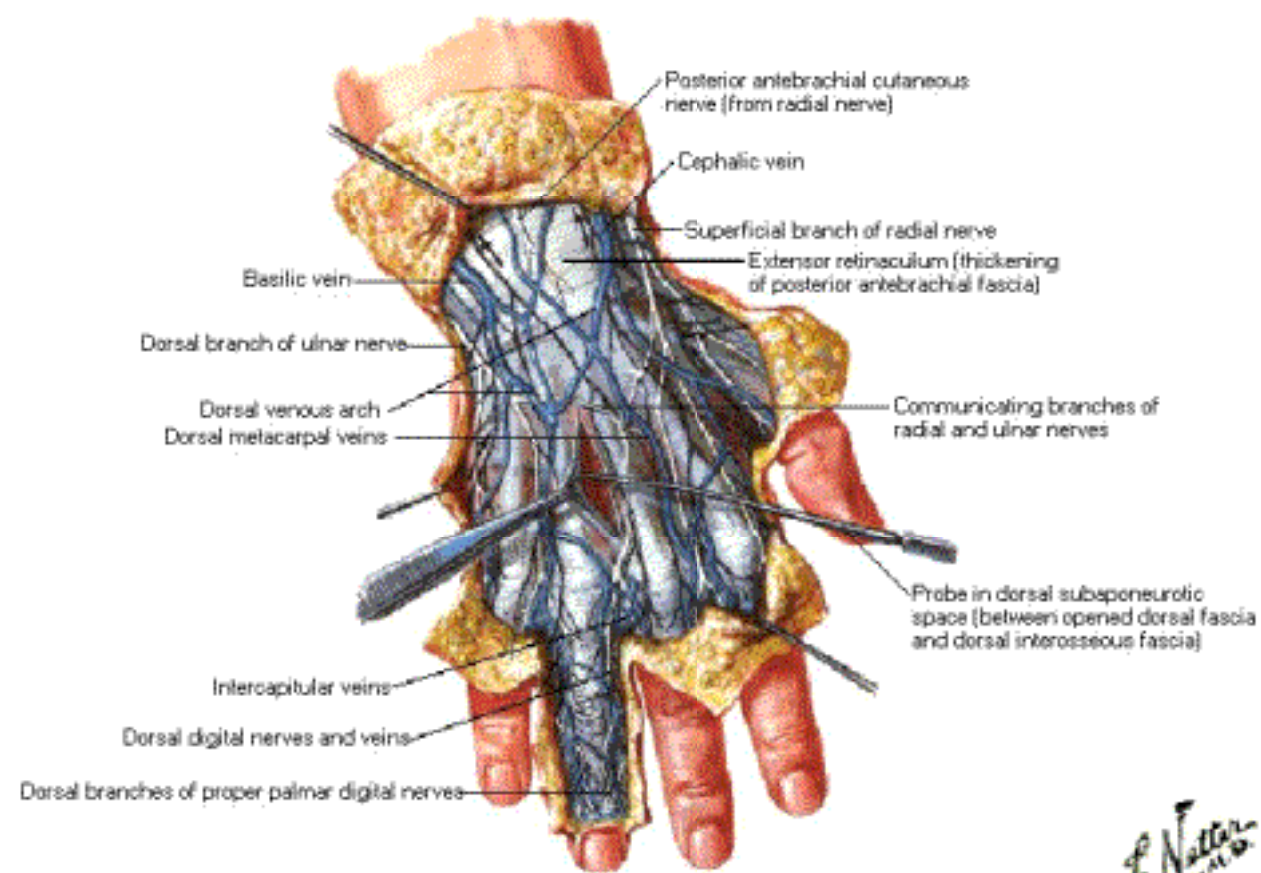


Wrist and Hand Superficial Radial Dissection



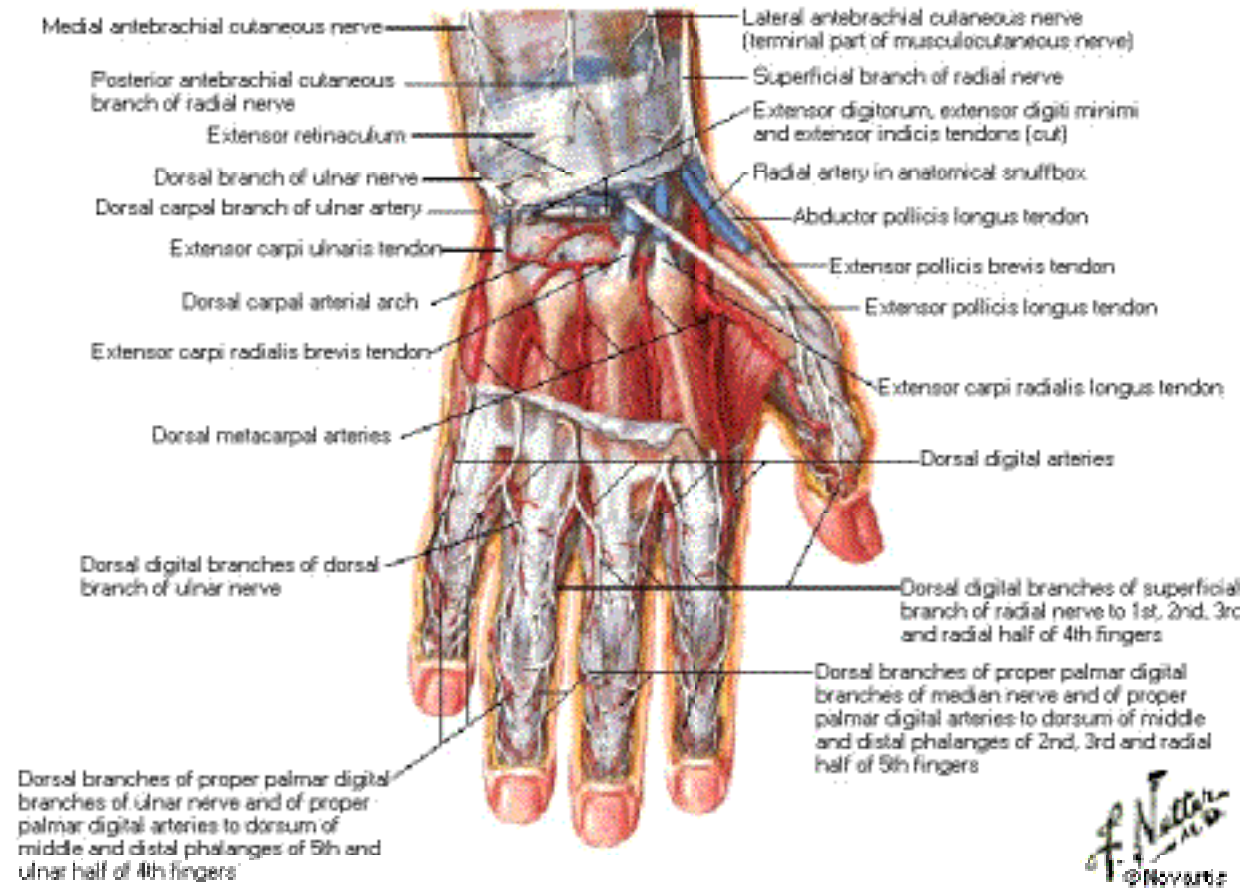
Wrist and Hand

Superficial Dorsal Dissection



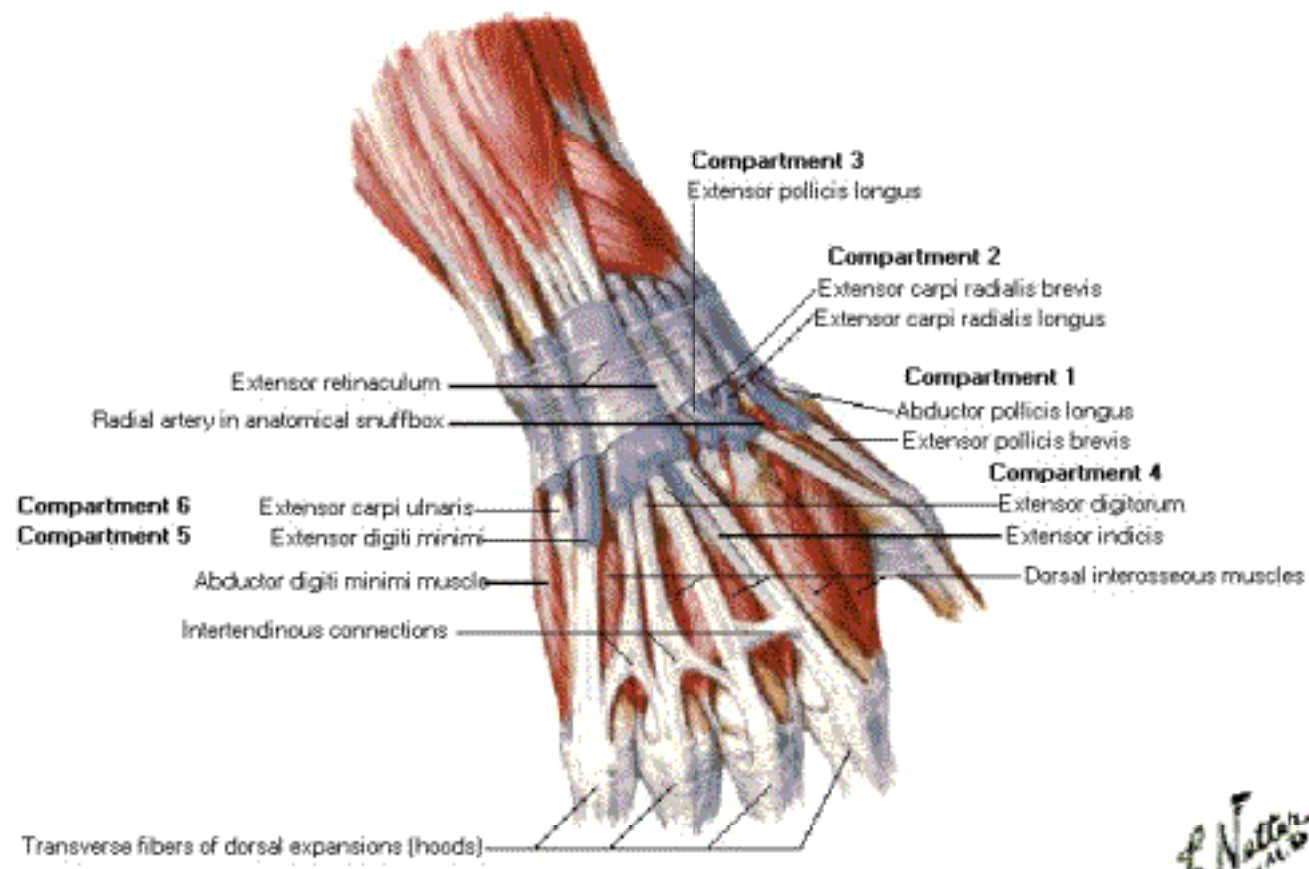
F. Netter M.D.
© Novartis

Wrist and Hand Deep Dorsal Dissection



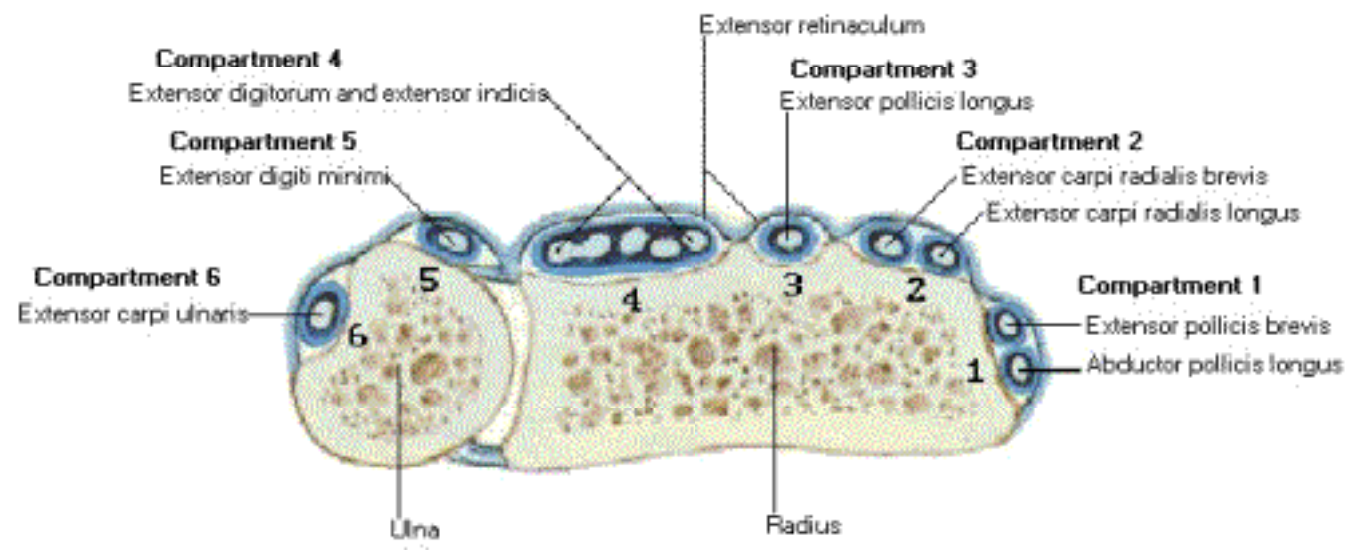
Extensor Tendons at Wrist

Posterior [Dorsal] View



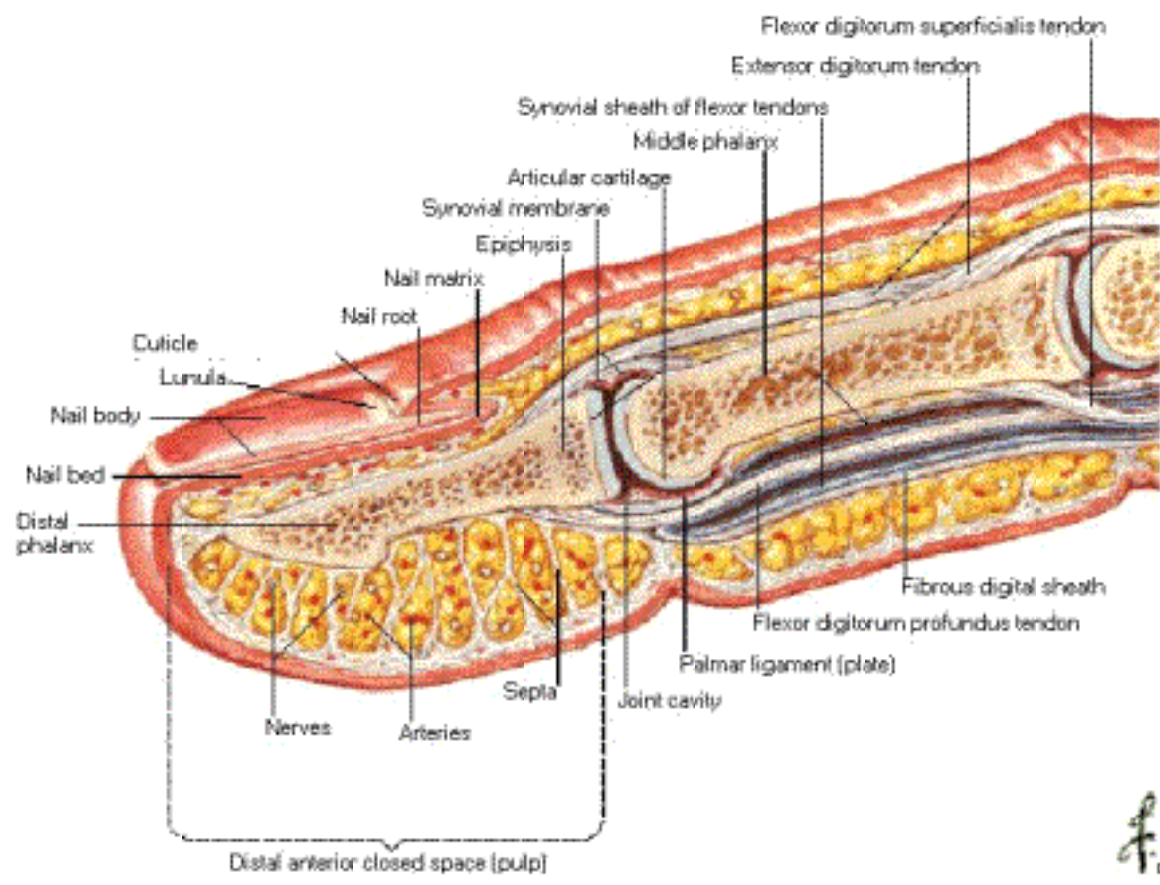
Extensor Tendons at Wrist

Cross Section at Proximal Wrist



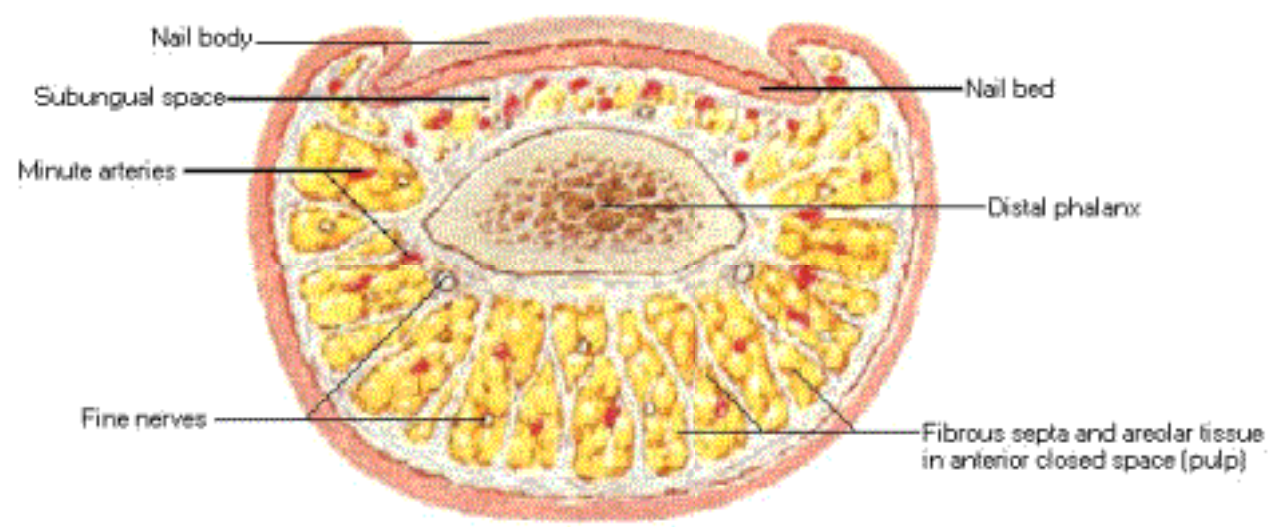
Fingers

Sagittal Section



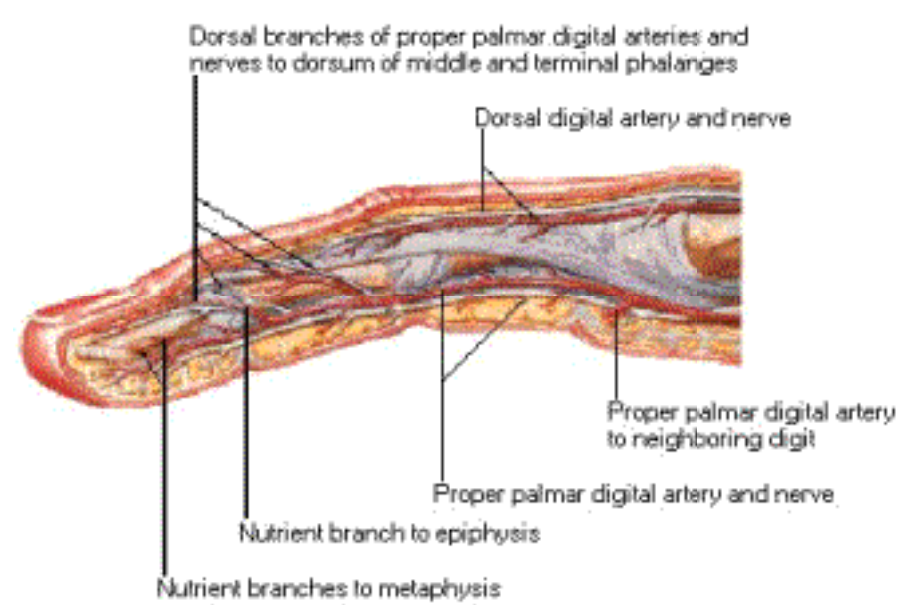
Fingers

Cross Section through Distal Phalanx



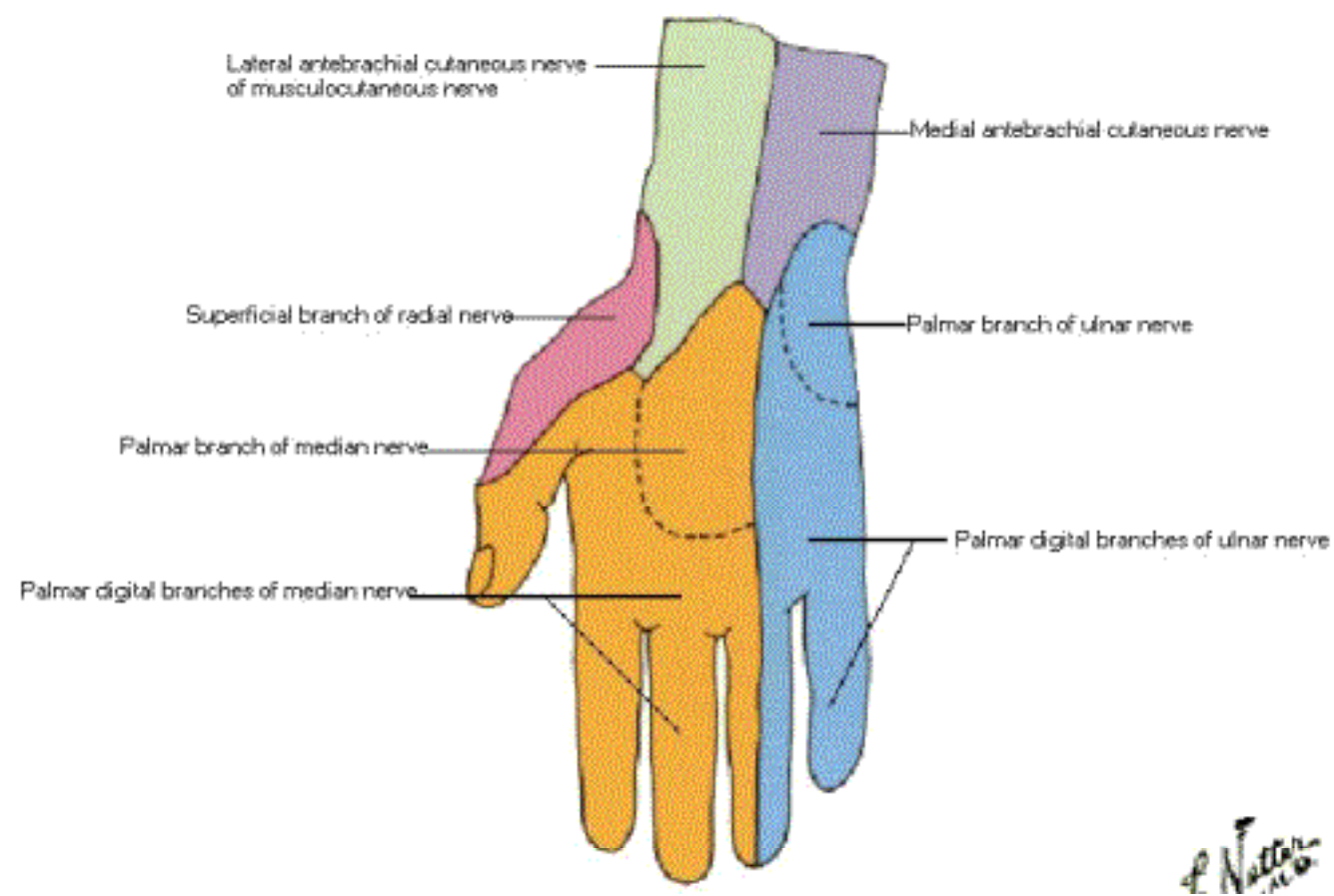
Fingers

Arteries and Nerves



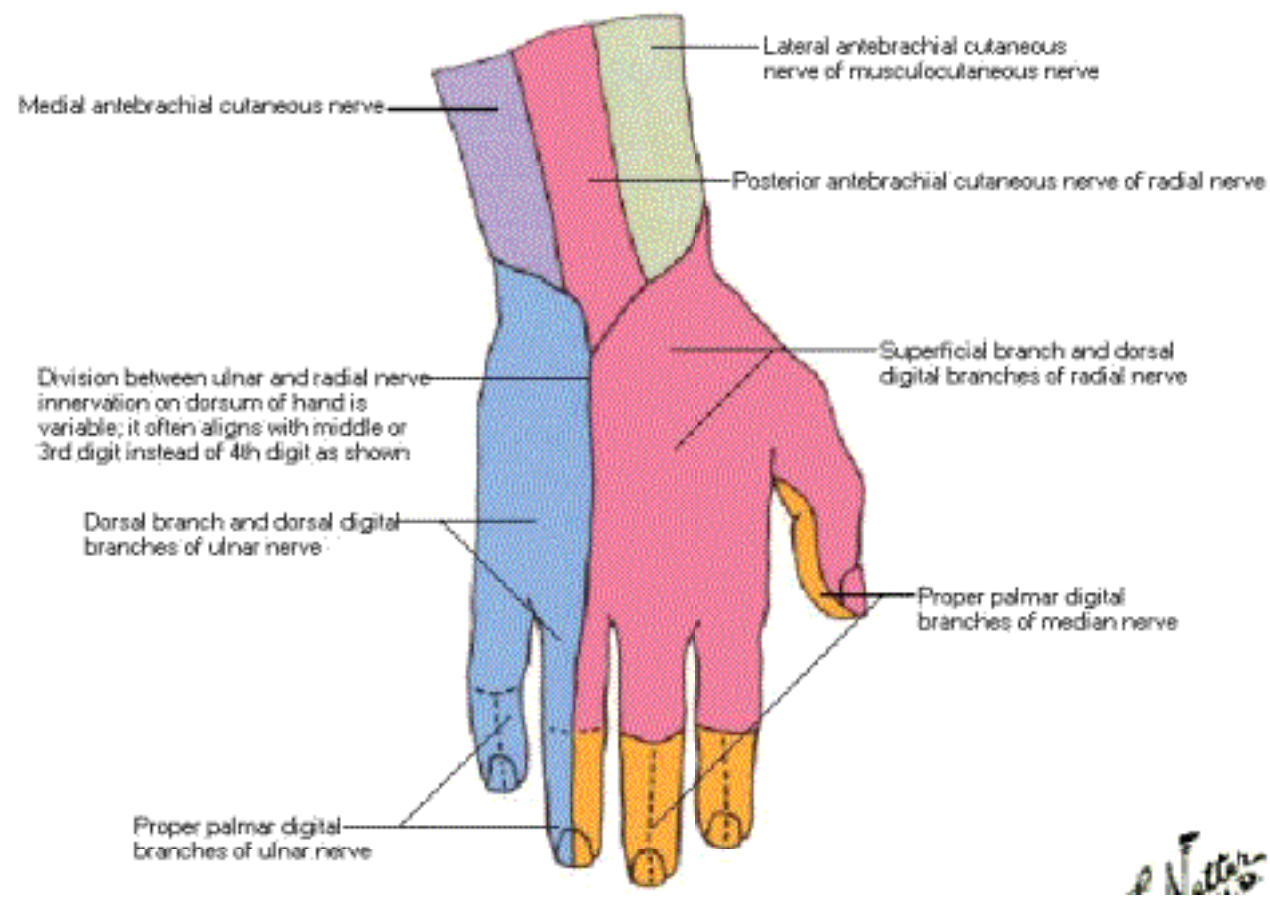
Cutaneous Nerves of Wrist and Hand

Anterior [Palmar] View

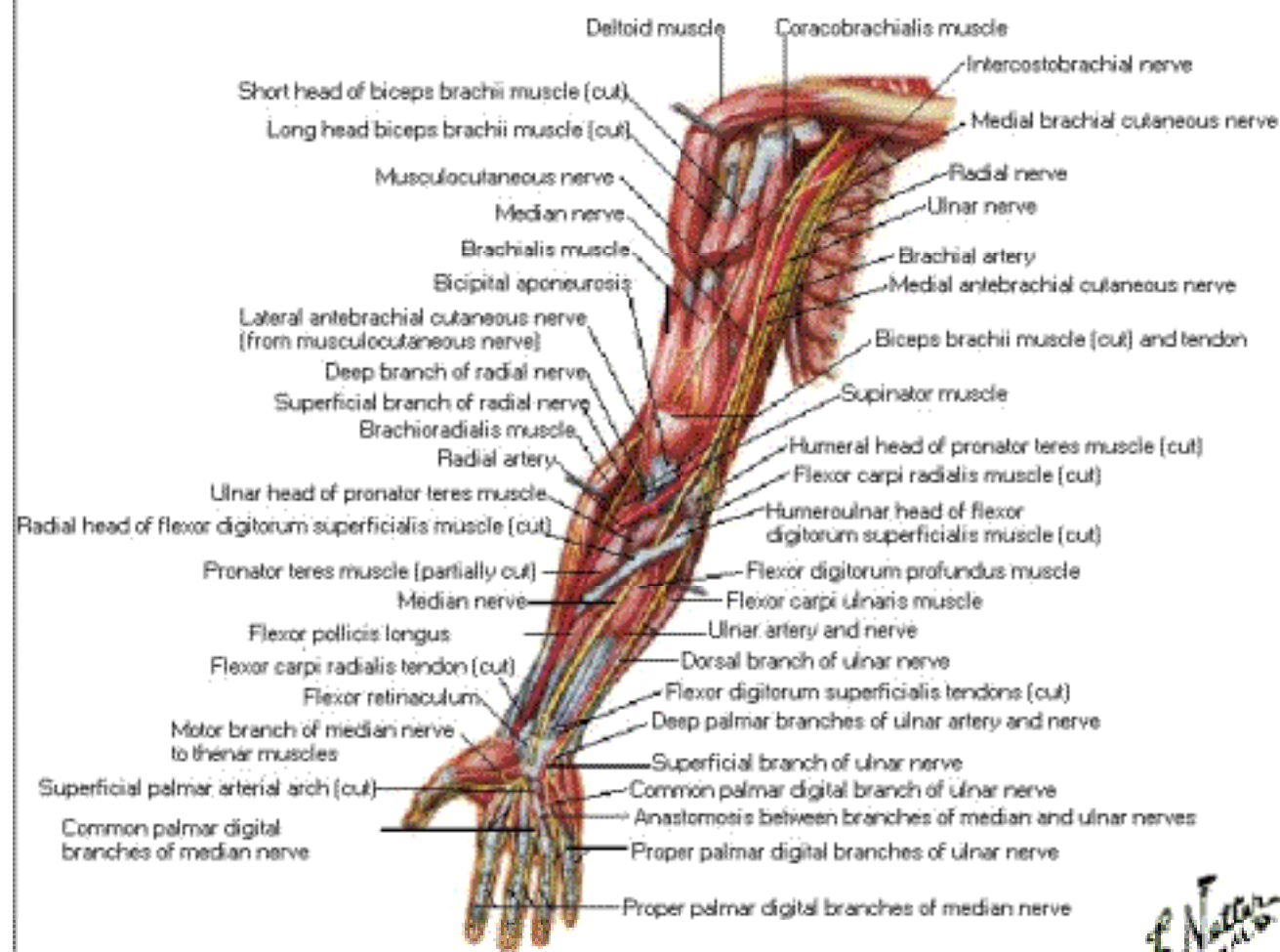


Cutaneous Nerves of Wrist and Hand

Posterior [Dorsal] View



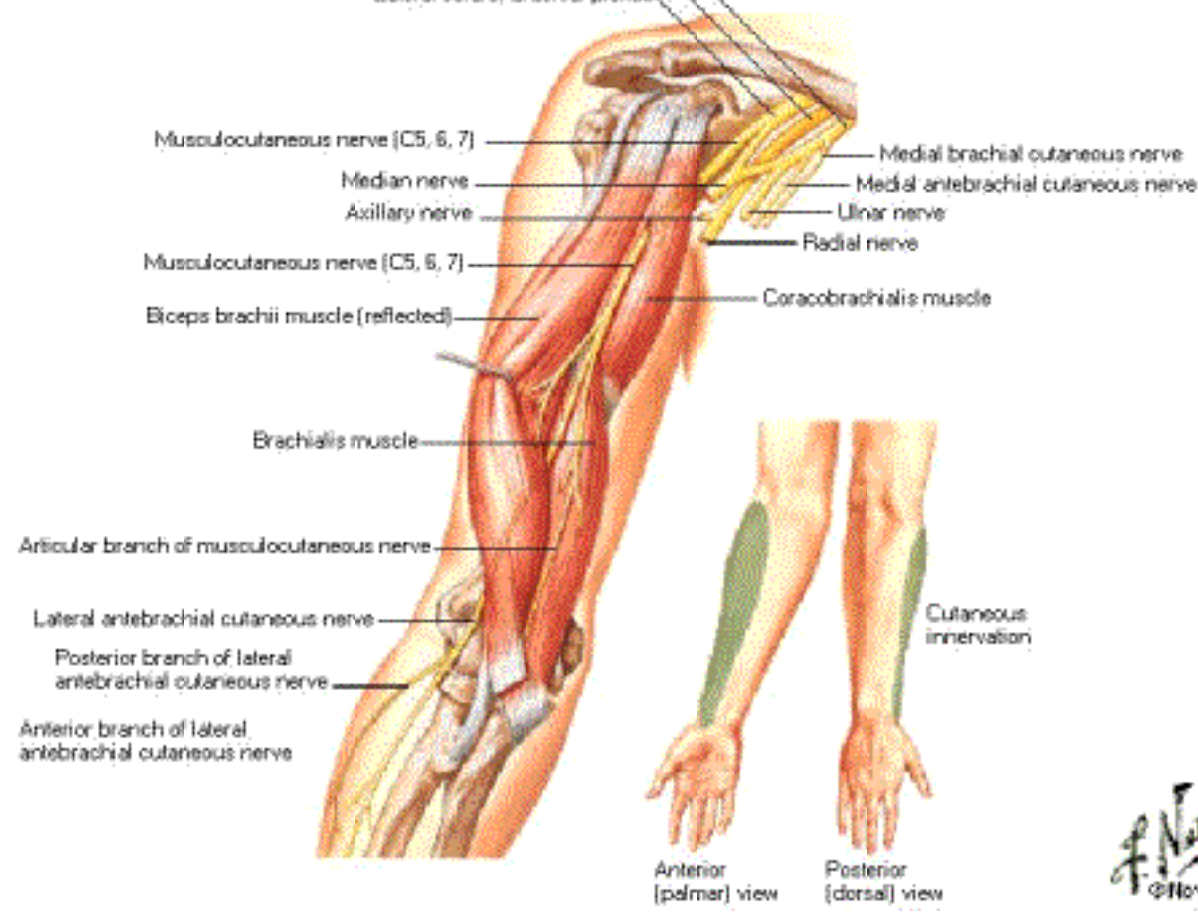
Arteries and Nerves of Upper Limb



Musculocutaneous Nerve

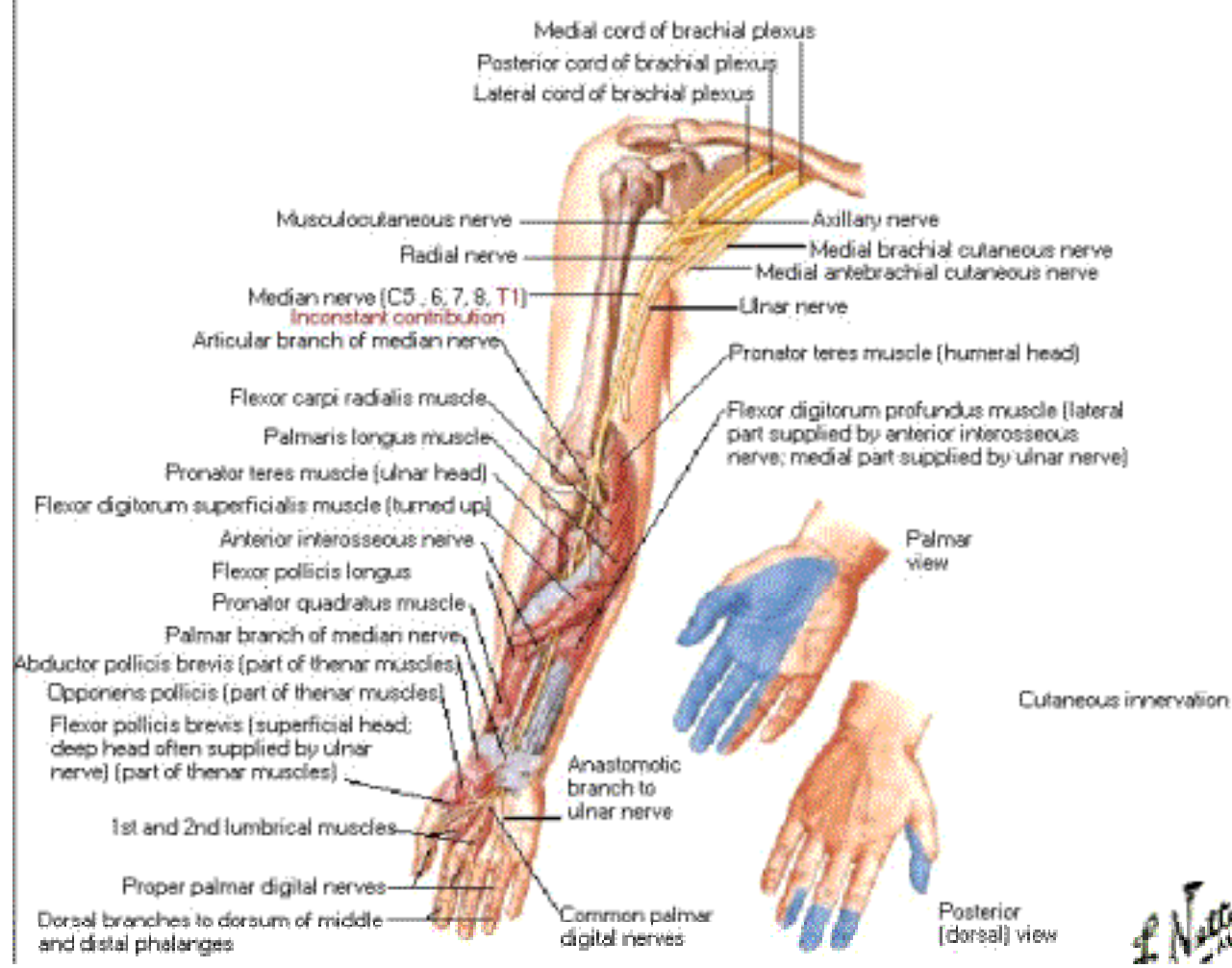
Medial cord of brachial plexus
Posterior cord of brachial plexus
Lateral cord of brachial plexus

Note: only muscles innervated by musculocutaneous nerve shown



F. Net
© Nov

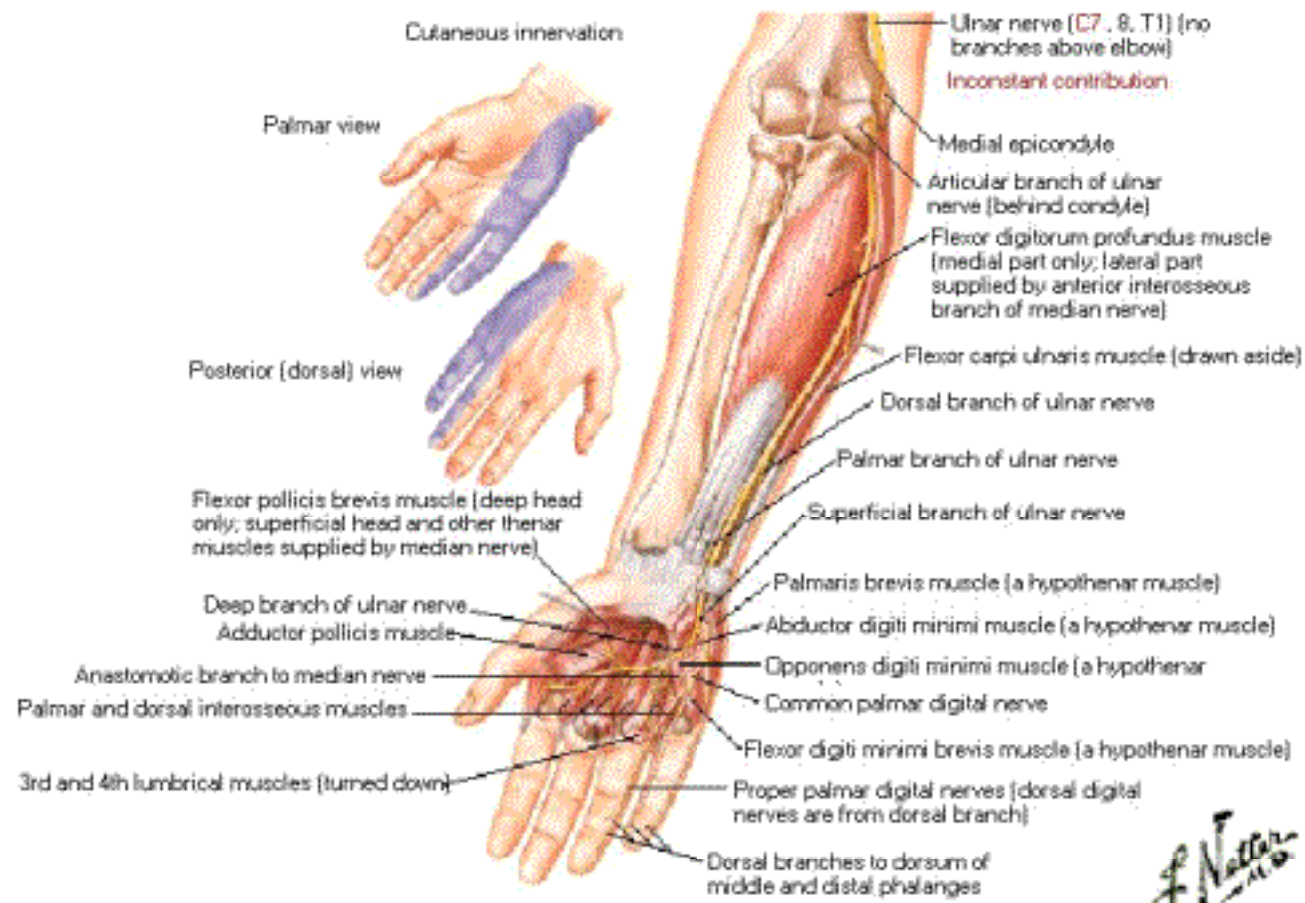
Median Nerve



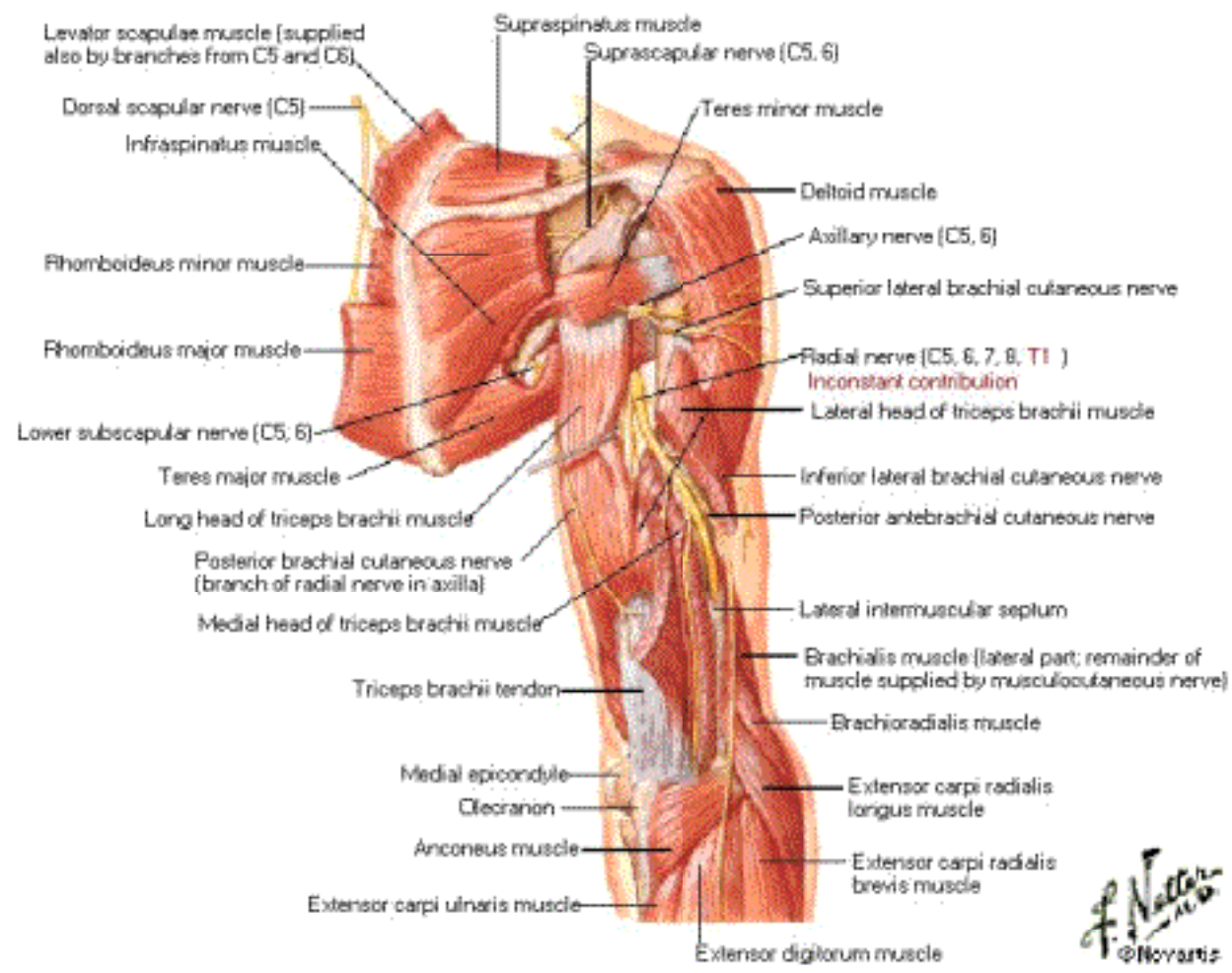
Dr. Nasser

Ulnar Nerve

Note: only muscles innervated by ulnar nerve shown

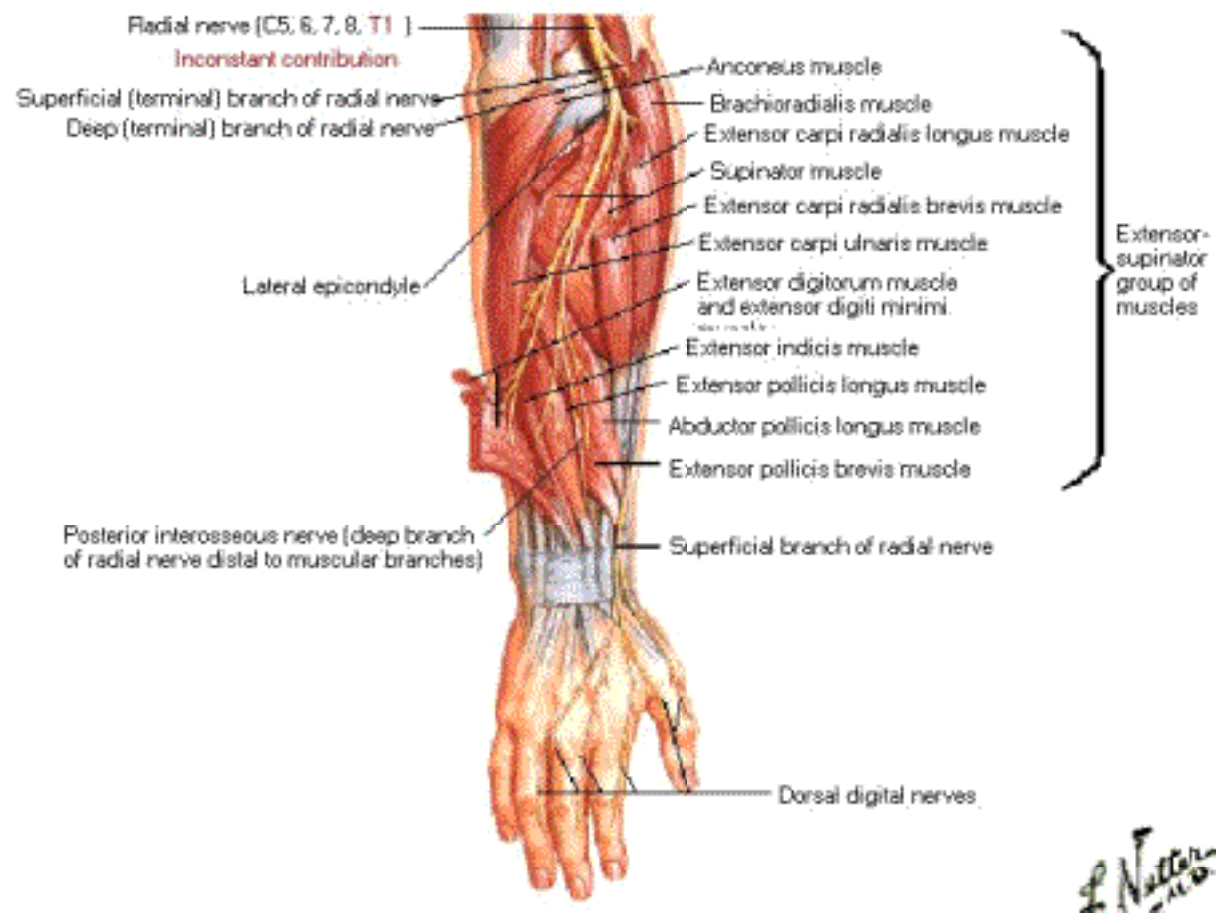


Radial Nerve in Arm and Nerves of Posterior Shoulder



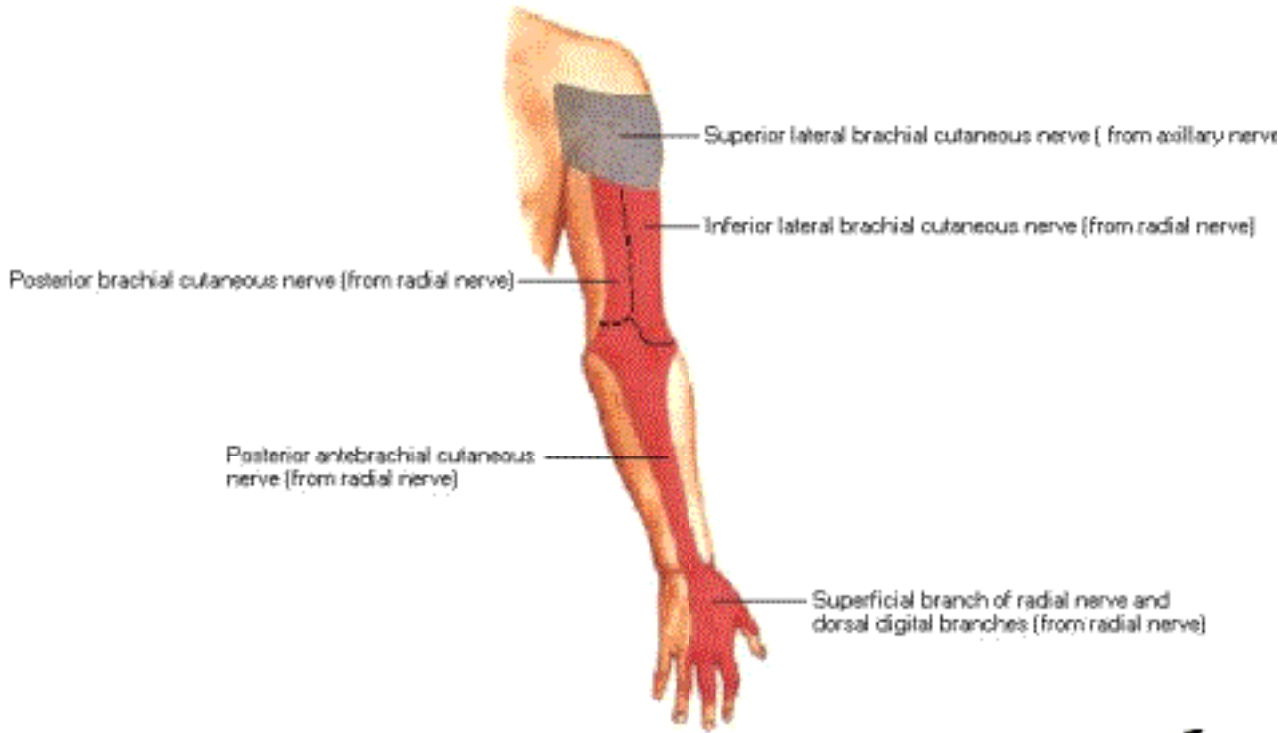
Radial Nerve in Forearm

Posterior View



Radial and Axillary Nerves

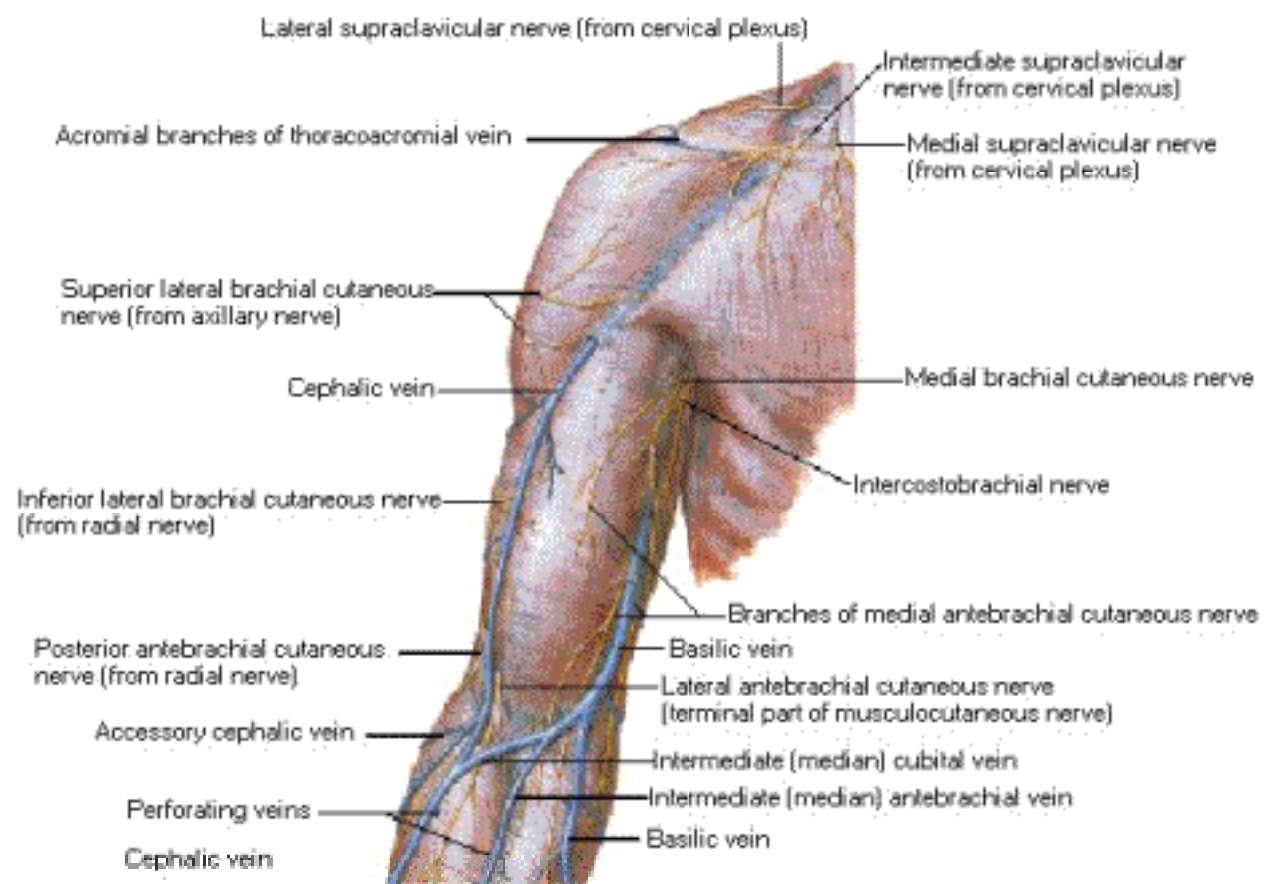
Cutaneous Innervation



Posterior View

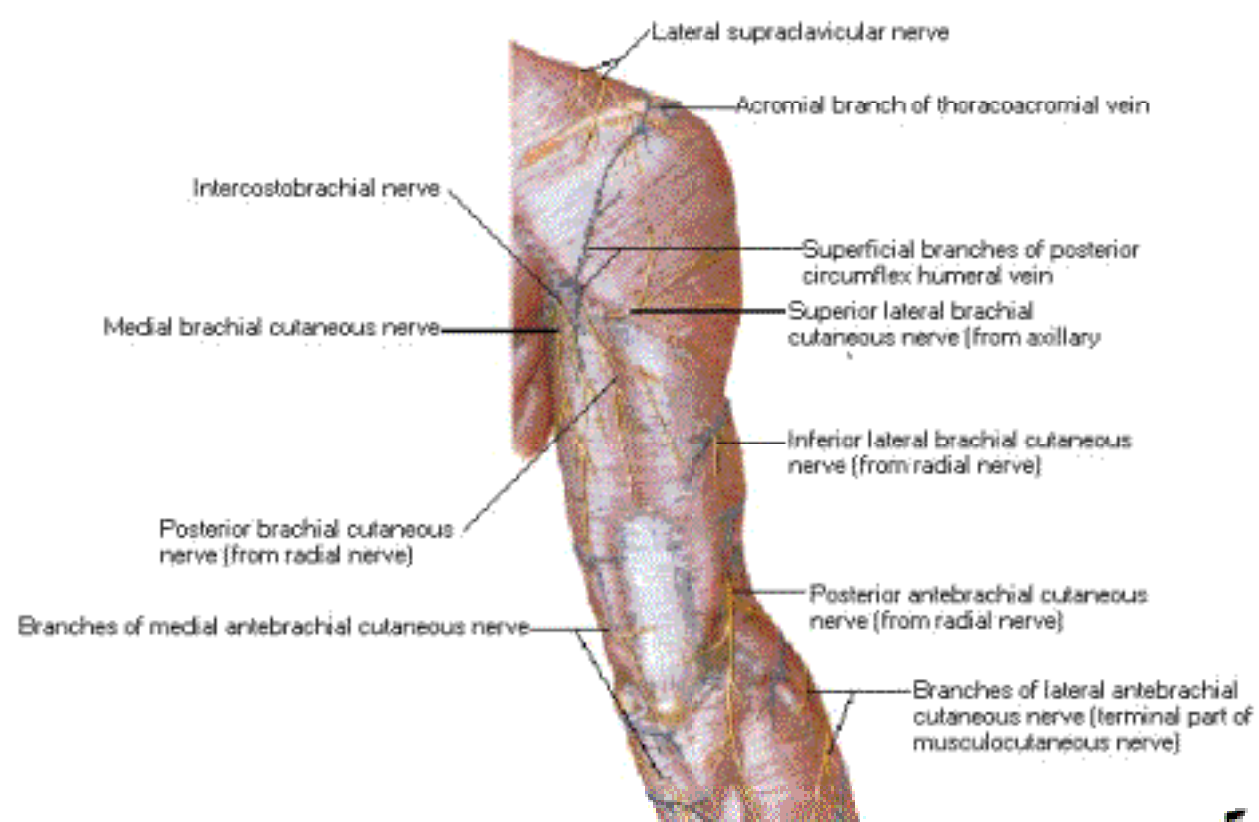
Superficial Nerves and Veins of Shoulder and Arm

Anterior View



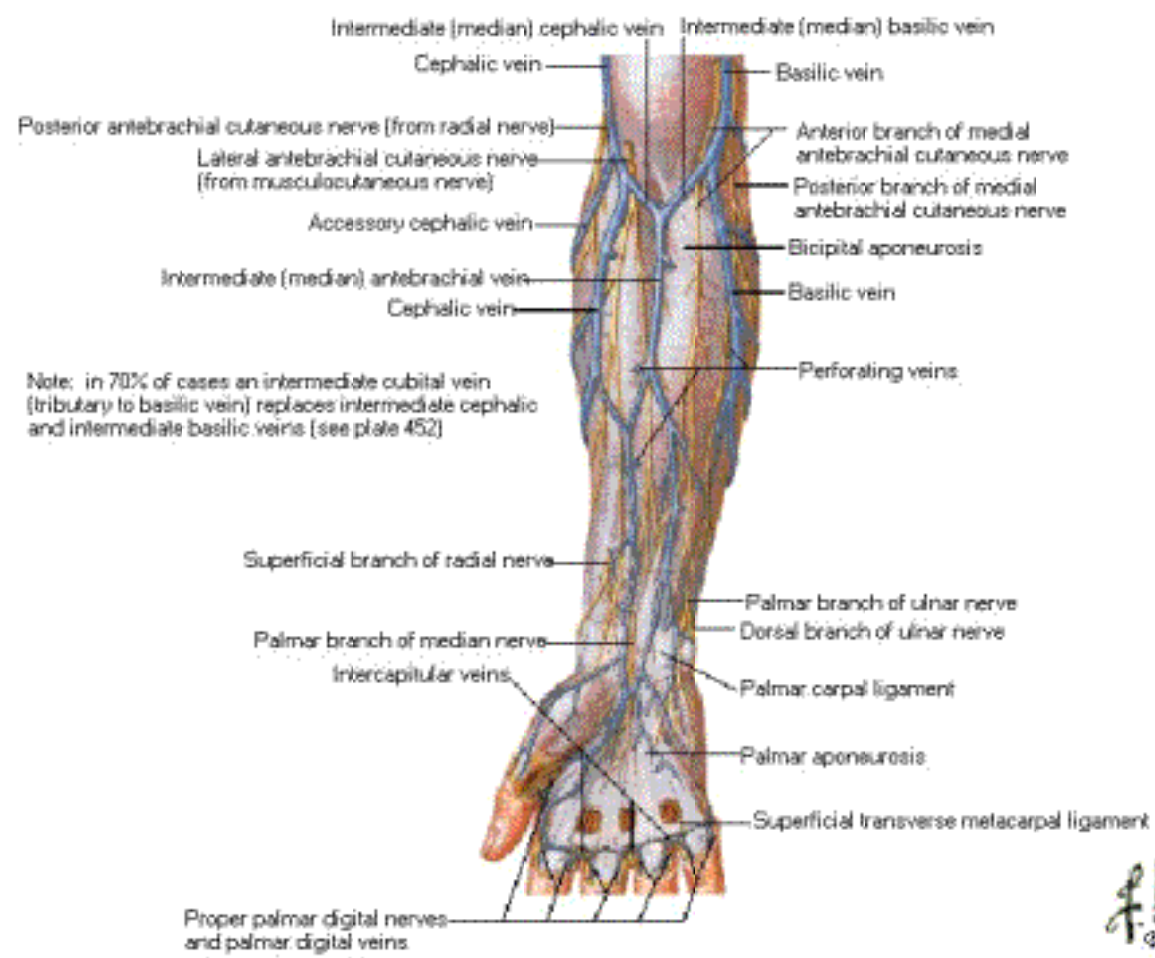
Superficial Nerves and Veins of Shoulder and Arm

Posterior View



Cutaneous Nerves and Superficial Veins of Forearm

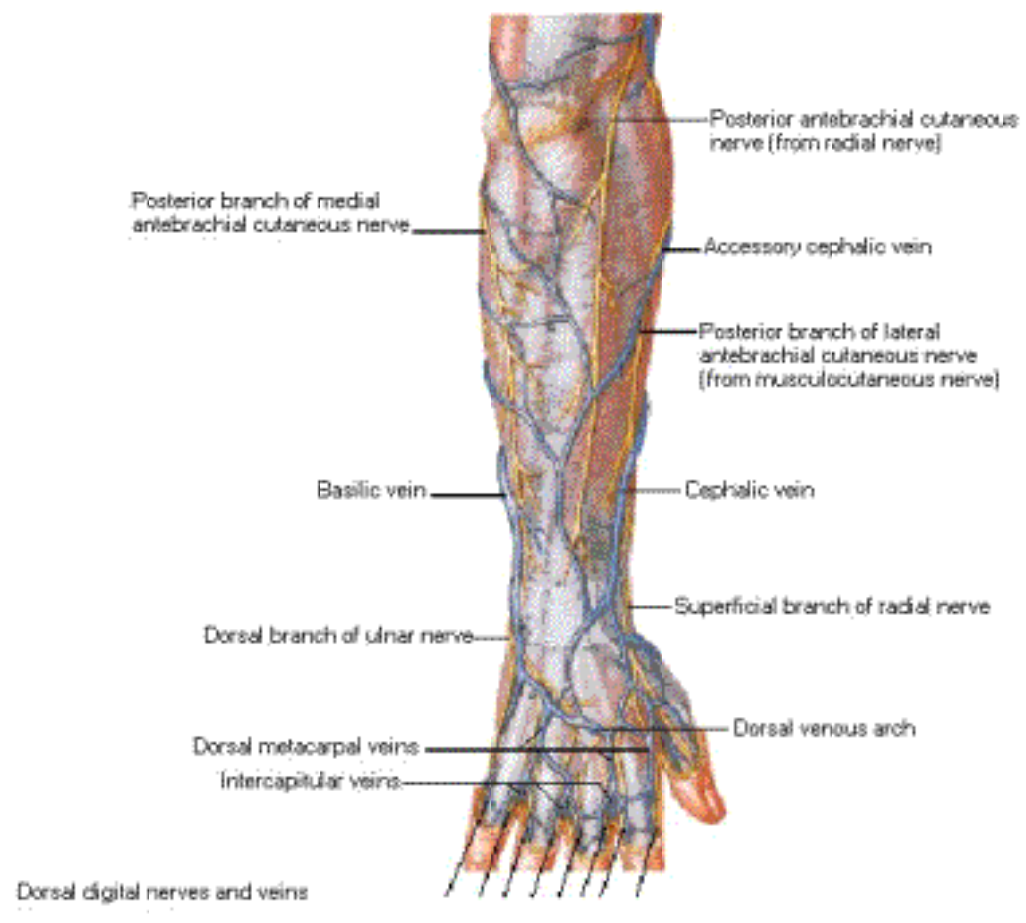
Anterior (Palmar) View



01

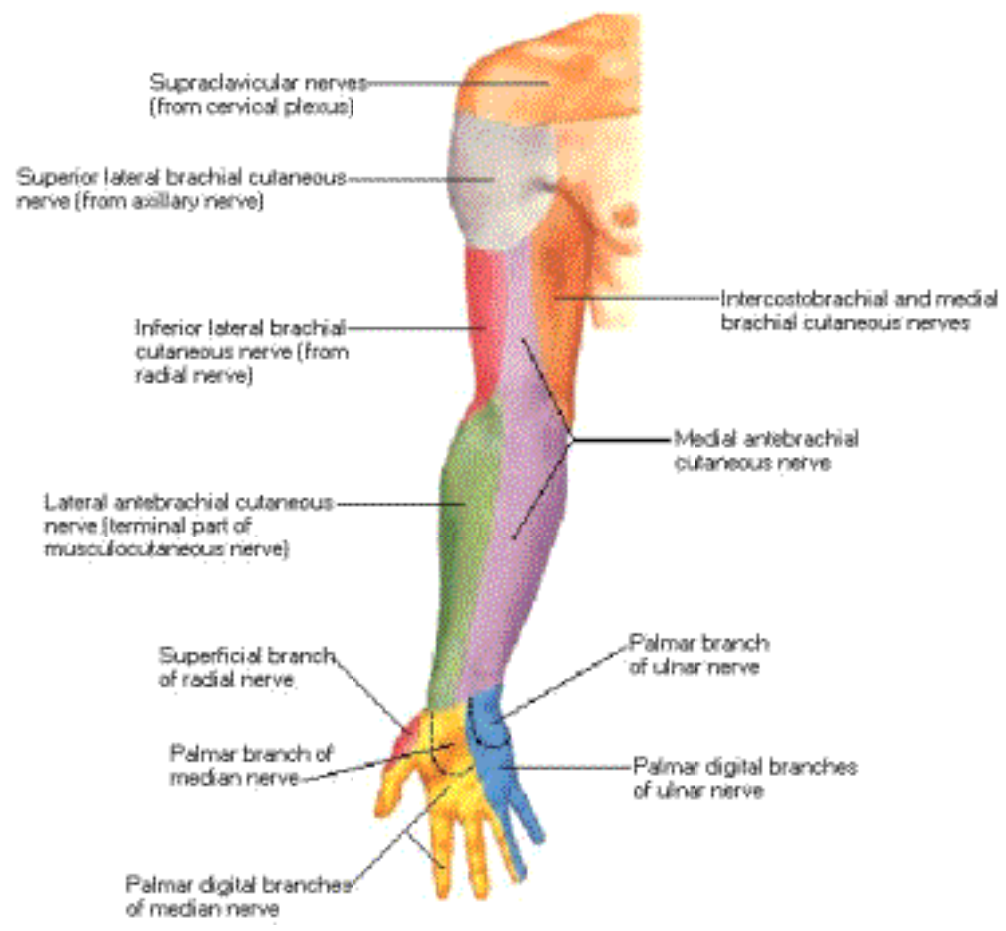
Cutaneous Nerves and Superficial Veins of Forearm

Posterior (Dorsal) View

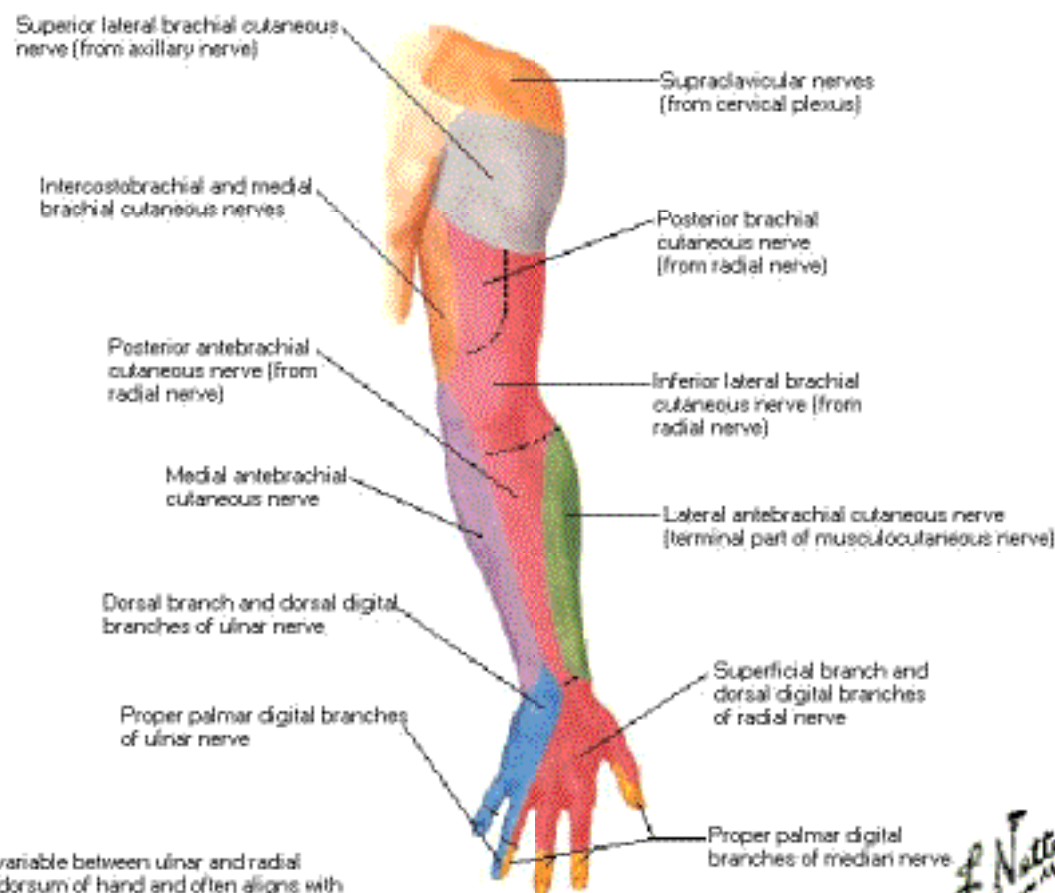


Cutaneous Innervation of Upper Limb

Anterior [Palmar] View



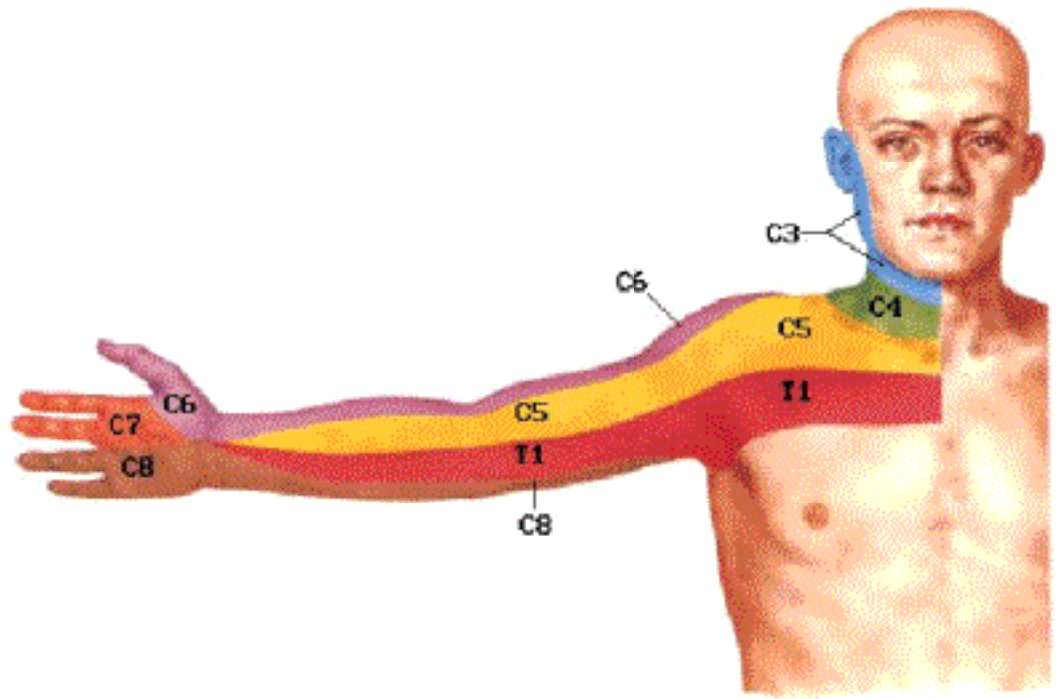
Cutaneous Innervation of Upper Limb Posterior [Dorsal] View



Note: division variable between ulnar and radial innervation on dorsum of hand and often aligns with middle of 3rd digit instead of 4th digit as shown.

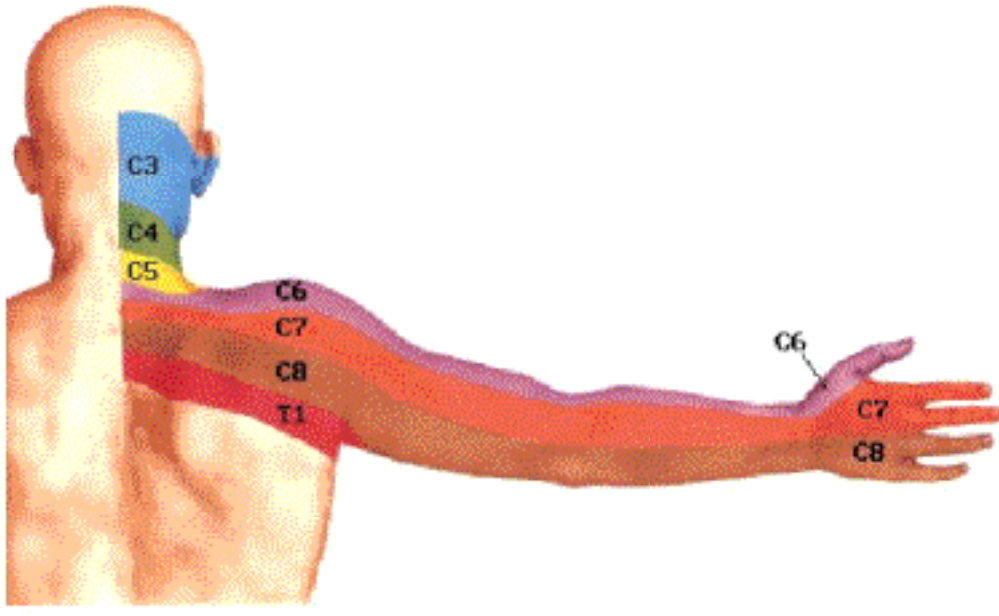
F. Netter
© Novas

Dermatomes of Upper Limb
Anterior View



Note: schematic demarcation of dermatomes shown as distinct segments. There is actually considerable overlap between adjacent dermatomes.

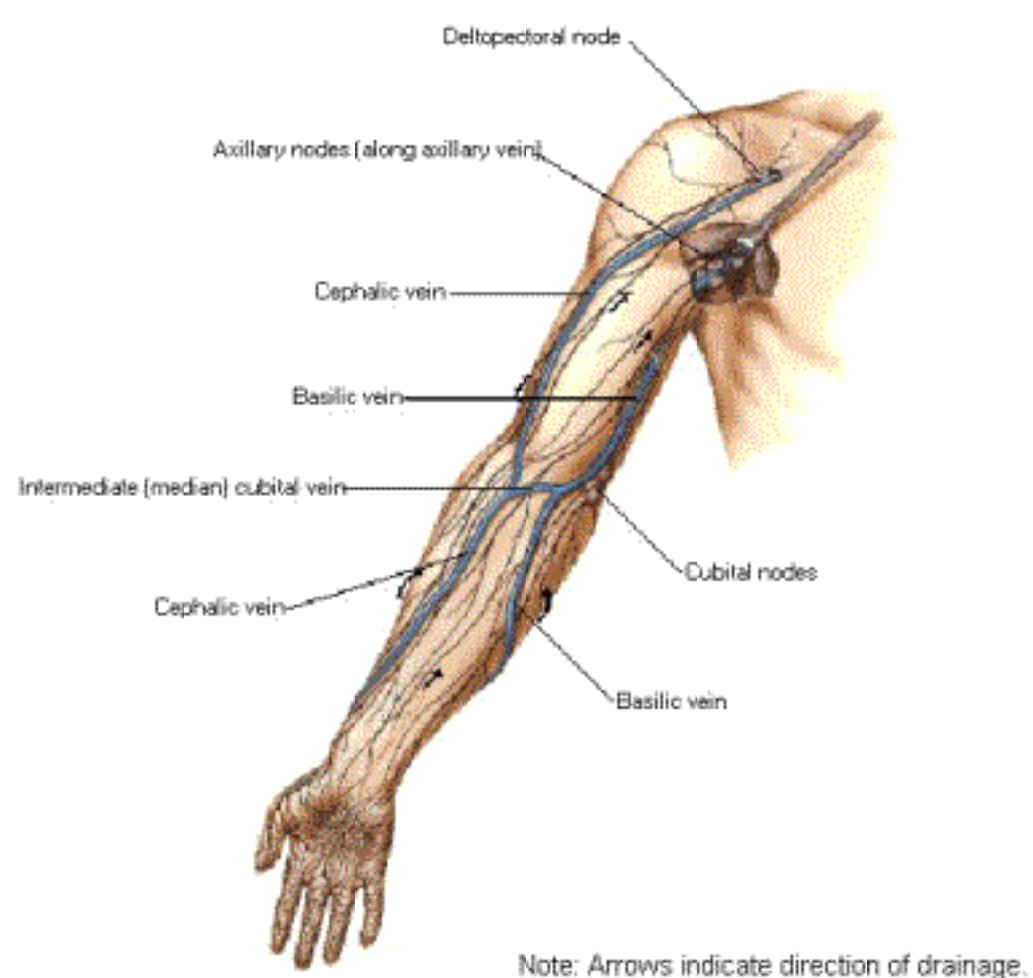
Dermatomes of Upper Limb Posterior View



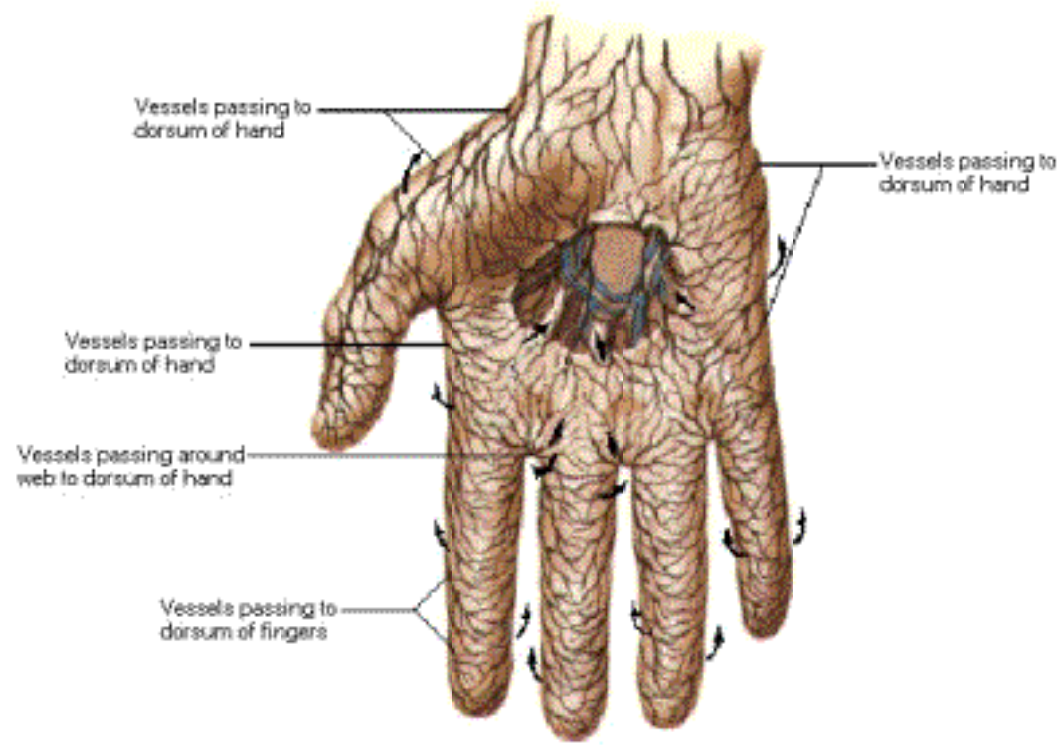
Note: schematic demarcation of dermatomes shown as distinct segments.
There is actually considerable overlap between adjacent dermatomes.

FN

Lymph Vessels and Nodes of Upper Limb



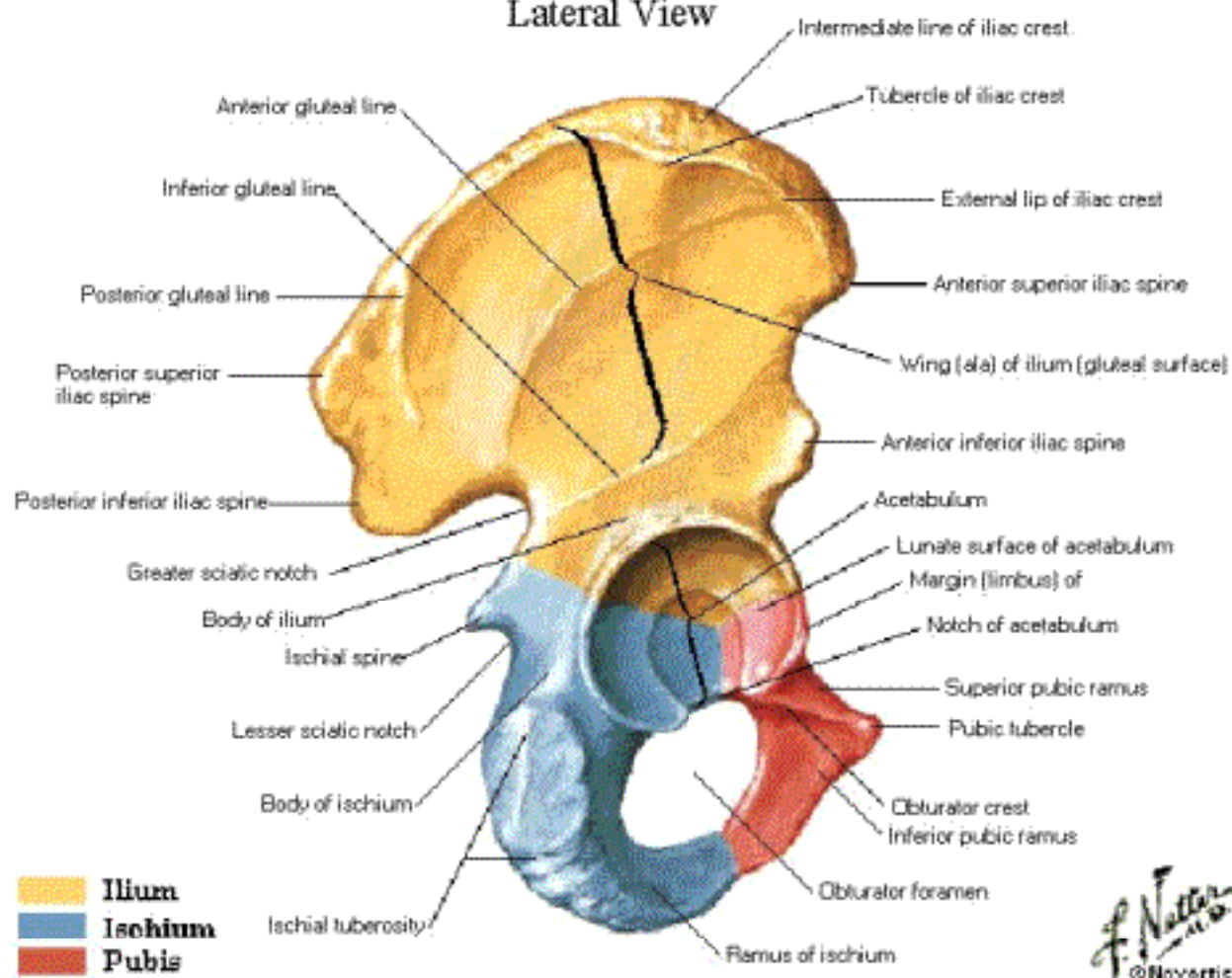
Lymph Vessels of Hand



Note: Arrows indicate direction of drainage.

Coxal Bone

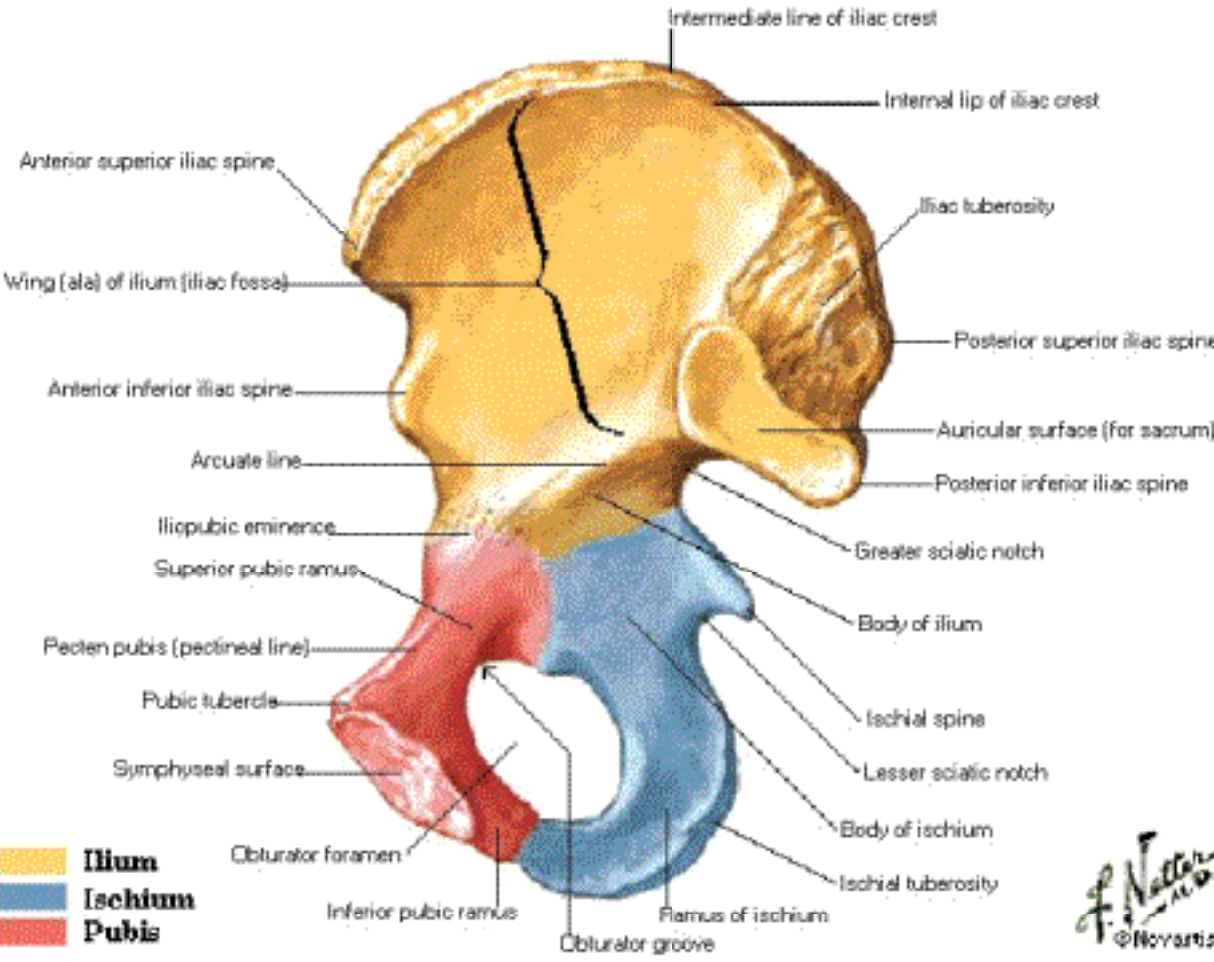
Lateral View



F. Netter
© Novartis

Coxal Bone

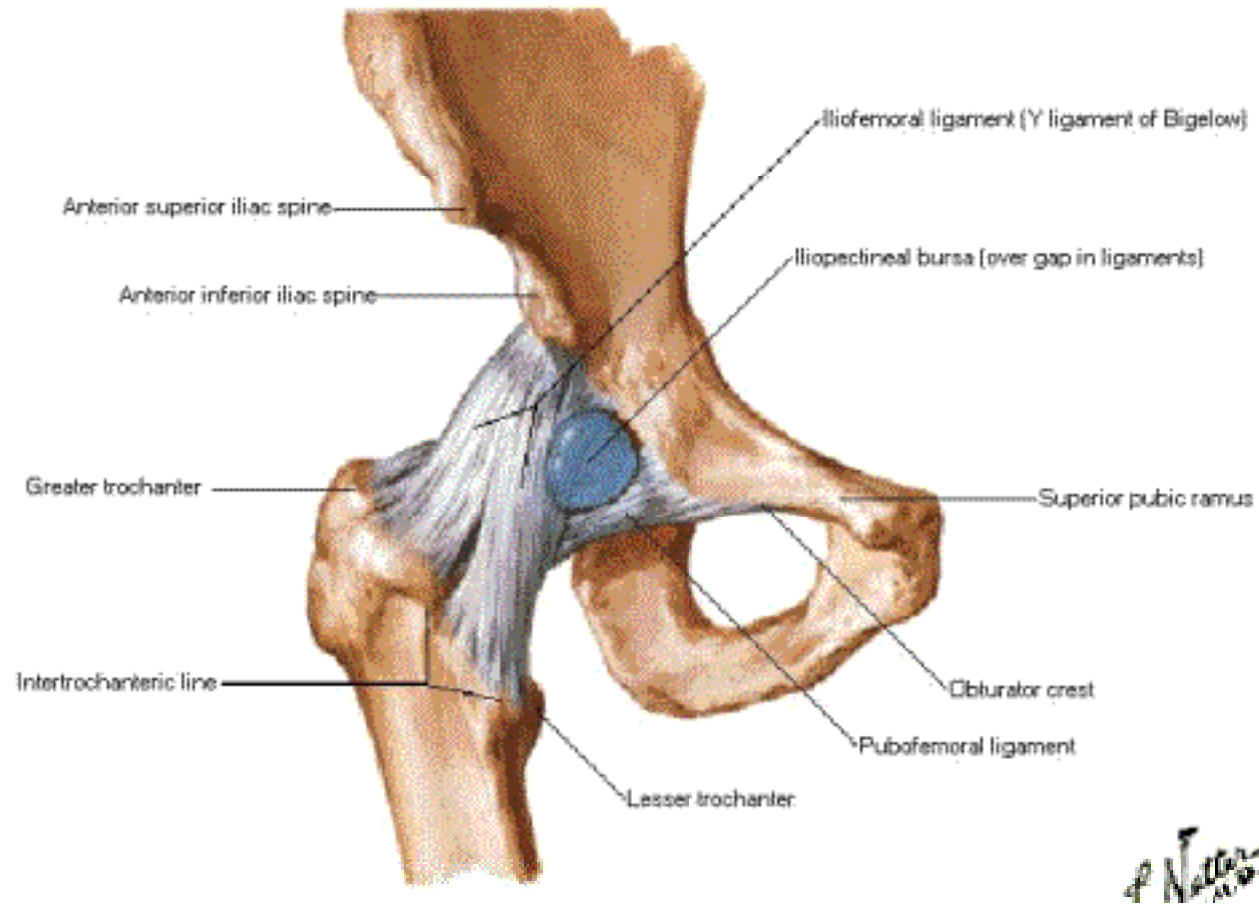
Medial View



F. Netter M.D.
 © Novartis

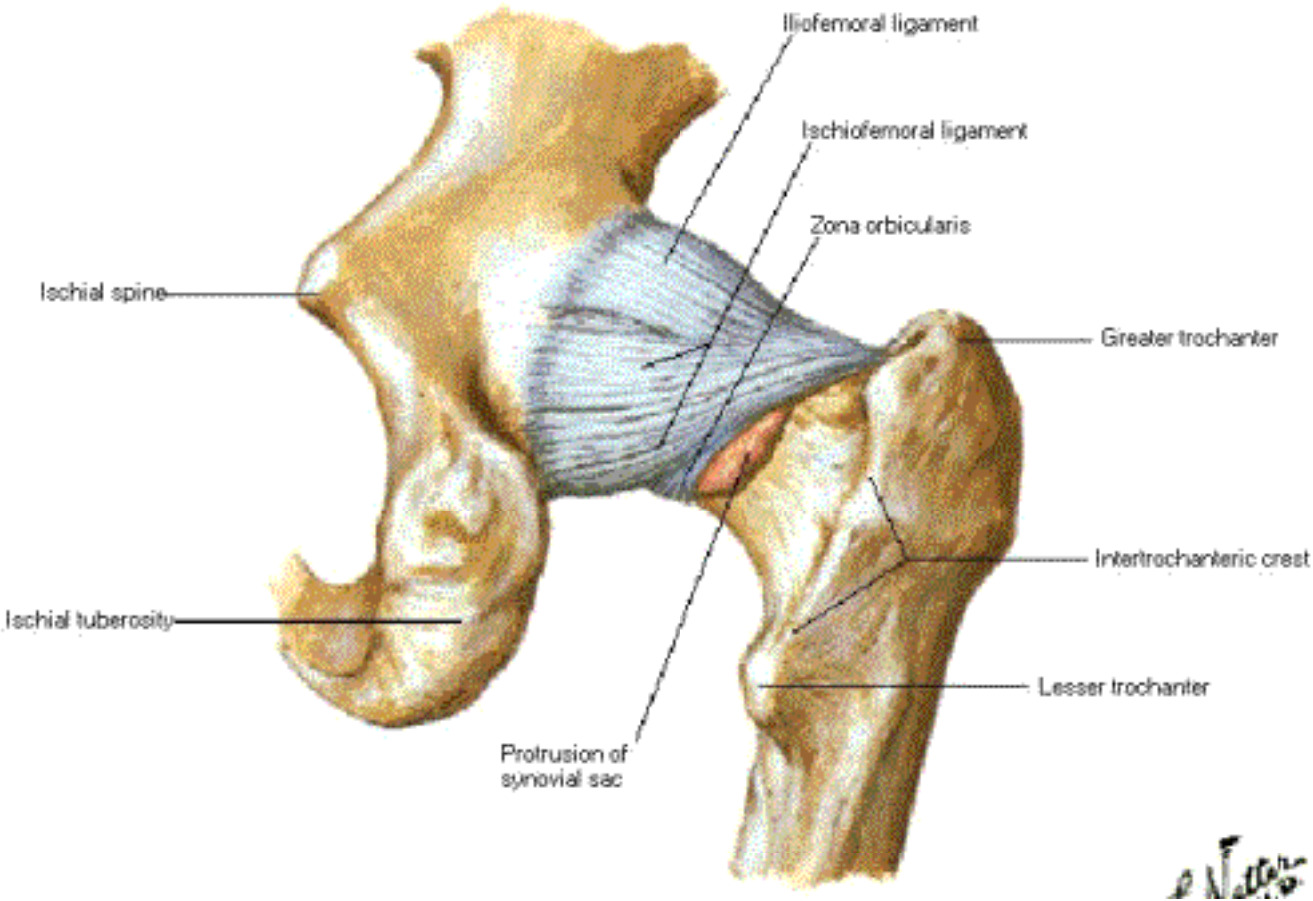
Hip Joint

Anterior View



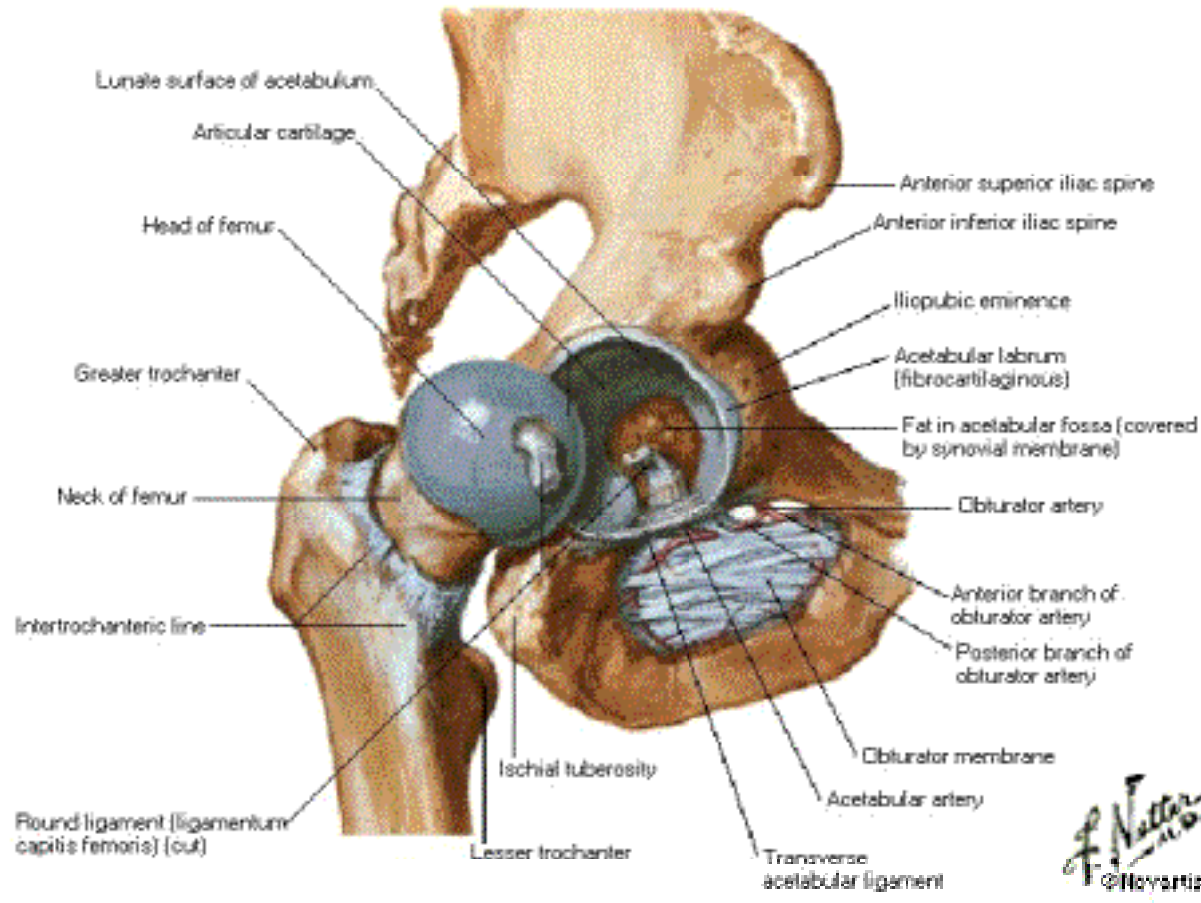
Hip Joint

Posterior View



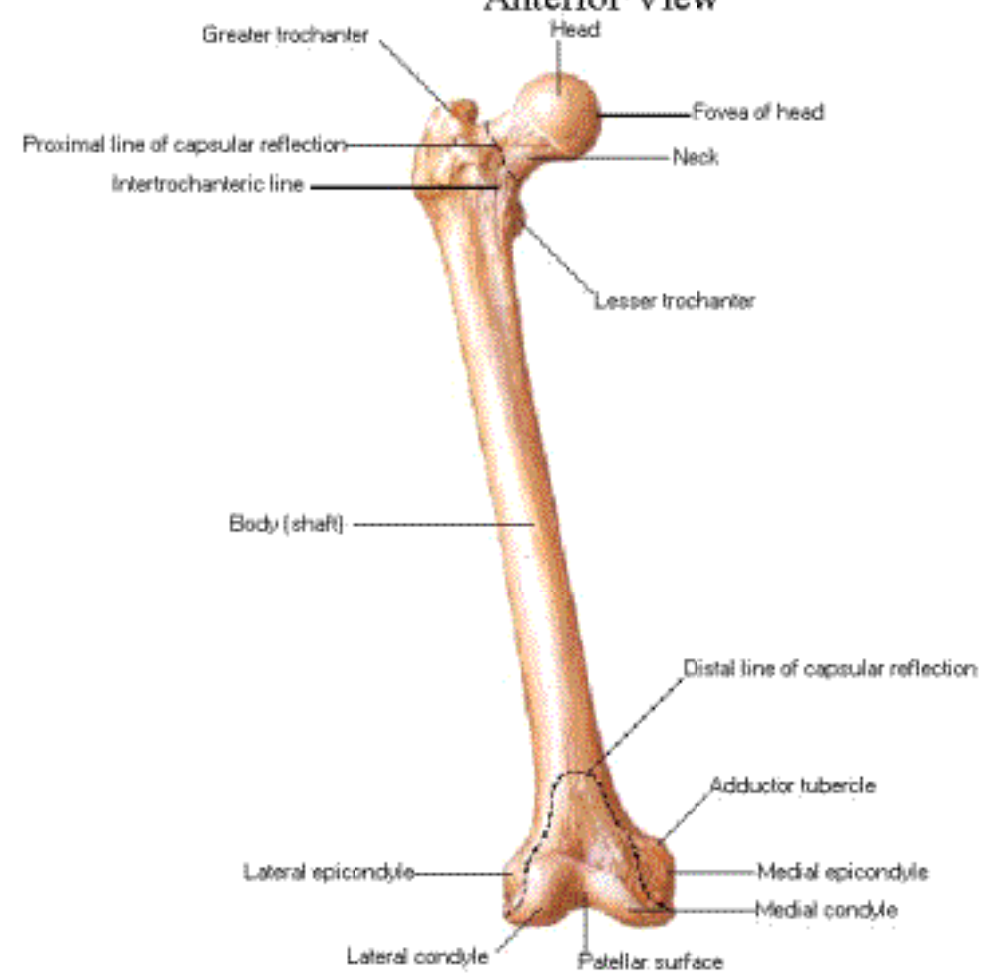
Hip Joint [Opened]

Lateral View



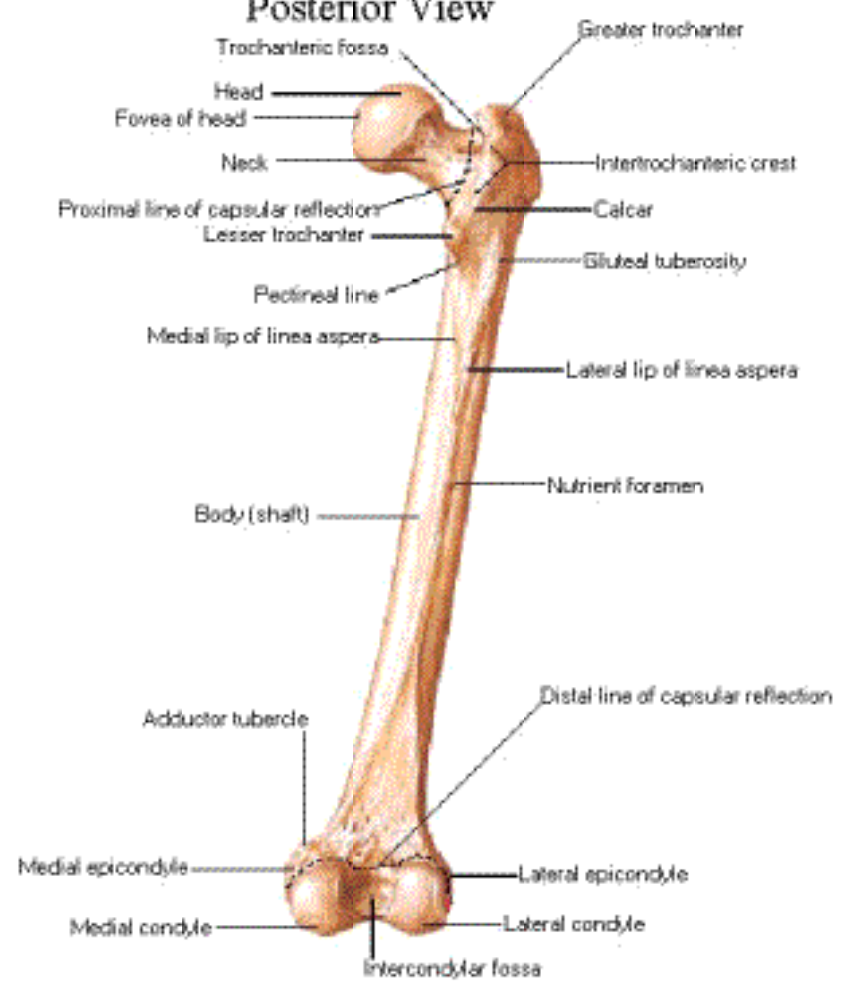
Femur

Anterior View



Femur

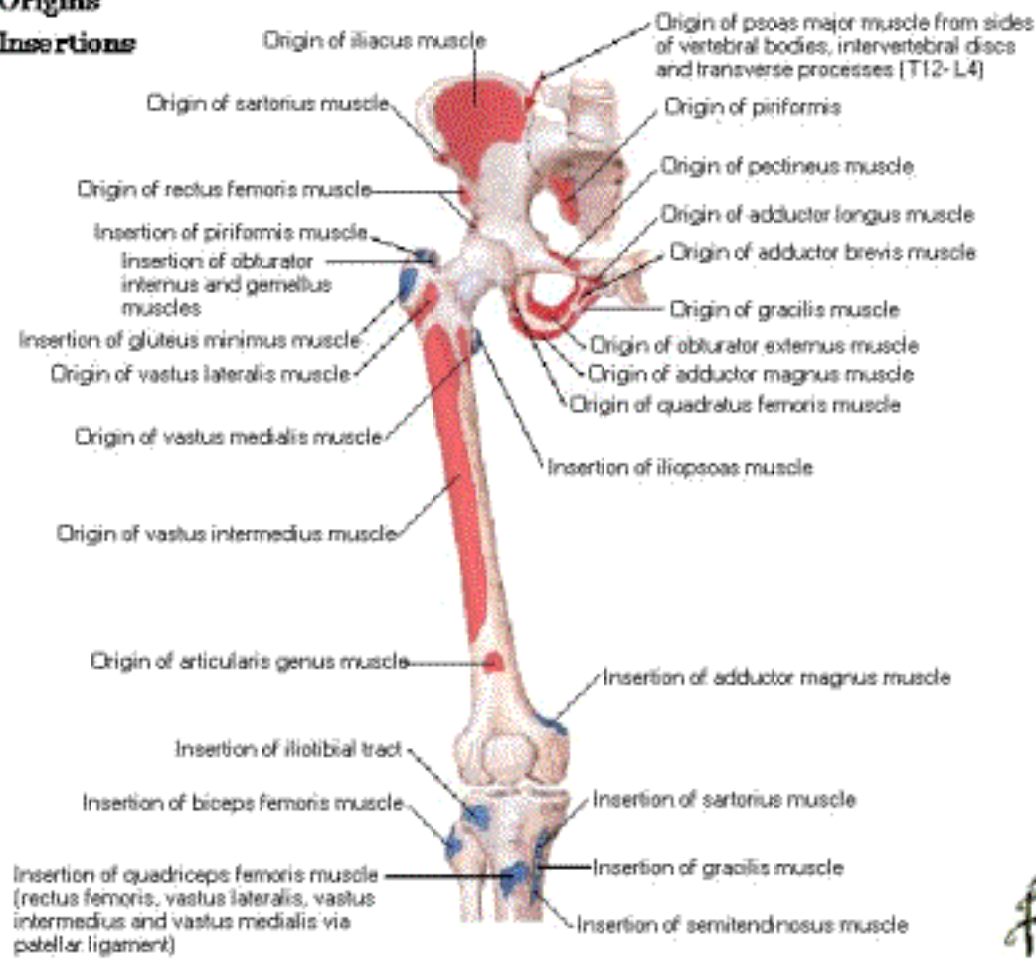
Posterior View



Bony Attachments of Muscles of Hip and Thigh

Origins
Insertions

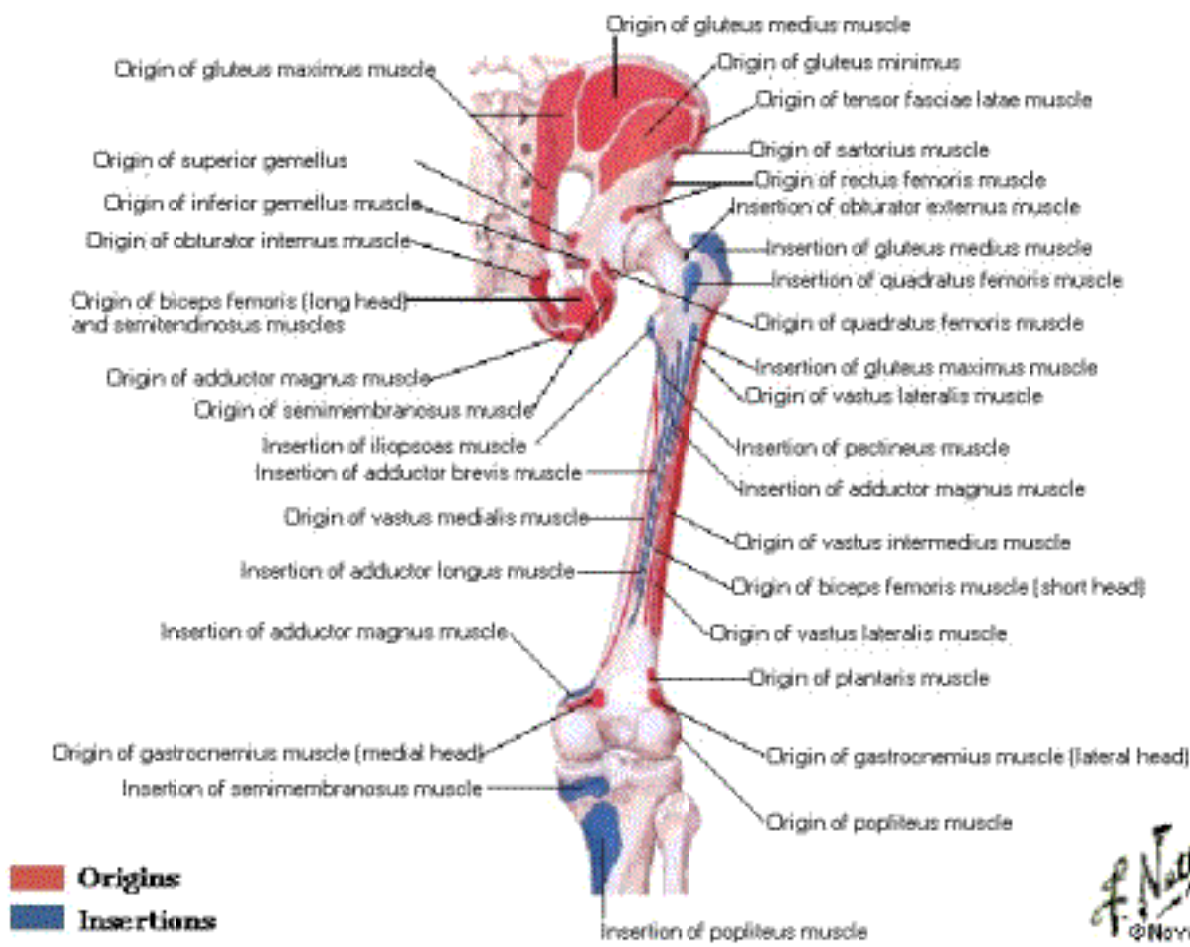
Anterior View



f

Bony Attachments of Muscles of Hip and Thigh

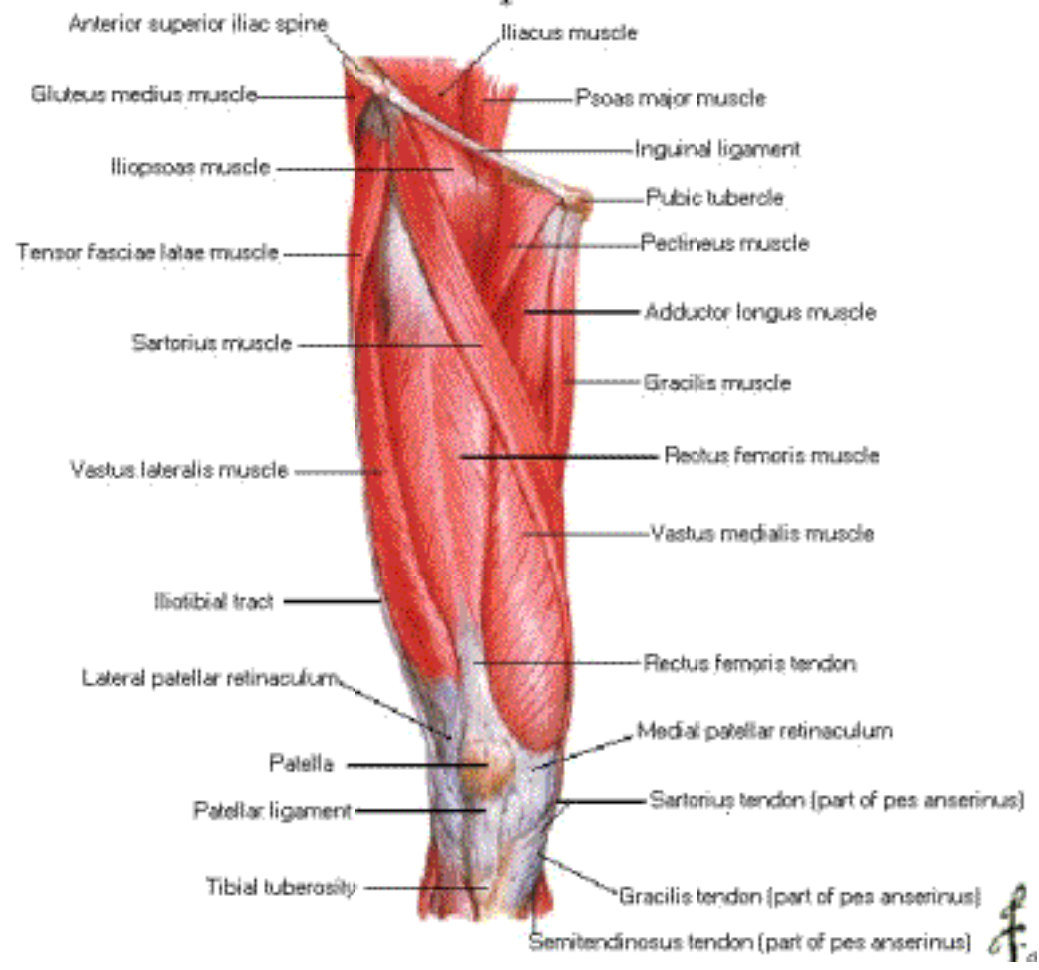
Posterior View



F. Netter
© Nova

Muscles of Thigh

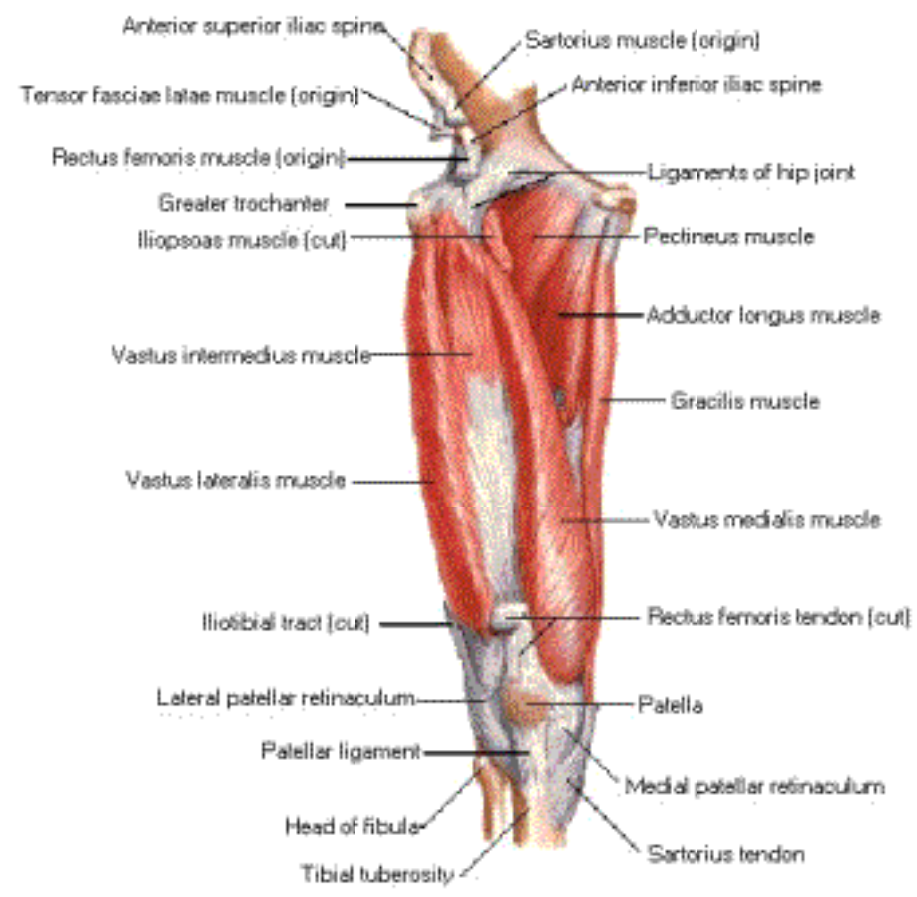
Anterior View - Superficial Dissection



i@

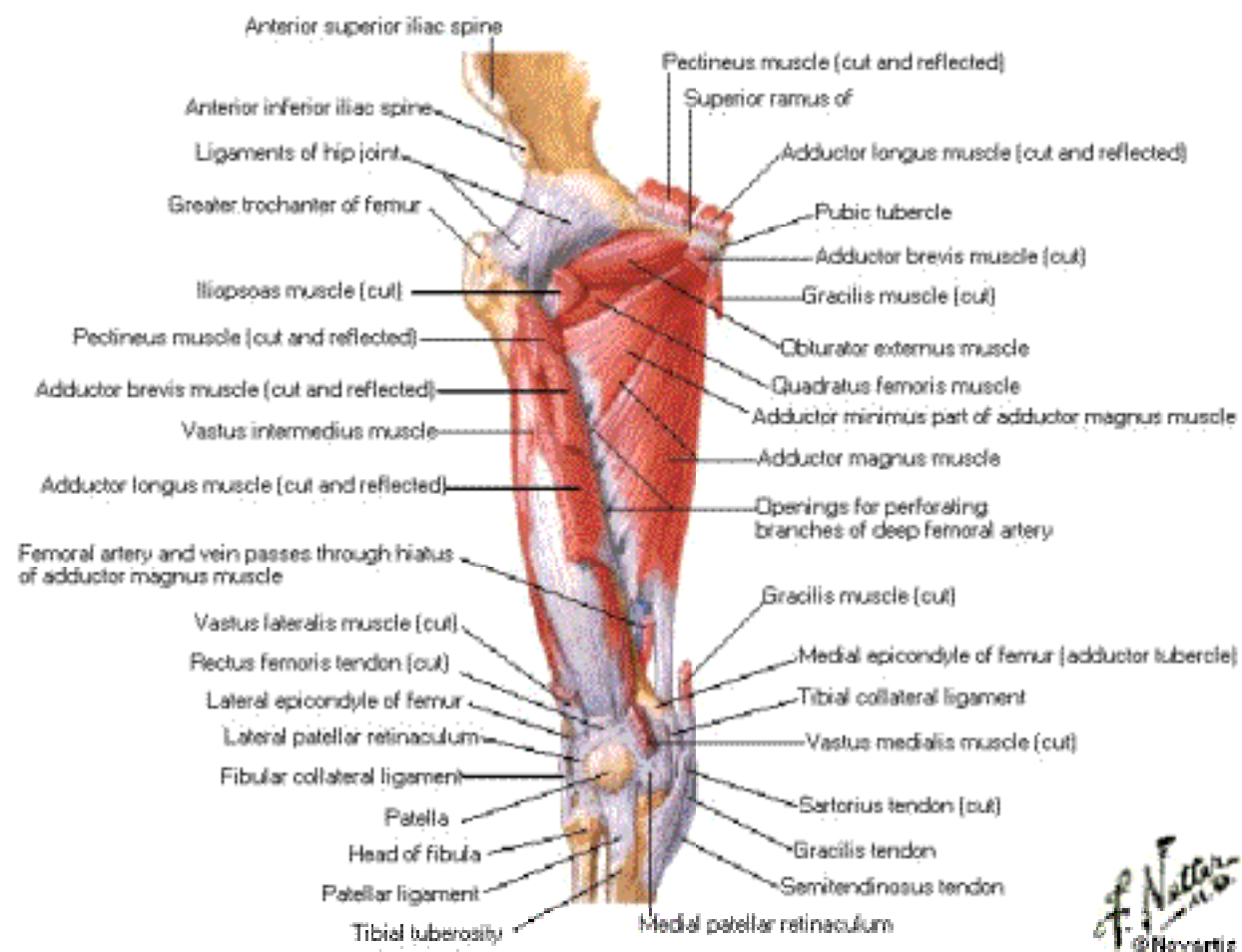
Muscles of Thigh

Anterior View - Deeper Dissection



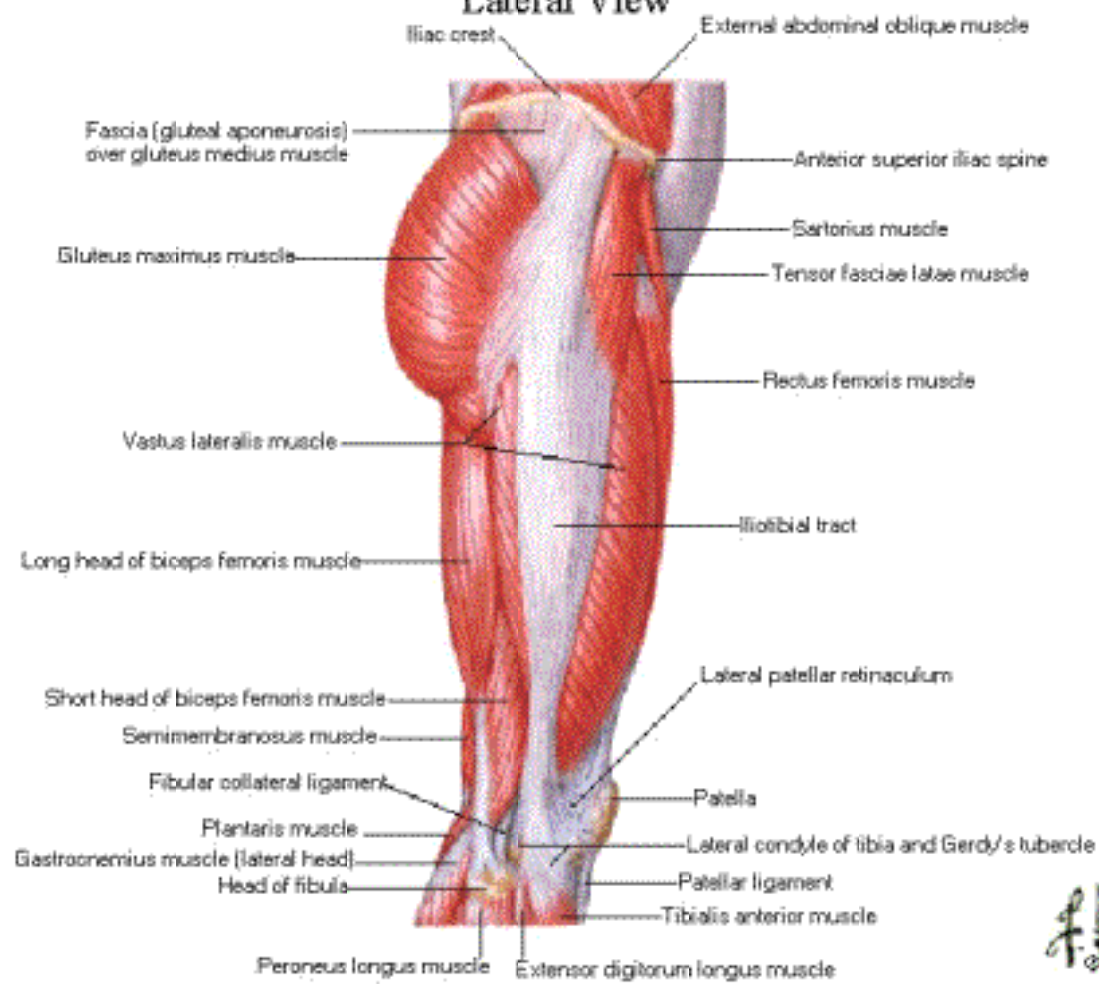
Muscles of Thigh

Anterior View - Deepest Dissection



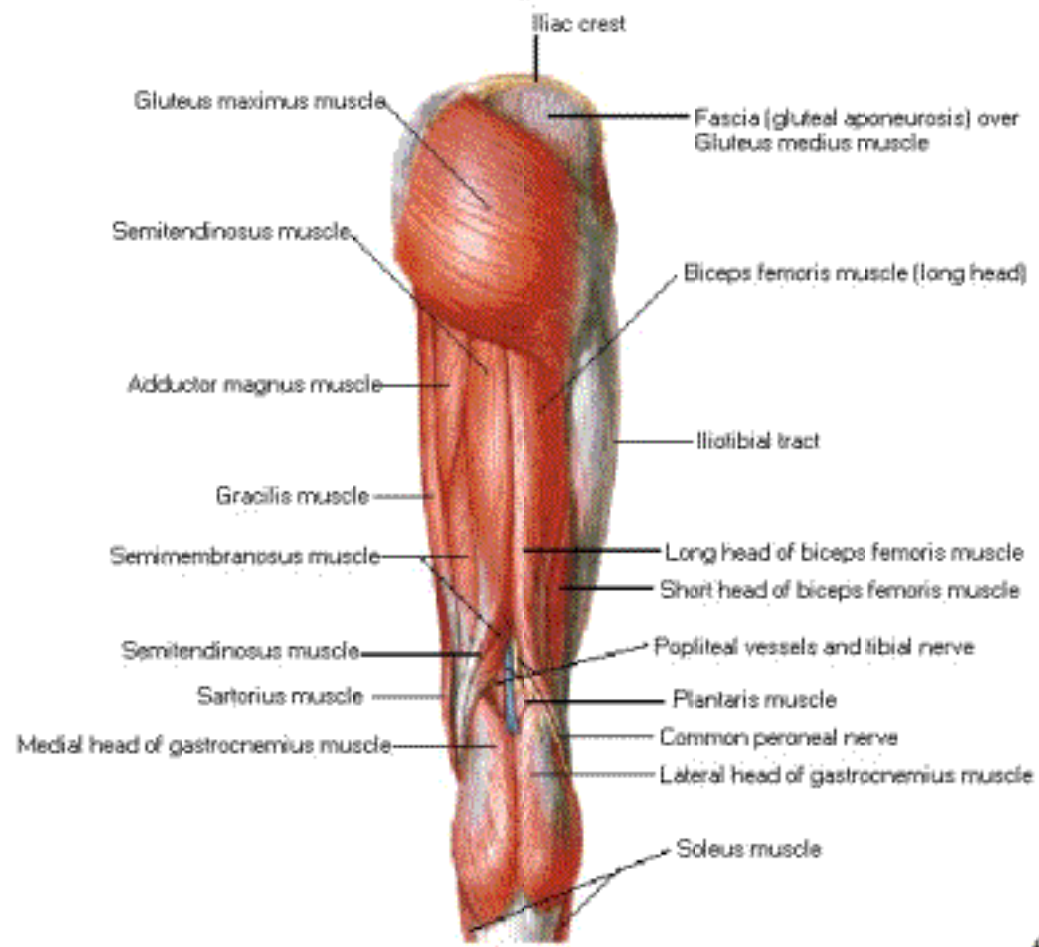
Muscles of Hip and Thigh

Lateral View



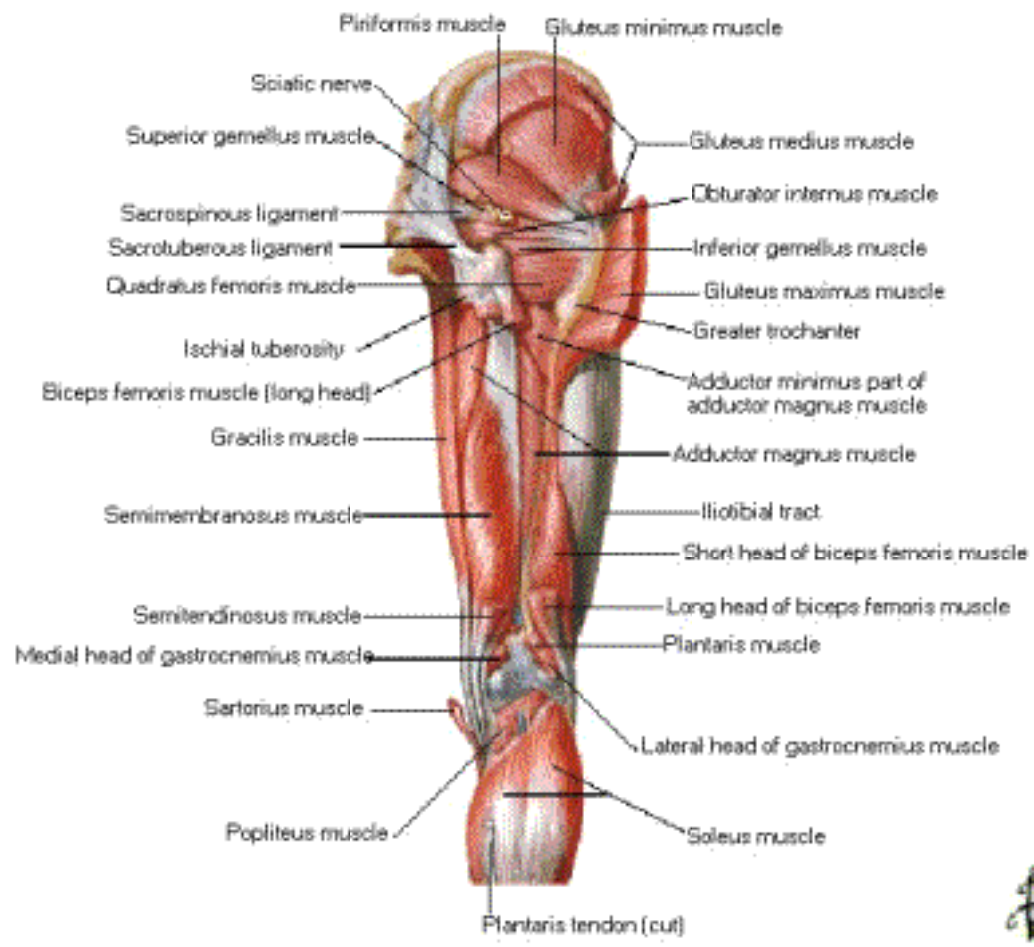
Muscles of Hip and Thigh

Posterior View - Superficial Dissection



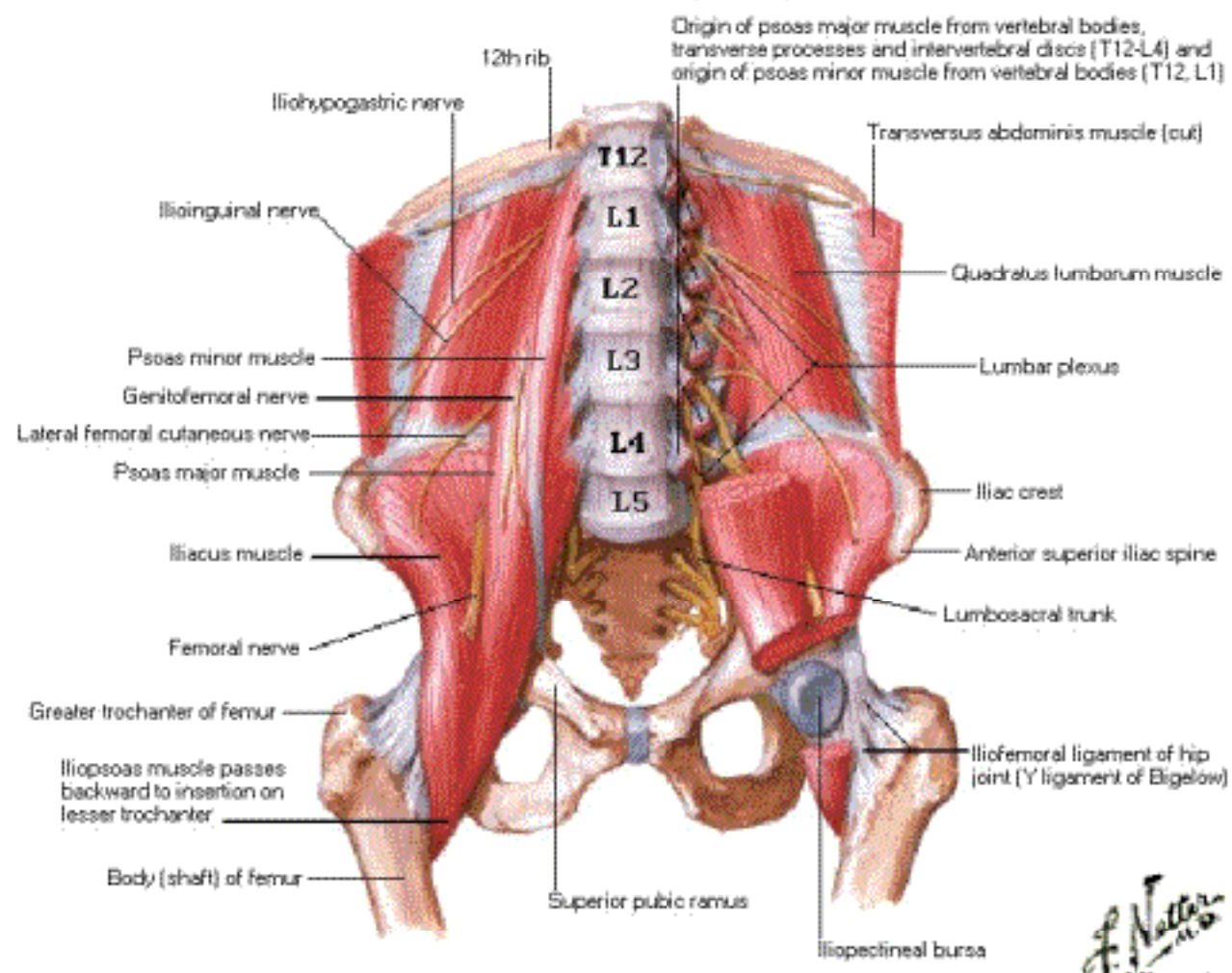
Muscles of Hip and Thigh

Posterior View - Deeper Dissection



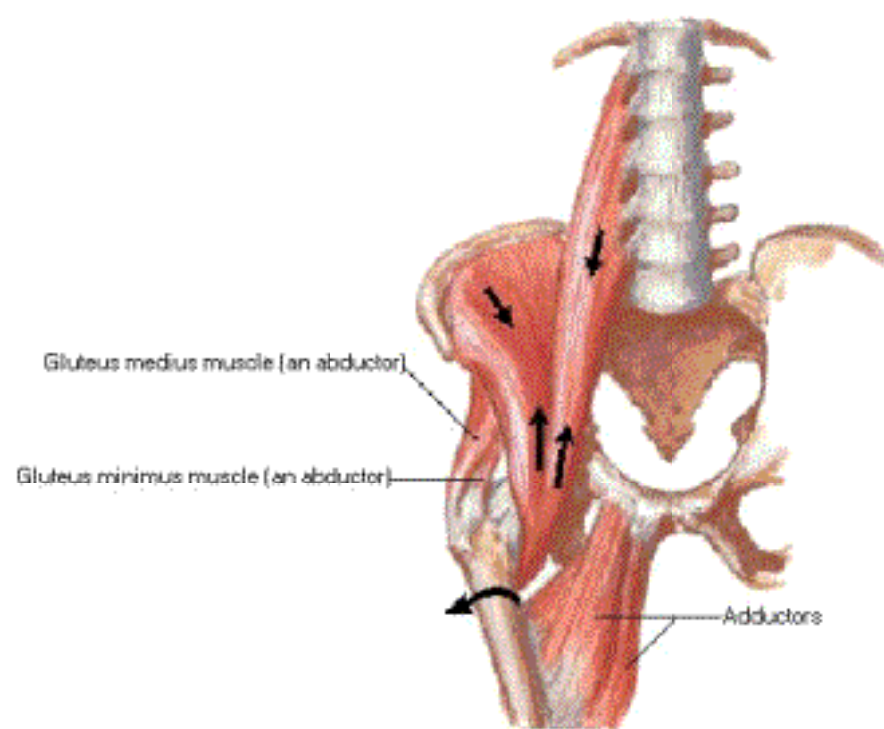
24

Psoas and Iliacus Muscles



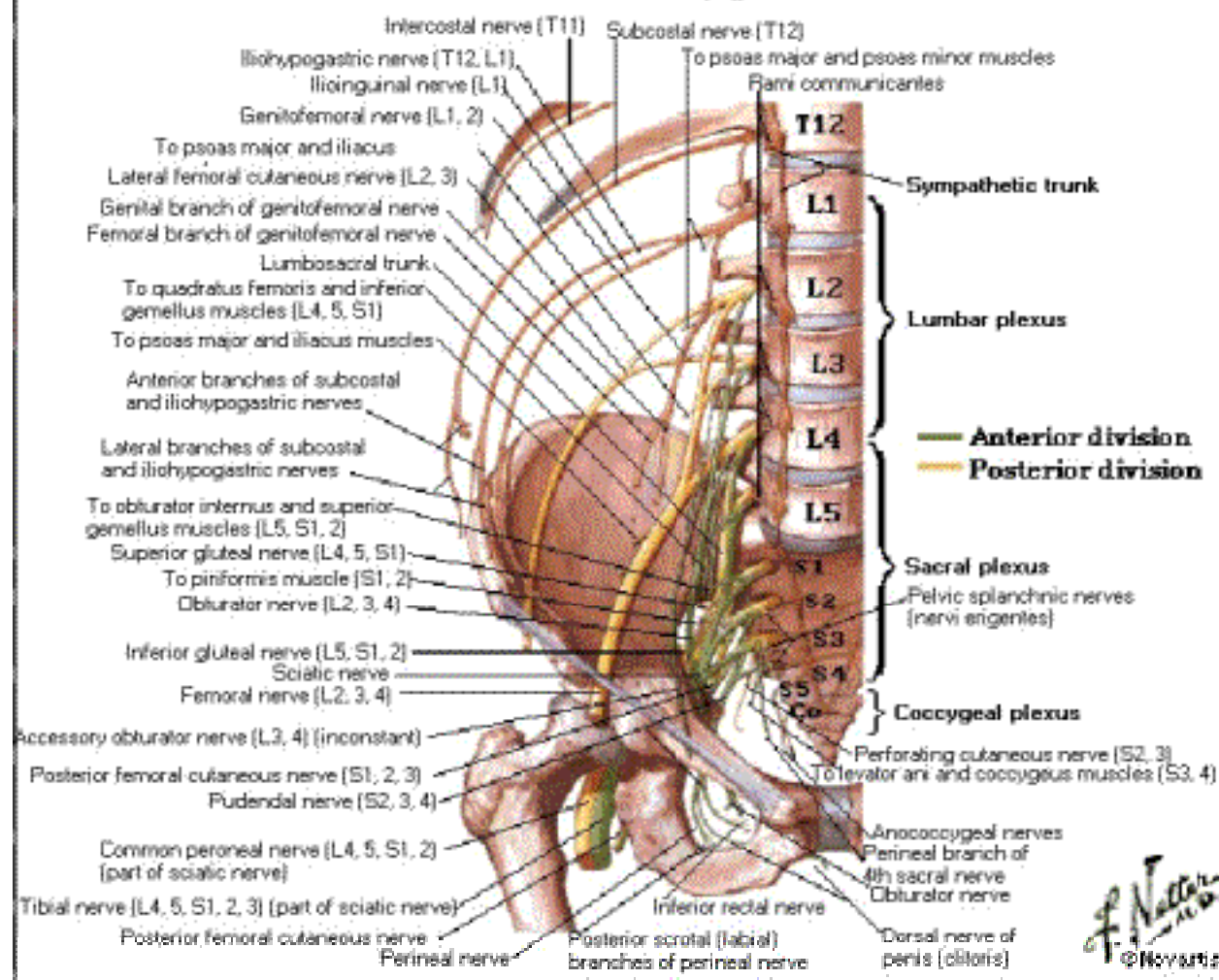
Psoas and Iliacus Muscles

Action

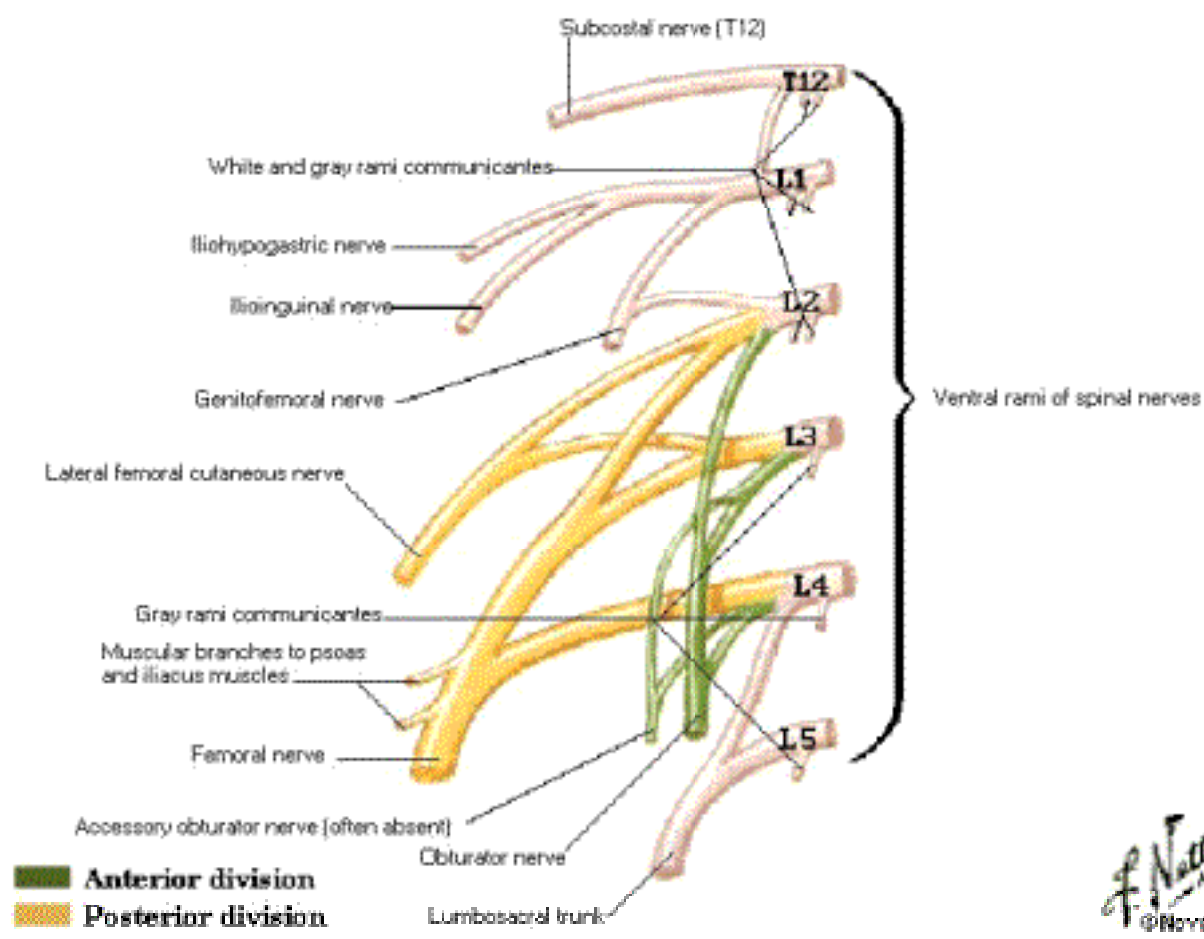


Note: arrows indicate direction of action of iliopsoas muscle

Lumbosacral and Coccygeal Plexuses

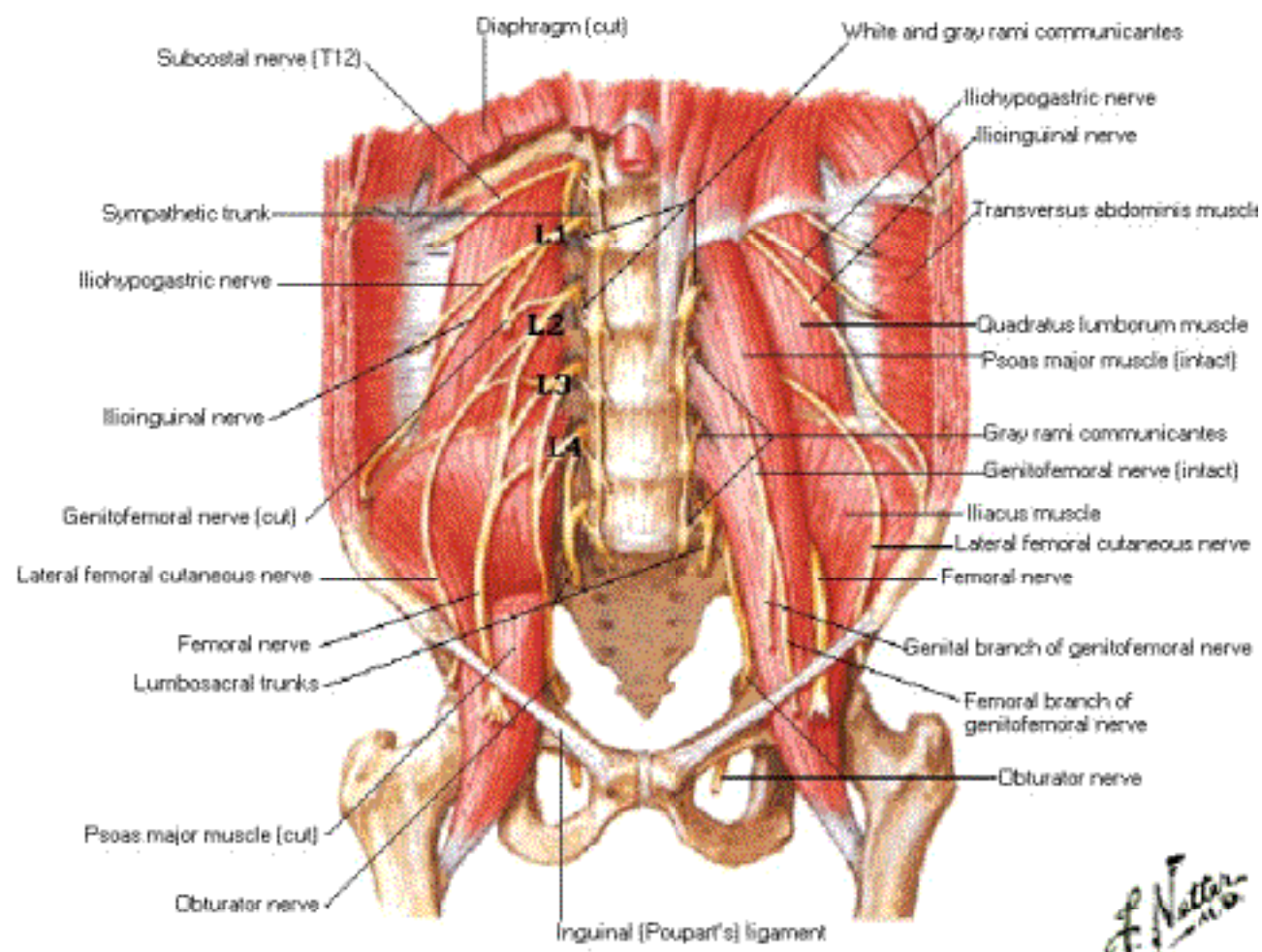


Lumbar Plexus Schema

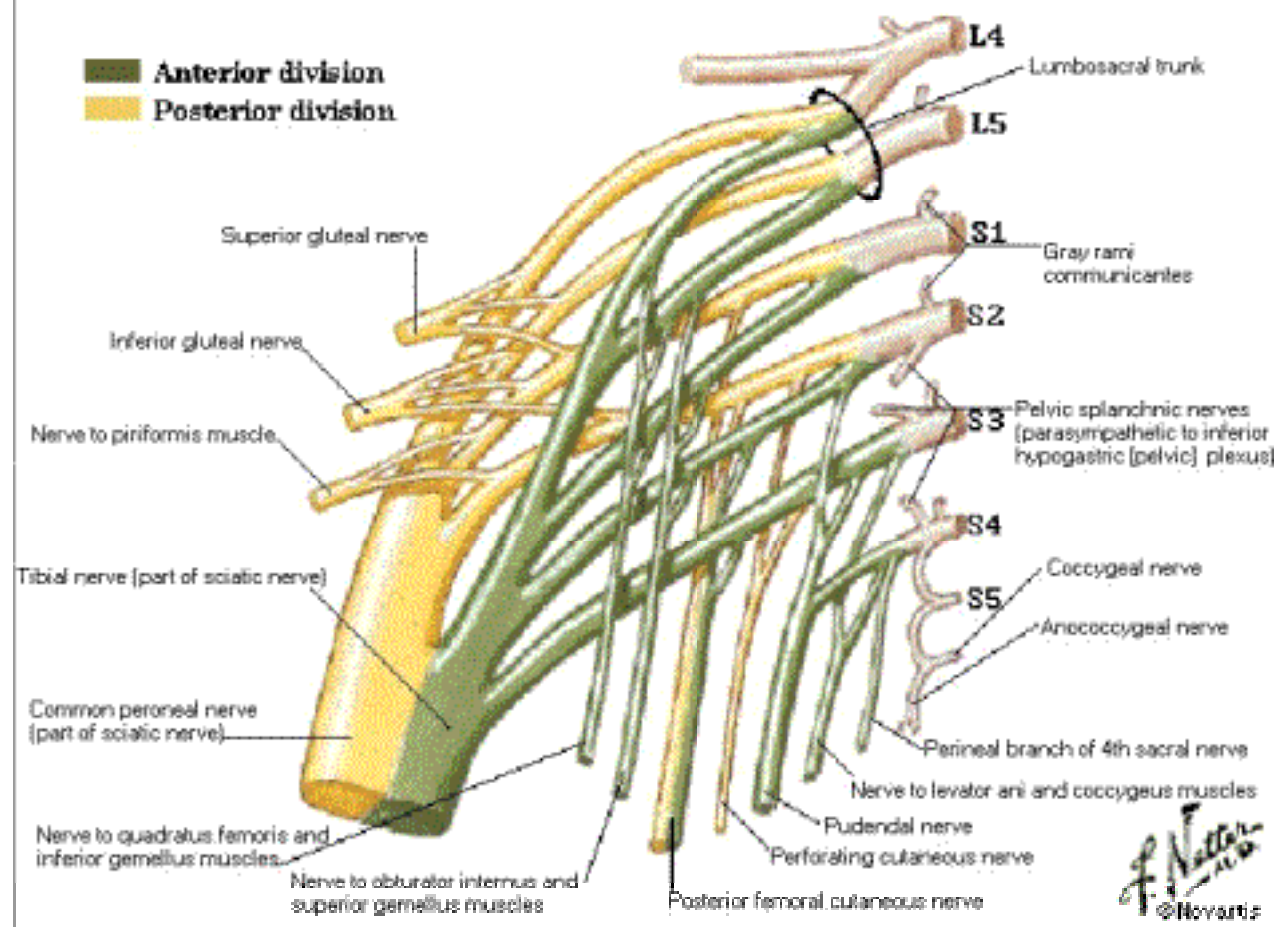


f. Naga
©Nova

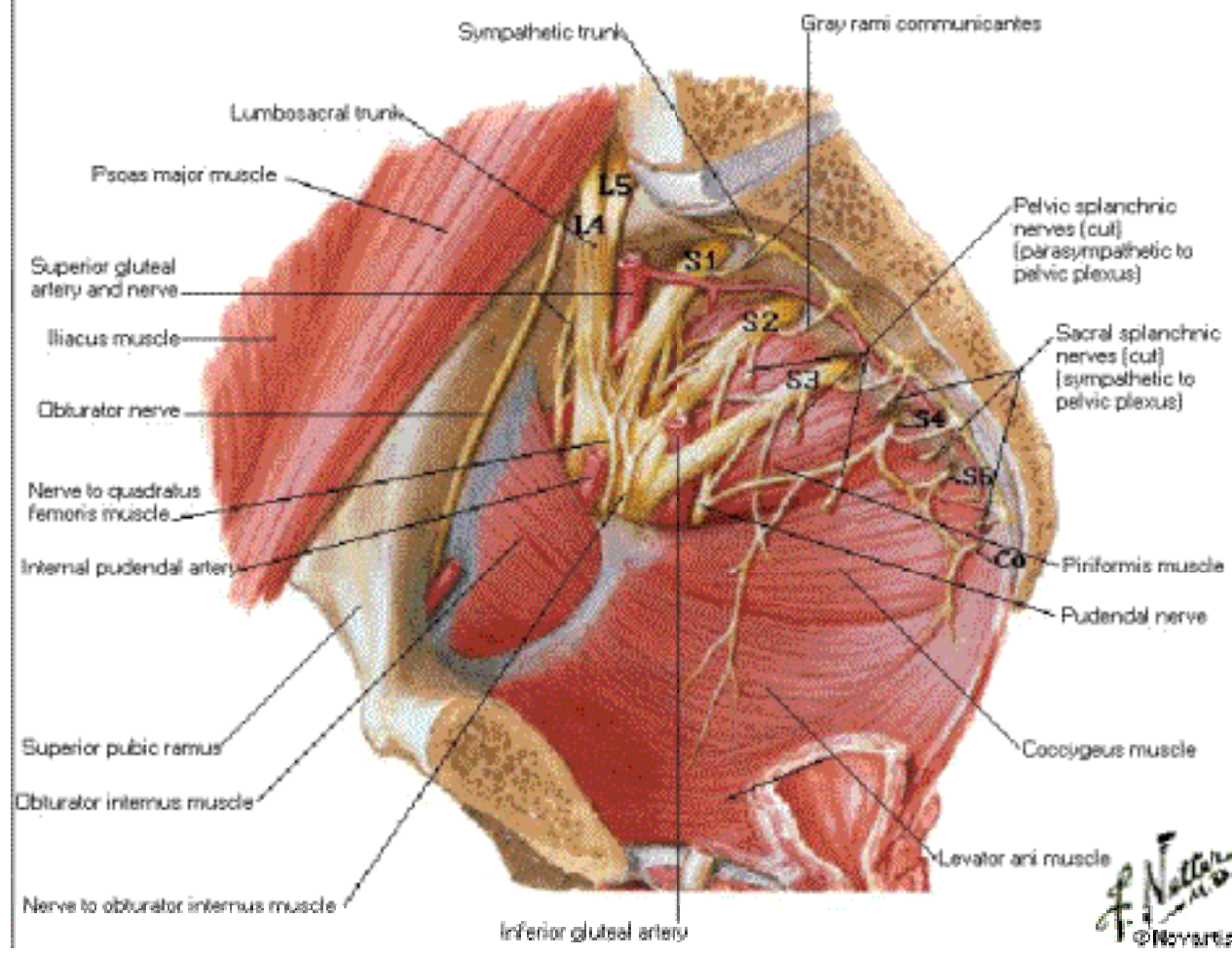
Lumbar Plexus in Situ



Sacral and Coccygeal Plexuses Schema

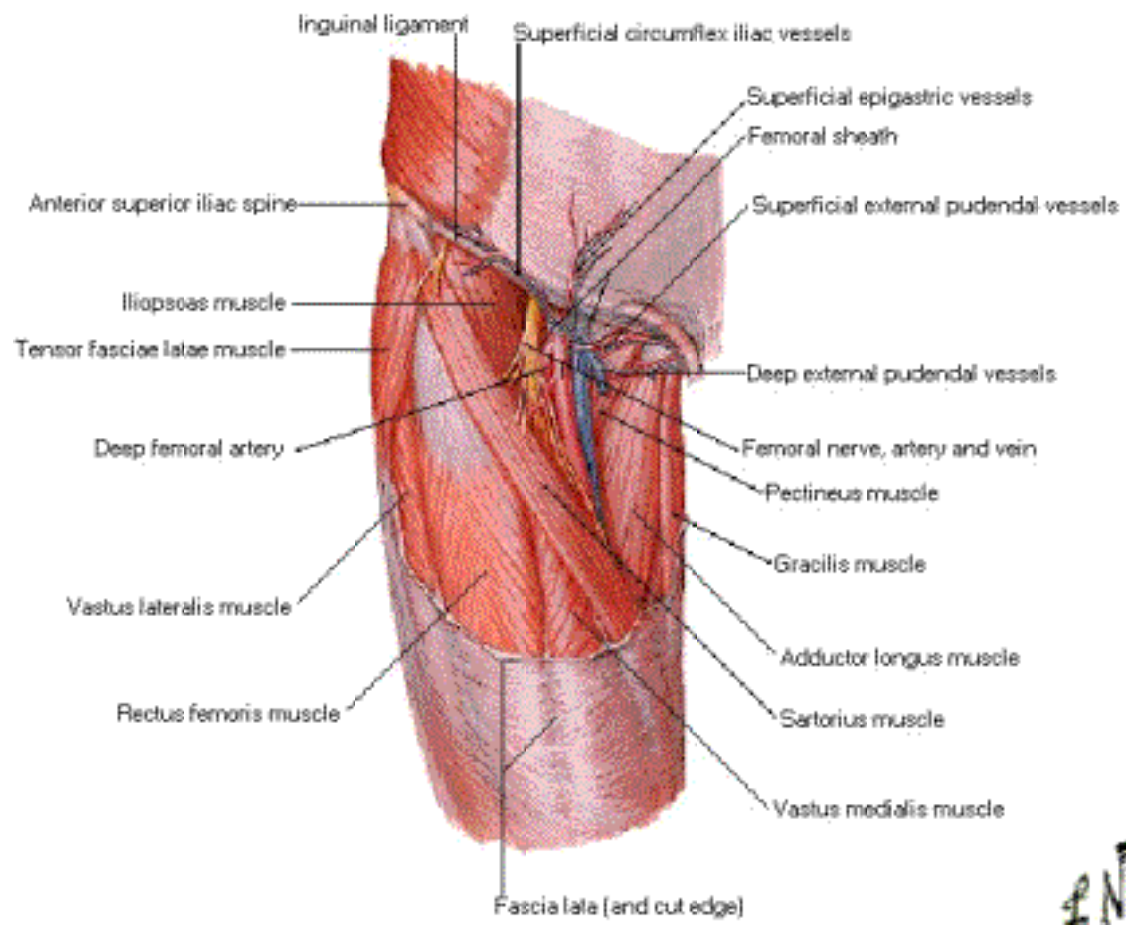


Sacral and Coccygeal Plexuses in Situ



Arteries and Nerves of Thigh

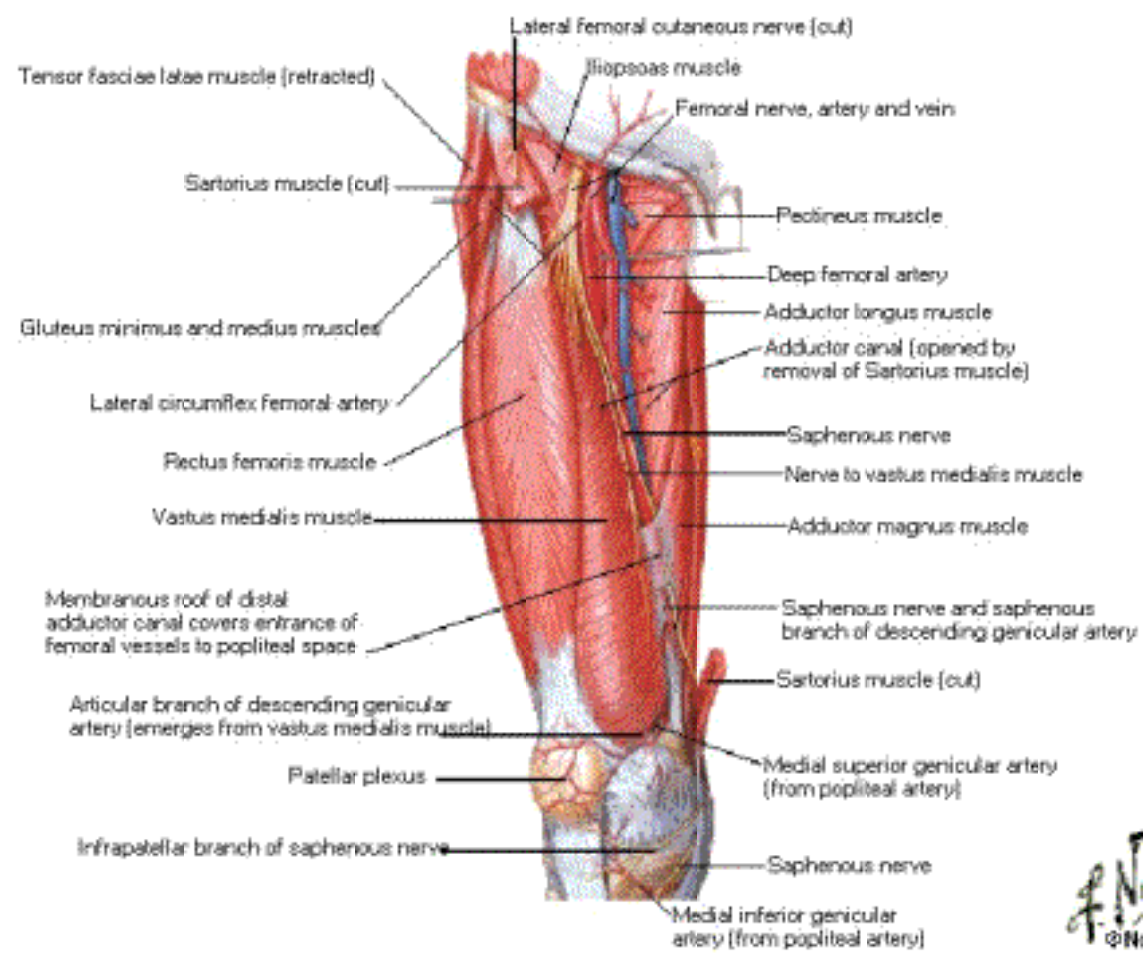
Superficial Anterior View



EN

Arteries and Nerves of Thigh

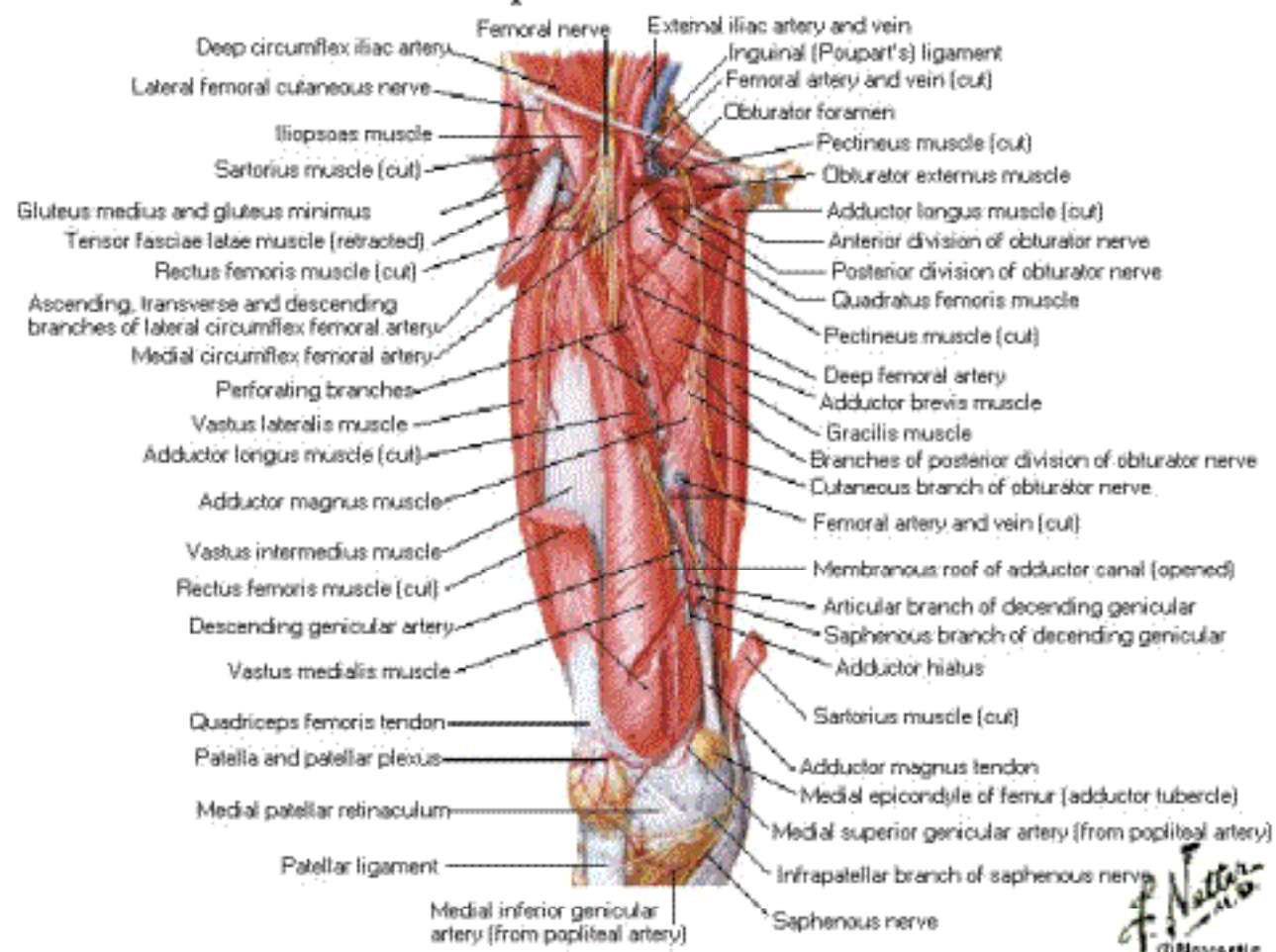
Deeper Anterior View



FN
ON

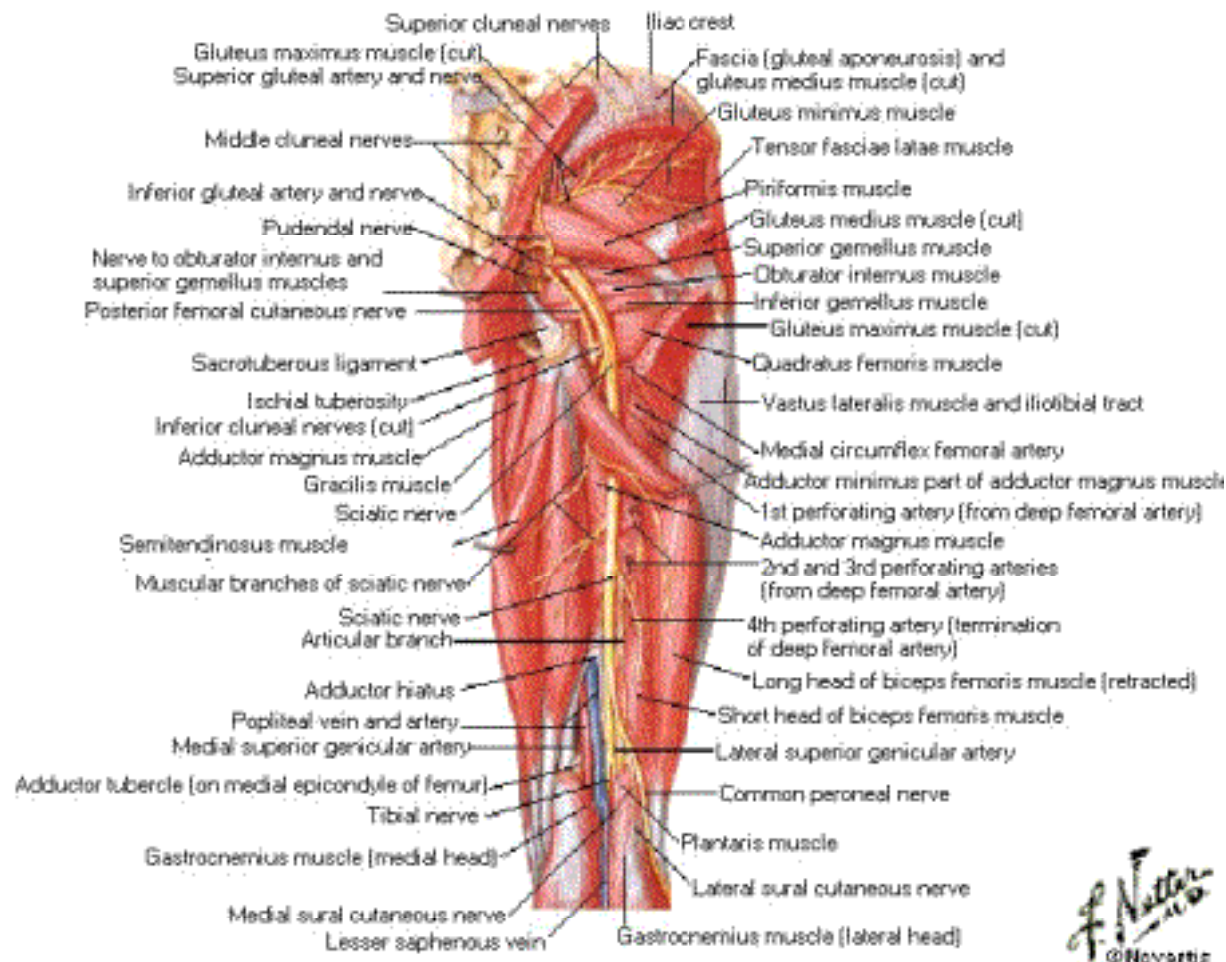
Arteries and Nerves of Thigh

Deepest Anterior View

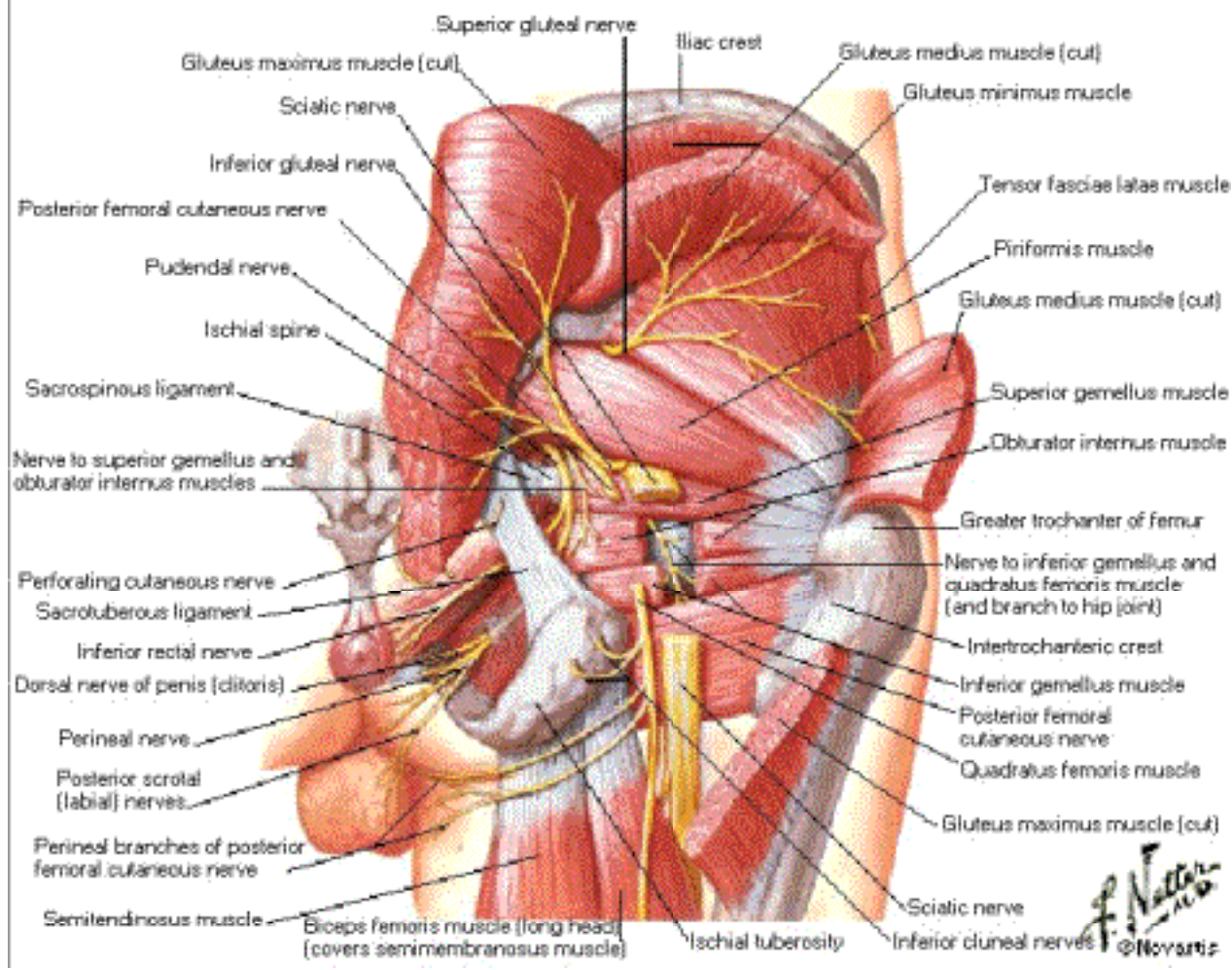


Arteries and Nerves of Thigh

Posterior View

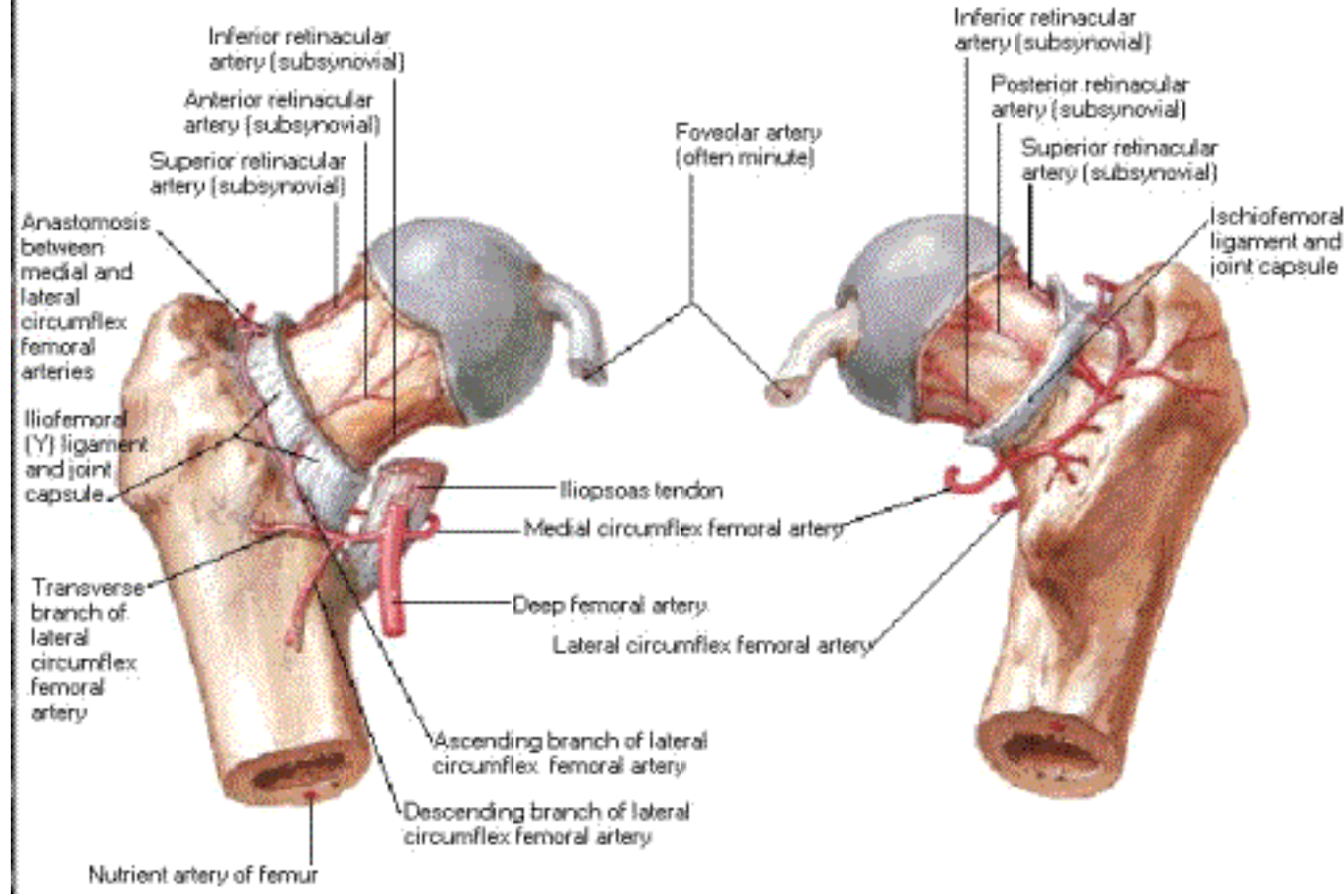


Nerves of Hip and Buttock



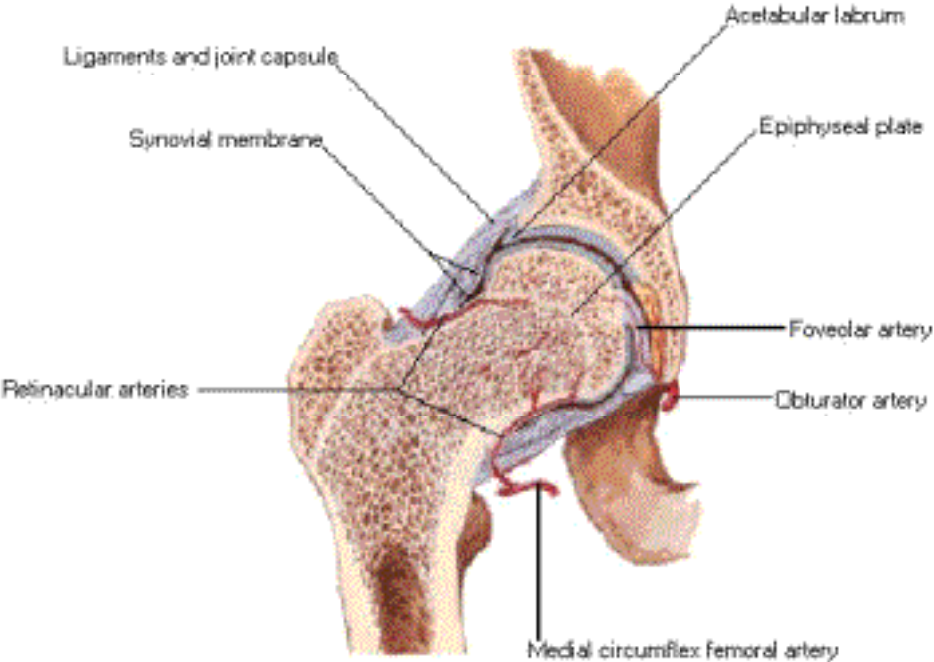
Arteries of Femoral Head and Neck

Anterior and Posterior Views



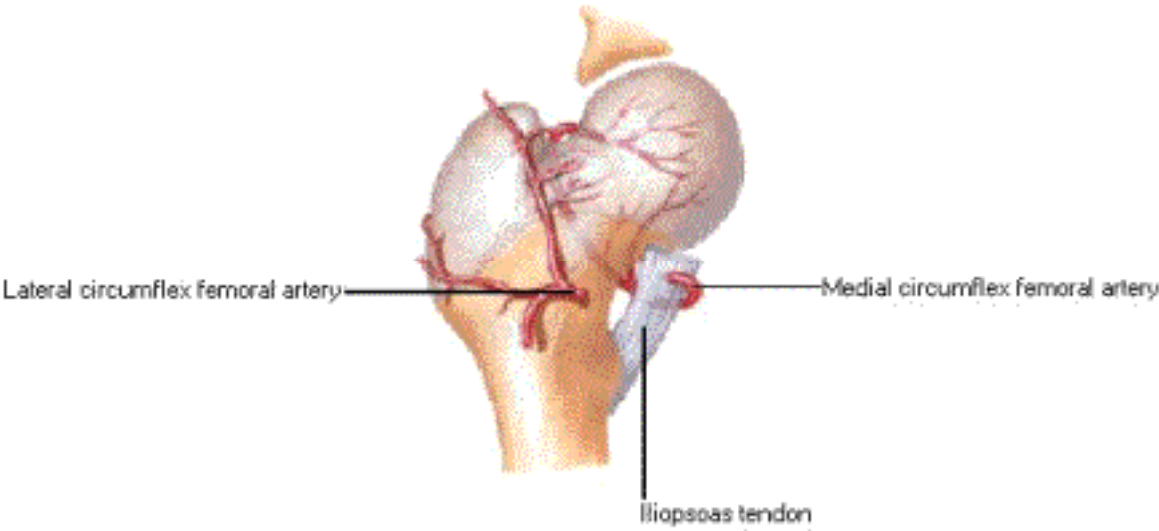
Arteries of Femoral Head and Neck

Coronal Section



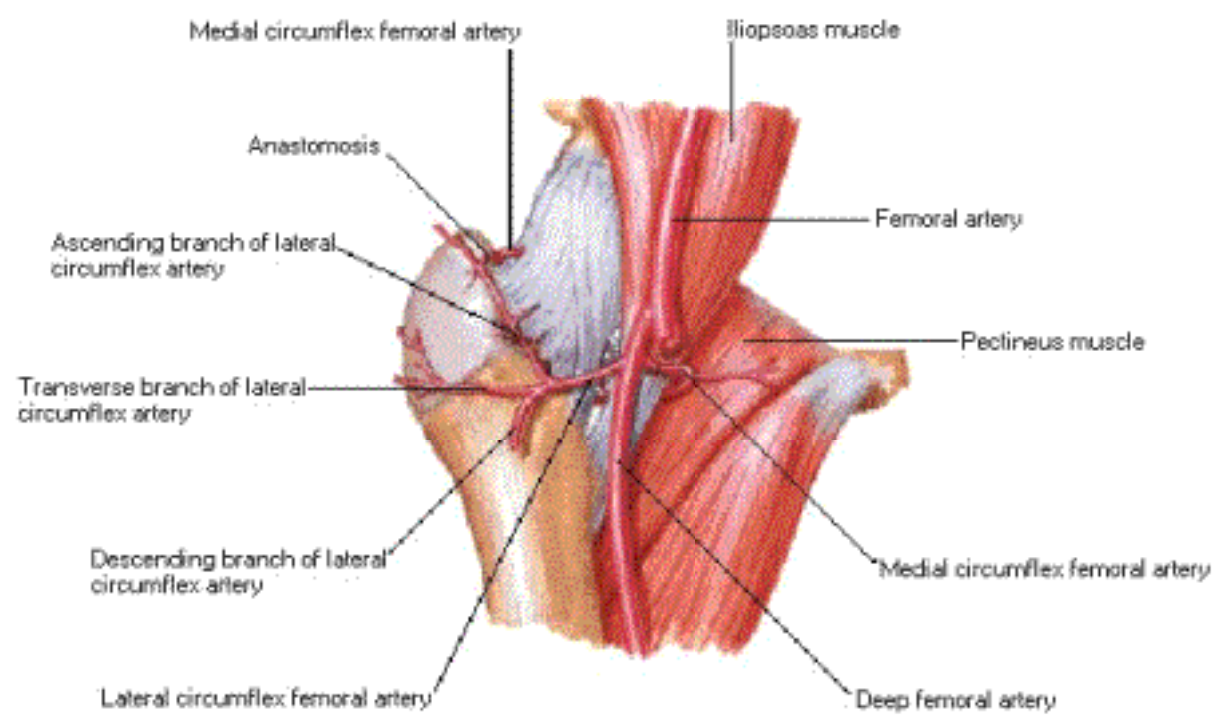
Arteries of Femoral Head and Neck

Femur of Child - Anterior View



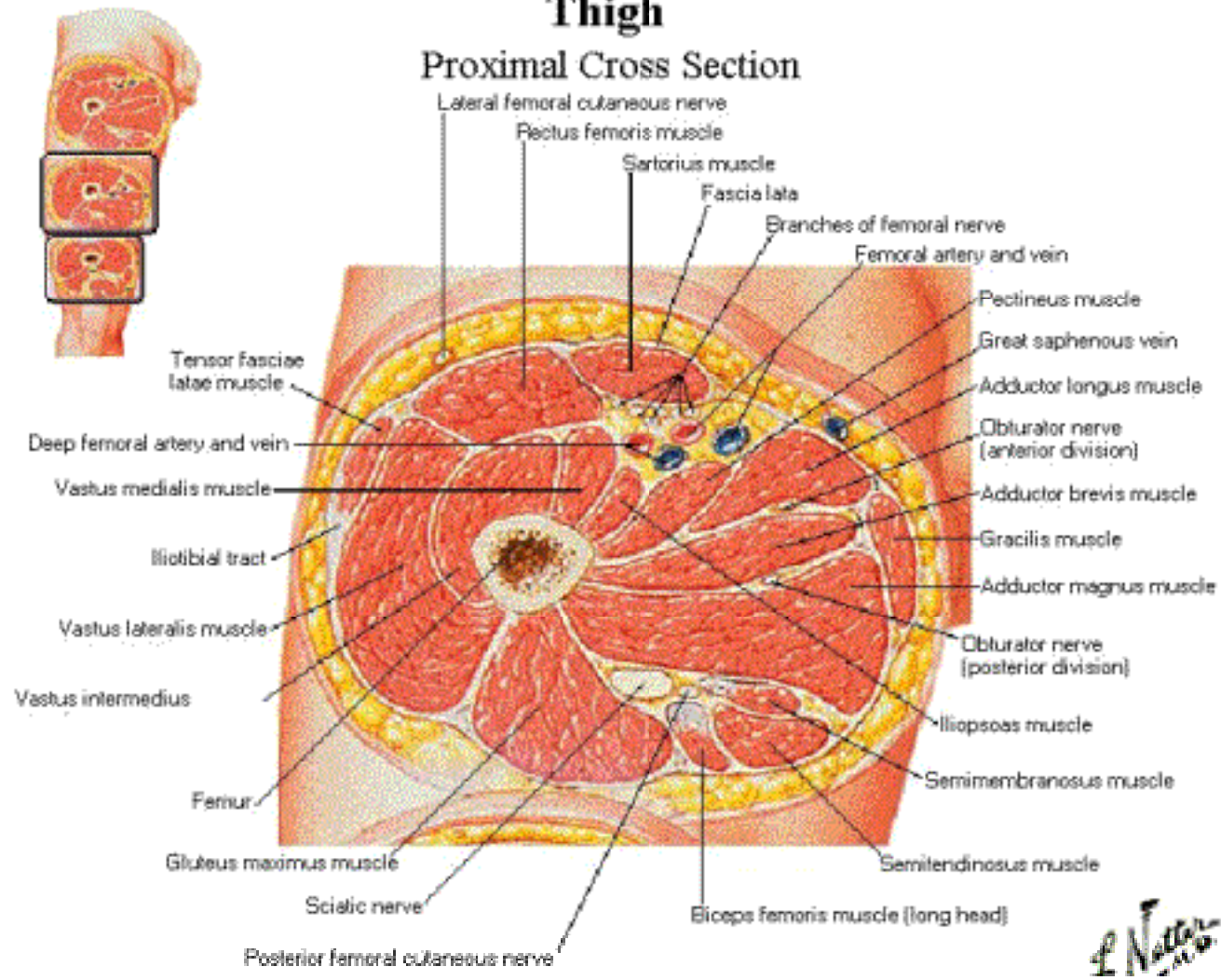
Arteries of Femoral Head and Neck

Anterior View in Situ



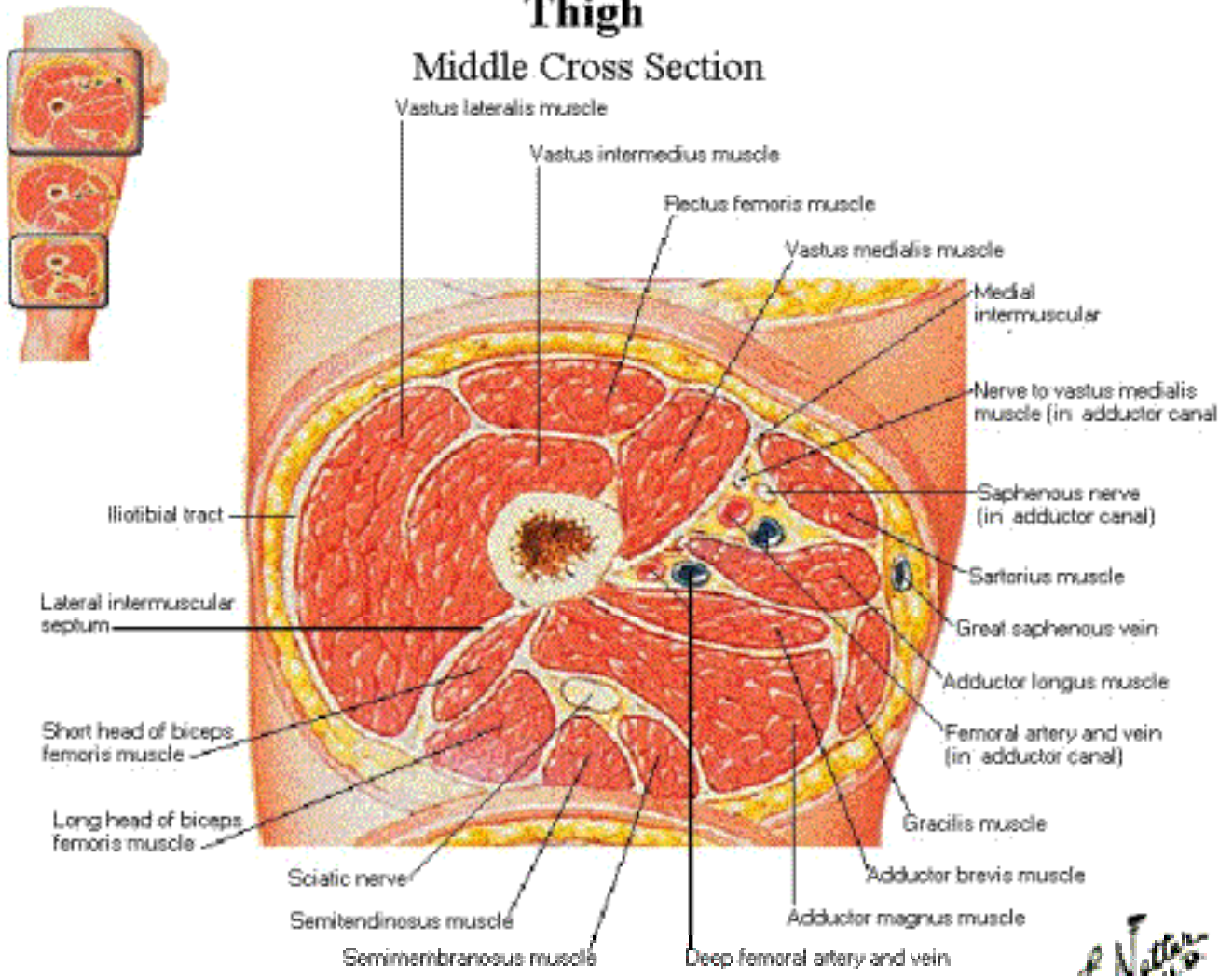
Thigh

Proximal Cross Section



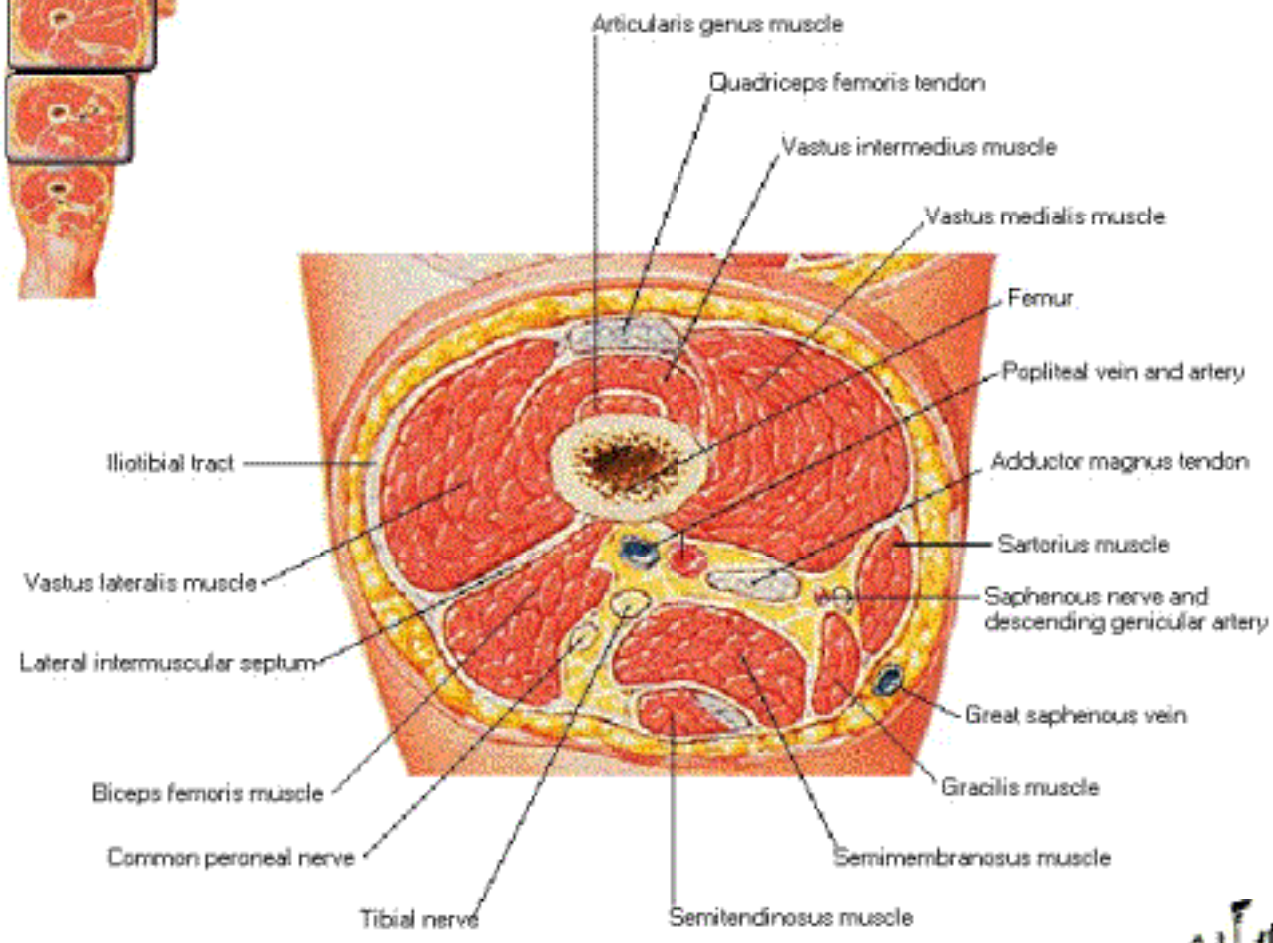
Thigh

Middle Cross Section



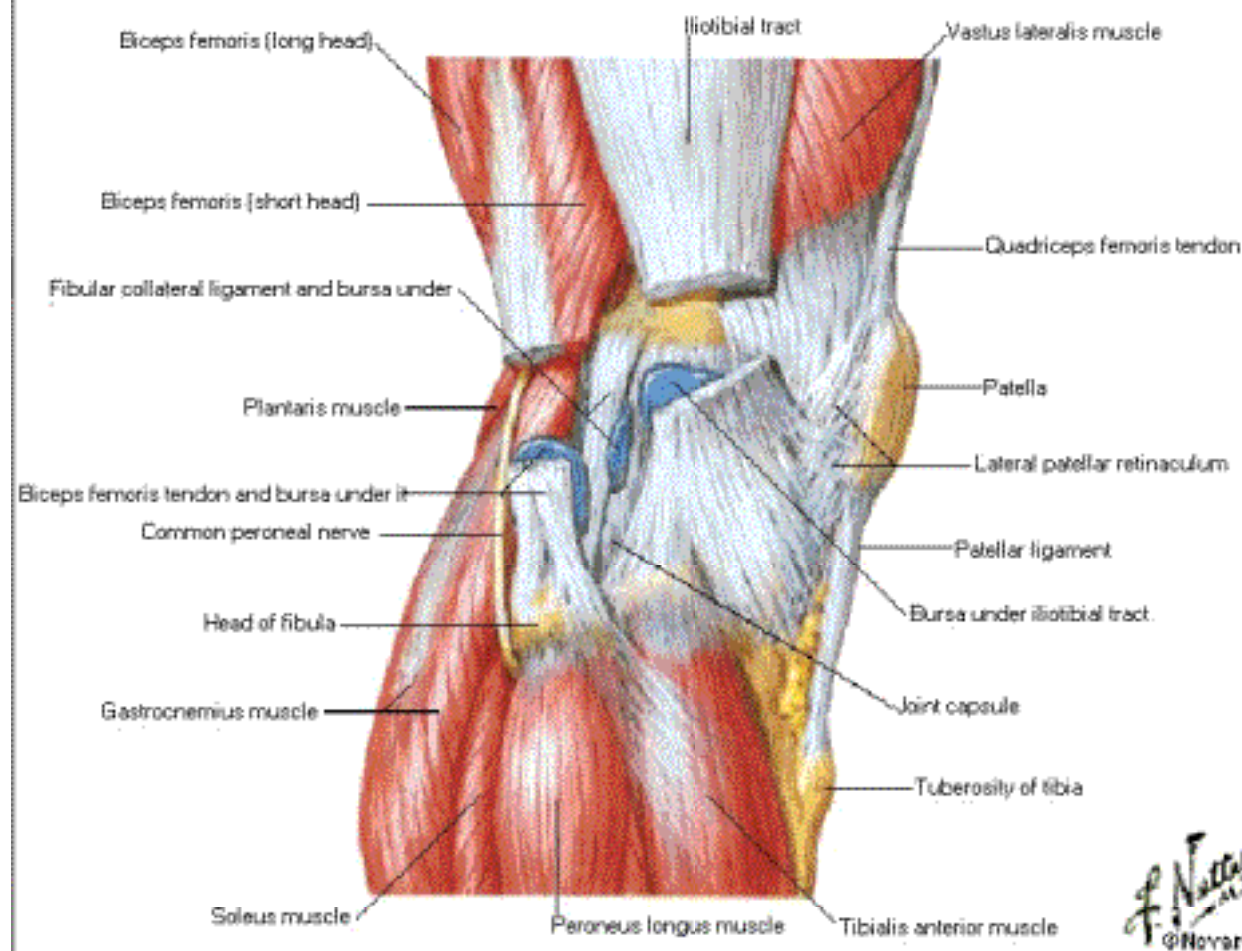
Thigh

Distal Cross Section



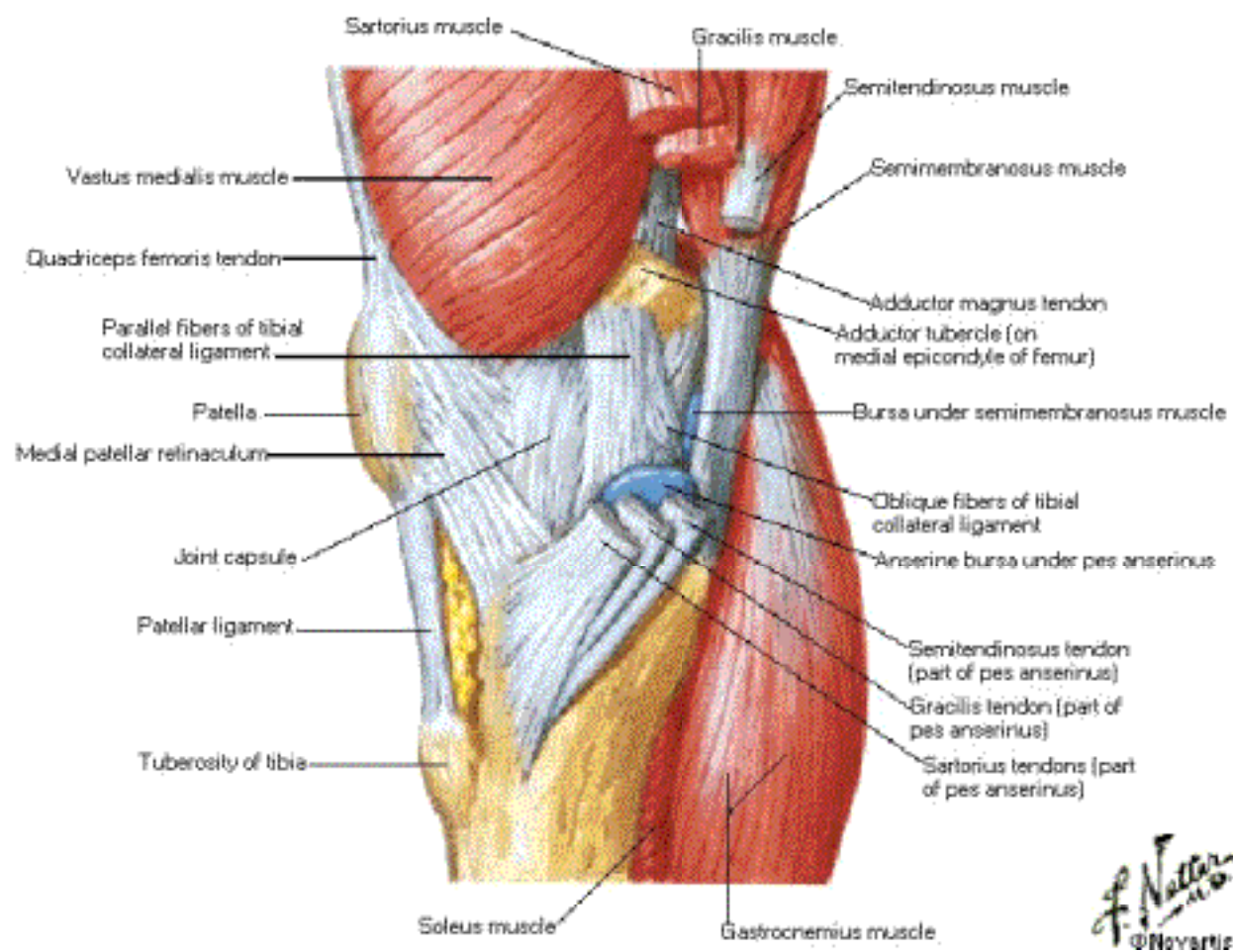
Knee

Lateral View



Knee

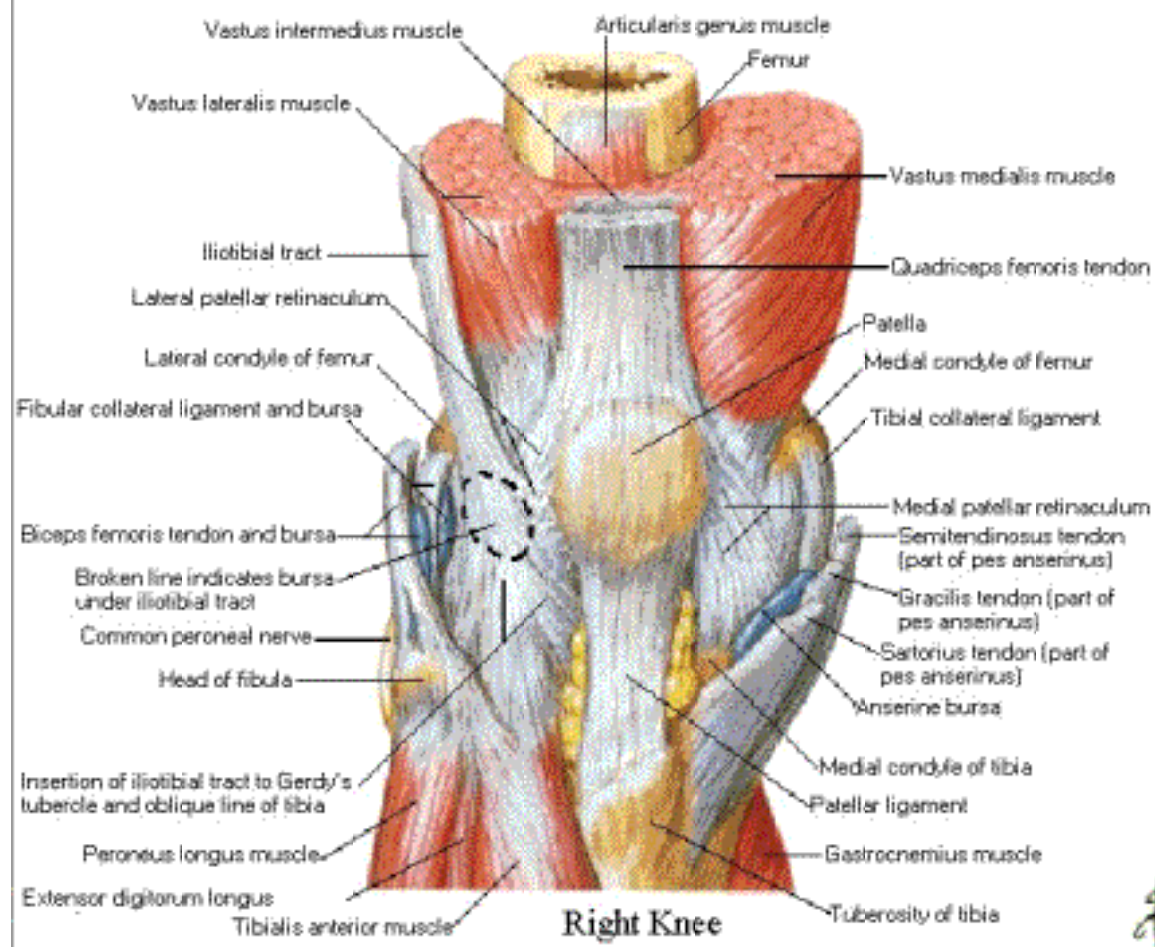
Medial View



F. Netter M.D.
©Novartis

Knee in Extension

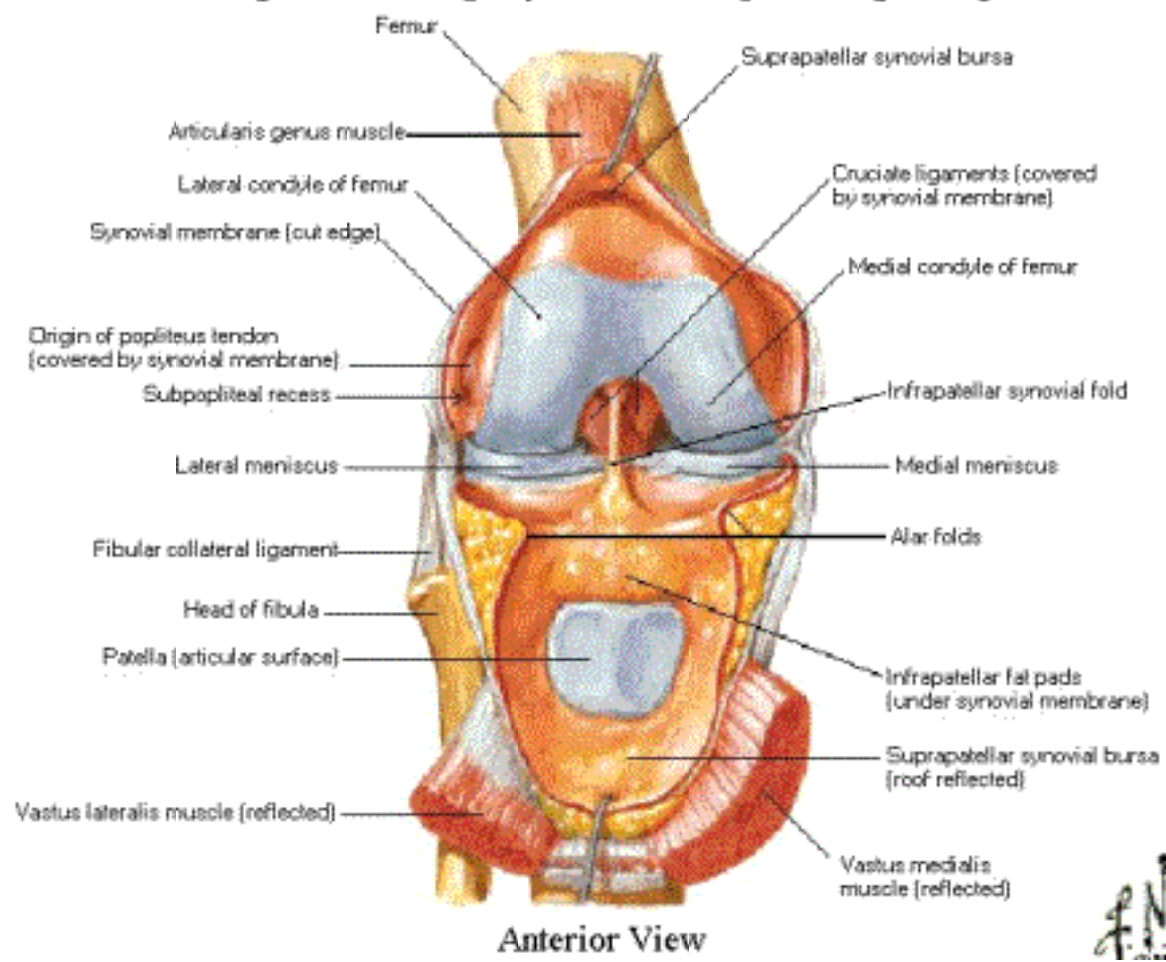
Anterior View



4

Knee

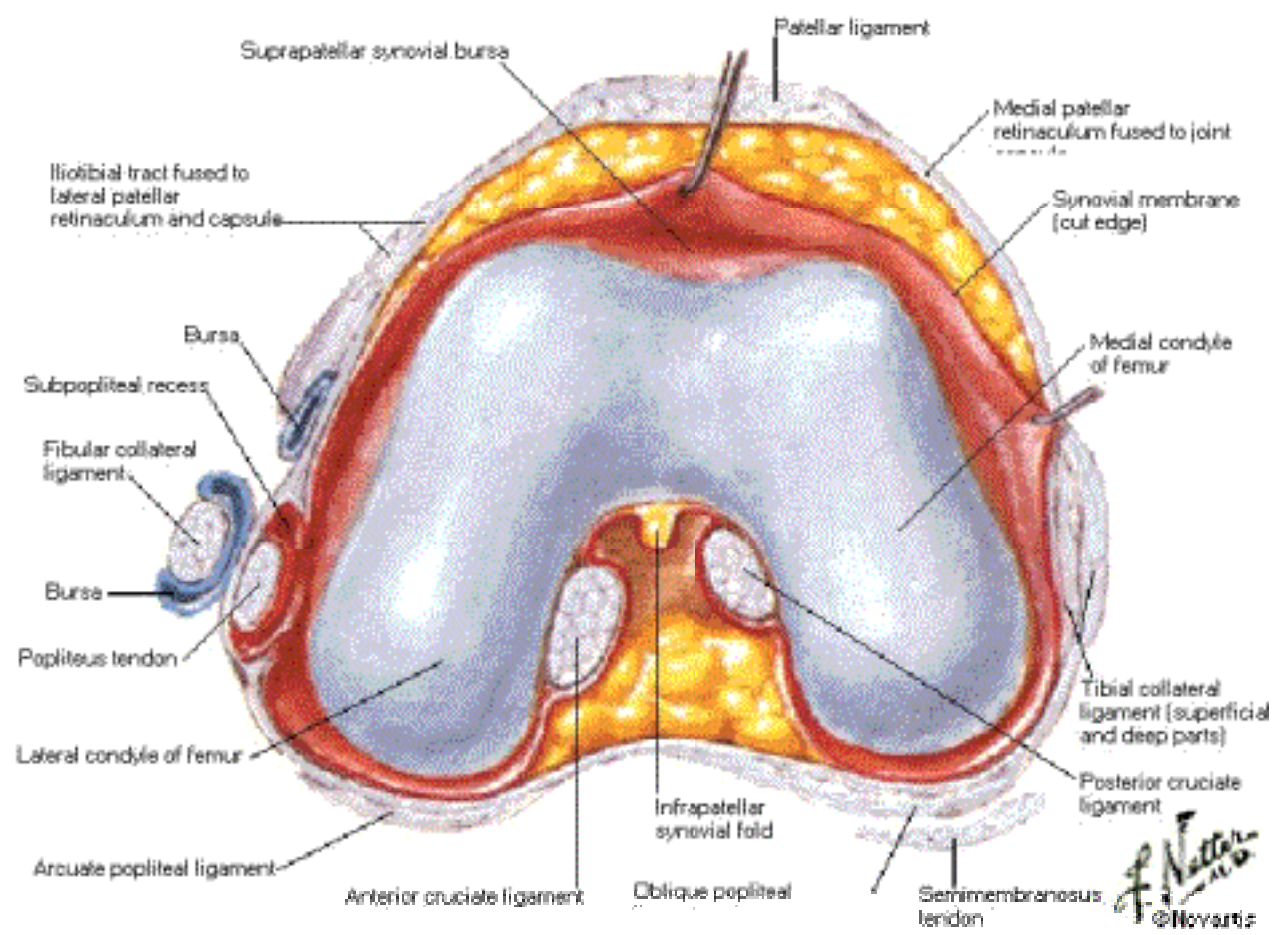
Right Knee Slightly in Flexion [Joint Opened]



FN

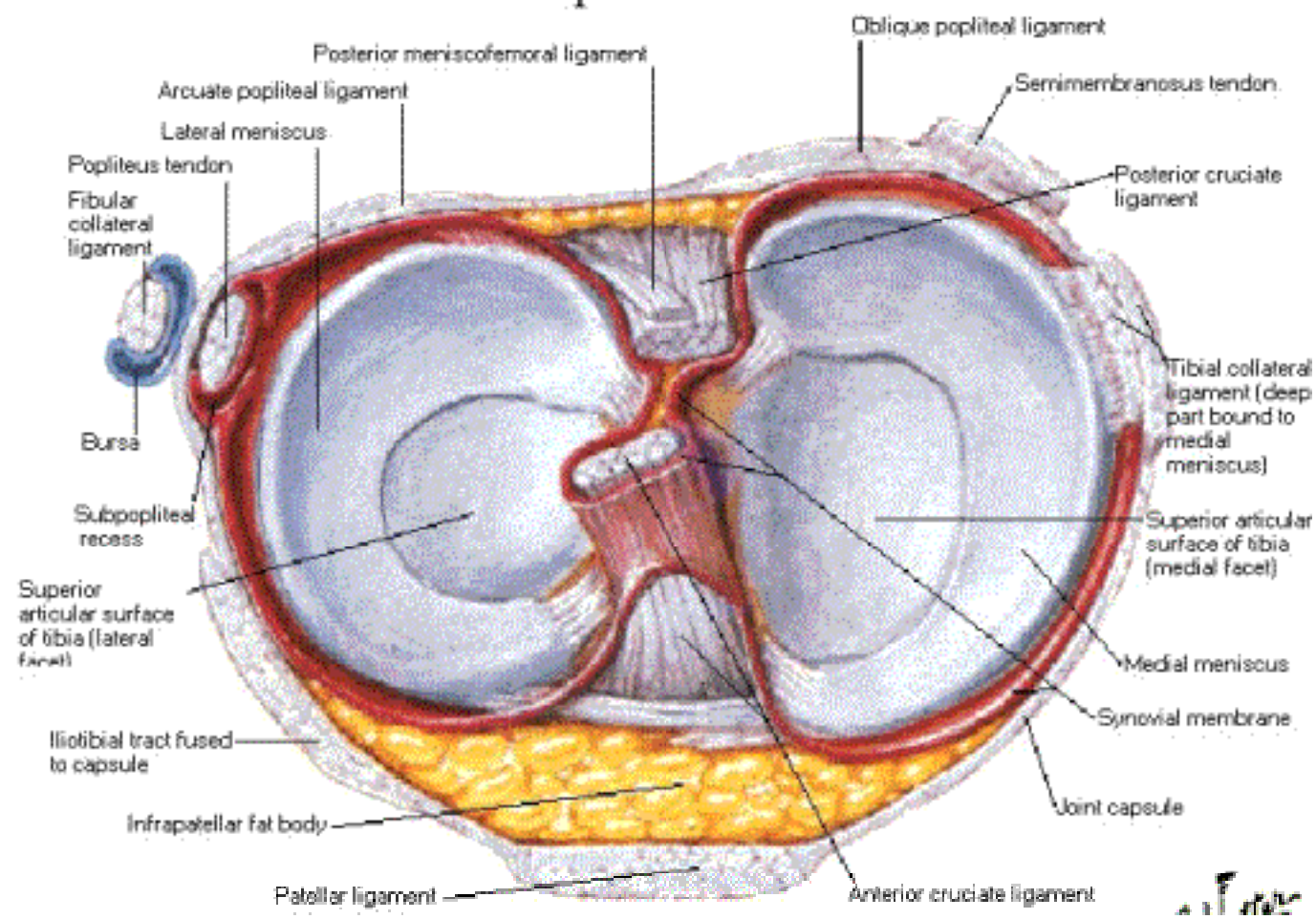
Knee - Interior

Inferior View



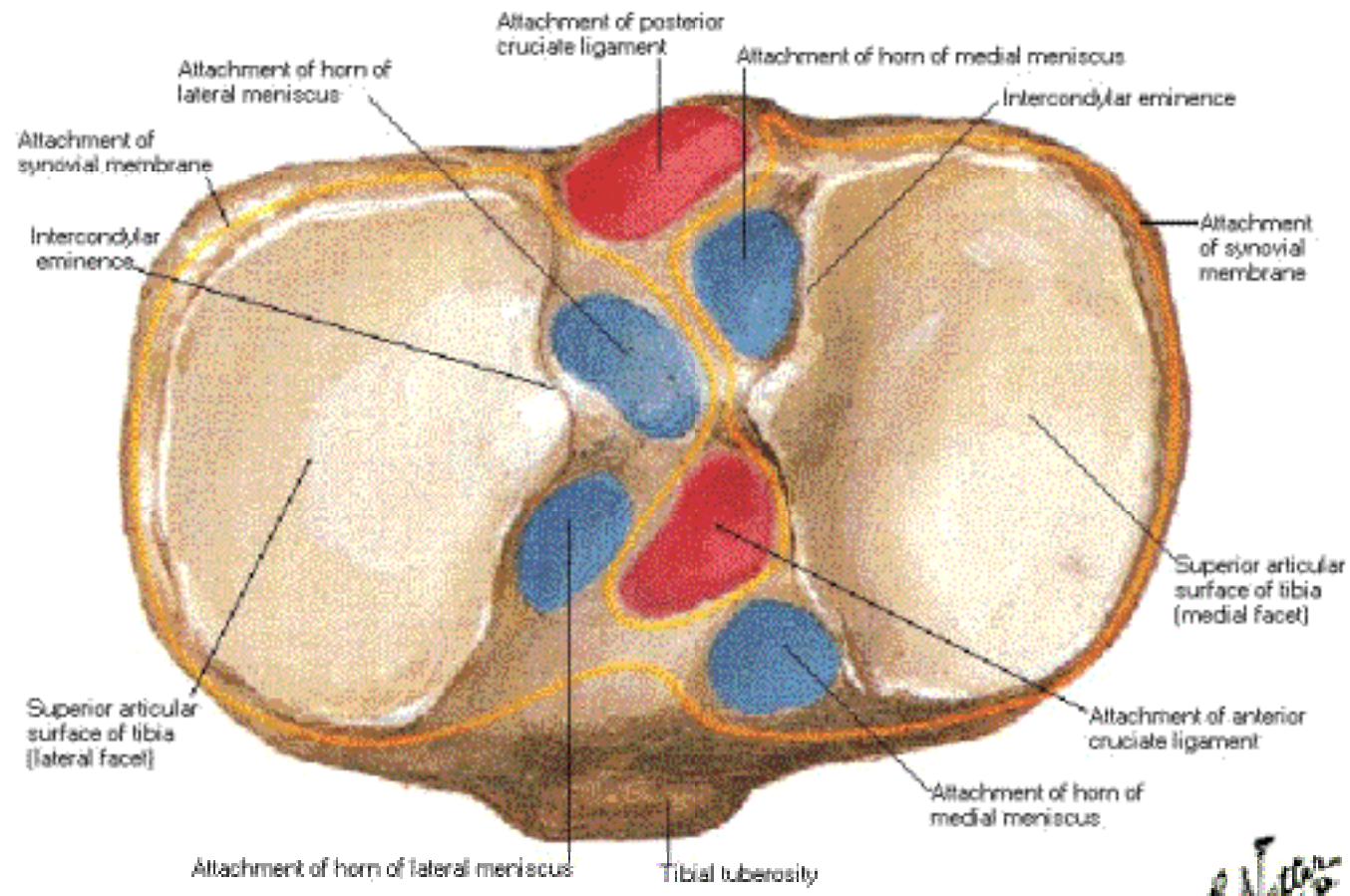
Knee - Interior

Superior View



Knee - Interior

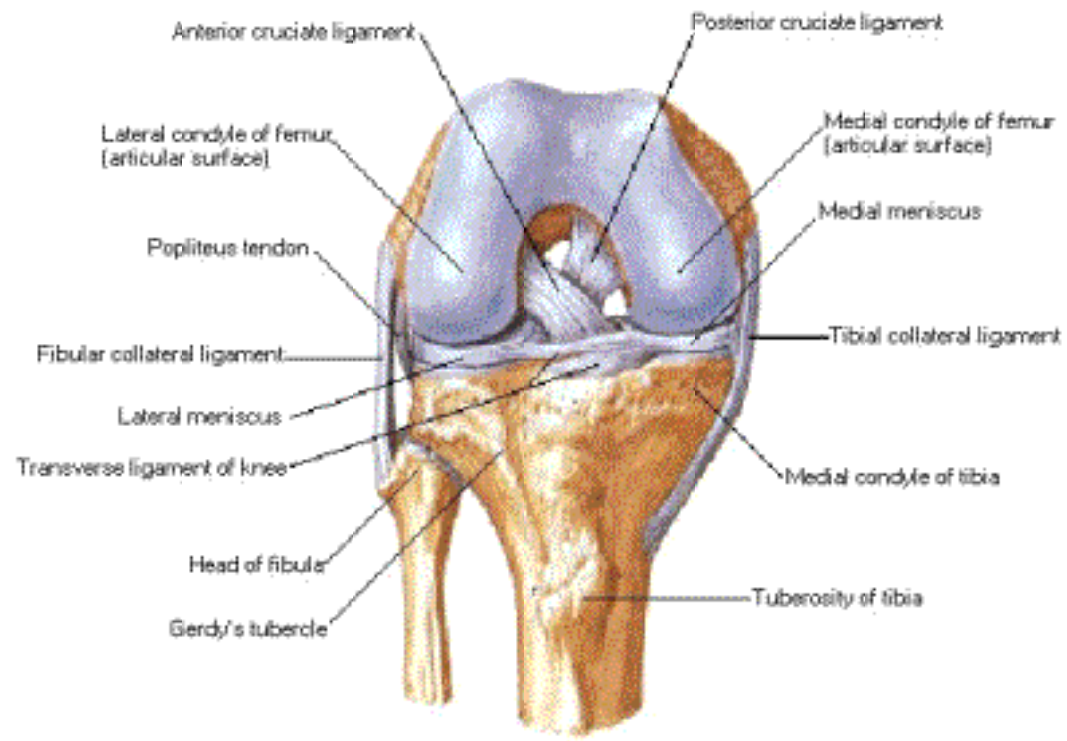
Superior View, Ligaments and Cartilage Removed



anatomy

Knee - Cruciate and Collateral Ligaments

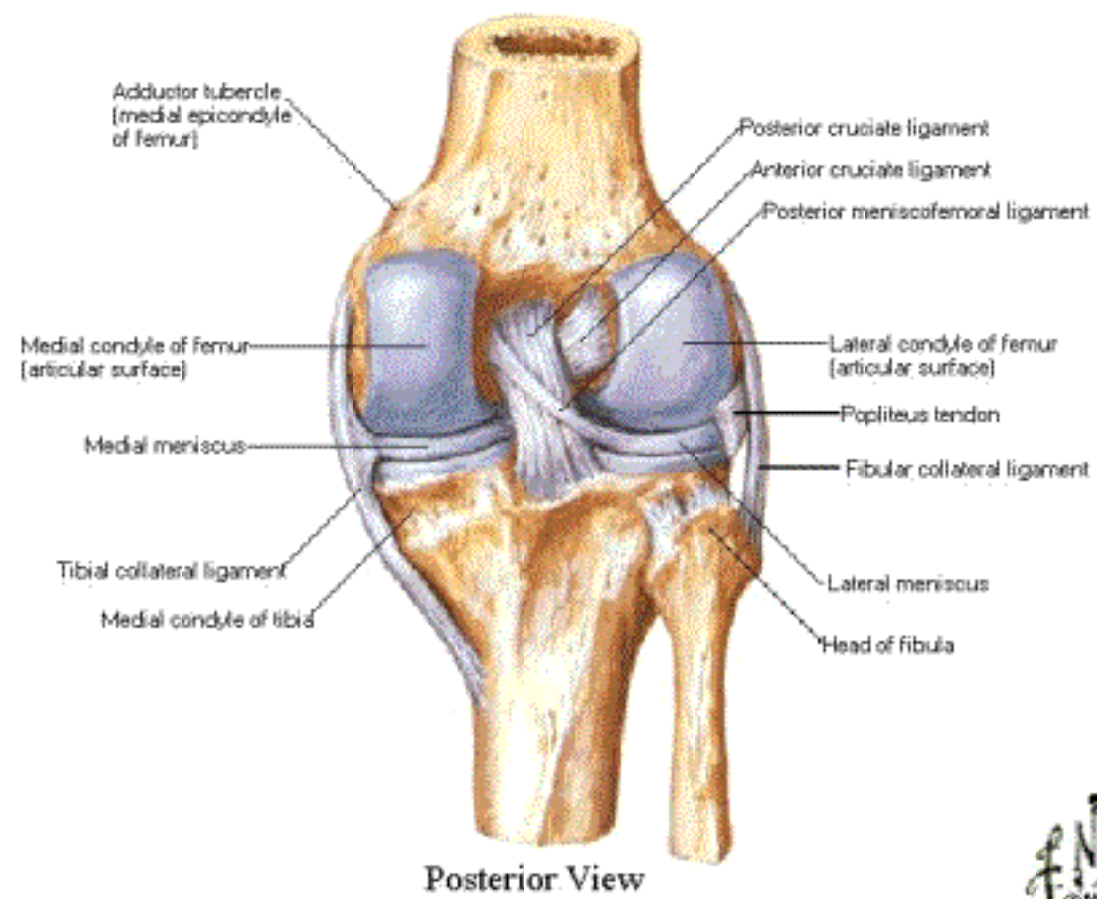
Right Knee in Flexion



Anterior View

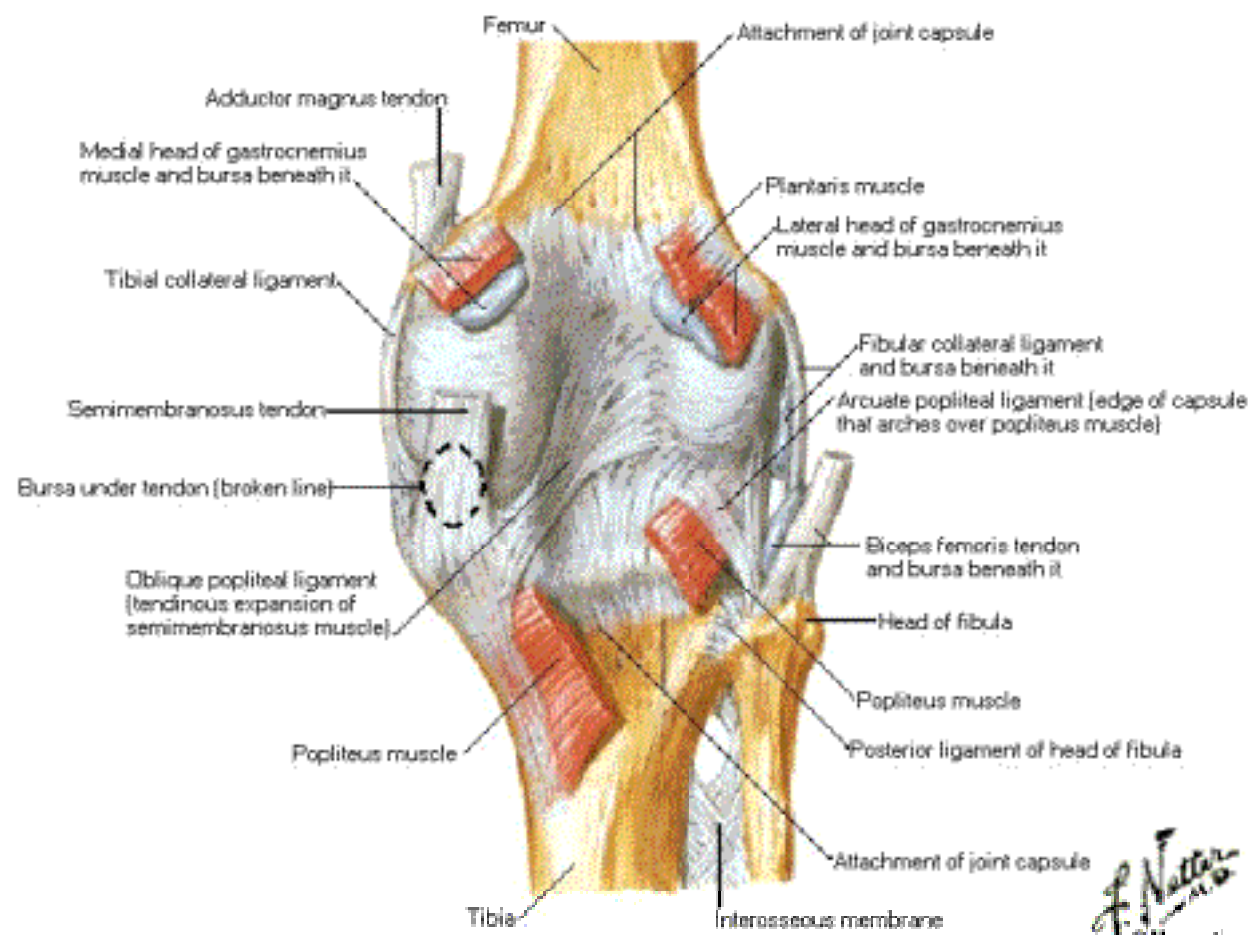
Knee - Cruciate and Collateral Ligaments

Right Knee in Extension



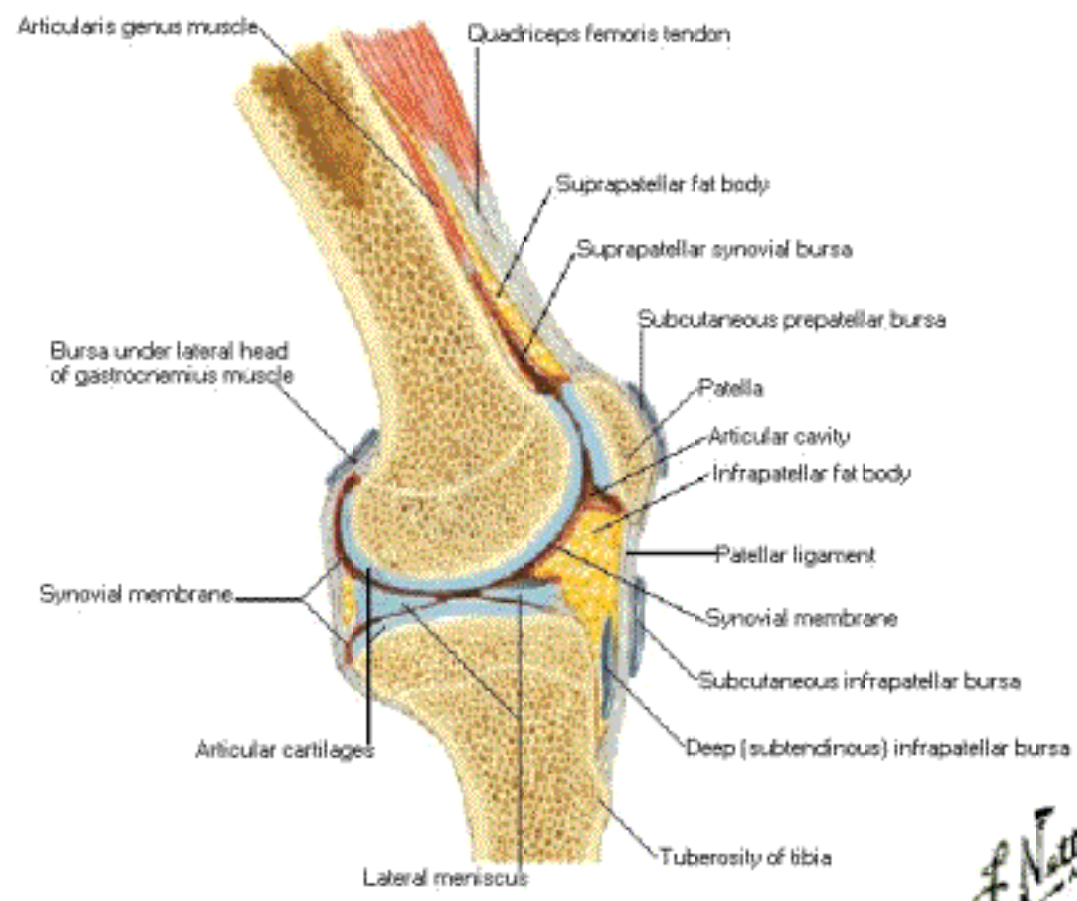
Knee

Posterior View



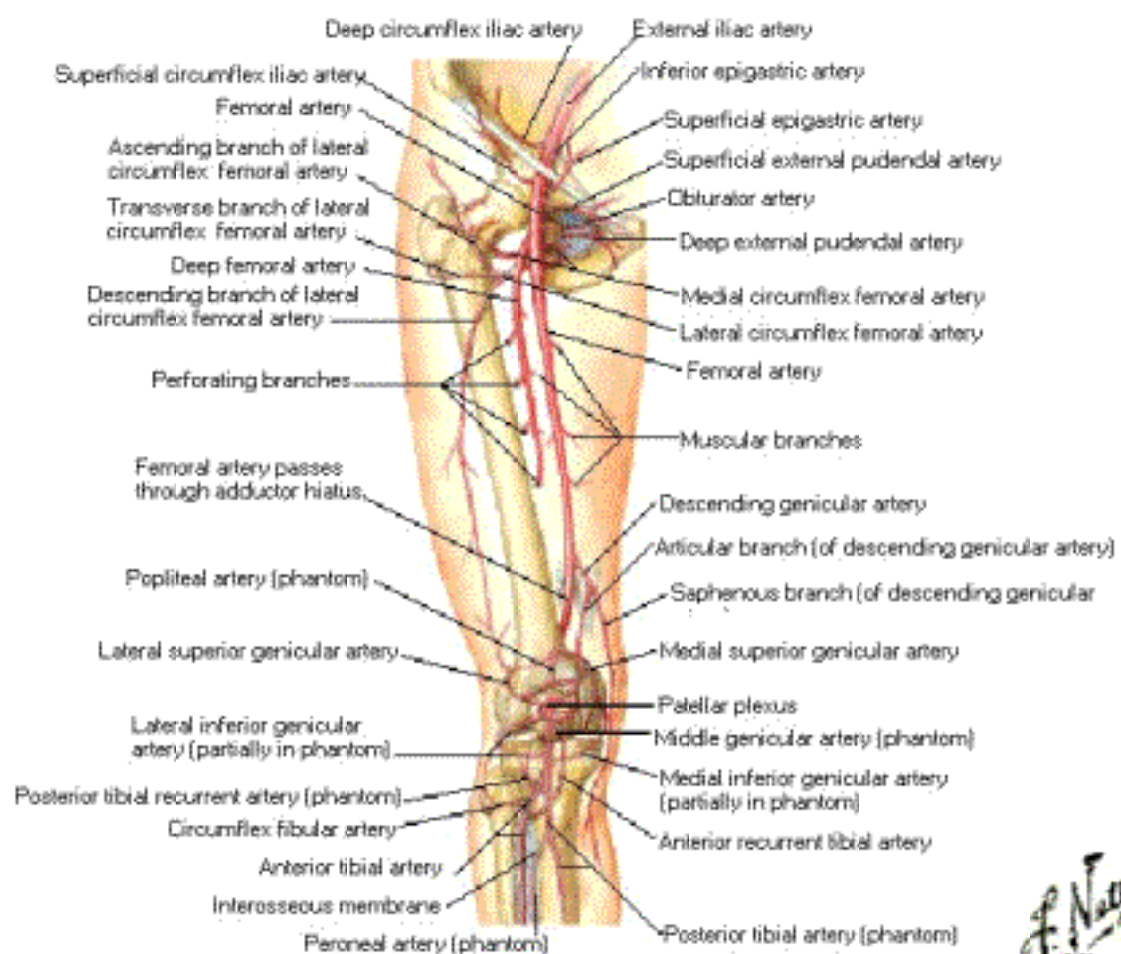
Knee

Parasagittal Section - Lateral to Midline



Arteries of Thigh and Knee

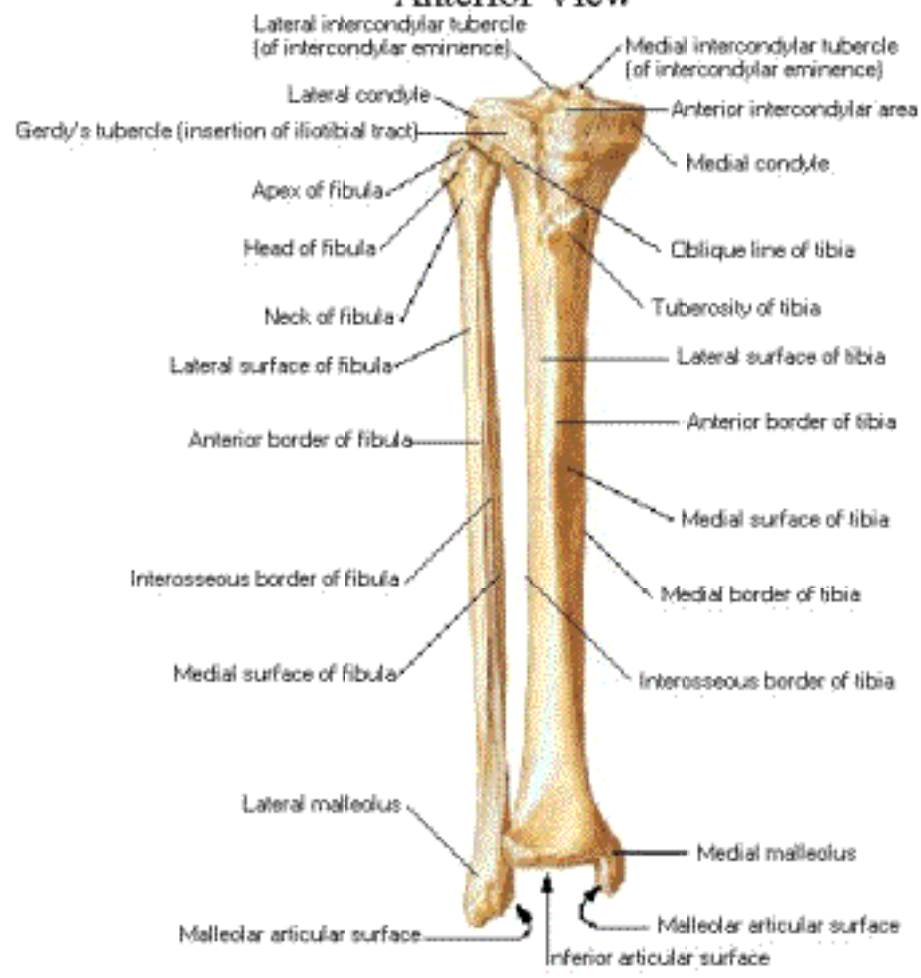
Schema



F. N. S.

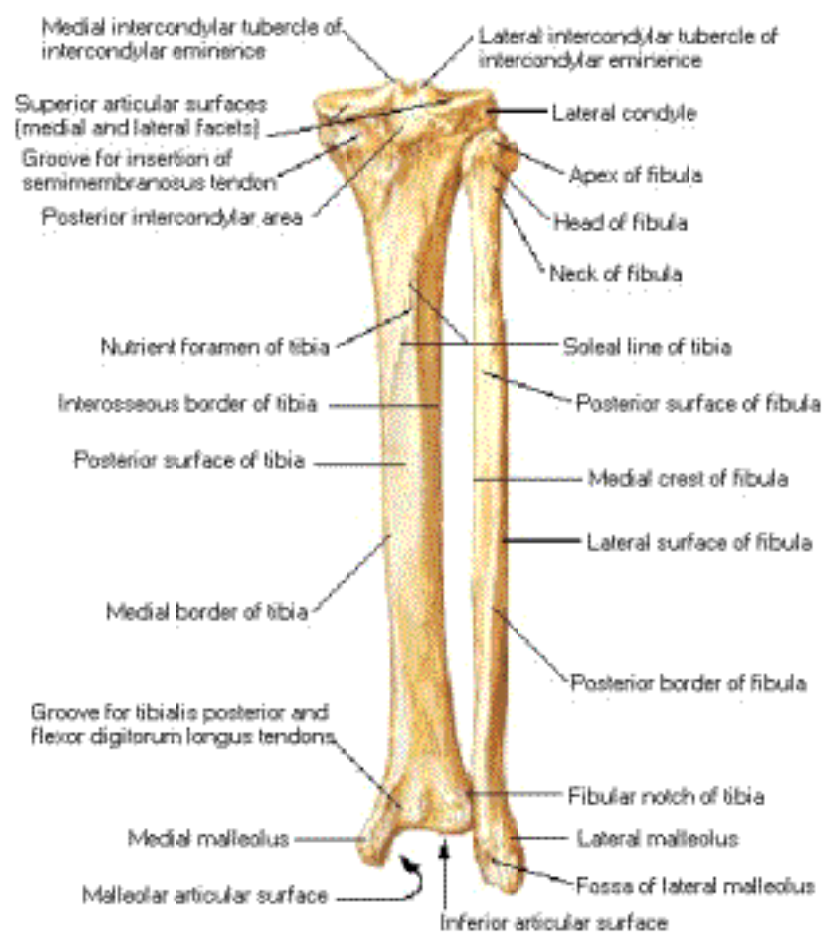
Tibia and Fibula of Right Leg

Anterior View



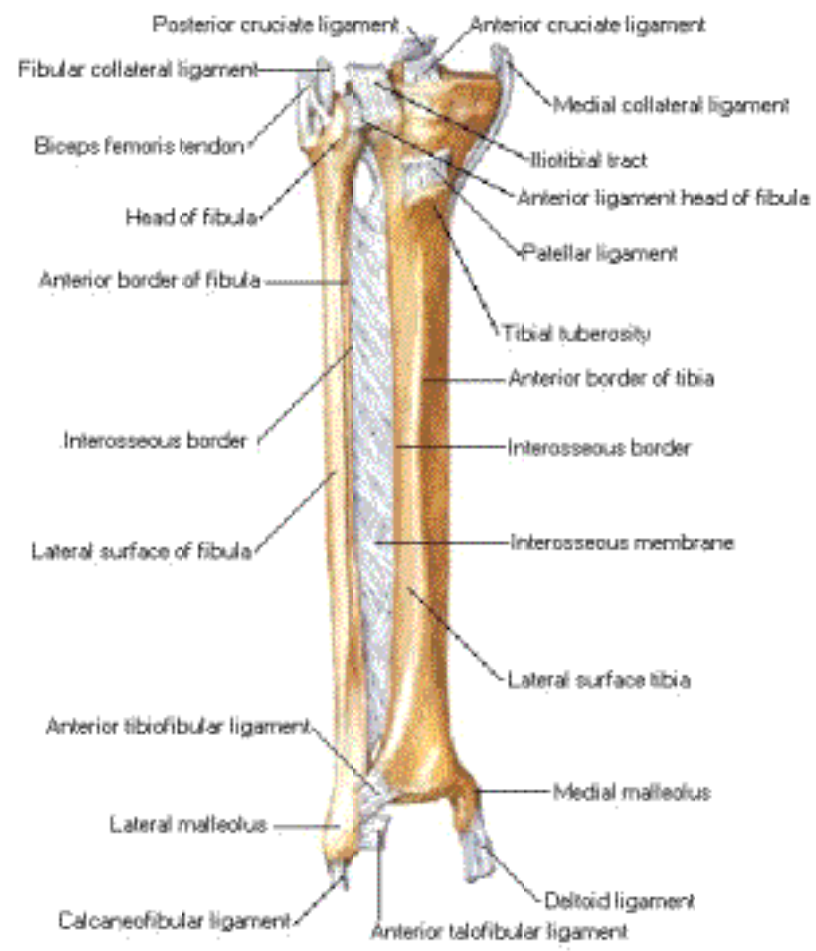
Tibia and Fibula of Right Leg

Posterior View



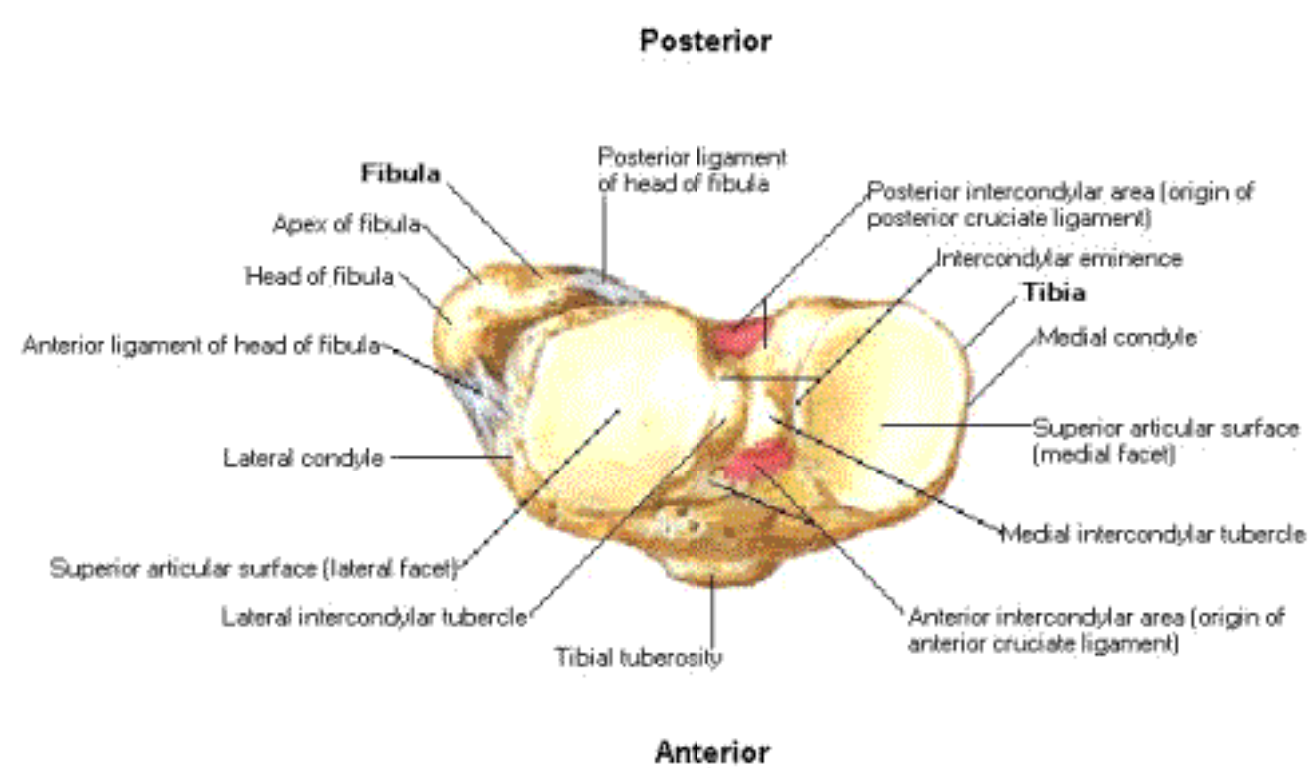
Tibia and Fibula of Right Leg

Anterior View - Ligament Attachments



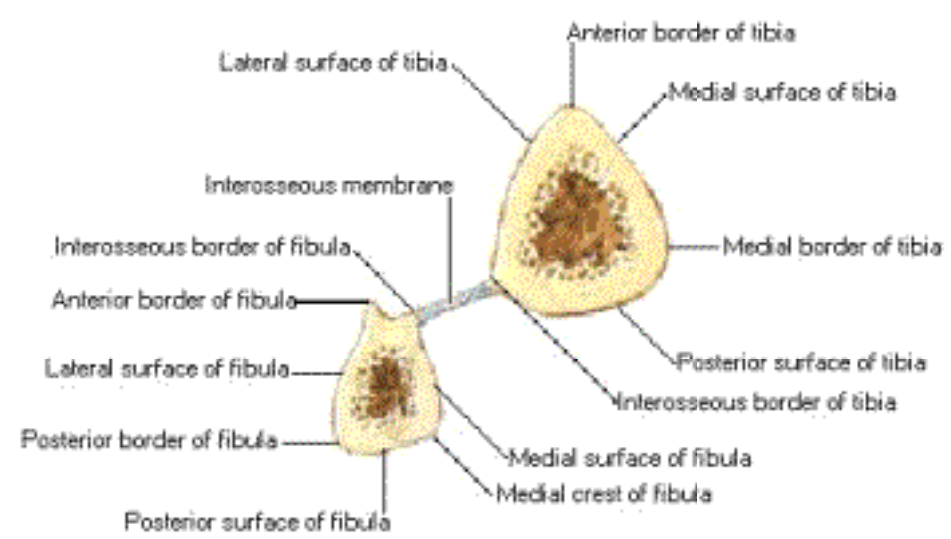
Tibia and Fibula of Right Leg

Superior View



Tibia and Fibula of Right Leg

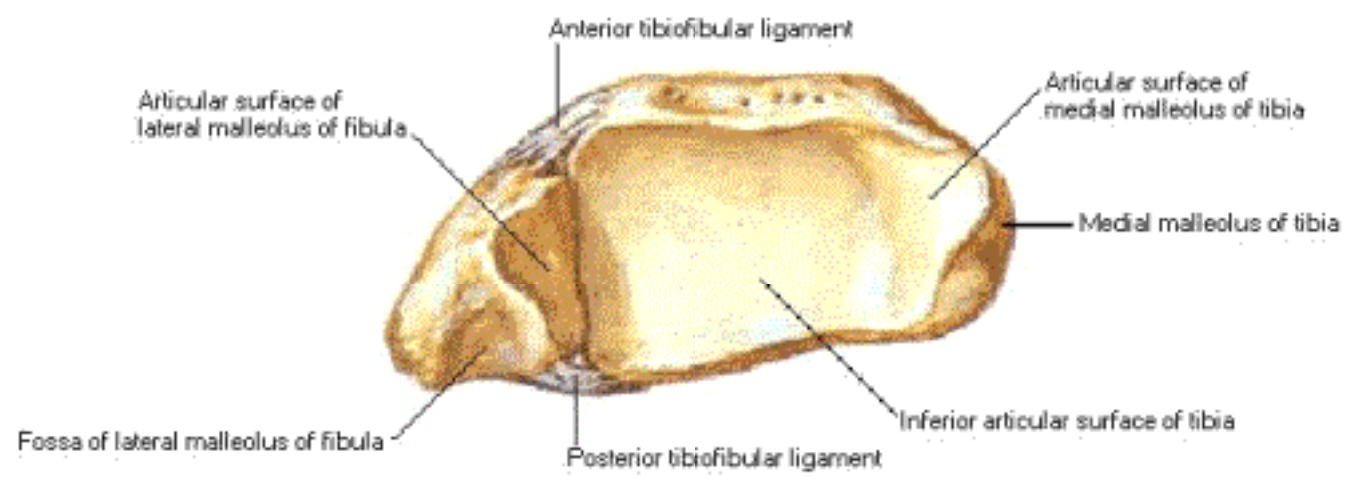
Cross Section



Tibia and Fibula of Right Leg

Inferior View

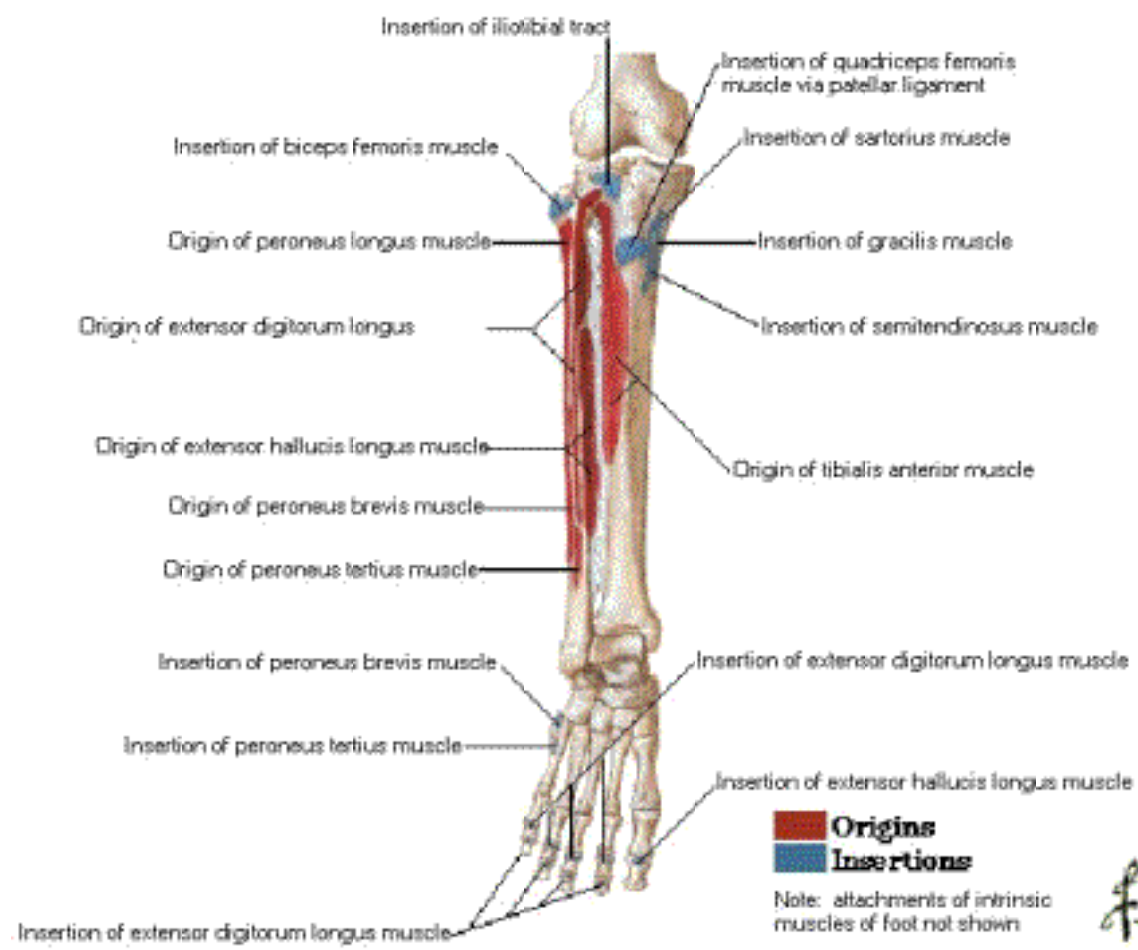
Anterior



Posterior

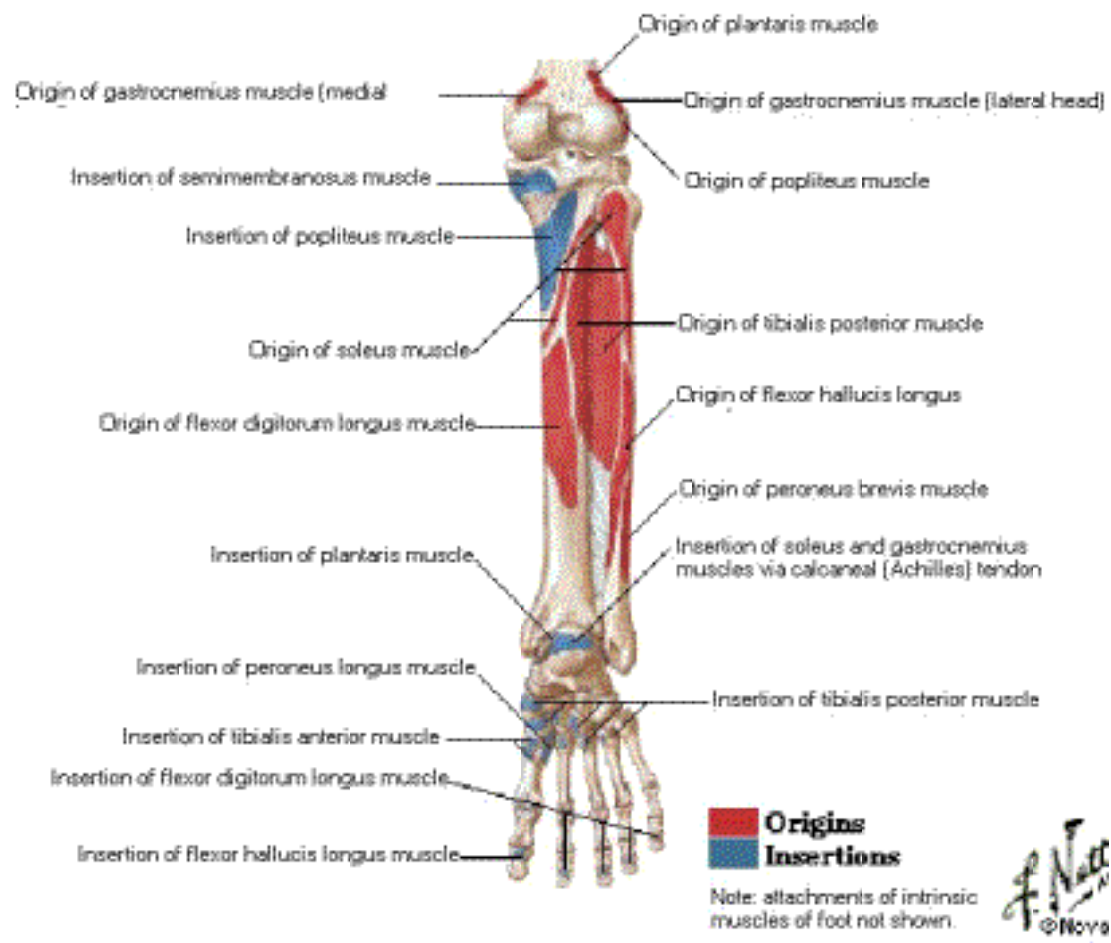
Bony Attachments of Muscles of Leg

Anterior View



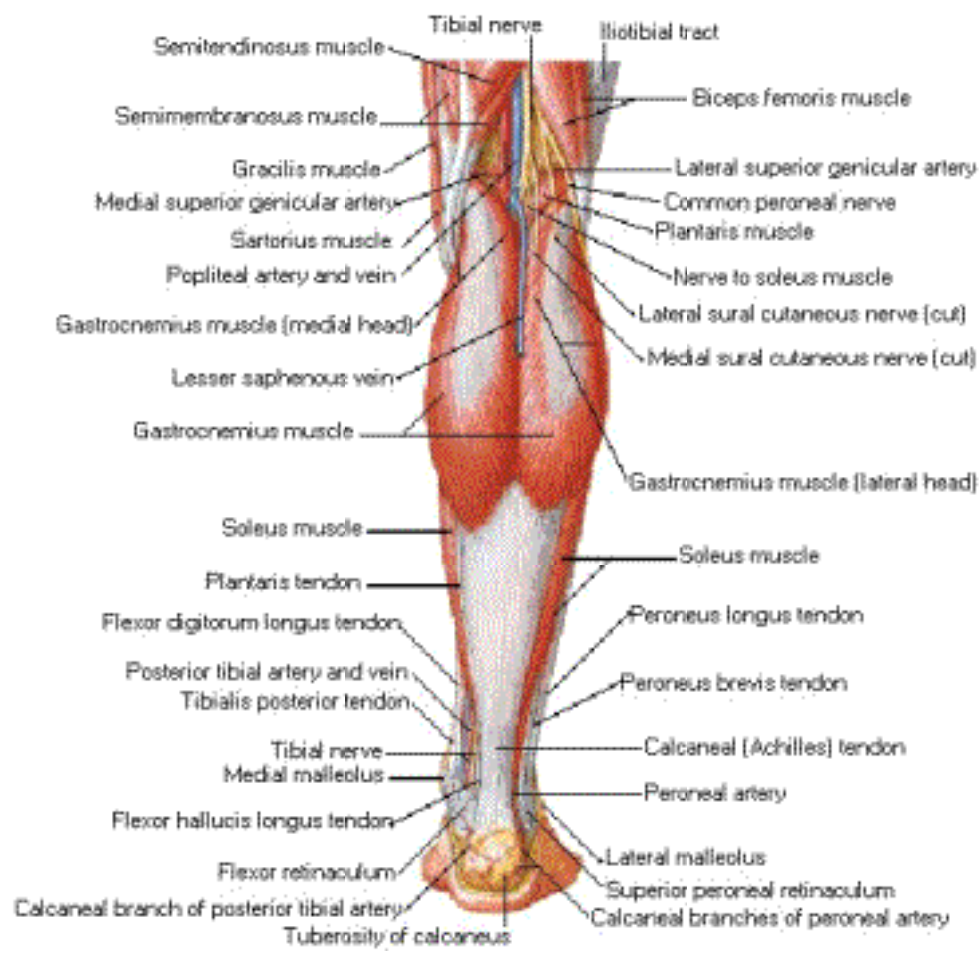
Bony Attachments of Muscles of Leg

Posterior View



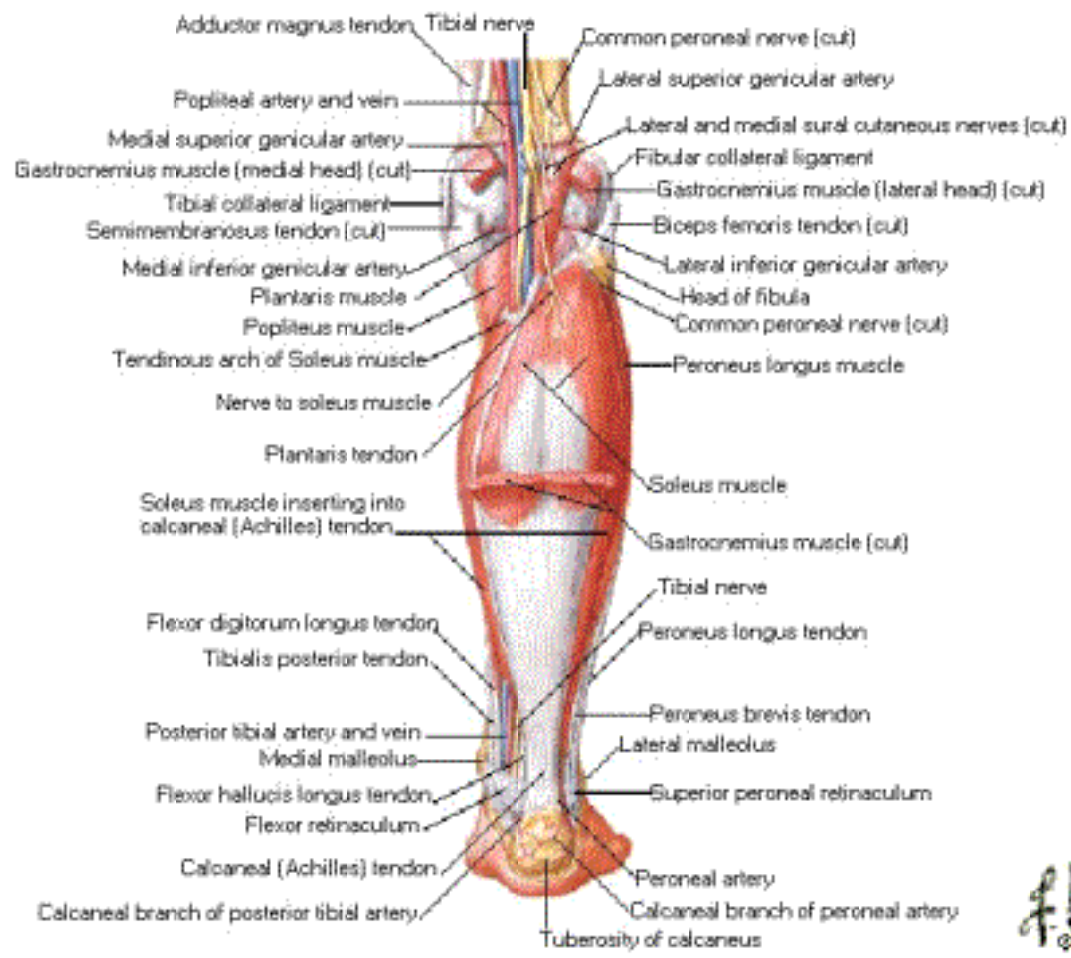
Muscles of Leg [Superficial Dissection]

Posterior View



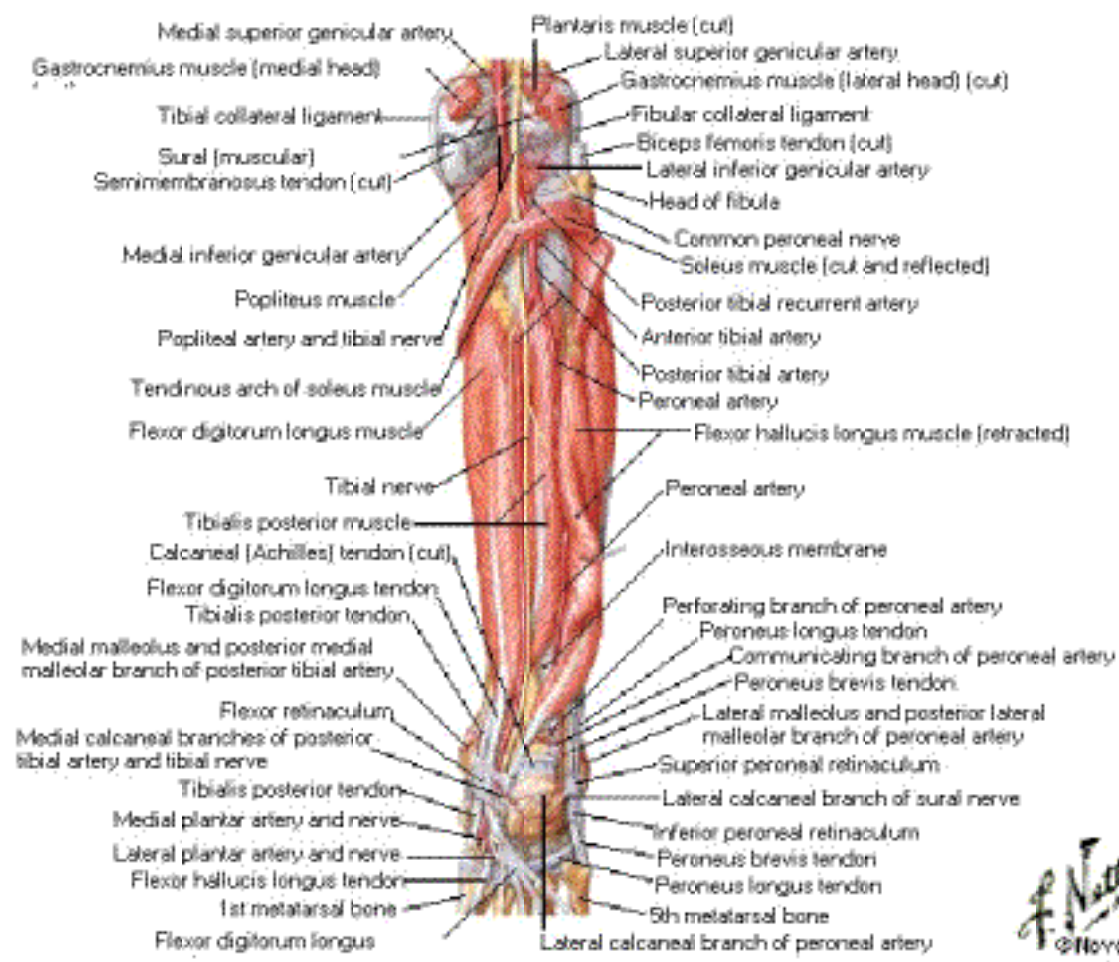
Muscles of Leg [Intermediate Dissection]

Posterior View



Muscles of Leg [Deep Dissection]

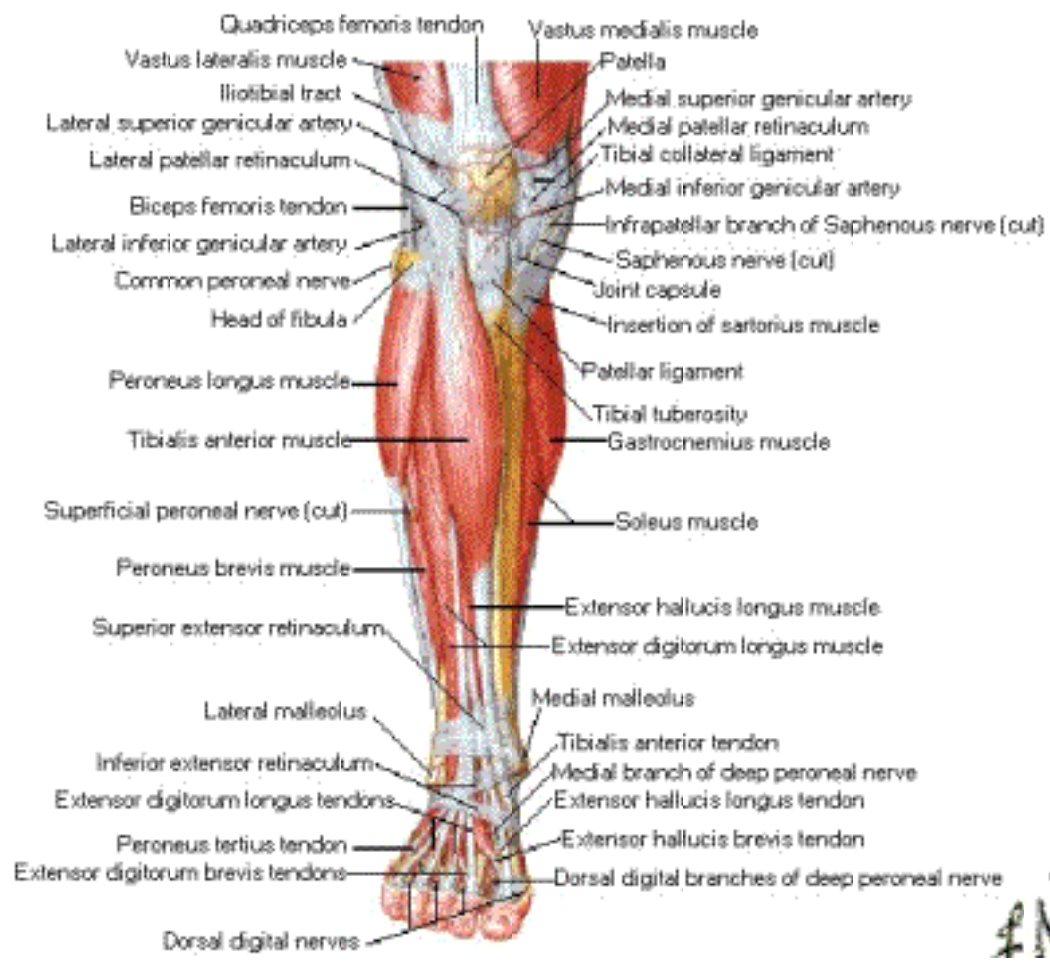
Posterior View



F. Net
©Nets

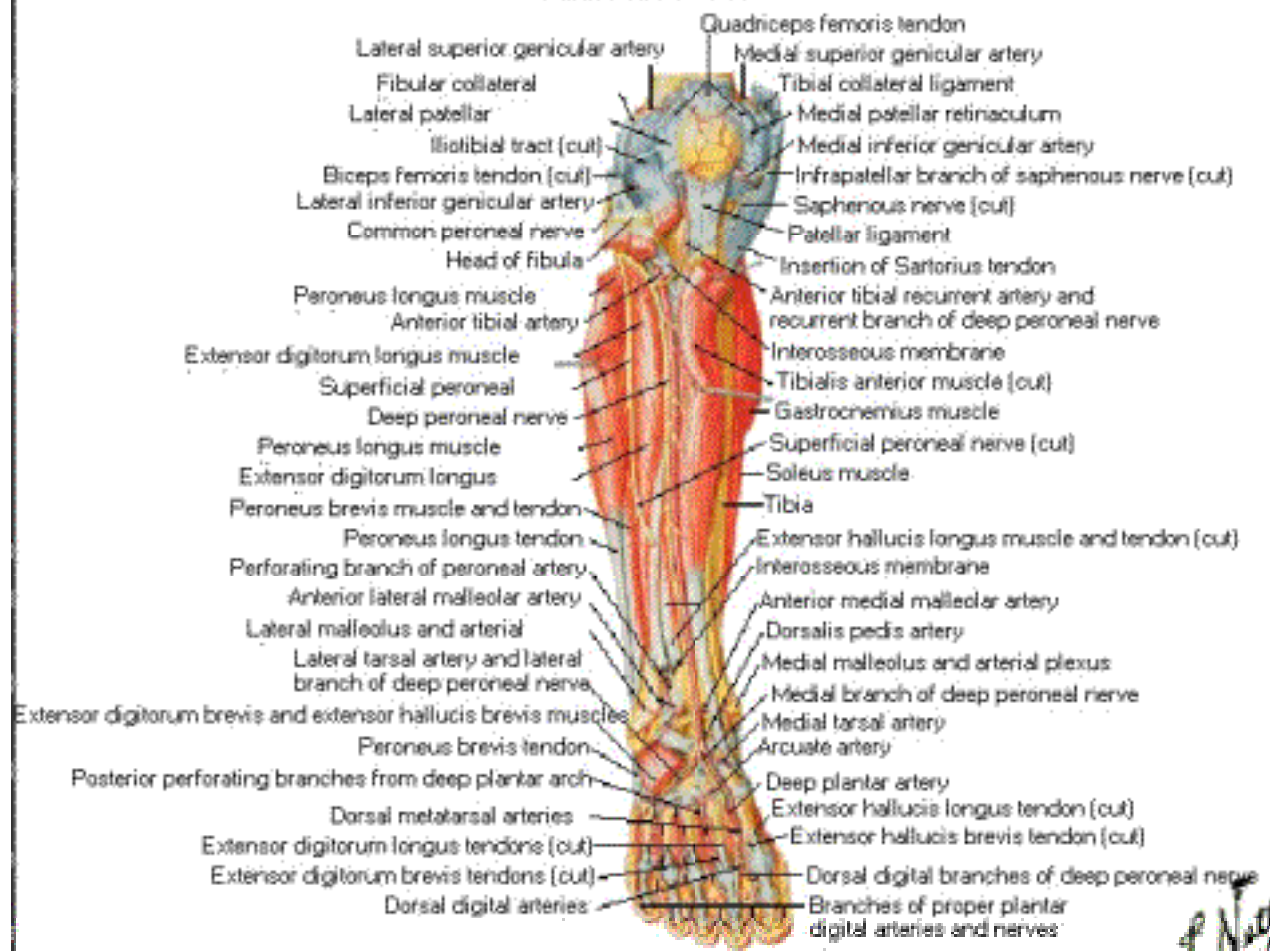Muscles of Leg [Superficial Dissection]

Anterior View



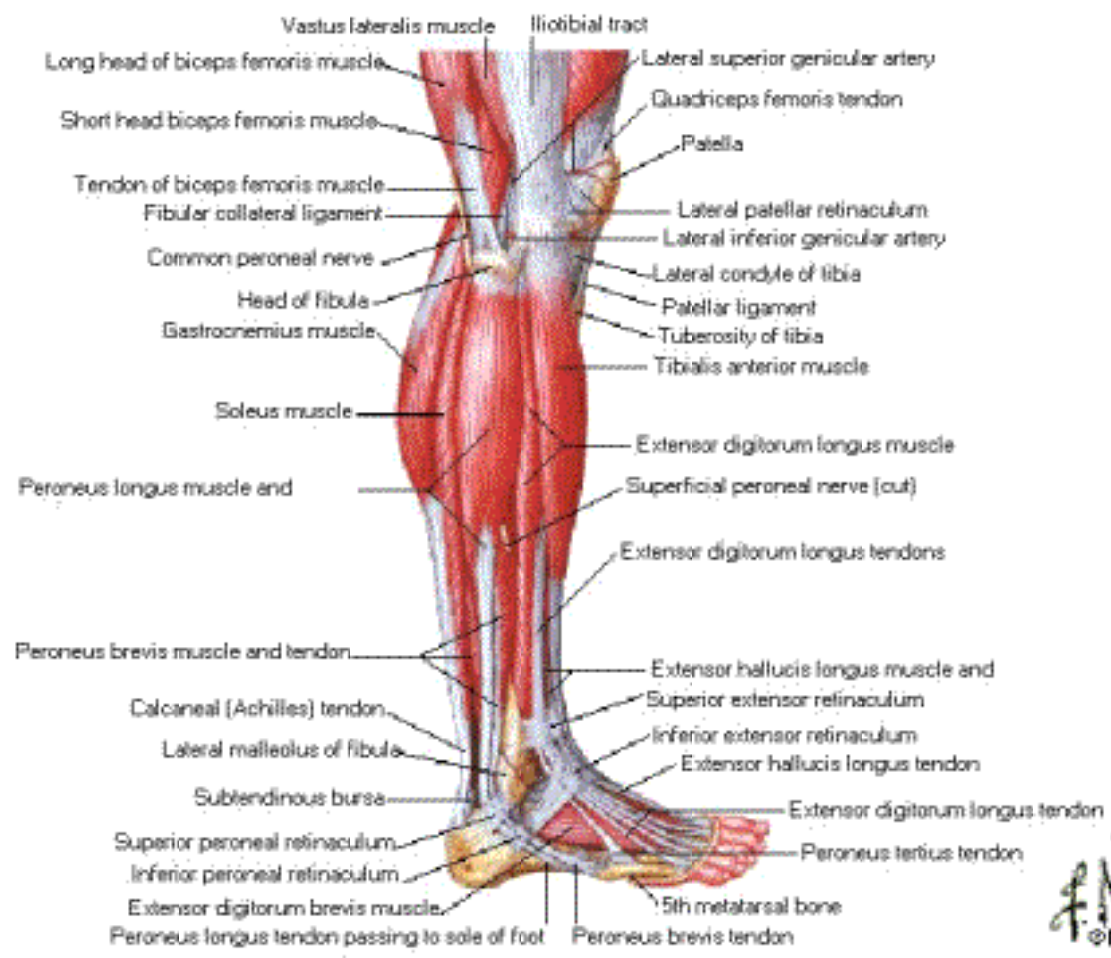
Muscles of Leg [Deep Dissection]

Anterior View



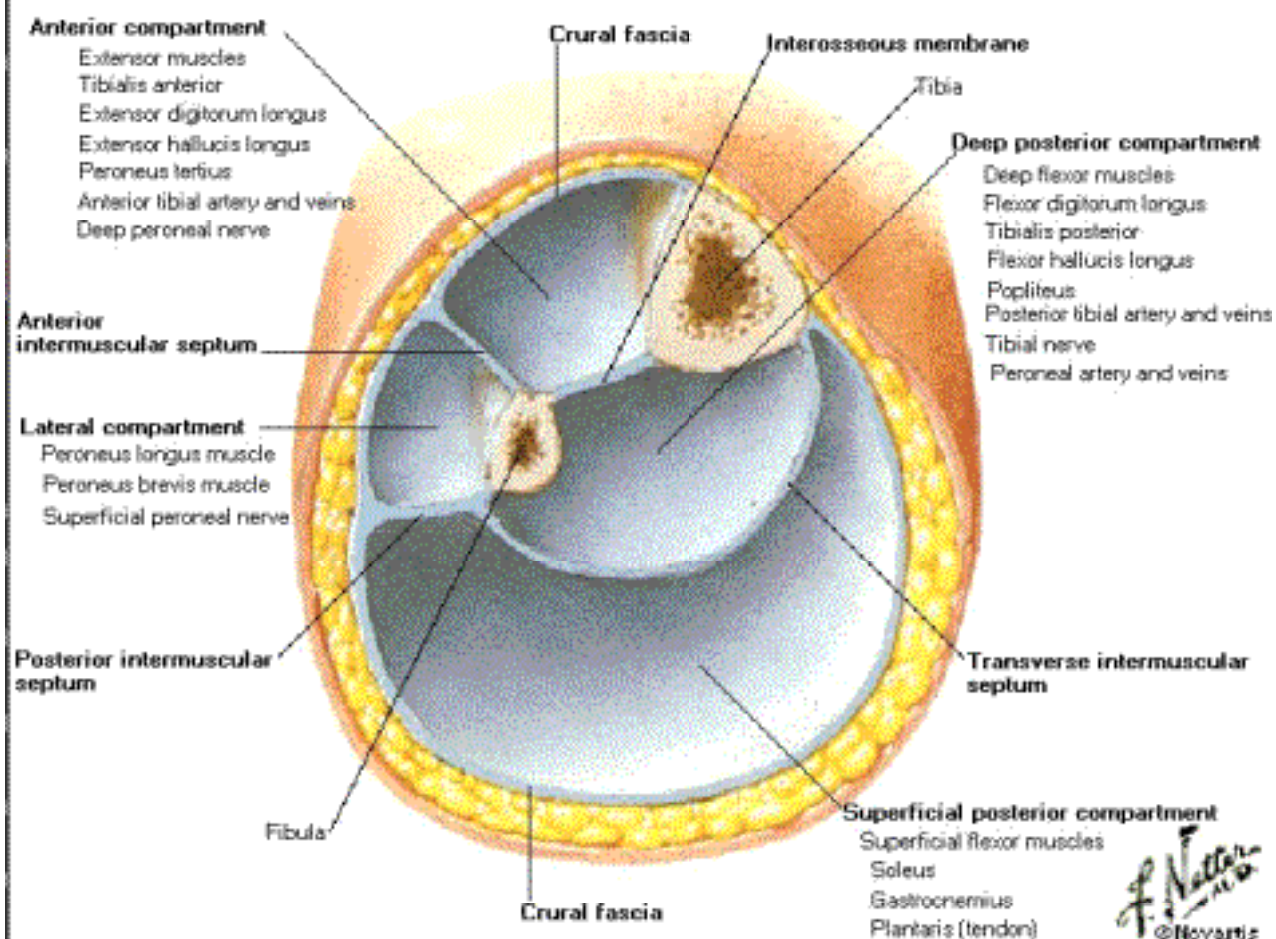
Muscles of Leg

Lateral View



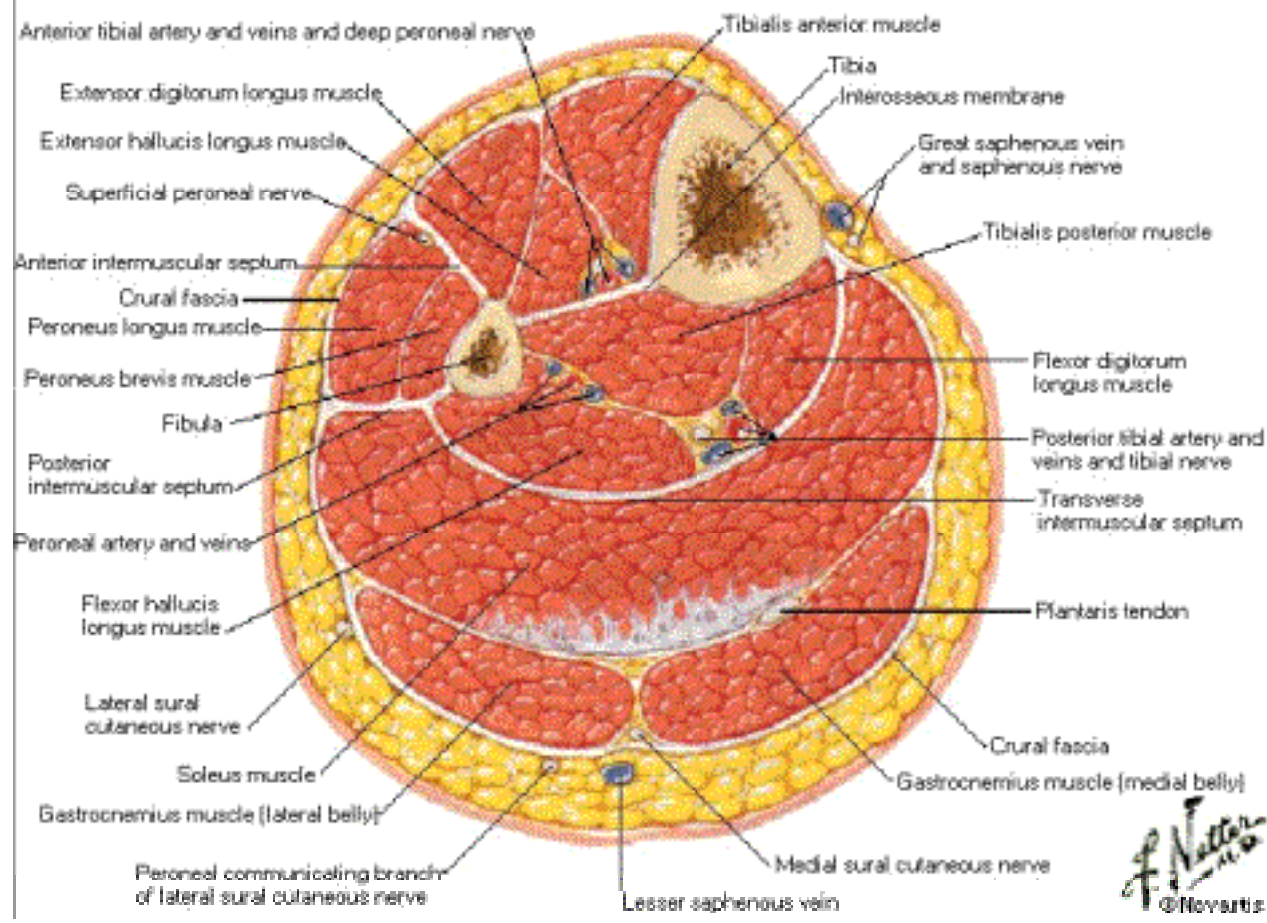
Leg

Cross Section - Fascial Compartments



Leg

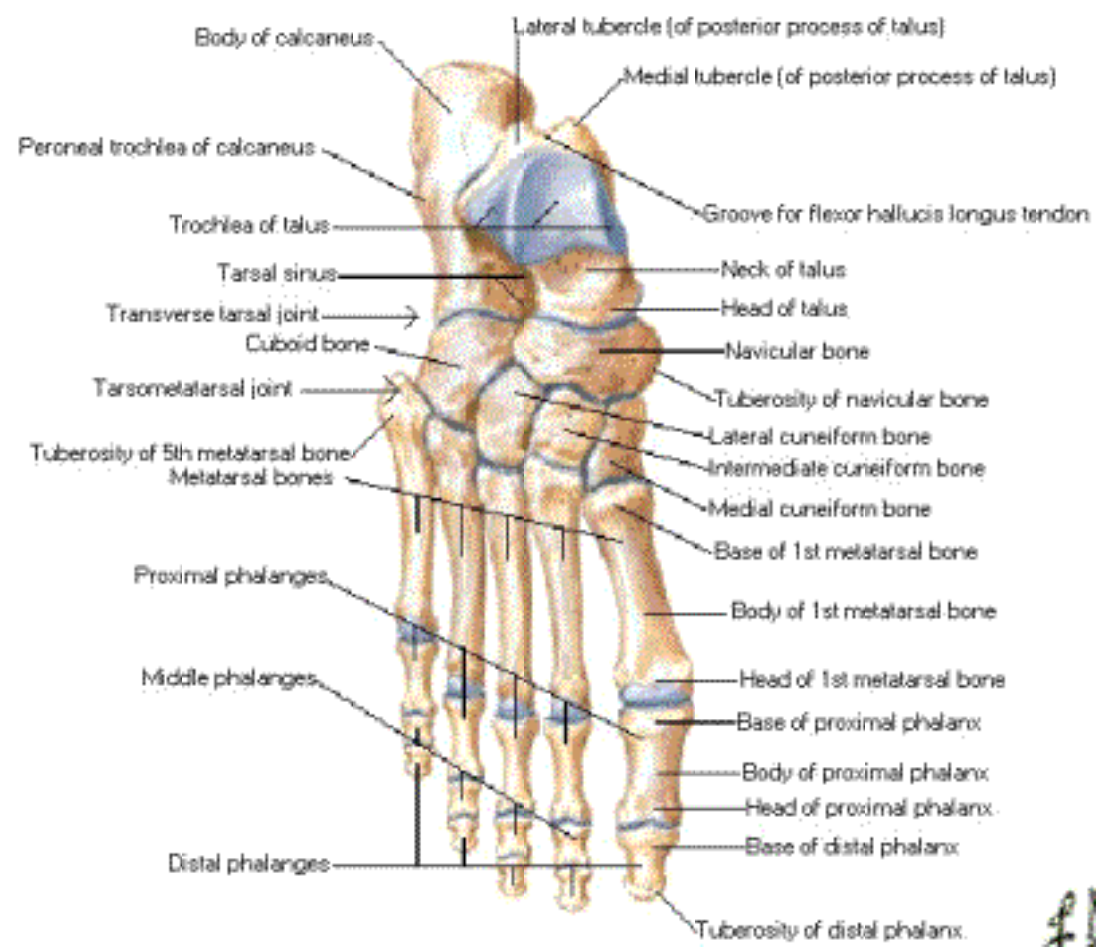
Cross Section just above Middle of Left Leg



F. Netter M.D.
© Novartis

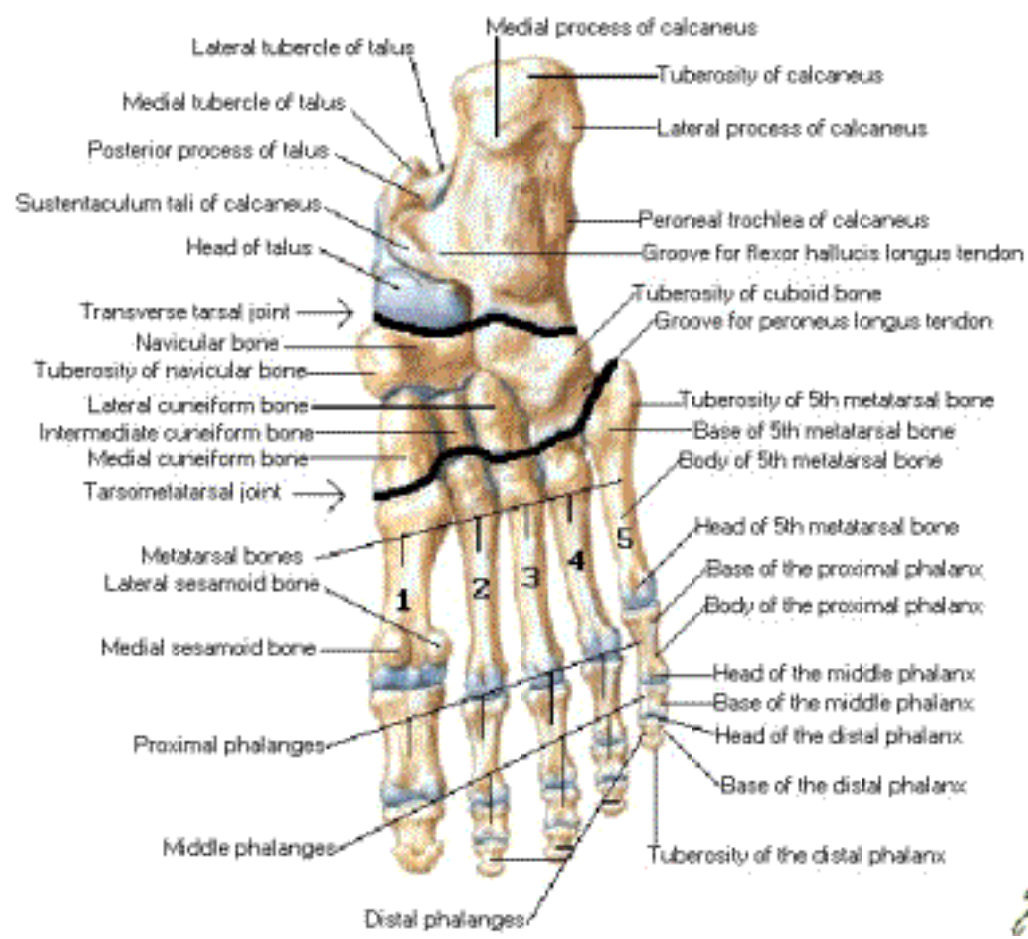
Bones of Foot

Dorsal View



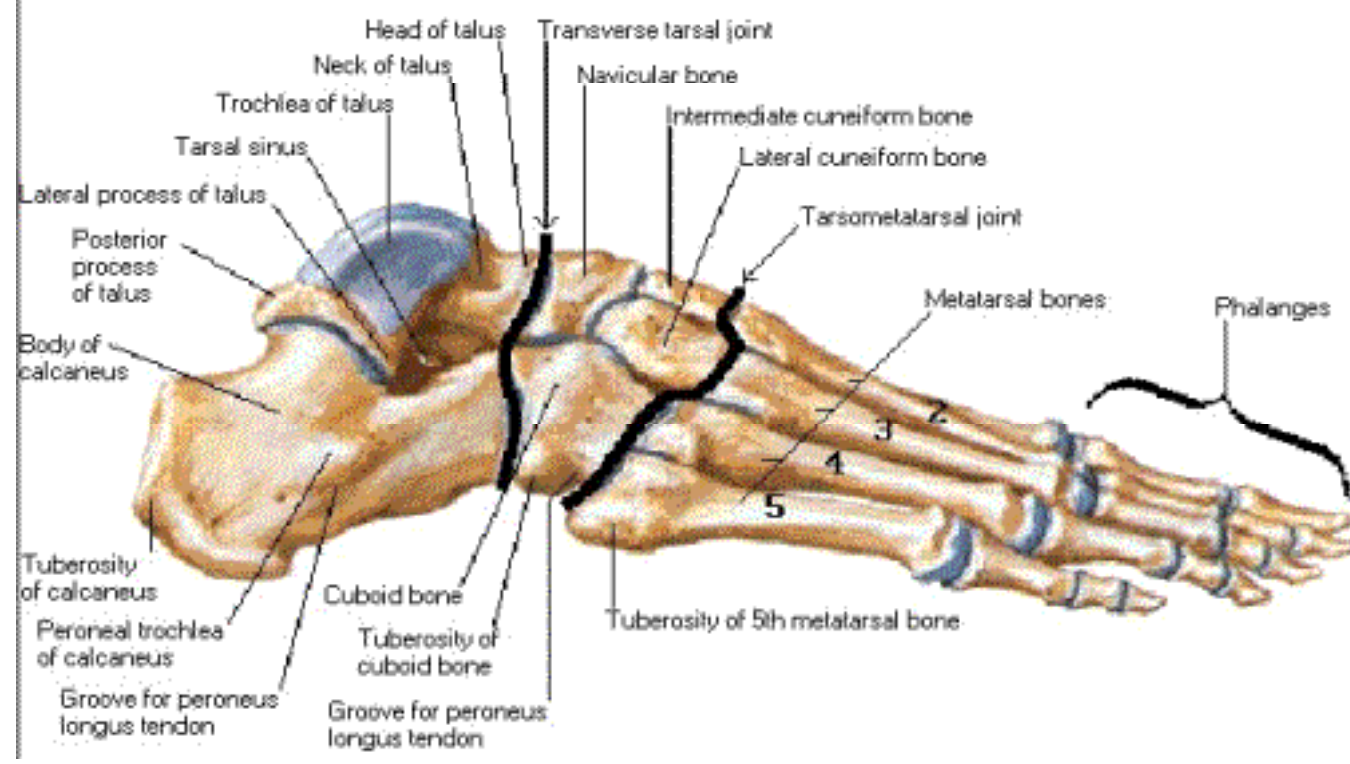
Bones of Foot

Plantar View



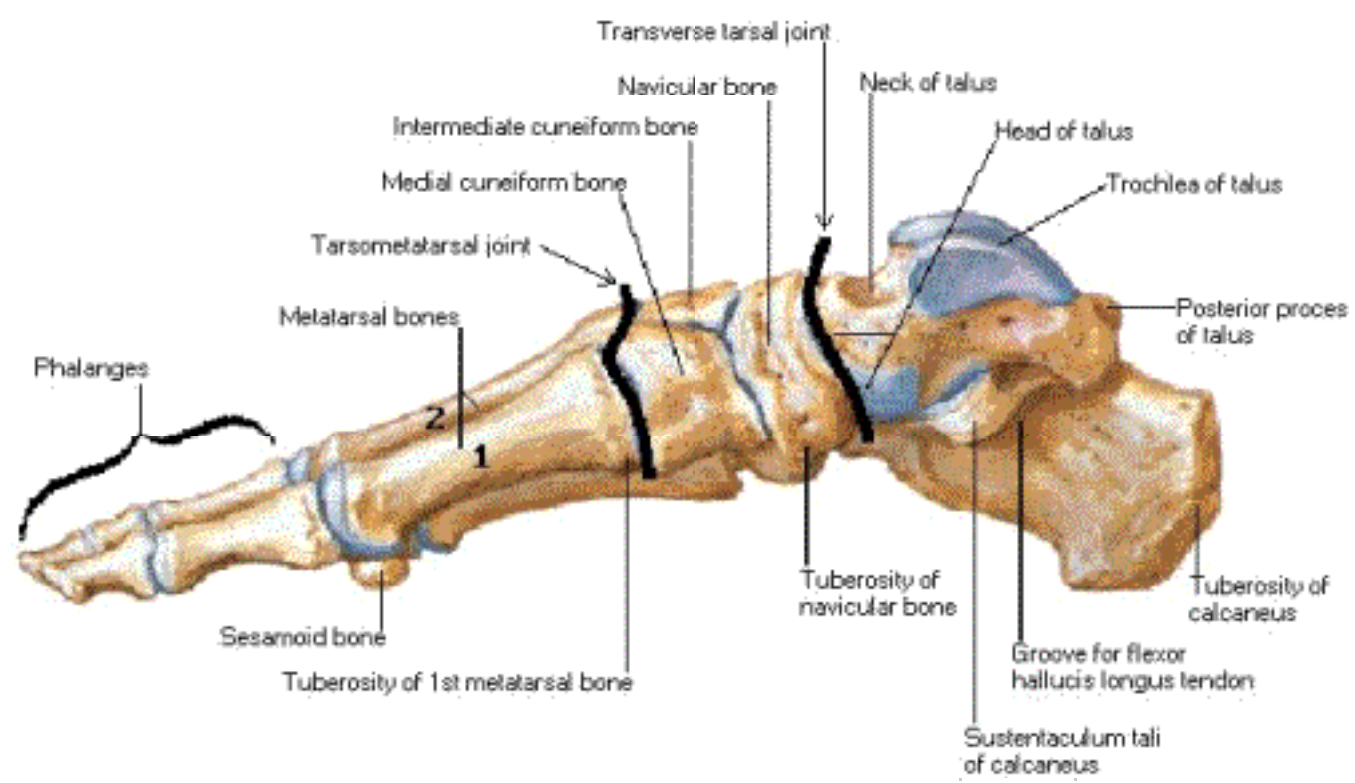
Bones of Foot

Lateral View



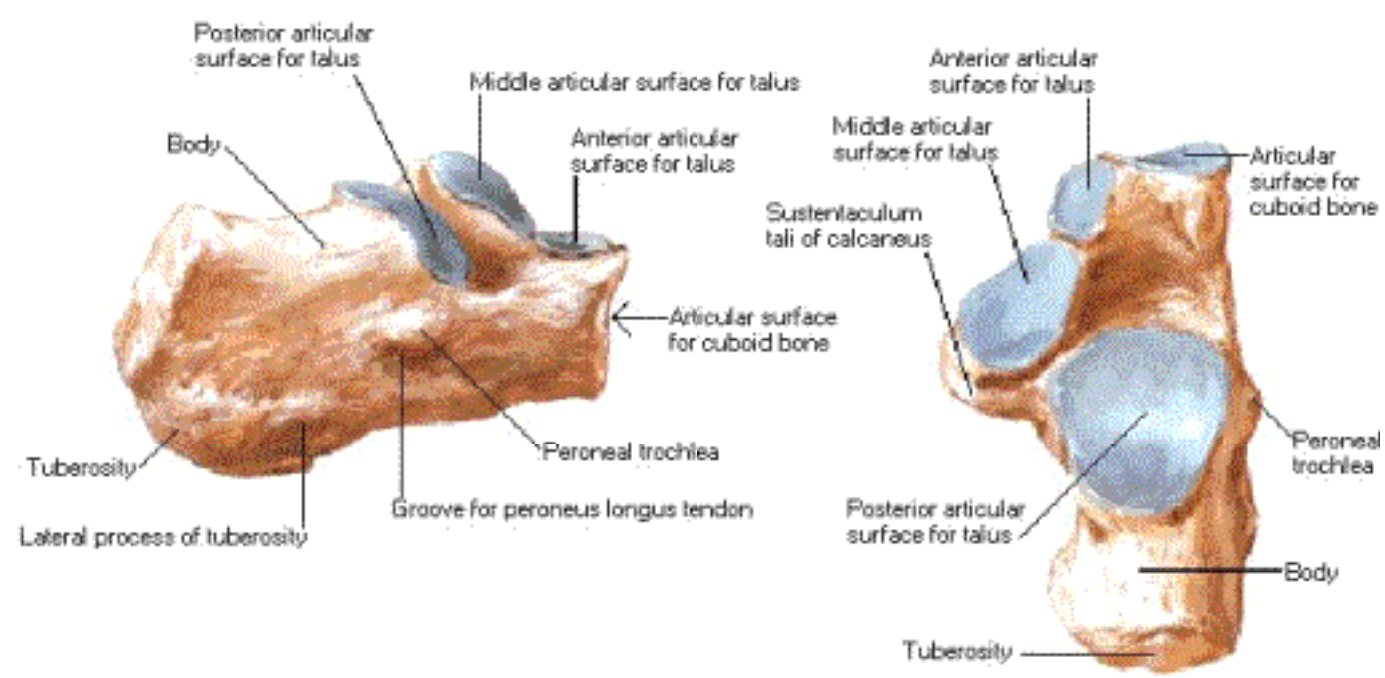
Bones of Foot

Medial View



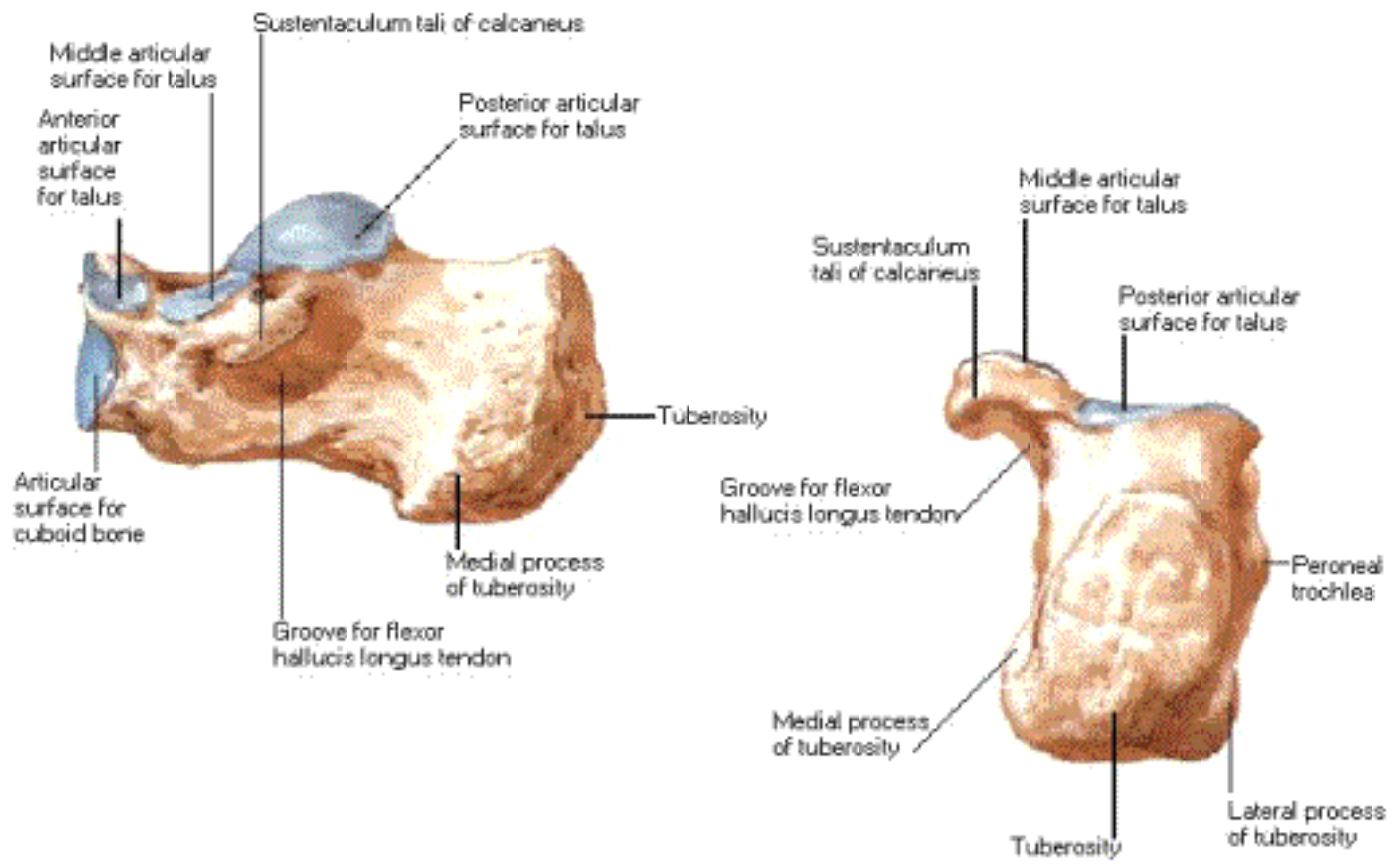
Calcaneus of Right Foot

Lateral and Superior Views



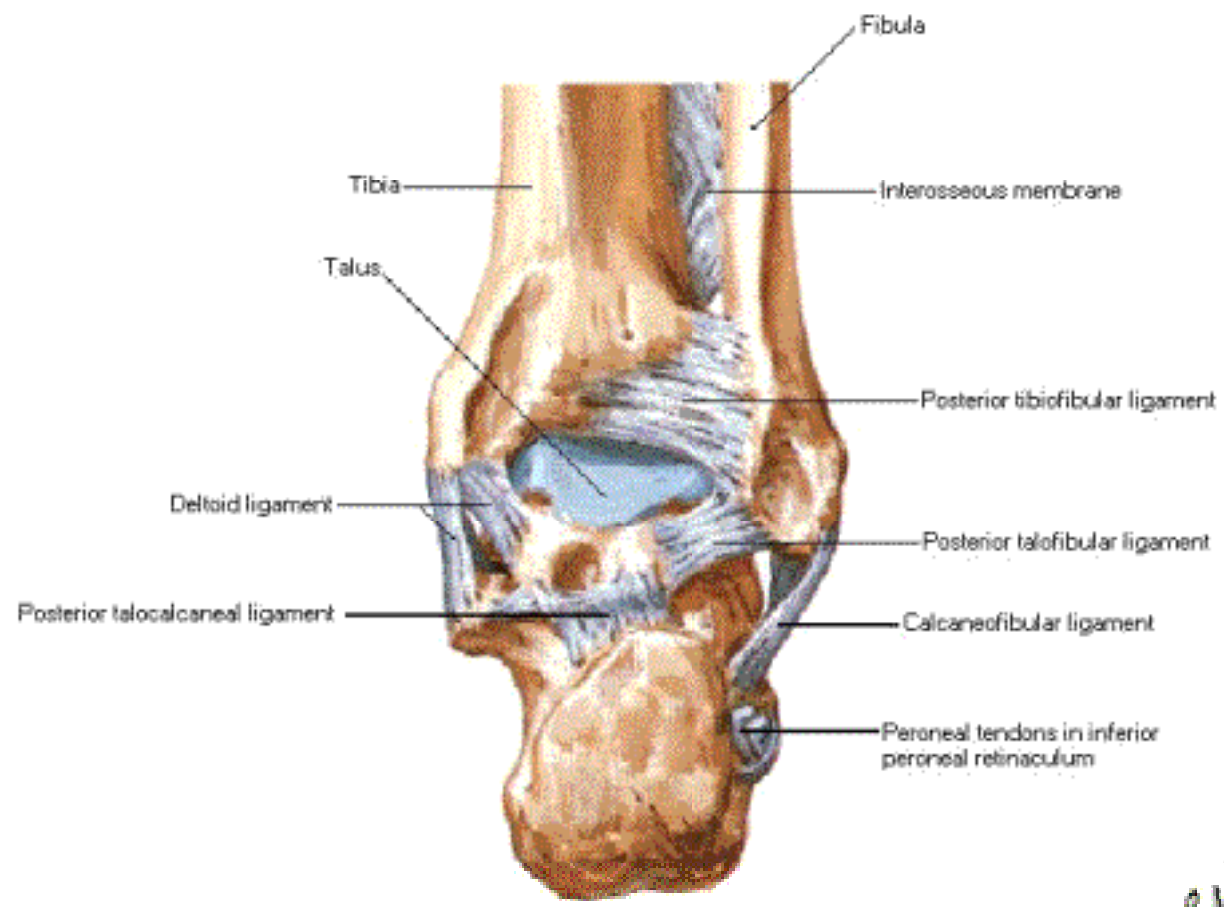
Calcaneus of Right Foot

Medial and Posterior Views

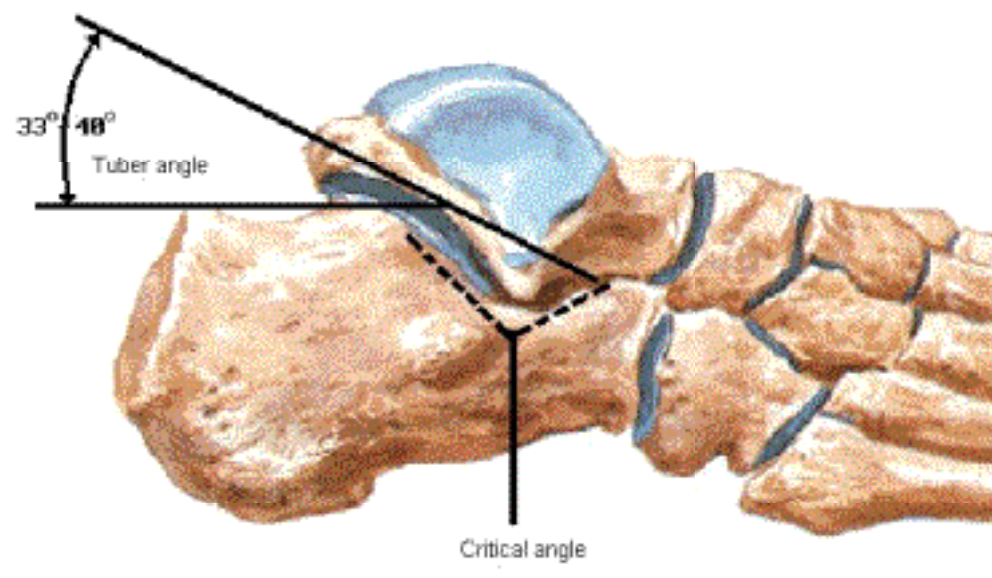


Calcaneus of Right Foot

Posterior View with Ligaments

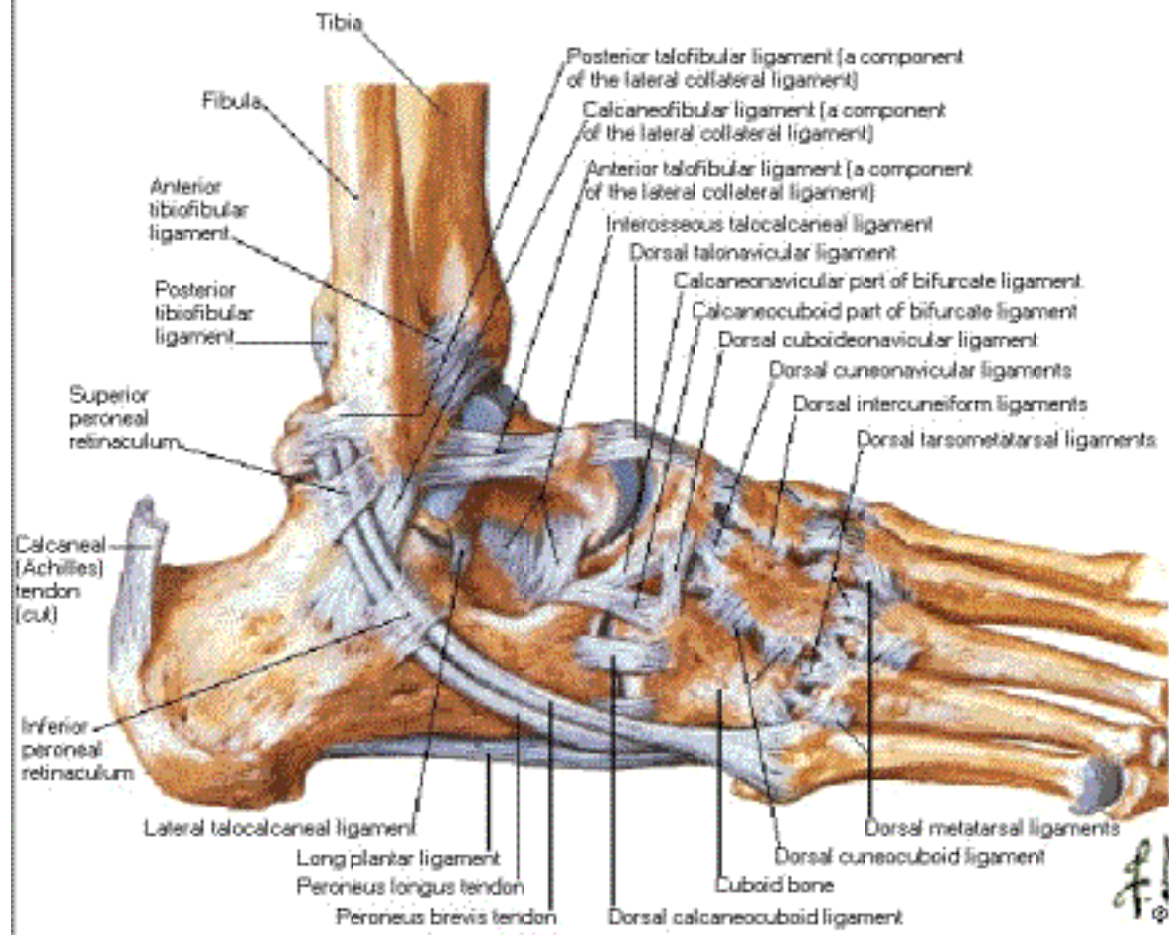


Calcaneus of Right Foot
Functional Relations of Calcaneus



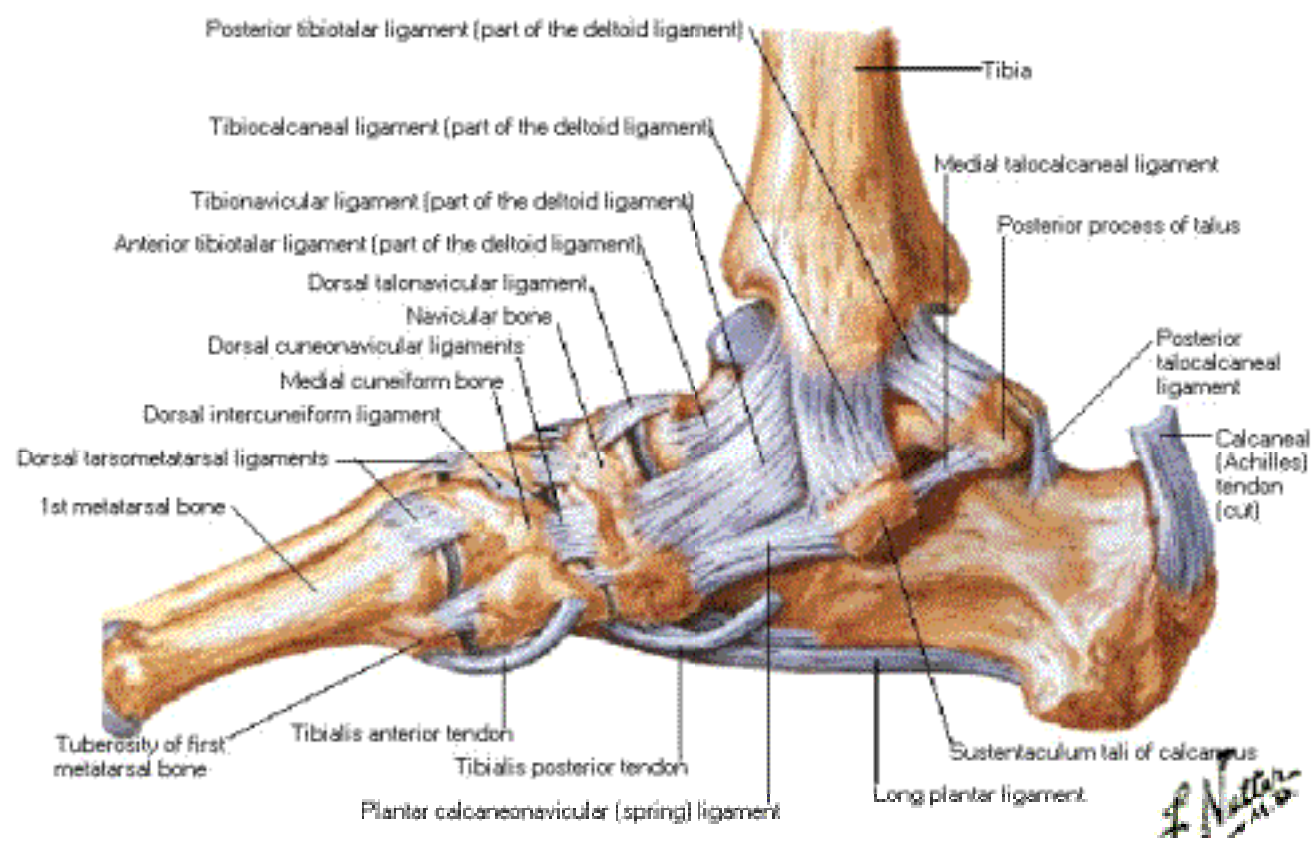
Ligaments and Tendons of Right Ankle

Lateral View



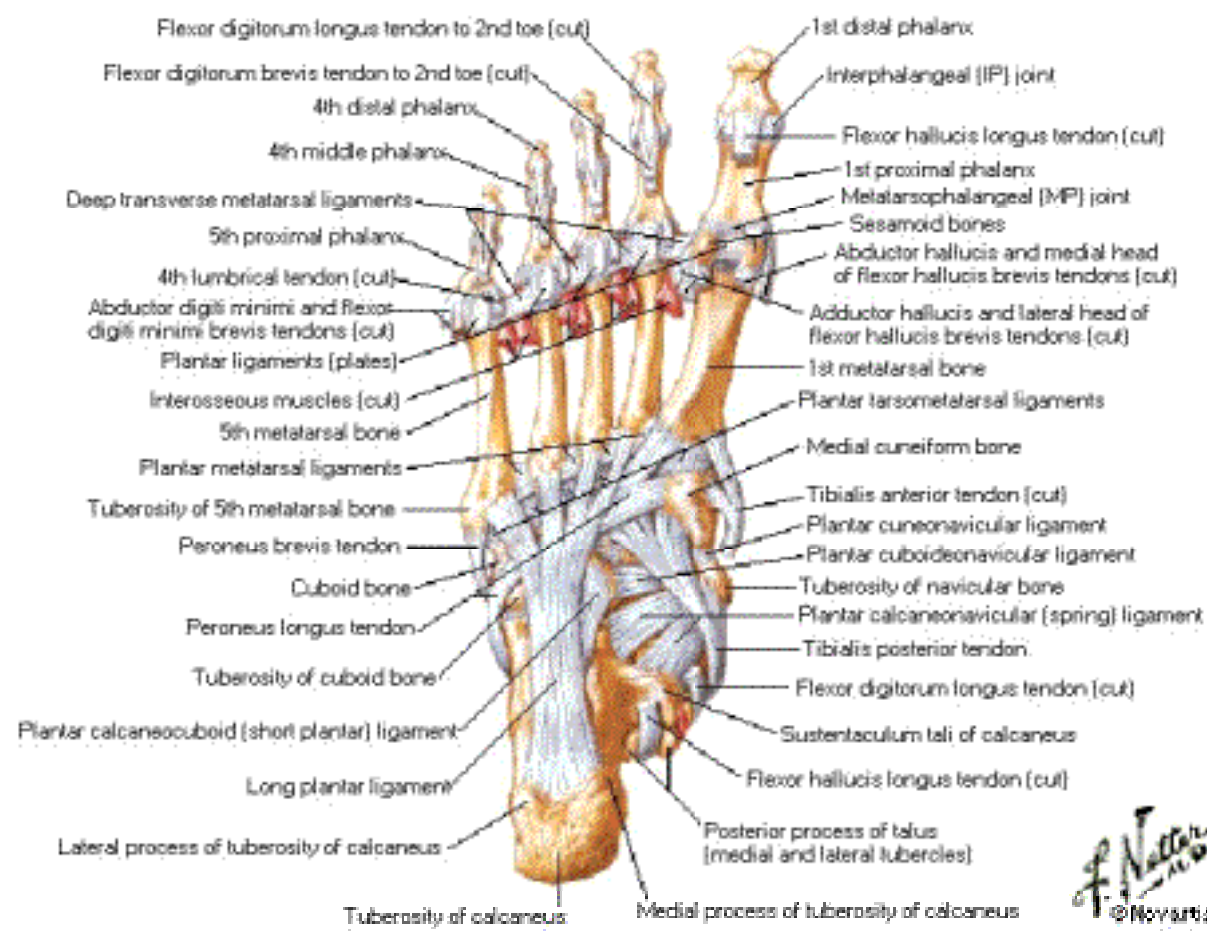
Ligaments and Tendons of Right Ankle

Medial View



Ligaments and Tendons of Foot

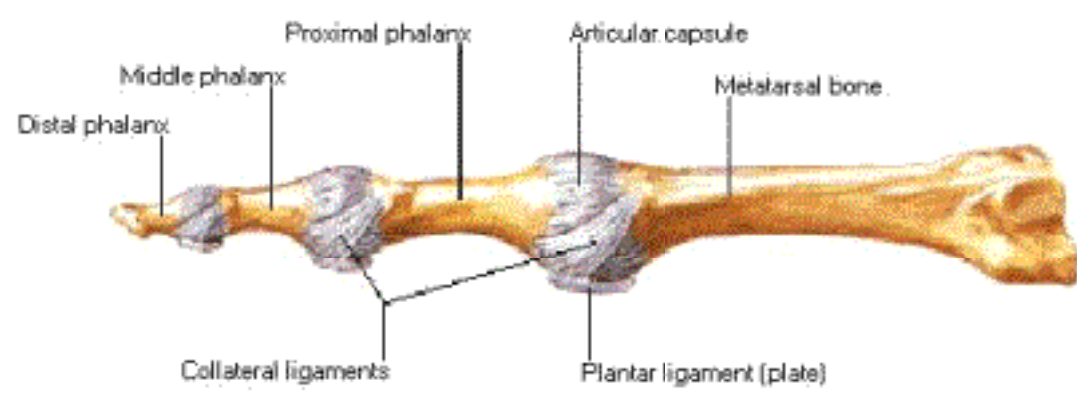
Plantar View



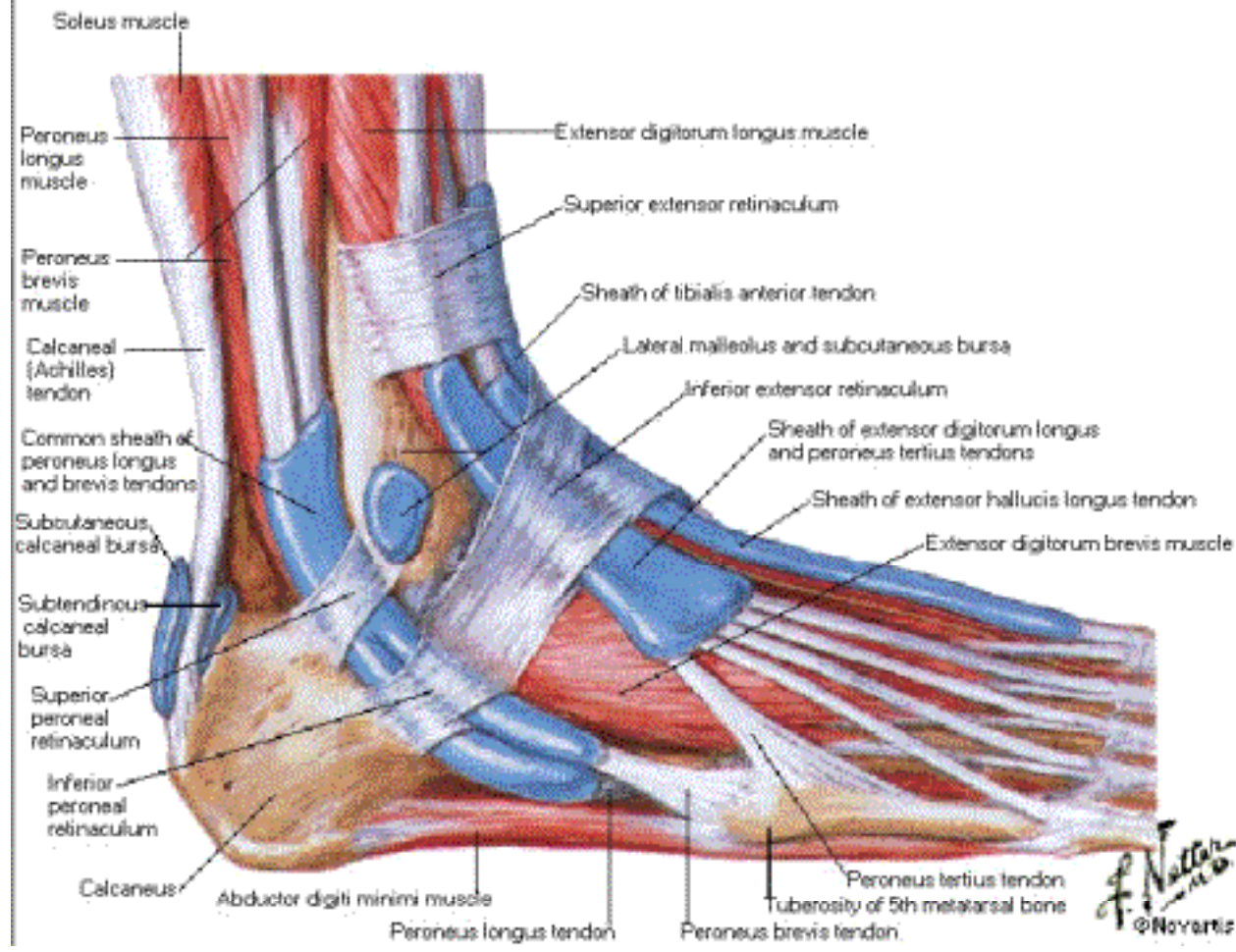
F. Netter M.D.
© 2007 Netter

Metatarsophalangeal and Interphalangeal Joints

Lateral View

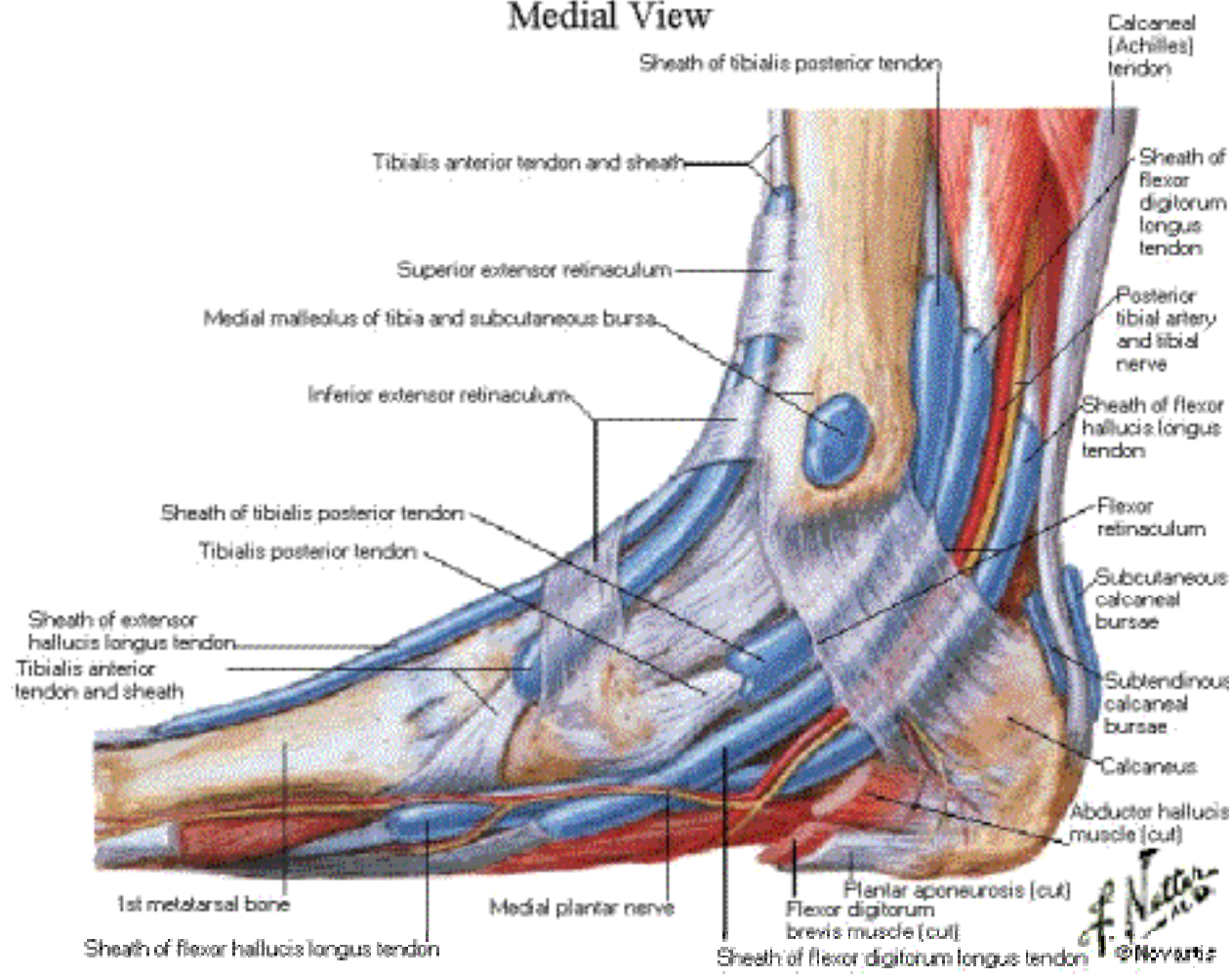


Tendon Sheaths of Ankle Lateral View



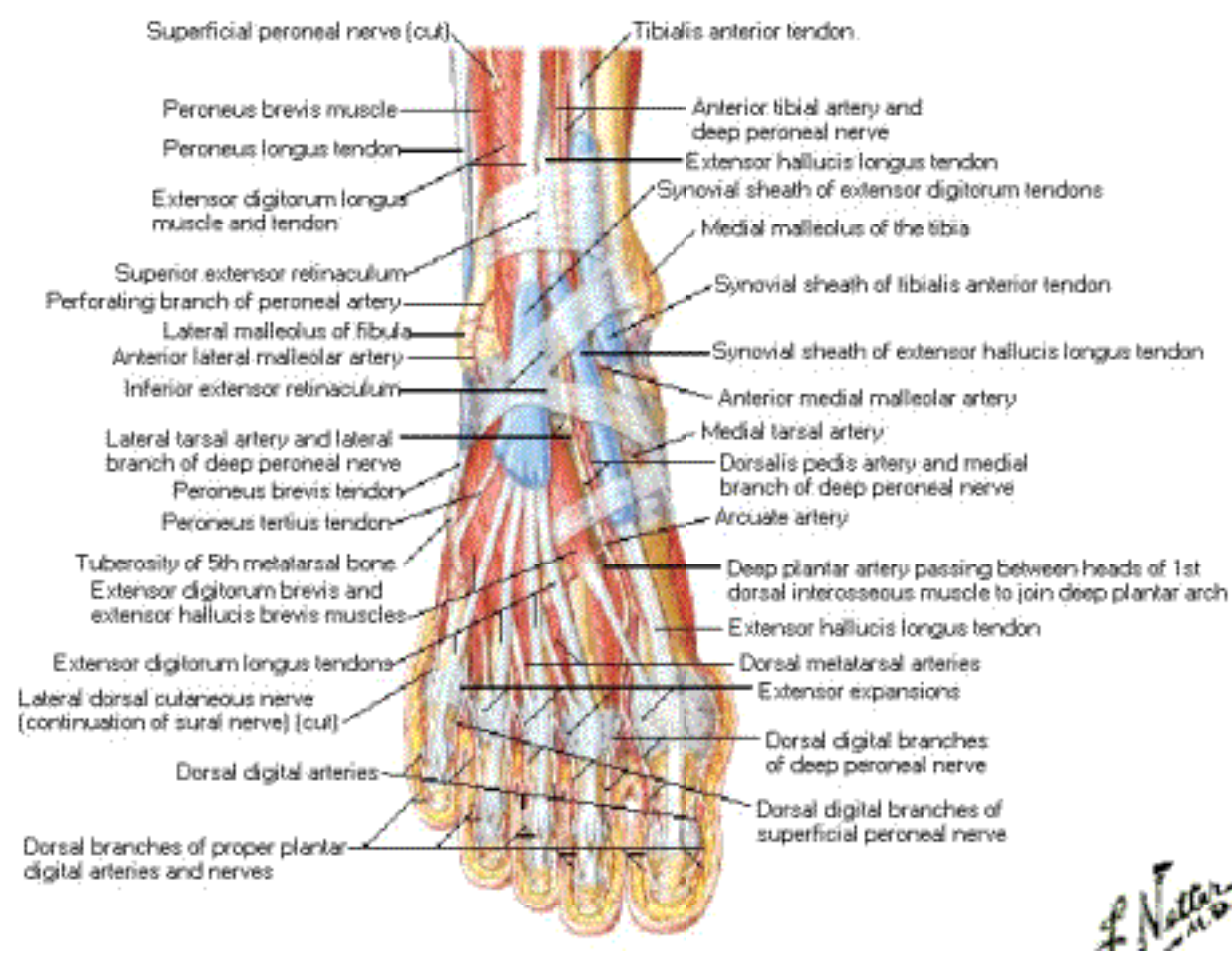
Tendon Sheaths of Ankle

Medial View



Muscles of Dorsum of Foot

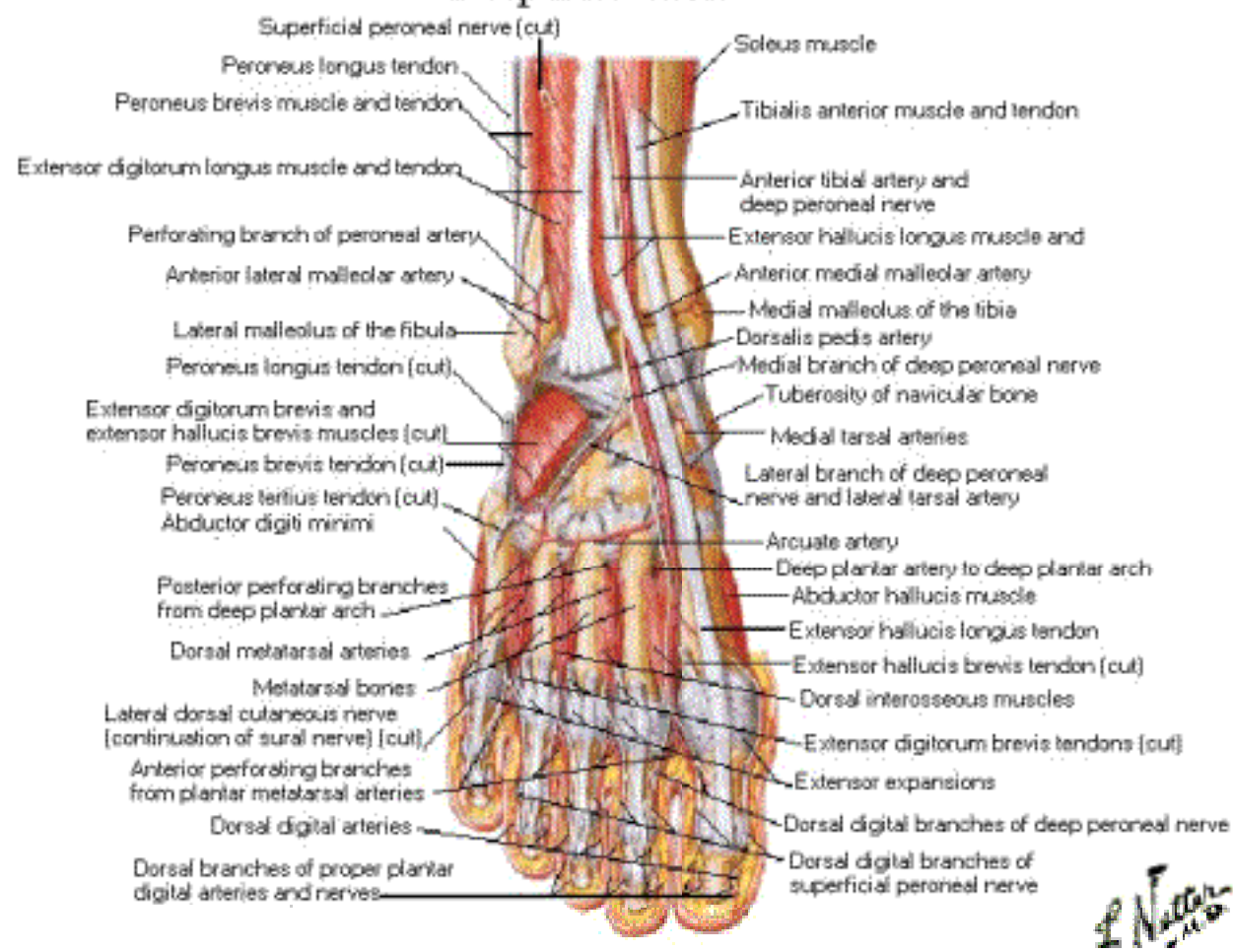
Superficial Dissection



L. Natter

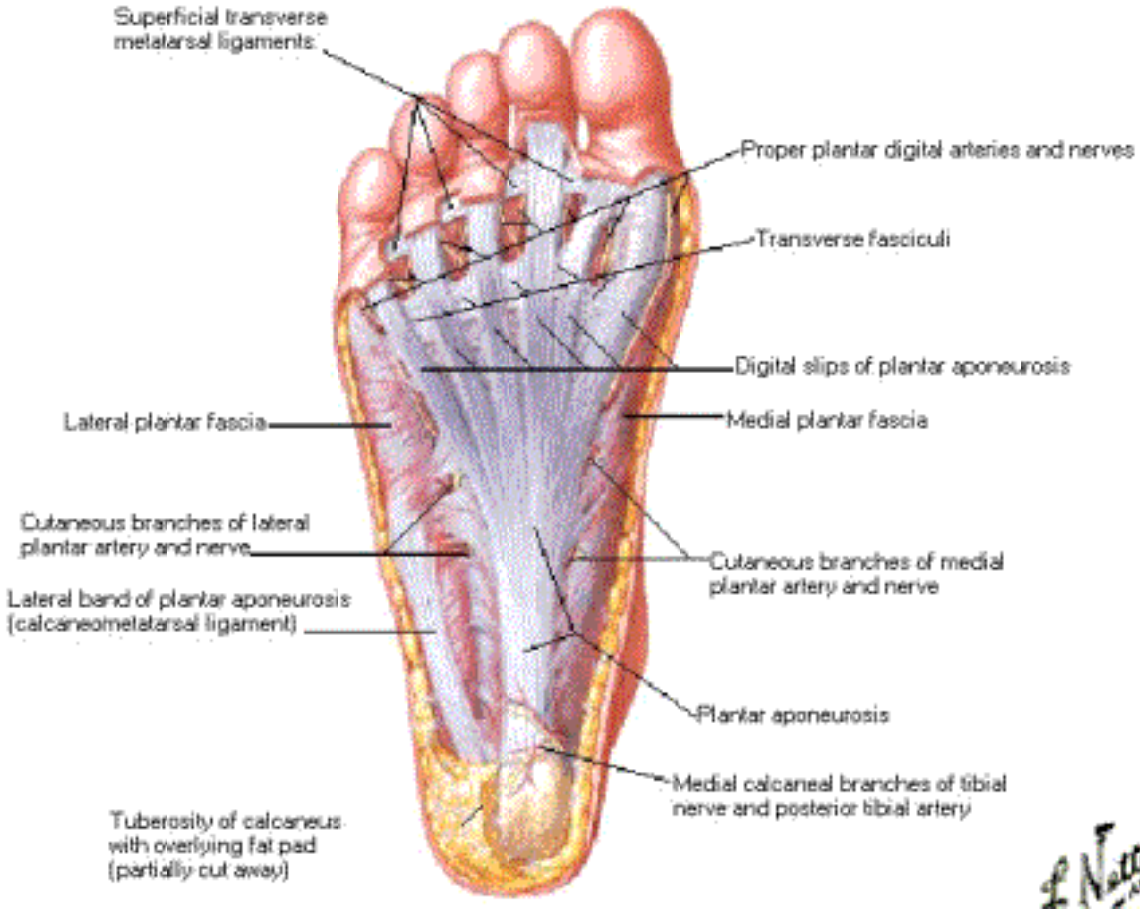
Dorsum of Foot

Deep Dissection



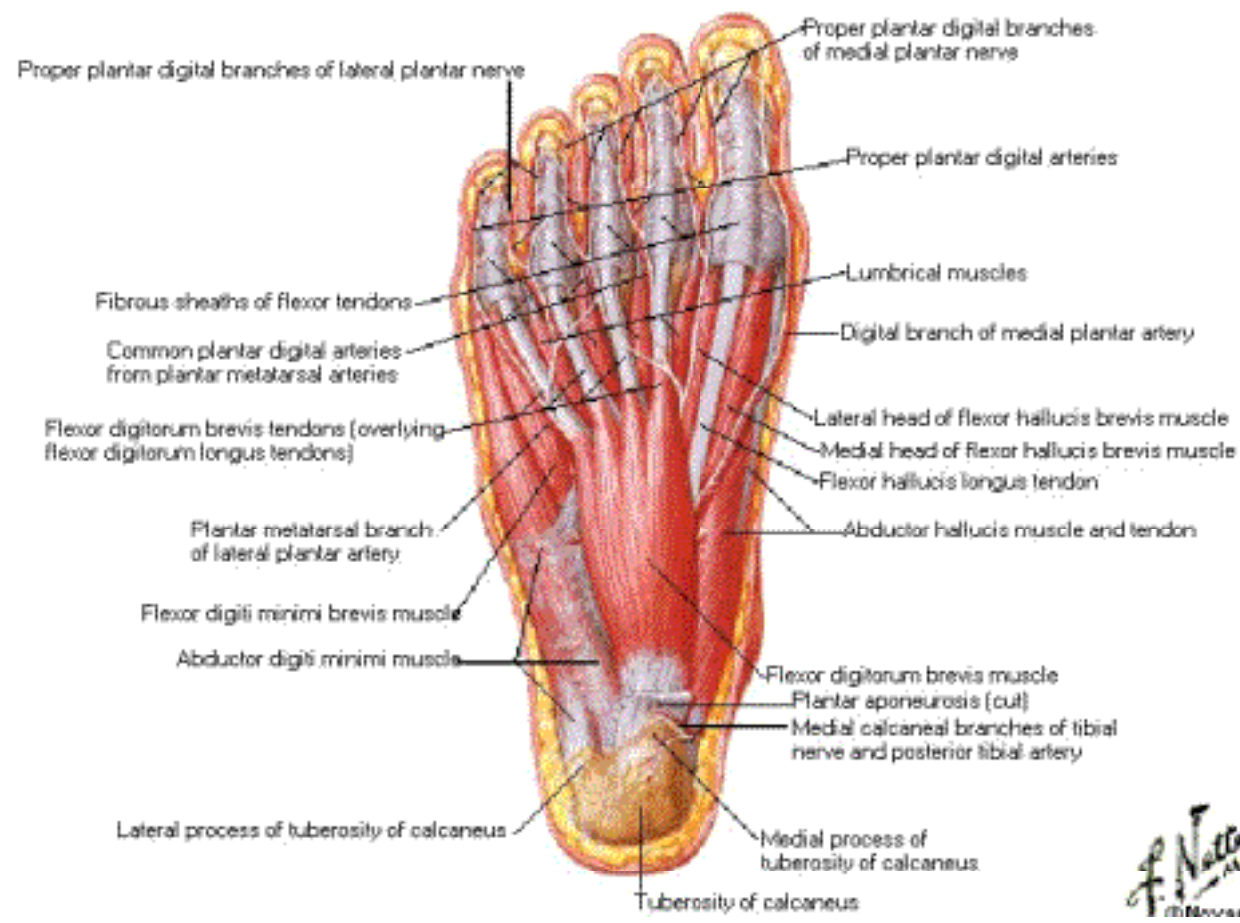
Sole of Foot

Superficial Dissection



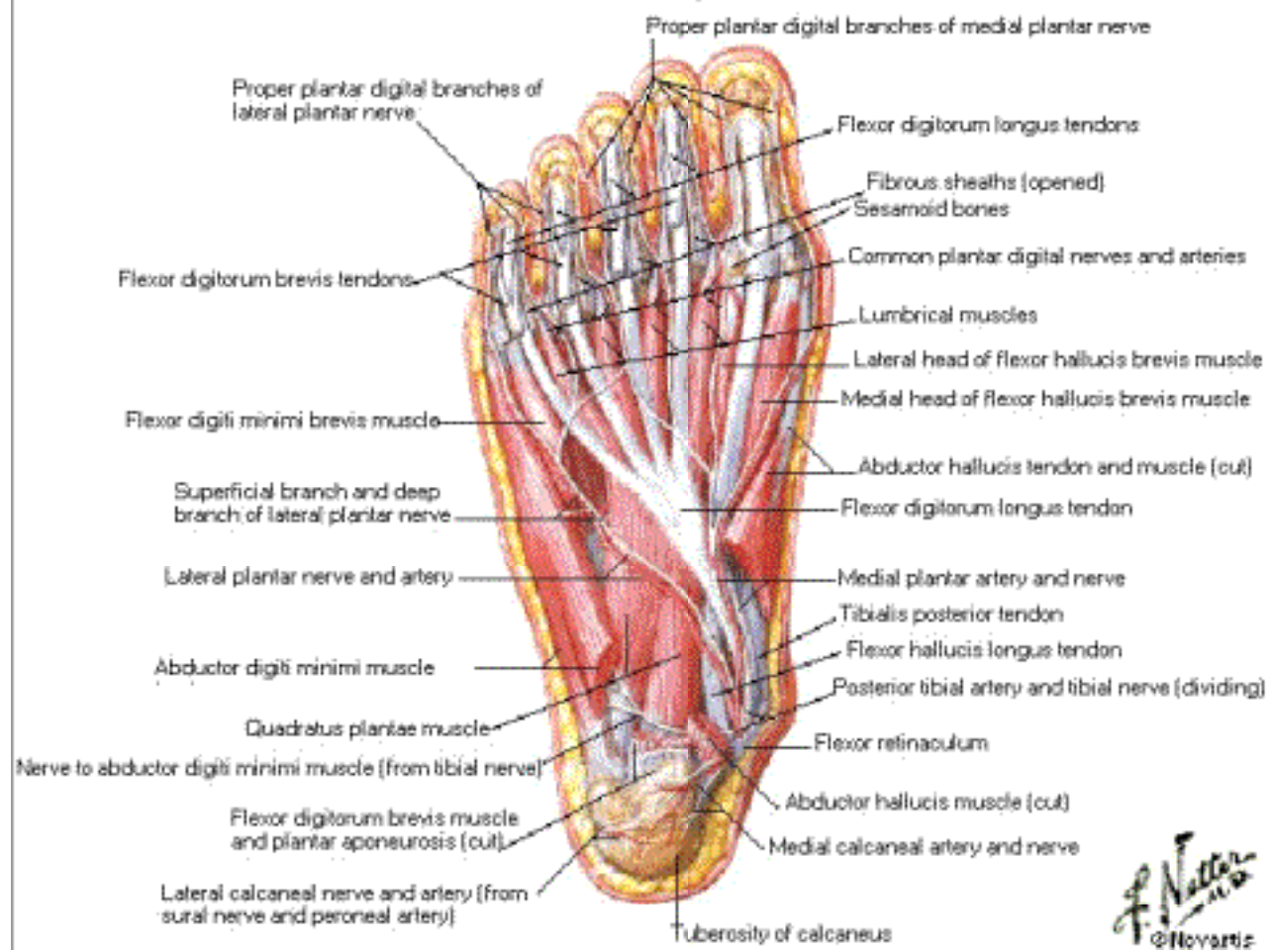
Muscles of Sole of Foot

First Layer



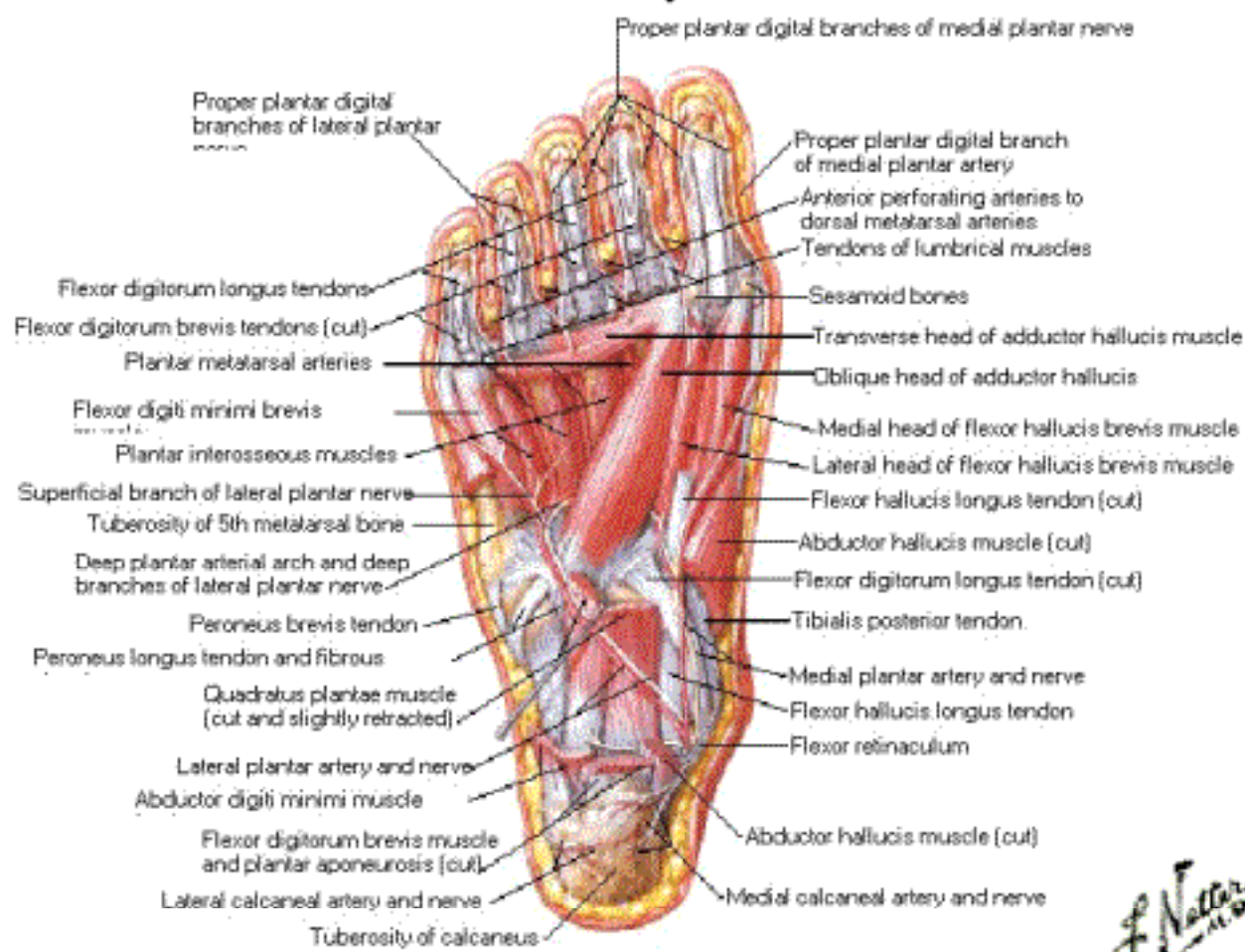
Muscles of Sole of Foot

Second Layer



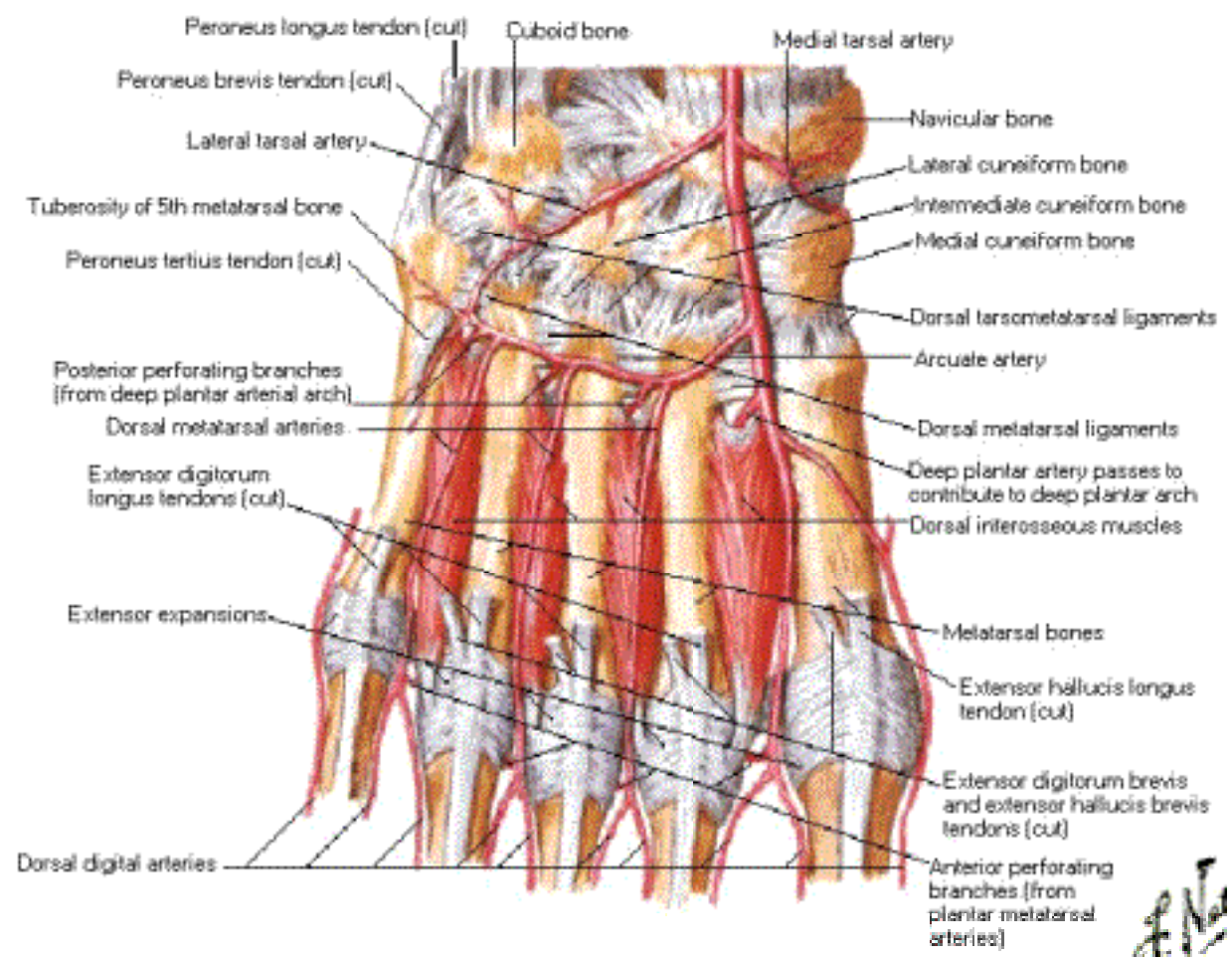
Muscles of Sole of Foot

Third Layer



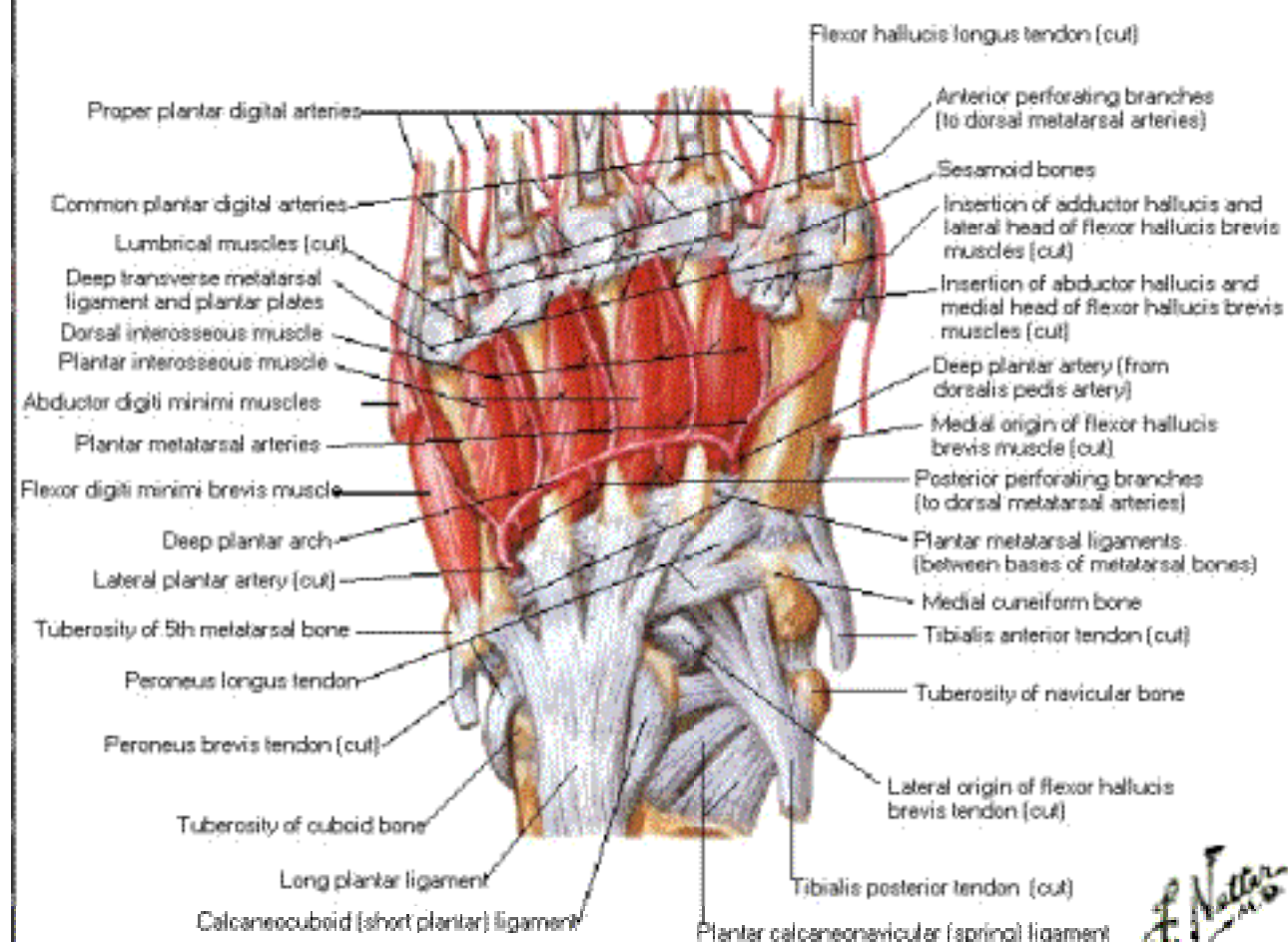
Interosseous Muscles and Deep Arteries of Foot

Dorsal View



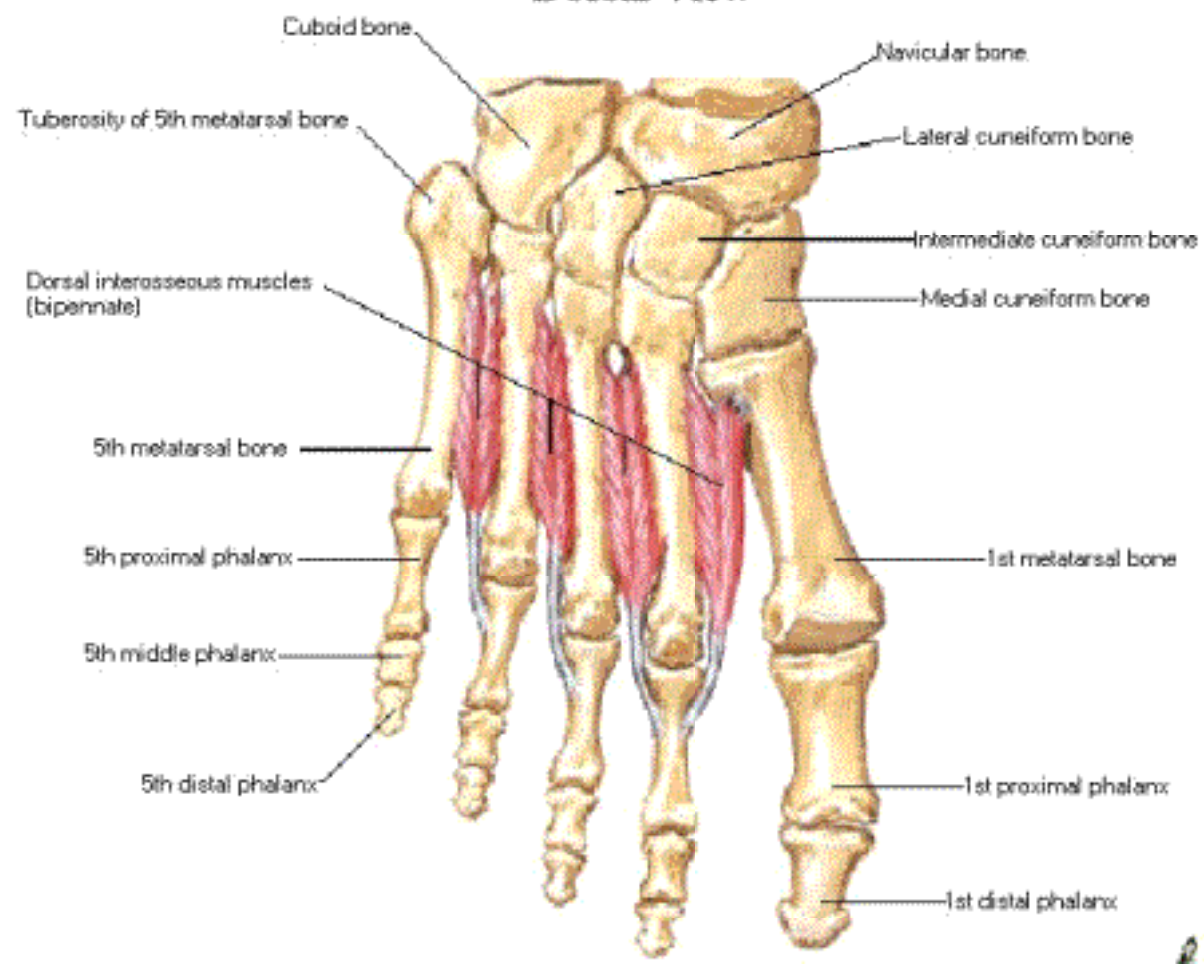
Interosseous Muscles and Deep Arteries of Foot

Plantar View



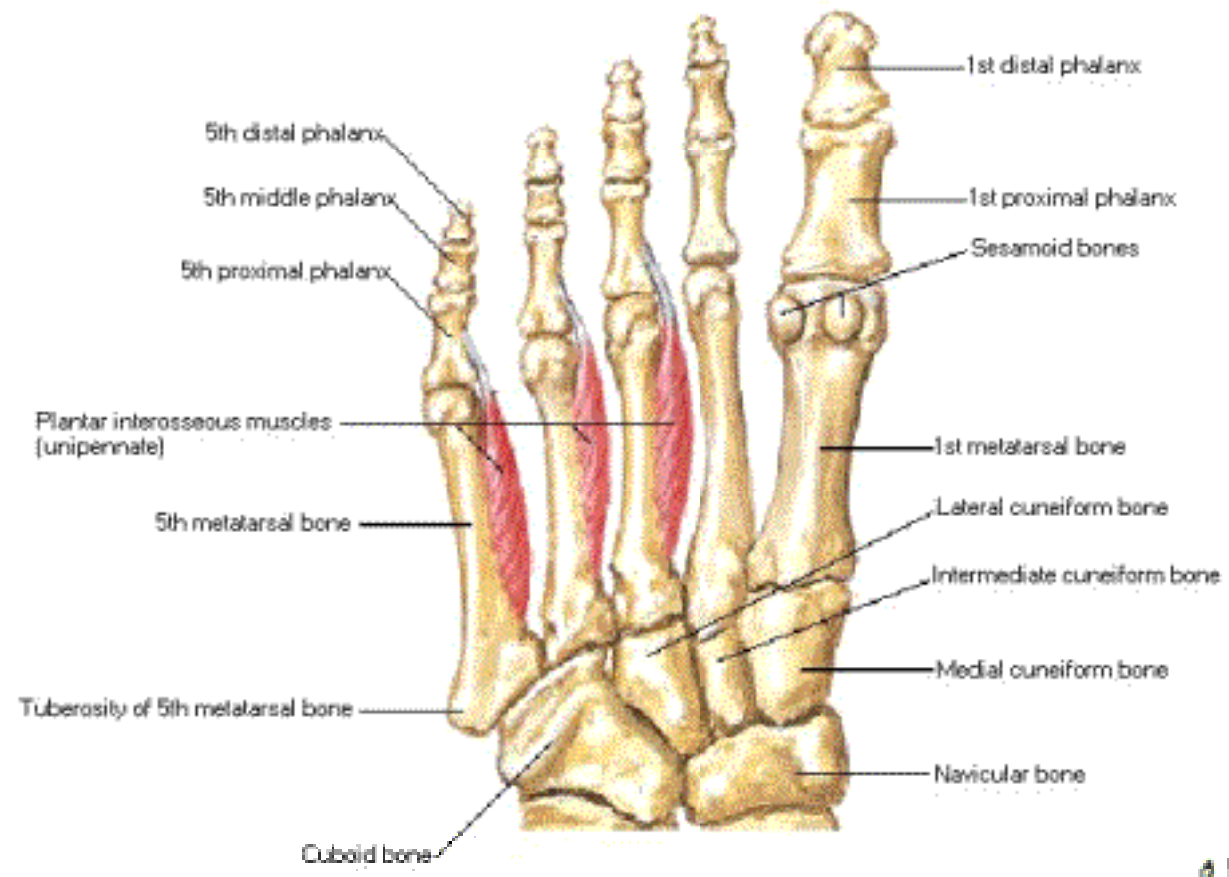
Interosseous Muscles of Foot

Dorsal View

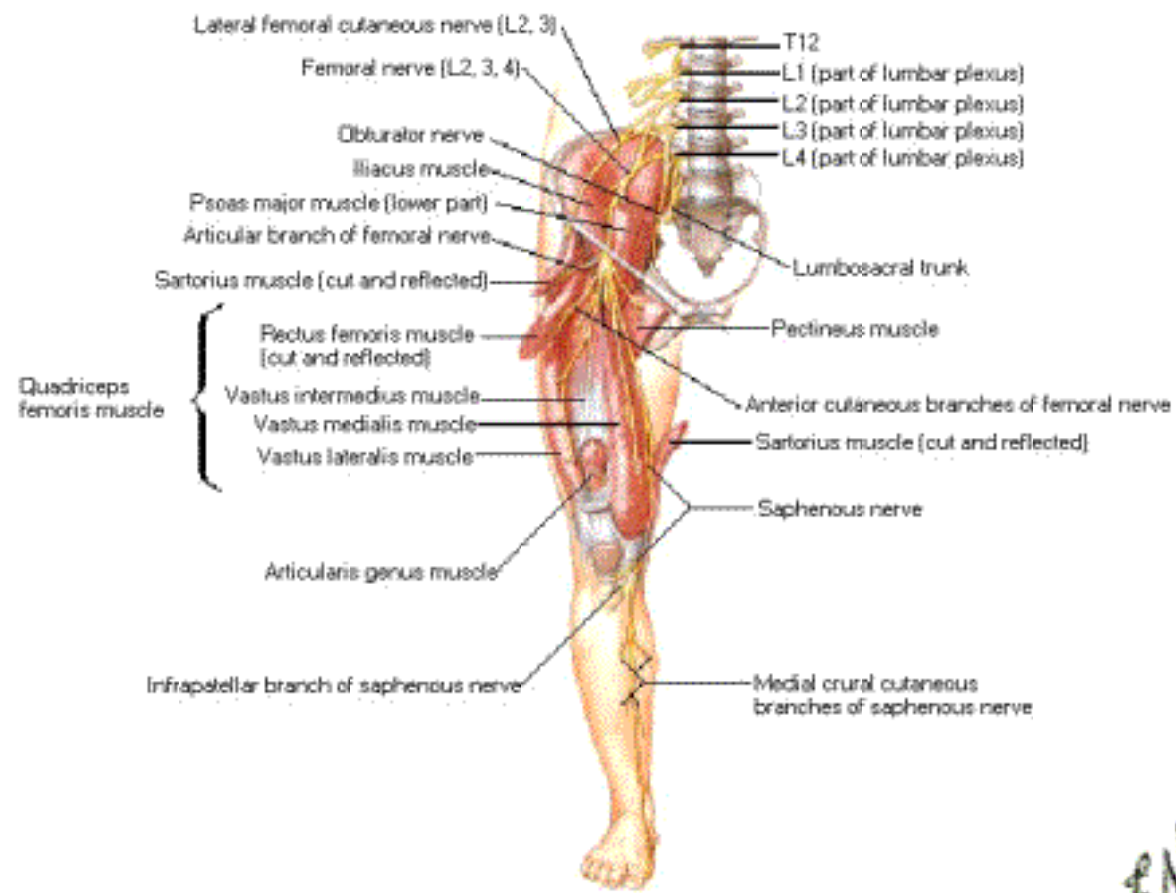


Interosseous Muscles of Foot

Plantar View



Femoral and Lateral Femoral Cutaneous Nerves

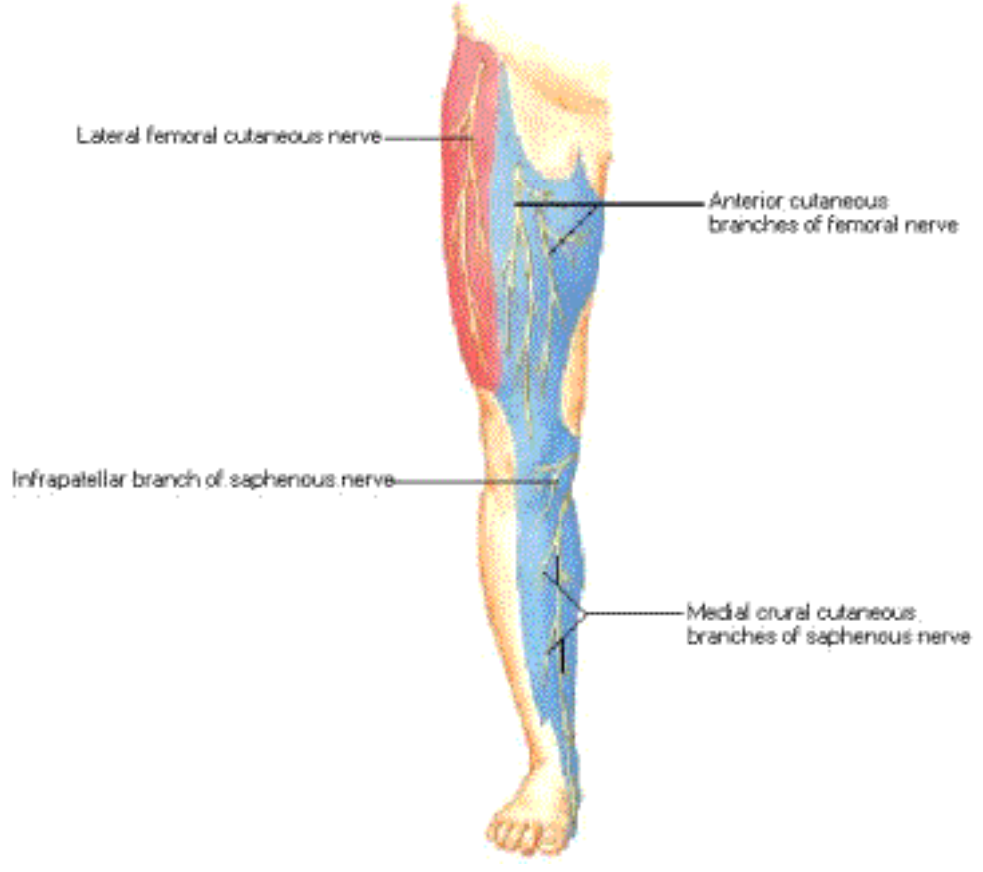


Note: only muscles innervated by femoral nerve shown

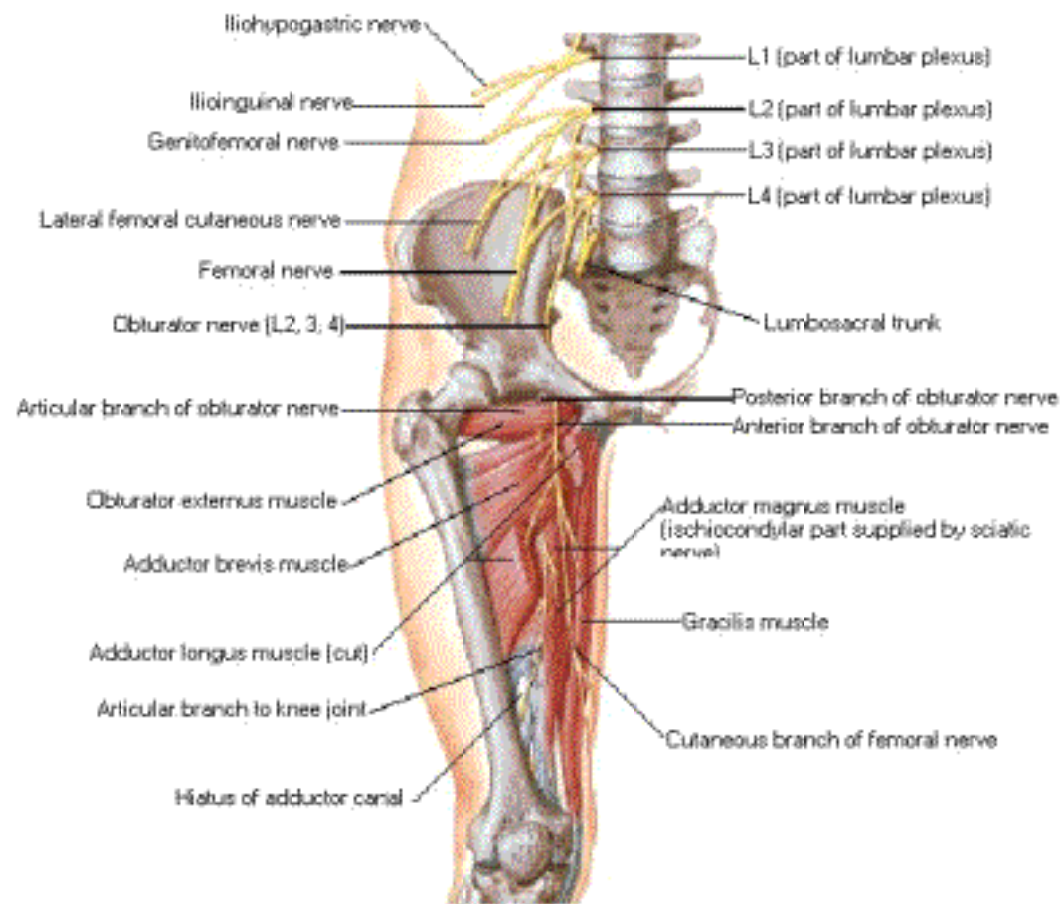


Femoral and Lateral Femoral Cutaneous Nerves

Cutaneous Innervation

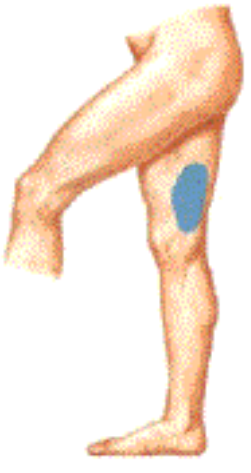

Obturator Nerve

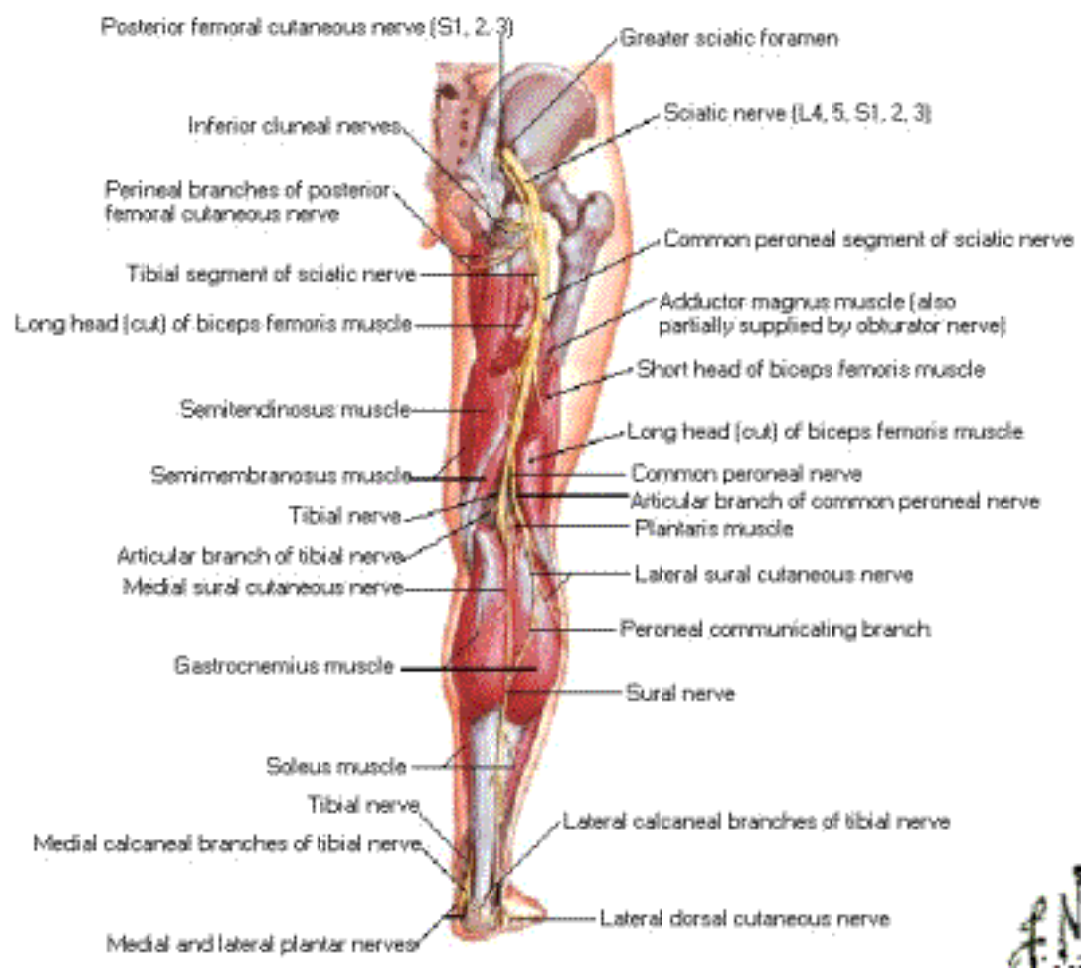


Note: only muscles innervated by obturator nerve shown

Obturator Nerve
Cutaneous Innervation

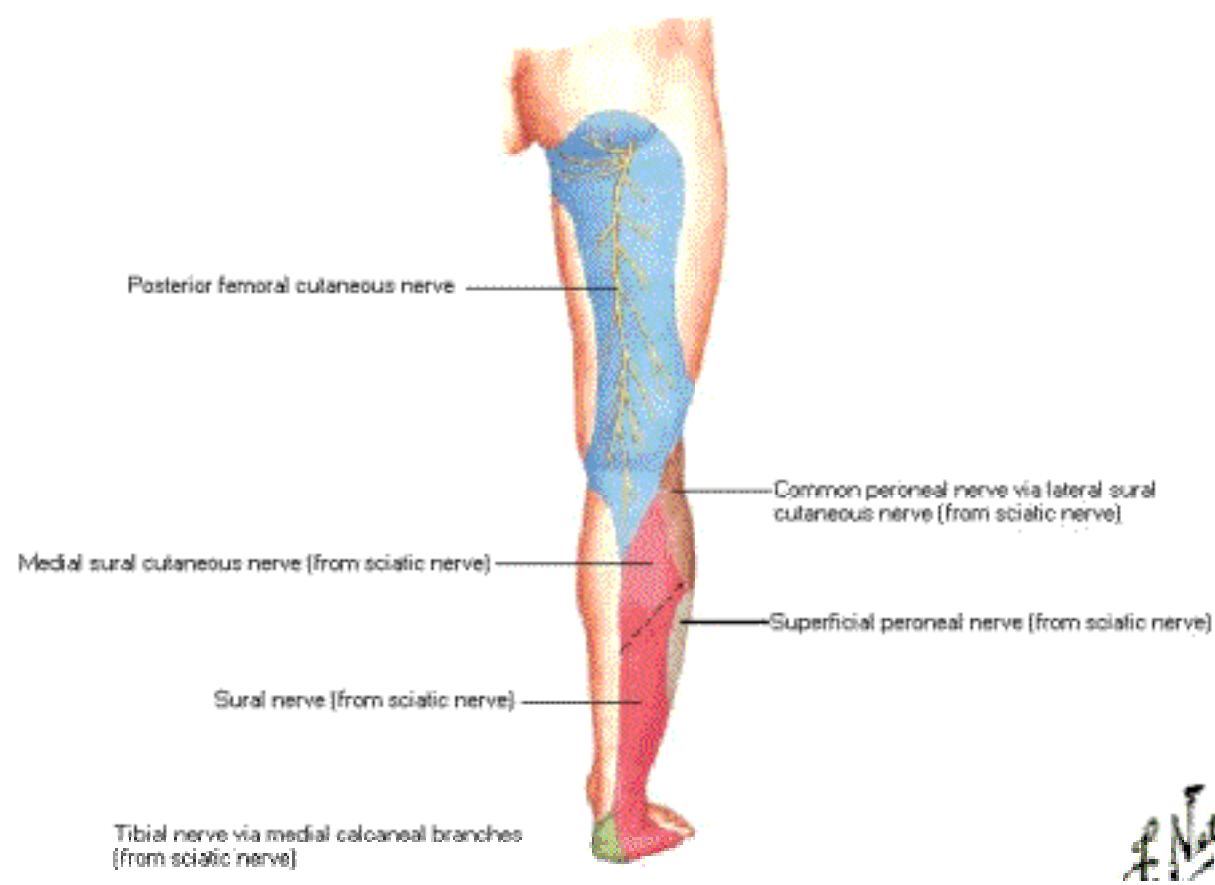


Sciatic and Posterior Femoral Cutaneous Nerves

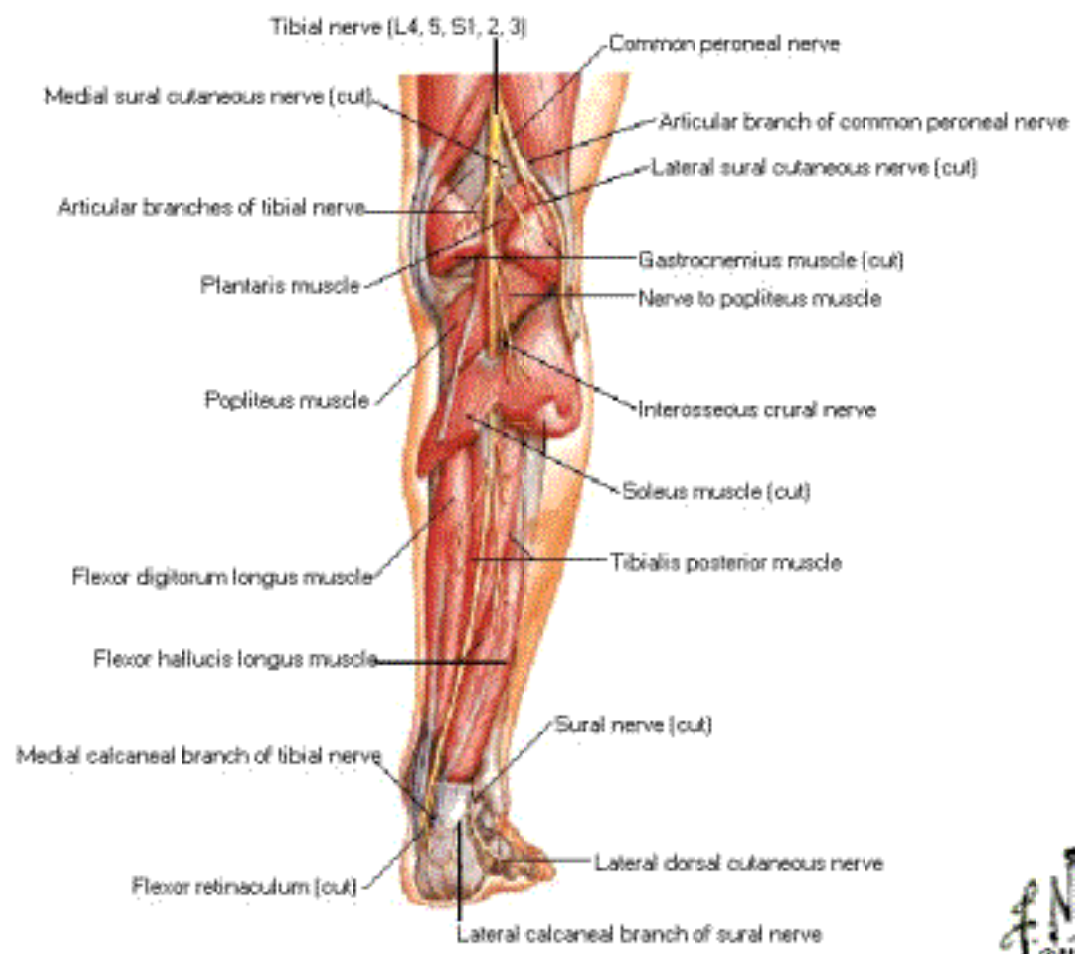


Sciatic and Posterior Femoral Cutaneous Nerves

Cutaneous Innervation

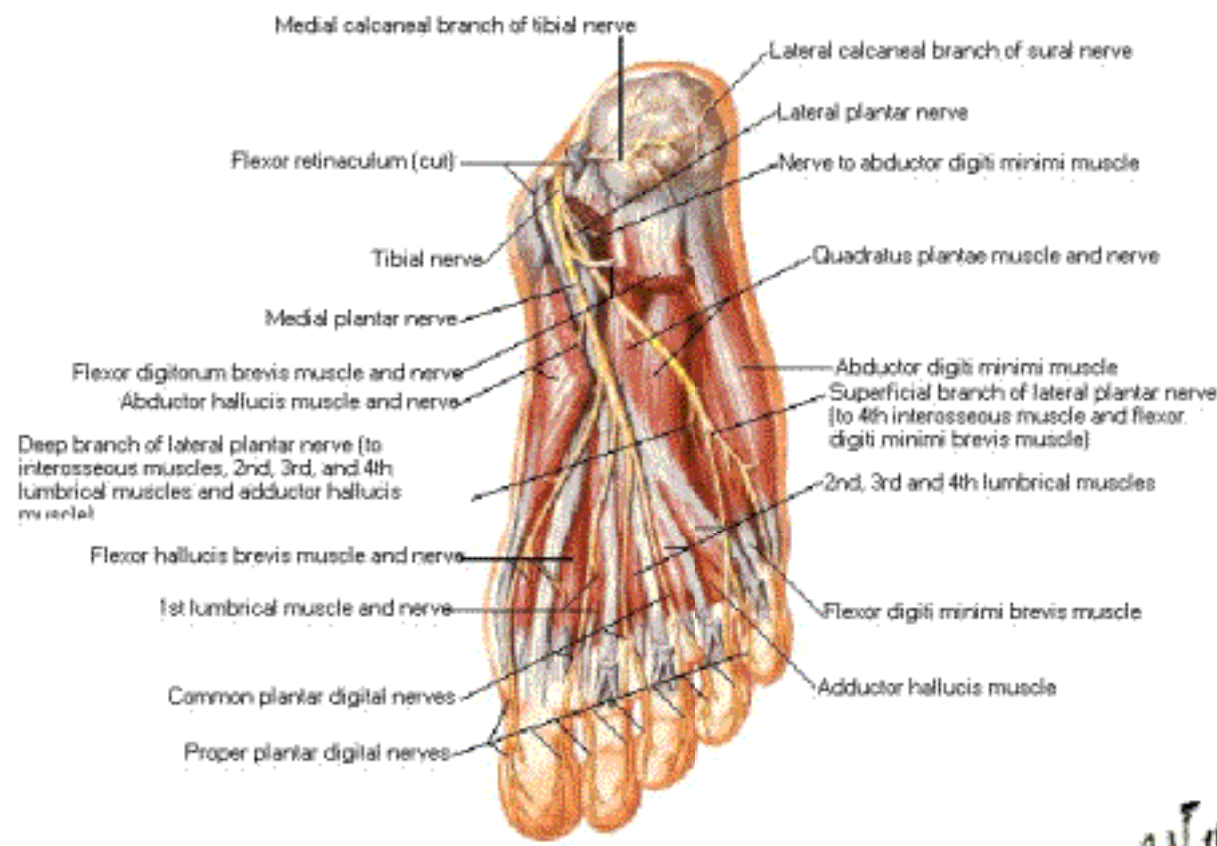


Tibial Nerve



FN

Tibial Nerve Plantar View

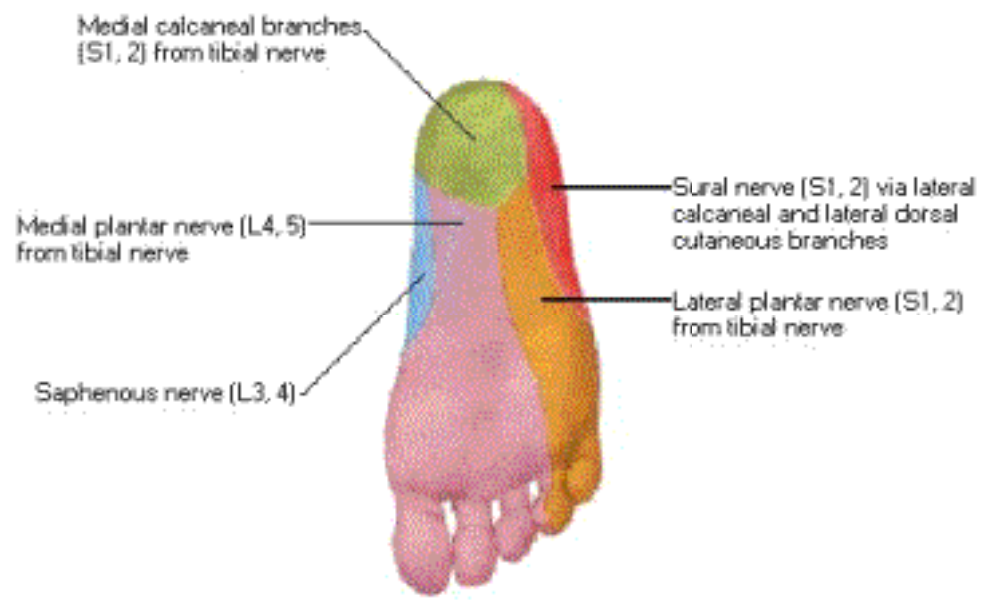


Note: articular branches not shown

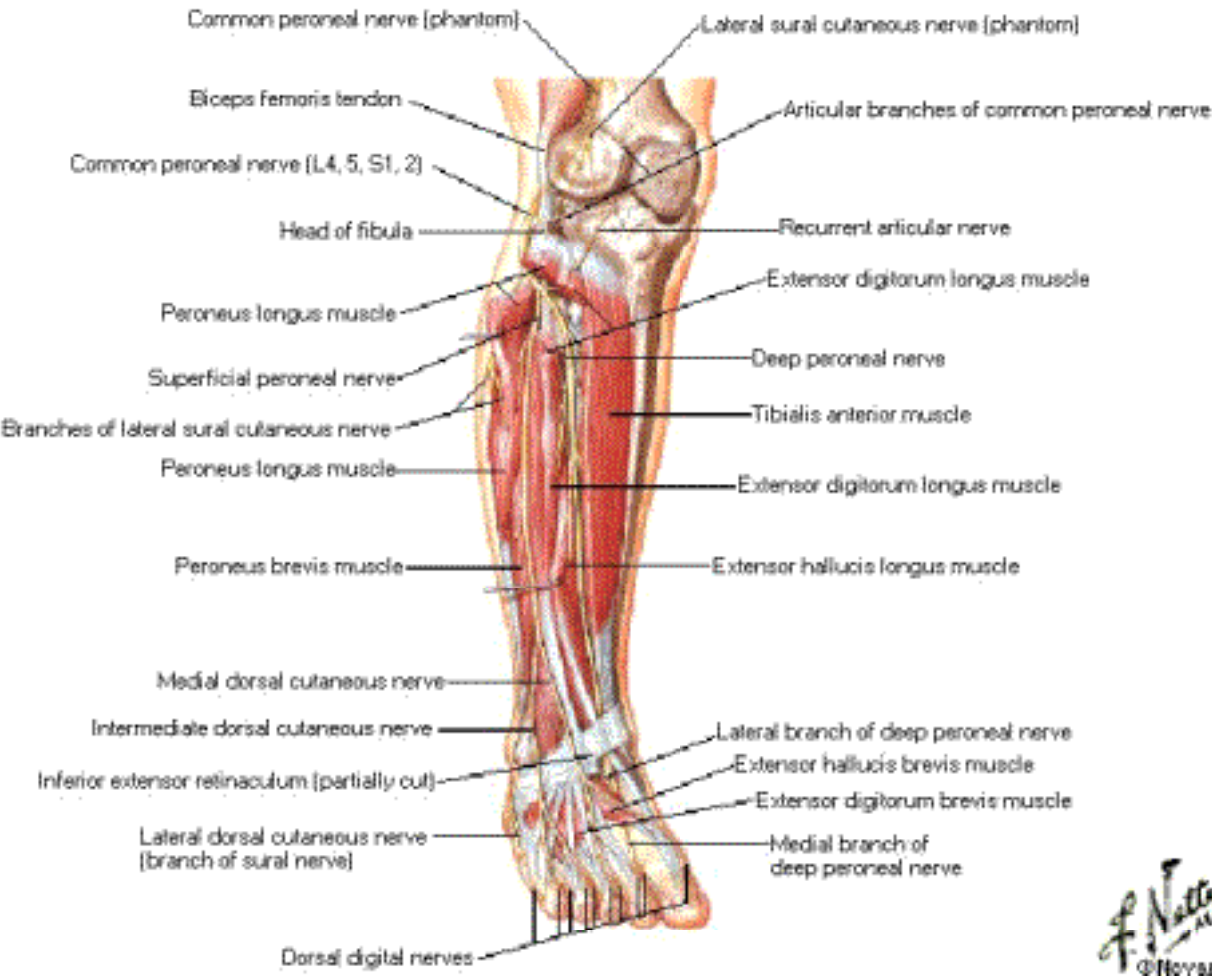
F. Netter
© Nova

Tibial Nerve

Cutaneous Innervation of Sole of Foot



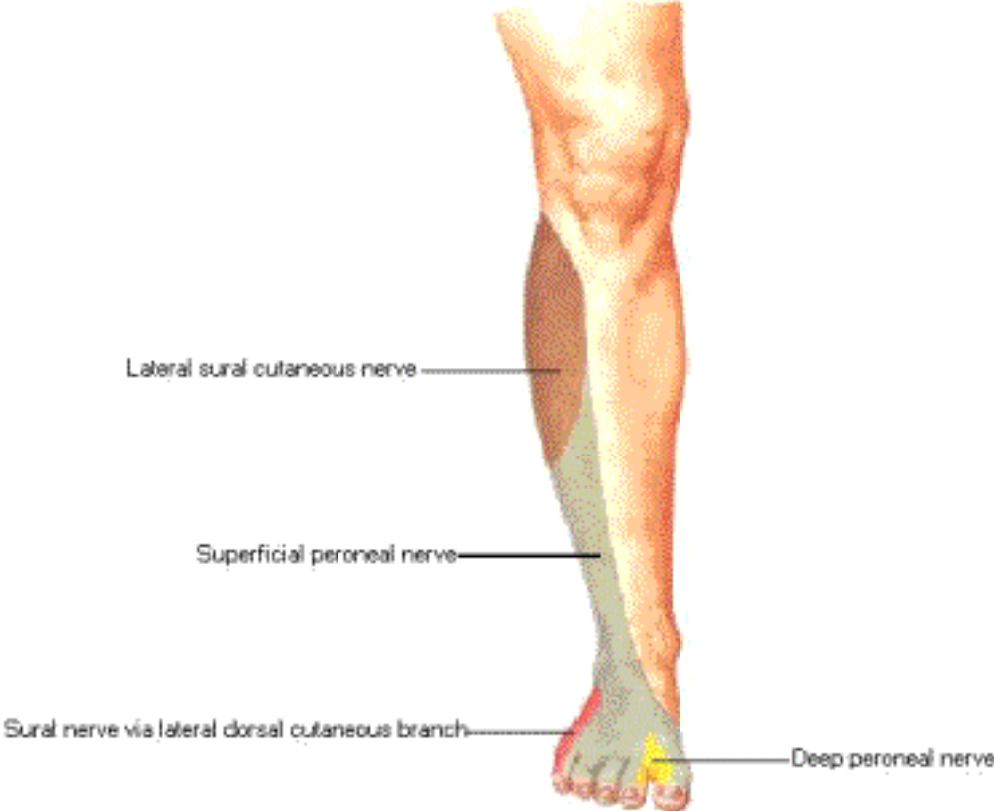
Common Peroneal Nerve



F. Netto
© Novar

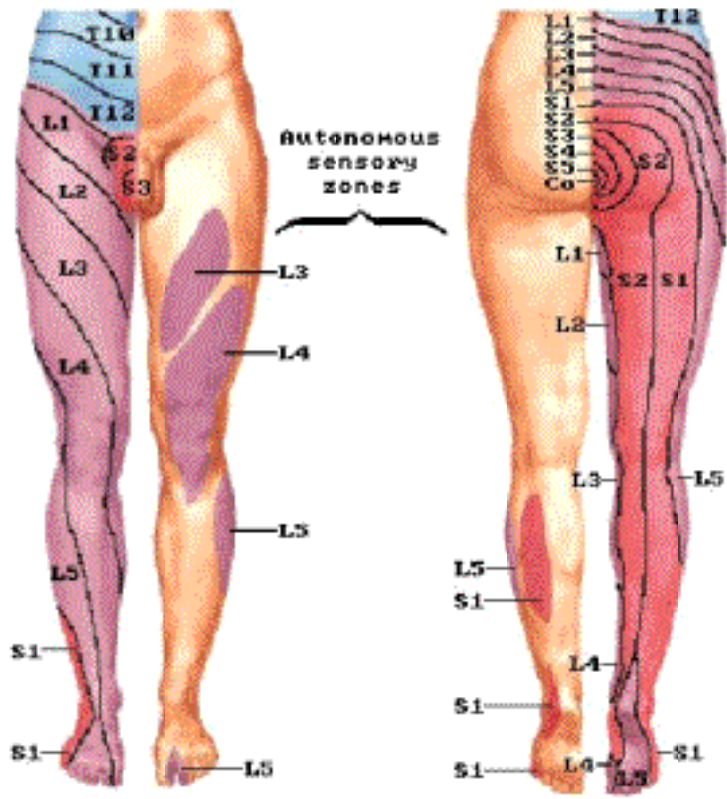
Common Peroneal Nerve

Cutaneous Innervation

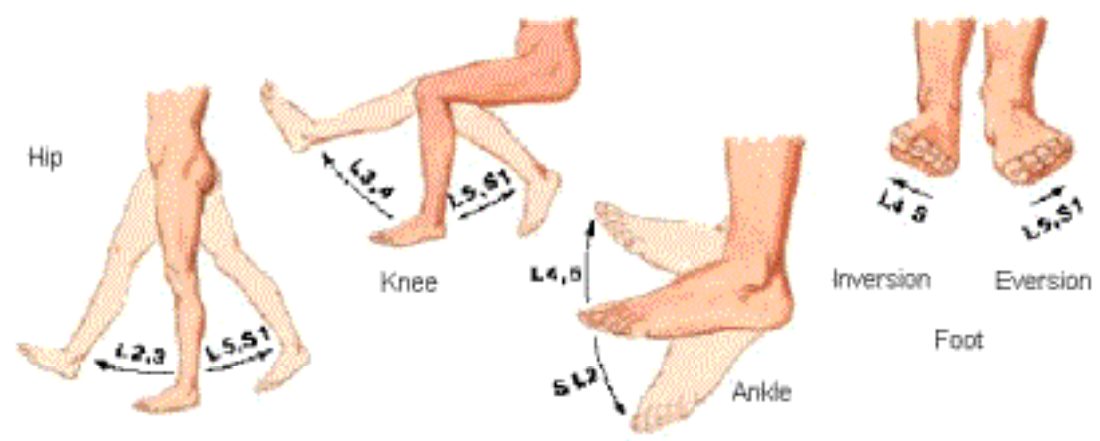


Dermatomes of Lower Limb

Anterior and Posterior Views

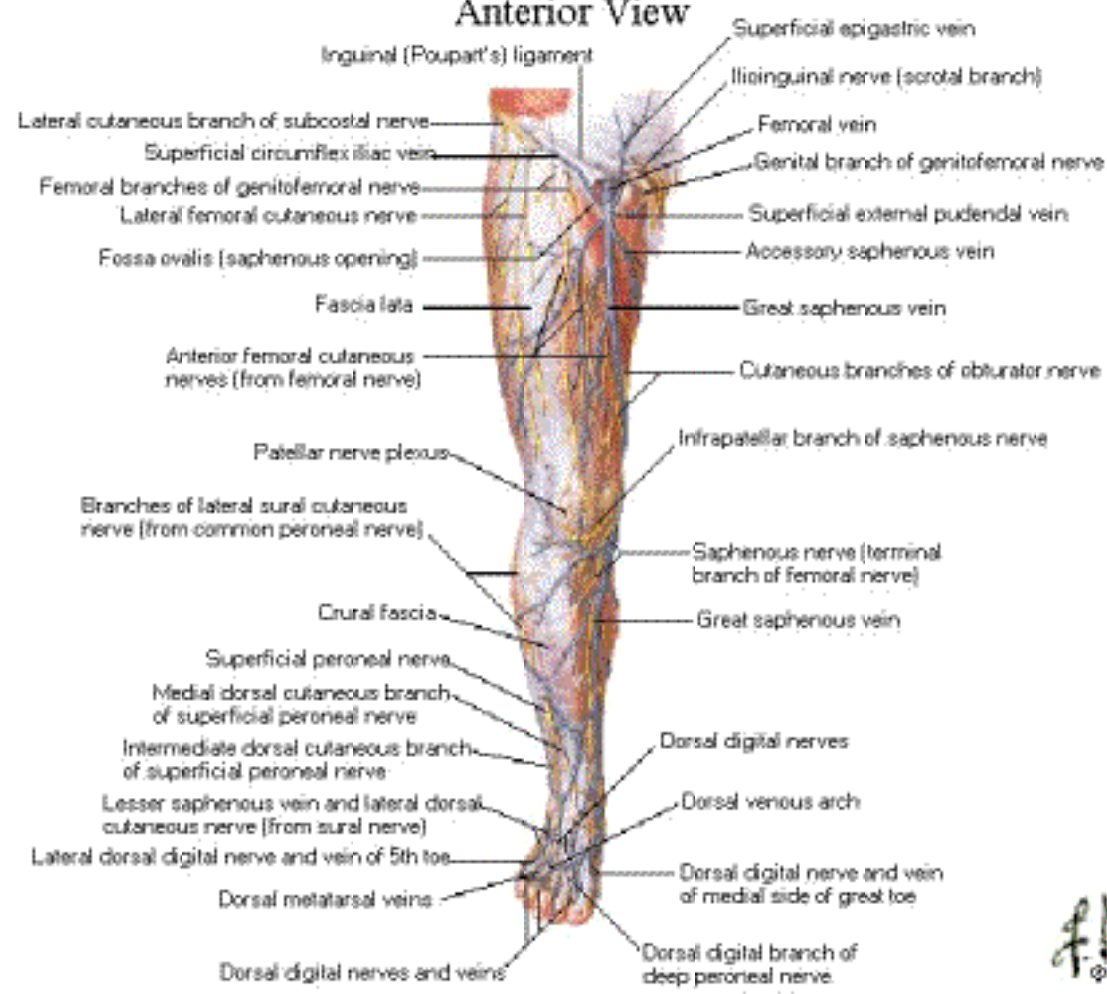


Segmental Innervation of Lower Limb Movements



Superficial Nerves and Veins of Lower Limb

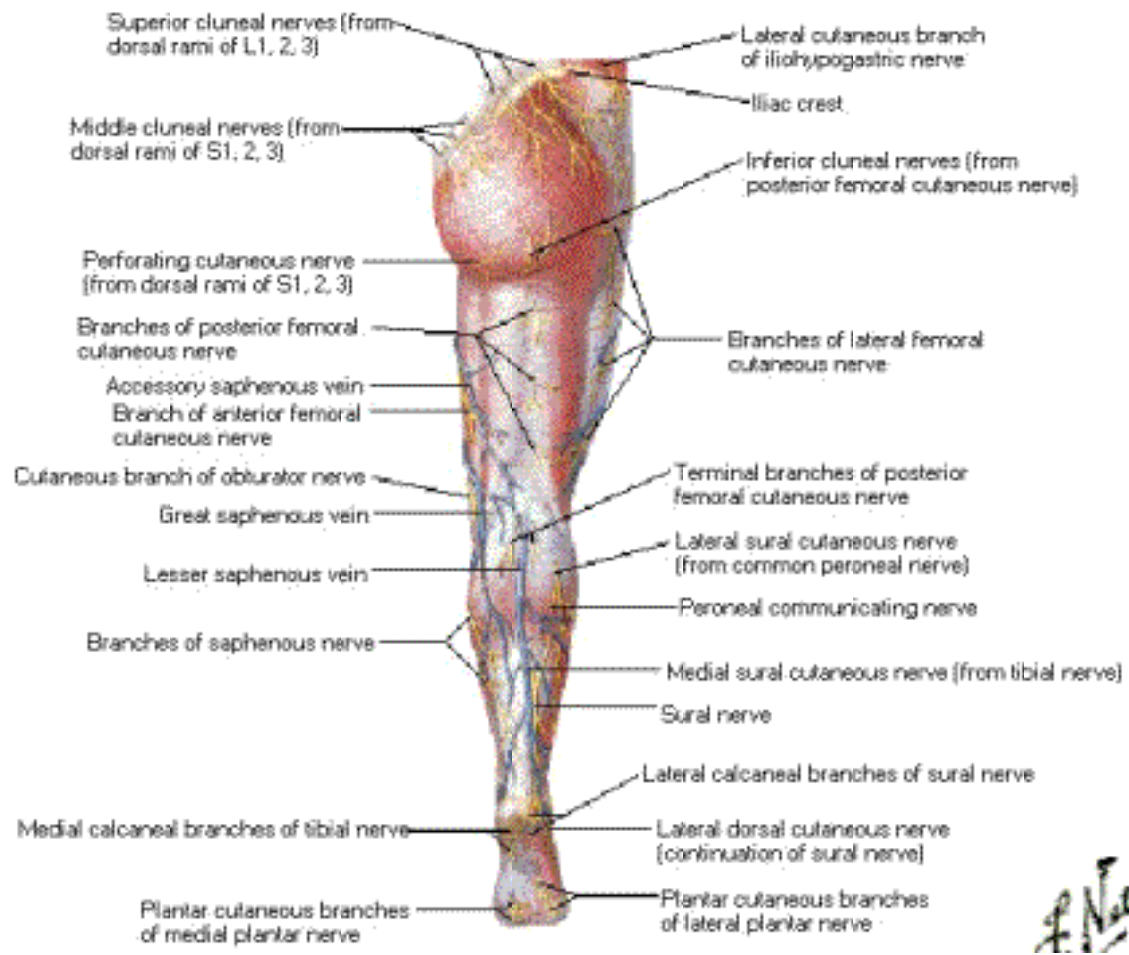
Anterior View



FN
©N

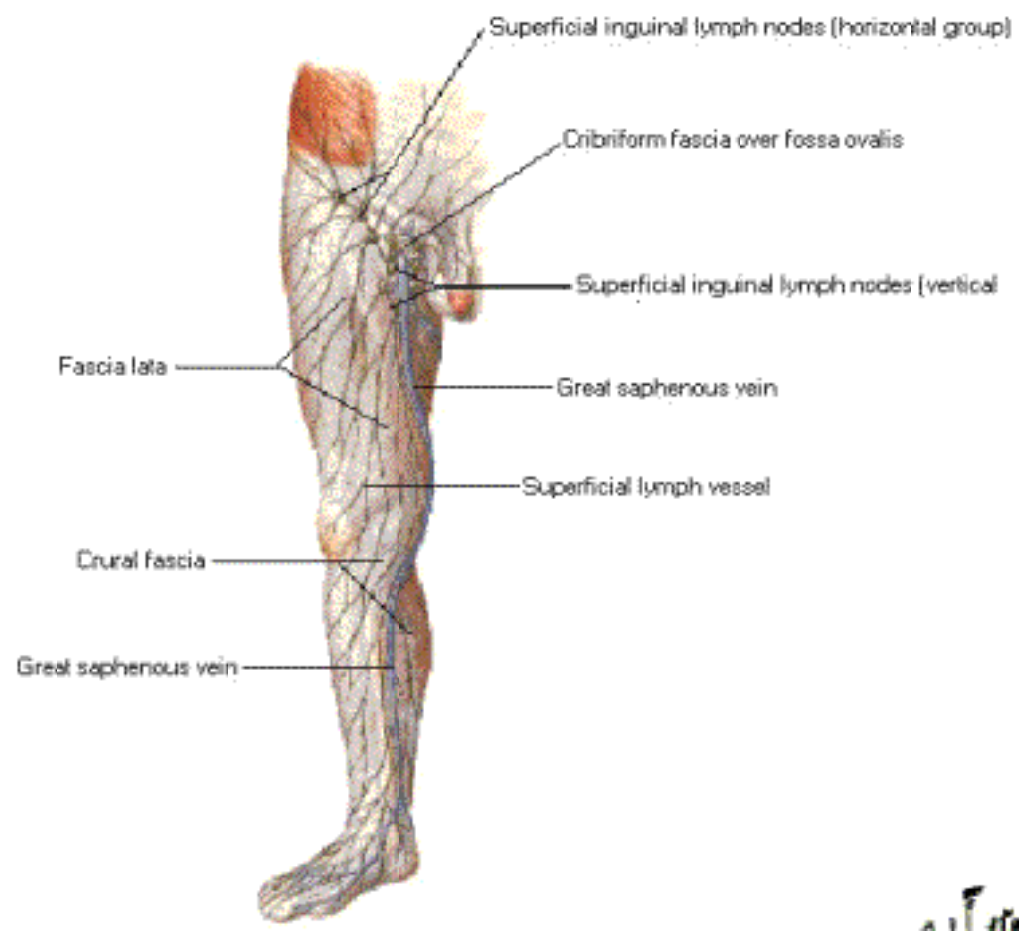
Superficial Nerves and Veins of Lower Limb

Posterior View



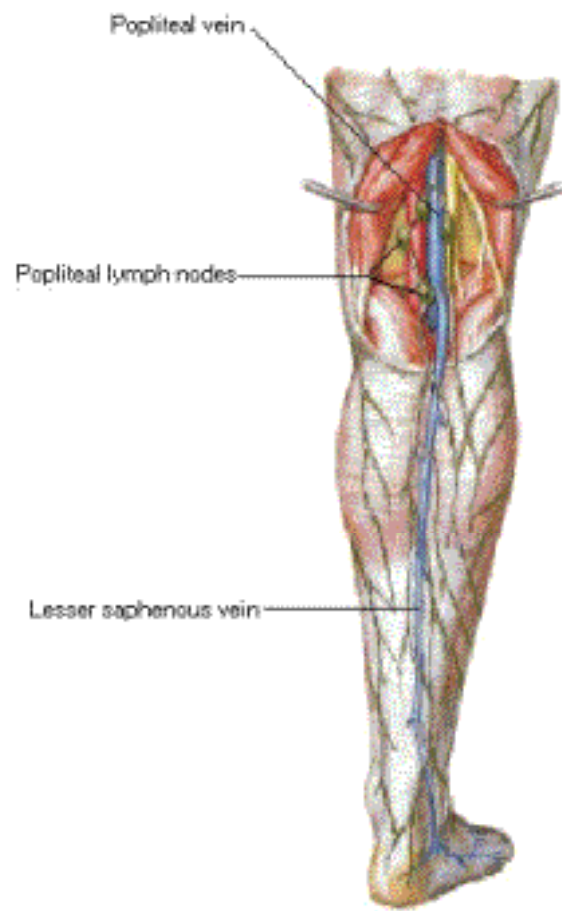
Lymph Vessels and Nodes of Lower Limb

Anterior View



Lymph Vessels and Nodes of Lower Limb

Posterior View



Lymph Vessels and Nodes of Lower Limb

Inguinal Region

