

THIEME FLEXIBOOK

B. Block

Color Atlas of
**Ultrasound
Anatomy**



Thieme

clinical sciences



Color Atlas of Ultrasound Anatomy

Berthold Block, M.D.

Private Practice
Braunschweig
Germany

544 illustrations

Thieme
Stuttgart · New York

Library of Congress Cataloging-in-Publication Data is available from the publisher.

This book is an authorized translation of the German edition published and copyrighted 2003 by Georg Thieme Verlag, Stuttgart, Germany. Title of the German edition: Der Sono-Guide: Taschenatlas der sonographischen Schnittbilddiagnostik

Translator: Terry C. Telger, Fort Worth, TX, USA

Illustrator: Gay & Sender, Bremen, Germany

© 2004 Georg Thieme Verlag,
Rüdigerstrasse 14, 70469 Stuttgart,
Germany
<http://www.thieme.de>
Thieme New York, 333 Seventh Avenue,
New York, NY 10001 USA
<http://www.thieme.com>

Cover design: Cyclus, Stuttgart
Typesetting by Gay & Sender, Bremen

Printed in Germany by Druckhaus Götz

ISBN 3-13-139051-4 (GTV)
ISBN 1-58890-281-1 (TNY) 1 2 3 4 5

Important note: Medicine is an ever-changing science undergoing continual development. Research and clinical experience are continually expanding our knowledge, in particular our knowledge of proper treatment and drug therapy. Insofar as this book mentions any dosage or application, readers may rest assured that the authors, editors, and publishers have made every effort to ensure that such references are in accordance with **the state of knowledge at the time of production of the book.**

Nevertheless, this does not involve, imply, or express any guarantee or responsibility on the part of the publishers in respect to any dosage instructions and forms of applications stated in the book. **Every user is requested to examine carefully** the manufacturers' leaflets accompanying each drug and to check, if necessary in consultation with a physician or specialist, whether the dosage schedules mentioned therein or the contraindications stated by the manufacturers differ from the statements made in the present book. Such examination is particularly important with drugs that are either rarely used or have been newly released on the market. Every dosage schedule or every form of application used is entirely at the user's own risk and responsibility. The authors and publishers request every user to report to the publishers any discrepancies or inaccuracies noticed.

Some of the product names, patents, and registered designs referred to in this book are in fact registered trademarks or proprietary names even though specific reference to this fact is not always made in the text. Therefore, the appearance of a name without designation as proprietary is not to be construed as a representation by the publisher that it is in the public domain.

This book, including all parts thereof, is legally protected by copyright. Any use, exploitation, or commercialization outside the narrow limits set by copyright legislation, without the publisher's consent, is illegal and liable to prosecution. This applies in particular to photostat reproduction, copying, mimeographing, preparation of microfilms, and electronic data processing and storage.

Preface

Ultrasound scanning yields a series of sectional images. The basis for interpreting the examination is the individual sectional image. At first sight, it is easy to be confused by the variable appearance of an ultrasound scan of the same region in different patients. This has numerous causes, including differences in density, body fat, age-related differences, overlying gas, and artifacts. In most cases the apparent discrepancies are not based on true anatomical differences. When a systematic scanning routine is closely followed, series of sectional images can be obtained in every patient with remarkable consistency. Even if the images themselves vary, the anatomical relationships that are demonstrated remain constant.

While some excellent atlases have been published on computed tomography and magnetic resonance imaging, it is curious that no one (to the author's knowledge) has taken the trouble to create a similar atlas of sectional anatomy for abdominal ultrasound. The present atlas attempts to fill this gap. In particular, the author hopes to provide the beginner with a comprehensive guide to the initially confusing world of sonographic anatomy.

Many have helped in the creation of this book. I wish to thank Dr. Hartwig Schöndube and Dr. Matthias Geist, who gave me some scans. I also thank Mrs. Stephanie Gay and Mr. Bert Sender of Bremen for their superb rendering of the illustrations. I am also grateful to the staff at Thieme Medical Publishers for enabling me to make this book a reality, with special thanks to Dr. Antje Schönpflug, Mrs. Marion Holzer, and, of course, Dr. Markus Becker.

Braunschweig, Spring 2004

Berthold Block

Table of Contents

Standard Sectional Planes
for Abdominal Scanning 1



Adrenal Glands 202



Vessels 14



Stomach 218



Liver 72



Bladder 242



Gallbladder 118



Prostate 250



Pancreas 134



Uterus 260



Spleen 168



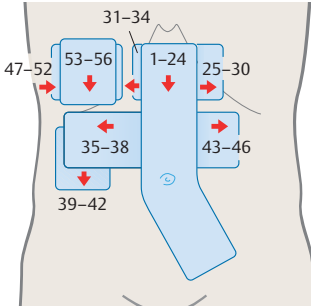
Thyroid Gland 272



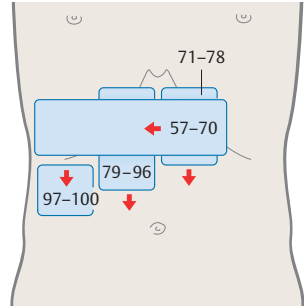
Kidneys 180

The numbers shown on the scanning paths refer to the corresponding *figure numbers*

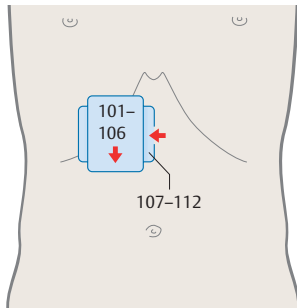
► **Vessels (1–56)**



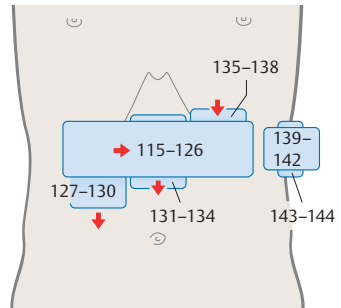
► **Liver (57–100)**



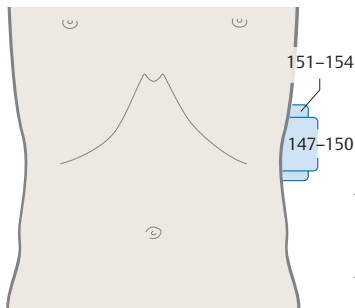
► **Gallbladder (101–114)**



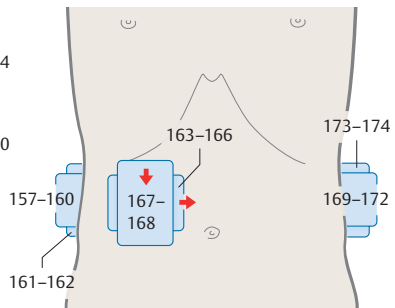
► **Pancreas (115–146)**



► **Spleen (147–156)**

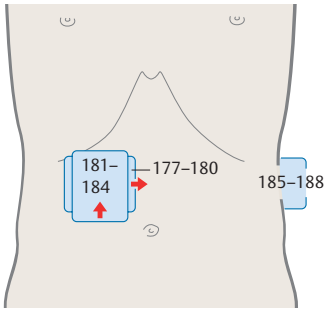


► **Kidney (157–176)**

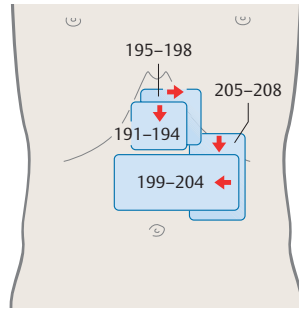


in this book.

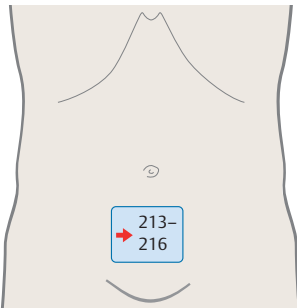
▶ **Adrenal gland (177–190)**



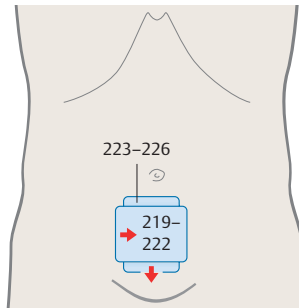
▶ **Stomach (191–212)**



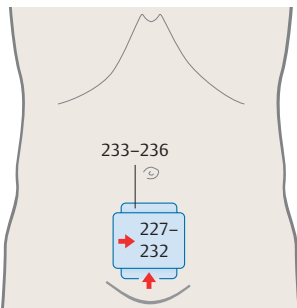
▶ **Bladder (213–218)**



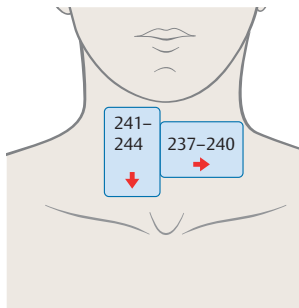
▶ **Prostate (219–226)**



▶ **Uterus (227–236)**



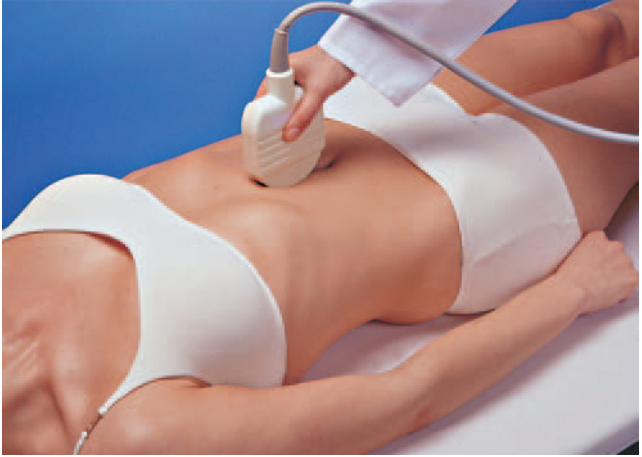▶ **Thyroid gland (237–244)**



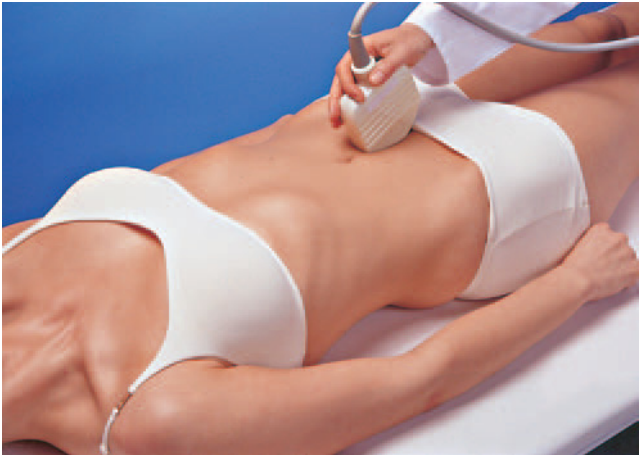Scanning Planes

Standard Planes for Abdominal Scanning

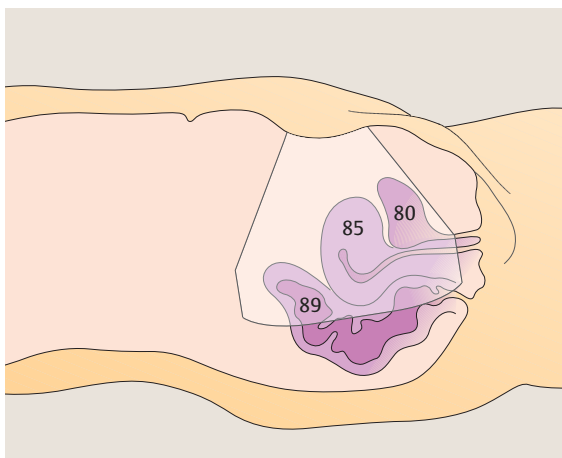
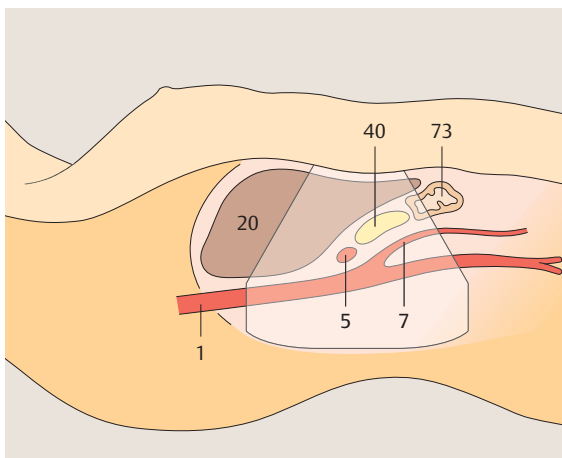
- p. 2/3** Upper abdominal longitudinal scan, center
Lower abdominal longitudinal scan, center
- p. 4/5** Upper abdominal longitudinal scan, right side
Lower abdominal longitudinal scan, left side
- p. 6/7** Upper abdominal transverse scan, center
Lower abdominal transverse scan, center
- p. 8/9** Upper abdominal transverse scan, right side
Upper abdominal transverse scan, left side
- p. 10/11** Longitudinal flank scan, right side
Longitudinal flank scan, left side
- p. 12/13** Transverse flank scan, right side
Transverse flank scan, left side

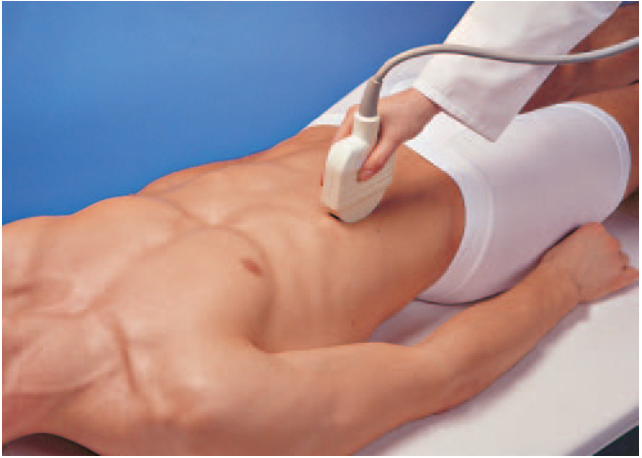

► Upper abdominal longitudinal scan, center

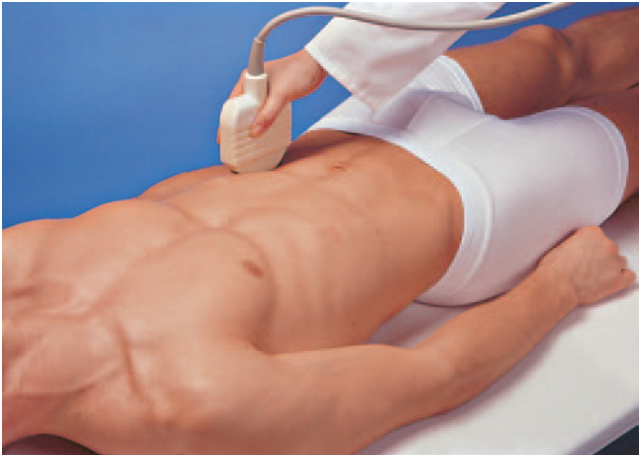

► Lower abdominal longitudinal scan, center

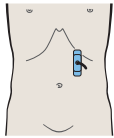
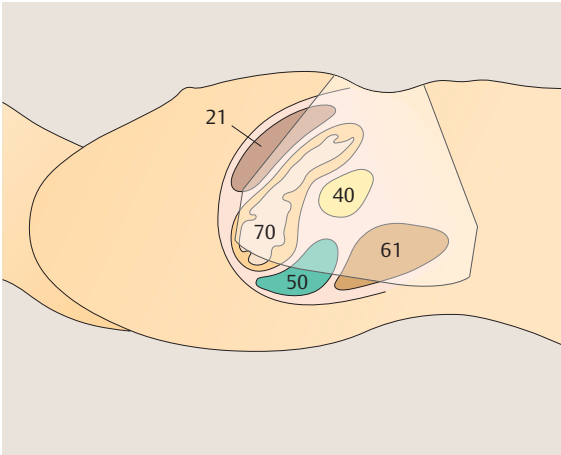
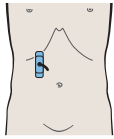
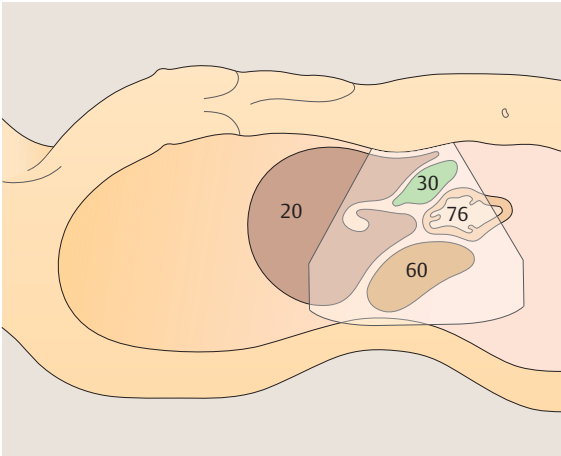


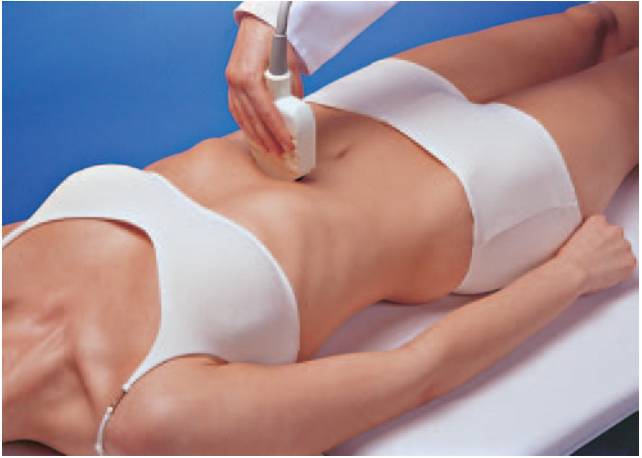

► Upper abdominal longitudinal scan, right side

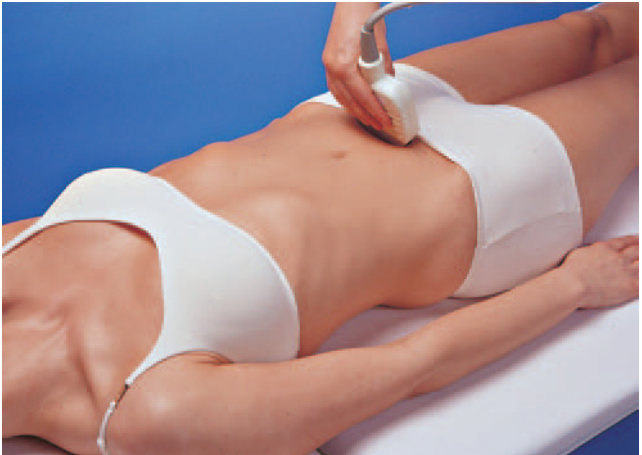

► Upper abdominal longitudinal scan, left side

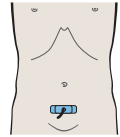
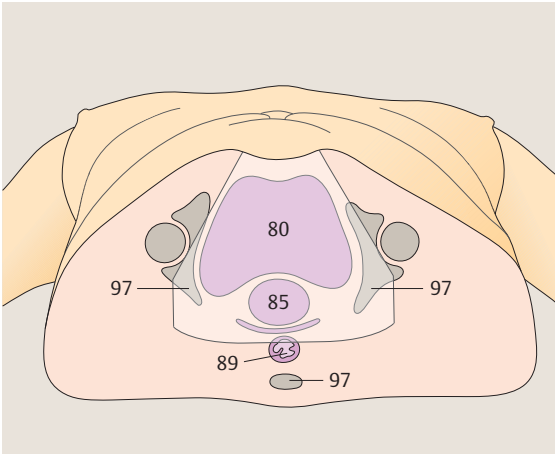
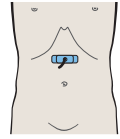
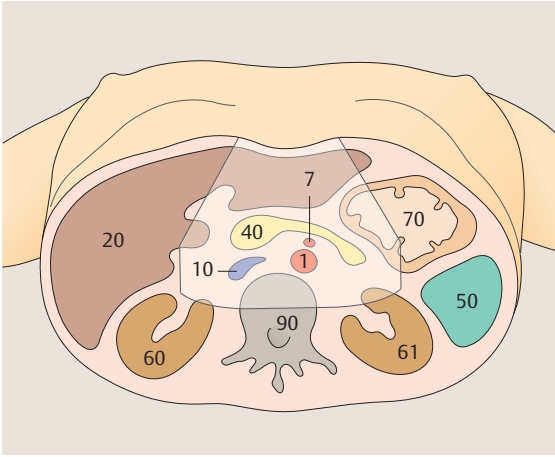


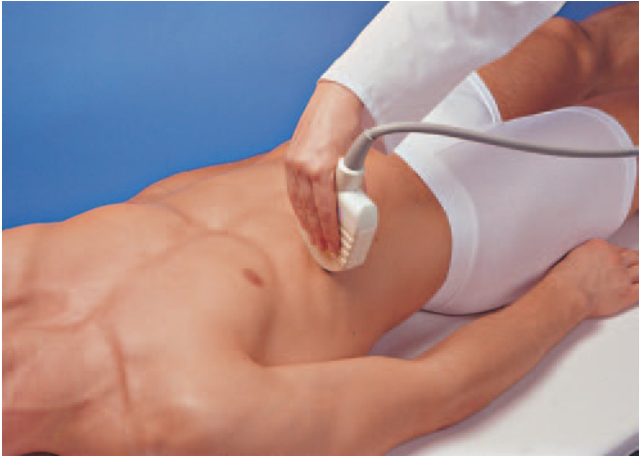

► Upper abdominal transverse scan, center

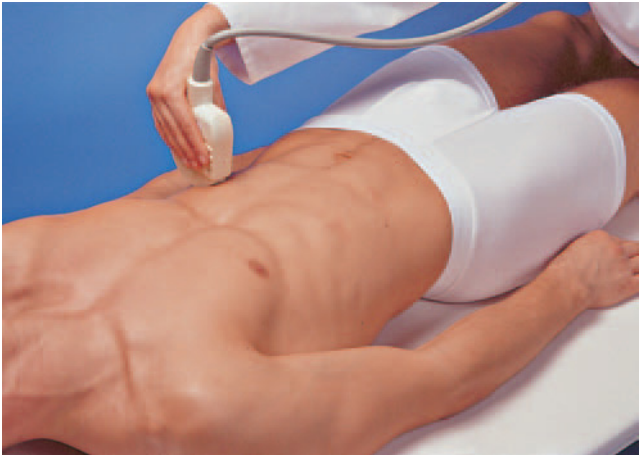

► Lower abdominal transverse scan, center

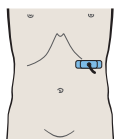
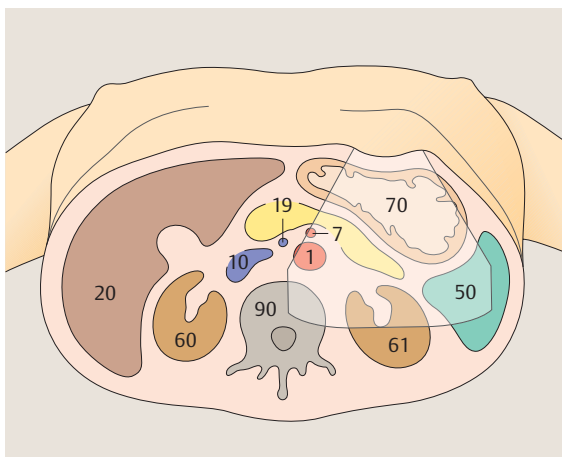
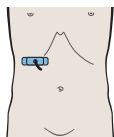
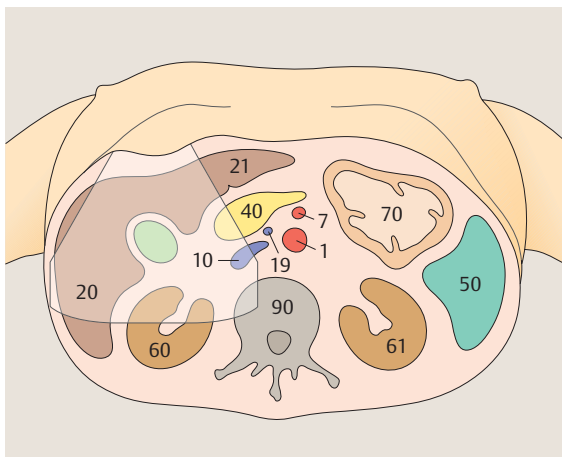


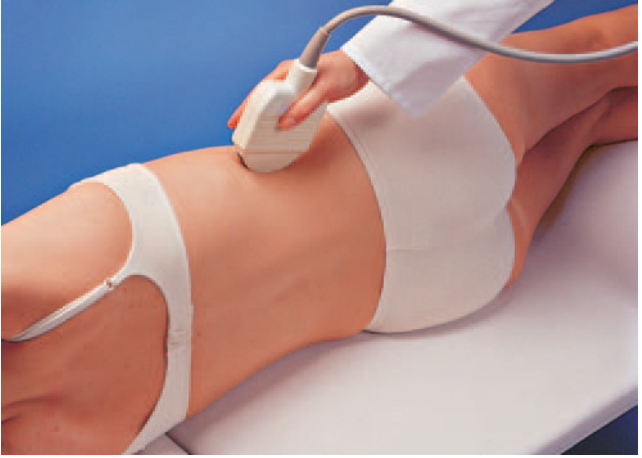

► Upper abdominal transverse scan, right side

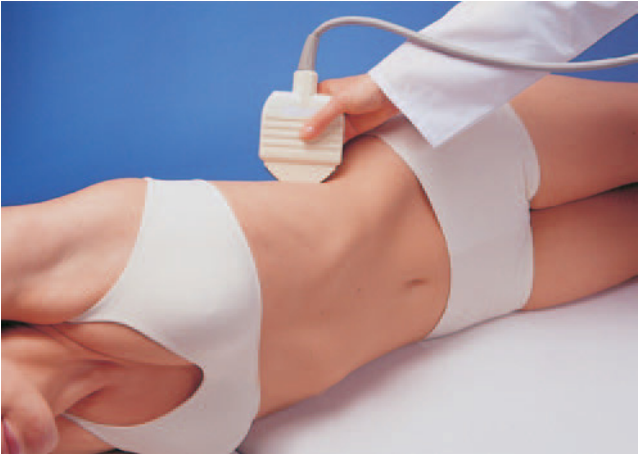

► Upper abdominal transverse scan, left side

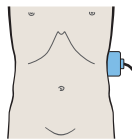
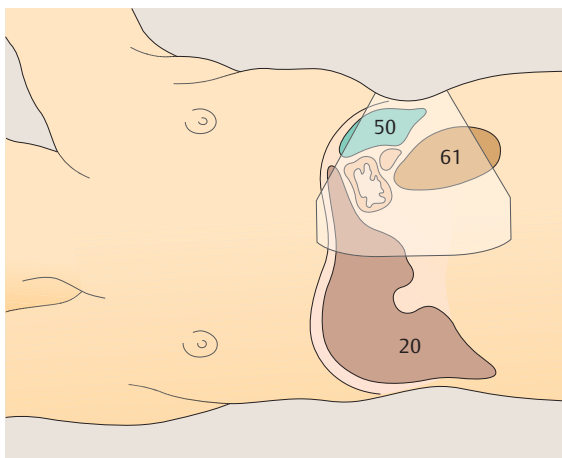
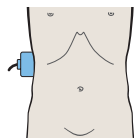
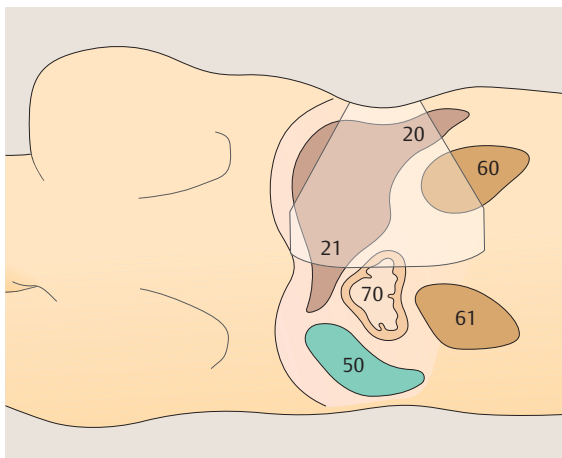


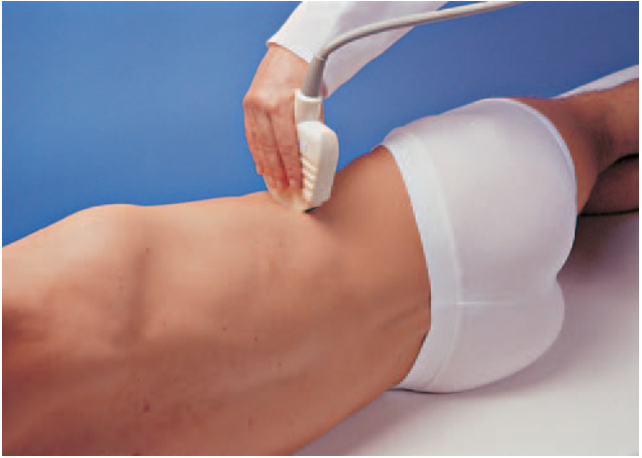

► Longitudinal flank scan, right side

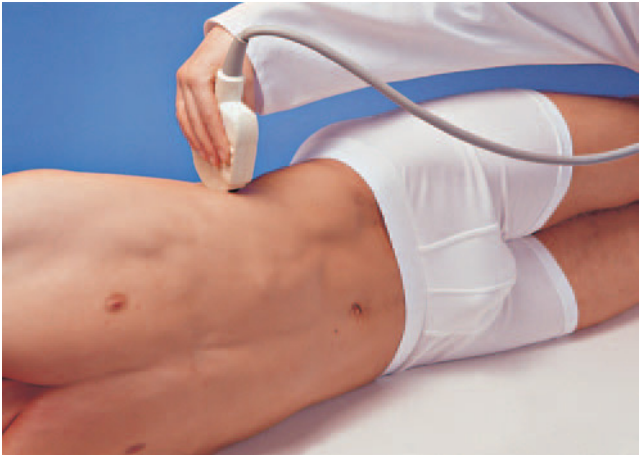

► Longitudinal flank scan, left side

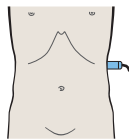
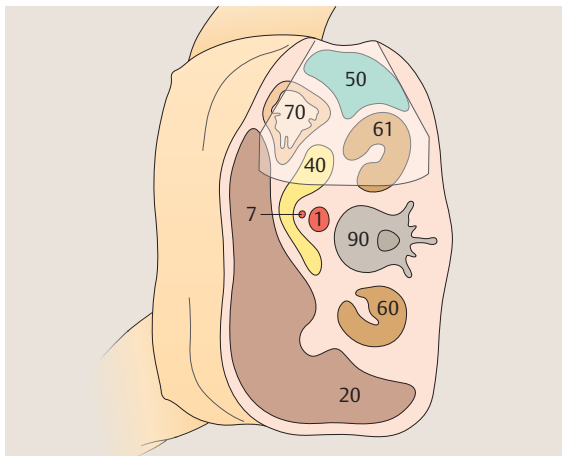
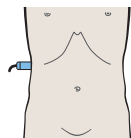
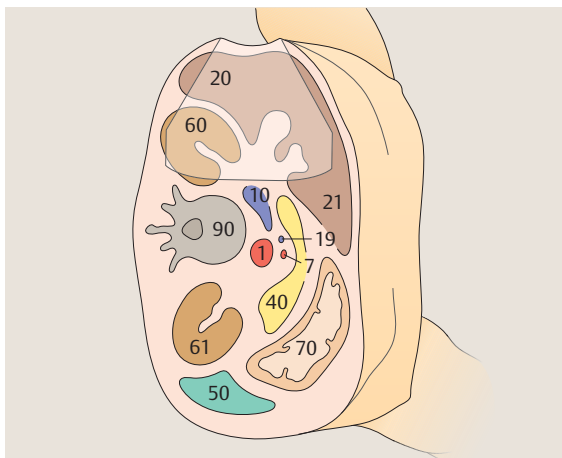




► Transverse flank scan, right side



► Transverse flank scan, left side



1 Vessels

Aorta and Vena Cava in Suprarenal Transverse Sections, Including the Renal Vessels

- 1 Passage of aorta and vena cava through diaphragm
- 2 Left gastric artery
- 3 Celiac trunk
- 4 Celiac trunk
- 5 Hepatic artery
- 6 Splenic artery
- 7 Superior mesenteric artery
- 8 Superior mesenteric artery
- 9 Superior mesenteric artery and splenic vein
- 10 Left renal vein and right renal artery

Aorta and Vena Cava in Infrarenal Transverse Sections

- 11 Infrarenal aorta and vena cava
- 12 Infrarenal aorta and vena cava
- 13 Infrarenal aorta and vena cava
- 14 Infrarenal aorta, vena cava, superior mesenteric artery and vein
- 15 Infrarenal aorta and vena cava
- 16 Aortic bifurcation
- 17 Iliac arteries
- 18 Confluence of iliac veins
- 19 Iliac vessels
- 20 Iliac vessels
- 21 Iliac vessels
- 22 Iliac vessels
- 23 Left iliac vessels
- 24 Left iliac vessels

Splenic Artery and Vein in Longitudinal Sections

- 25 Aorta
- 26 Splenic vein and left gastric artery
- 27 Splenic artery and vein, celiac trunk
- 28 Splenic artery and vein, celiac trunk
- 29 Splenic artery and vein, renal artery and vein
- 30 Splenic artery and vein, renal artery and vein

Hepatic Artery in Longitudinal Sections

- 31 Celiac trunk
- 32 Hepatic artery and splenic vein
- 33 Hepatic artery and superior mesenteric vein
- 34 Hepatic artery and portal vein

Renal Artery and Vein in Longitudinal Sections

- 35 Aorta
- 36 Right renal artery and left renal vein
- 37 Vena cava and right renal artery
- 38 Right renal artery and right renal vein

Right Renal Artery and Vein in Transverse Sections

- 39 Opening of renal vein
- 40 Renal vein
- 41 Renal vein at hilum, renal artery
- 42 Renal artery

Left Renal Artery and Vein in Longitudinal Sections

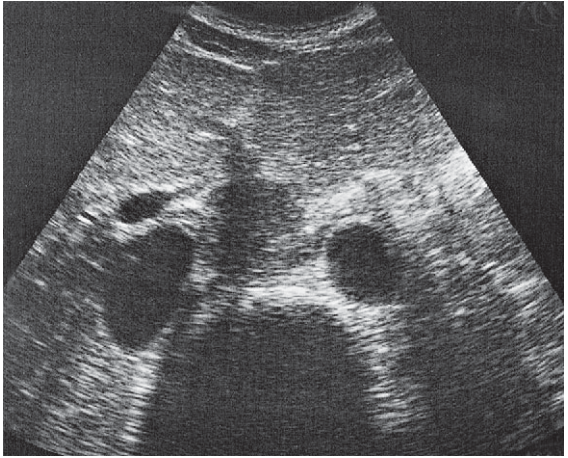
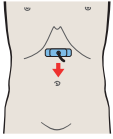
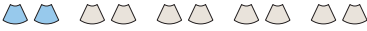- 43 Vena cava
- 44 Right renal artery and left renal vein
- 45 Aorta and left renal vein
- 46 Left renal vessels, splenic artery and vein

Vessels of the Porta Hepatis in Longitudinal Sections

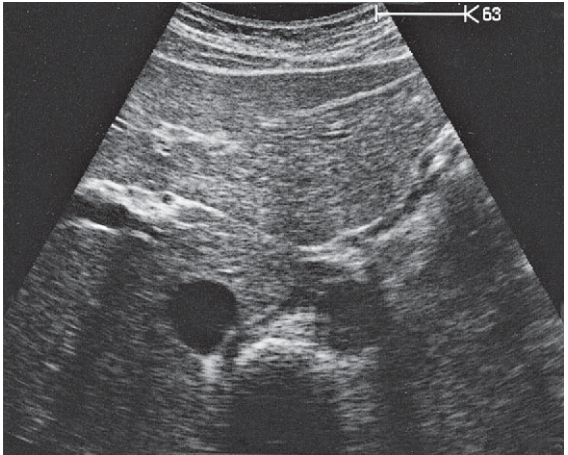
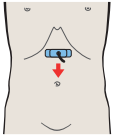
- 47 Portal vein, vena cava, right renal artery
- 48 Portal vein, vena cava, right renal artery, and bile duct
- 49 Portal vein, vena cava, and bile duct
- 50 Portal vein and hepatic artery
- 51 Hepatic artery, superior mesenteric vein
- 52 Hepatic artery, superior mesenteric artery, and splenic vein

Vessels of the Porta Hepatis in Transverse Sections

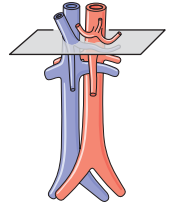
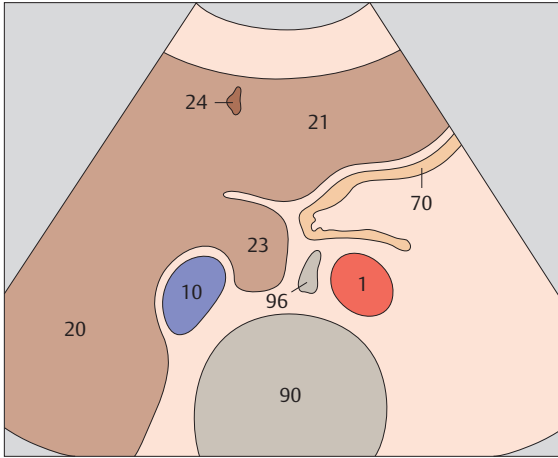
- 53 Hepatic artery, portal vein, vena cava
- 54 Hepatic artery, bile duct, portal vein
- 55 Bile duct, gallbladder, vena cava
- 56 Bile duct, gallbladder, superior mesenteric vein



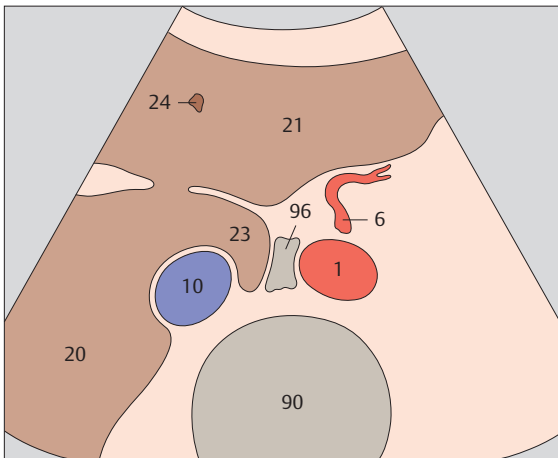
▶ 1 Passage of aorta and vena cava through diaphragm



▶ 2 Left gastric artery

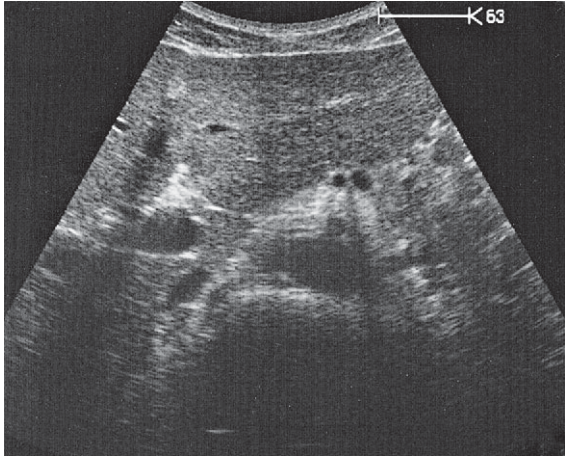
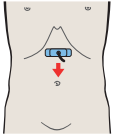
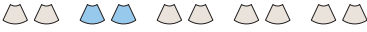

Just below the diaphragm, the vena cava is surrounded by liver tissue. The aorta lies directly behind the gastroesophageal junction, often making the vessel more difficult to scan.

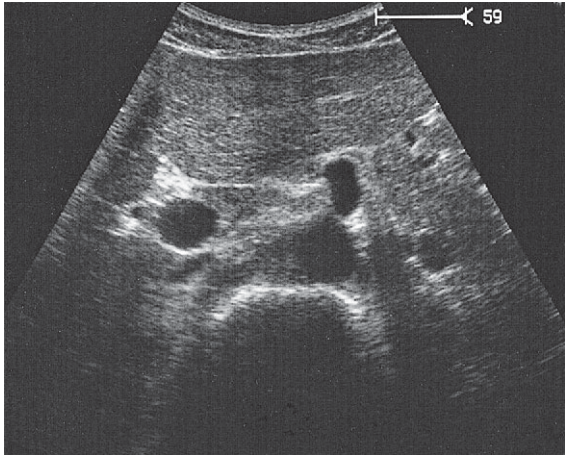
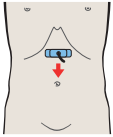


The left gastric artery is identified as a small-caliber vessel cranial to the celiac trunk.

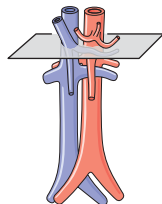
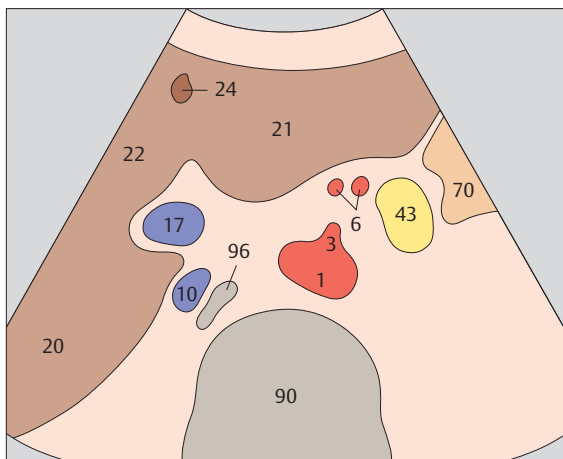




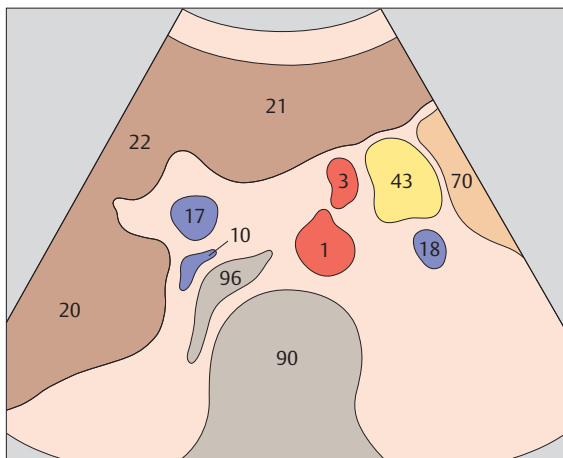
▶ 3 Celiac trunk



▶ 4 Celiac trunk

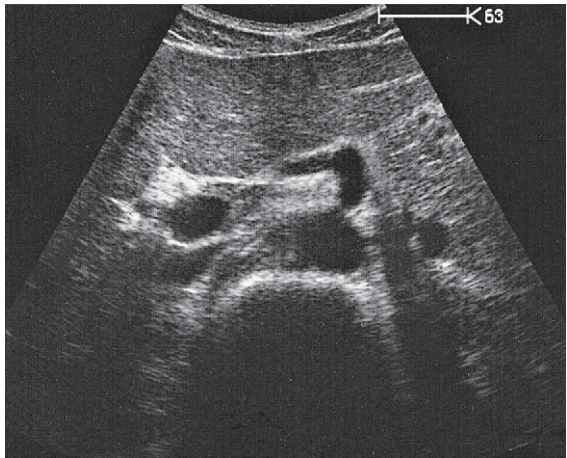
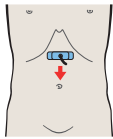
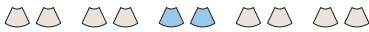

After arising from the aorta, the celiac trunk runs a short distance to the left.

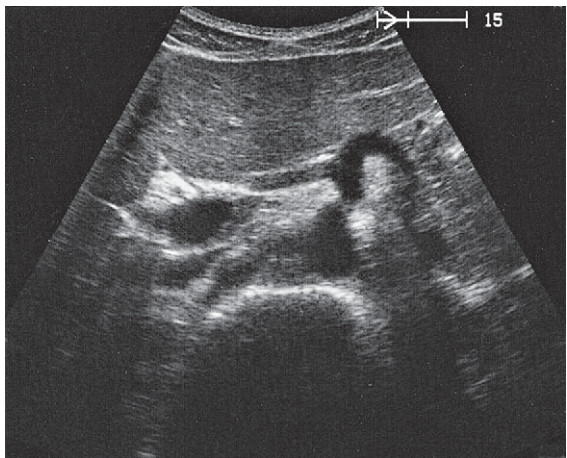
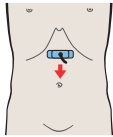


The proximal part of the celiac trunk also turns slightly downward in most cases.

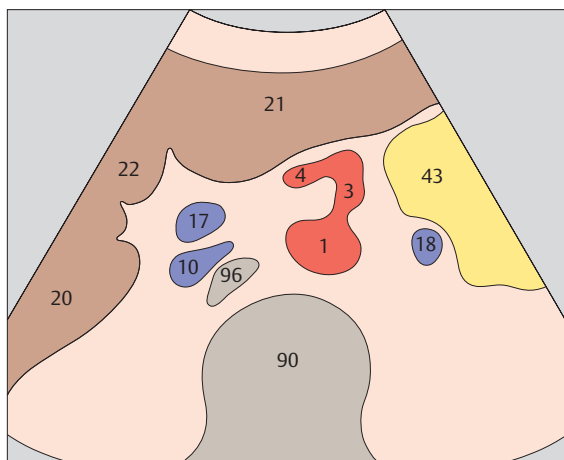




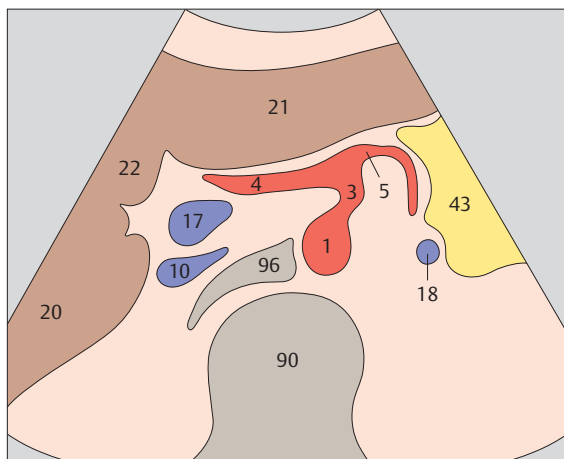
▶ 5 Hepatic artery



▶ 6 Splenic artery

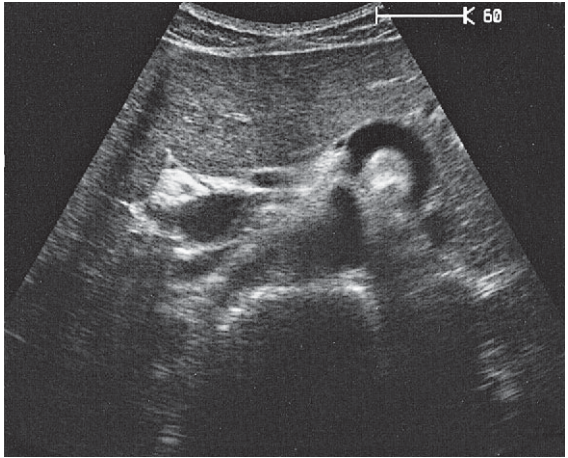
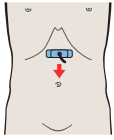
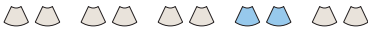

The celiac trunk runs slightly to the right, giving rise to the hepatic artery.

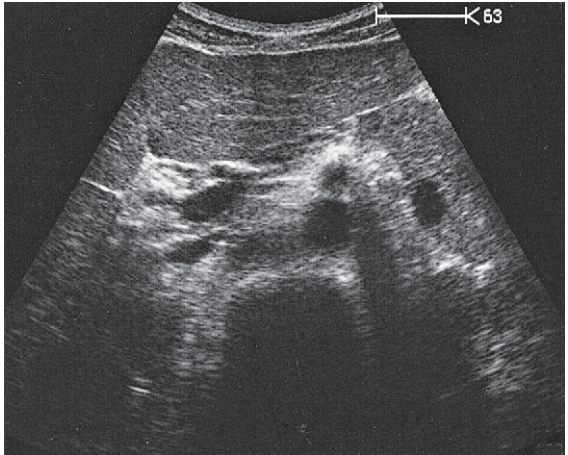
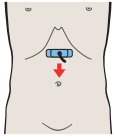


The splenic artery branches from the celiac trunk at a right angle.

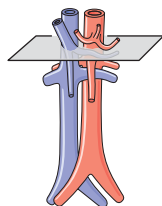
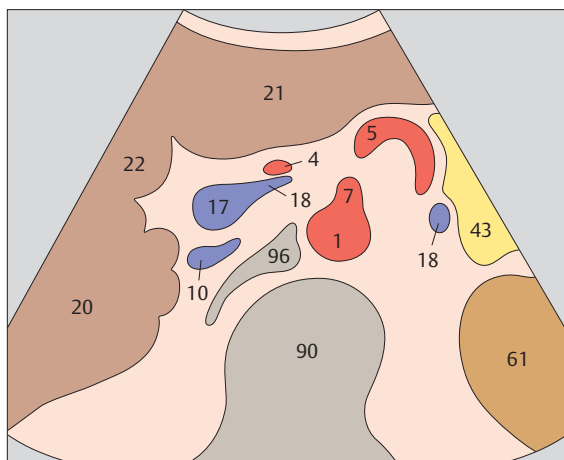




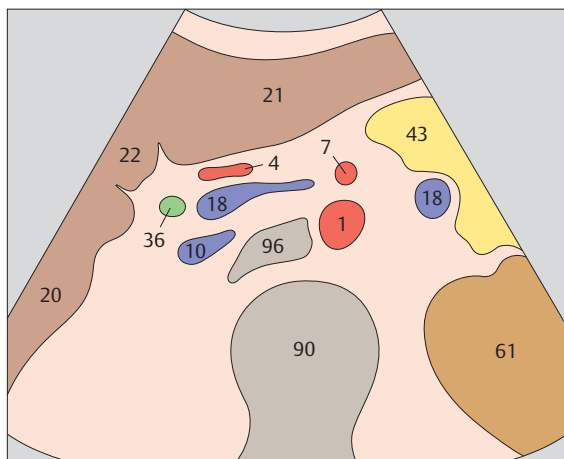
▶ 7 Superior mesenteric artery



▶ 8 Superior mesenteric artery

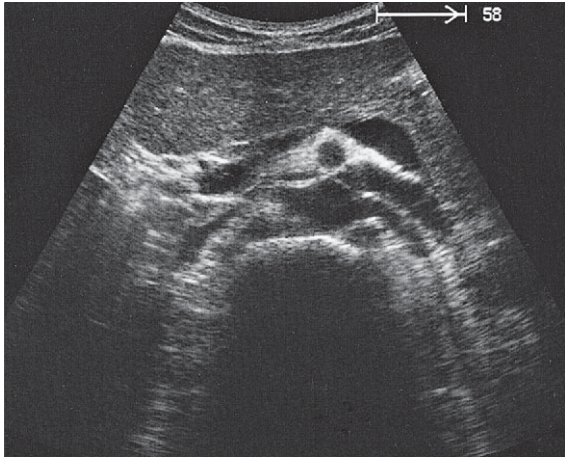
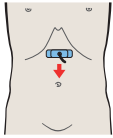
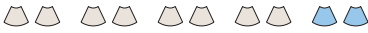

The superior mesenteric artery arises just below the celiac trunk and runs parallel to the aorta.

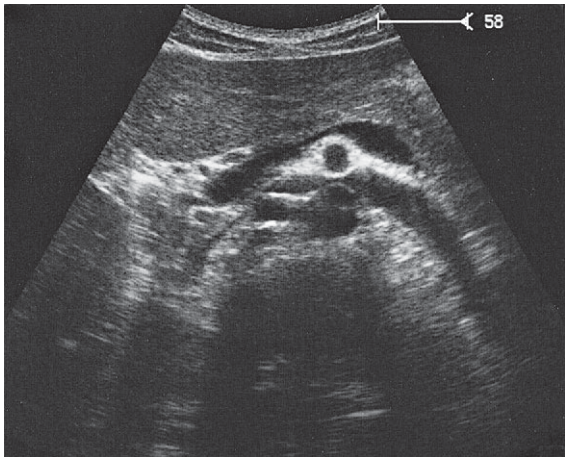
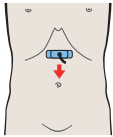


The root of the superior mesenteric artery is usually surrounded by an echodense fat pad.

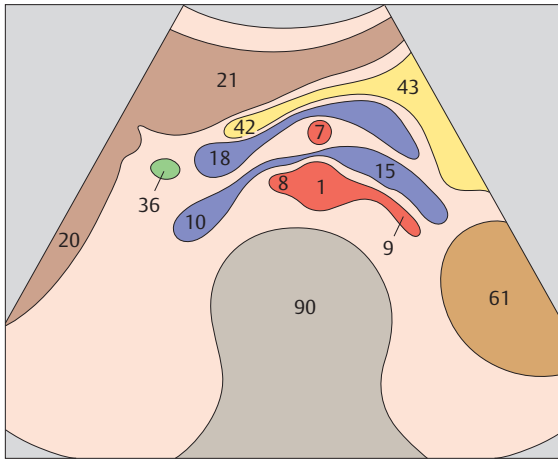




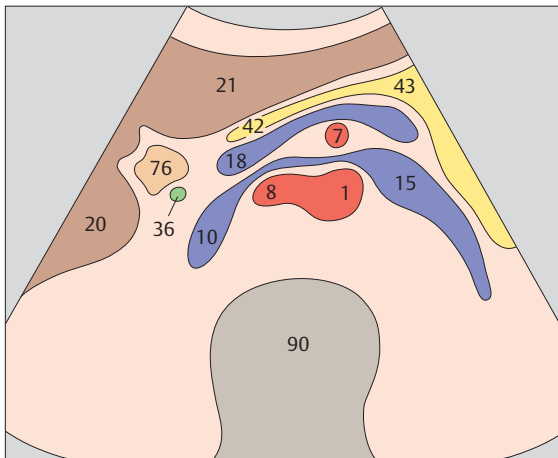
► 9 Superior mesenteric artery and splenic vein



► 10 Left renal vein and right renal artery

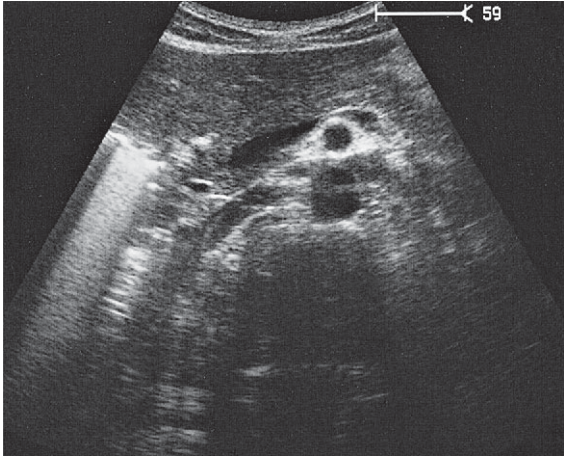
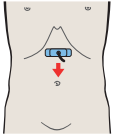
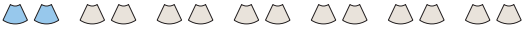

The aorta, the superior mesenteric artery, and the splenic vein crossing over the superior mesenteric artery provide landmarks for identifying the head of the pancreas.

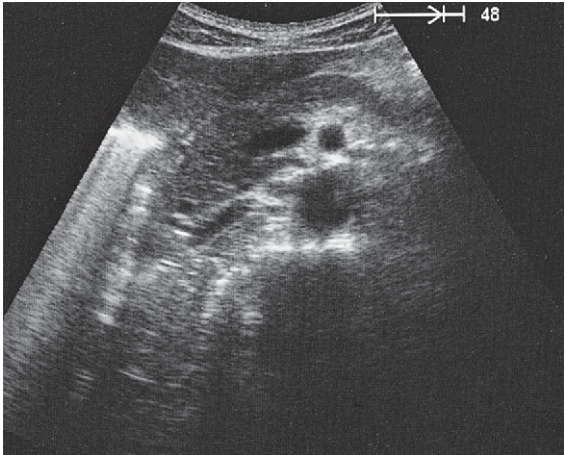
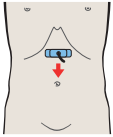


The left renal vein is physiologically compressed between the aorta and the superior mesenteric artery. It is slightly congested proximal to the compression site.

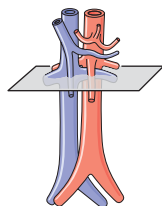
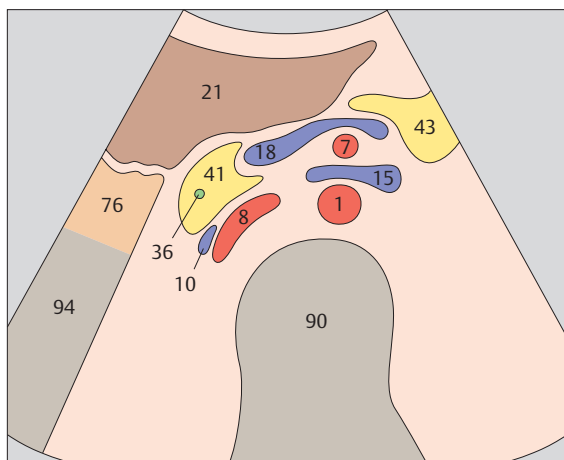




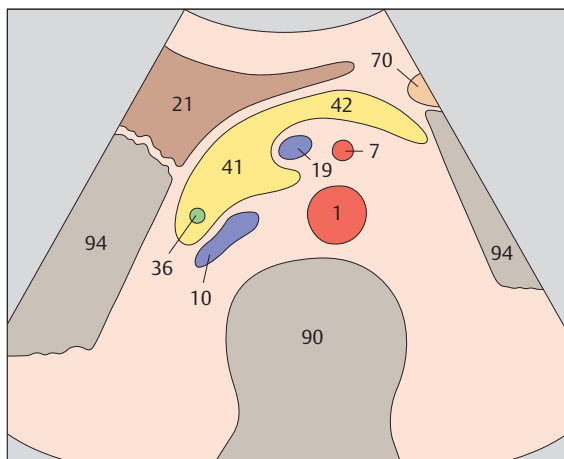
▶ 11 Infrarenal aorta and vena cava



▶ 12 Infrarenal aorta and vena cava

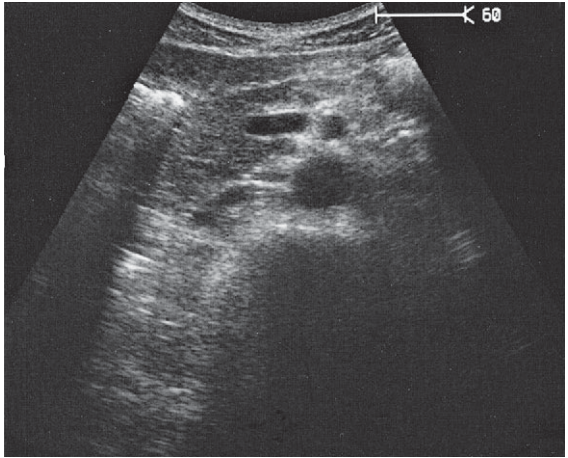
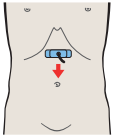
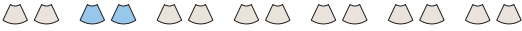

The vena cava is easily compressible with the transducer, and it bears impressions from adjacent organs.

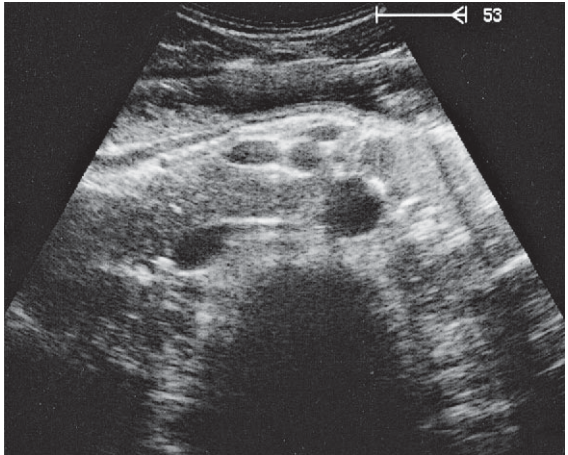
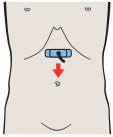


The aorta has a circular cross section, whereas the vena cava is somewhat flattened.

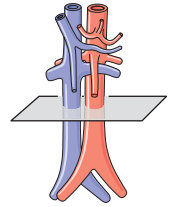
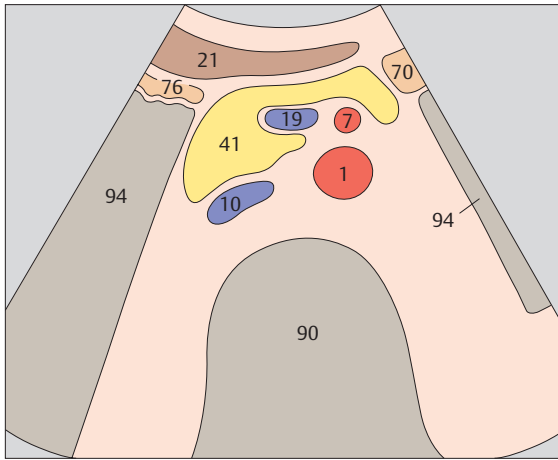




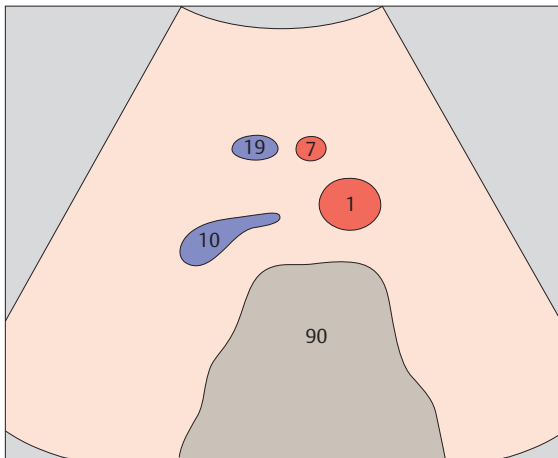
▶ 13 Infrarenal aorta and vena cava



▶ 14 Infrarenal aorta, vena cava, and superior mesenteric artery and vein

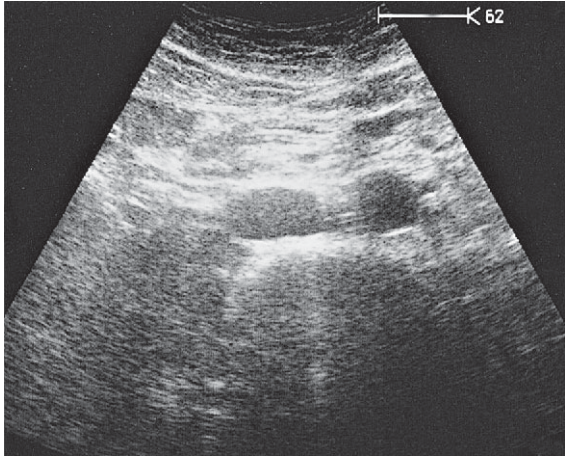
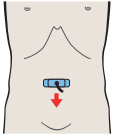
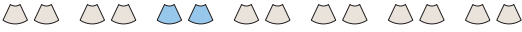

The caliber of the vena cava varies with the pulse and respirations. The diameter of the aorta measures 2.5 cm in its cranial portion, 2.0 cm in its caudal portion.

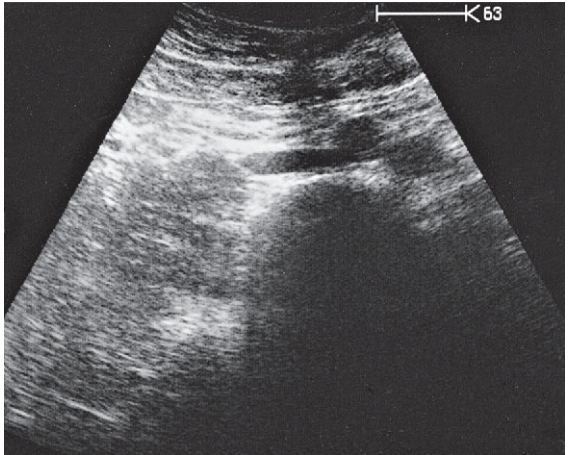
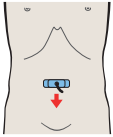


Together with the aorta and vena cava, the superior mesenteric artery and vein form a typical four-vessel pattern in a low transverse scan through the upper abdomen.

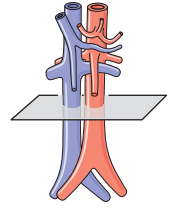
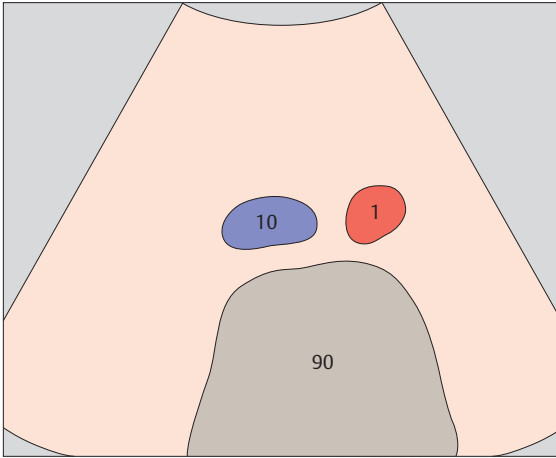




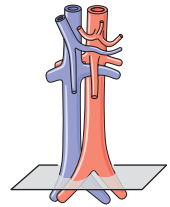
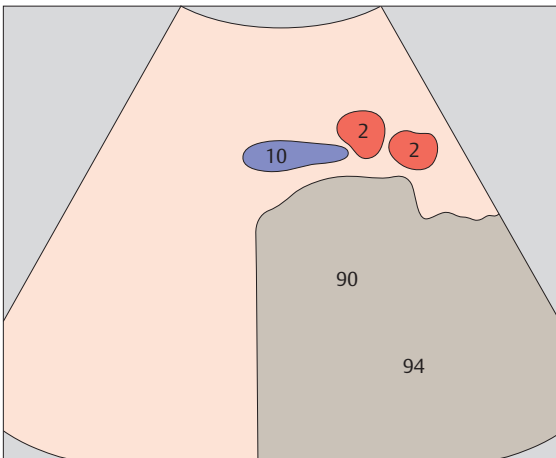
▶ 15 Infrarenal aorta and vena cava



▶ 16 Aortic bifurcation

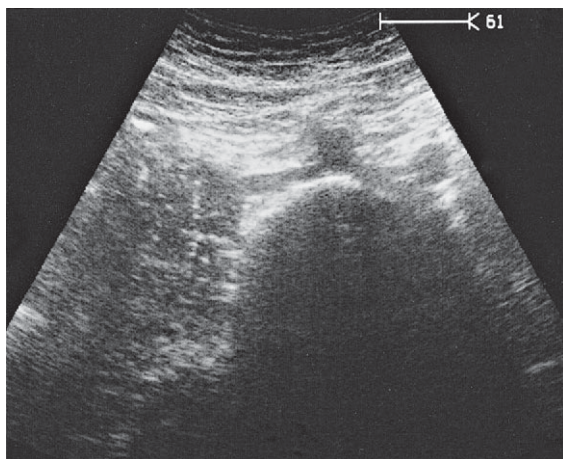
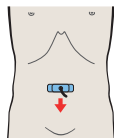
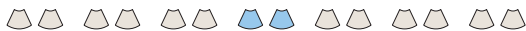

While the aorta and vena cava are relatively far apart in the upper abdomen, they converge at the level of the promontory, coming very close together.

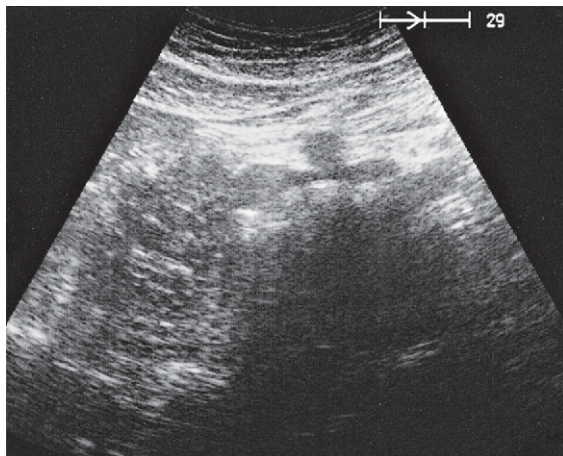
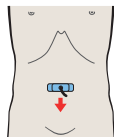


The aorta divides into the common iliac arteries at the level of the L4 vertebral body, above the promontory.

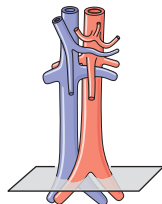
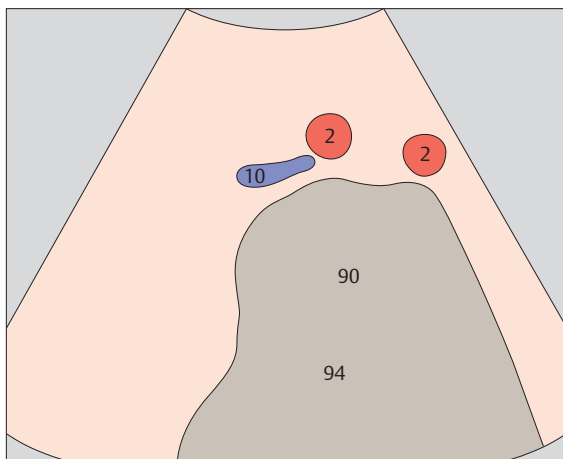




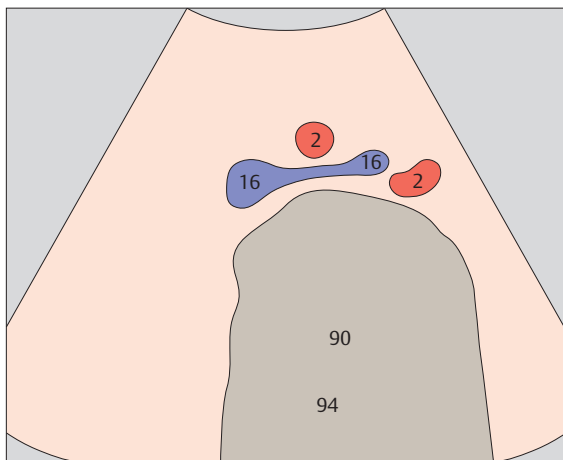
▶ 17 Iliac arteries



▶ 18 Confluence of iliac veins

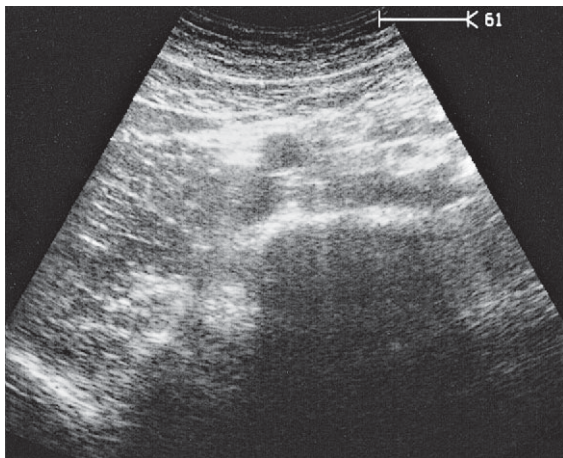
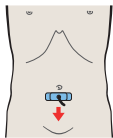
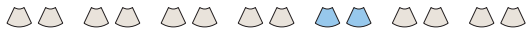

The aortic bifurcation is located slightly above the confluence of the iliac veins.

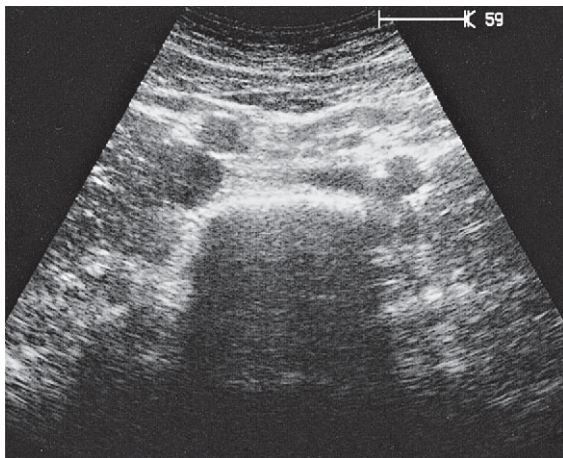
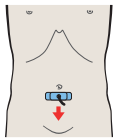


The confluence of the iliac veins lies approximately at the level of the umbilicus.

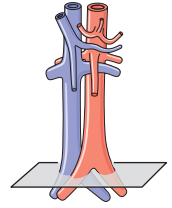
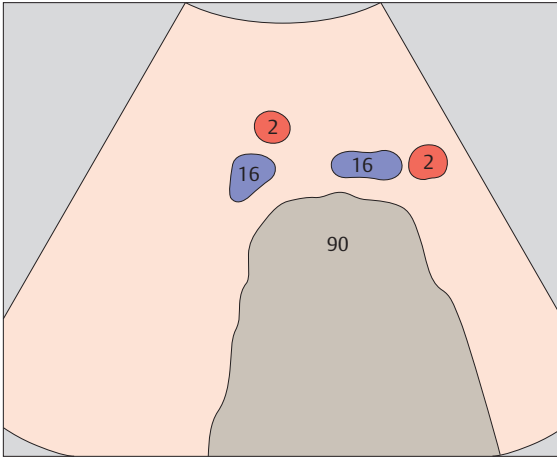




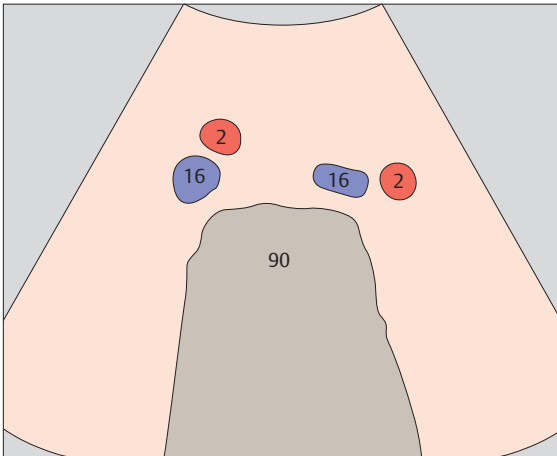
▶ 19 Iliac vessels



▶ 20 Iliac vessels

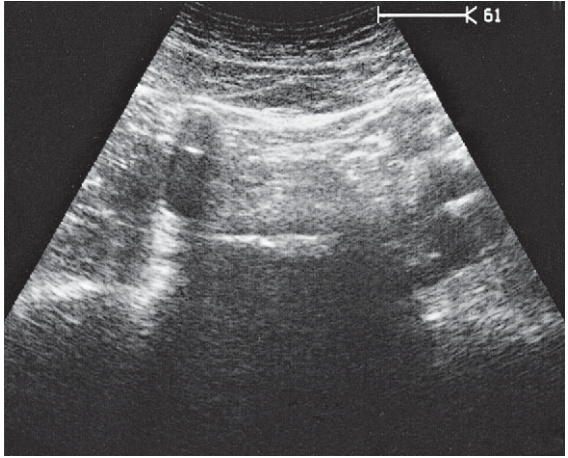
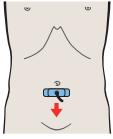
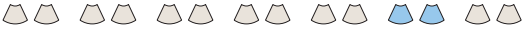

The iliac arteries are first anterior and then lateral to the iliac veins.

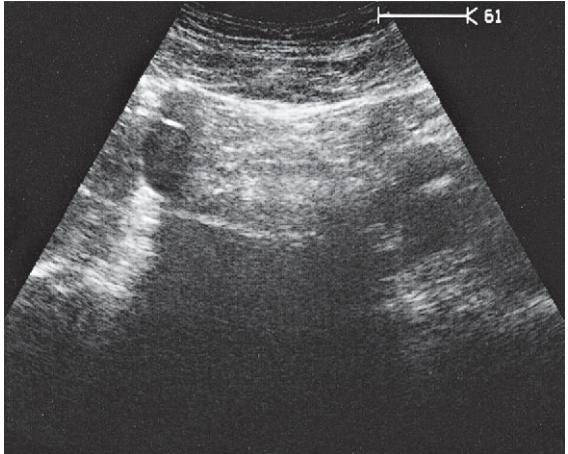
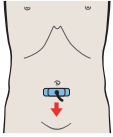


The iliac vessels follow the concavity of the lesser pelvis to the femoral arteries.

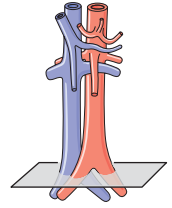
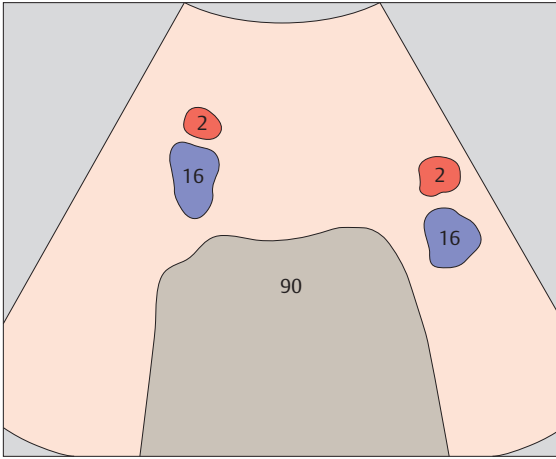




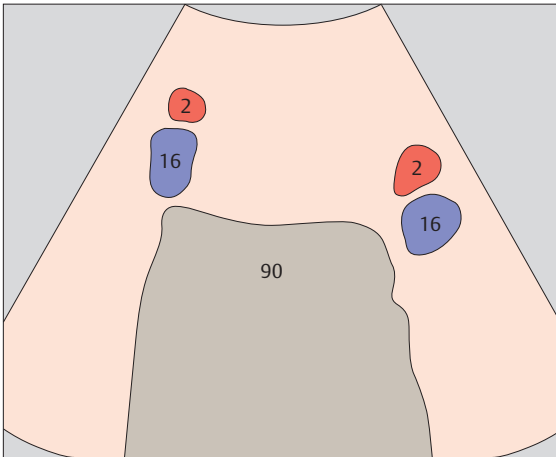
▶ 21 Iliac vessels



▶ 22 Iliac vessels

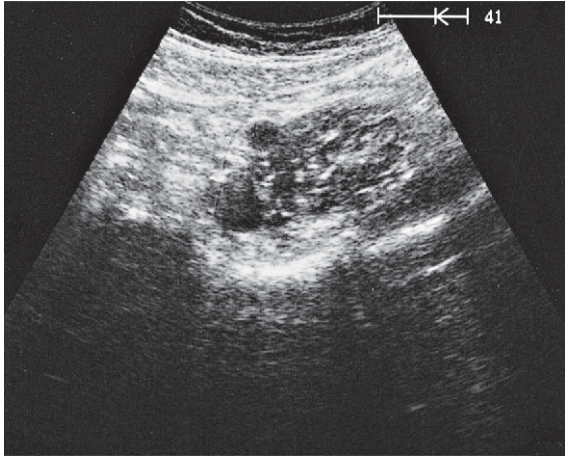
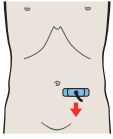
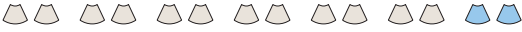

In serial transverse scans down the iliac vessels, the sections of the vessels are seen to move laterally and posteriorly.

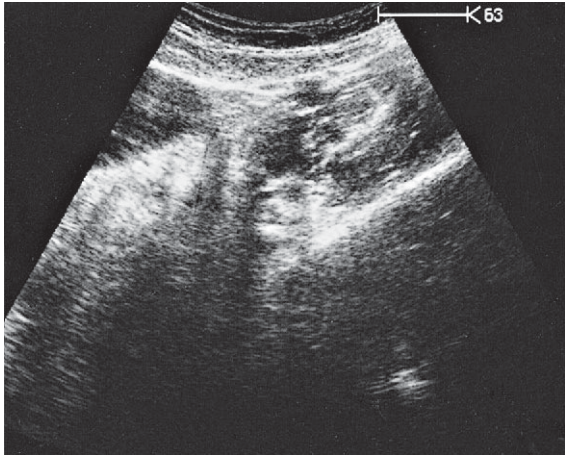
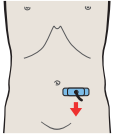


The iliac vessels are more difficult to scan at lower levels due to intervening bowel gas.

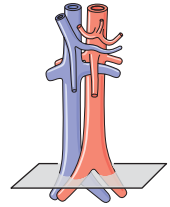
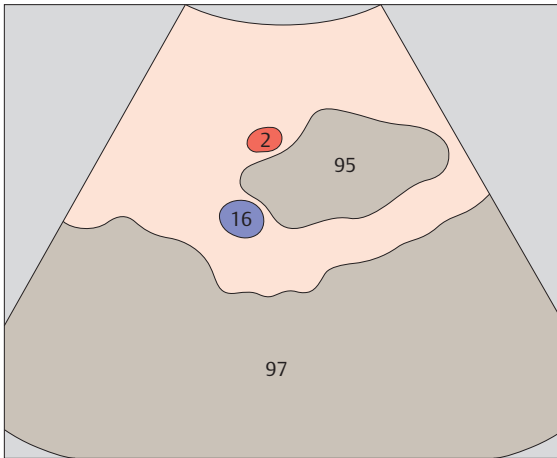




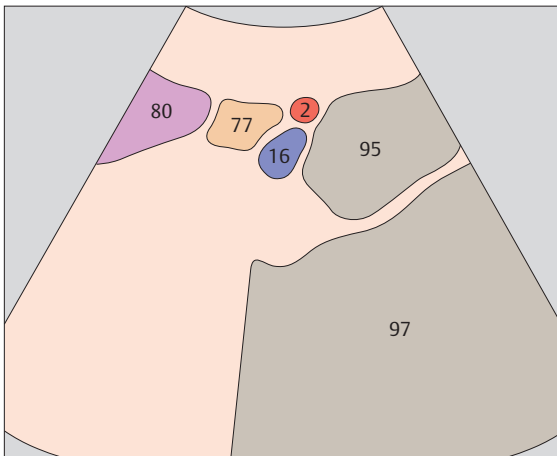
▶ 23 Left iliac vessels



▶ 24 Left iliac vessels

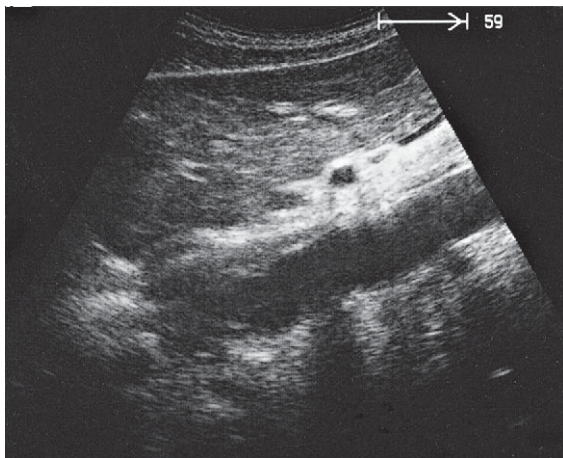
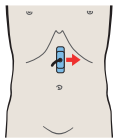
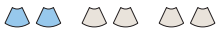

The iliac veins run dorsomedial to the iliac arteries in the lesser pelvis.

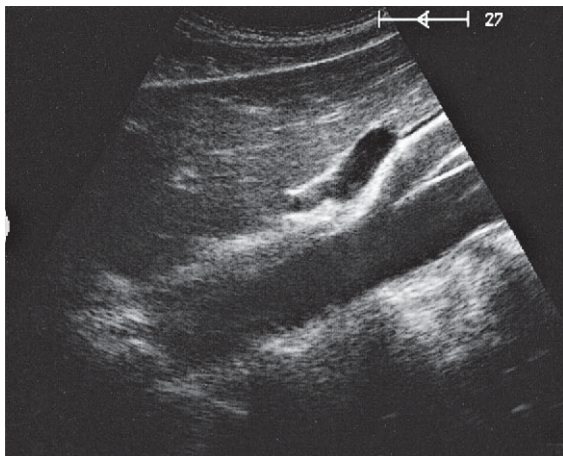
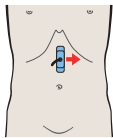


The iliac veins are always medial to the arteries at the level of the inguinal ligament.

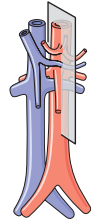
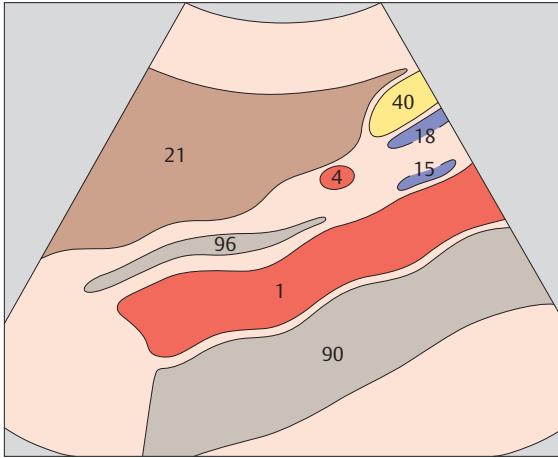




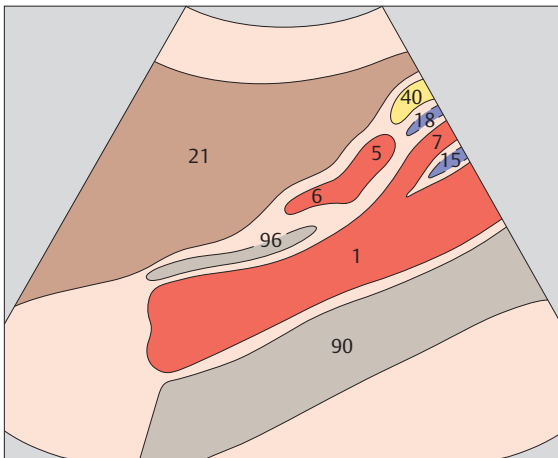
▶ 25 Aorta



▶ 26 Splenic artery and left gastric artery

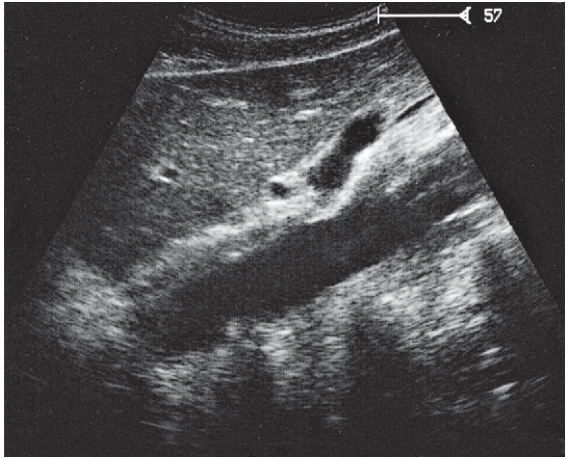
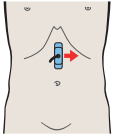


Because the celiac trunk runs slightly to the left initially, often it is not displayed in a longitudinal scan centered over the aorta.

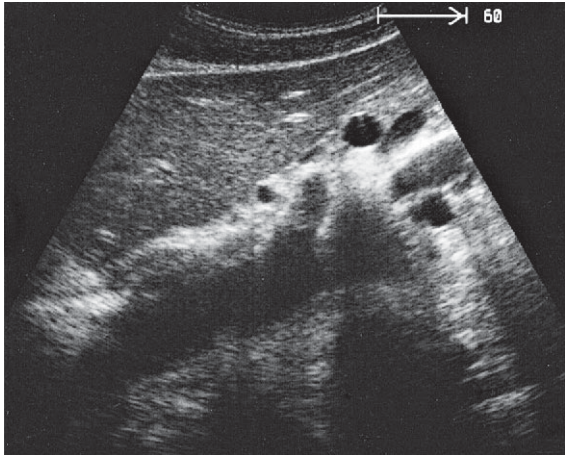
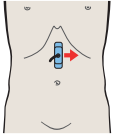


The left gastric artery runs cranially between the common hepatic artery and splenic artery. It is often difficult to define.

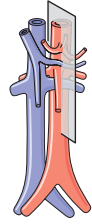
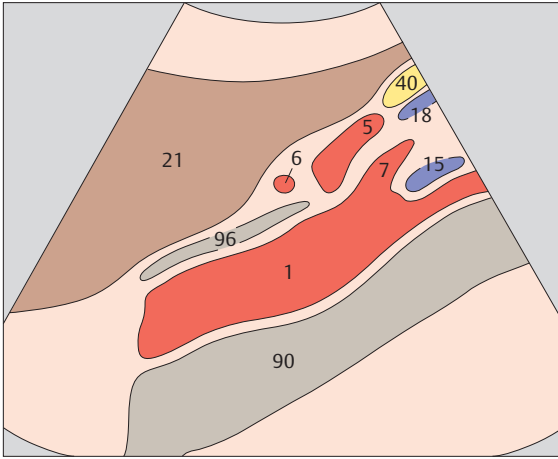




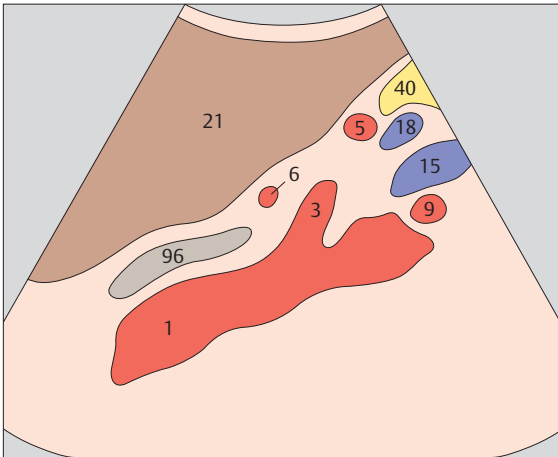
▶ 27 Splenic artery and vein, celiac trunk



▶ 28 Splenic artery and vein, celiac trunk

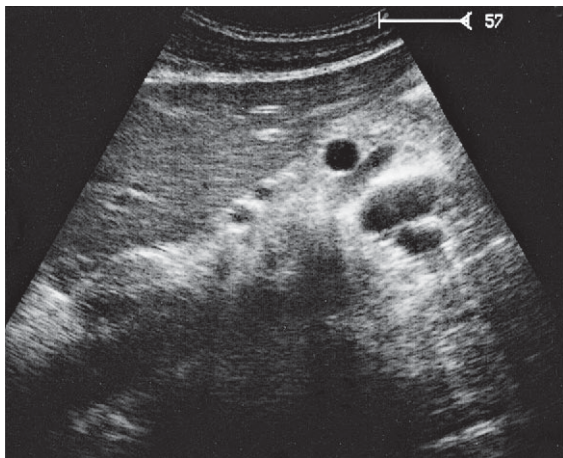
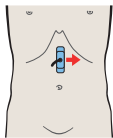
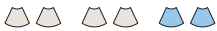

The celiac trunk divides into the left gastric artery, common hepatic artery, and splenic artery.

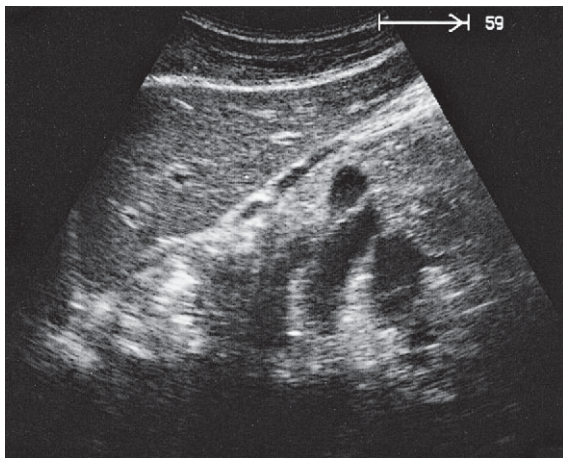
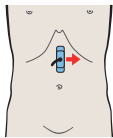


The curved course of the celiac trunk and splenic artery explains why both vessels appear in the same sagittal section.

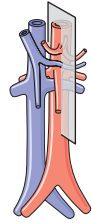
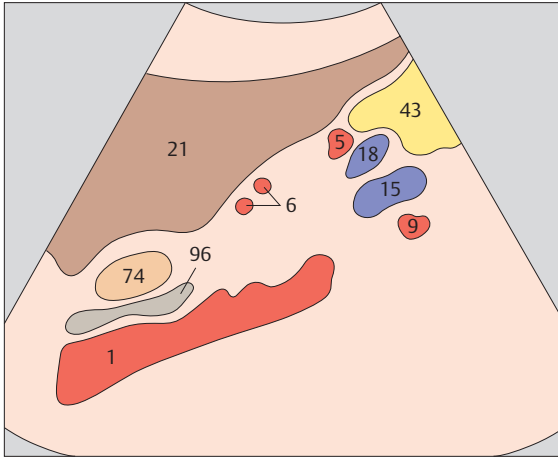




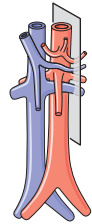
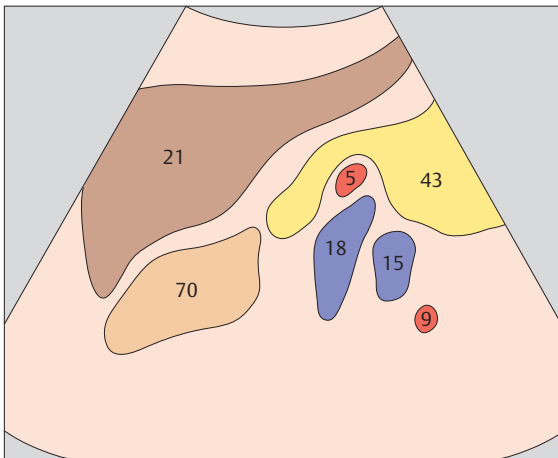
▶ 29 Splenic artery and vein, renal artery and vein



▶ 30 Splenic artery and vein, renal artery and vein

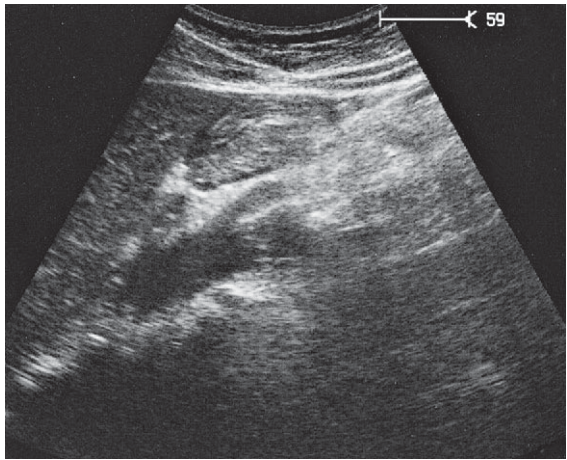
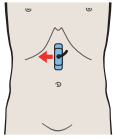
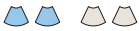

The splenic artery turns left and runs posteriorly with the splenic vein to the hilum of the spleen.

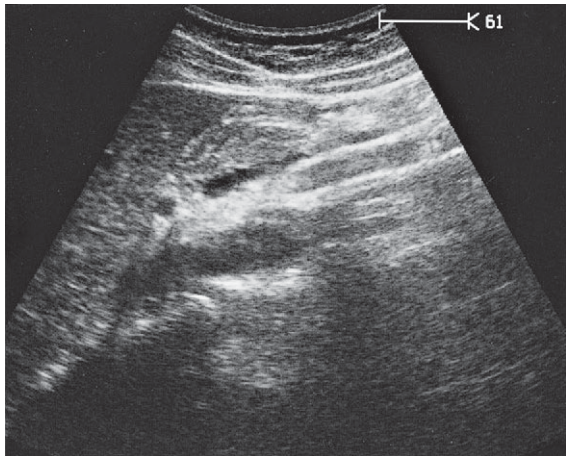
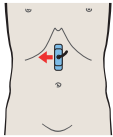


Longitudinal scan on the left side shows the typical appearance of the large splenic and renal veins and the smaller splenic and renal arteries.

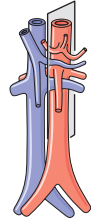
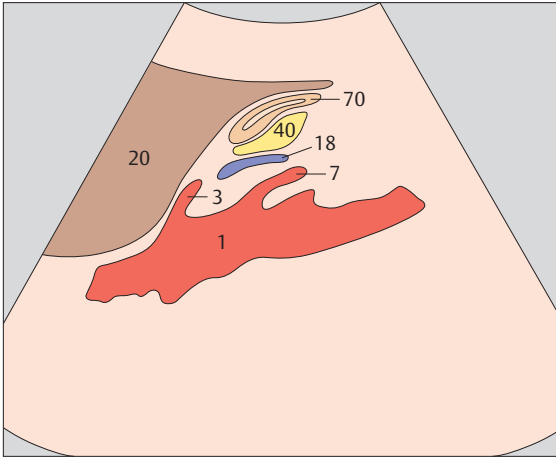




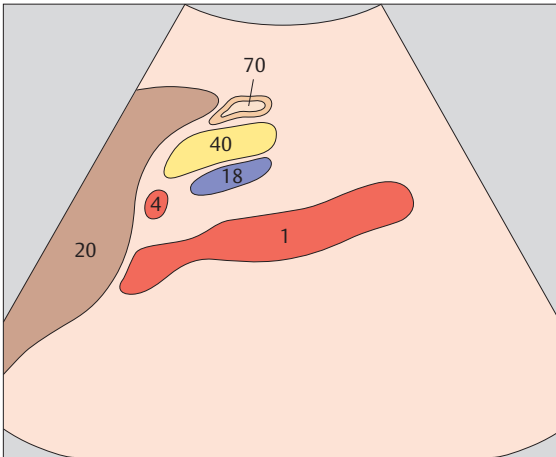
▶ 31 Celiac trunks



▶ 32 Hepatic artery and splenic vein

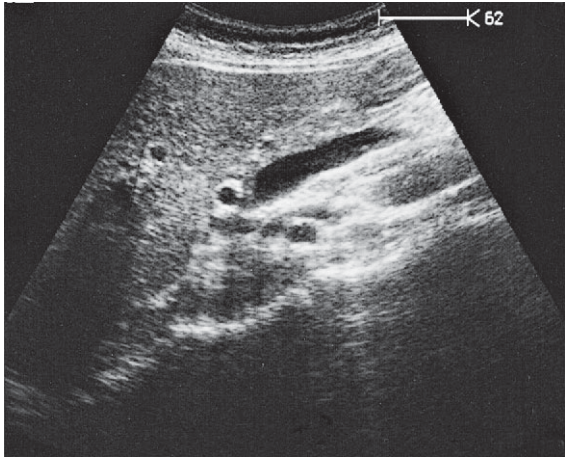
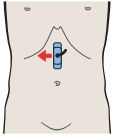
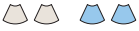

The origin of the celiac trunk and its division into branches are subject to numerous variations.

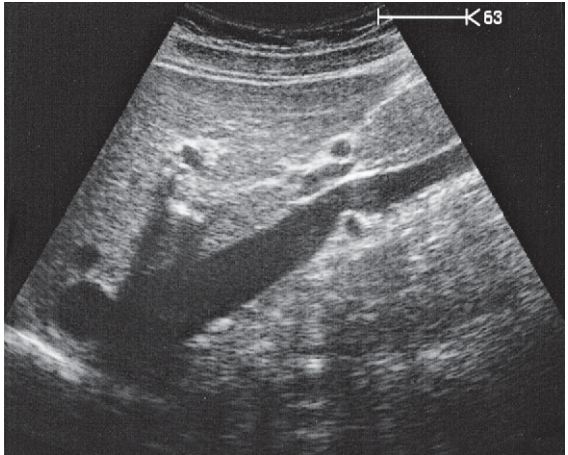
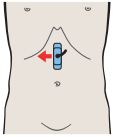


The hepatic artery turns upward and to the right and runs along the inferior border of the liver toward the porta hepatis.

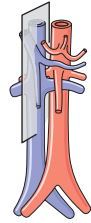
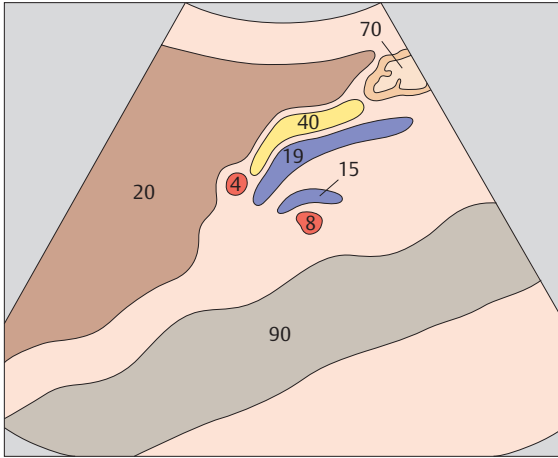




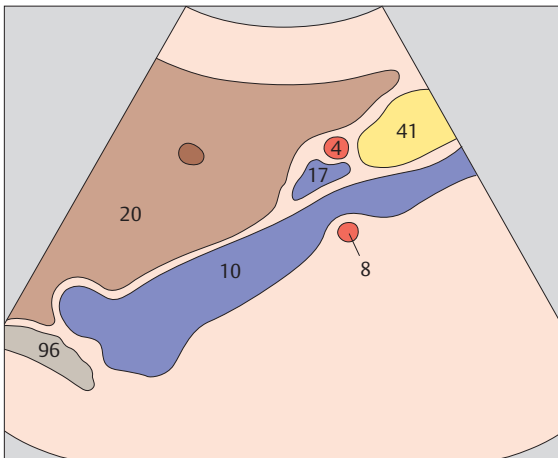
▶ 33 Hepatic artery and superior mesenteric vein



▶ 34 Hepatic artery and portal vein

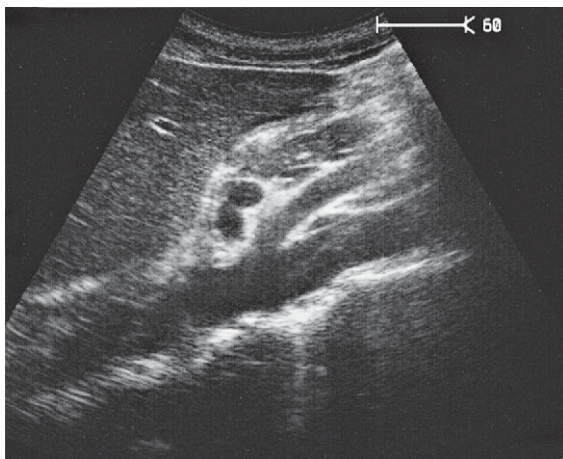
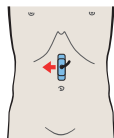


A longitudinal scan between the aorta and vena cava typically displays sections of four vessels: the hepatic artery, venous confluence, left renal vein, and right renal artery.

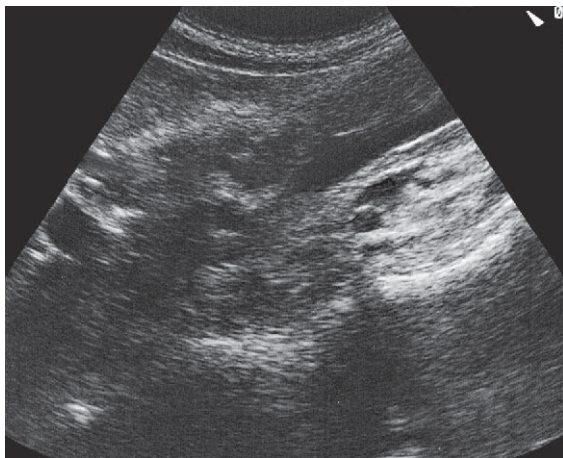
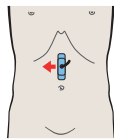


A longitudinal scan over the vena cava displays four typical vascular sections: the vena cava, portal vein, hepatic artery, and renal artery.

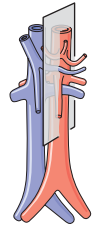
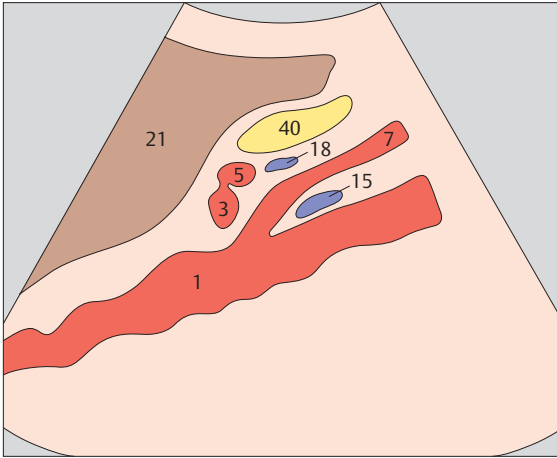




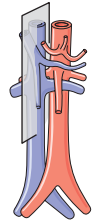
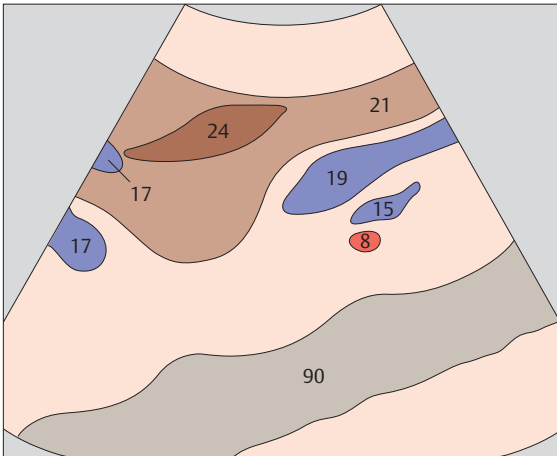
▶ 35 Aorta



▶ 36 Right renal artery and left renal vein

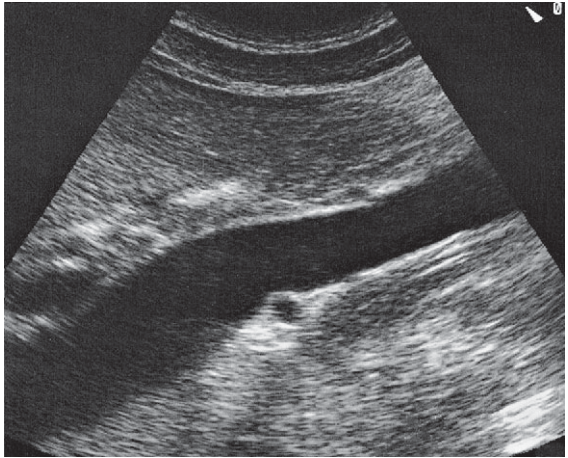
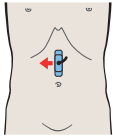


The left renal vein runs between the aorta and superior mesenteric artery, where it is subject to physiologic compression.

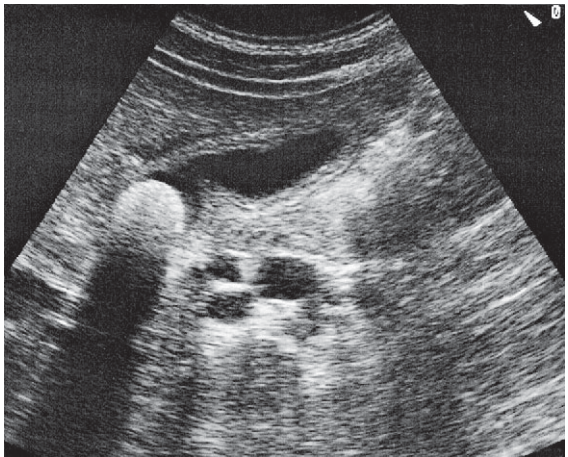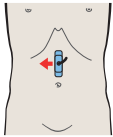


The section of the right renal artery can be identified between the aorta and vena cava. Just above the renal artery are the left renal vein and a longitudinal section of the superior mesenteric vein.

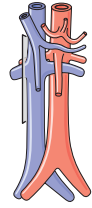
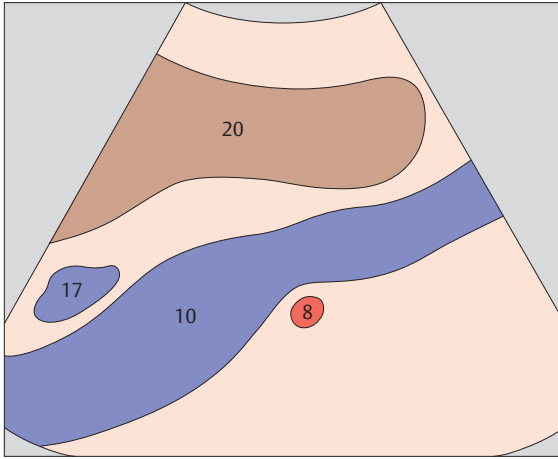




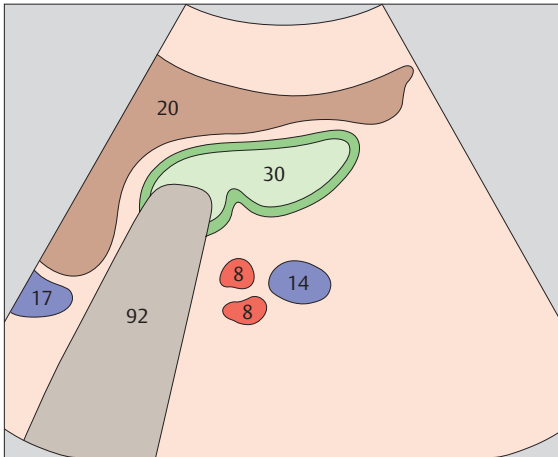
▶ 37 Vena cava and right renal artery



▶ 38 Right renal artery and right renal vein

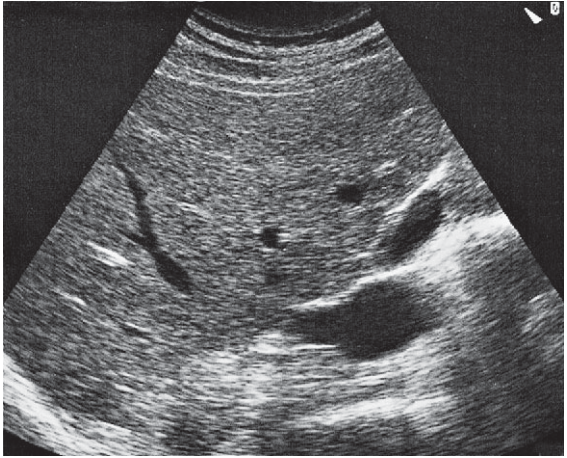
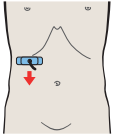
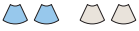

The right renal artery usually impresses the posterior surface of the vena cava, although variants may occur.

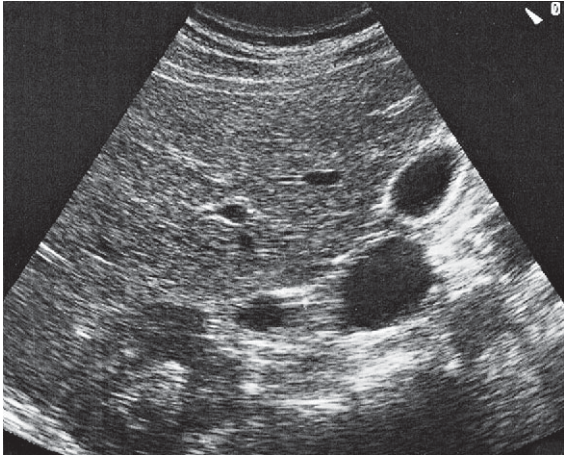
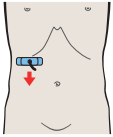


The renal veins are often more than twice the diameter of the renal arteries.

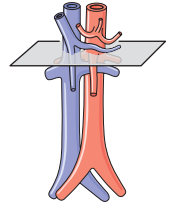
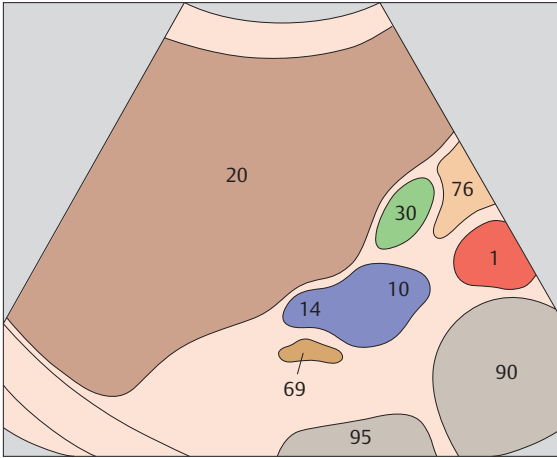




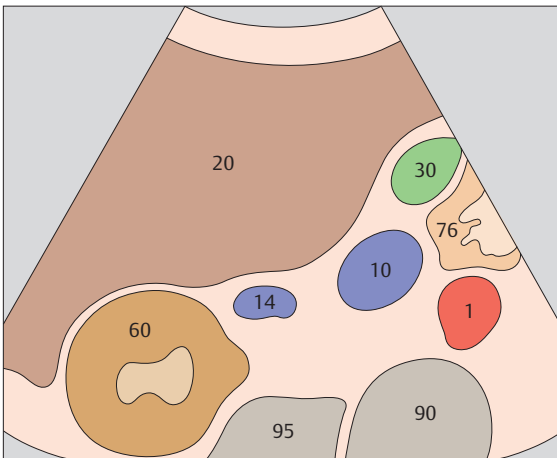
▶ 39 Opening of renal vein



▶ 40 Renal vein

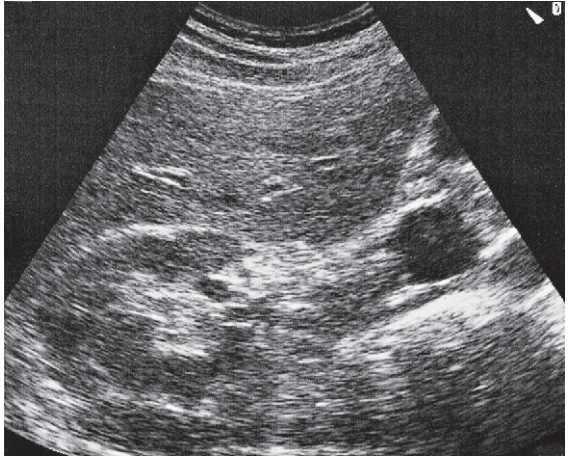
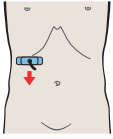
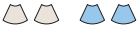

The opening of the right renal vein at the vena cava can be clearly defined above the kidney in most subjects.

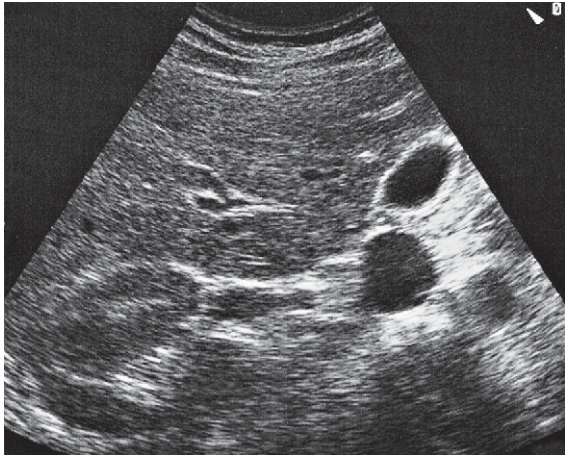
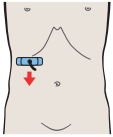


In serial transverse scans down the vena cava, the oval cross section of the renal vein separates from the vena cava and moves laterally toward the kidney.

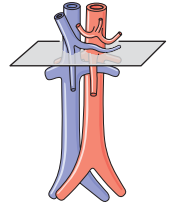
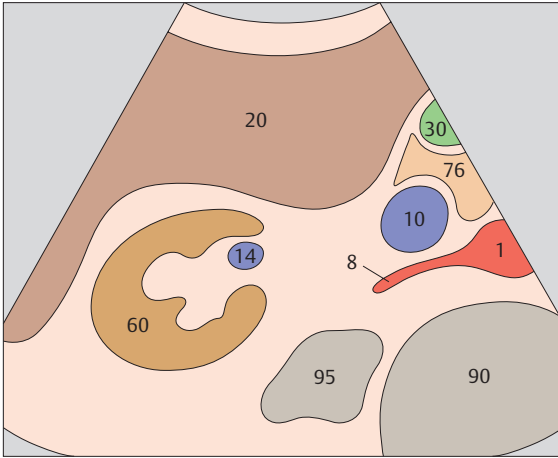




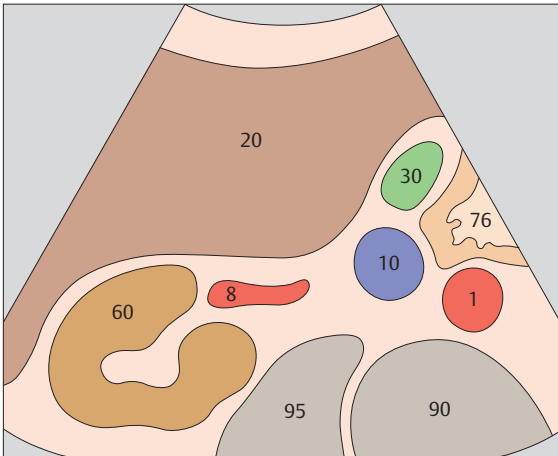
▶ 41 Renal vein at hilum, renal artery



▶ 42 Renal artery

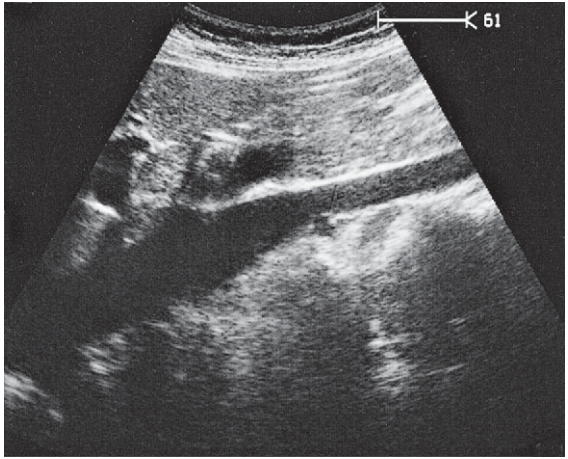
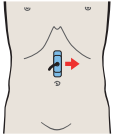


The renal artery follows the same course as the renal vein, but at a slightly more caudal level.

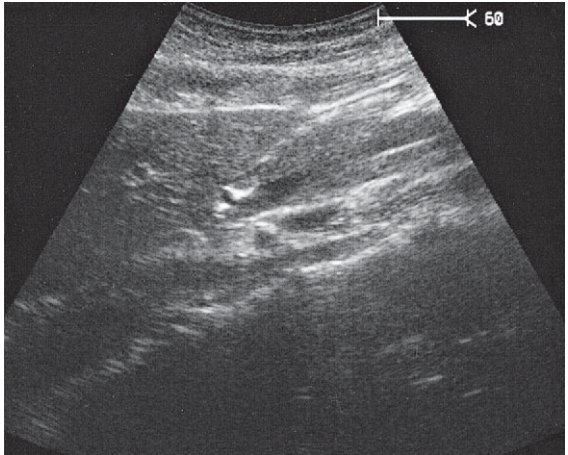
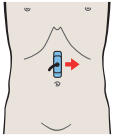


The renal arteries are located posterior and caudal to the renal veins.

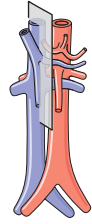
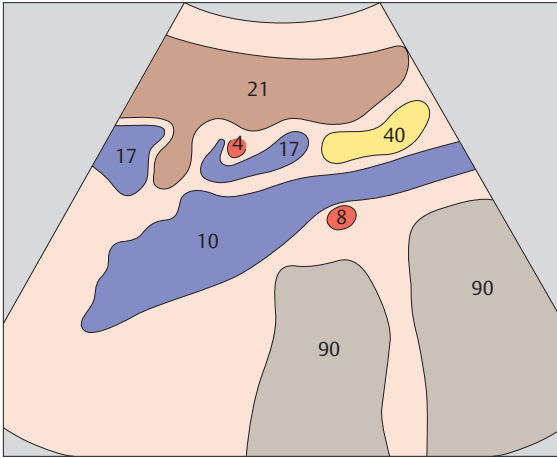




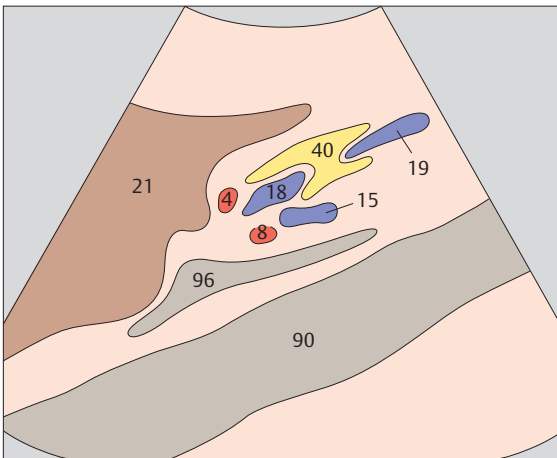
▶ 43 Vena cava



▶ 44 Right renal artery and left renal vein

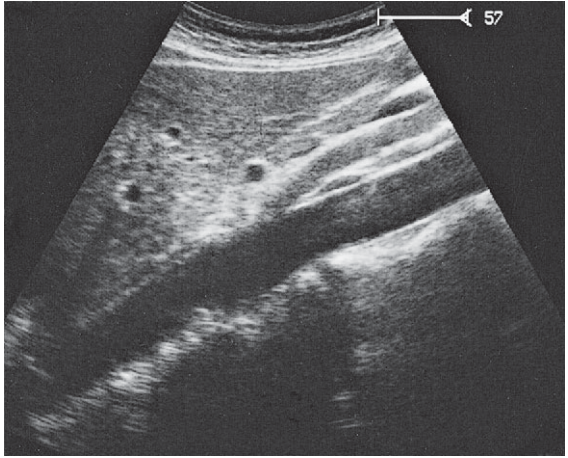
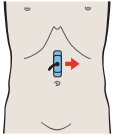


The right renal artery passes behind the vena cava, impressing its posterior surface.

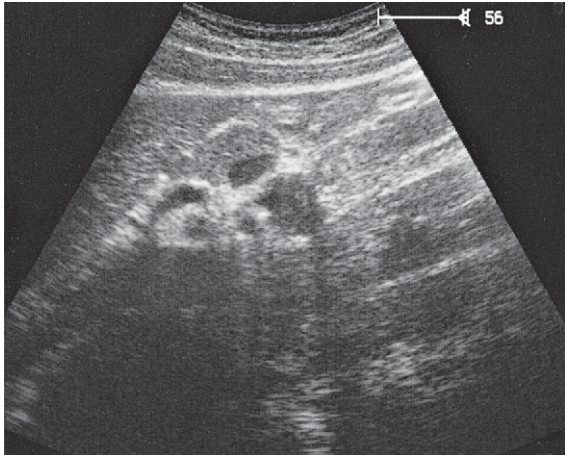
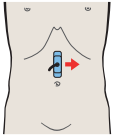


The scan plane cuts the left renal vein and right renal artery between the aorta and vena cava.

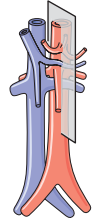
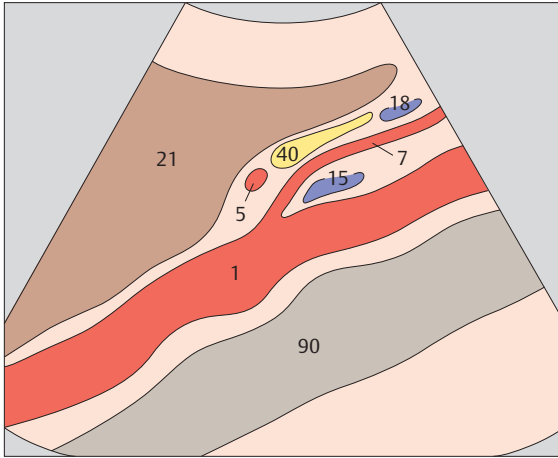




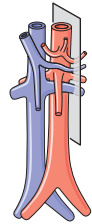
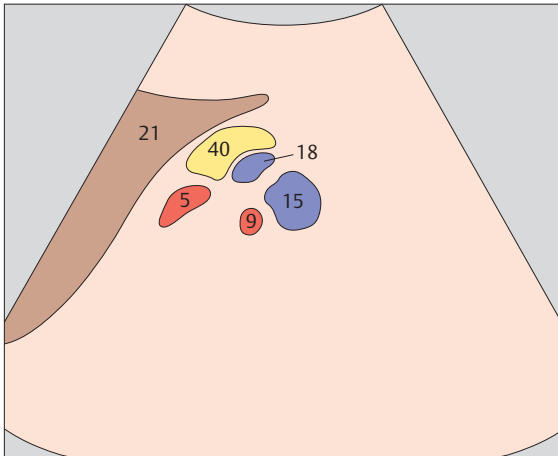
▶ 45 Aorta and left renal vein



▶ 46 Left renal vessels, splenic artery and vein

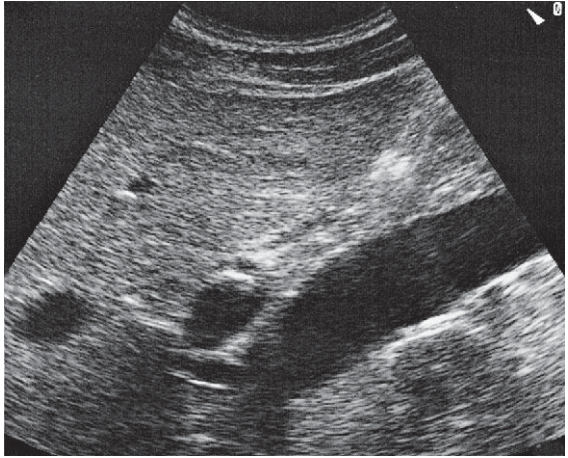
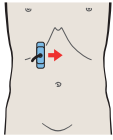
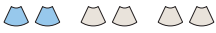

The left renal vein runs between the aorta and superior mesenteric artery.

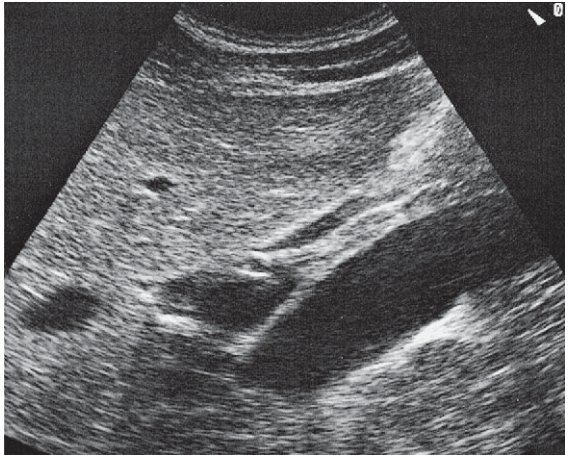
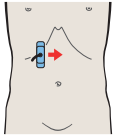


The left renal vessels are often difficult to scan because of overlying air.

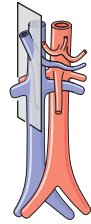
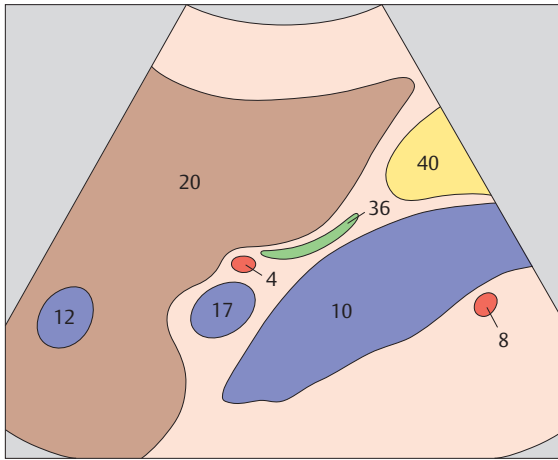




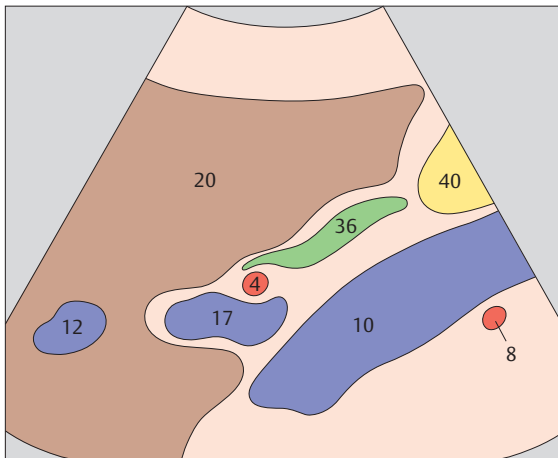
▶ 47 Portal vein, vena cava, right renal artery



▶ 48 Portal vein, vena cava, right renal artery

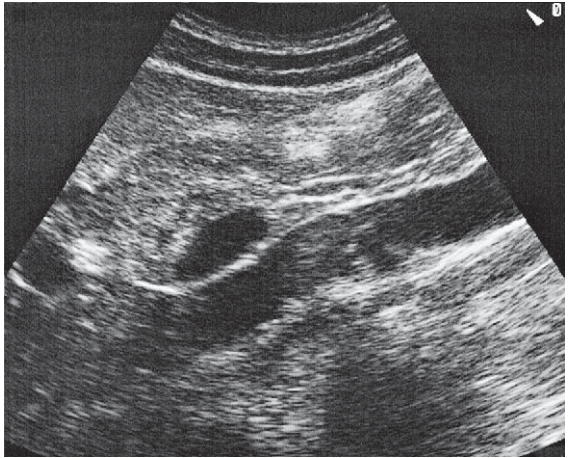
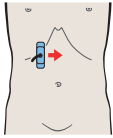
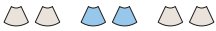

The triad of the portal vein, vena cava, and right renal artery provides a typical landmark in the upper abdominal longitudinal scan.

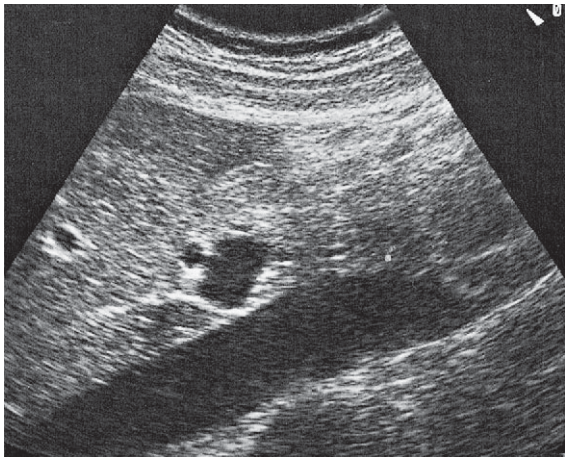
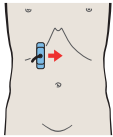


When the triad of the portal vein, vena cava, and right renal artery is identified, the scan will usually include a longitudinal section of the bile duct.

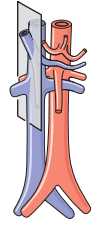
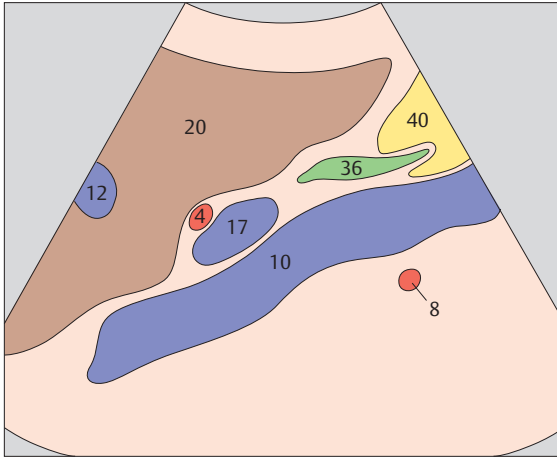




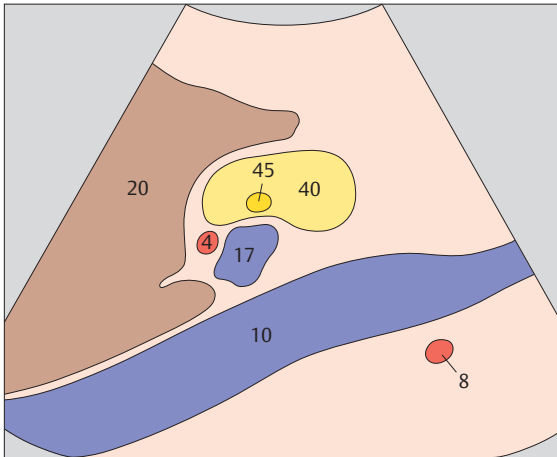
▶ 49 Portal vein, vena cava, and bile duct



▶ 50 Portal vein and hepatic artery

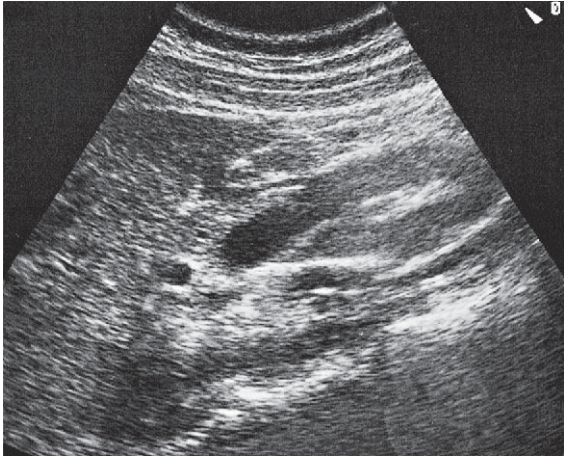
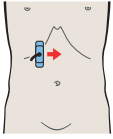
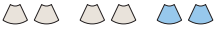

The bile duct enters the head of the pancreas anterior to the vena cava.

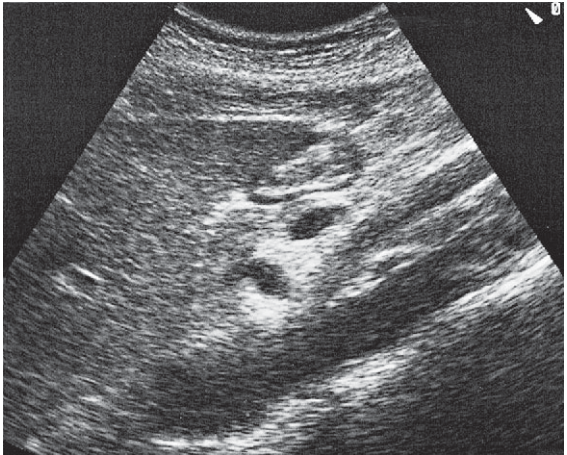
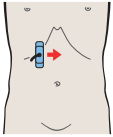


The portal vein and hepatic artery run side-by-side posterior to the head of the pancreas.

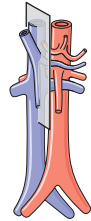
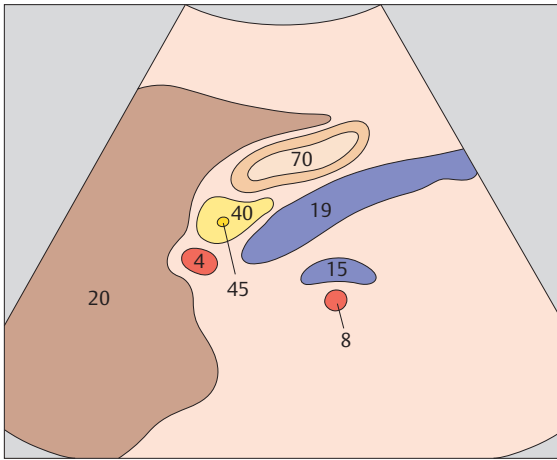




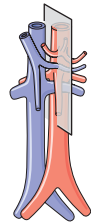
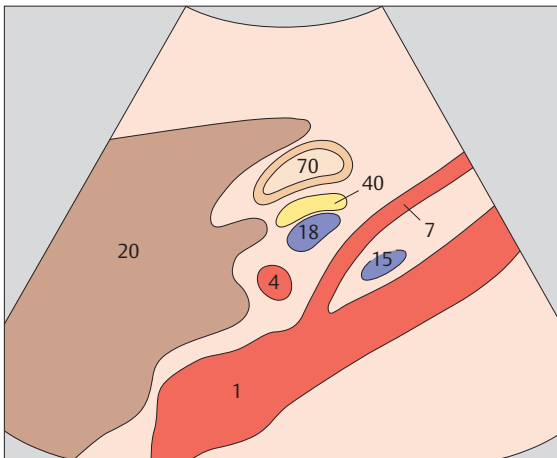
▶ 51 Hepatic artery, superior mesenteric vein



▶ 52 Hepatic artery, superior mesenteric artery, and splenic vein

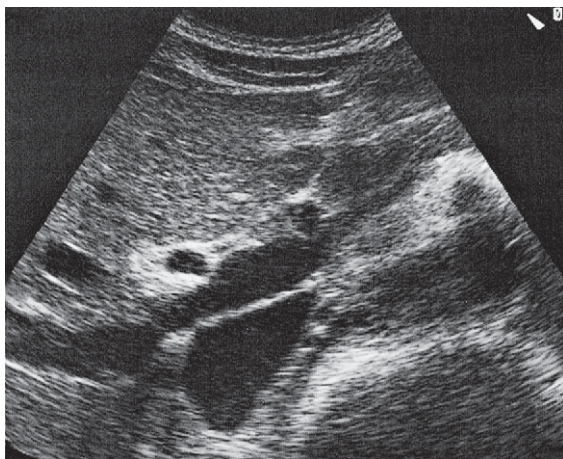
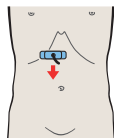


When the mesenteric vein is viewed in longitudinal section, typically the scan will also display the hepatic artery cranially and the right renal artery and left renal vein posteriorly.

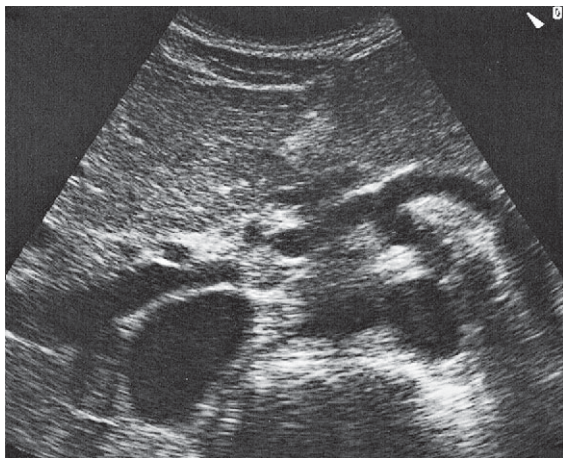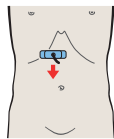


When the superior mesenteric artery is viewed in longitudinal section, typically the scan will also show the hepatic artery, splenic vein, and left renal vein.

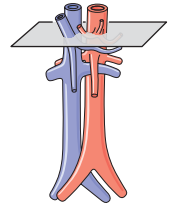
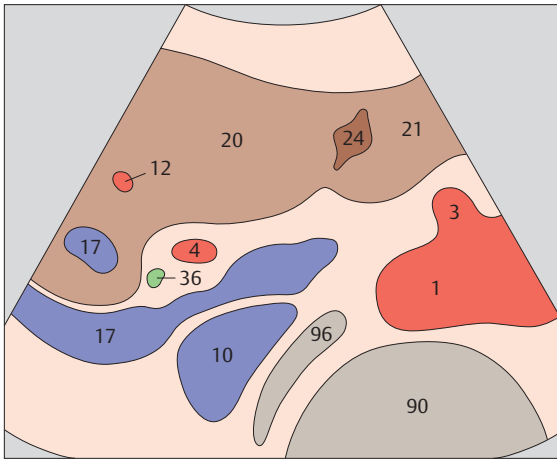




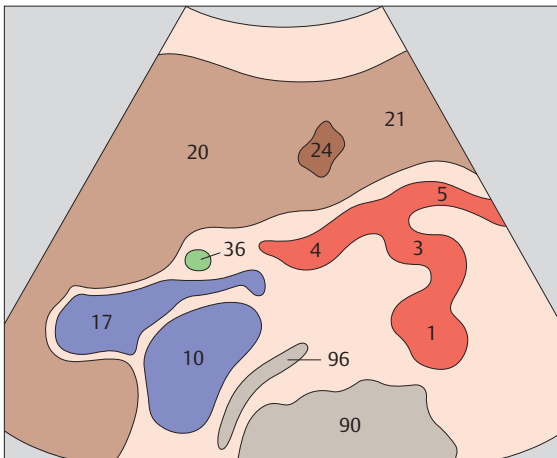
► 53 Hepatic artery, portal vein, vena cava



► 54 Hepatic artery, bile duct, portal vein

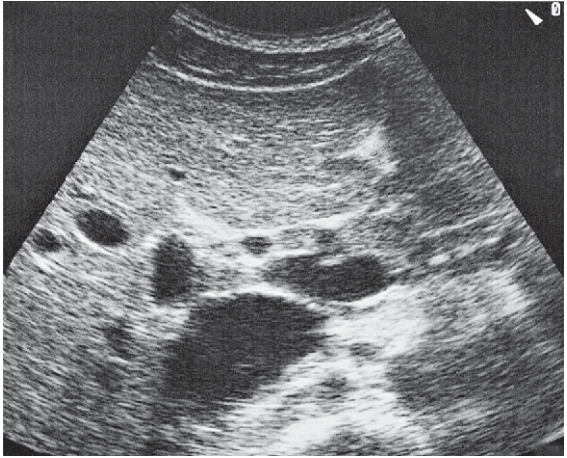
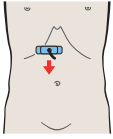


The portal vein runs between the vena cava and hepatic artery.

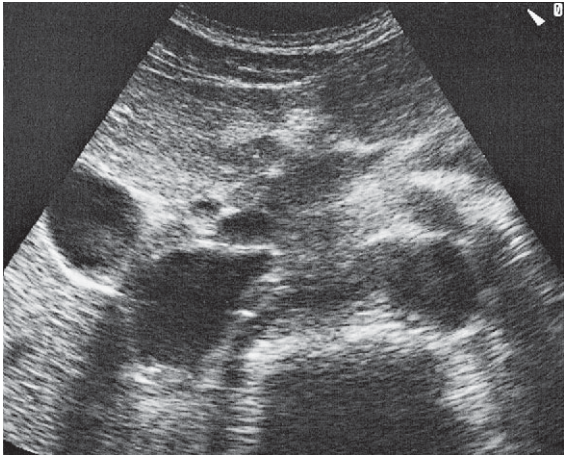
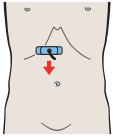


The hepatic artery runs cephalad into the porta hepatis.

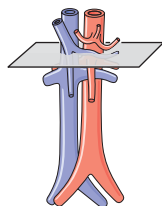
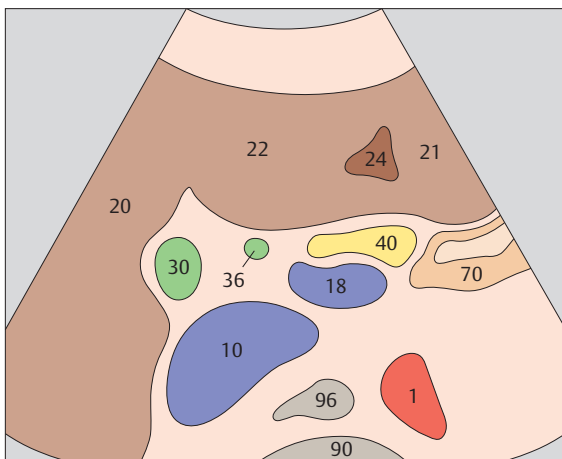




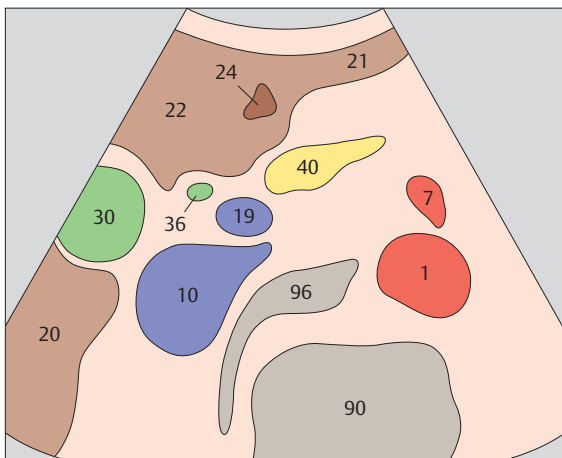
▶ 55 Bile duct, gallbladder, vena cava



▶ 56 Bile duct, gallbladder, superior mesenteric vein



The bile duct is identified medial to the gallbladder and anterior to the vena cava.



The bile duct runs parallel to the superior mesenteric vein for a short distance, then turns laterally to the right toward the papilla.



2 Liver

Liver in Longitudinal Sections

- 57 Left lobe of liver, lateral segment, subsegments II and III
- 58 Left lobe of liver, ligamentum teres, boundary between lateral and medial segments
- 59 Left lobe of liver, ligamentum teres, boundary between lateral and medial segments
- 60 Left lobe of liver, ligamentum teres, boundary between lateral and medial segments, caudate lobe
- 61 Left hepatic vein, ligamentum teres, boundary between lateral and medial segments, caudate lobe
- 62 Left hepatic vein, ligamentum teres, boundary between lateral and medial segments, caudate lobe
- 63 Left hepatic vein, ligamentum teres, boundary between lateral and medial segments, caudate lobe
- 64 Medial segment, subsegment IV, quadrate lobe
- 65 Gallbladder, portal vein, vena cava, boundary between medial and anterior segments
- 66 Middle hepatic vein, boundary between medial and anterior segments
- 67 Anterior segment, subsegments VIII and V
- 68 Right hepatic vein, boundary between anterior and posterior segments
- 69 Posterior segment, subsegments VII and VI
- 70 Posterior segment, lateral portions of liver, kidney

Left Portions of the Liver in Transverse Sections

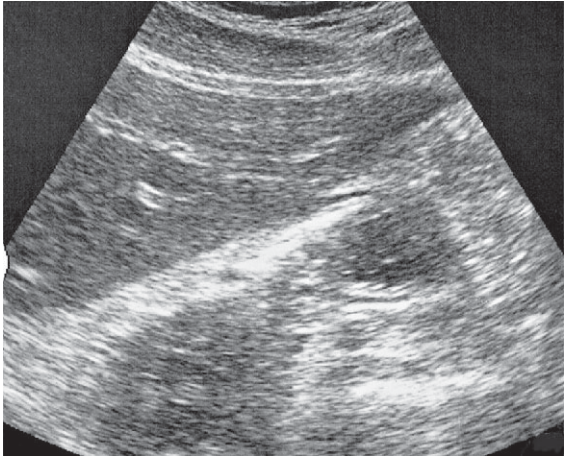
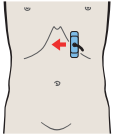
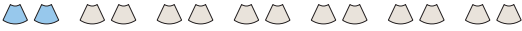- 71 Left lobe of liver, lateral segment, heart
- 72 Left lobe of liver, lateral segment, heart
- 73 Left lobe of liver, lateral segment, hepatic veins
- 74 Left lobe of liver, lateral segment, caudate lobe
- 75 Left lobe of liver, lateral segment, caudate lobe
- 76 Left lobe of liver, lateral segment, left portal vein branch
- 77 Left lobe of liver, lateral segment, ligamentum teres
- 78 Left lobe of liver, subsegment III, ligamentum teres

Central Portions of the Liver in Transverse Sections

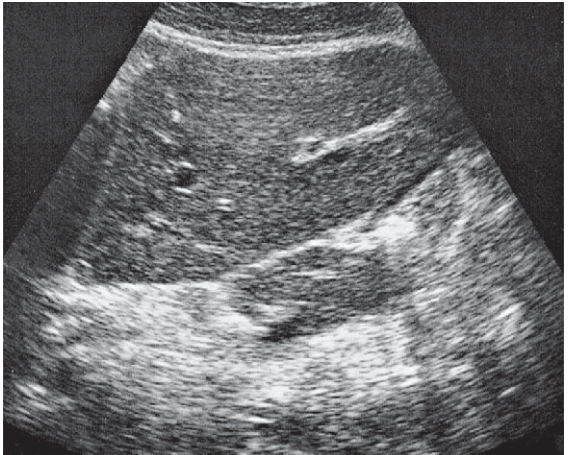
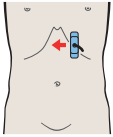
- 79 Medial and anterior hepatic segments, opening of hepatic veins
- 80 Medial and anterior hepatic segments, opening of hepatic veins
- 81 Medial and anterior hepatic segments, hepatic veins, caudate lobe
- 82 Medial and anterior hepatic segments, hepatic veins, caudate lobe
- 83 Medial and anterior hepatic segments, caudate lobe
- 84 Medial and anterior hepatic segments, left portal vein branch, caudate lobe
- 85 Medial and anterior hepatic segments, left portal vein branch, caudate lobe
- 86 Medial and anterior hepatic segments, left portal vein branch, caudate lobe
- 87 Medial and anterior hepatic segments, bifurcation of portal vein
- 88 Medial and anterior hepatic segments, bifurcation of portal vein
- 89 Medial and anterior hepatic segments, right portal vein branch
- 90 Medial and anterior hepatic segments, right and left portal vein branches
- 91 Medial and anterior hepatic segments, right and left portal vein branches
- 92 Medial and anterior hepatic segments, quadrate lobe, ligamentum teres, portal vein
- 93 Medial and anterior hepatic segments, quadrate lobe, ligamentum teres, portal vein
- 94 Medial and anterior hepatic segments, quadrate lobe, ligamentum teres, gallbladder
- 95 Medial and anterior hepatic segments, quadrate lobe, ligamentum teres, gallbladder
- 96 Inferior border of liver, kidney, gallbladder, ligamentum teres

Right Portions of the Liver in Transverse Sections

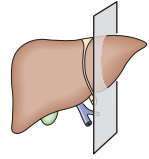
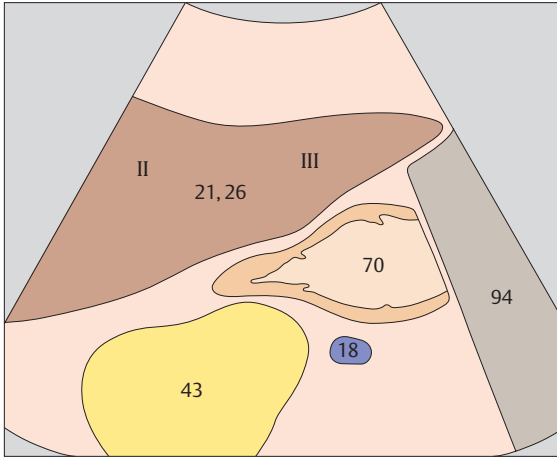
- 97 Posterior segment, cranial subsegment
- 98 Posterior segment, portal vein
- 99 Posterior segment, caudal subsegment, kidney
- 100 Posterior segment, inferior border



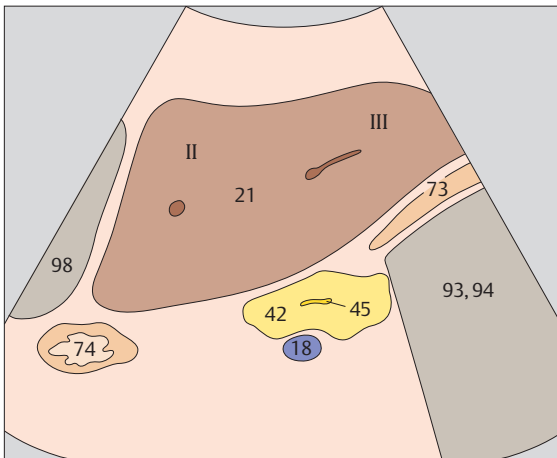
► 57 Left lobe of liver, lateral segment, subsegments II and III



► 58 Left lobe of liver, ligamentum teres, boundary between lateral and medial segments

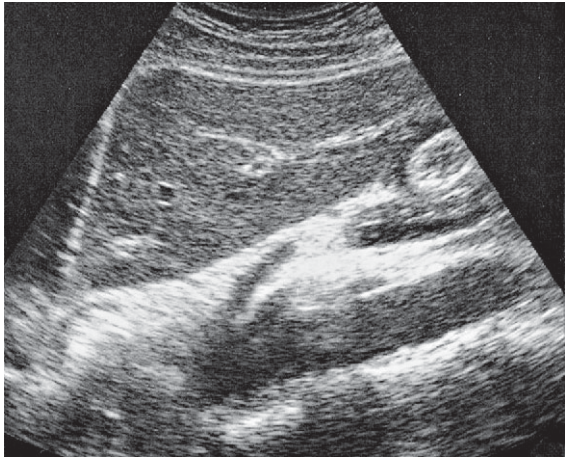
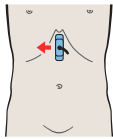
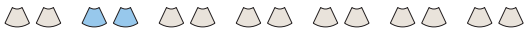

The liver is divided into a left and a right lobe on anatomical criteria. The left lobe corresponds to the lateral segment; the right lobe consists of the medial, anterior, and posterior segments.

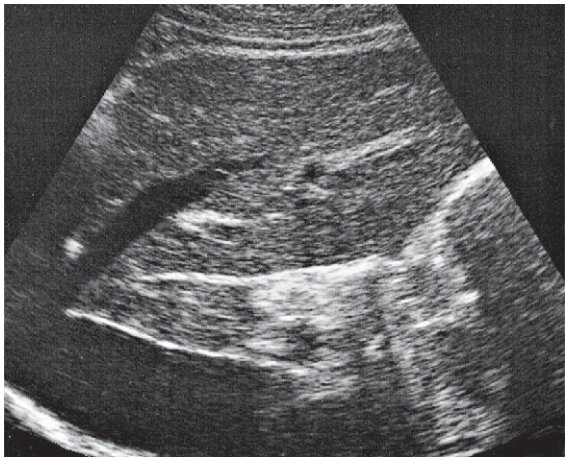
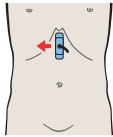


On functional criteria, the lateral and medial segments belong to the left lobe of the liver while the anterior and posterior segments belong to the right lobe.

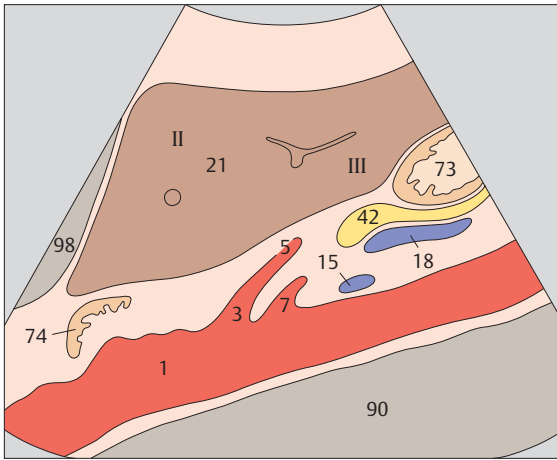




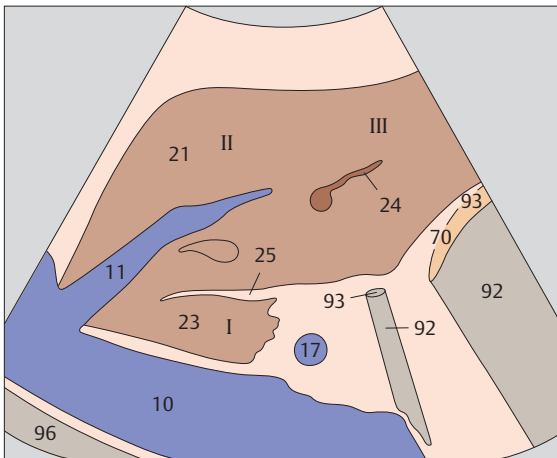
- ▶ 59 Left lobe of liver, ligamentum teres, boundary between lateral and medial segments



- ▶ 60 Left hepatic vein, ligamentum teres, boundary between lateral and medial segments, caudate lobe

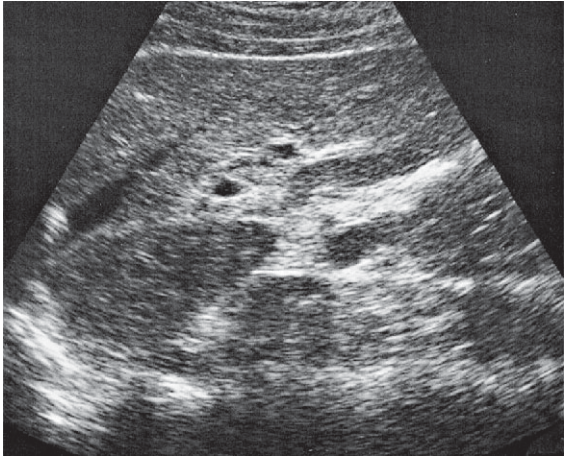
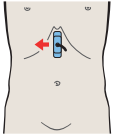
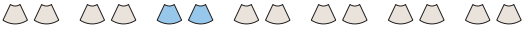

The lateral segment is composed of subsegment II cranially and subsegment III caudally.

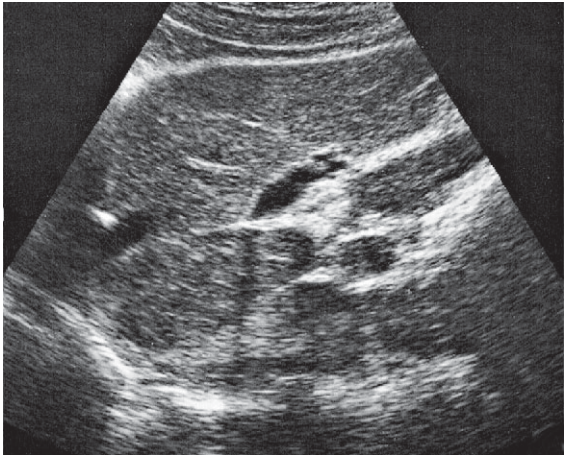
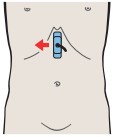


The boundary between the lateral and medial segments, i.e., between the anatomical left and right lobes of the liver, is the left hepatic vein.

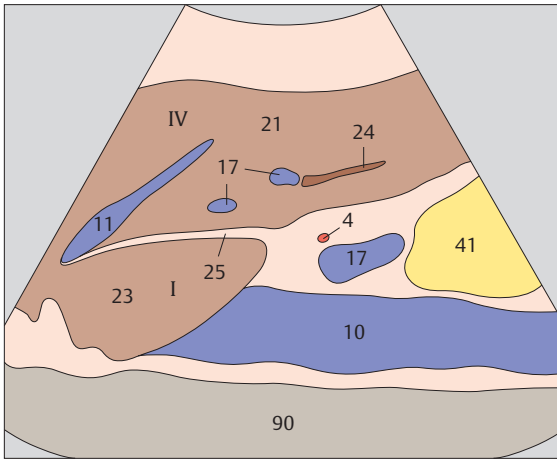




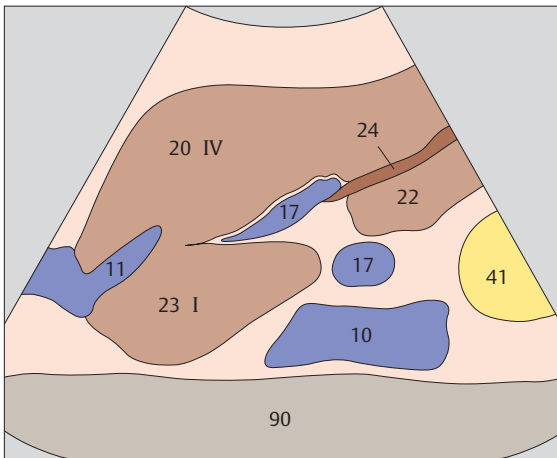
- ▶ **61** Left hepatic vein, ligamentum teres, boundary between lateral and medial segments, caudate lobe



- ▶ **62** Left hepatic vein, ligamentum teres, boundary between lateral and medial segments, caudate lobe

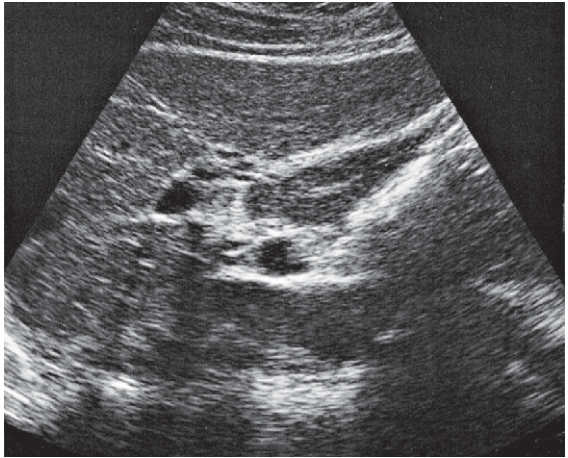
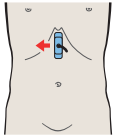
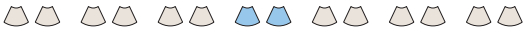

The caudate lobe corresponds to subsegment I of the medial segment and is located lateral and anterior to the vena cava. Most of the medial segment consists of subsegment IV.

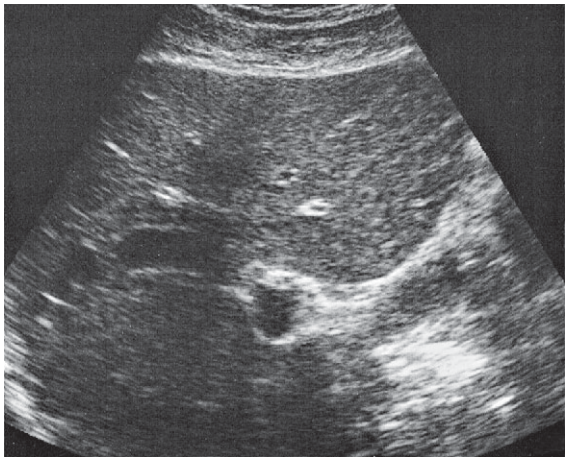
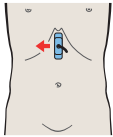


The boundary between the lateral and medial segments, i.e., between the anatomical left and right lobes of the liver, is the ligamentum teres.

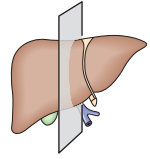
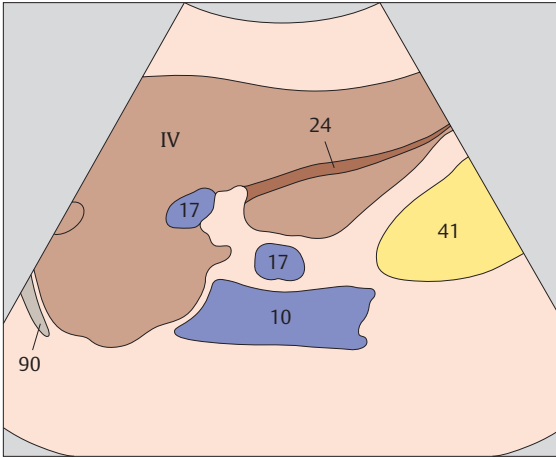




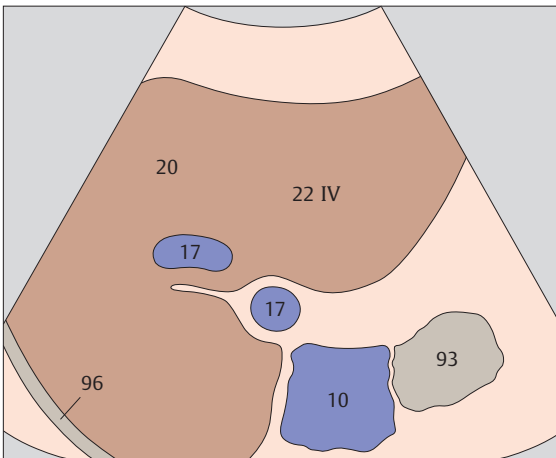
- ▶ **63** Left hepatic vein, ligamentum teres, boundary between lateral and medial segments, caudate lobe



- ▶ **64** Medial segment, subsegment IV, quadrate lobe

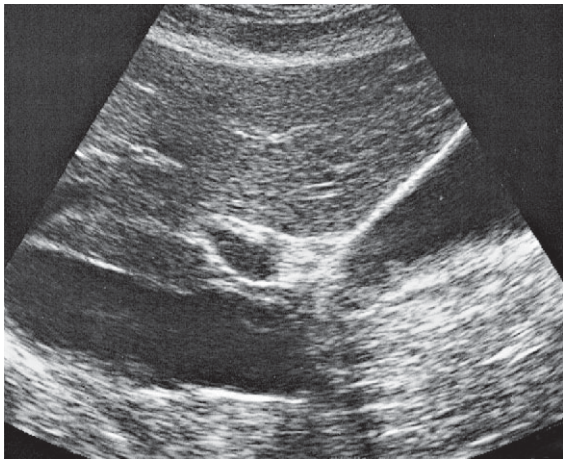
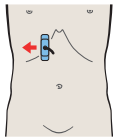
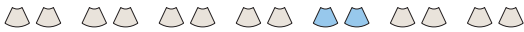

Ligamentum teres (the obliterated umbilical vein) extends from the left portal vein branch to the anterior inferior border of the liver.

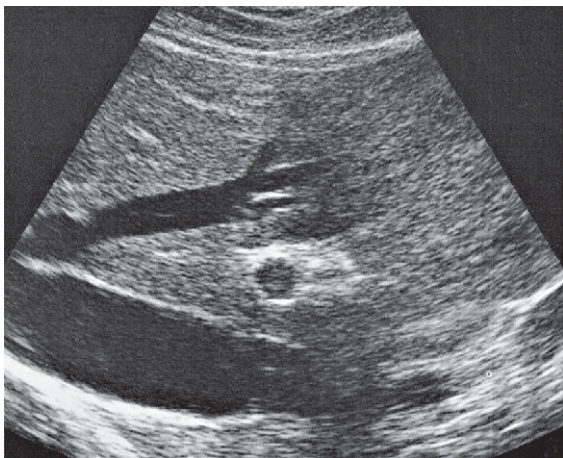
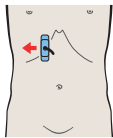


The caudal part of the medial segment, the quadrangle lobe, is situated between ligamentum teres and the gallbladder. The quadrangle lobe is part of subsegment IV.

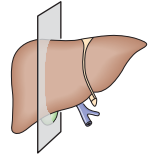
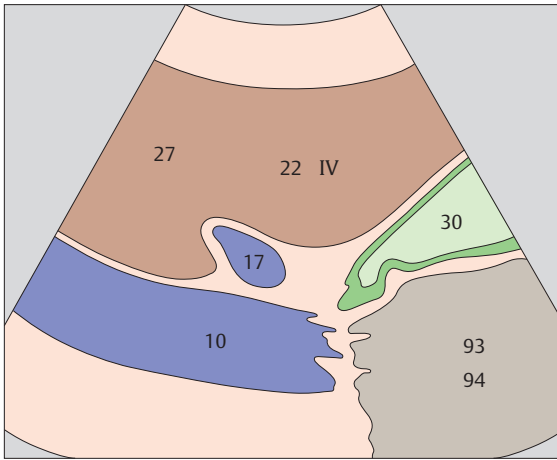




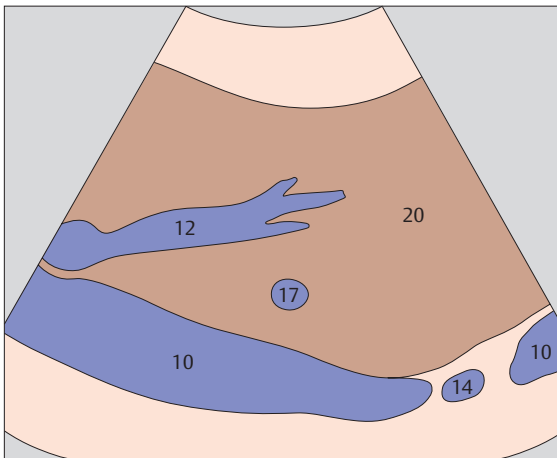
- ▶ 65 Gallbladder, portal vein, vena cava, boundary between medial and anterior segments



- ▶ 66 Middle hepatic vein, boundary between medial and anterior segments

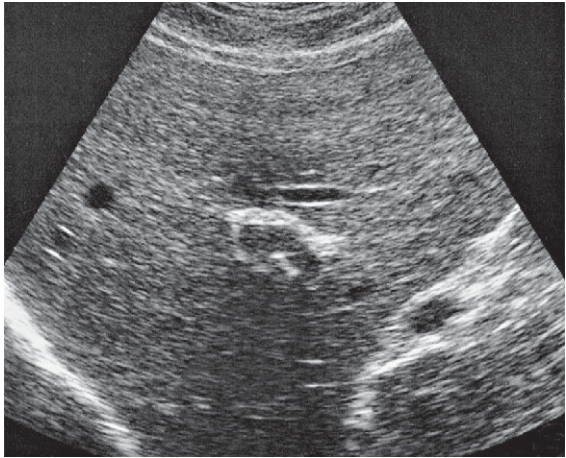
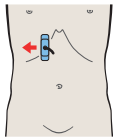
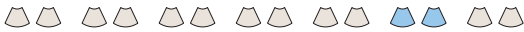

The plane of the gallbladder and vena cava forms the boundary plane between the medial and anterior segments of the liver.

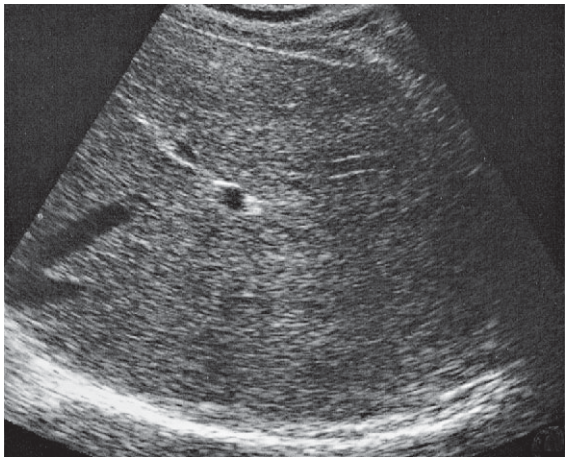
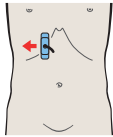


The middle hepatic vein marks the boundary between the medial and anterior segments in the cranial part of the liver.

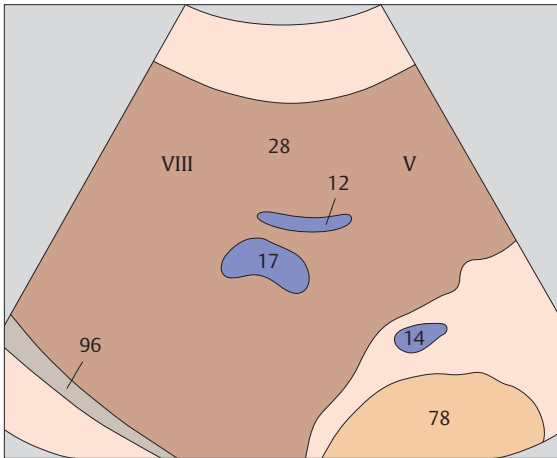




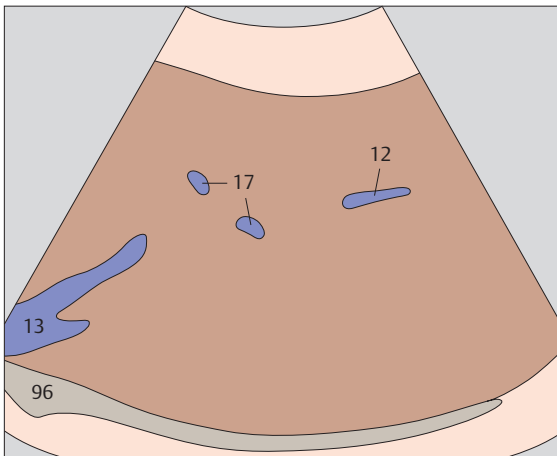
▶ 67 Anterior segment, subsegments VIII and V



▶ 68 Right hepatic vein, boundary between anterior and posterior segments

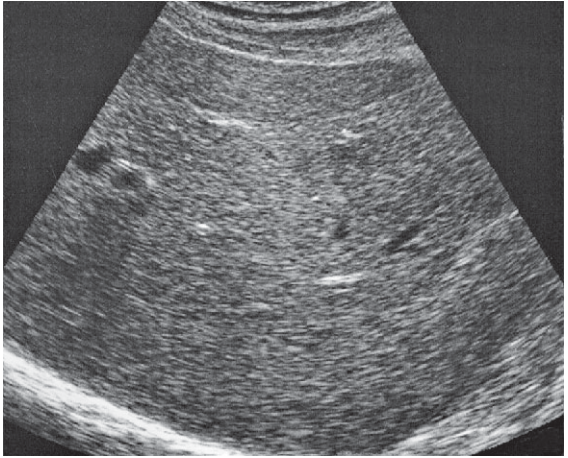
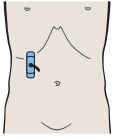
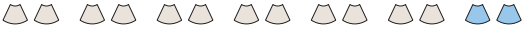

The anterior segment consists of subsegment VIII cranially and subsegment V caudally.

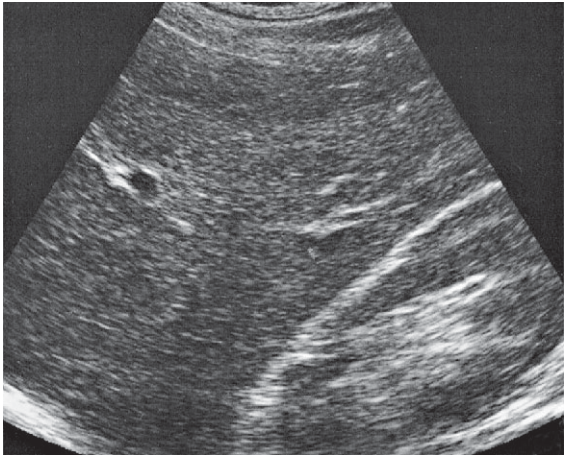
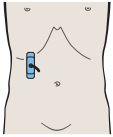


The right hepatic vein and the division of the right portal vein branch mark the boundary plane between the anterior and posterior segments.

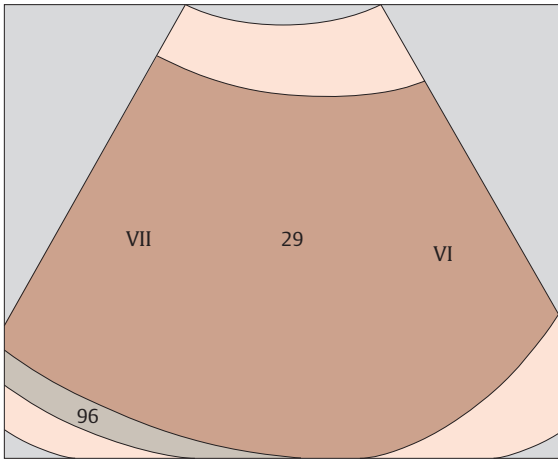




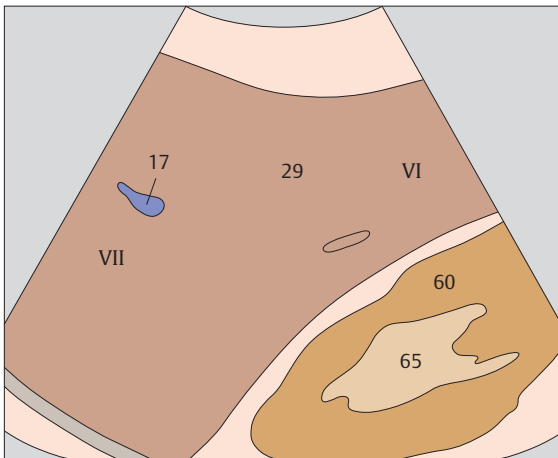
▶ 69 Posterior segment, subsegments VII and VI



▶ 70 Posterior segment, lateral portions of liver, kidney

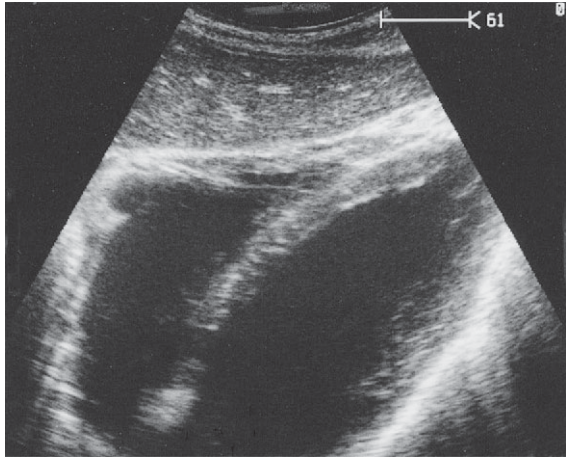
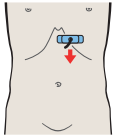
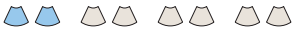

The posterior segment consists of subsegment VII cranially and subsegment VI caudally.

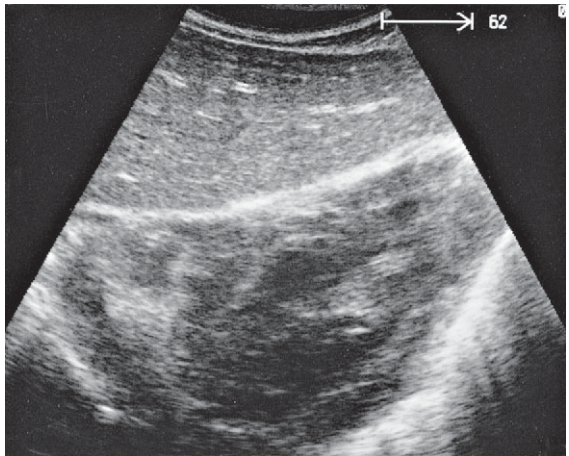
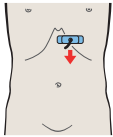


The right lobe of the liver is highly variable in its caudal extent.

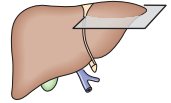
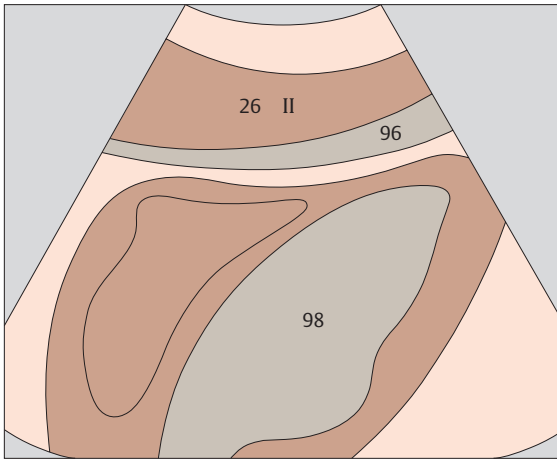




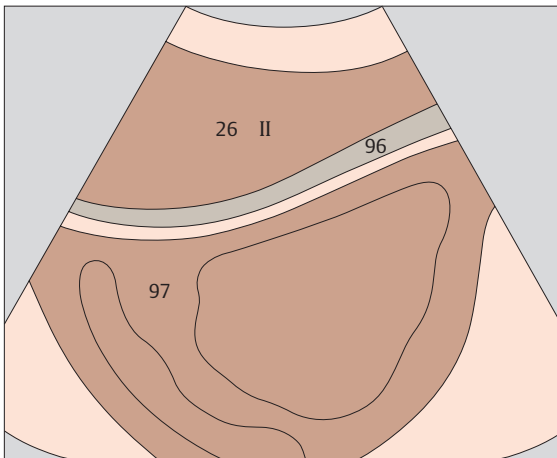
▶ 71 Left lobe of liver, lateral segment, heart



▶ 72 Left lobe of liver, lateral segment, heart

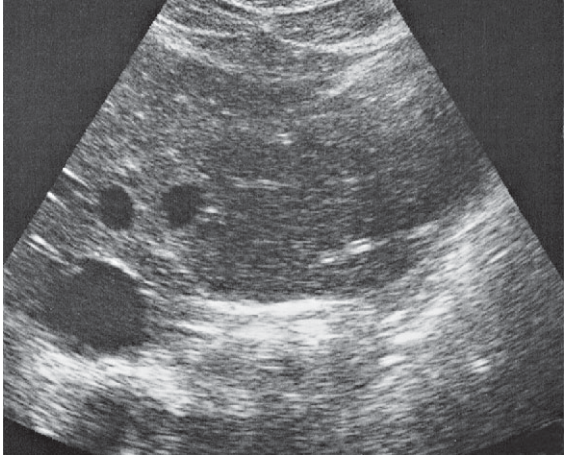
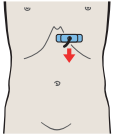


The left lobe of the liver is in close proximity to the heart, separated from it only by the diaphragm.

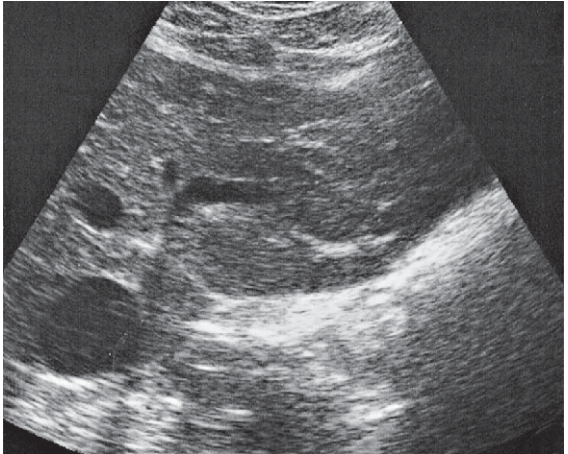
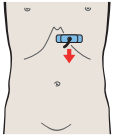


The anatomical left lobe of the liver corresponds to the lateral hepatic segment.

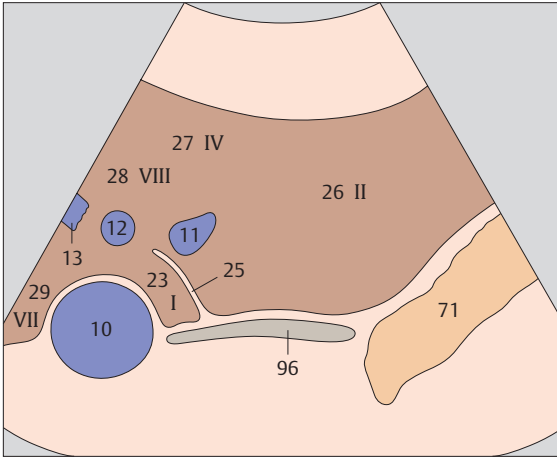




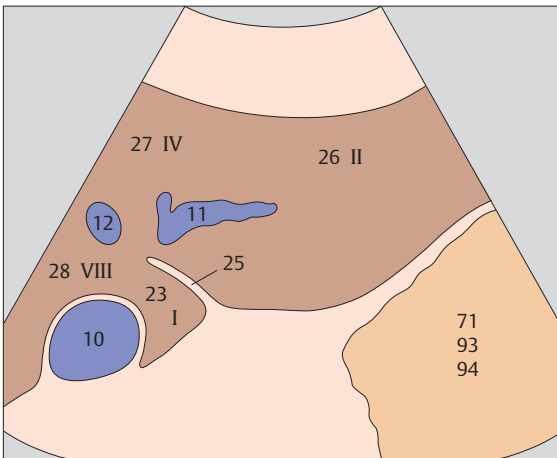
▶ 73 Left lobe of liver, lateral segment, hepatic veins



▶ 74 Left lobe of liver, lateral segment, caudate lobe

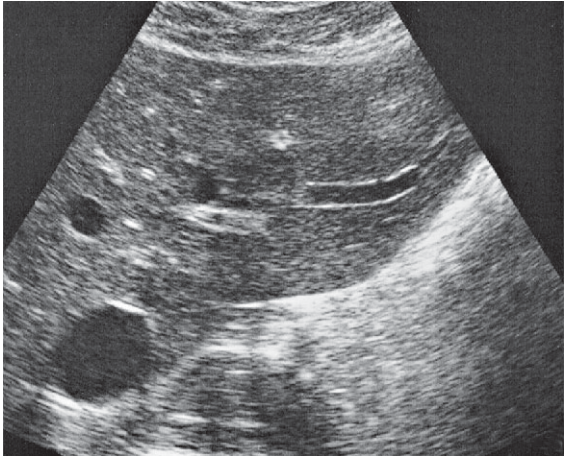
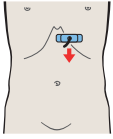


The left hepatic vein marks the boundary between the lateral and medial hepatic segments.

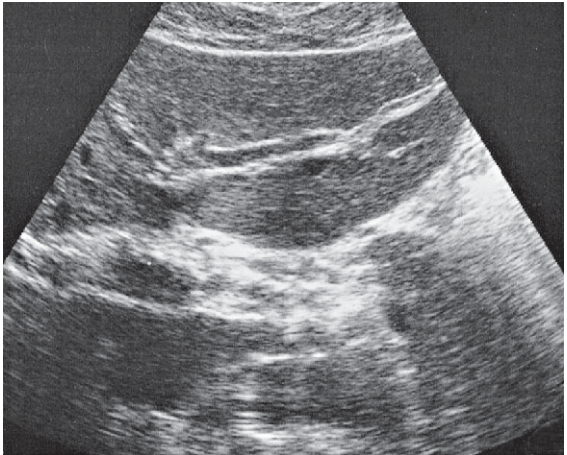
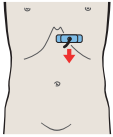


The cranial part of the lateral hepatic segment is designated as subsegment II.

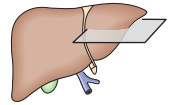
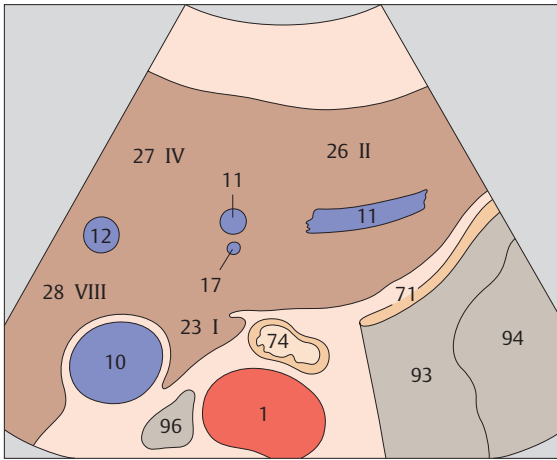




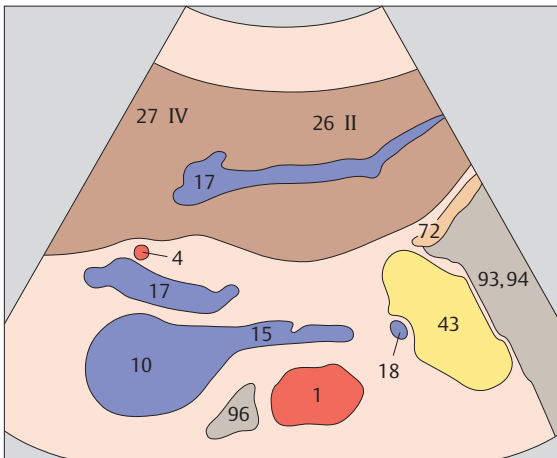
▶ 75 Left lobe of liver, lateral segment, caudate lobe



▶ 76 Left lobe of liver, lateral segment, left portal vein branch

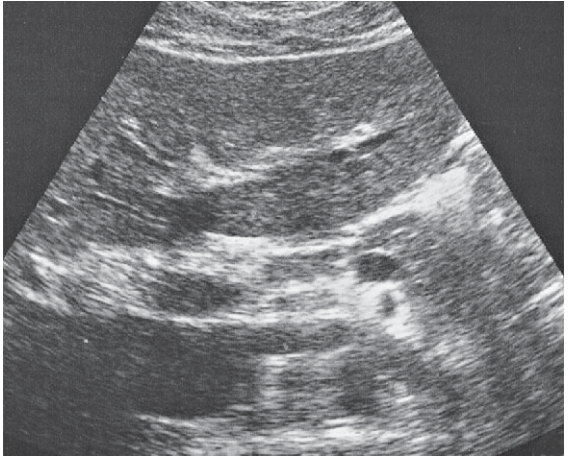
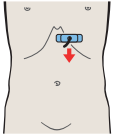


The caudate lobe is considered a separate entity, designated as subsegment I.

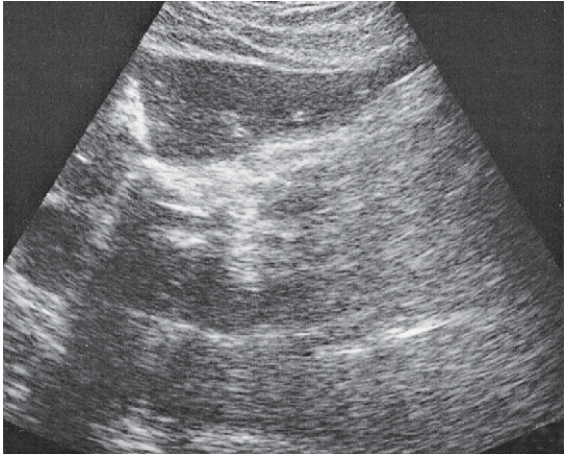
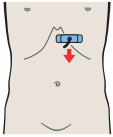


In scanning down the left lobe of the liver, the left branch of the portal vein marks the boundary between the cranial and caudal subsegments of the lobe.

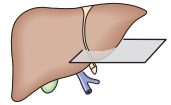
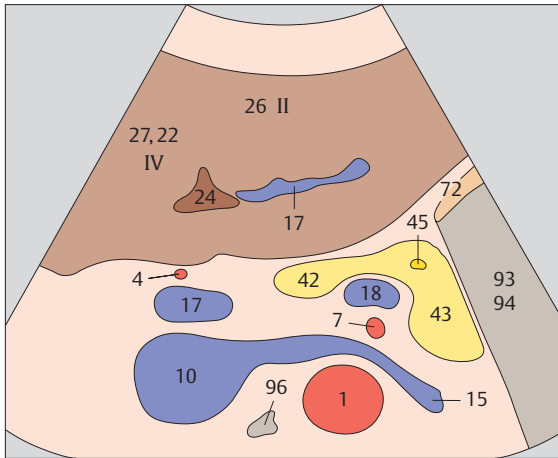




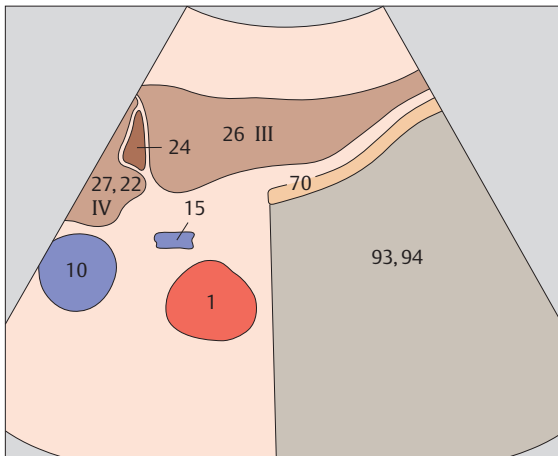
▶ 77 Left lobe of liver, lateral segment, ligamentum teres



▶ 78 Left lobe of liver, subsegment III, ligamentum teres

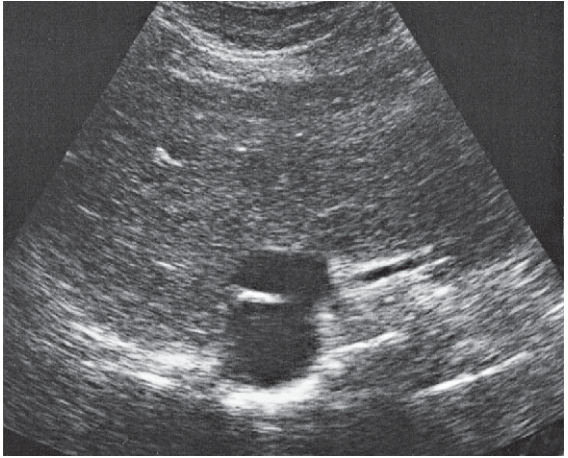
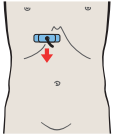
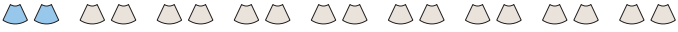

Ligamentum teres arises directly from the left portal vein branch and runs forward and downward.

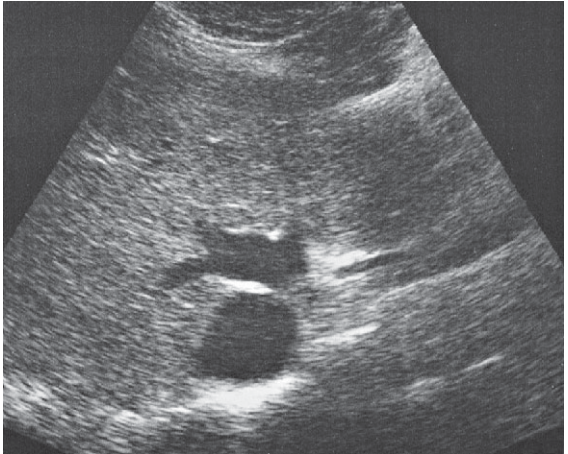
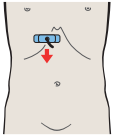


Ligamentum teres presents a triangular or polygonal shape in cross section. It marks the boundary between subsegment III and the quadrate lobe, which is designated as subsegment IVb.

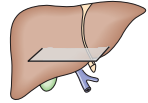
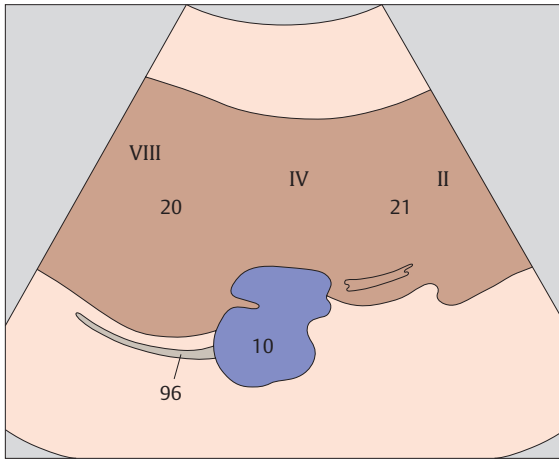




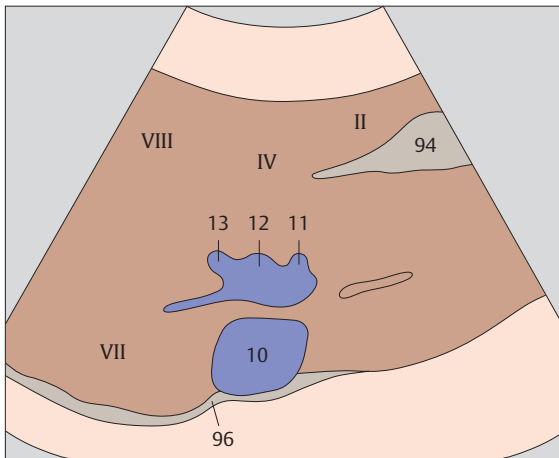
- ▶ **79** Medial and anterior hepatic segments,
opening of hepatic veins



- ▶ **80** Medial and anterior hepatic segments,
opening of hepatic veins

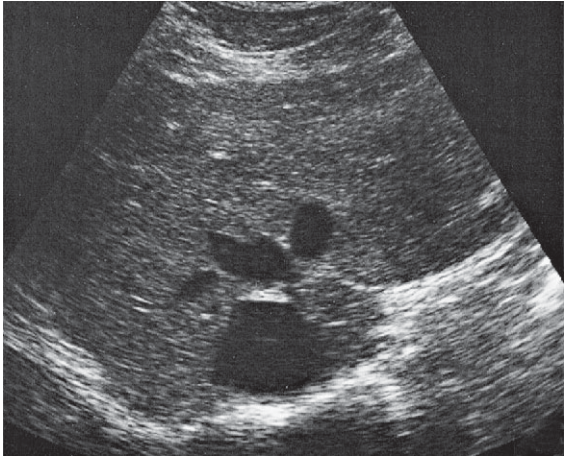
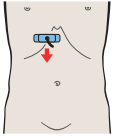
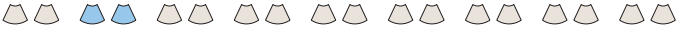

The hepatic veins converge and enter the vena cava just below the diaphragm.

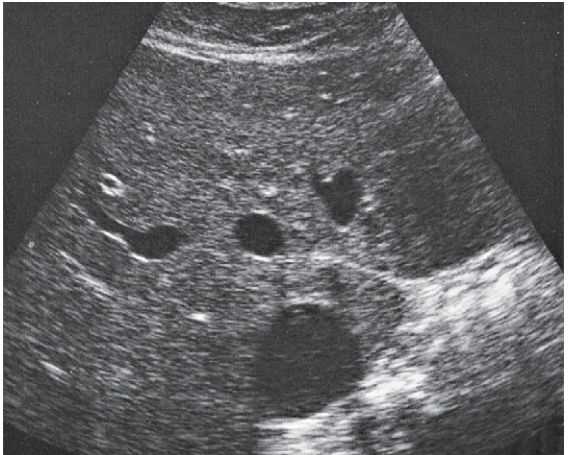
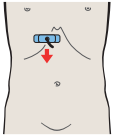


The opening of the hepatic veins at the vena cava forms a typical stellate pattern in transverse section.

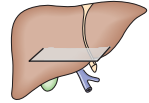
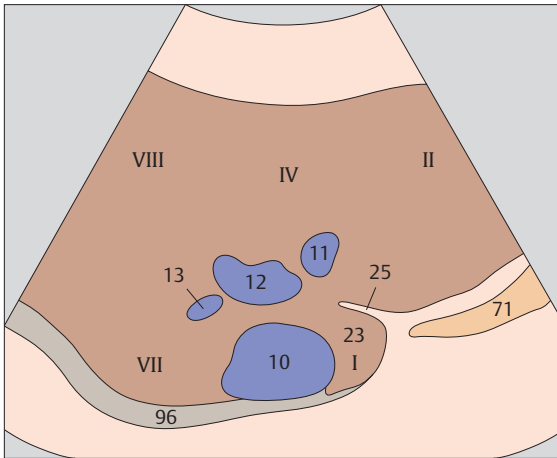




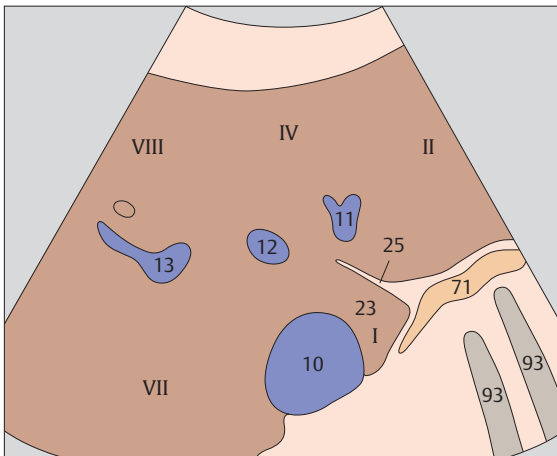
- ▶ **81** Medial and anterior hepatic segments, hepatic veins, caudate lobe



- ▶ **82** Medial and anterior hepatic segments, hepatic veins, caudate lobe

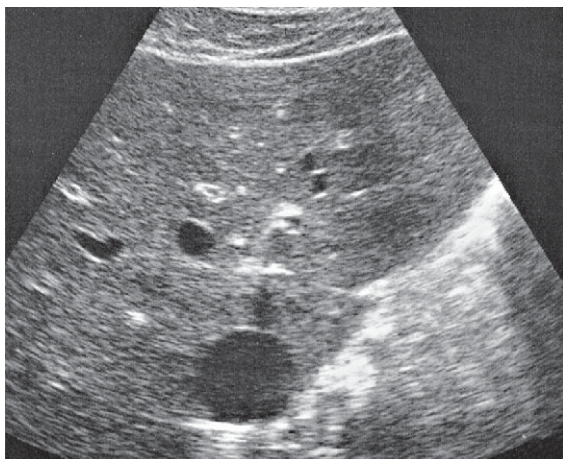
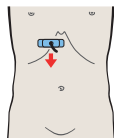
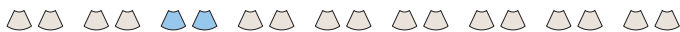

The upper pole of the caudate lobe extends to a point just below the opening of the hepatic veins into the vena cava.

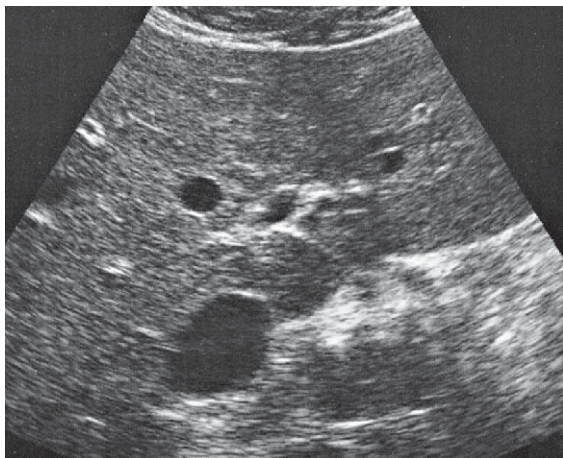
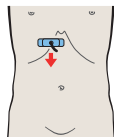


The three hepatic veins define the boundaries between the lateral, medial, anterior, and posterior segments of the liver.

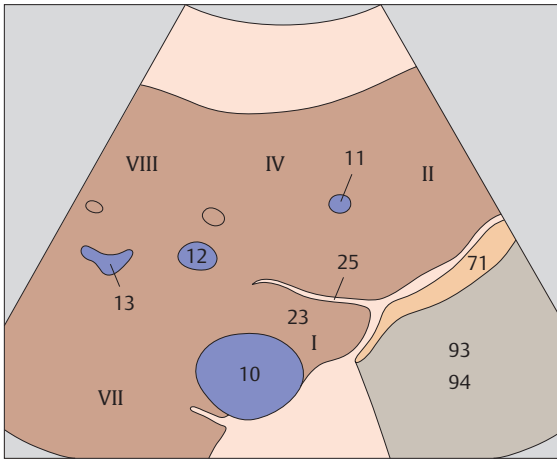




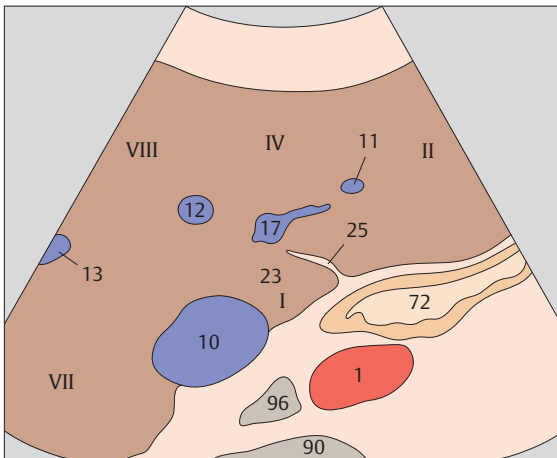
- ▶ **83** Medial and anterior hepatic segments, caudate lobe



- ▶ **84** Medial and anterior hepatic segments, left portal vein branch, caudate lobe

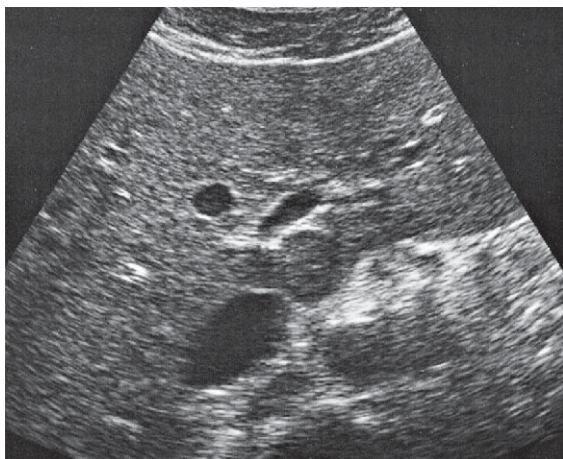
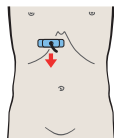
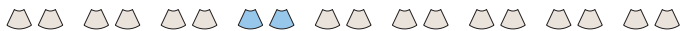

Ligamentum venosum separates the caudate lobe from subsegment II of the lateral hepatic segment.

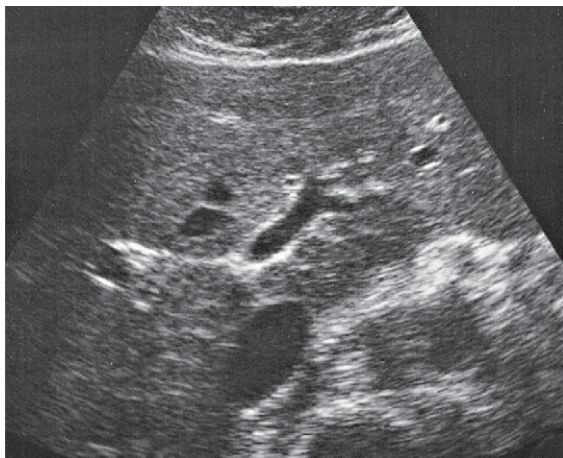
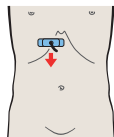


The caudate lobe of the liver is designated as subsegment I.

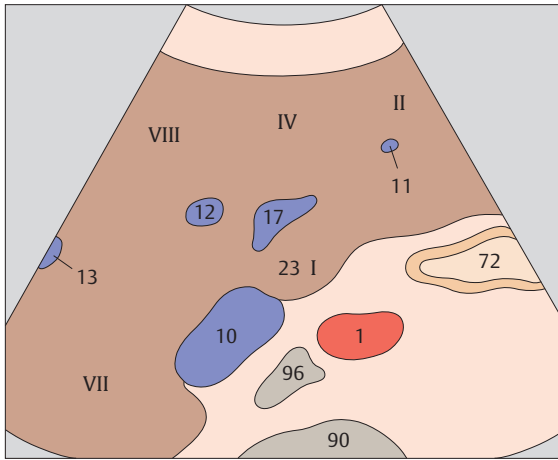




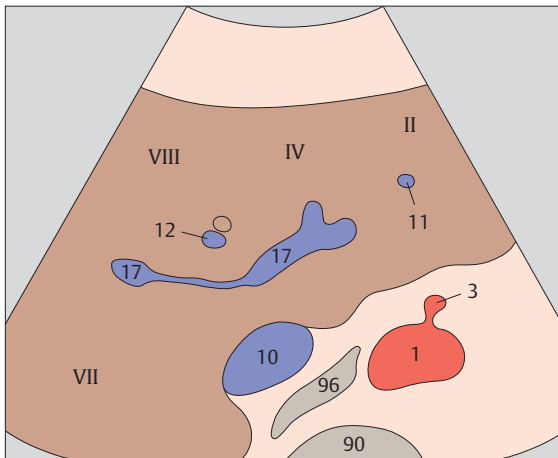
- ▶ 85 Medial and anterior hepatic segments,
left portal vein branch, caudate lobe



- ▶ 86 Medial and anterior hepatic segments,
left portal vein branch, caudate lobe

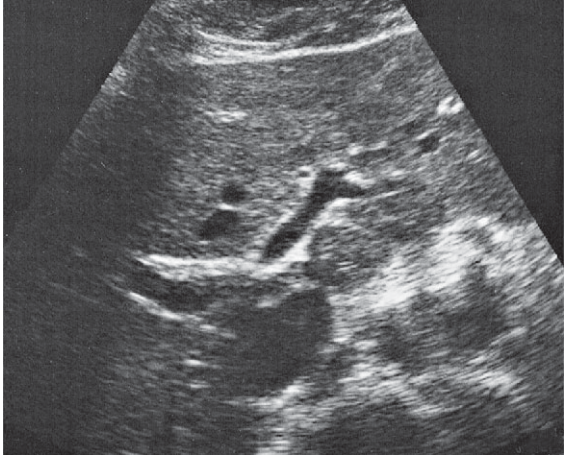
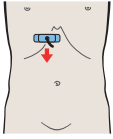


The caudate lobe is interposed between the vena cava and left portal vein branch.

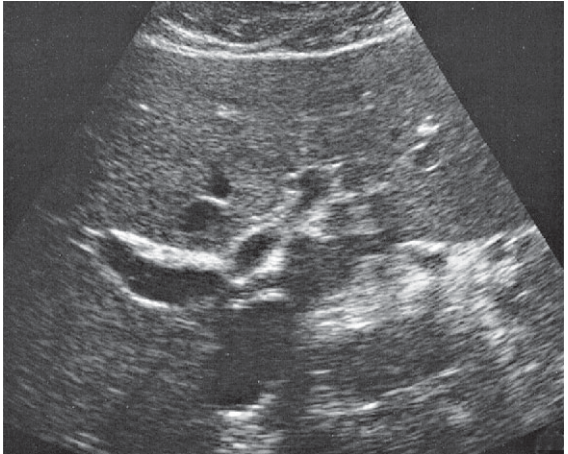
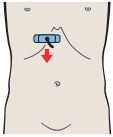


The upper subsegments of the lateral and medial hepatic segments are designated as subsegment II and subsegment IVa, respectively.

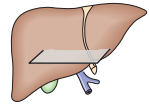
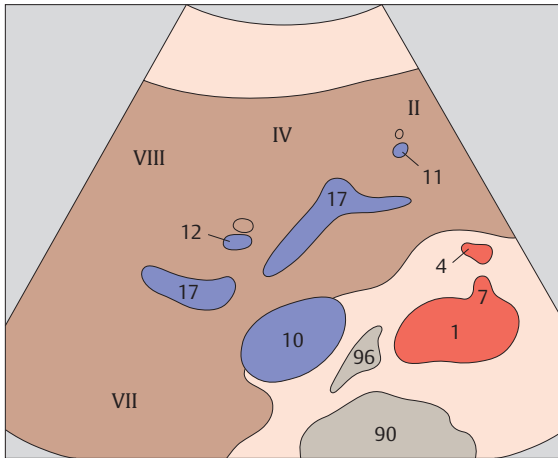




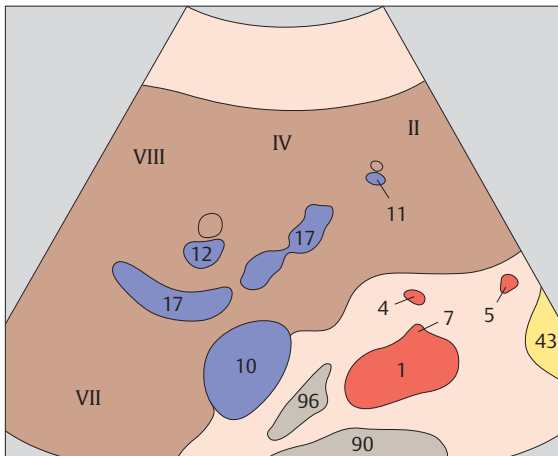
- ▶ **87** Medial and anterior hepatic segments, bifurcation of portal vein



- ▶ **88** Medial and anterior hepatic segments, bifurcation of portal vein

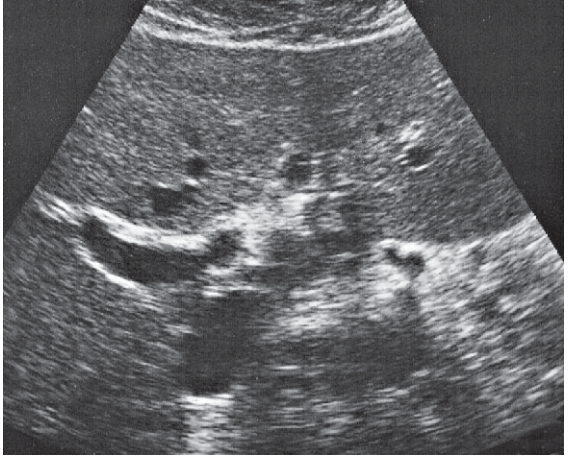
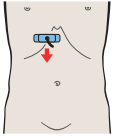
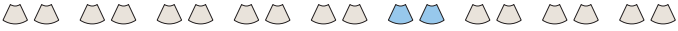

The upper subsegments of the anterior and posterior hepatic segments are designated as subsegments VIII and VII.

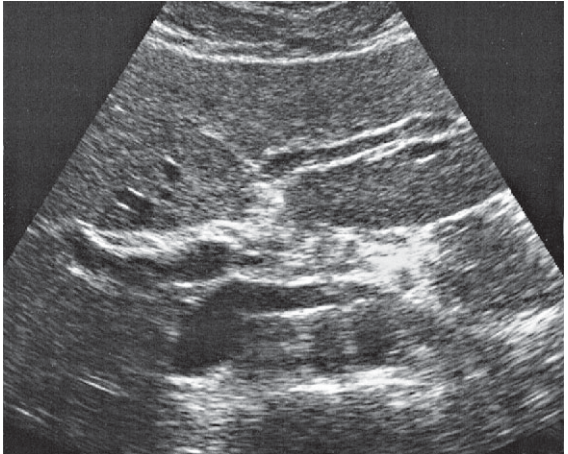
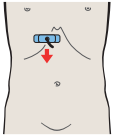


The bifurcation of the portal vein is located just anterior to the vena cava.

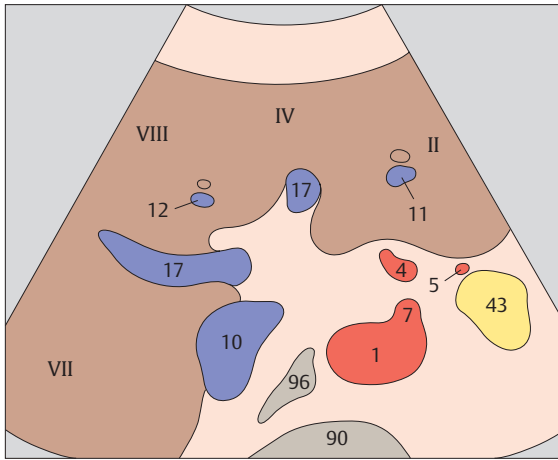




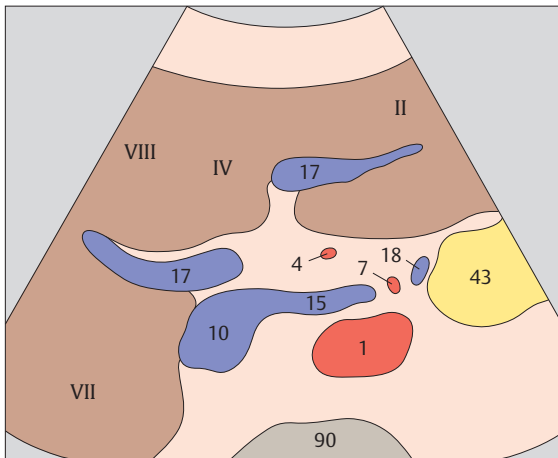
- ▶ 89 Medial and anterior hepatic segments,
right portal vein branch



- ▶ 90 Medial and anterior hepatic segments,
right and left portal vein branches

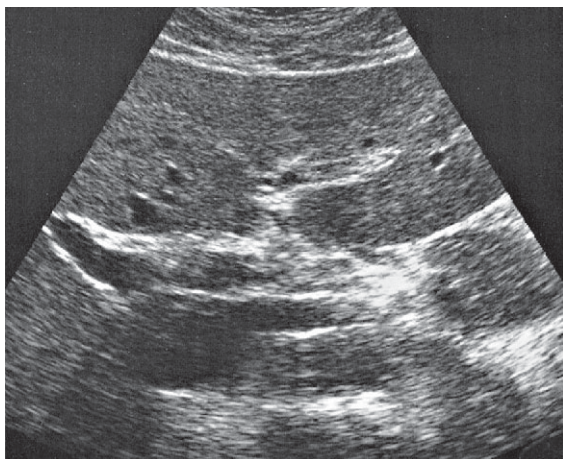
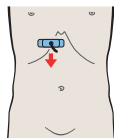
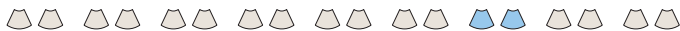

The division of the portal vein into right and left branches marks the approximate boundary between the upper and lower subsegments.

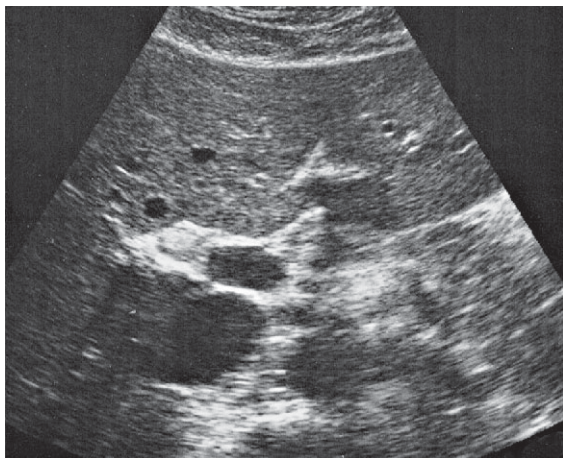
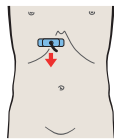


The division of the portal vein into right and left branches shows an antler-like configuration on ultrasound.

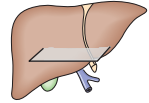
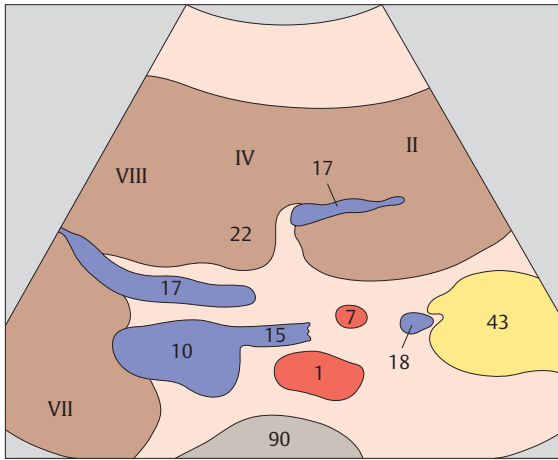




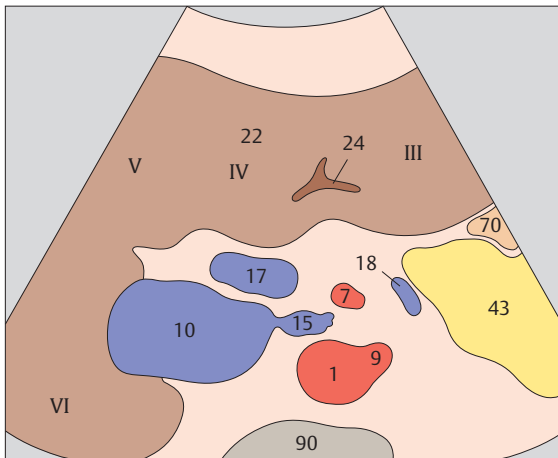
- ▶ 91 Medial and anterior hepatic segments,
right and left portal vein branches



- ▶ 92 Medial and anterior hepatic segments,
quadrate lobe, ligamentum teres, portal vein

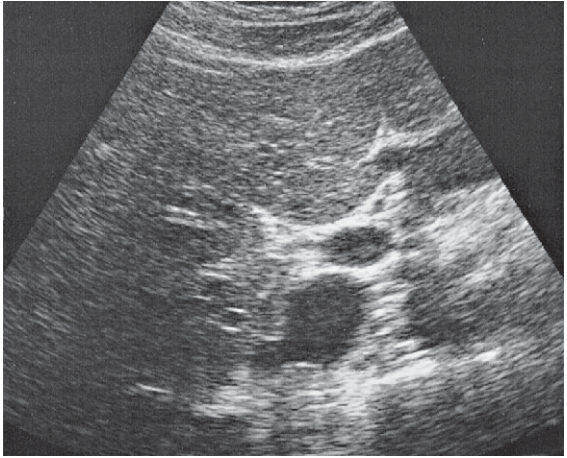
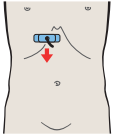
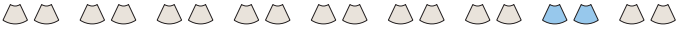

The right portal vein branch initially runs slightly caudally from the bifurcation.

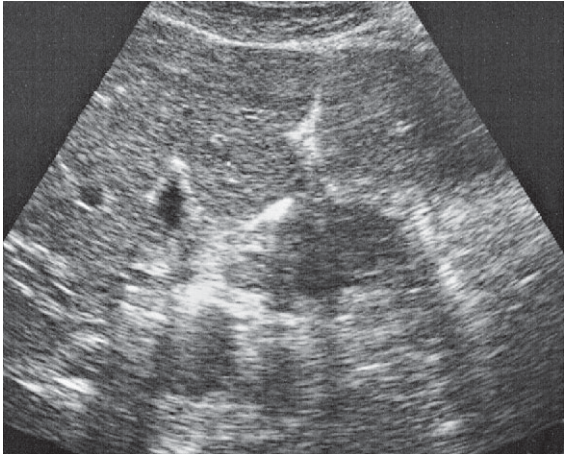
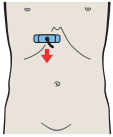


Ligamentum teres marks the boundary plane between the right and left lobes of the liver.

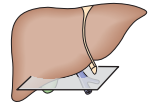
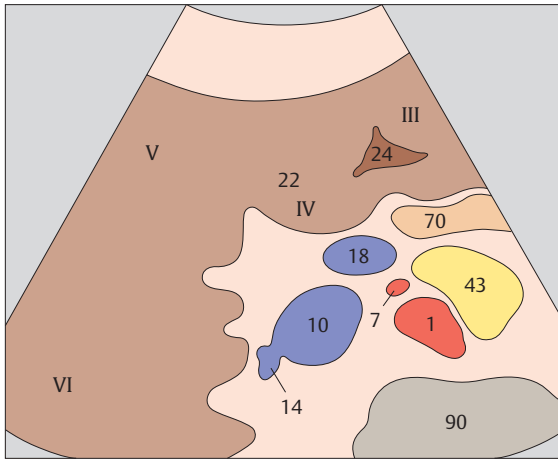




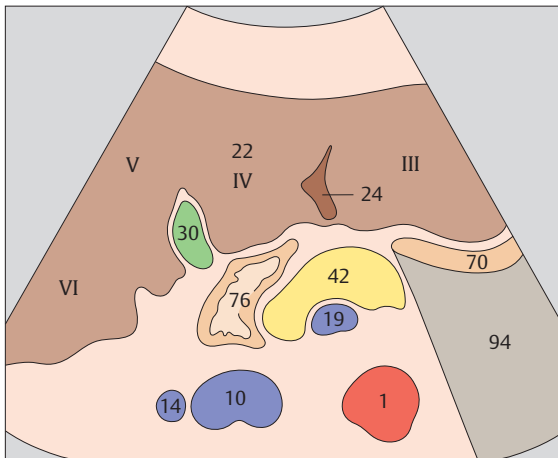
- ▶ 93 Medial and anterior hepatic segments, quadrate lobe, ligamentum teres, portal vein



- ▶ 94 Medial and anterior hepatic segments, quadrate lobe, ligamentum teres, gallbladder

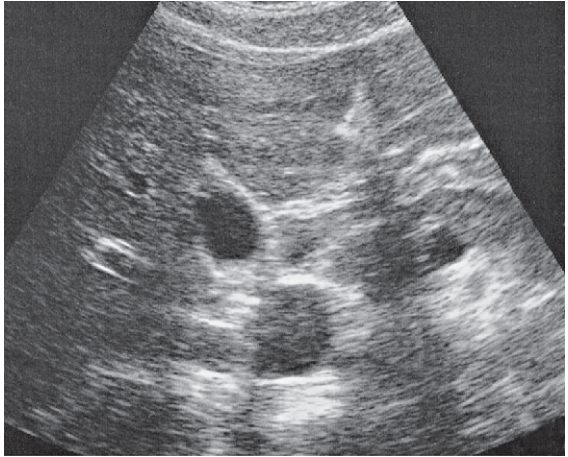
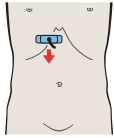
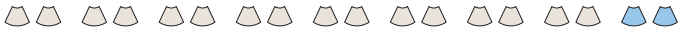

The lower subsegments of the lateral, medial, anterior, and posterior hepatic segments are designated, respectively, subsegments III, IVb, V, and VI.

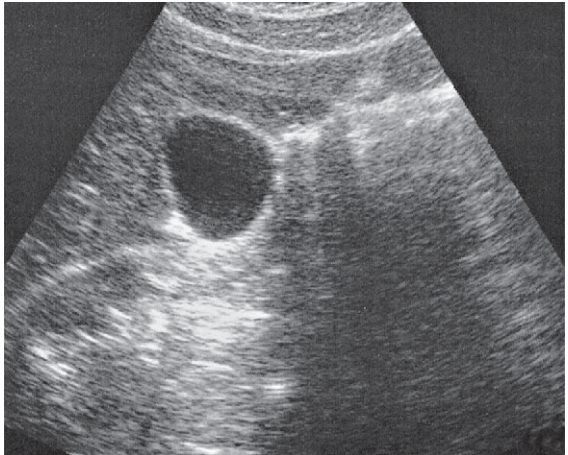
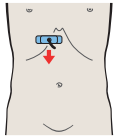


The gallbladder and ligamentum teres form the boundary structures of the quadrate lobe in transverse section.

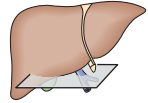
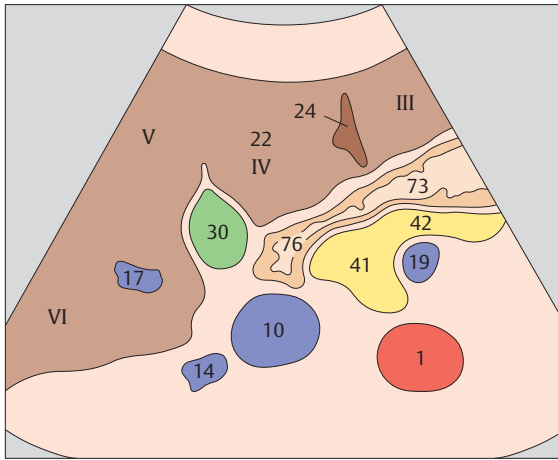




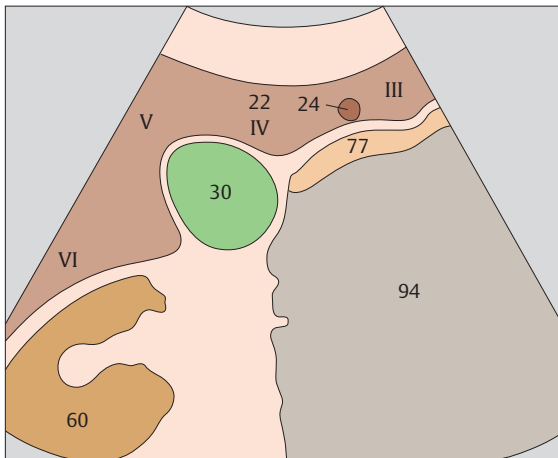
- ▶ 95 Medial and anterior hepatic segments, quadrate lobe, ligamentum teres, gallbladder



- ▶ 96 Inferior border of liver, kidney, gallbladder, ligamentum teres

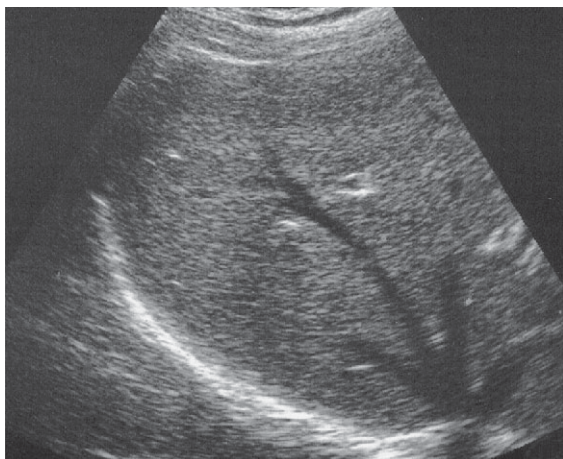
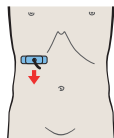


The vena cava–gallbladder plane marks the boundary between the right and left lobes of the liver based on functional criteria.

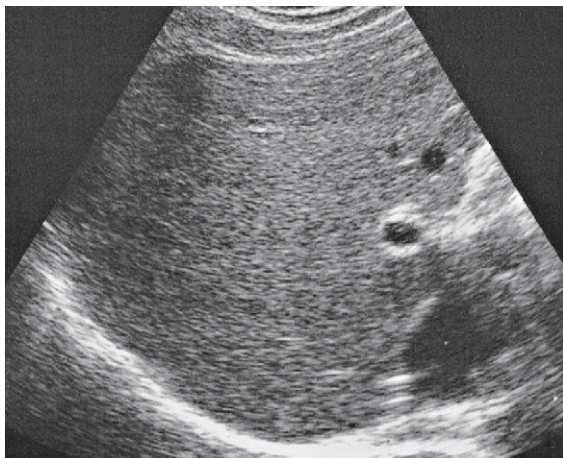
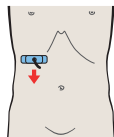


The shape of the inferior hepatic border is influenced by the kidney, the gallbladder, and the groove for ligamentum teres.

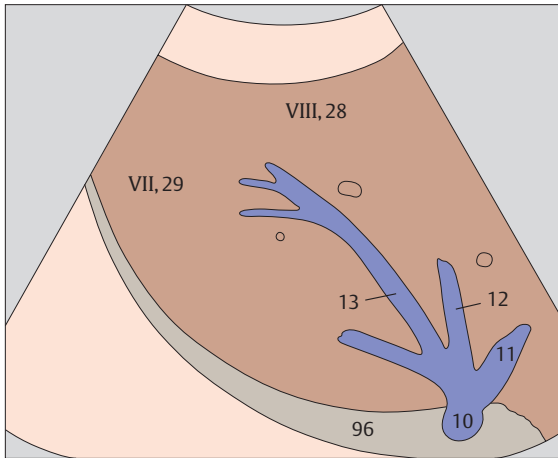




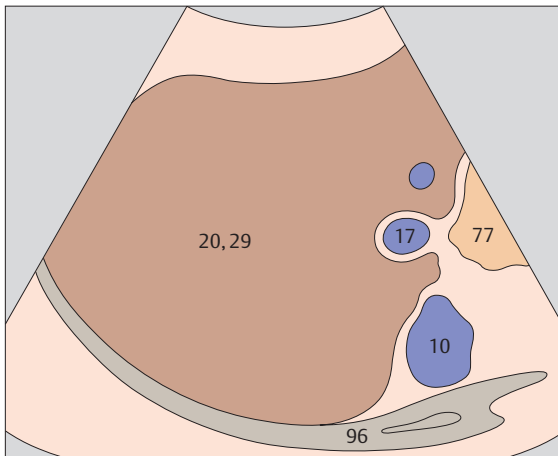
► 97 Posterior segment, upper subsegment



► 98 Posterior segment, portal vein

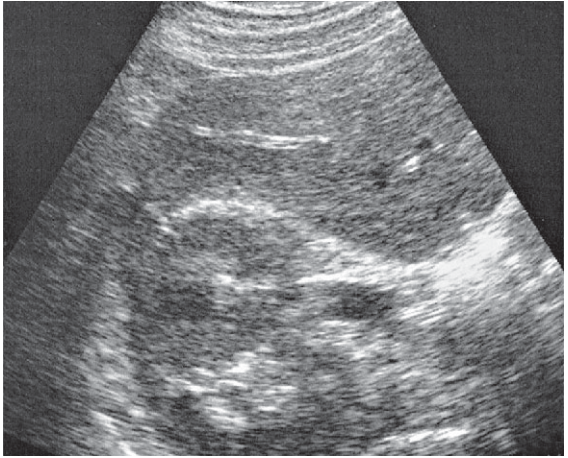
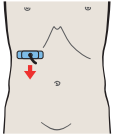


The upper subsegment of the posterior hepatic segment is designated as subsegment VII.

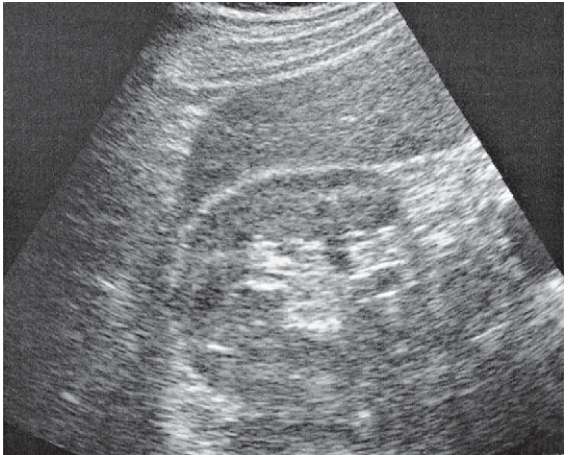
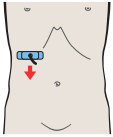


The right portal vein branch marks the approximate boundary between subsegment VII cranially and subsegment V caudally.

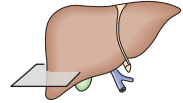
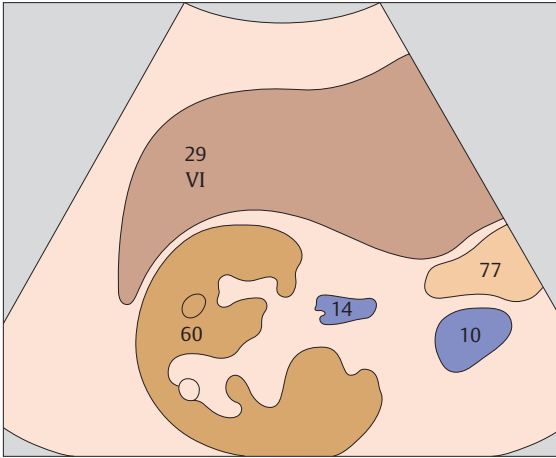




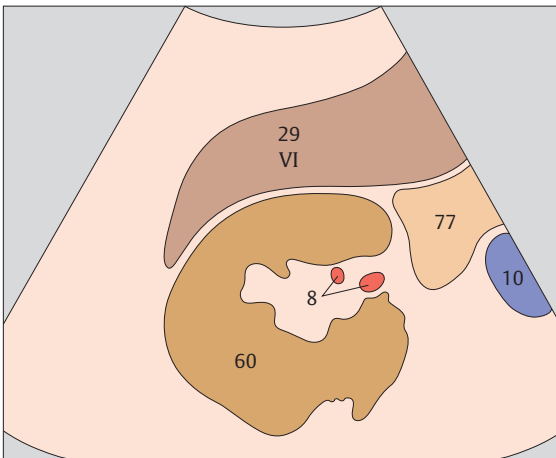
▶ 99 Posterior segment, lower subsegment, kidney



▶ 100 Posterior segment, inferior border



The lower subsegment of the posterior hepatic segment is designated as subsegment VI.



The right lobe of the liver is highly variable in its inferior extent.



3 Gallbladder

Gallbladder in Upper Abdominal Transverse Sections

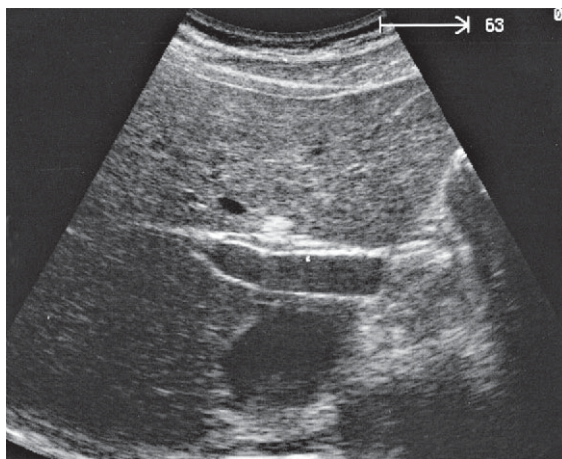
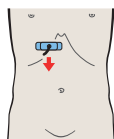
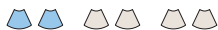- 101** Right portal vein branch, ligamentum venosum
- 102** Gallbladder neck
- 103** Junction of neck and body of gallbladder
- 104** Body of gallbladder
- 105** Gallbladder fundus
- 106** Gallbladder fundus, inferior border

Gallbladder in Longitudinal Sections

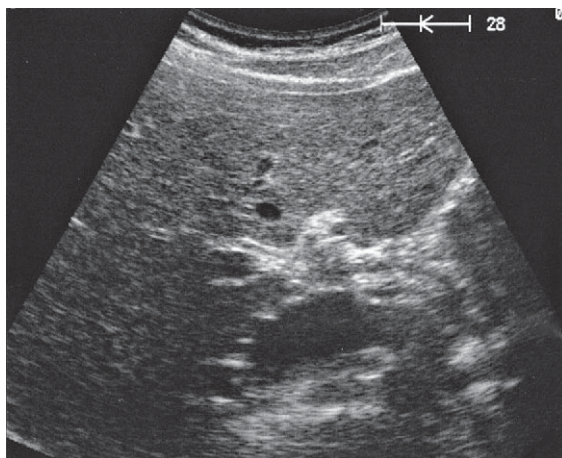
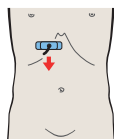
- 107** Vena cava, duodenum, bifurcation of portal vein
- 108** Right portal vein branch, duodenum, gallbladder body
- 109** Right portal vein branch, body and neck of gallbladder
- 110** Body and fundus of gallbladder, kidney
- 111** Gallbladder fundus, kidney
- 112** Gallbladder fundus, kidney

Details of the Gallbladder

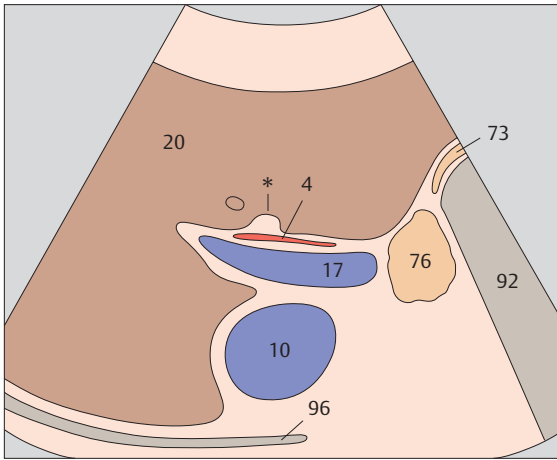
- 113** Regions of the gallbladder, spiral folds
- 114** Layers of the gallbladder wall



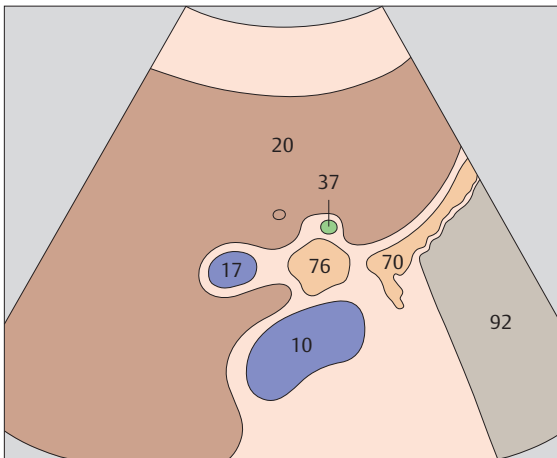
▶ 101 Right portal vein branch, ligamentum venosum



▶ 102 Gallbladder neck

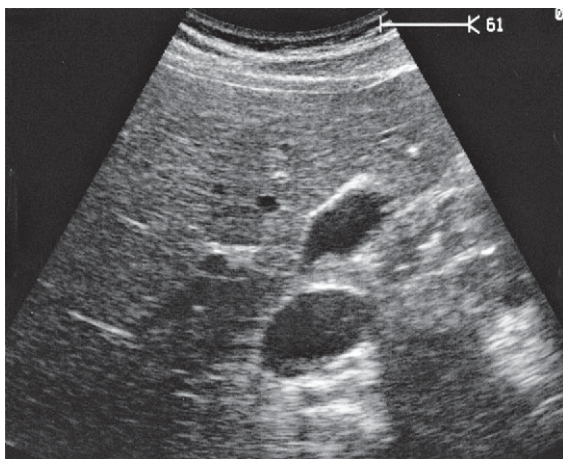
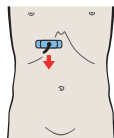
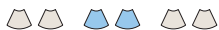

The interlobar fissure (), located anterior to the right portal vein branch, is the landmark for identifying the gallbladder.*

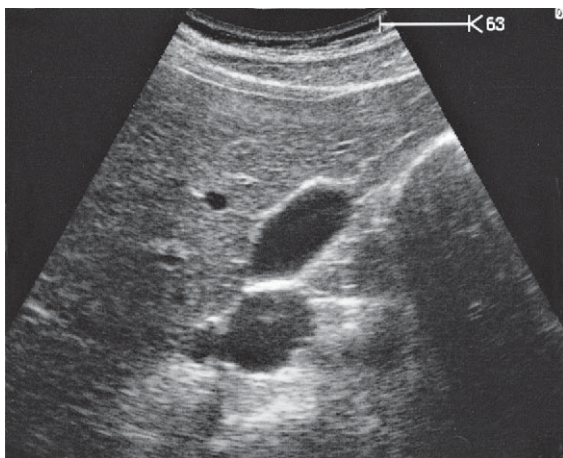
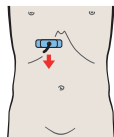


The neck of the gallbladder is located just caudal to the right portal vein branch and the interlobar fissure.

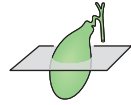
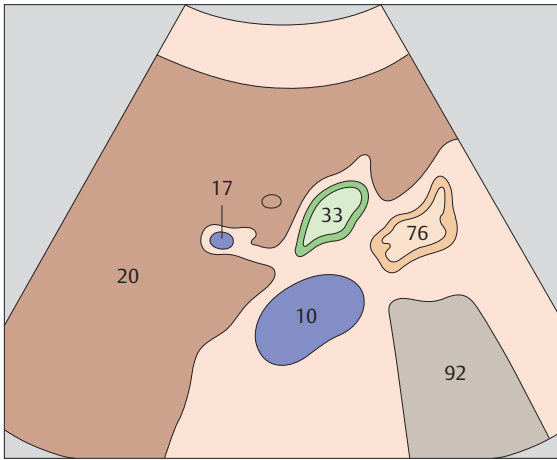




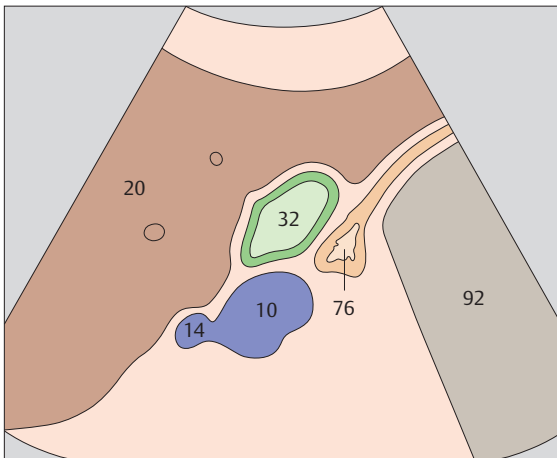
▶ 103 Junction of neck and body of gallbladder



▶ 104 Body of gallbladder

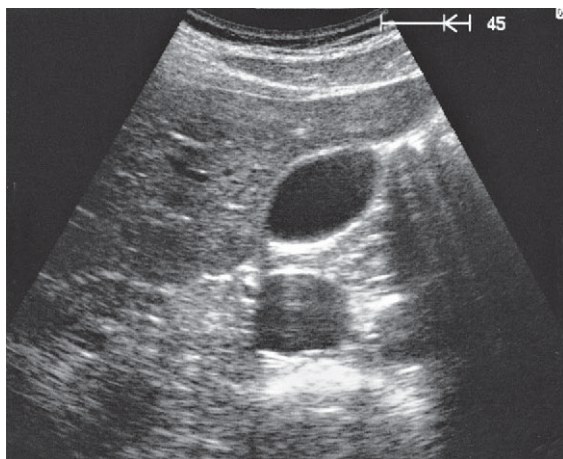
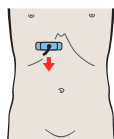
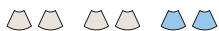

In a transverse scan through the body of the gallbladder, the duodenum is located between the gallbladder and the vena cava.

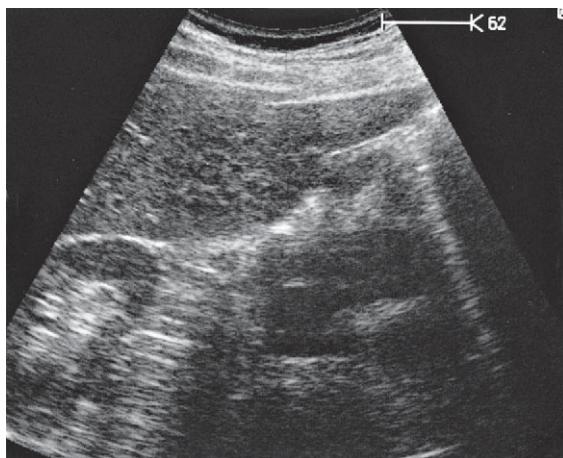
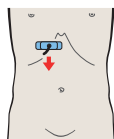


The duodenal bulb can consistently be identified on the free peritoneal side of the body or neck of the gallbladder.

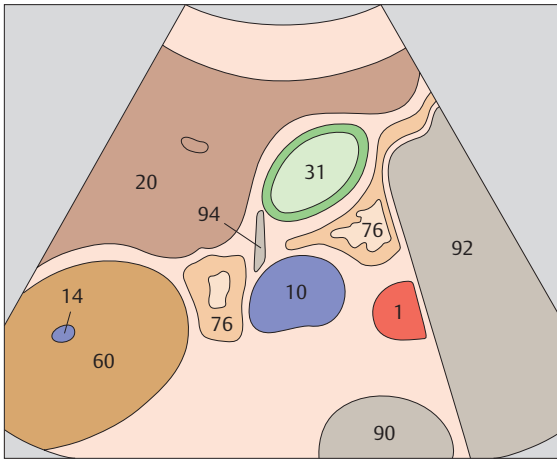




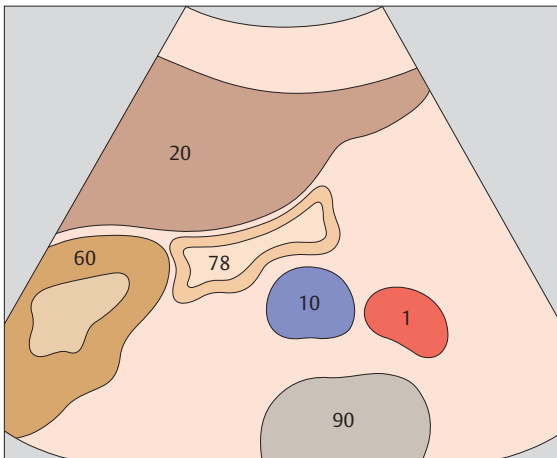
▶ 105 Gallbladder fundus



▶ 106 Gallbladder fundus, inferior border

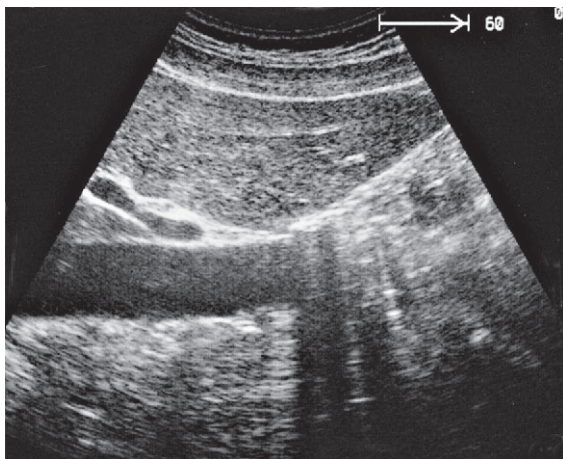
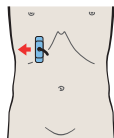
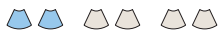

The gallbladder fundus may extend almost to the anterior abdominal wall, but it may also be placed very deeply behind the liver.

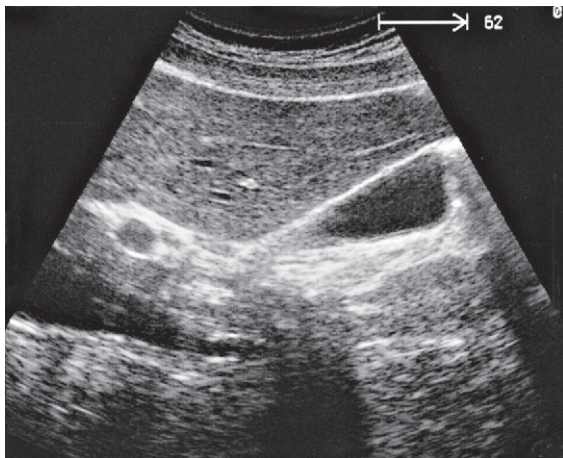
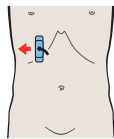


The right colic flexure often impresses on the caudal surface of the gallbladder fundus.

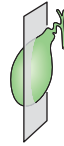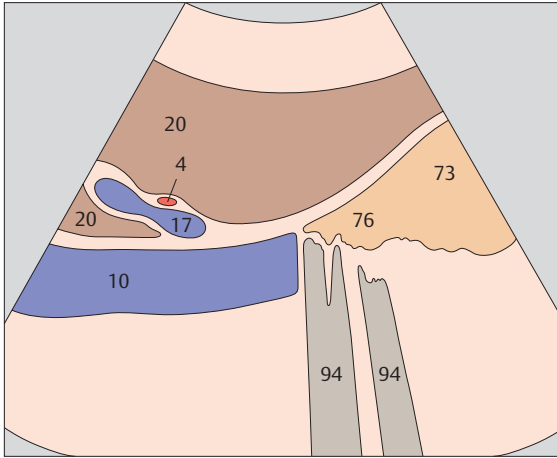




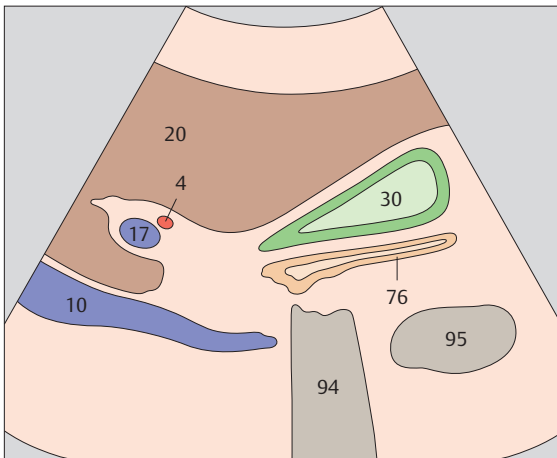
▶ **107** Vena cava, duodenum, bifurcation of portal vein



▶ **108** Right portal vein branch, duodenum, gallbladder body

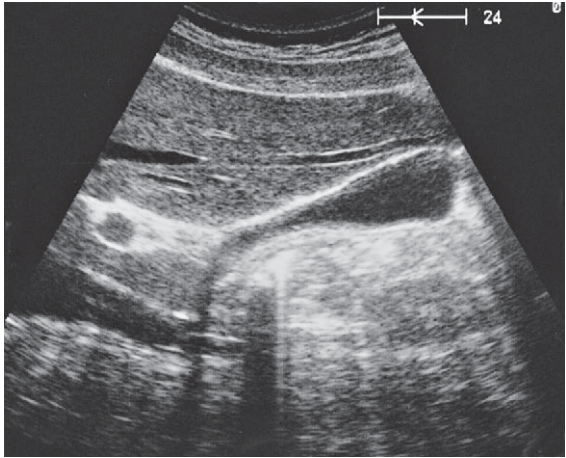
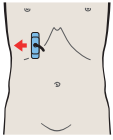


The vena cava, the portal bifurcation, and the echodense band of the interlobar fissure provide conspicuous landmarks for locating the gallbladder in longitudinal section.

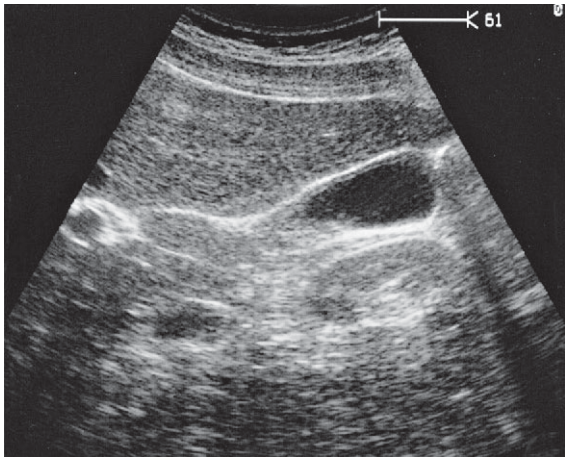
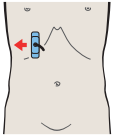


The duodenum is adjacent to the gallbladder posteriorly and to the right colic flexure caudally.

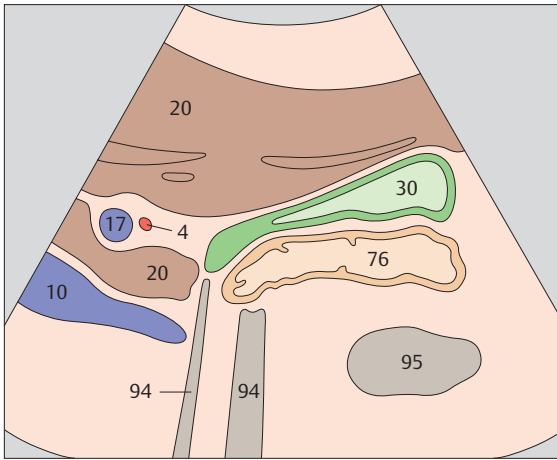




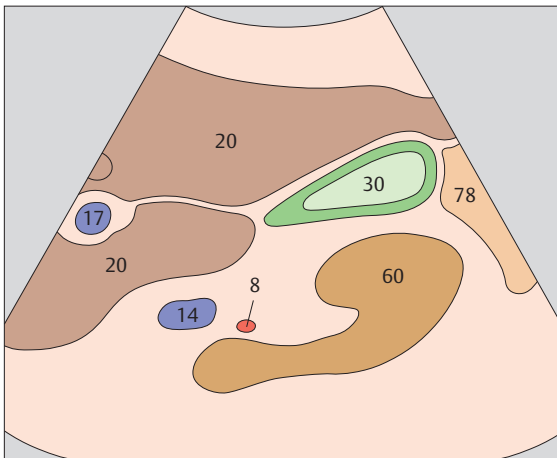
▶ 109 Right portal vein branch, body and neck of gallbladder



▶ 110 Body and fundus of gallbladder, kidney

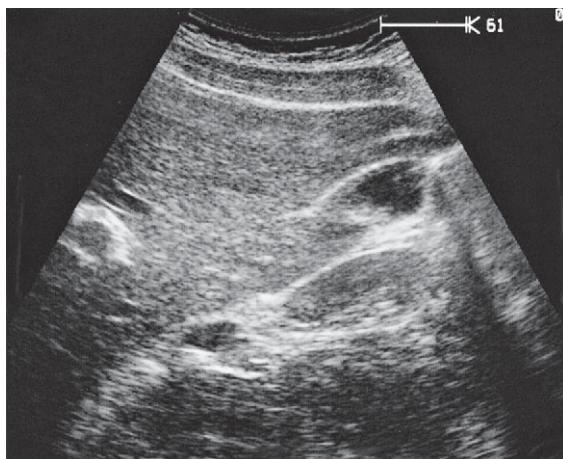
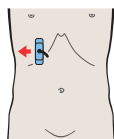


The shape and position of the gallbladder are highly variable. However, the neck of the gallbladder is always located in the porta hepatis, caudal to the right portal vein branch.

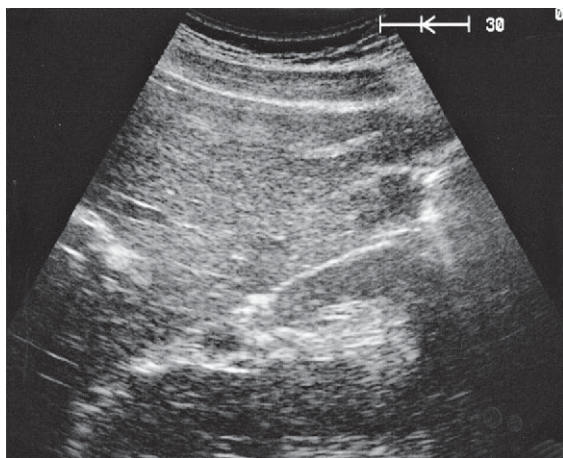
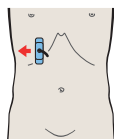


The healthy gallbladder is typically a pear-shaped, fluid-filled organ that contains no internal echoes.

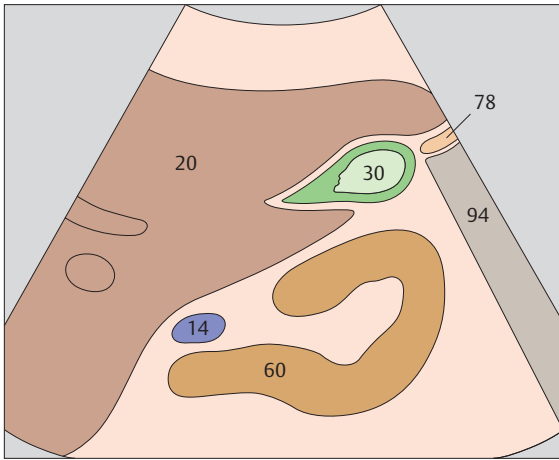




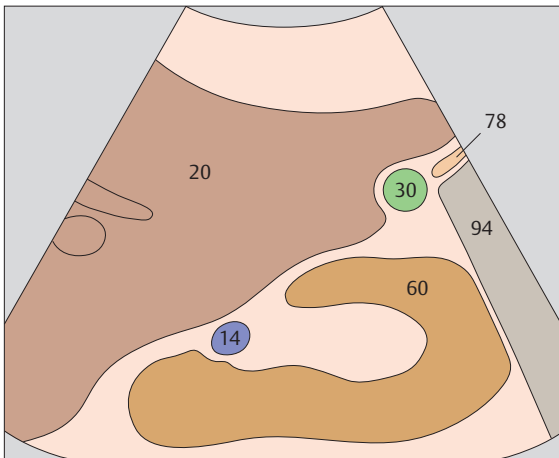
▶ 111 Gallbladder fundus, kidney



▶ 112 Gallbladder fundus, kidney

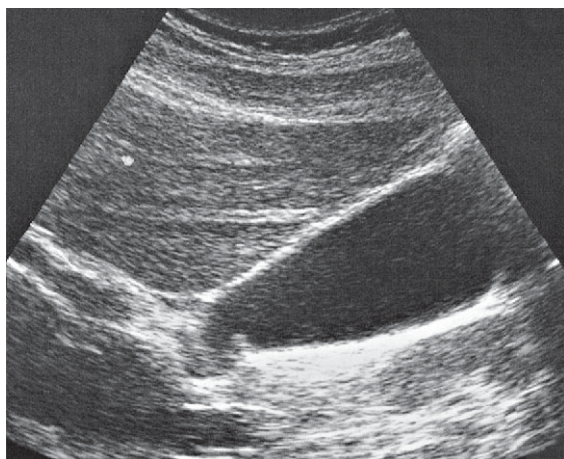
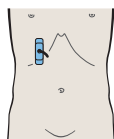


A wedge of liver tissue, variable in size, is interposed between the gallbladder and kidney in longitudinal section.

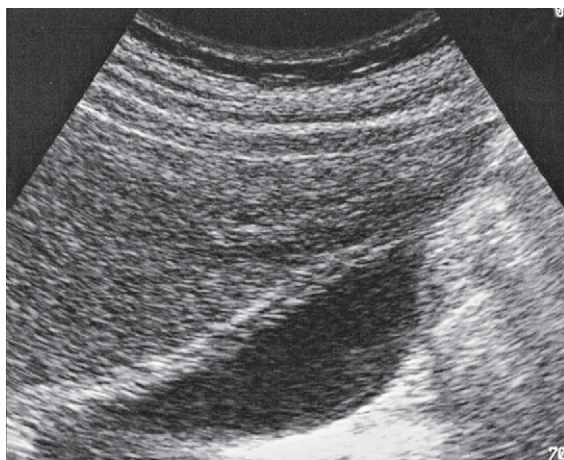
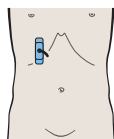


In a more lateral scan, the gallbladder may be in direct contact with the kidney.

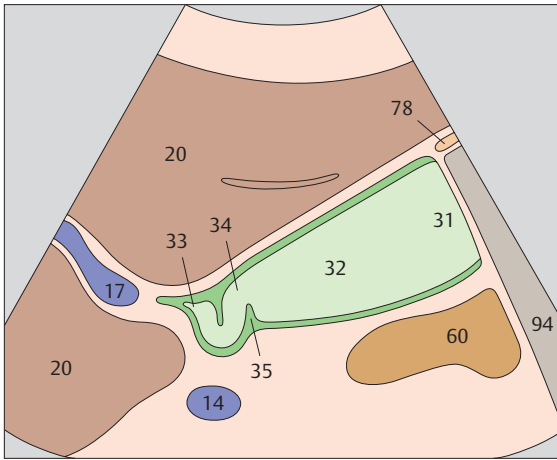




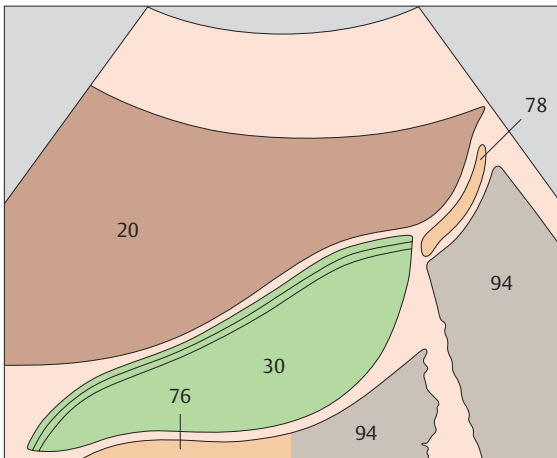
▶ 113 Regions of gallbladder, spiral folds



▶ 114 Layers of gallbladder wall



The spiral folds and gallbladder neck are often clearly visualized in a lateral scan over the gallbladder.



The anterior wall of the gallbladder consists of three identifiable layers. Usually the posterior wall of the gallbladder is poorly demarcated from the duodenum.



4 Pancreas

Pancreas in Longitudinal Sections

- 115 Duodenum lateral to head of pancreas
- 116 Head of pancreas, bile duct
- 117 Head of pancreas, bile duct
- 118 Head of pancreas, hilar vessels, vena cava
- 119 Head of pancreas, superior mesenteric vein, uncinete process
- 120 Head of pancreas, superior mesenteric vein, uncinete process
- 121 Body of pancreas, splenic vein
- 122 Body of pancreas, splenic vein, superior mesenteric artery, aorta
- 123 Body of pancreas, splenic vein
- 124 Tail of pancreas, splenic artery and vein, renal artery and vein
- 125 Tail of pancreas, splenic artery and vein, renal artery and vein
- 126 Tail of pancreas

Head of the Pancreas in Transverse Sections

- 127 Section cranial to head of pancreas, vena cava, splenic vein
- 128 Head of pancreas, vena cava, superior mesenteric vein
- 129 Head of pancreas, vena cava, superior mesenteric vein, uncinete process, common bile duct
- 130 Head of pancreas, vena cava, superior mesenteric vein, uncinete process, gallbladder

Body of the Pancreas in Transverse Sections

- 131 Scan cranial to body of pancreas, celiac trunk
- 132 Body of pancreas, splenic vein
- 133 Body of pancreas, splenic vein, superior mesenteric artery, aorta
- 134 Left renal artery and vein, superior mesenteric artery and vein, aorta

Tail of the Pancreas in Transverse Sections

- 135 Tail of pancreas, splenic artery
- 136 Tail of pancreas, splenic vein
- 137 Tail of pancreas, gas in stomach
- 138 Tail of pancreas

Transsplenic View of the Tail of the Pancreas in Longitudinal Sections

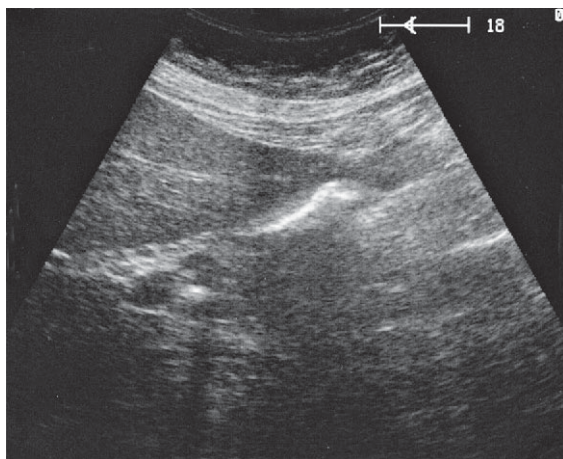
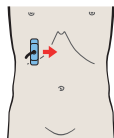
- 139 Scan posterior to tail of pancreas, spleen, kidney
- 140 Spleen, tail of pancreas, kidney
- 141 Spleen, tail of pancreas, kidney
- 142 Scan anterior to tail of pancreas, spleen, stomach

Transsplenic View of the Tail of the Pancreas in Transverse Sections

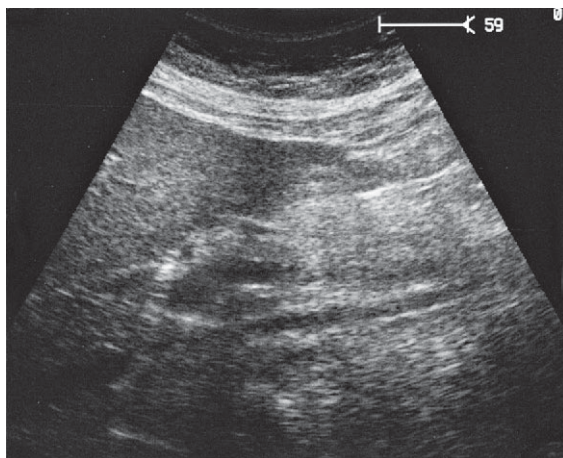
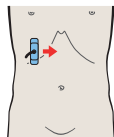
- 143 Spleen, tail of pancreas, kidney
- 144 Spleen, tail of pancreas, kidney

Details of the Pancreas

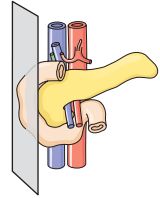
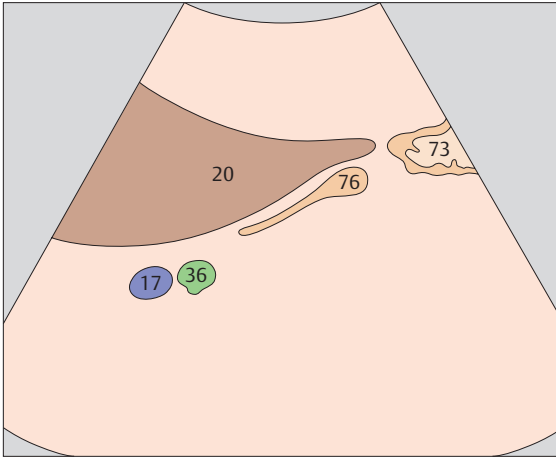
- 145 Transverse scan of pancreatic duct
- 146 Longitudinal scan of pancreatic duct



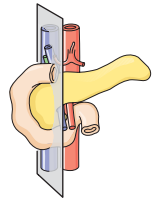
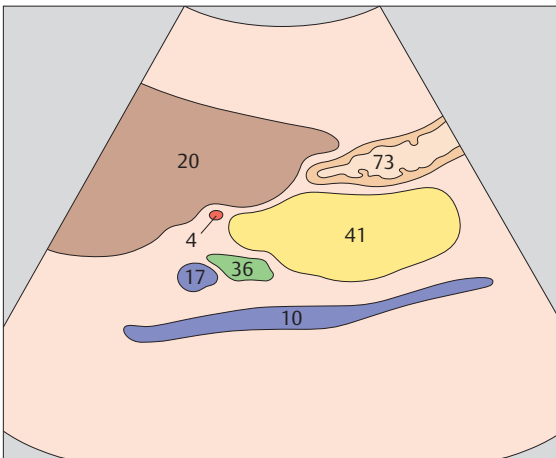
▶ 115 Duodenum lateral to head of pancreas



▶ 116 Head of pancreas, bile duct

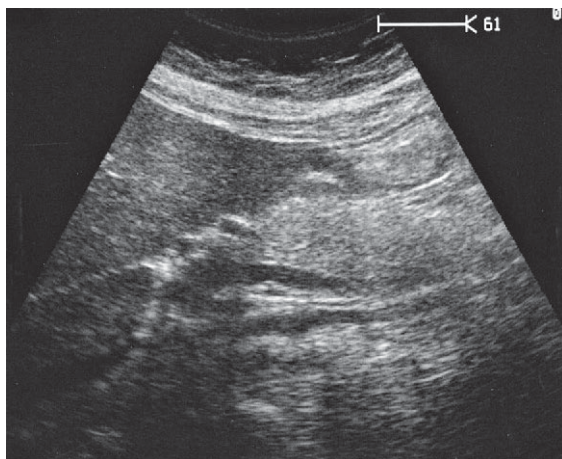
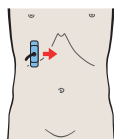


The head of the pancreas lies in the duodenal loop of the duodenum and is bounded laterally by the duodenum.

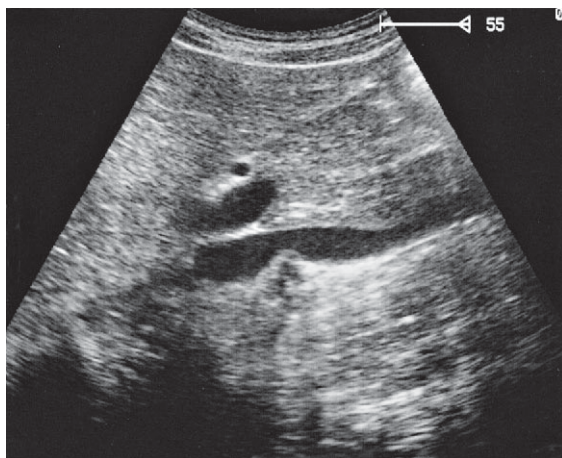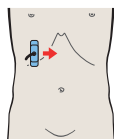


The bile duct, hepatic artery, and portal vein are located cranial to the head of the pancreas.

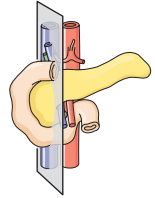
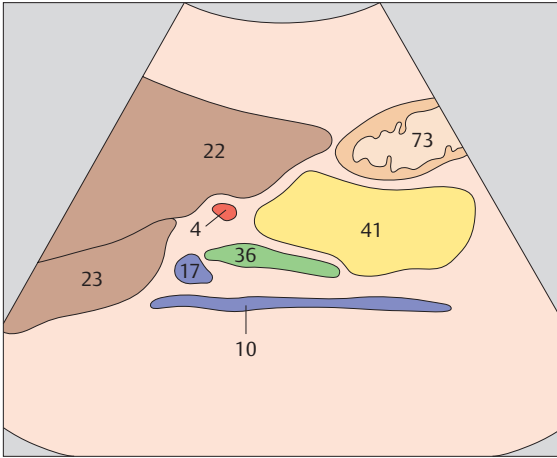




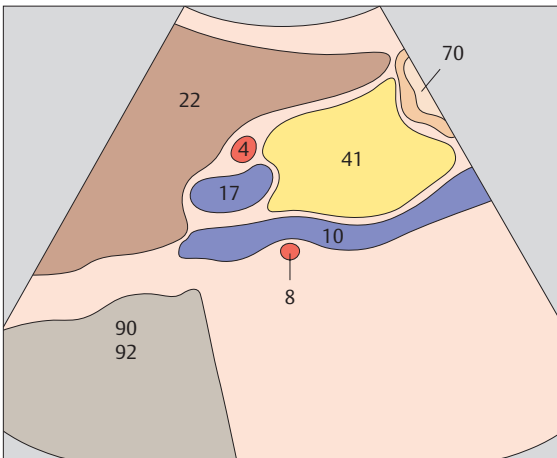
▶ 117 Head of pancreas, bile duct



▶ 118 Head of pancreas, hilar vessels, vena cava

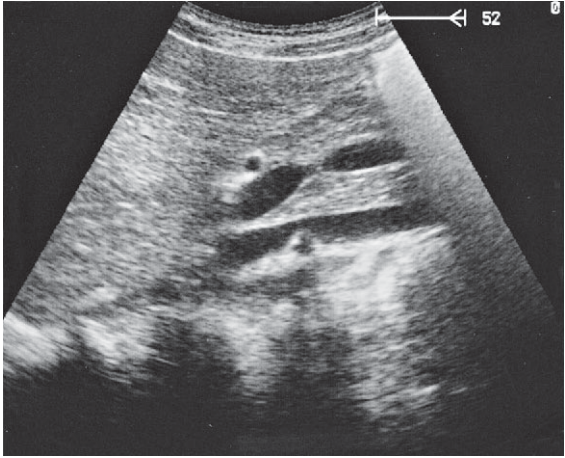
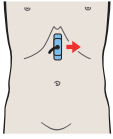
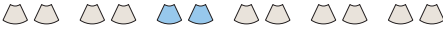

The bile duct runs posteriorly in the head of the pancreas to the papilla, which usually cannot be visualized with ultrasound.

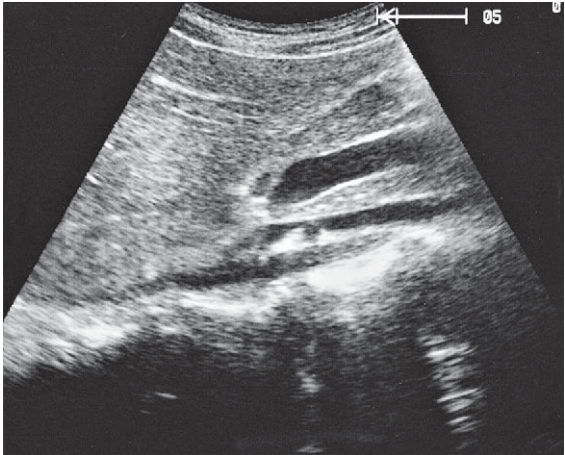
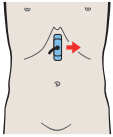


The head of the pancreas lies against the anterior surface of the vena cava and is bordered cranially by the main trunk of the portal vein.

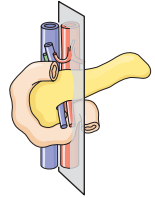
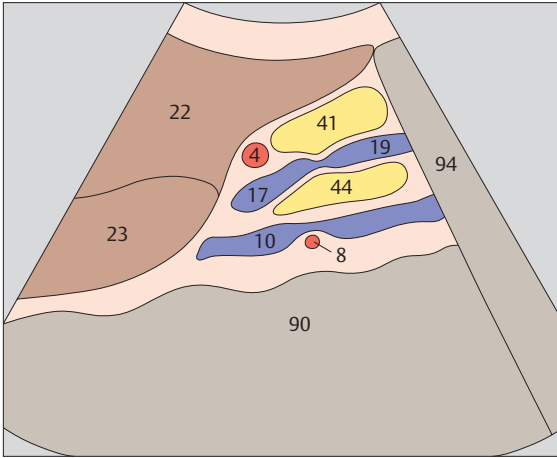




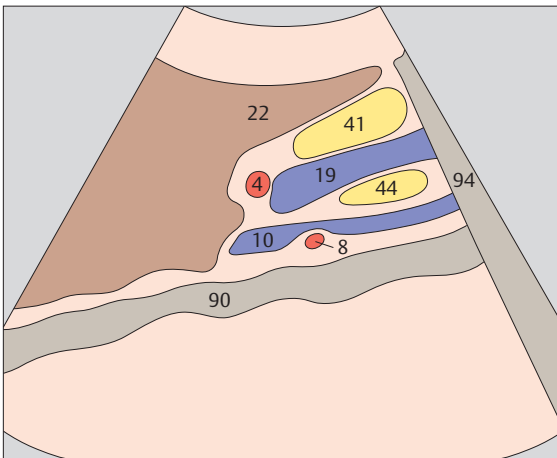
- ▶ **119** Head of pancreas, superior mesenteric vein, uncinate process



- ▶ **120** Head of pancreas, superior mesenteric vein, uncinate process

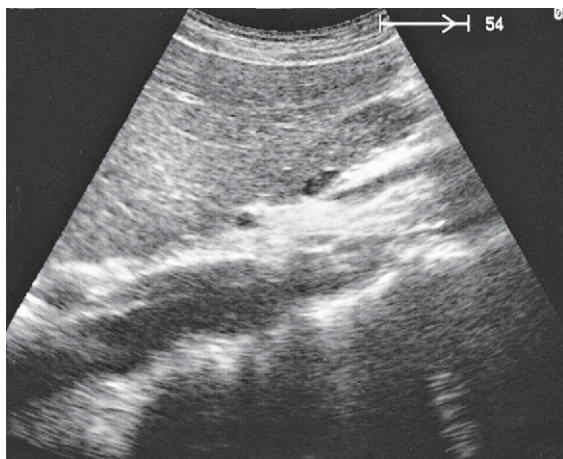
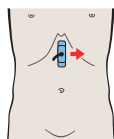


The uncinate process runs posteriorly around the mesenteric vein, coming between that vessel and the vena cava.

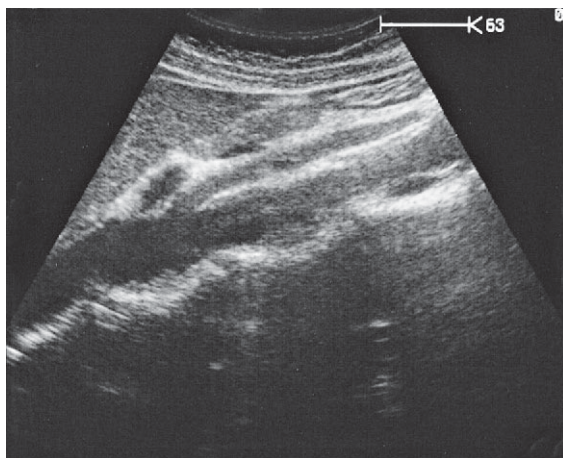
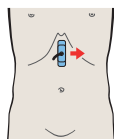


The superior mesenteric vein marks the boundary between the head and body of the pancreas.

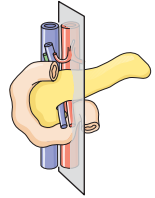
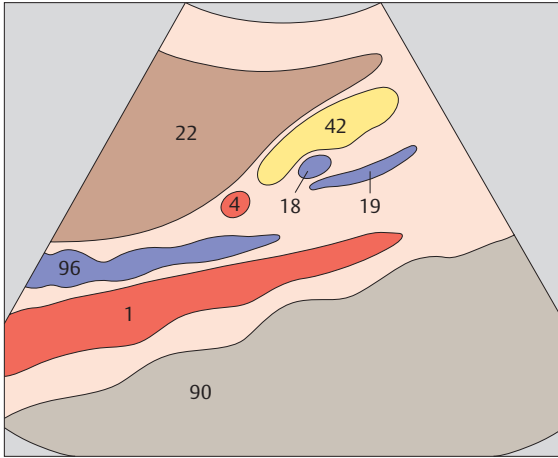




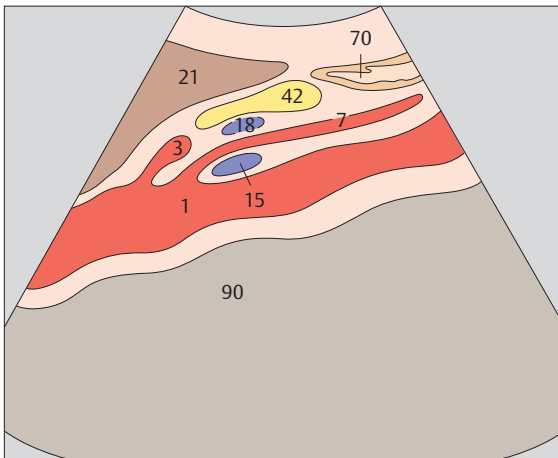
▶ 121 Body of pancreas, splenic vein



▶ 122 Body of pancreas, splenic vein,
superior mesenteric artery, aorta

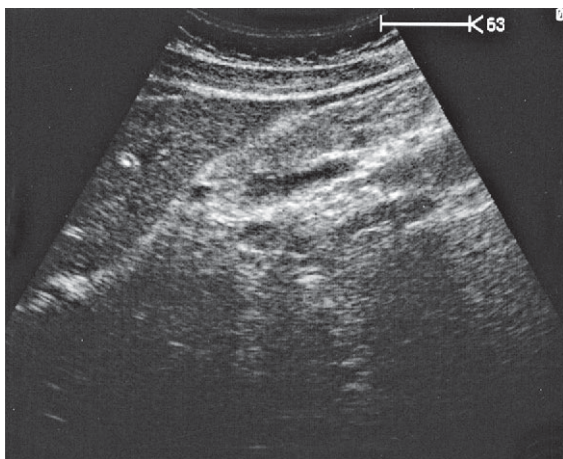
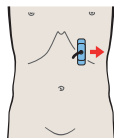
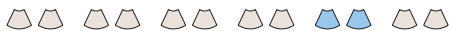

The body of the pancreas is the narrowest part of the organ in its ventrodorsal dimension.

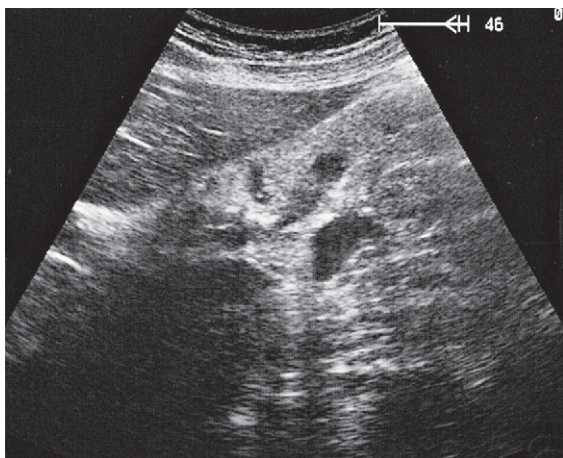
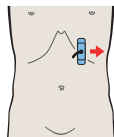


The celiac trunk is cranially adjacent to the body of the pancreas. The splenic vein and body of the pancreas cross over the superior mesenteric artery.

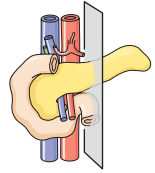
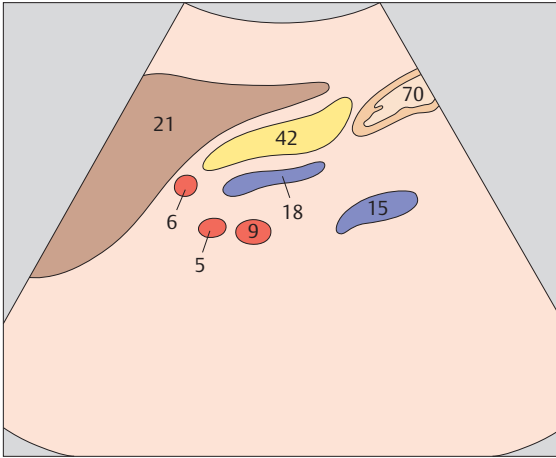




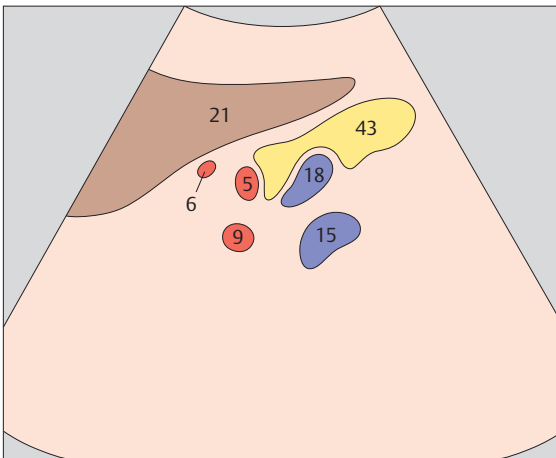
▶ 123 Body of pancreas, splenic vein



▶ 124 Tail of pancreas, splenic artery and vein,
renal artery and vein

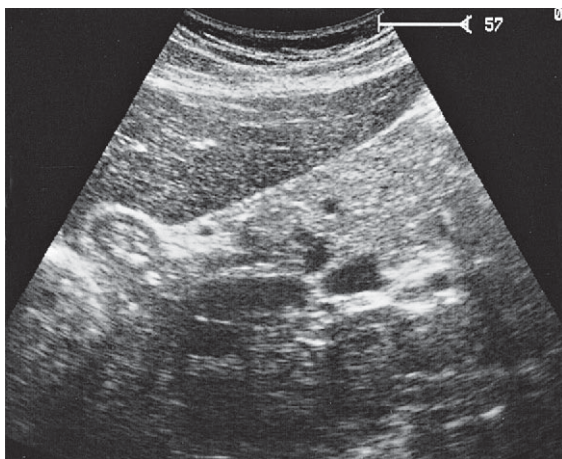
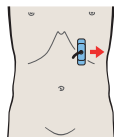
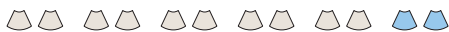

The left margin of the aorta marks the junction between the body and tail of the pancreas.

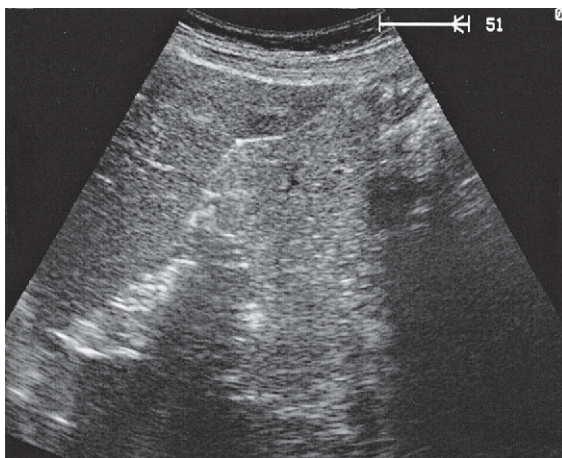
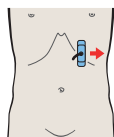


A longitudinal scan at the junction of the body and tail of the pancreas displays four vessels in cross section: the splenic artery, splenic vein, renal artery, and renal vein.

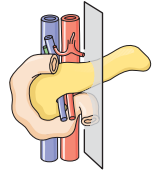
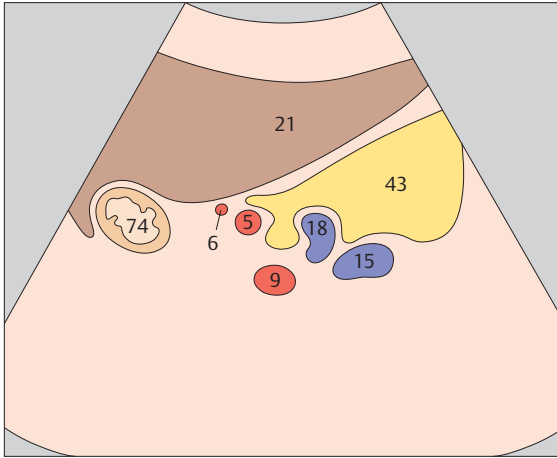




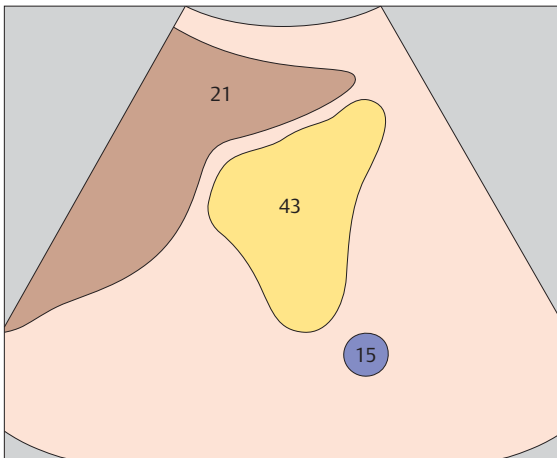
- ▶ 125 Tail of pancreas, splenic artery and vein, renal artery and vein



- ▶ 126 Tail of pancreas

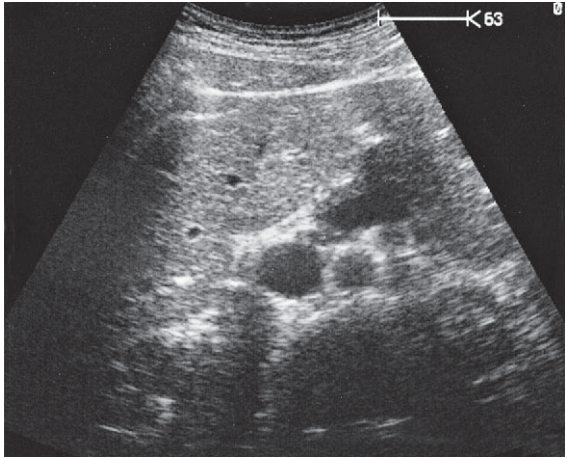
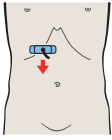


The tail of the pancreas often has a plump appearance in cross section.

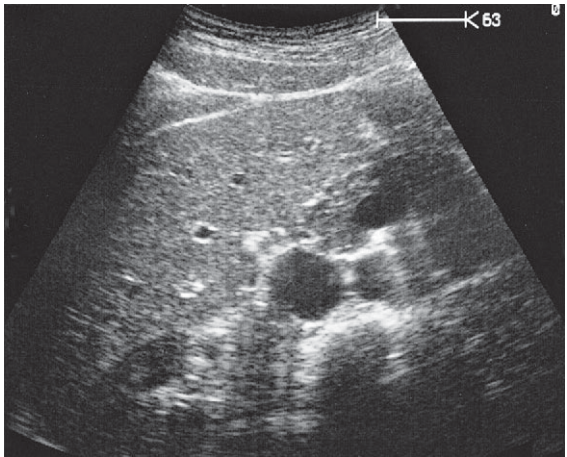
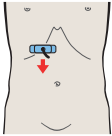


The tail of the pancreas can be completely visualized in an anterior scan only if acoustic conditions are good.

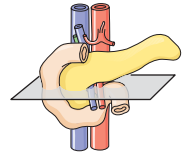
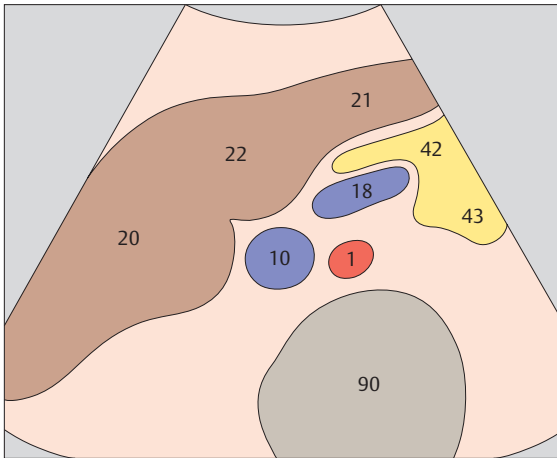




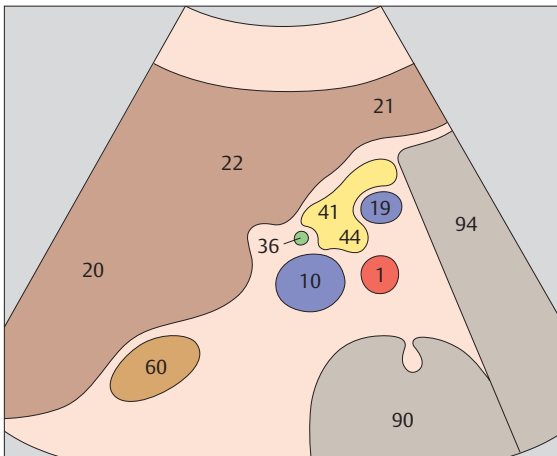
- ▶ **127** Section cranial to head of pancreas, vena cava, splenic vein



- ▶ **128** Head of pancreas, vena cava, superior mesenteric vein

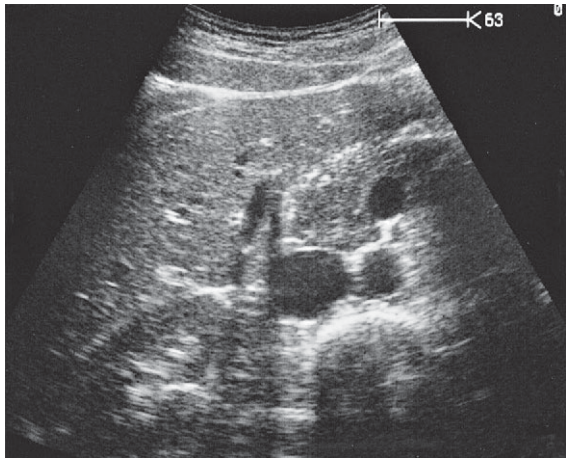
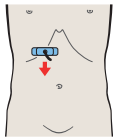
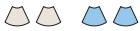

*The body of the pancreas overlies the superior mesenteric vein.
All parts of the gland that lie to the right of the superior
mesenteric vein are designated as the head of the pancreas.*

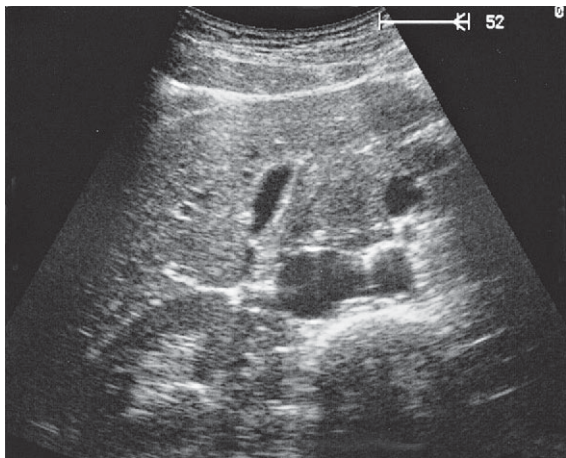
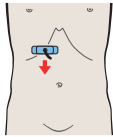


*The uncinate process extends between
the vena cava and superior mesenteric vein.*

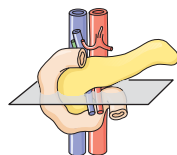
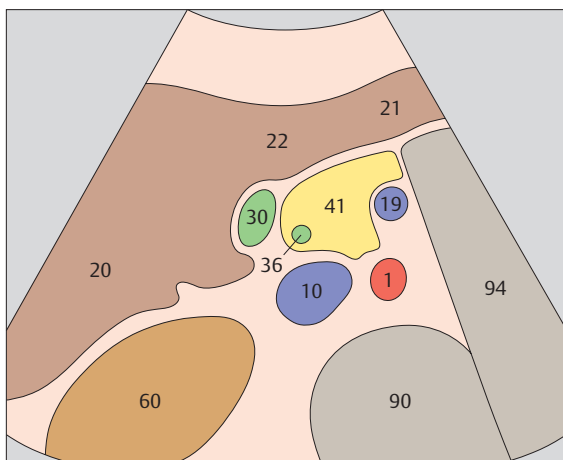




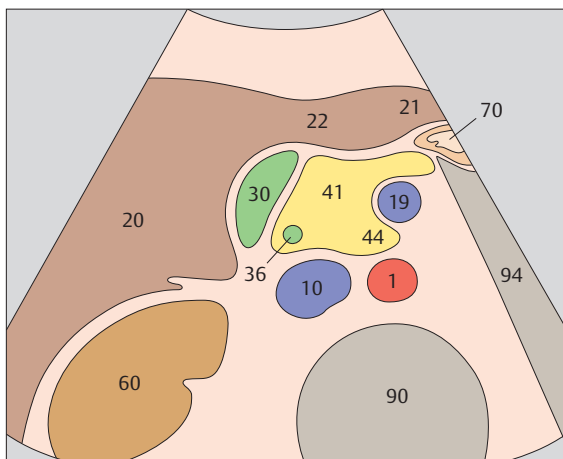
- ▶ **129** Head of pancreas, vena cava, superior mesenteric vein, uncinate process, common bile duct



- ▶ **130** Head of pancreas, vena cava, superior mesenteric vein, uncinate process, gallbladder

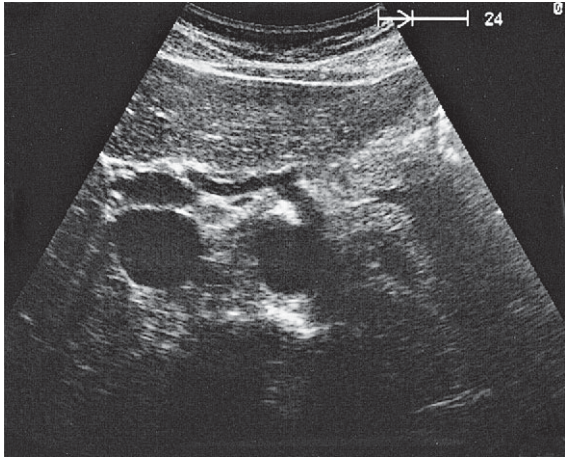
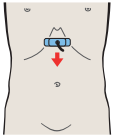


The common bile duct is visible at the right border of the pancreatic head in transverse section.

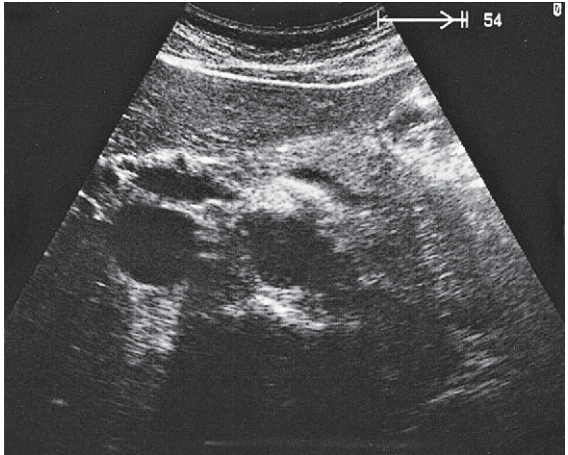
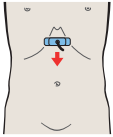


The head of the pancreas lies between the liver, gallbladder, vena cava, and superior mesenteric vein.

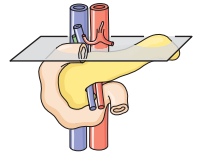
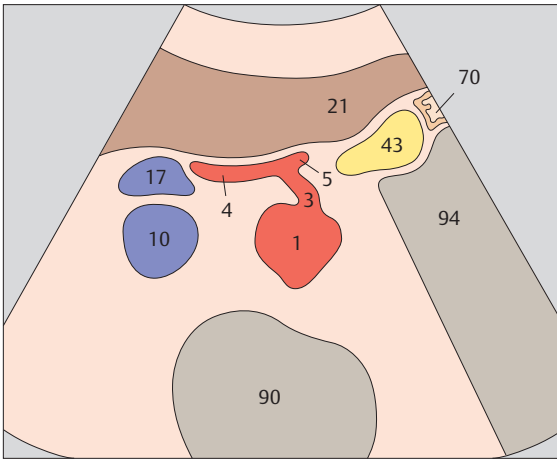




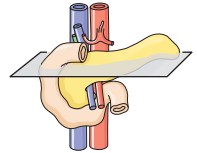
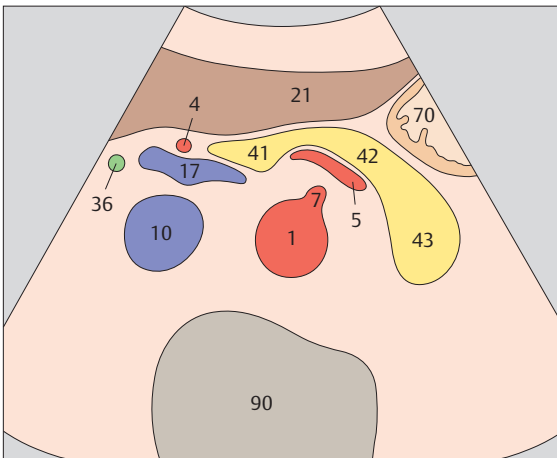
▶ 131 Scan cranial to body of pancreas, celiac trunk



▶ 132 Body of pancreas, splenic vein

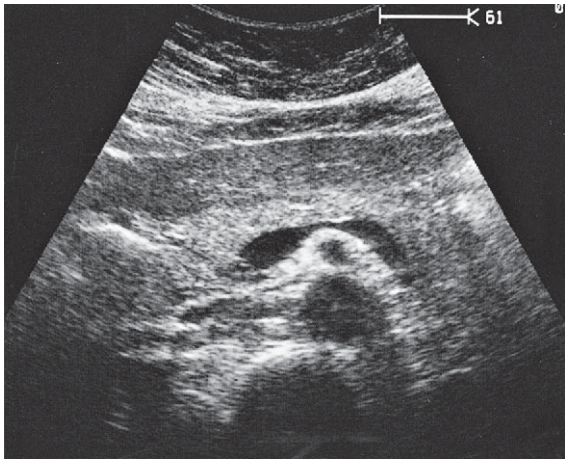
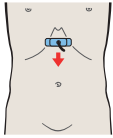


The body of the pancreas is bounded cranially by the celiac trunk and its two branches, the hepatic artery and splenic artery.

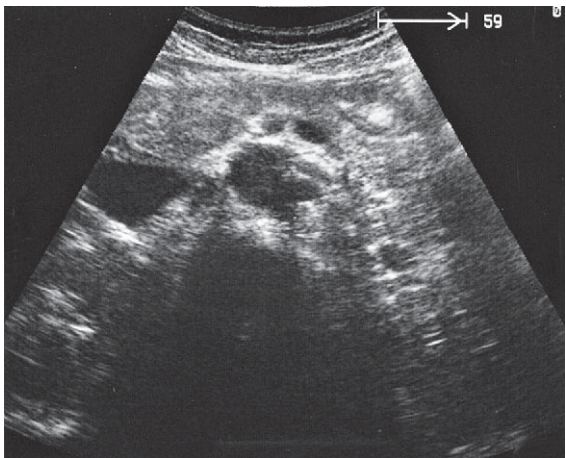
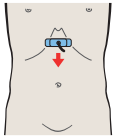


The borders of the healthy pancreas form a continuous outline from head to body to tail.

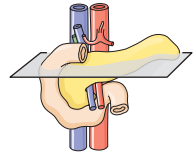
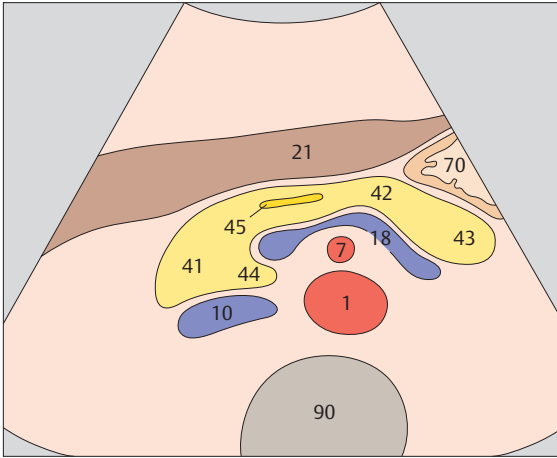




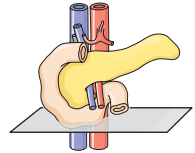
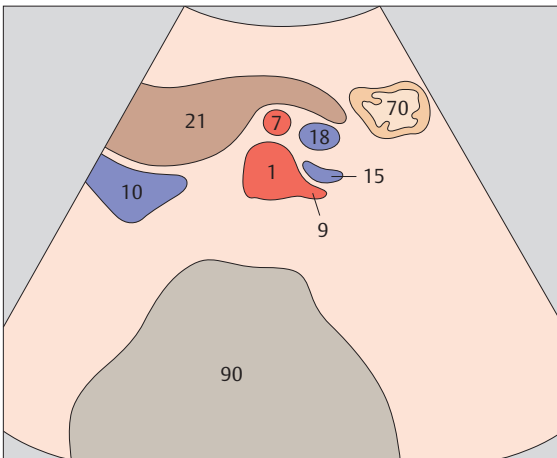
- ▶ **133** Body of pancreas, splenic vein, superior mesenteric artery, aorta



- ▶ **134** Left renal artery and vein, superior mesenteric artery and vein, aorta

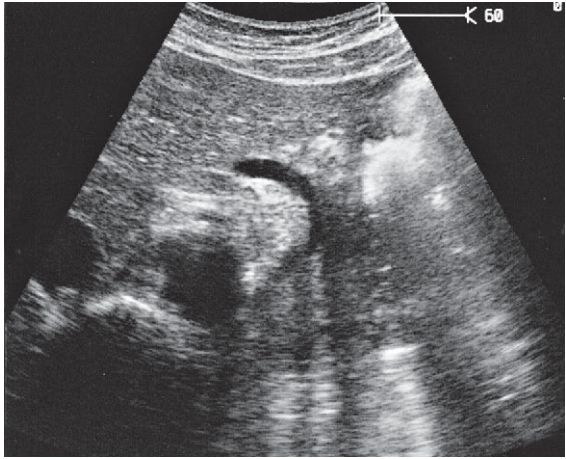
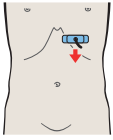


The splenic vein is the landmark for locating the pancreas. The superior mesenteric artery lies between the splenic vein and the aorta, appearing as an echo-free spot surrounded by bright echoes.

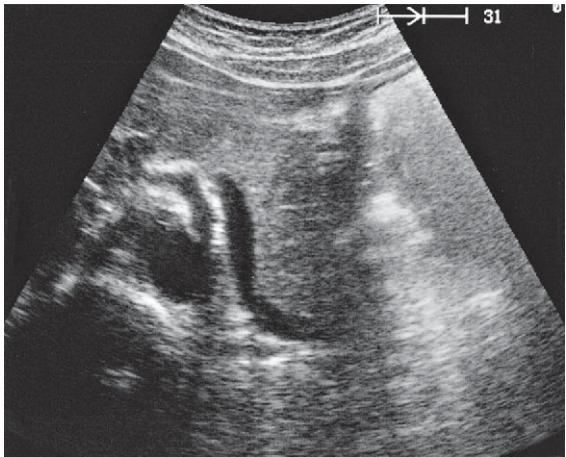
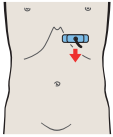


When the renal vessels are displayed in a transverse scan, usually the pancreas is no longer visualized.

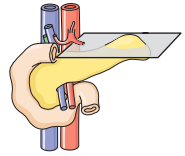
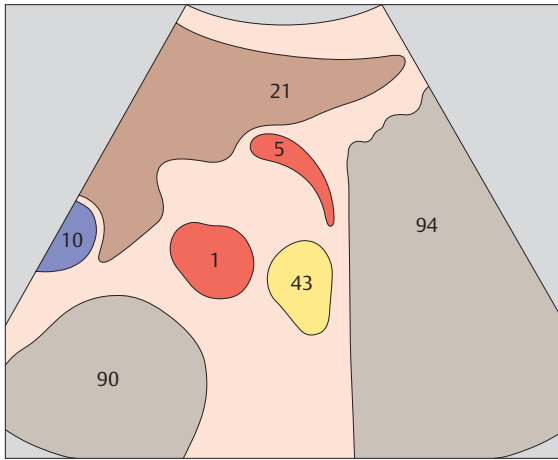




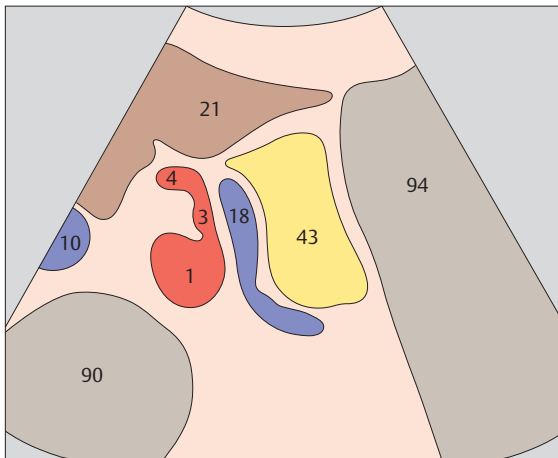
▶ 135 Tail of pancreas, splenic artery



▶ 136 Tail of pancreas, splenic vein

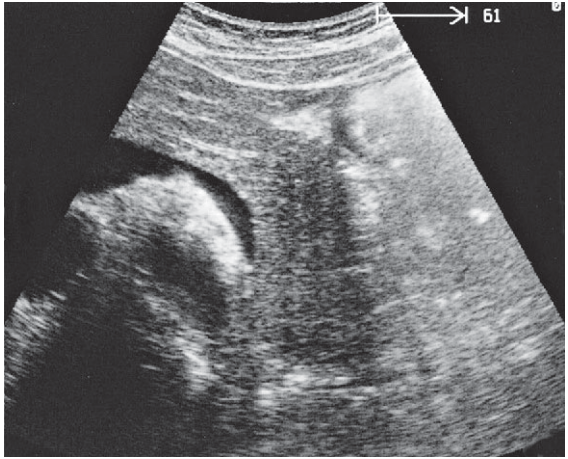
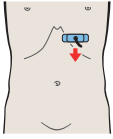


The tail of the pancreas is located well posteriorly, on the left side of the aorta.

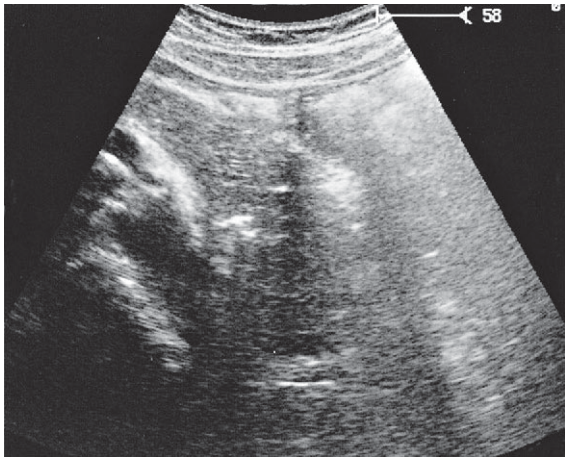
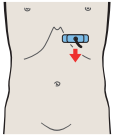


The tail of the pancreas is angled sharply posterior from the body and extends a variable distance between the stomach and the upper renal pole toward the splenic hilum.

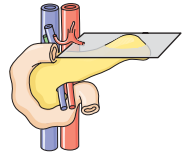
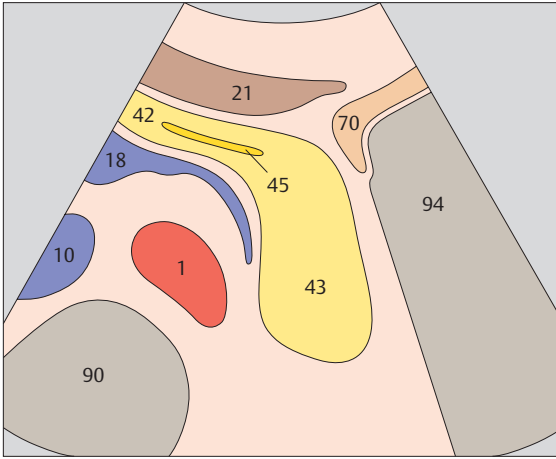




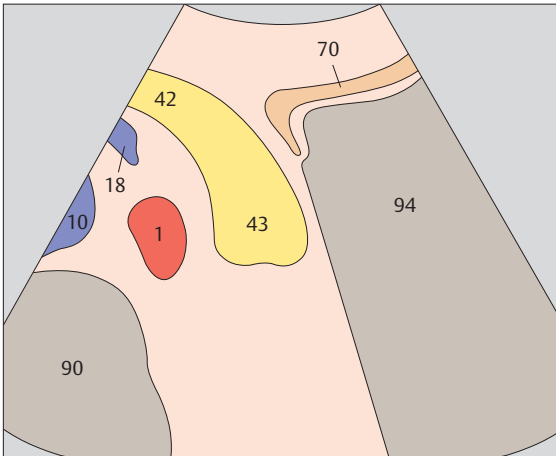
▶ 137 Tail of pancreas, gas in stomach



▶ 138 Tail of pancreas

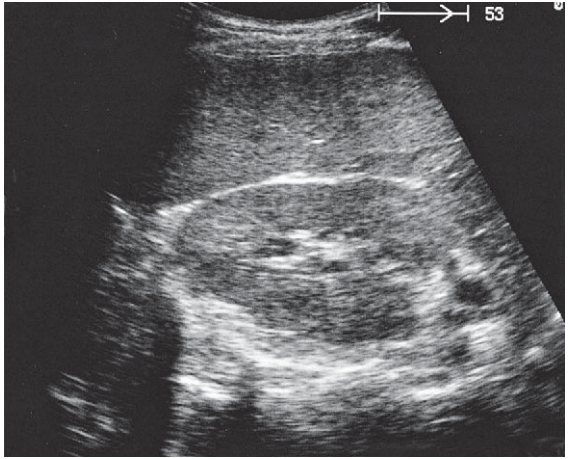
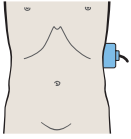


The junction between the body and tail of the pancreas is located at the level of the left aortic margin.

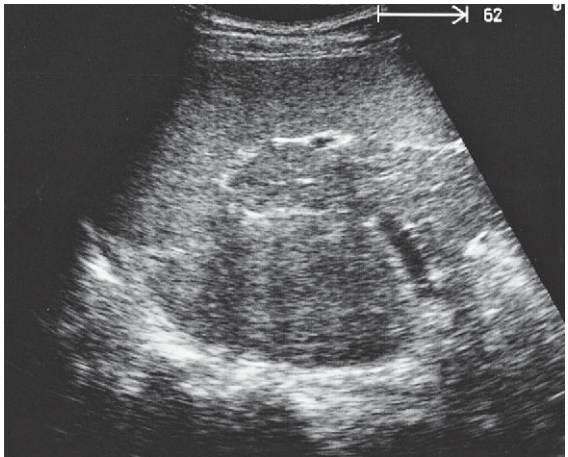
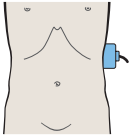


The tail of the pancreas is the most difficult part of the gland to evaluate with ultrasound.

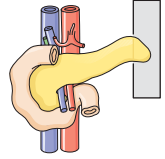
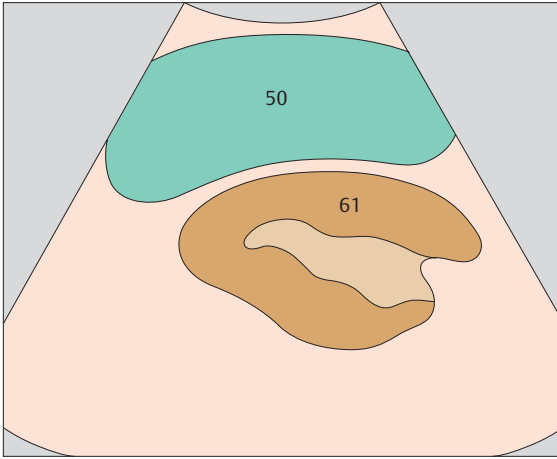




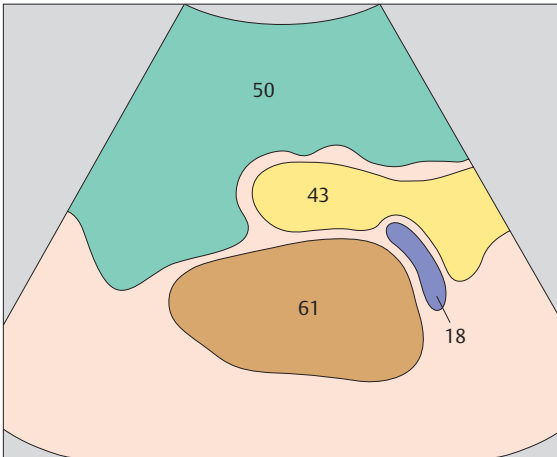
▶ 139 Scan posterior to tail of pancreas, spleen, kidney



▶ 140 Spleen, tail of pancreas, kidney

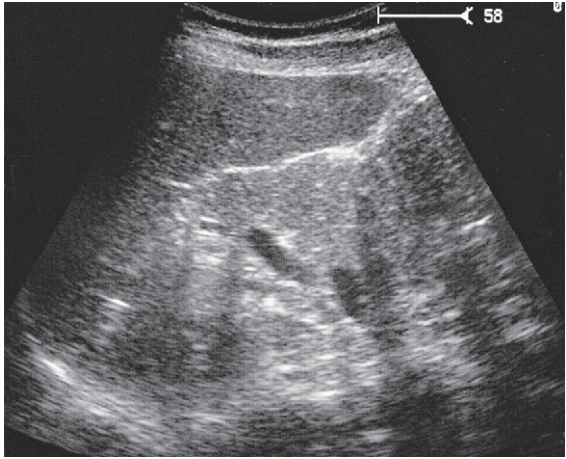
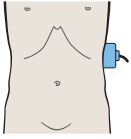


The tail of the pancreas is scanned intercostally through the spleen. Kidney and spleen serve as landmarks.

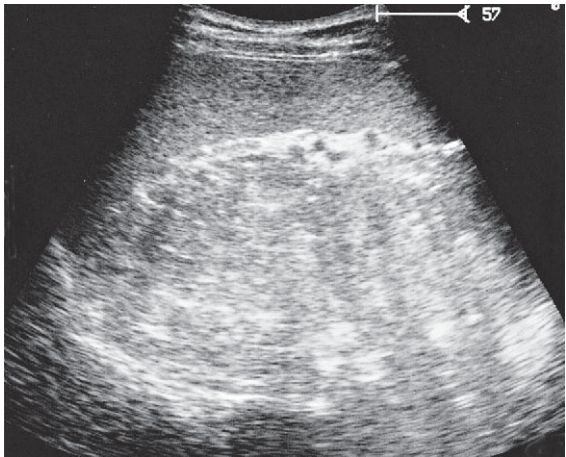
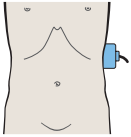


The tail of the pancreas is located in the splenic hilum between the spleen and the kidney.

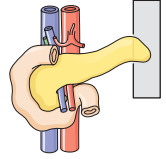
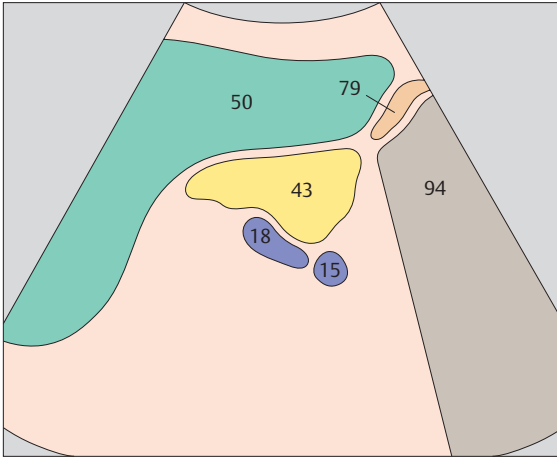




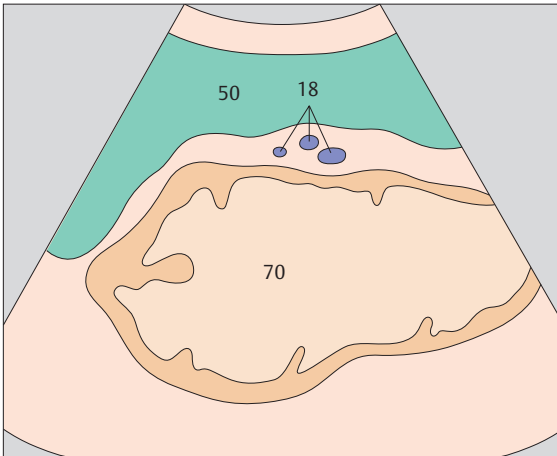
▶ 141 Spleen, tail of pancreas, kidney



▶ 142 Scan anterior to tail of pancreas, spleen, stomach

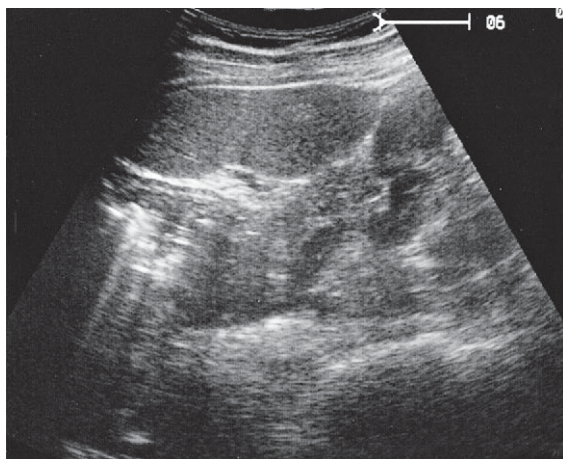
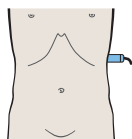


Interference from bowel gas is often encountered caudal to the tail of the pancreas.

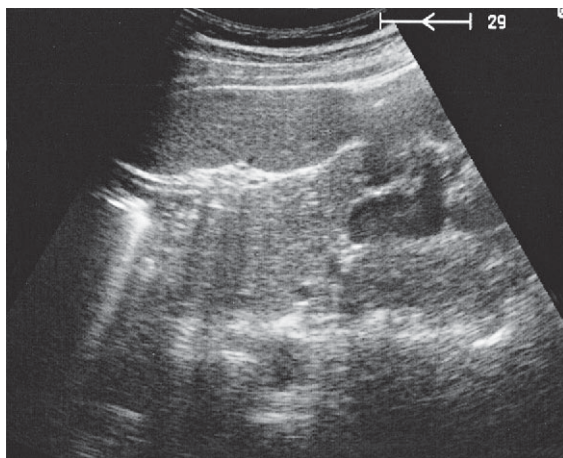
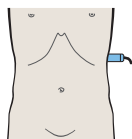


The stomach is a source of numerous artifacts anterior to the tail of the pancreas.

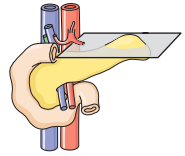
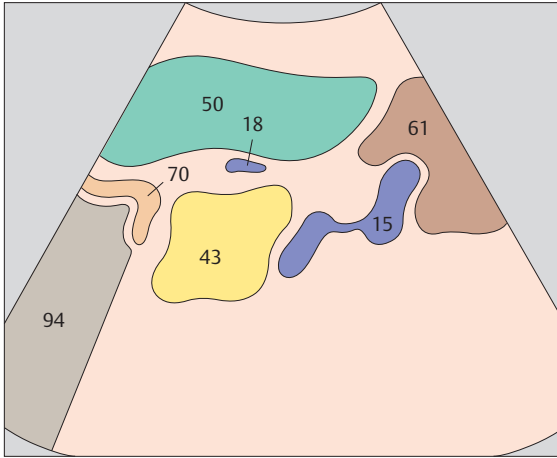




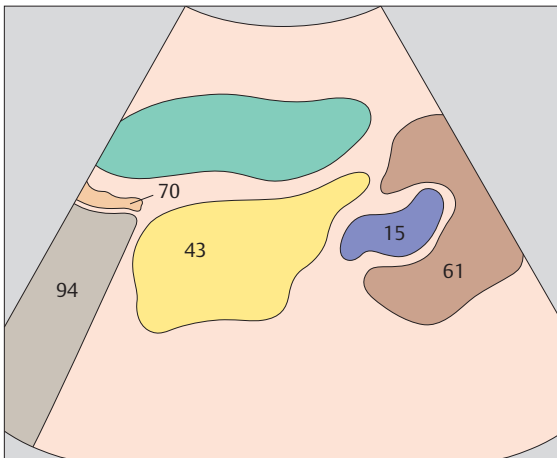
▶ 143 Spleen, tail of pancreas, kidney



▶ 144 Spleen, tail of pancreas, kidney

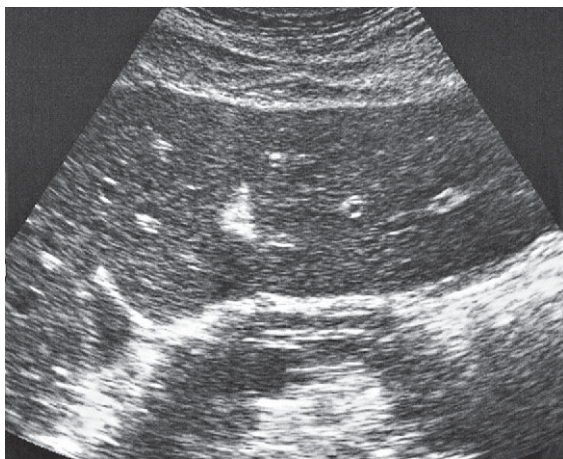
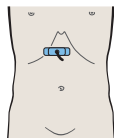


In transverse sections as well, the spleen is used as an acoustic window for scanning the tail of the pancreas.

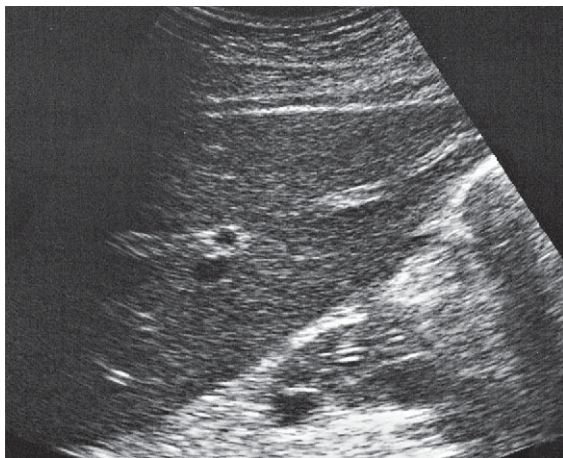
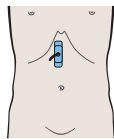


The tail of the pancreas lies in an angle between the spleen and the kidney.

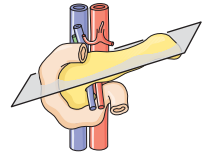
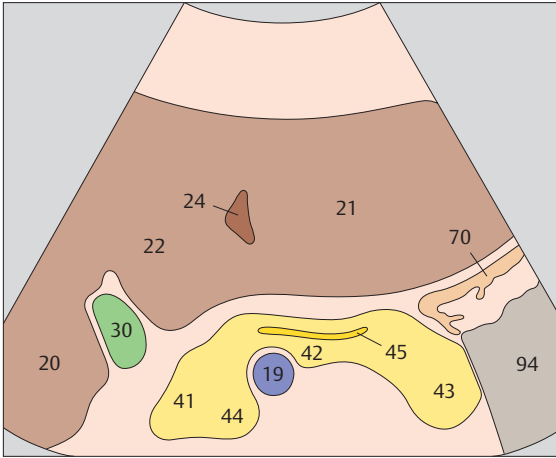




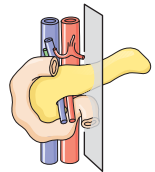
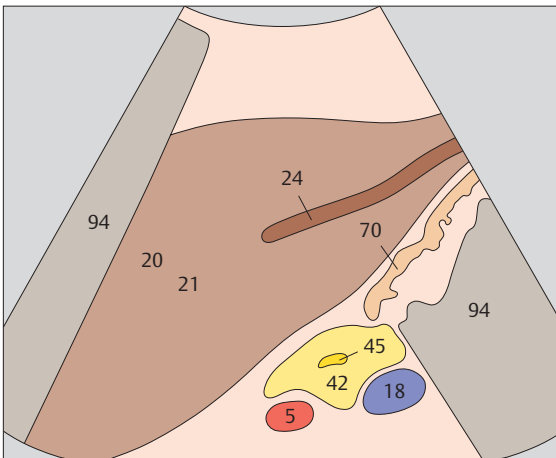
▶ 145 Transverse scan of pancreatic duct



▶ 146 Longitudinal scan of pancreatic duct



The pancreatic duct has a variable course. It usually runs in the ventrocranial part of the parenchyma, appearing sonographically as two parallel echogenic lines.



In this plane the pancreatic duct appears as a fine, tubular structure with a luminal diameter up to 3 mm. It is located slightly anterior to the center of the gland.



Spleen

Longitudinal Flank Scans of the Spleen

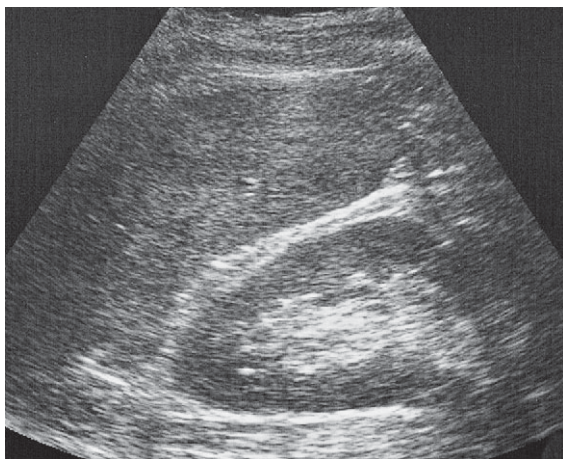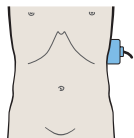
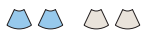- 147** Spleen, kidney
- 148** Splenic hilum, splenic vein
- 149** Spleen, stomach
- 150** Spleen, stomach

Transverse Flank Scans of the Spleen

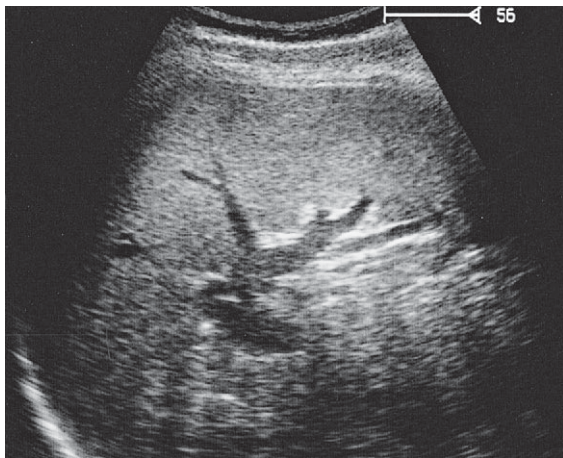
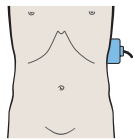
- 151** Spleen, kidney, stomach
- 152** Spleen, kidney, pancreas
- 153** Spleen, stomach
- 154** Spleen, small bowel

Details of the Spleen

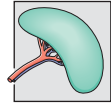
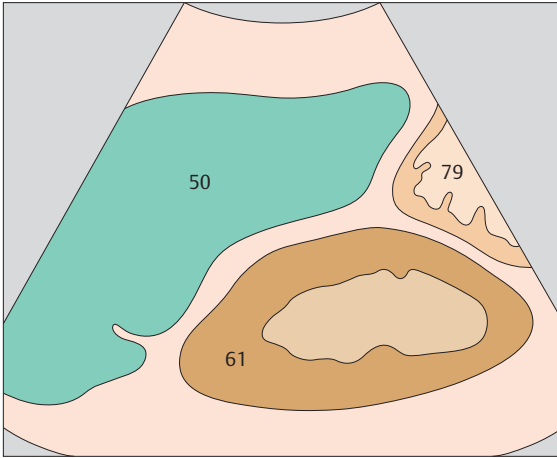
- 155** Accessory spleen
- 156** Accessory spleen



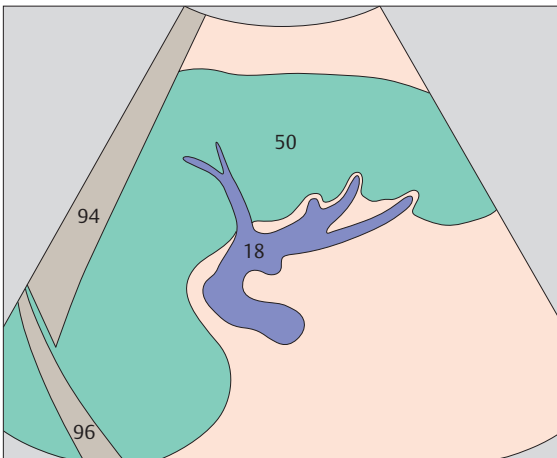
▶ 147 Spleen, kidney



▶ 148 Splenic hilum, splenic vein

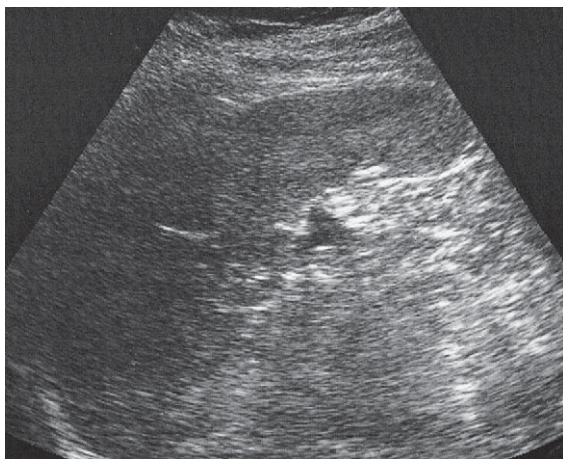
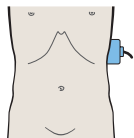
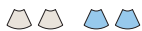

The spleen is identified in the longitudinal flank scan as a rounded triangle between the upper renal pole and the diaphragm.

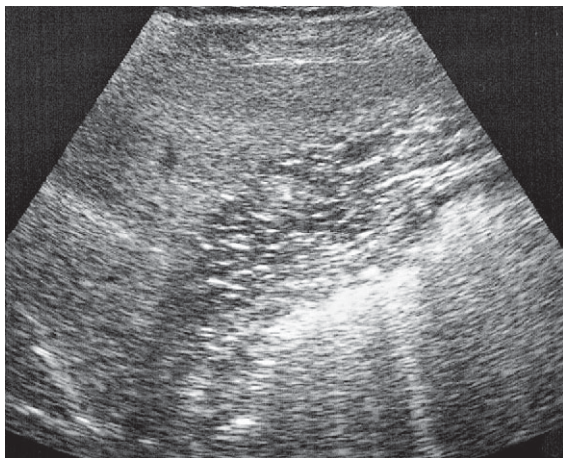
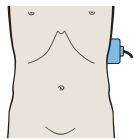


A flank scan at the level of the hilum displays the spleen in its greatest longitudinal dimension.

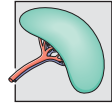
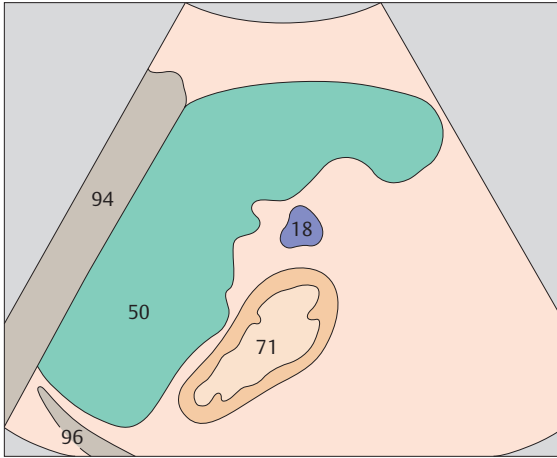




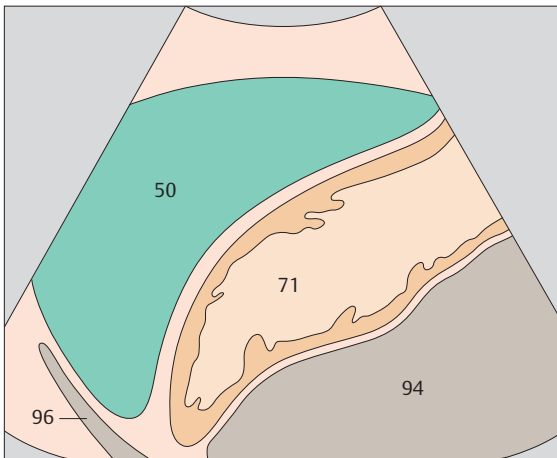
▶ 149 Spleen, stomach



▶ 150 Spleen, stomach

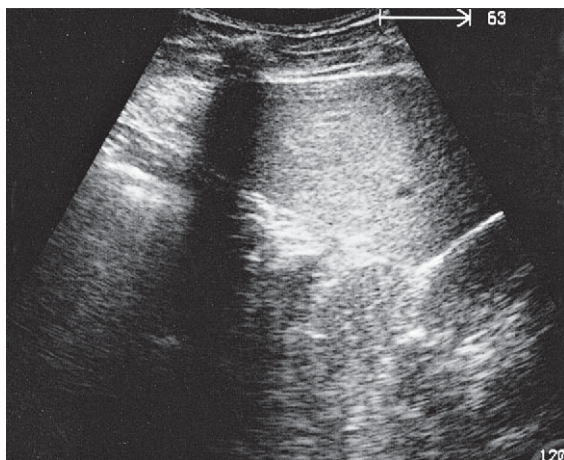
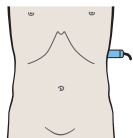
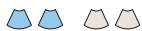

The spleen lies against the stomach anteriorly and medially.

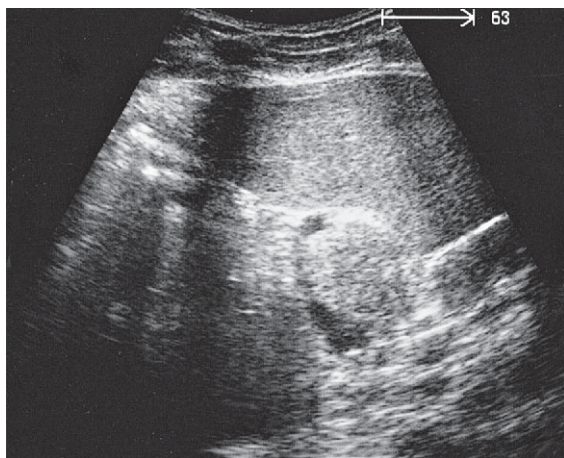
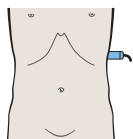


The spleen exhibits a typical crescent shape in an anterior flank scan.

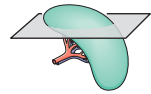
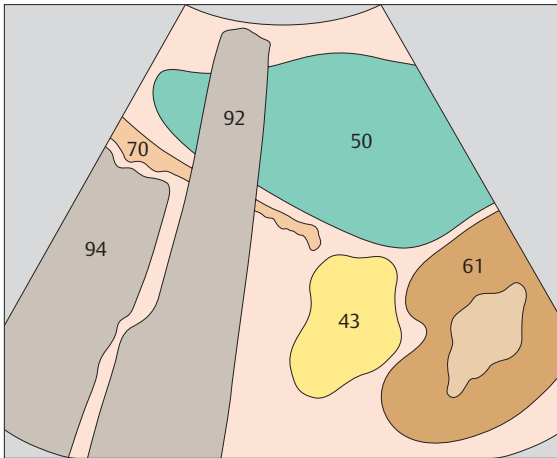




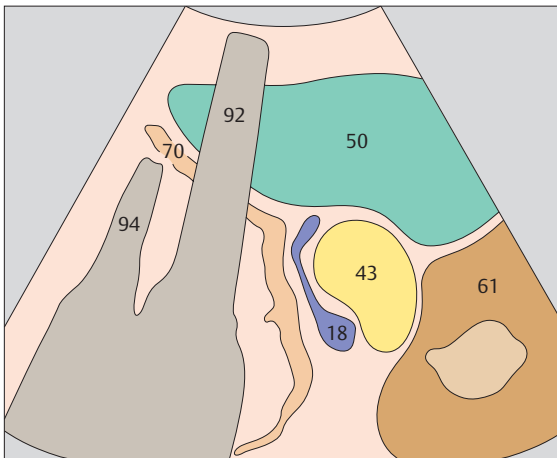
▶ 151 Spleen, kidney, pancreas, stomach



▶ 152 Spleen, kidney, pancreas

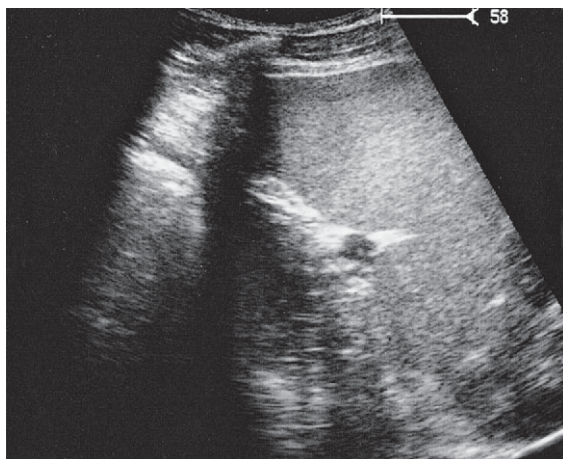
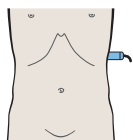
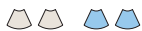

A high transverse flank scan demonstrates the typical triad of the spleen, kidney, and stomach.

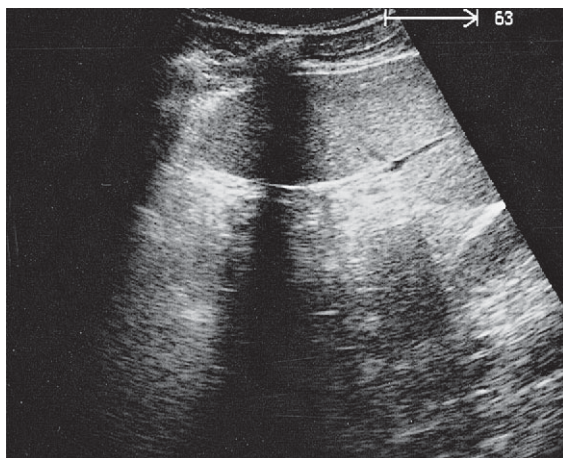
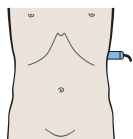


The tail of the pancreas can usually be identified in the splenic hilum next to the splenic vessels.

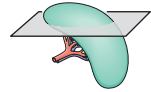
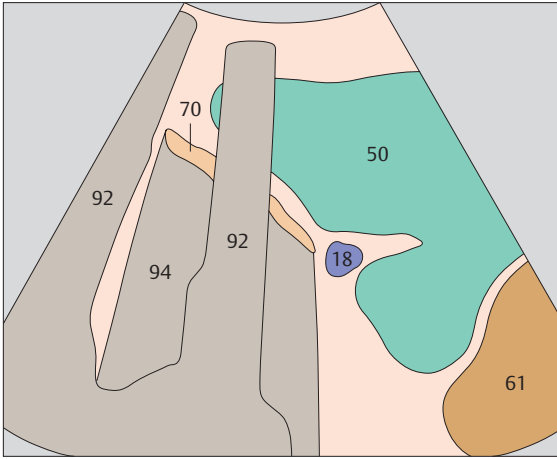




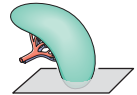
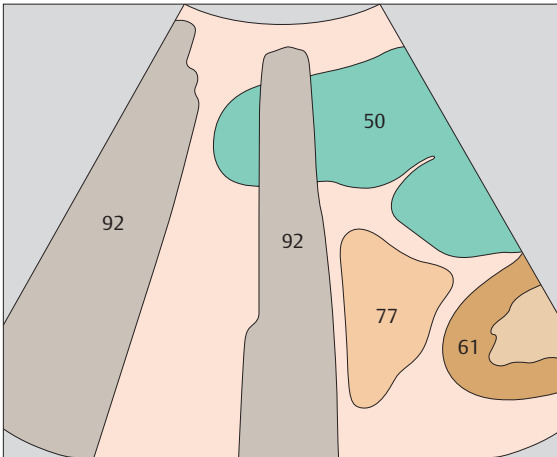
▶ 153 Spleen, stomach



▶ 154 Spleen, small bowel

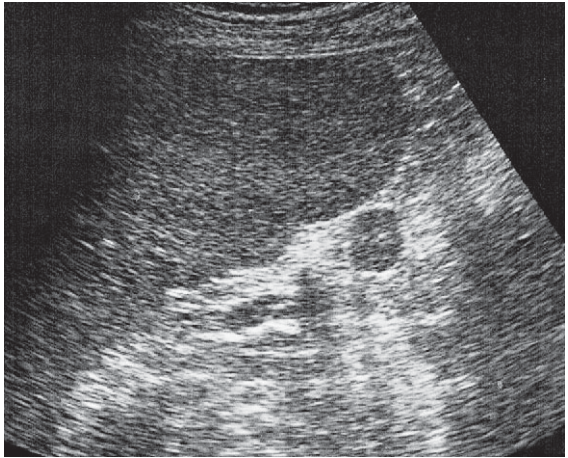
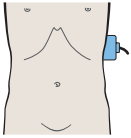


The spleen may be deeply lobulated by septa.

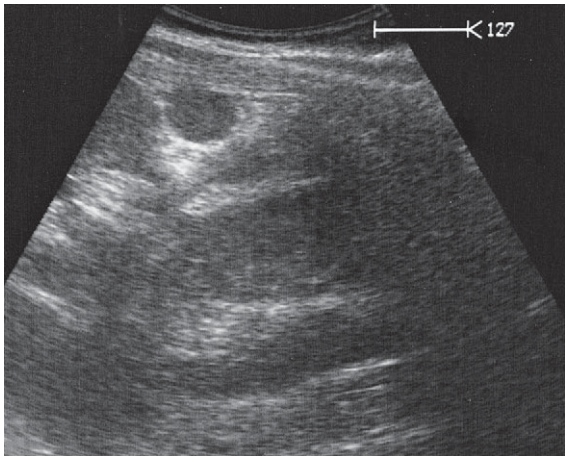
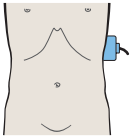


Loops of small bowel are located medial to the lower pole of the spleen.

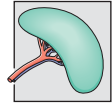
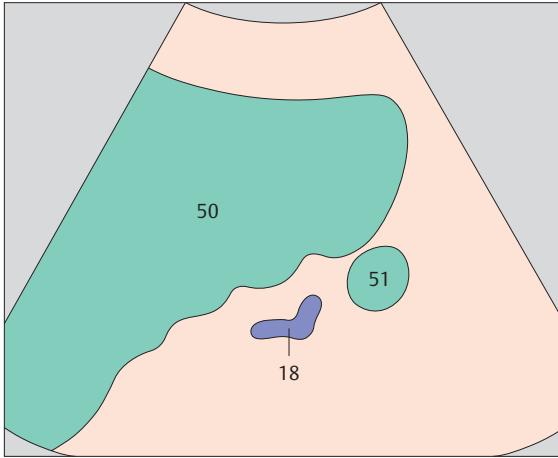




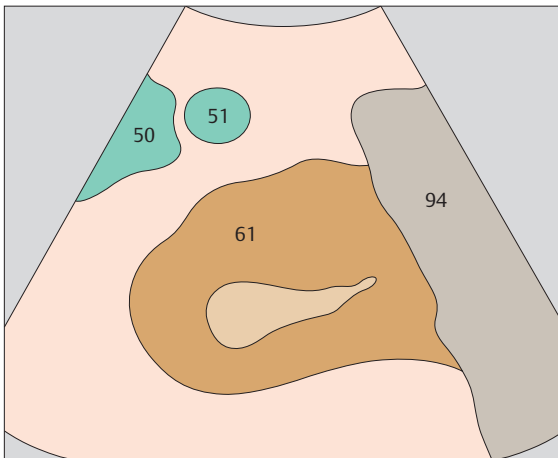
▶ 155 Accessory spleen



▶ 156 Accessory spleen



Accessory spleens are most commonly found in the hilar region.



An accessory spleen is occasionally found at the lower pole.



6 Kidneys

Longitudinal Flank Scans of the Right Kidney from Posterior to Anterior

- 157** Kidney, liver
- 158** Kidney, liver, colic flexure
- 159** Kidney, renal vein, liver
- 160** Kidney, renal vein, liver

Transverse Flank Scans of the Right Kidney from Above Downward

- 161** Kidney, liver, psoas muscle, quadratus lumborum muscle
- 162** Kidney, liver, psoas muscle, quadratus lumborum muscle

Upper Abdominal Longitudinal Scans of the Right Kidney from Right to Left

- 163** Kidney, liver
- 164** Kidney, liver, colic flexure
- 165** Kidney, renal vein, colon
- 166** Kidney, renal vein, colon

Upper Abdominal Transverse Scans of the Right Kidney from Above Downward

- 167** Kidney, renal vein, vena cava, liver
- 168** Kidney, renal vein, renal artery, vena cava, liver

Longitudinal Flank Scans of the Left Kidney from Posterior to Anterior

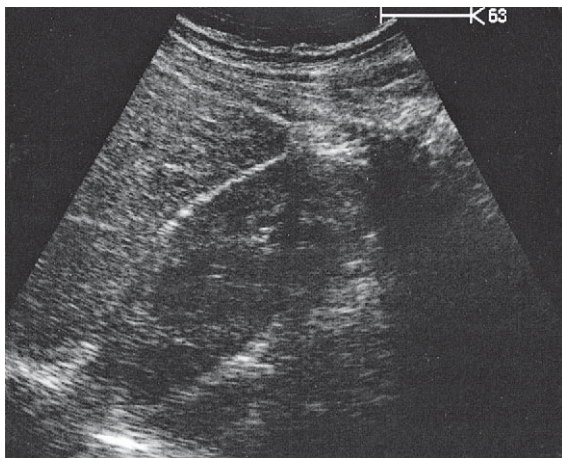
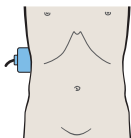
- 169** Kidney, spleen, psoas muscle
- 170** Kidney, spleen, psoas muscle
- 171** Kidney, spleen, psoas muscle
- 172** Kidney, renal vein, spleen, aorta

Transverse Flank Scans of the Left Kidney from Above Downward

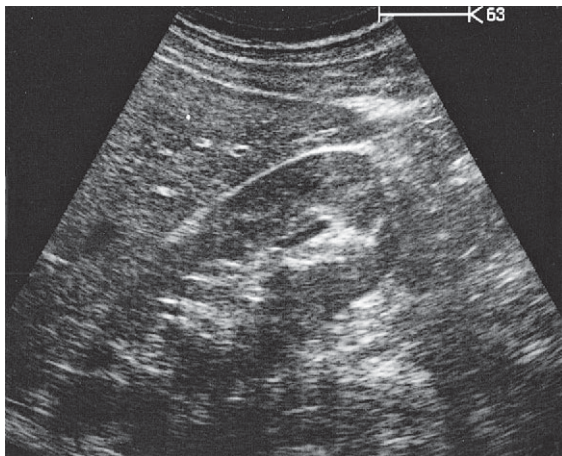
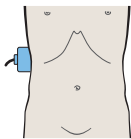
- 173** Kidney, spleen, bowel
- 174** Kidney, spleen, psoas muscle

Details of the Kidneys

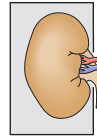
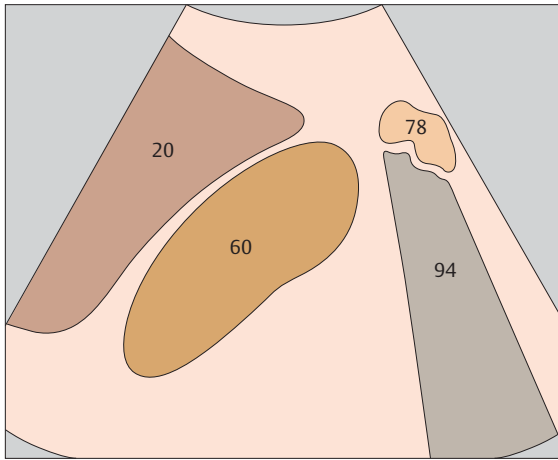
- 175** Medullary pyramids
- 176** Collecting system



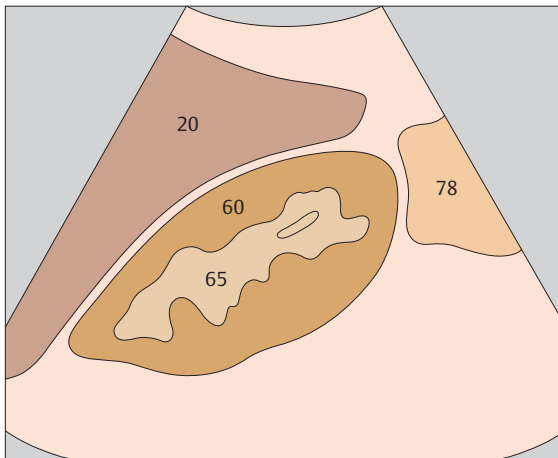
▶ 157 Kidney, liver



▶ 158 Kidney, liver, colic flexure

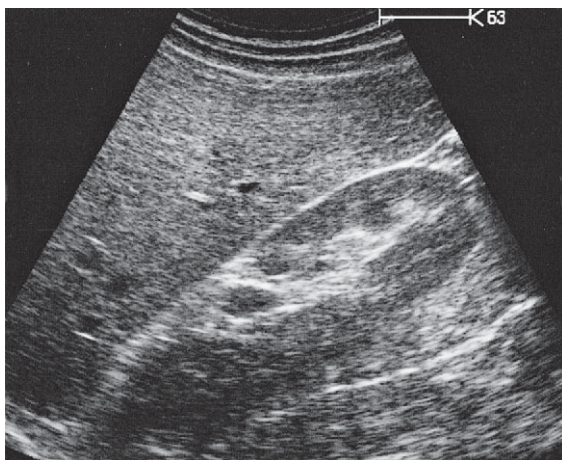
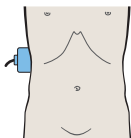
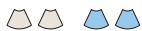

The liver serves as an acoustic window for scanning the right kidney.

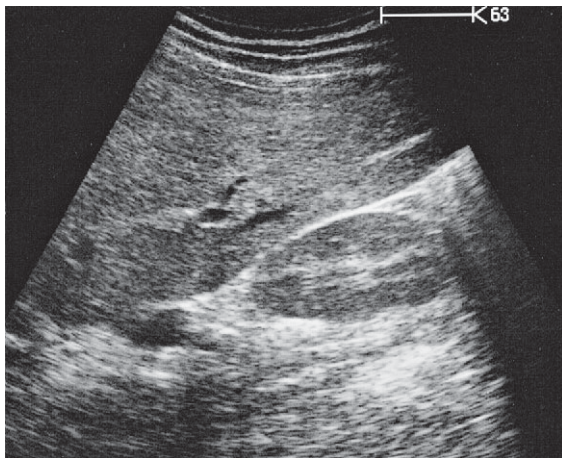
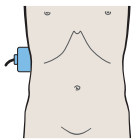


The central echo complex of the kidney is a summation effect produced by the pyelocaliceal system, blood vessels, lymphatics, fatty tissue, and the renal sinus.

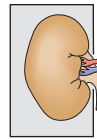
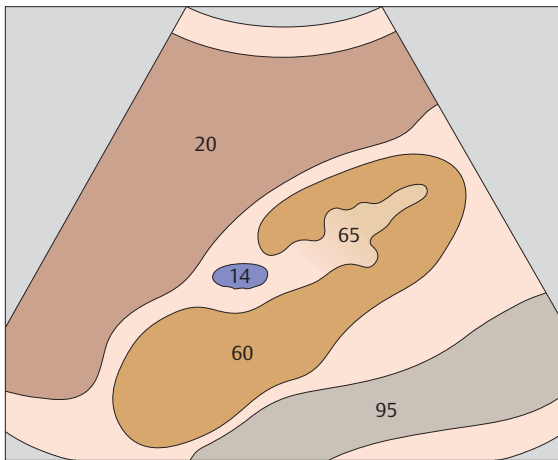




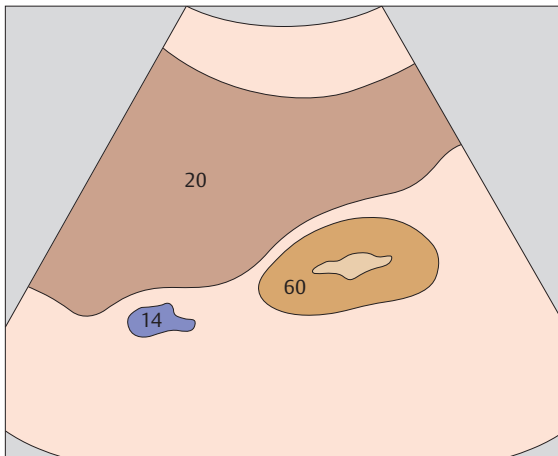
▶ 159 Kidney, renal vein, liver



▶ 160 Kidney, renal vein, liver

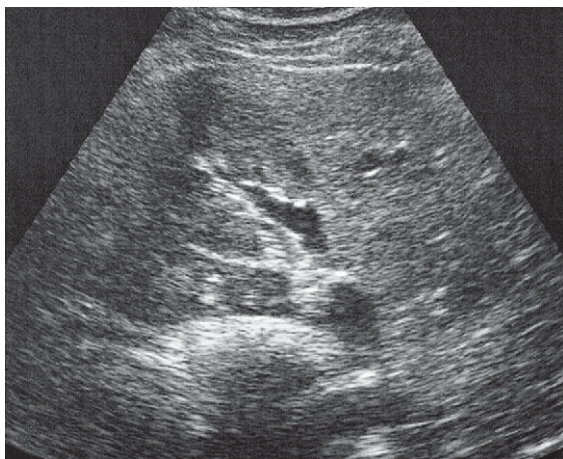
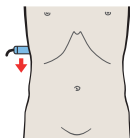


During respiratory excursions, the kidneys glide downward on the lumbar muscles.

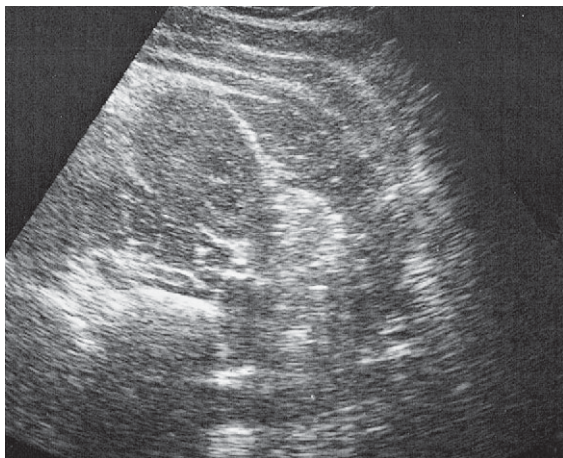
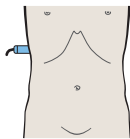


The fibrous renal capsule cannot be visualized with ultrasound.

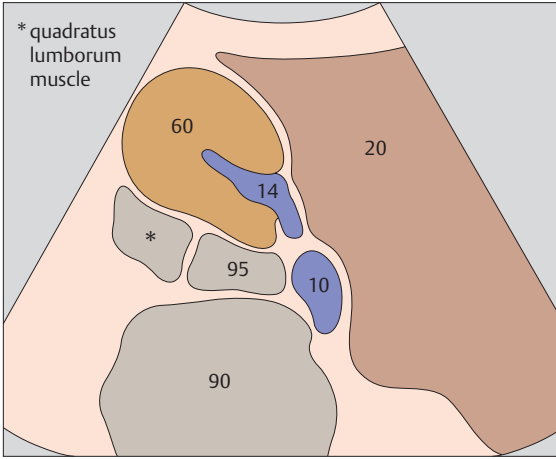




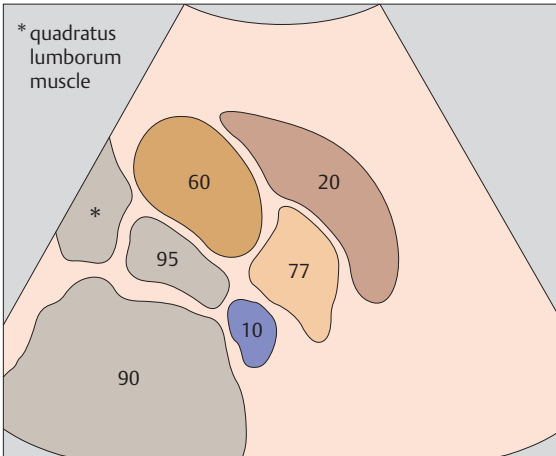
- ▶ **161** Kidney, liver, psoas muscle, quadratus lumborum muscle



- ▶ **162** Kidney, liver, psoas muscle, quadratus lumborum muscle

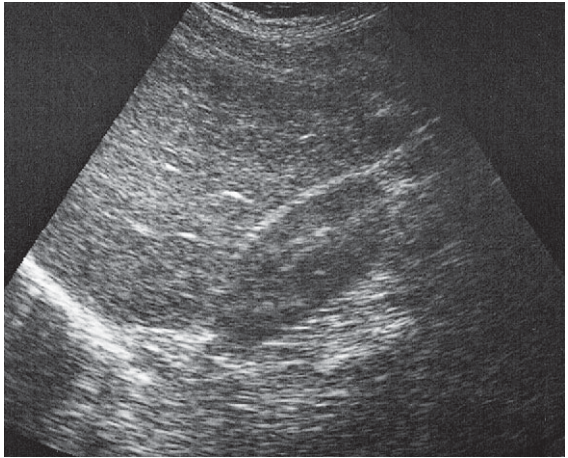
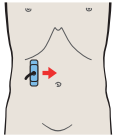
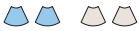

The posterior aspect of the right kidney lies in an angle between the spinal column, musculature, and right lobe of the liver.

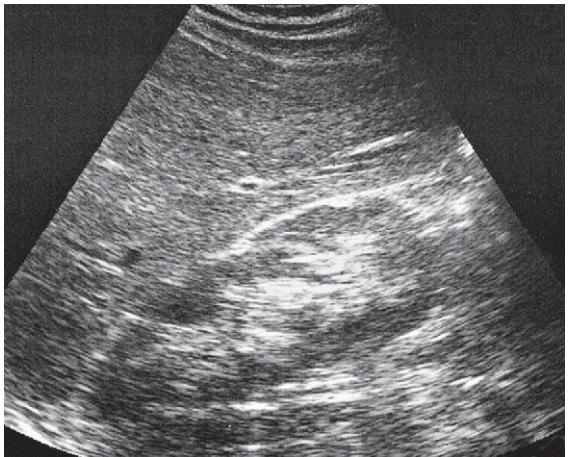
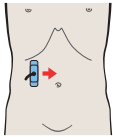


The kidney is located anterior to the quadratus lumborum muscle and lateral to the psoas major muscle.

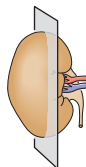
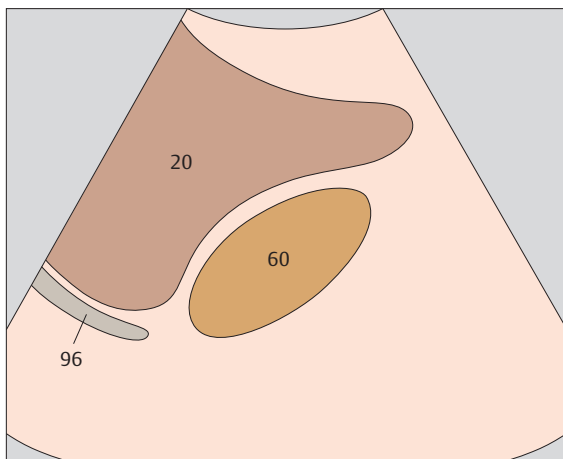




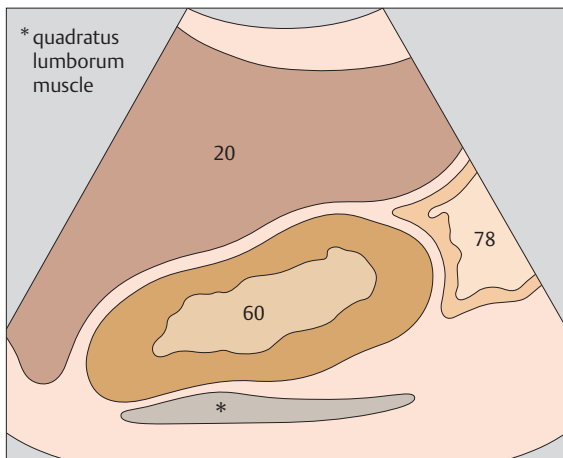
▶ 163 Kidney, liver



▶ 164 Kidney, liver, colic flexure

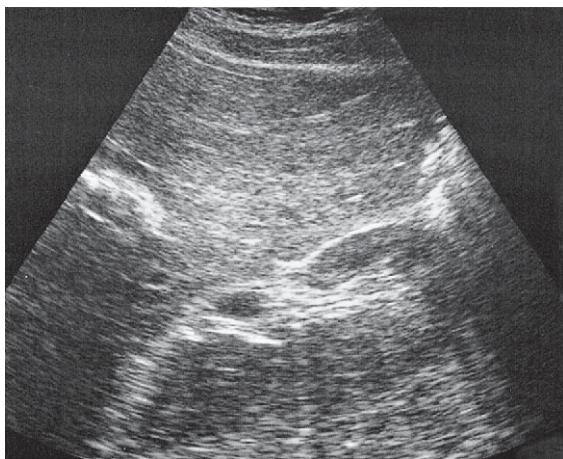
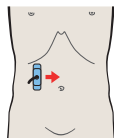


Unlike the left kidney, the right kidney is readily scanned from the anterior aspect by using the liver as an acoustic window.

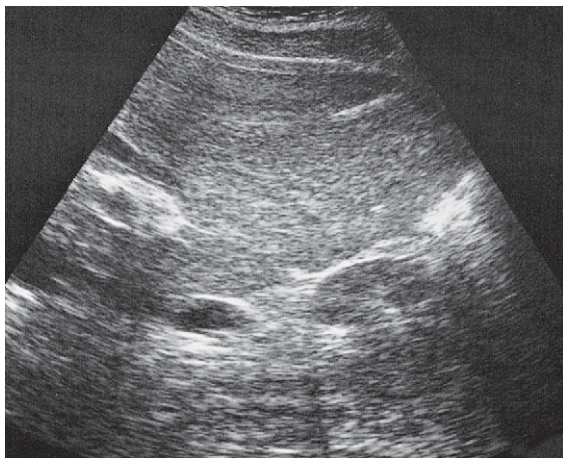
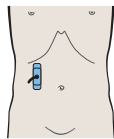


The right lobe of the liver covers the kidney anteriorly. The right colic flexure and duodenum also overlie the kidney, especially its caudal half.

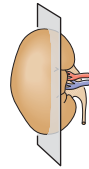
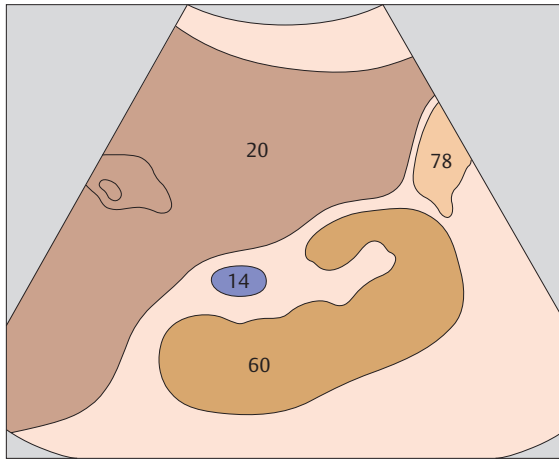




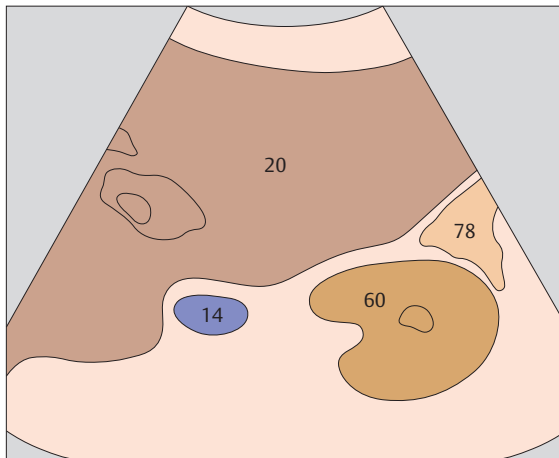
▶ 165 Kidney, renal vein, colon



▶ 166 Kidney, renal vein, colon

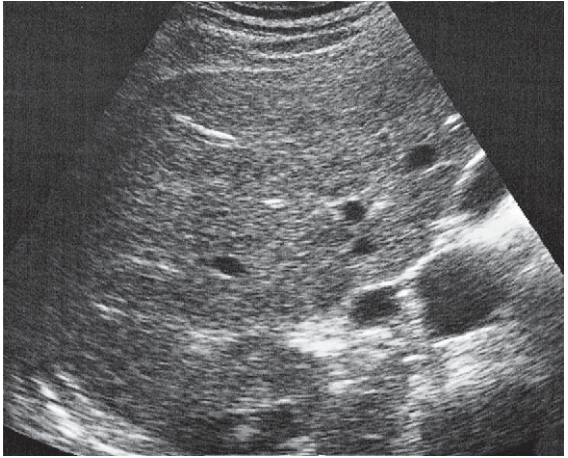
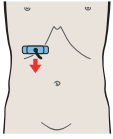


The colon overlies the lower pole of the right kidney.

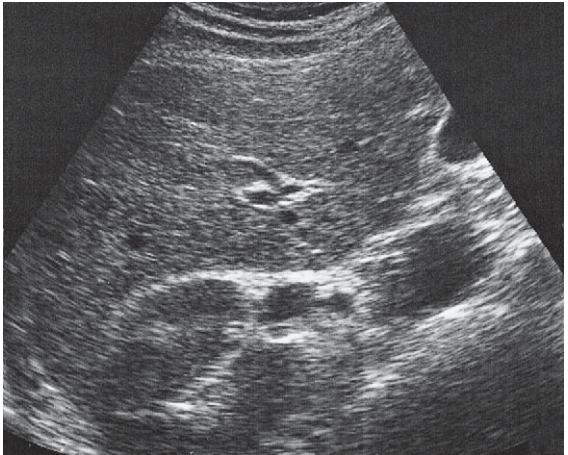
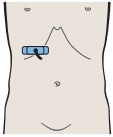


The renal vein runs obliquely upward from the hilum to the vena cava.

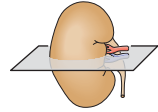
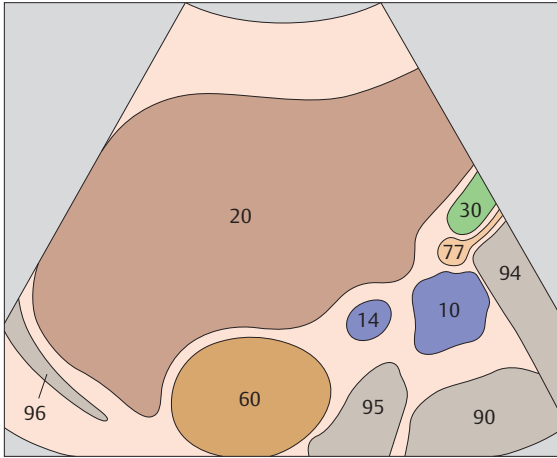




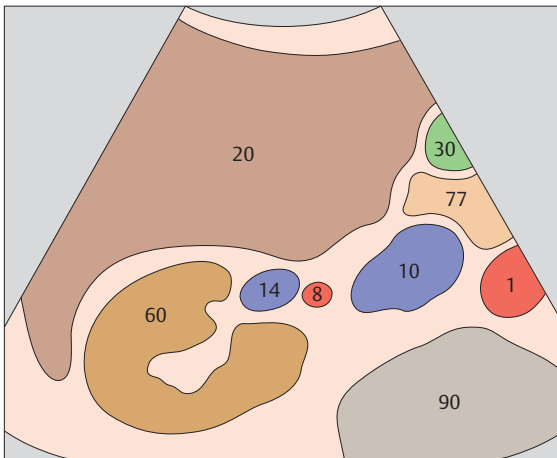
▶ **167** Kidney, renal vein, vena cava, liver



▶ **168** Kidney, renal vein, renal artery, vena cava, liver

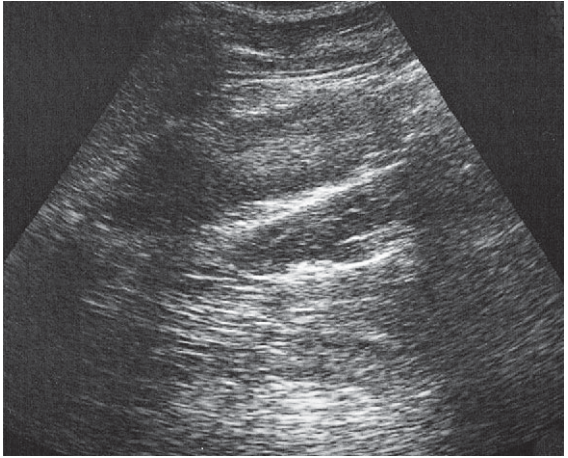
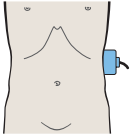
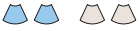

The renal vein opens into the vena cava at the level of the upper renal pole.

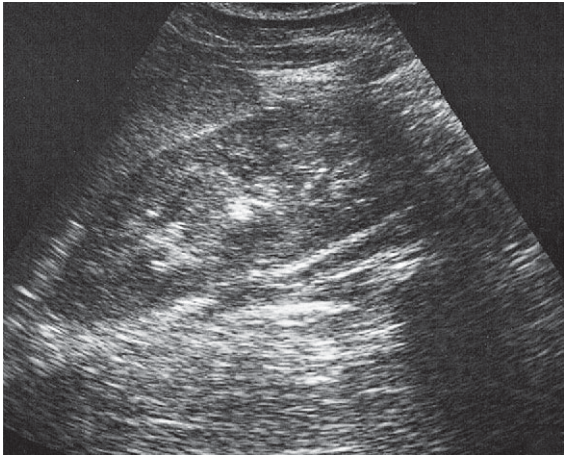
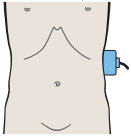


The renal artery arises from the aorta and enters the renal hilum. At that location it is dorsocaudal to the renal vein, which usually is considerably larger than the artery.

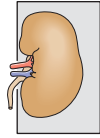
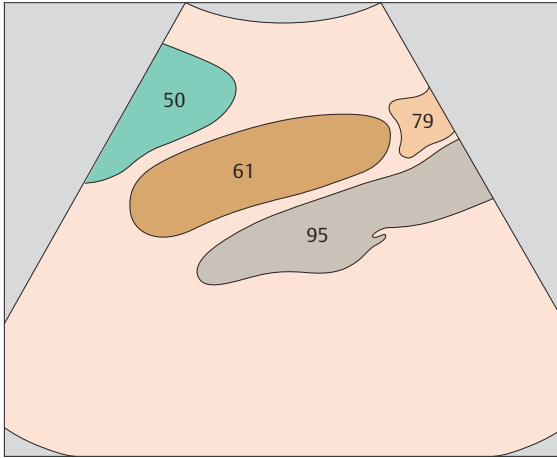




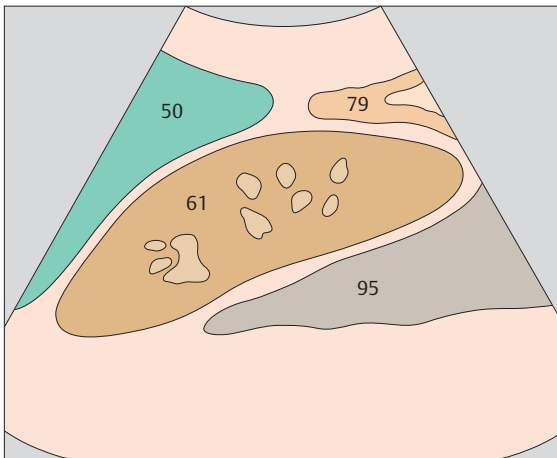
▶ 169 Kidney, spleen, psoas muscle



▶ 170 Kidney, spleen, psoas muscle

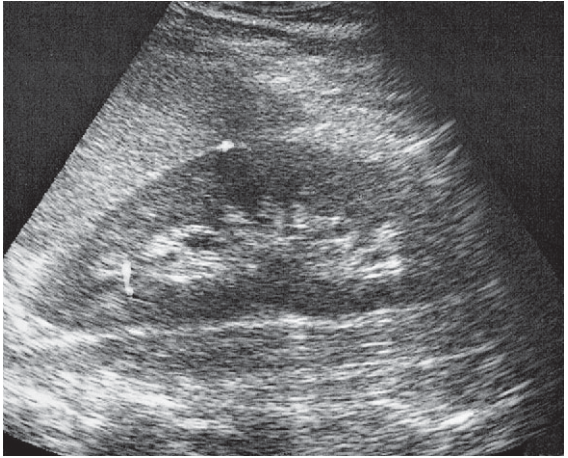
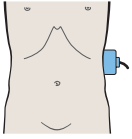
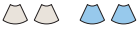

There is no good acoustic window available for scanning the left kidney.

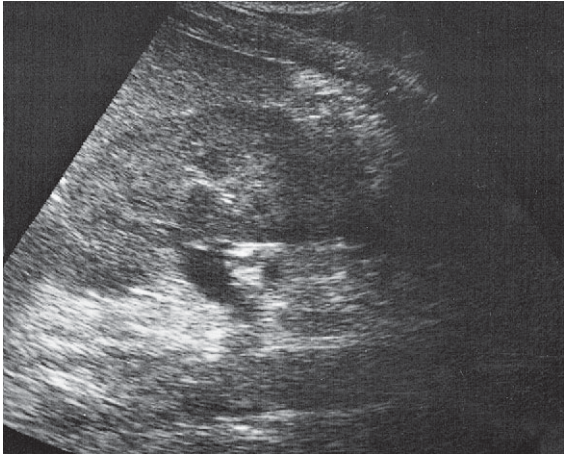
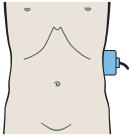


The spleen extends laterally to about the middle of the kidney.

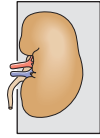
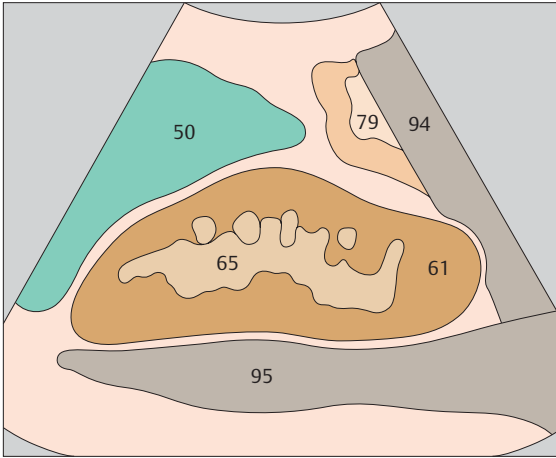




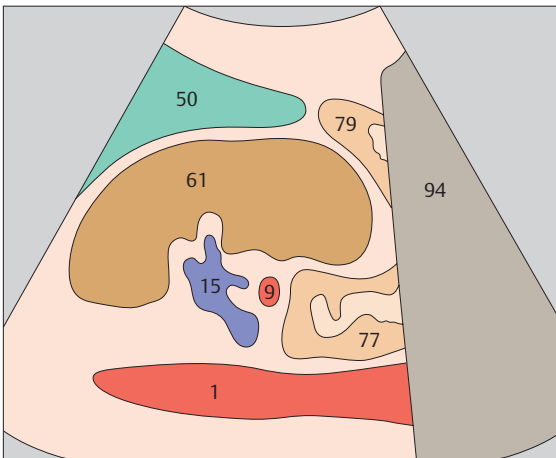
▶ 171 Kidney, spleen, psoas muscle



▶ 172 Kidney, renal vein, spleen, aorta

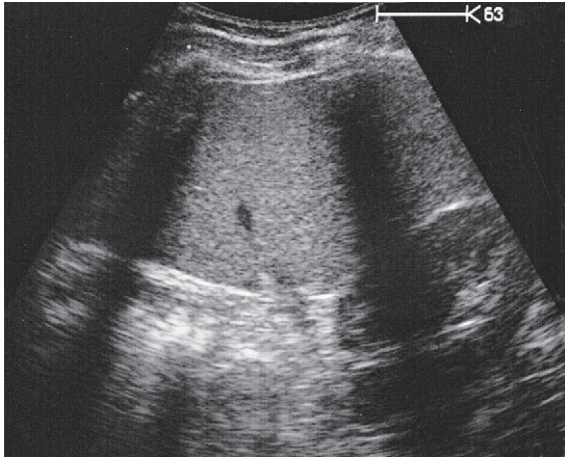
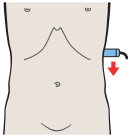


The lower half of the left kidney is covered laterally by the descending colon and left colic flexure.

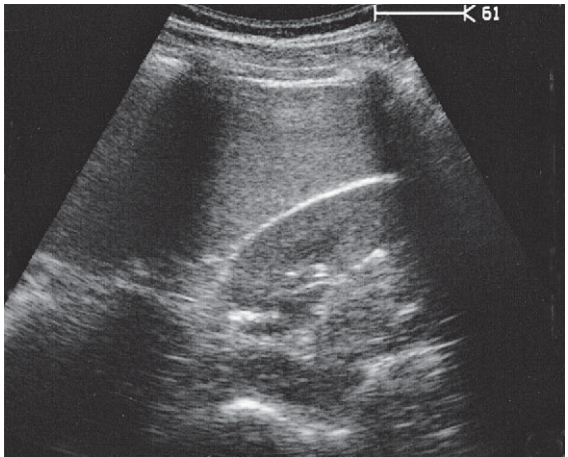
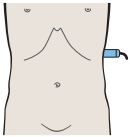


In the left longitudinal flank scan, the aorta is seen in the lower part of the image.

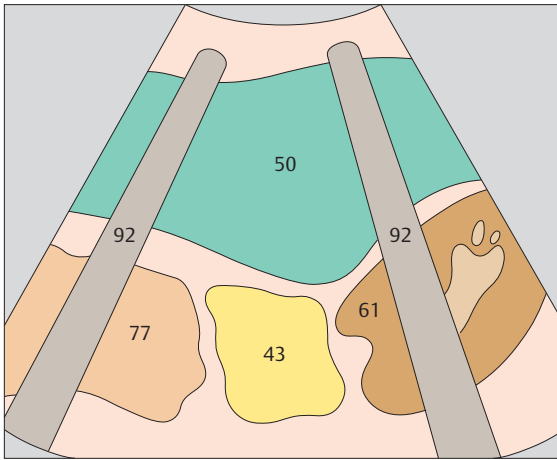




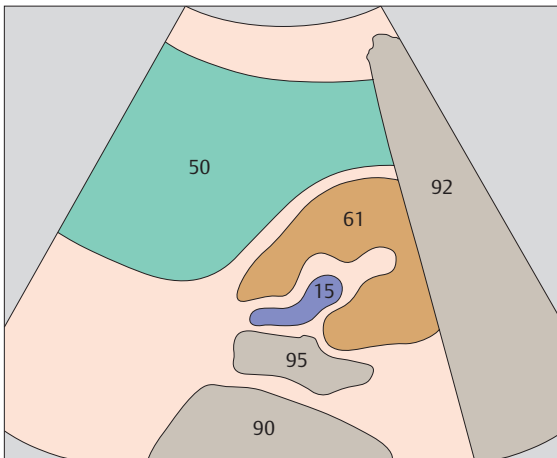
▶ 173 Kidney, spleen, bowel



▶ 174 Kidney, spleen, psoas muscle

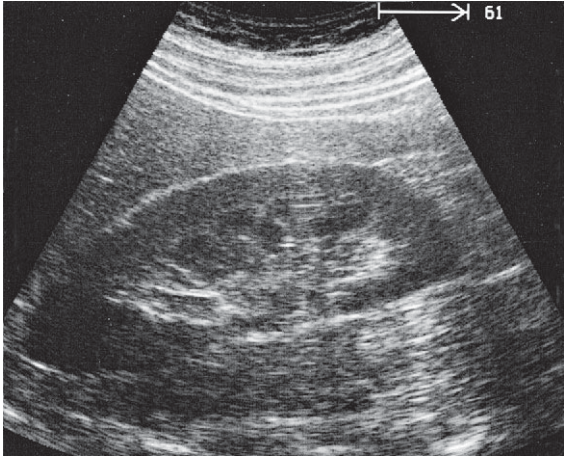
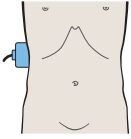


The ribs pose a barrier to transsplenic scanning of the left kidney.

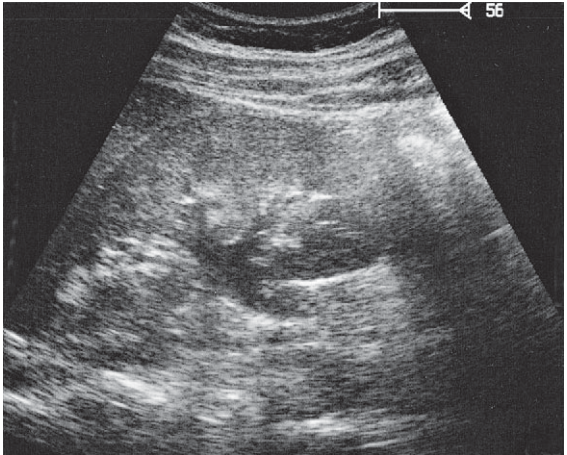
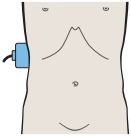


The posterior aspect of the left kidney lies in an angle between the spinal column, musculature, and spleen.

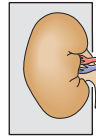
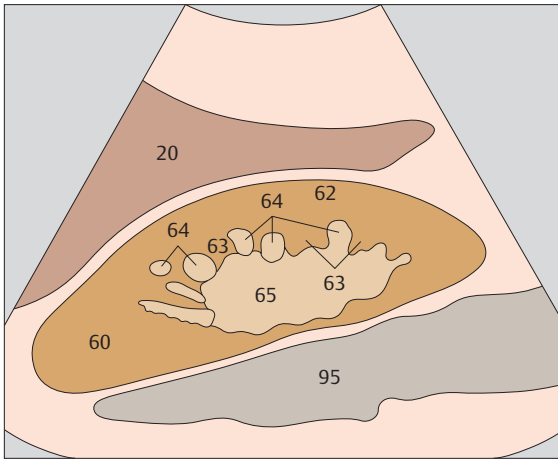




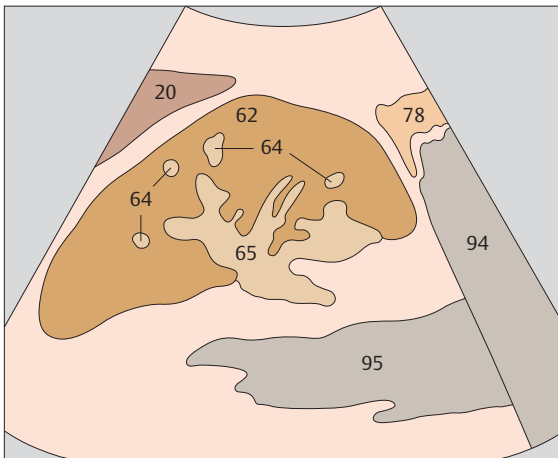
▶ 175 Medullary pyramids



▶ 176 Collecting system



An imaginary line joining the bases of the hypoechoic medullary pyramids in the ultrasound image marks the boundary line between the renal cortex and medulla.



Strong diuresis produces a band-like or stellate fluid-filling pattern in the renal pelvis.



7 Adrenal Glands

Upper Abdominal Longitudinal Scans of the Right Adrenal Gland from Right to Left

- 177** Kidney, liver
- 178** Kidney, liver
- 179** Adrenal gland, liver
- 180** Adrenal gland, vena cava, renal artery

Upper Abdominal Transverse Scans of the Right Adrenal Gland from Below Upward

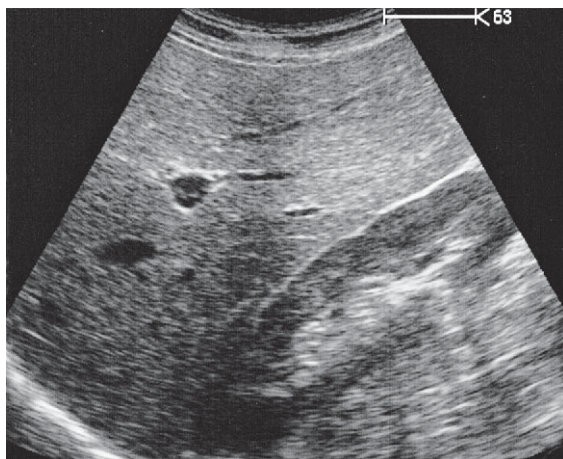
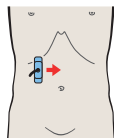
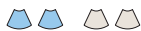- 181** Kidney, vena cava
- 182** Kidney, renal vein, vena cava
- 183** Renal vein, vena cava
- 184** Adrenal gland, vena cava

Longitudinal Flank Scans of the Left Adrenal Gland from Back to Front

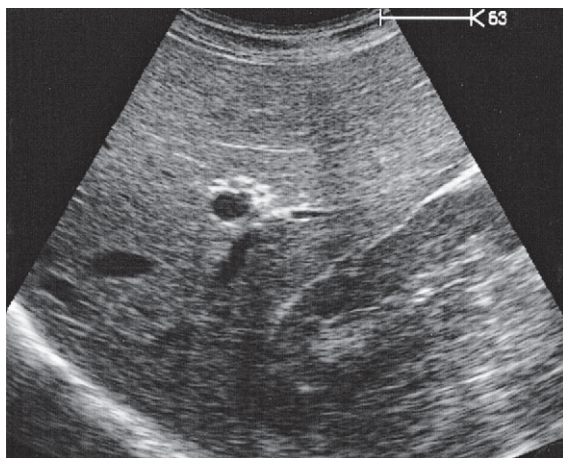
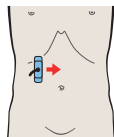
- 185** Kidney, spleen
- 186** Adrenal gland, kidney, spleen
- 187** Adrenal gland, kidney, spleen
- 188** Spleen, tail of pancreas

Details of the Adrenal Glands

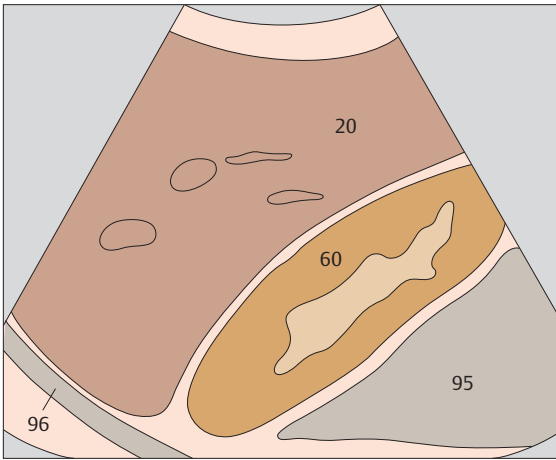
- 189** Layers of adrenal gland
- 190** Layers of adrenal gland



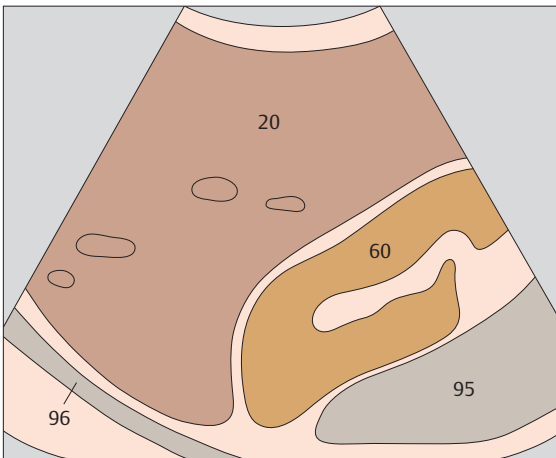
▶ 177 Kidney, liver



▶ 178 Kidney, liver

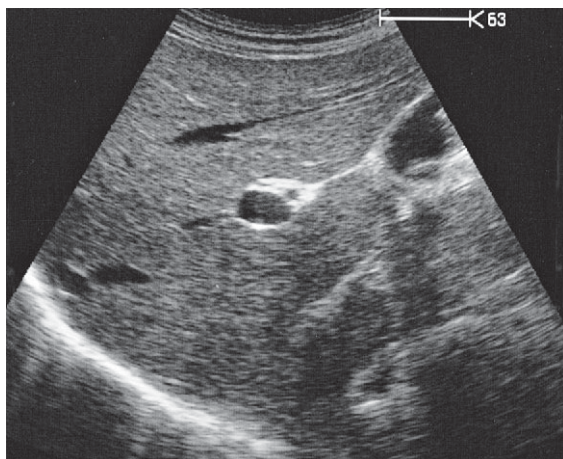
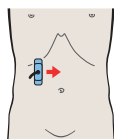
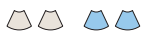

The right adrenal gland is located at the level of the upper renal pole, medial and anterior to the right kidney.

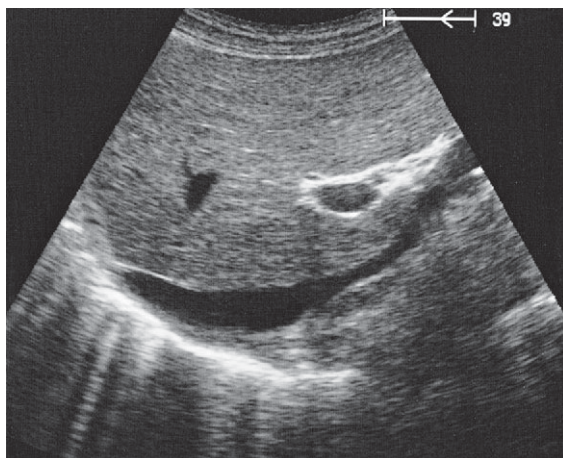
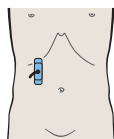


In an upper abdominal longitudinal scan from the anterior aspect, the kidney is used as a landmark for locating the right adrenal gland.

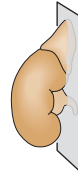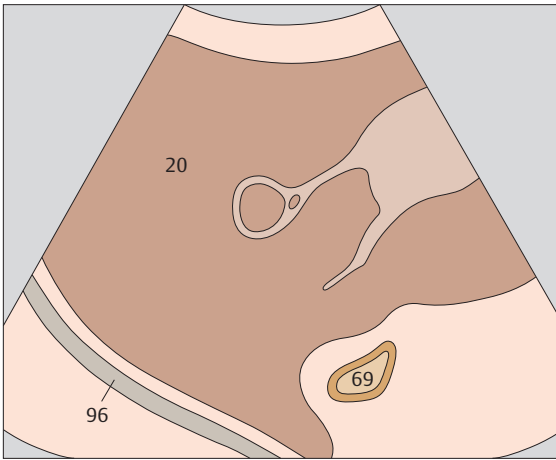




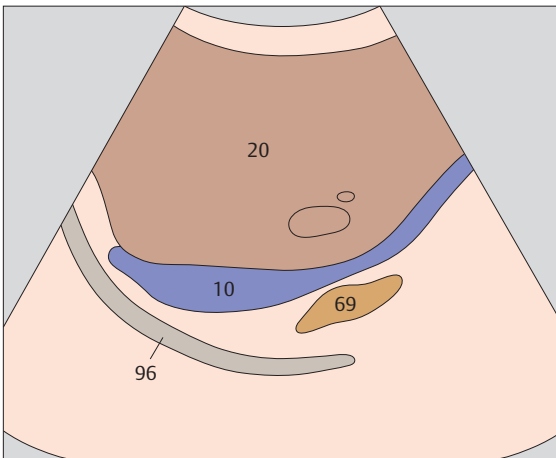
▶ 179 Adrenal gland, liver



▶ 180 Adrenal gland, vena cava, renal artery

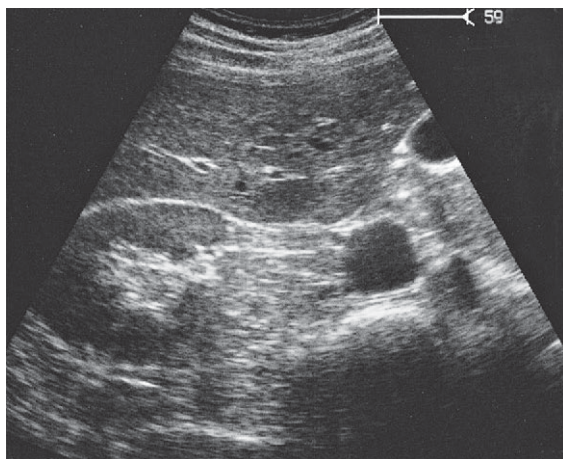
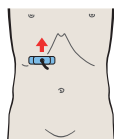
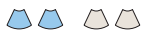

In a scan across the kidney from right to left, when the upper renal pole is just disappearing from the image the region of the right adrenal gland has been located.

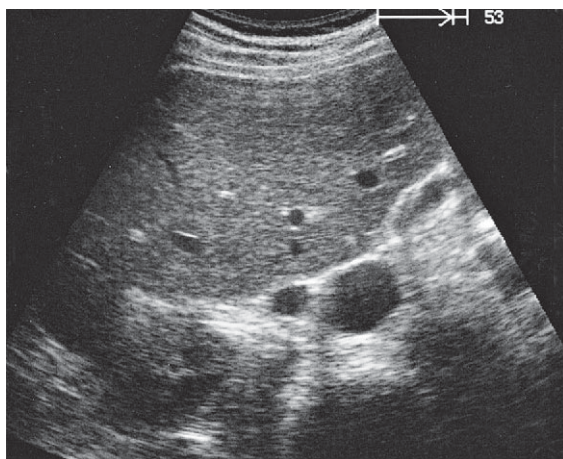
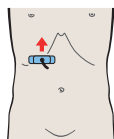


The right adrenal gland extends behind the vena cava, above the renal vessels.

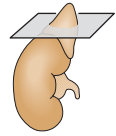
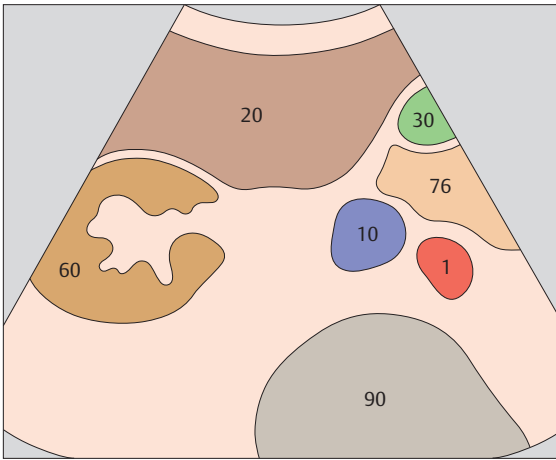




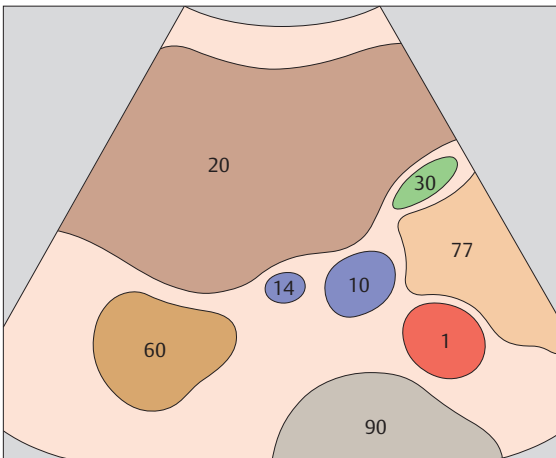
▶ 181 Kidney, vena cava



▶ 182 Kidney, renal vein, vena cava

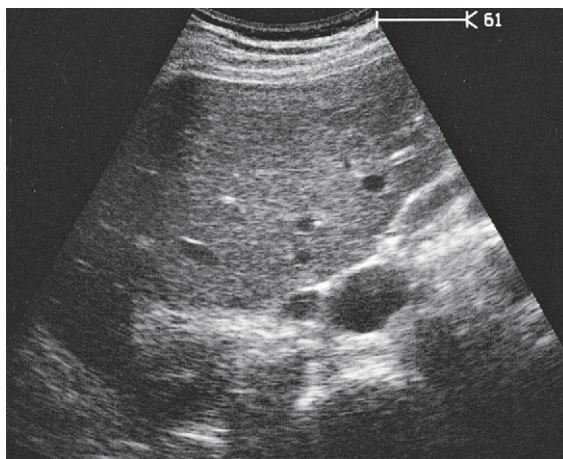
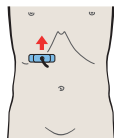


The landmarks for identifying the right adrenal gland region in transverse section are the kidney, the inferior surface of the liver, and the vena cava.

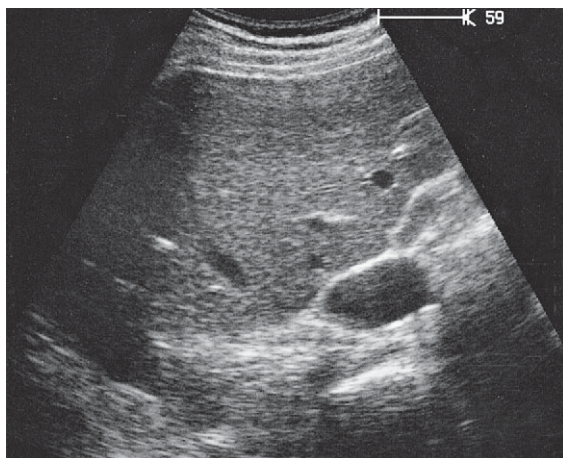
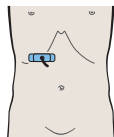


The adrenal region is located above the renal hilar vessels.

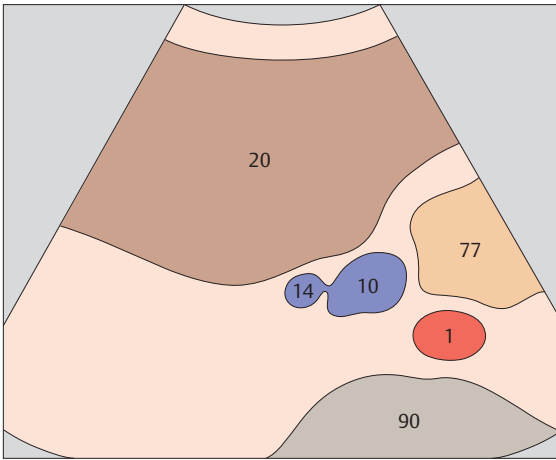




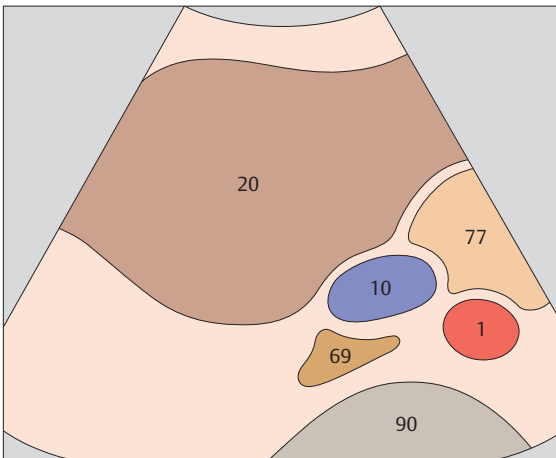
▶ 183 Renal vein, vena cava



▶ 184 Adrenal gland, vena cava

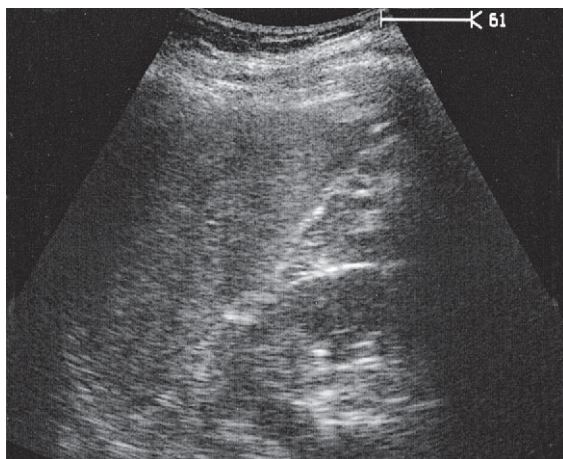
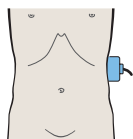


The right adrenal gland is identified just above the renal pole, lateral and posterior to the vena cava.

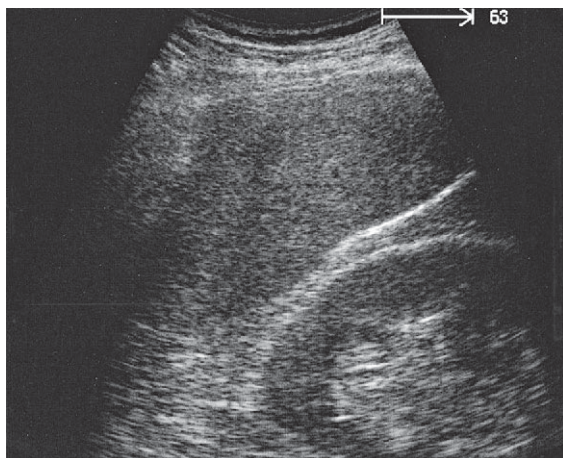
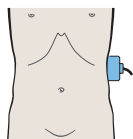


The right adrenal gland appears as a narrow, triangular, hypoechoic structure with an echodense rim.

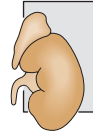
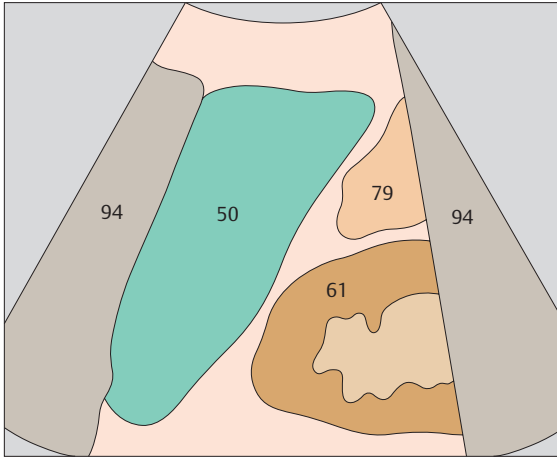




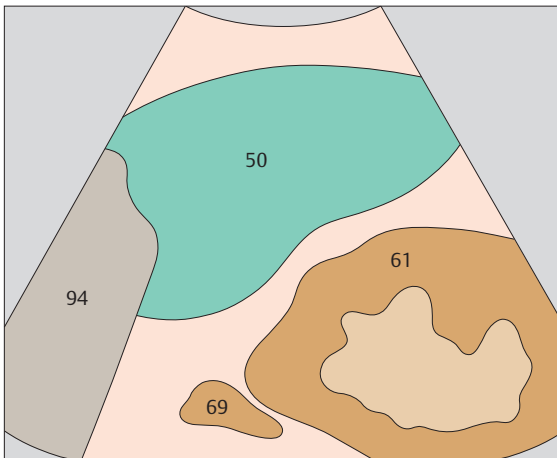
▶ 185 Kidney, spleen



▶ 186 Adrenal gland, kidney, spleen

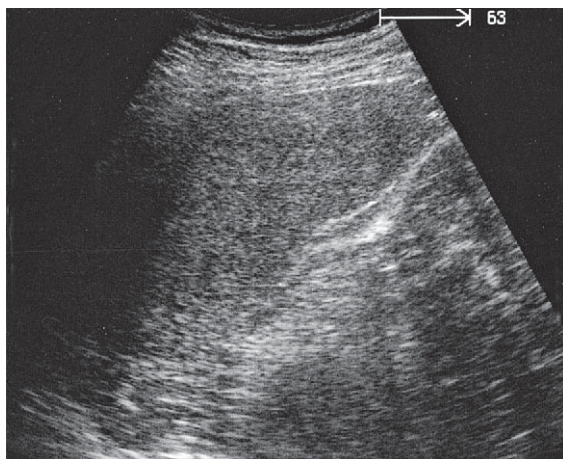
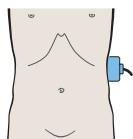
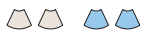

The left adrenal gland is usually more difficult to locate than the right adrenal gland.

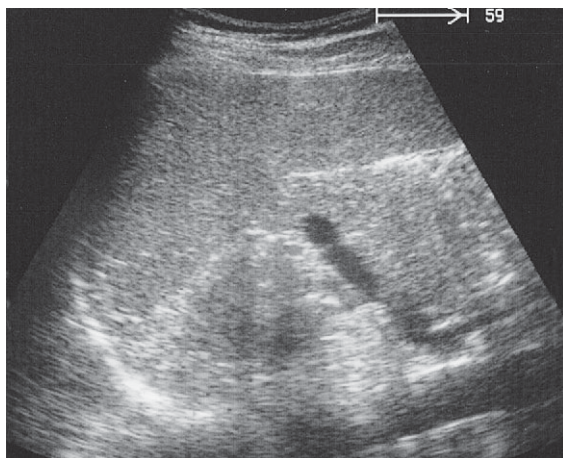
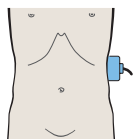


The left adrenal gland is identified between the upper renal pole, spleen, and aorta.

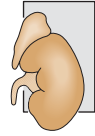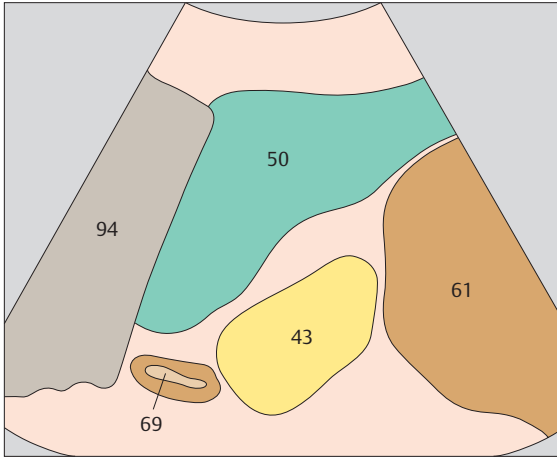




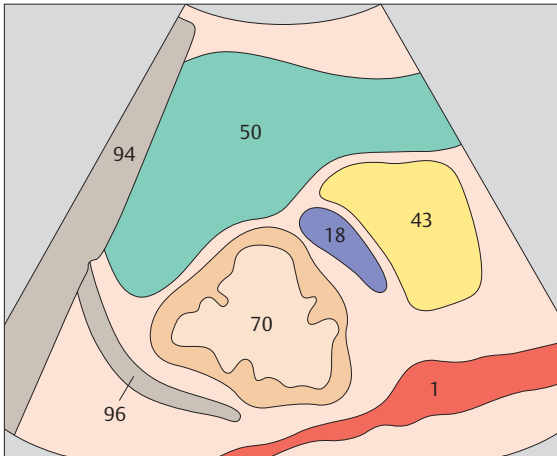
▶ 187 Adrenal gland, kidney, spleen



▶ 188 Spleen, tail of pancreas

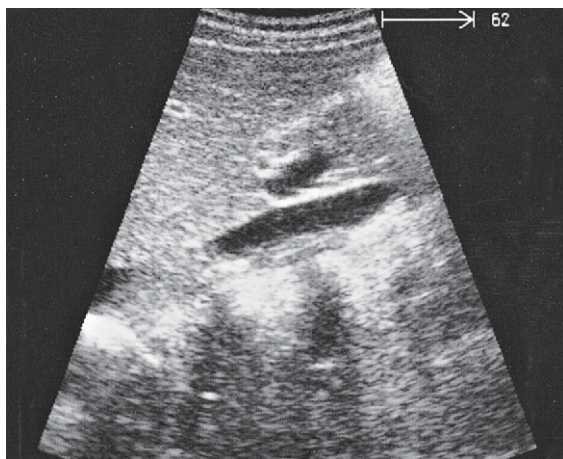
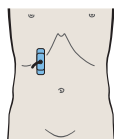


The left adrenal gland is frequently crescent-shaped.

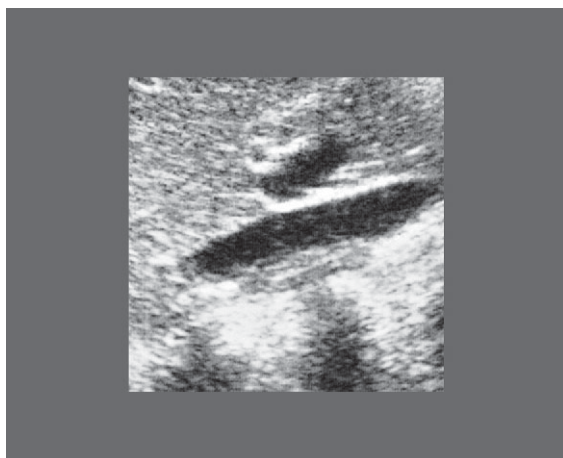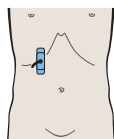


The left adrenal gland often extends relatively far downward toward the renal hilum.

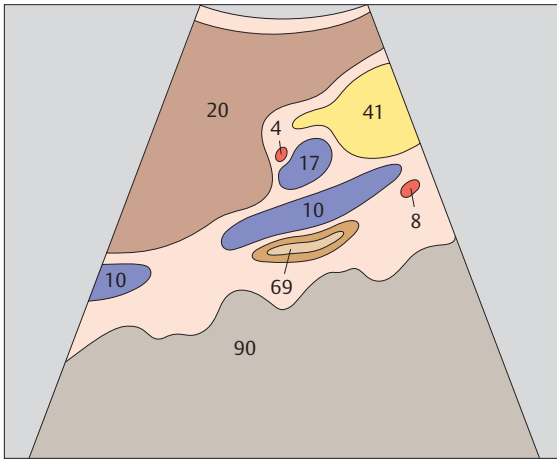




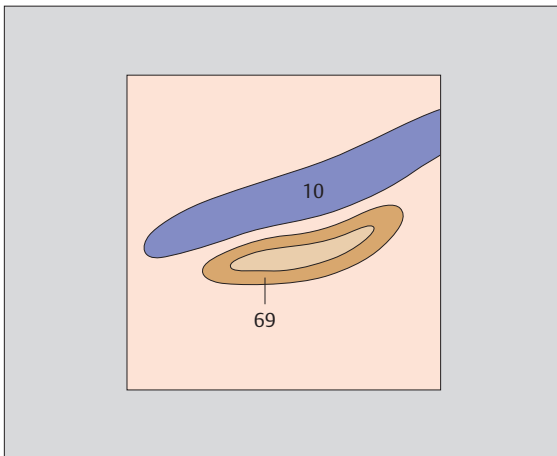
▶ 189 Layers of adrenal gland



▶ 190 Layers of adrenal gland



The adrenal gland is seen to consist of three layers: two echodense outer layers and a hypoechoic middle layer.



The adrenal cortex is hypoechoic, and the medulla is hyperechoic.



8 Stomach

Upper Abdominal Transverse Scans of the Gastric Cardia from Above Downward

- 191 Esophagus, aorta, liver
- 192 Cardia, aorta, liver
- 193 Cardia, body of stomach, aorta, liver
- 194 Body of stomach, aorta, liver

Upper Abdominal Longitudinal Scans of the Stomach from Right to Left

- 195 Esophagus, aorta, liver
- 196 Esophagus, aorta, liver
- 197 Cardia, liver
- 198 Body of stomach, liver

Upper Abdominal Longitudinal Scans of the Stomach from Left to Right

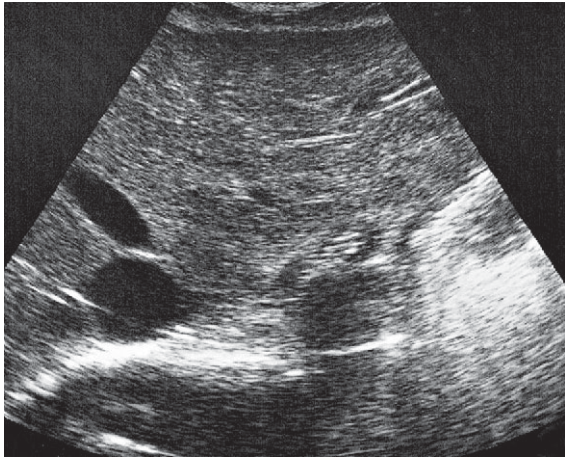
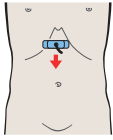
- 199 Body of stomach, liver
- 200 Antrum, liver, pancreas
- 201 Antrum, liver, pancreas
- 202 Pylorus, pancreas, liver
- 203 Duodenal bulb, liver, vena cava
- 204 Duodenum, gallbladder, vena cava

Upper Abdominal Transverse Scans of the Antrum and Duodenum from Above Downward

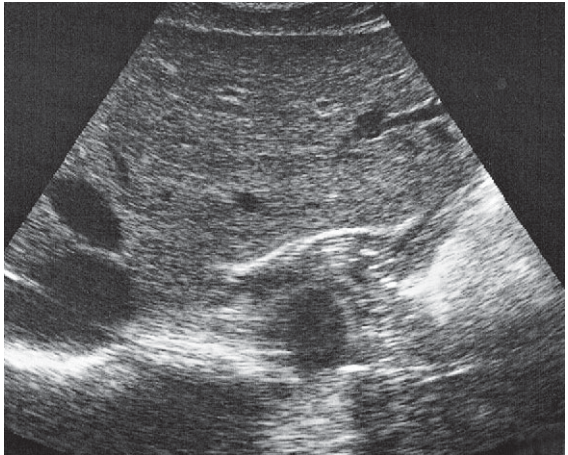
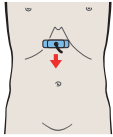
- 205 Antrum, liver, pancreas
- 206 Antrum, duodenum, liver, pancreas, gallbladder
- 207 Antrum, duodenum, liver, pancreas, gallbladder
- 208 Antrum, gallbladder

Details of the Stomach

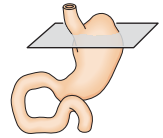
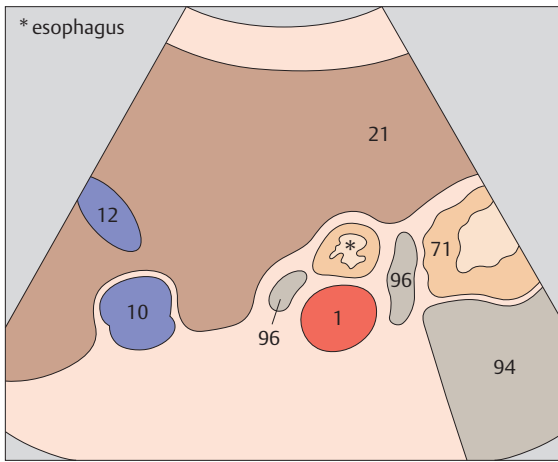
- 209 Layers of gastric wall
- 210 Layers of gastric wall
- 211 Gastric folds
- 212 Gastric folds



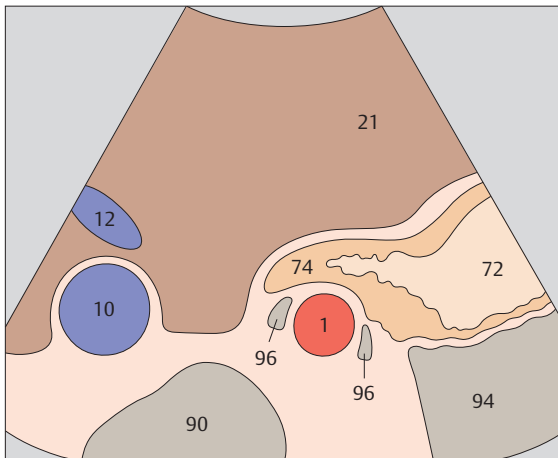
▶ 191 Esophagus, aorta, liver



▶ 192 Cardia, aorta, liver

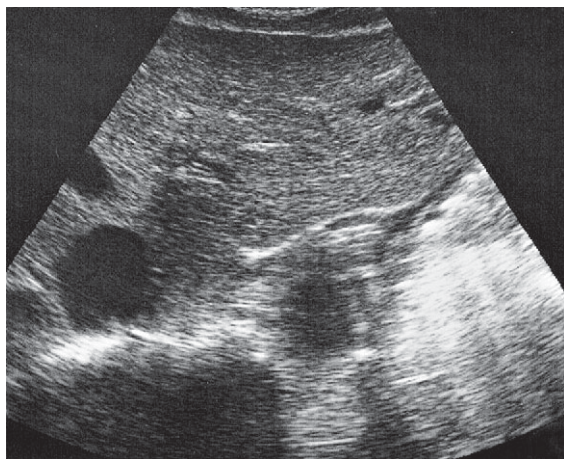
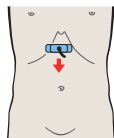
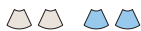

The gastroesophageal junction is identified between the liver, aorta, and diaphragmatic crura.

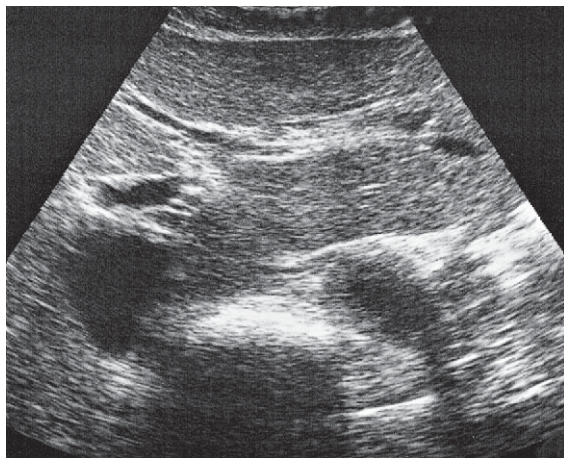
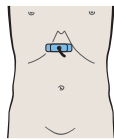


The cardia displays a typical pointed, triangular shape in transverse section.

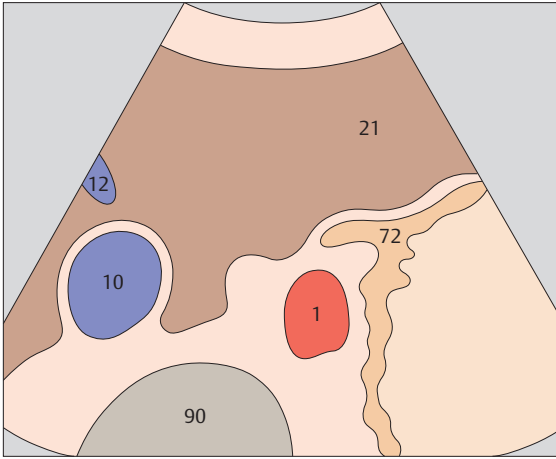




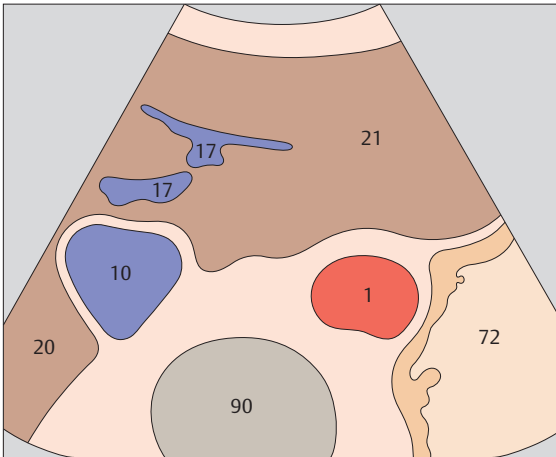
▶ 193 Cardia, body of stomach, aorta, liver



▶ 194 Body of stomach, aorta, liver

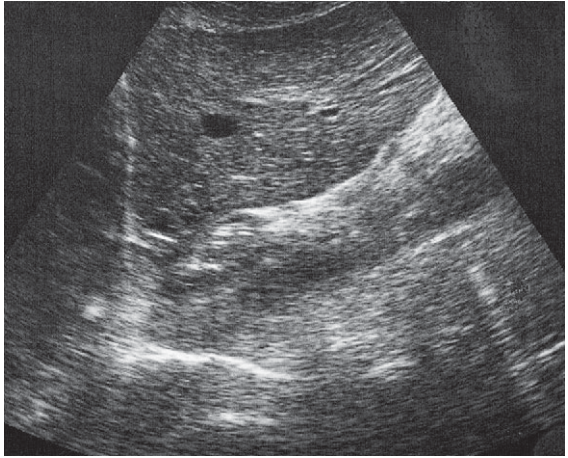
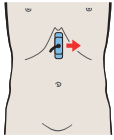
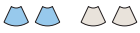

The cardia adjoins the body of the stomach, which presents a seemingly chaotic pattern of solid, liquid, and gaseous contents.

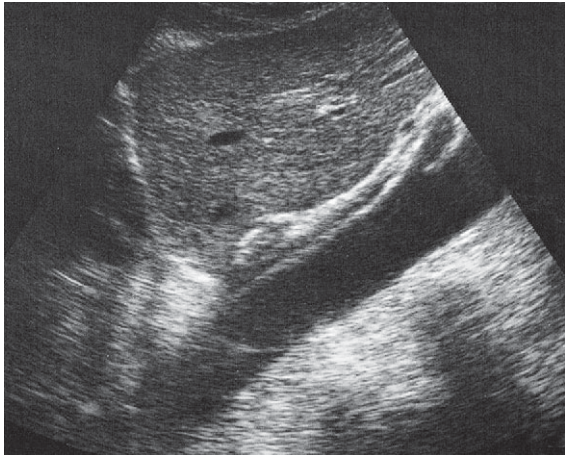
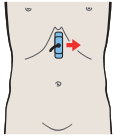


Below the cardia, the body of the stomach lies against the aorta.

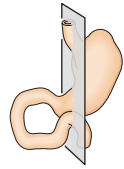
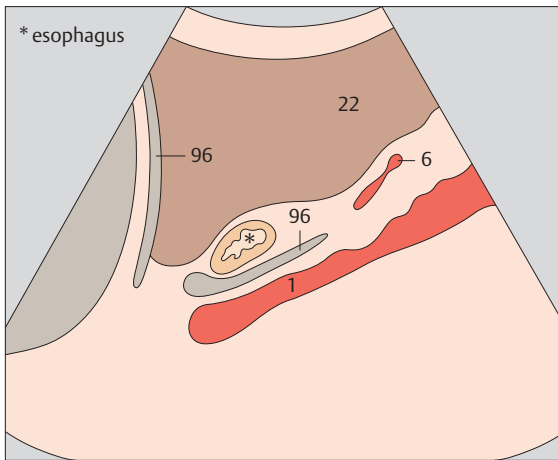




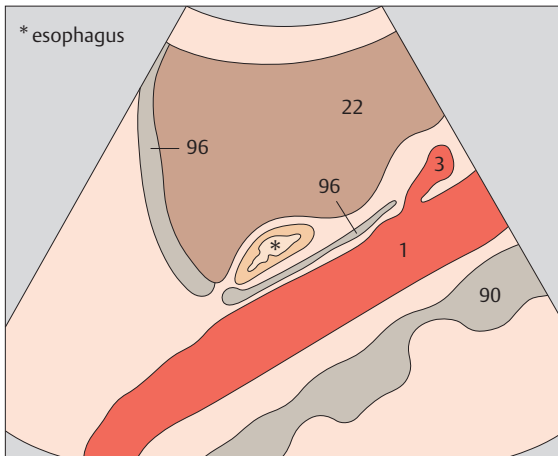
▶ 195 Esophagus, aorta, liver



▶ 196 Esophagus, aorta, liver

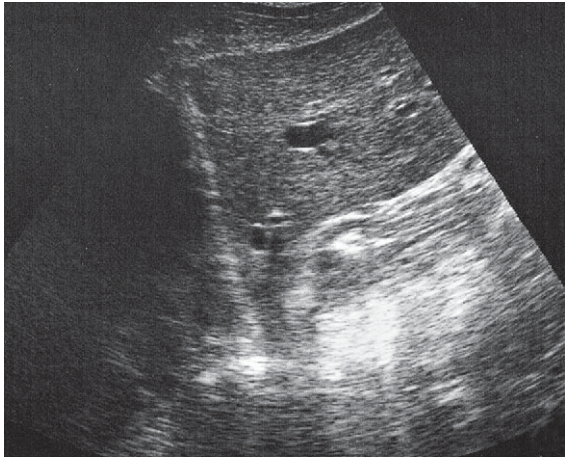
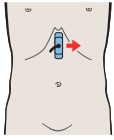
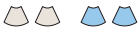

The abdominal esophagus is identified just anterior and to the right of the aorta.

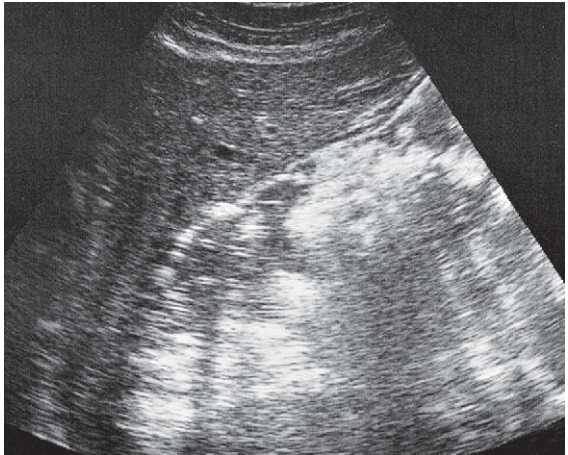
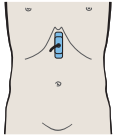


The esophagus and the cardia are located between the liver and aorta in the upper abdominal longitudinal scan.

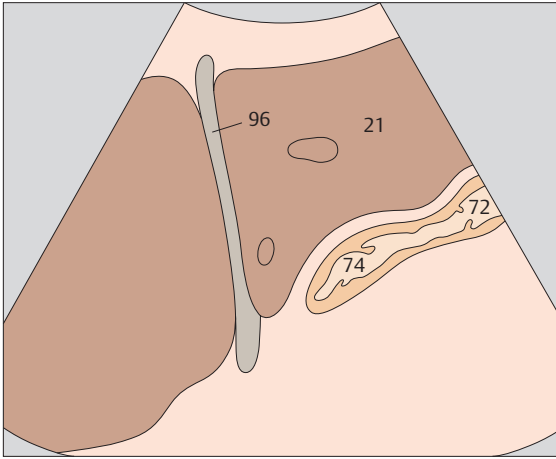




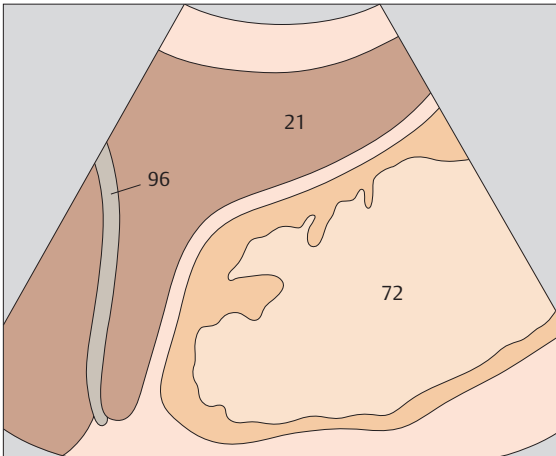
▶ 197 Cardia, liver



▶ 198 Body of stomach, liver

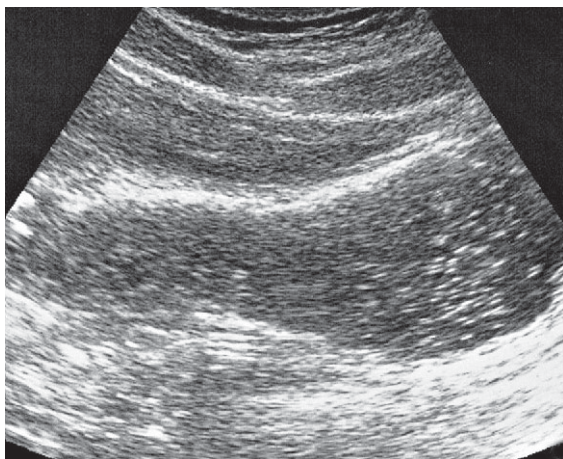
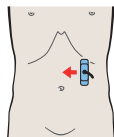
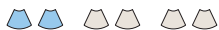

The first step in identifying the cardia and body of the stomach is to demonstrate the gastroesophageal junction.

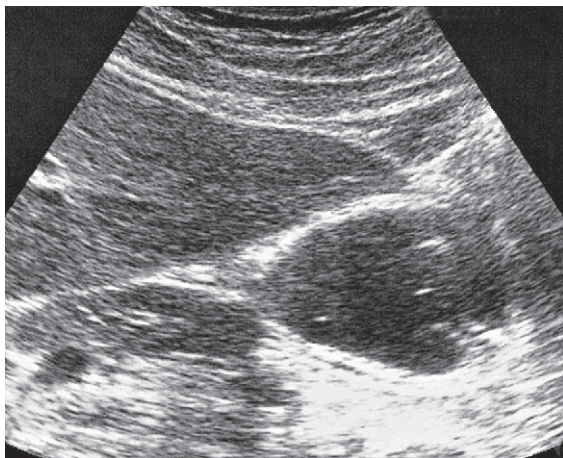
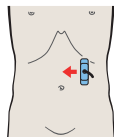


Without special patient preparation, the body of the stomach produces a heterogeneous echo pattern posterior to the left lobe of the liver.

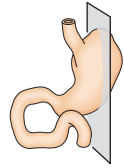
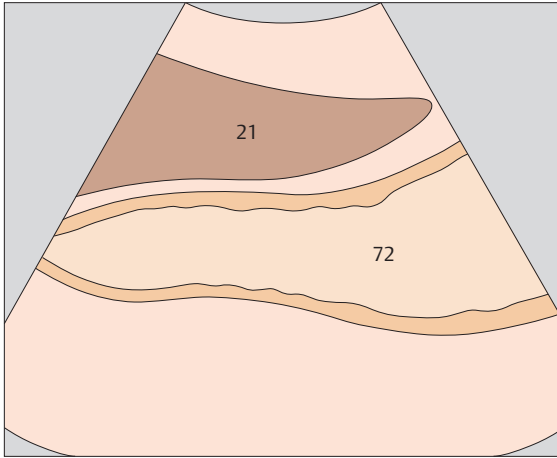




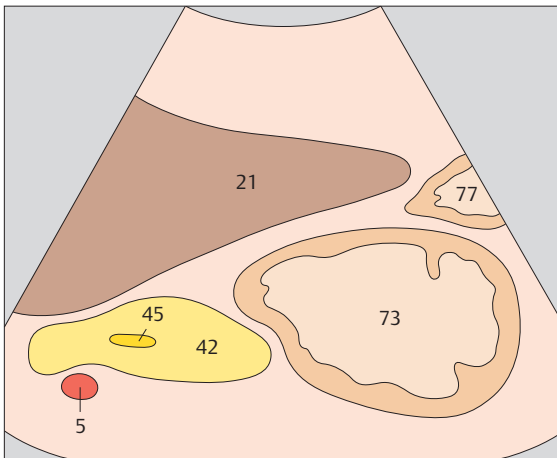
▶ 199 Body of stomach, liver



▶ 200 Antrum, liver, pancreas

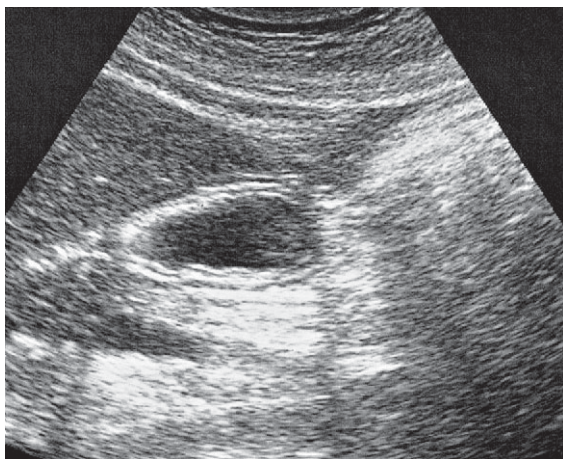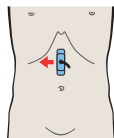

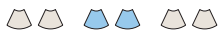
The body of the stomach is consistently located behind the left lobe of the liver. It may be fluid-filled and clearly defined, or empty and difficult to identify.

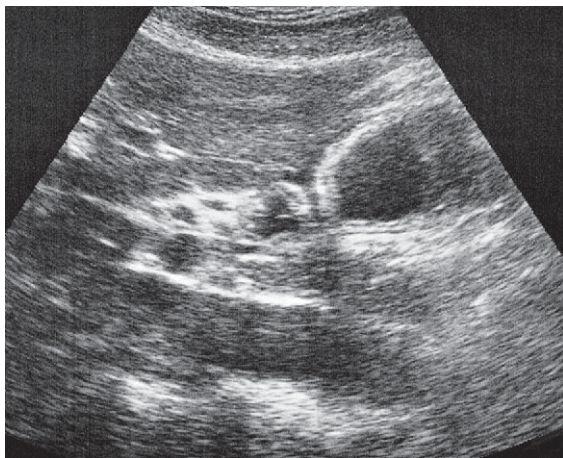
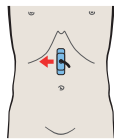


A longitudinal scan through the upper midabdomen demonstrates the characteristic triad of stomach, liver, and pancreas.

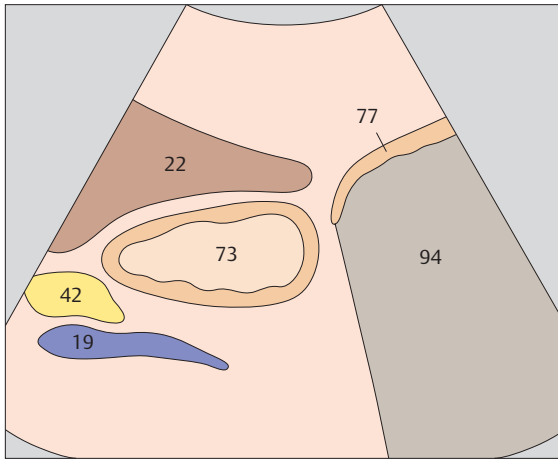




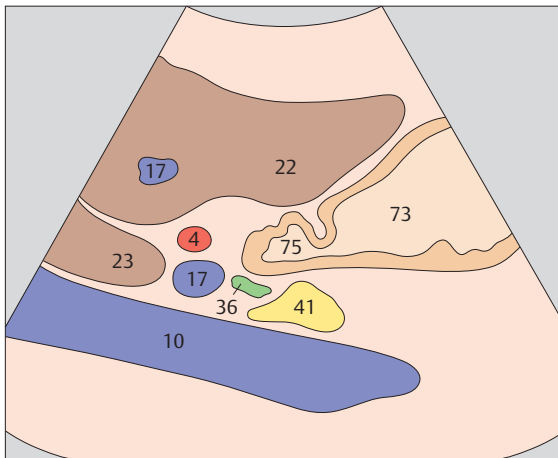
▶ 201 Antrum, liver, pancreas



▶ 202 Pylorus, pancreas, liver

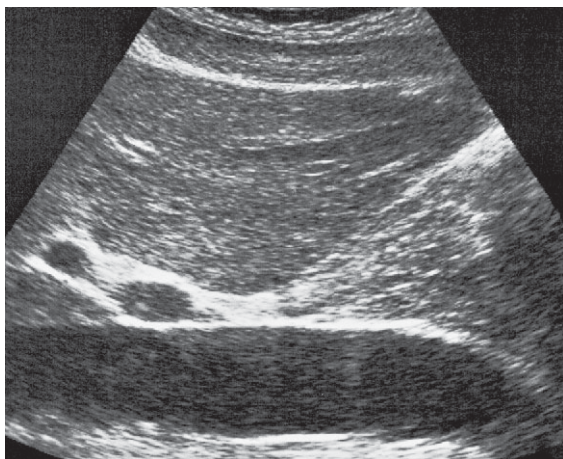
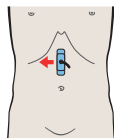
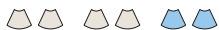

The typical target pattern of the gastric antrum is best appreciated in a longitudinal scan at the inferior border of the liver.

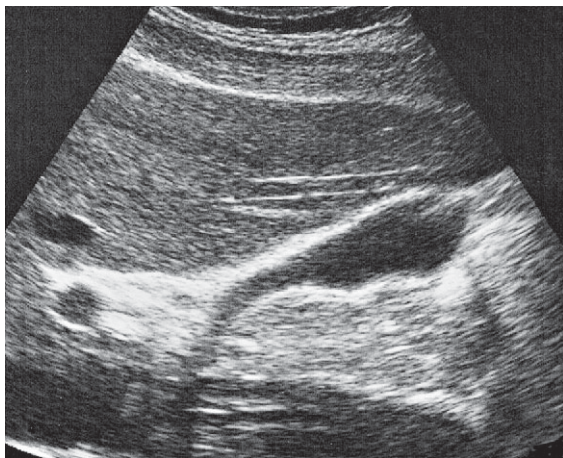
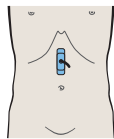


The pylorus is characterized by a marked thickening of the muscular coat anterior to the head of the pancreas.

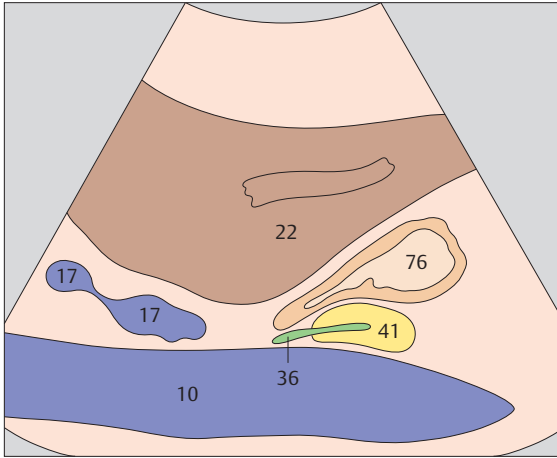




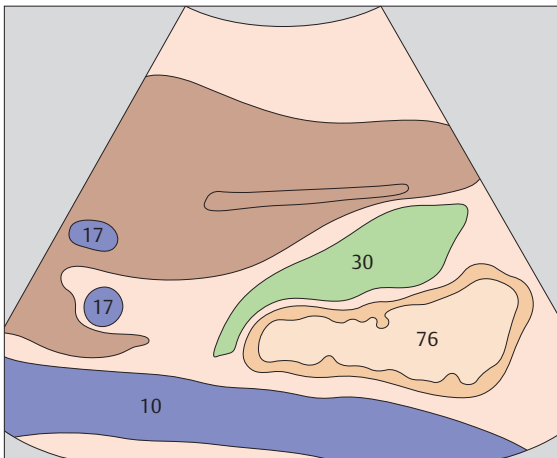
▶ 203 Duodenal bulb, liver, vena cava



▶ 204 Duodenum, gallbladder, vena cava

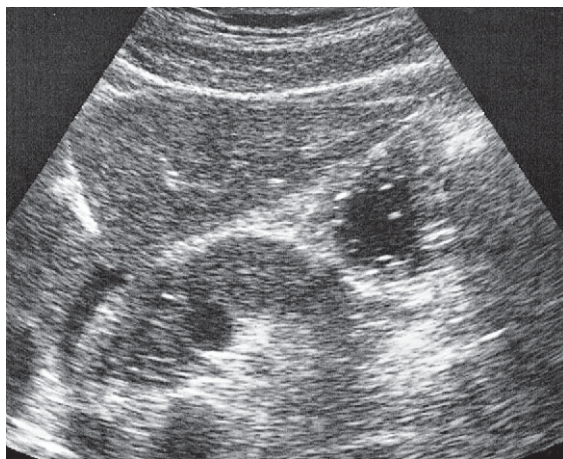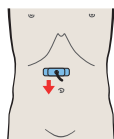


The duodenal bulb runs laterally upward and backward before joining the second part of the duodenum.

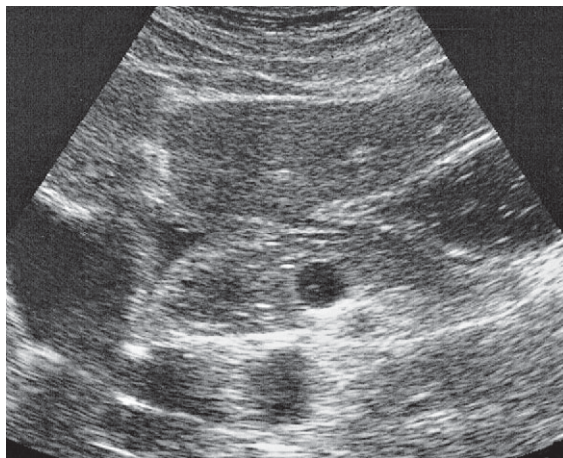
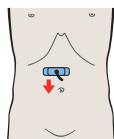


The second part of the duodenum is displayed posterior to the gallbladder.

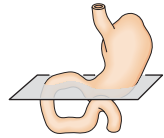
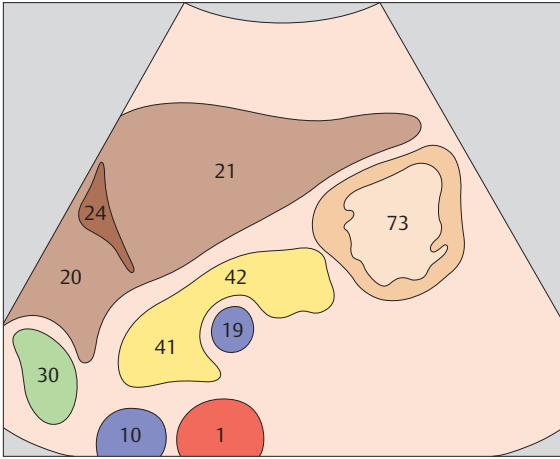




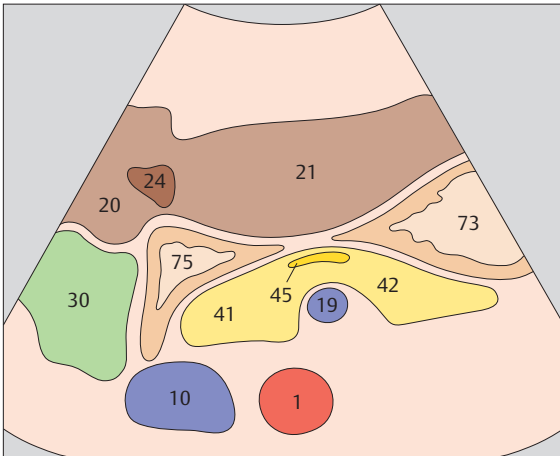
▶ 205 Antrum, liver, pancreas



▶ 206 Antrum, duodenum, liver, pancreas, gallbladder

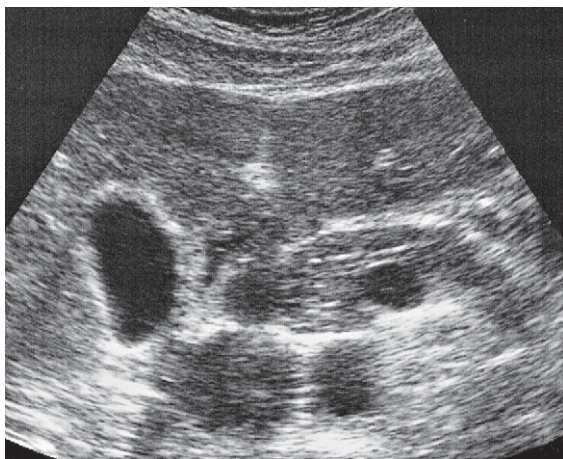
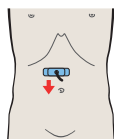


The pancreas lies against the posterior surface of the stomach.

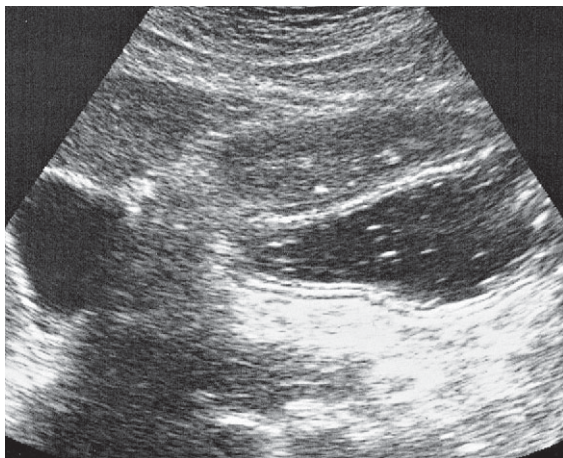
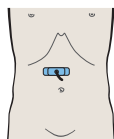


The antrum extends to the right, coming between the pancreas and liver. It is difficult to visualize at that location.

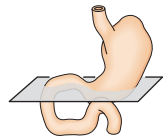
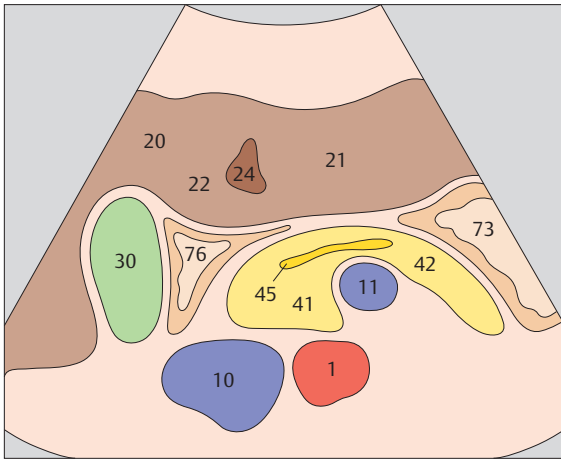




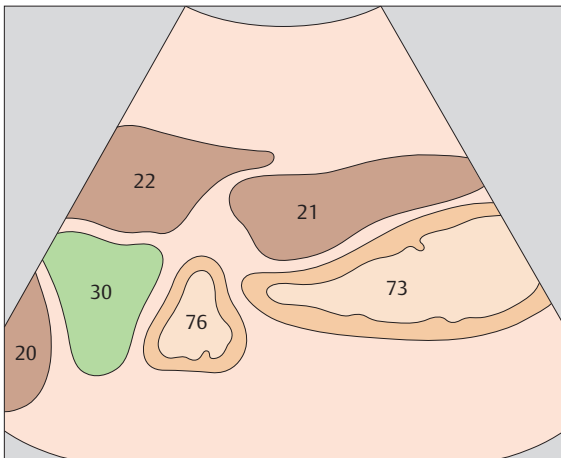
► 207 Antrum, duodenum, liver, pancreas, gallbladder



► 208 Antrum, gallbladder

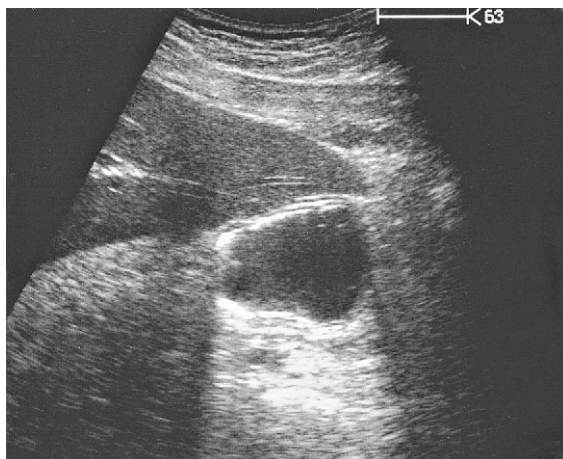
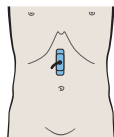


The second part of the duodenum lies between the liver, gallbladder, vena cava, and head of pancreas.

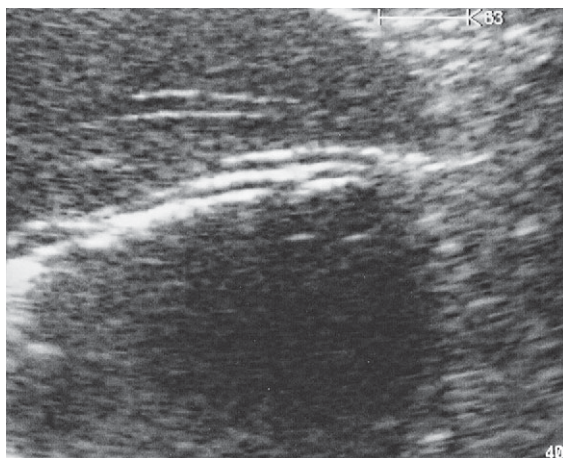
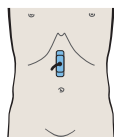


The antrum often extends quite far downward, especially when the stomach is full and the subject is standing upright.

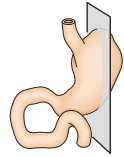
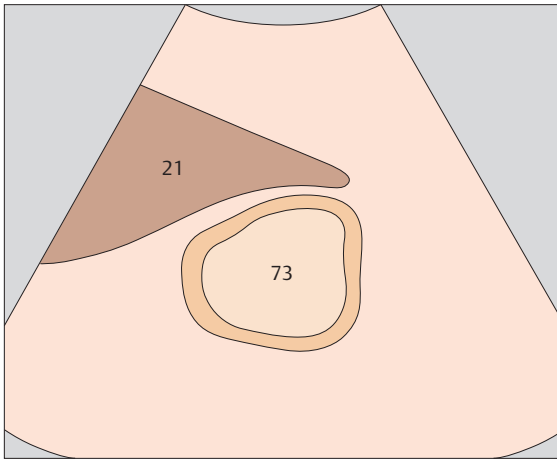




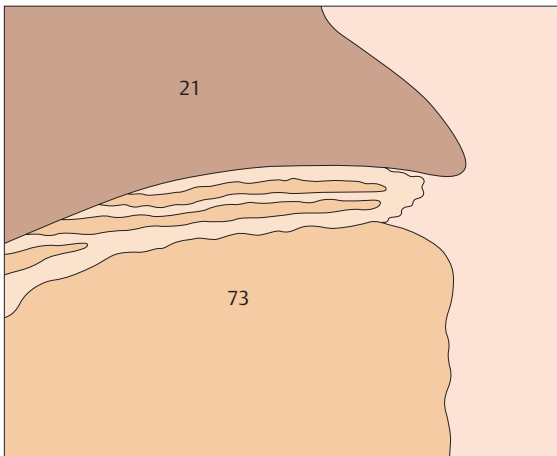
▶ 209 Layers of gastric wall



▶ 210 Layers of gastric wall

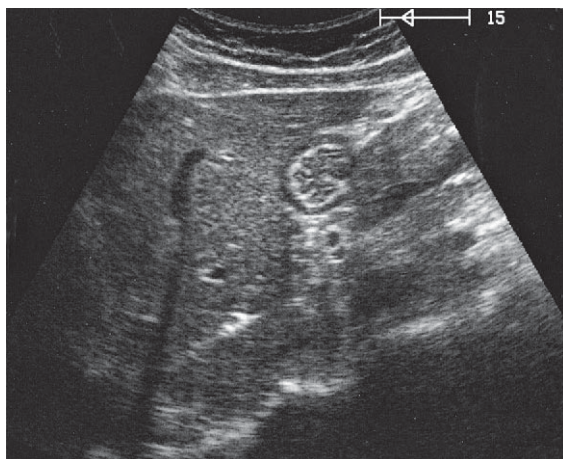
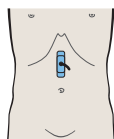


With a high-resolution device and favorable scanning conditions, five layers can be distinguished in the gastric wall.

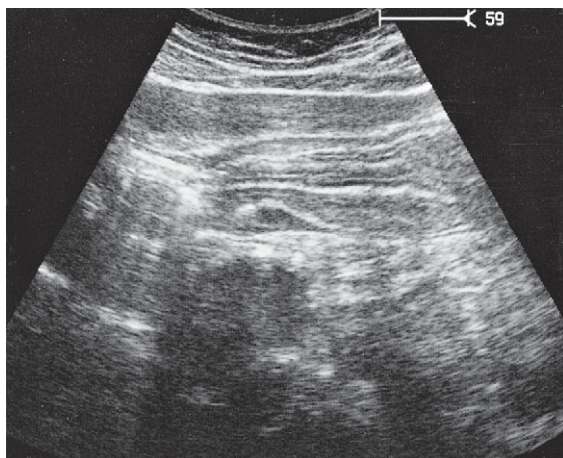
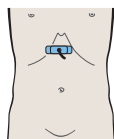


A scan through the antrum is best for differentiating the layers of the gastric wall.

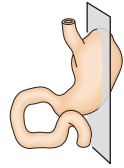
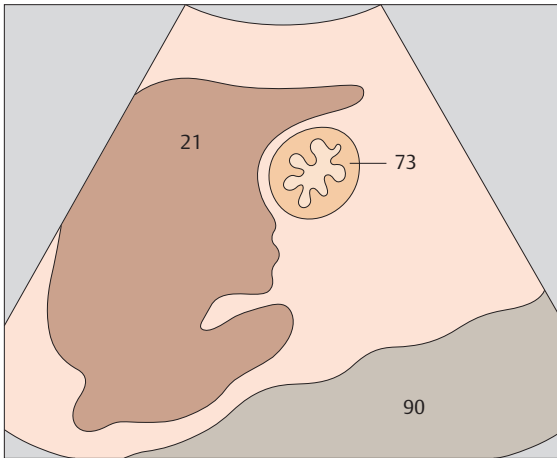




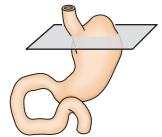
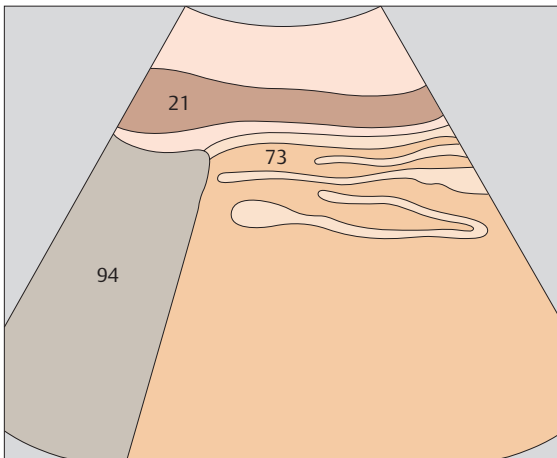
▶ 211 Gastric folds



▶ 212 Gastric folds



The rugal folds of the stomach are demonstrated most clearly in the fasted state.



In an upper abdominal transverse scan, the gastric folds produce a confusing pattern in which numerous wall layers are seen.



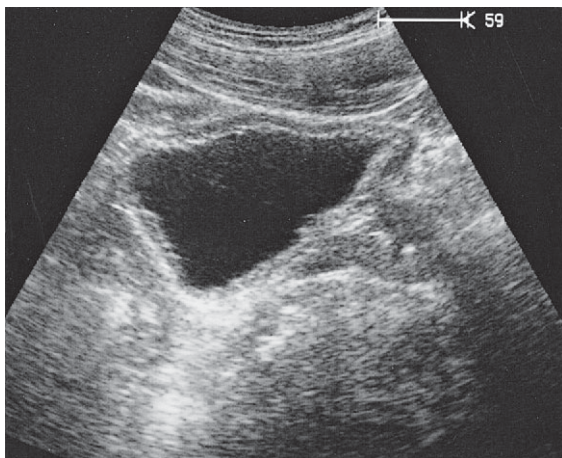
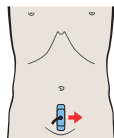
9 Bladder

Bladder in Longitudinal Sections

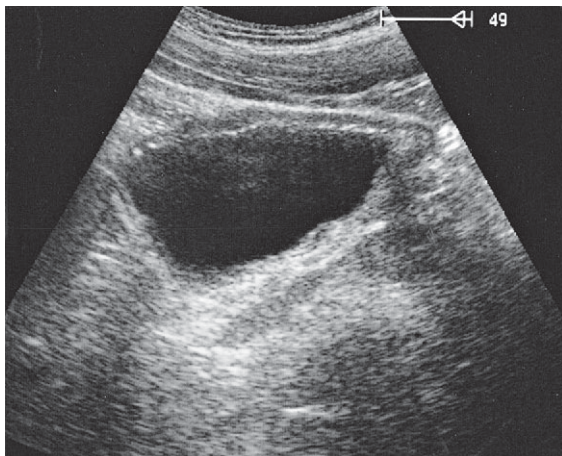
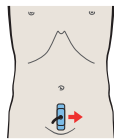
- 213** Bladder, prostate, rectum
- 214** Bladder, ureteral orifice, prostate, rectum
- 215** Bladder, rectum
- 216** Bladder, bowel

Details of the Bladder

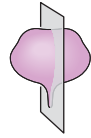
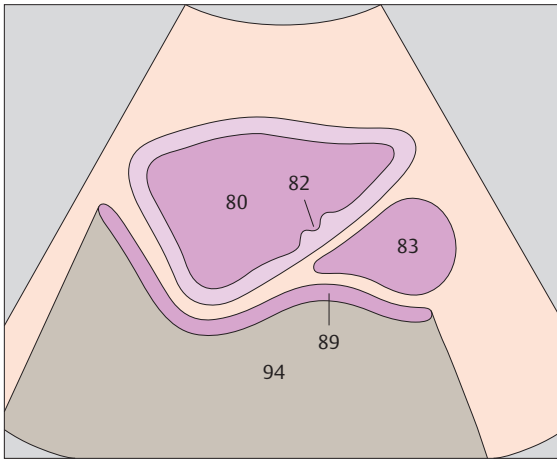
- 217** Bladder, ureteral orifices
- 218** Bladder, inflow of urine



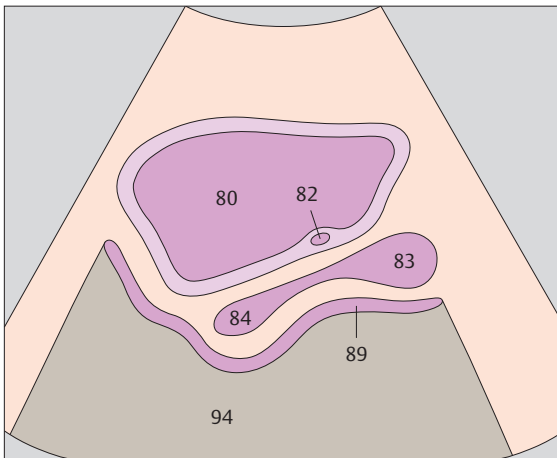
▶ 213 Bladder, prostate, rectum



▶ 214 Bladder, ureteral orifice, prostate, rectum

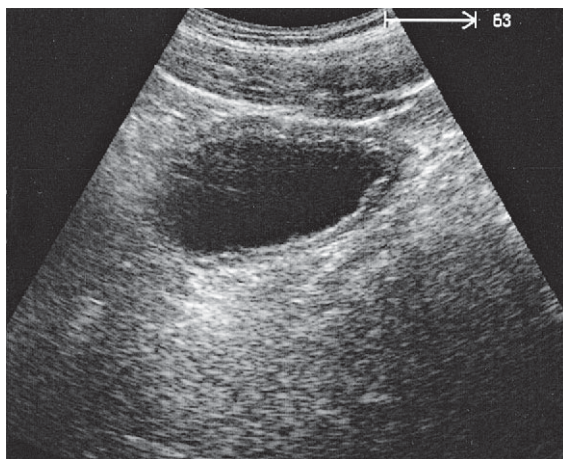
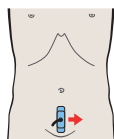


The full bladder appears in longitudinal section as a triangular structure devoid of internal echoes.

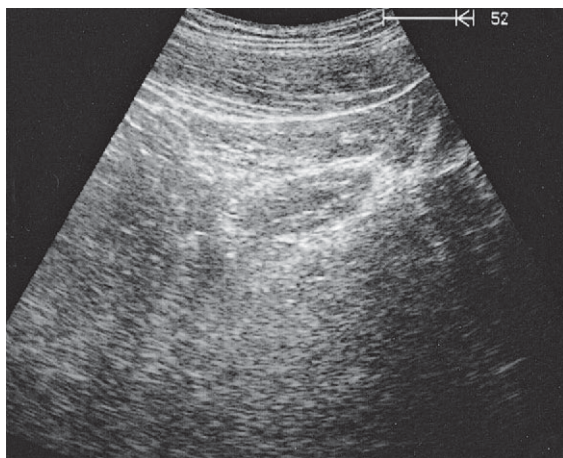
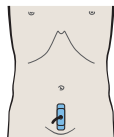


The internal genitalia are seen posterior to the bladder in the midsagittal scan.

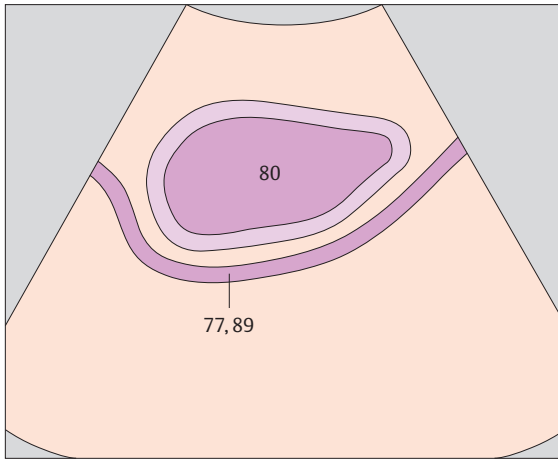




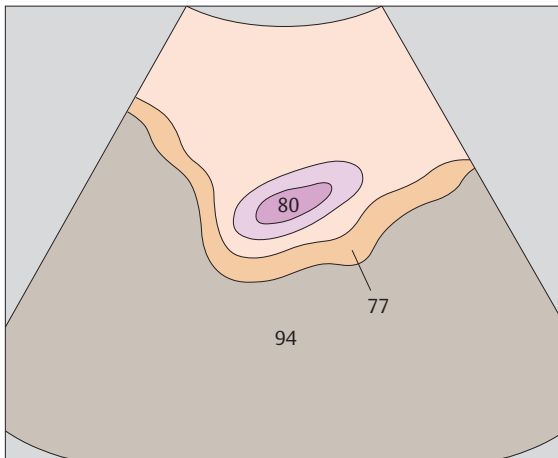
▶ 215 Bladder, rectum



▶ 216 Bladder, bowel

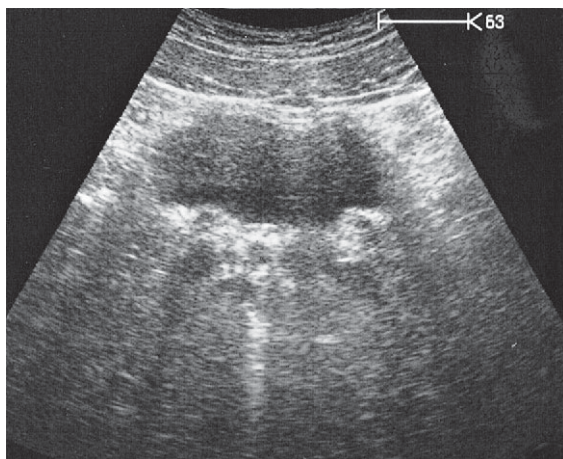
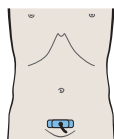


The anterior wall of the bladder is loosely attached to the anterior abdominal wall by the vesicourethral fascia. This keeps gas-containing bowel loops from coming between the abdominal wall and the anterior surface of the full bladder.

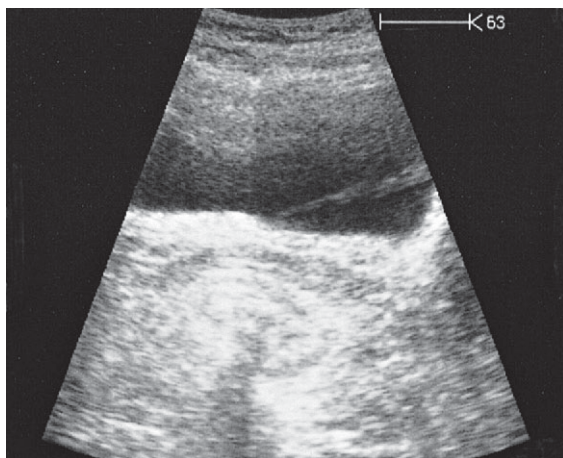
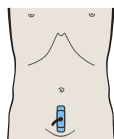


Bowel loops containing gas are seen posterior to the bladder in the lateral scan.

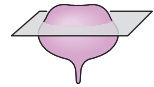
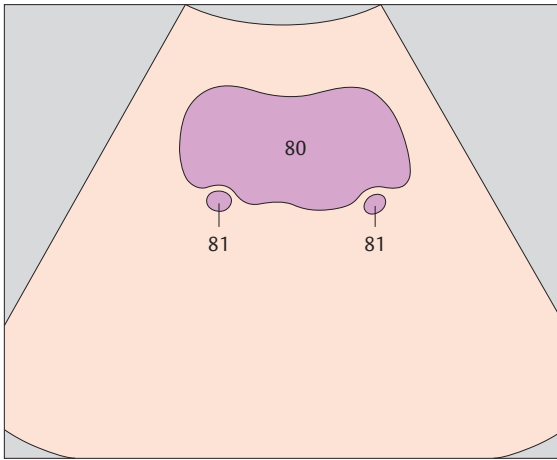




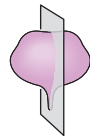
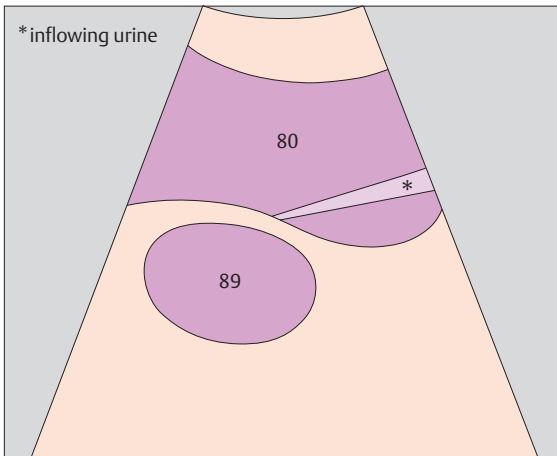
▶ 217 Bladder, ureteral orifices



▶ 218 Bladder, inflow of urine



The ureters appear as fine tubular structures in the posterior bladder wall.



Ultrasound can often demonstrate urine flowing into the bladder from a ureteral orifice.



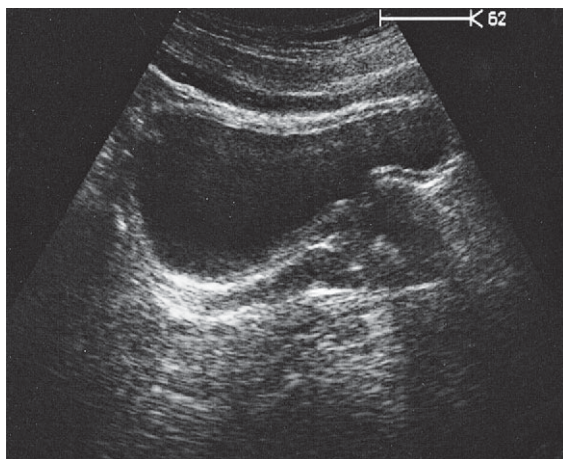
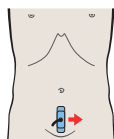
10 Prostate

Prostate in Longitudinal Sections

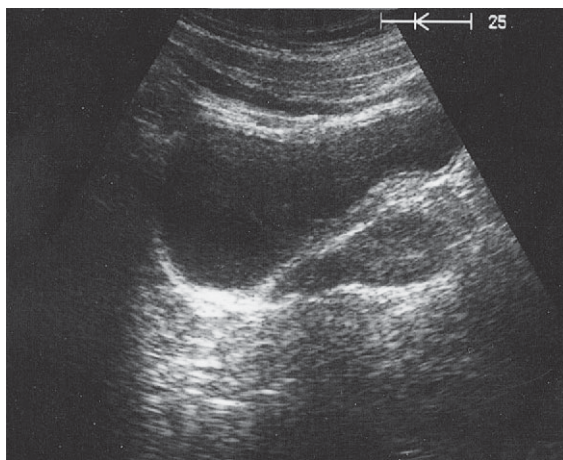
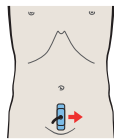
- 219** Prostate, rectum, bladder
- 220** Prostate, rectum, bladder
- 221** Prostate, seminal vesicles
- 222** Prostate, seminal vesicles

Prostate in Transverse Sections

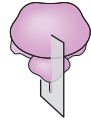
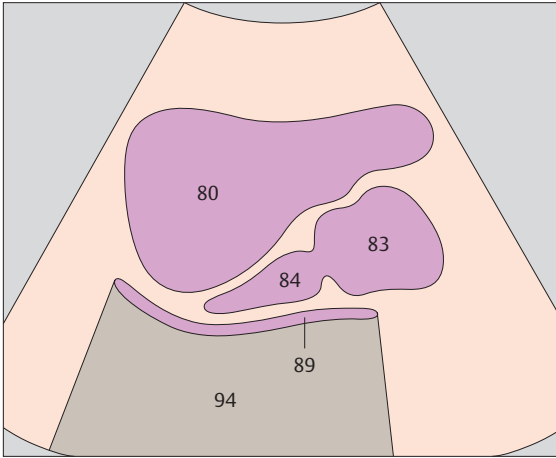
- 223** Prostate, urethra, bladder
- 224** Prostate, urethra, bladder
- 225** Prostate, bladder
- 226** Seminal vesicles, bladder



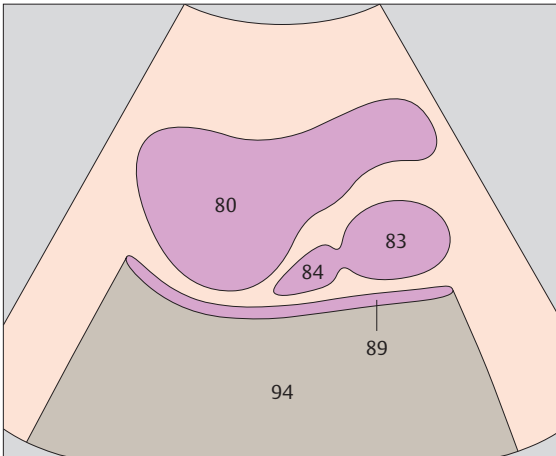
▶ 219 Prostate, rectum, bladder



▶ 220 Prostate, rectum, bladder

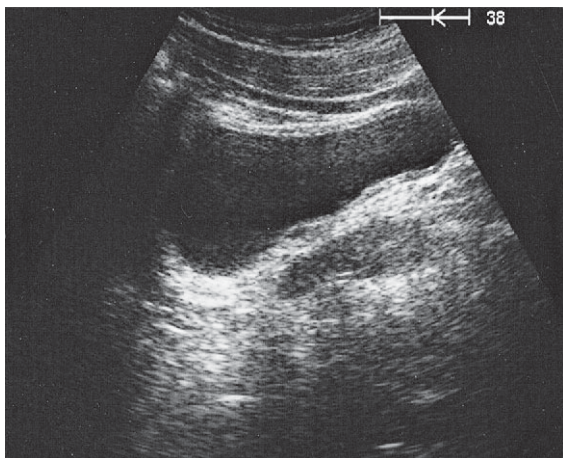
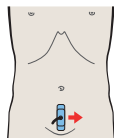


The prostate appears onion-shaped in longitudinal section.

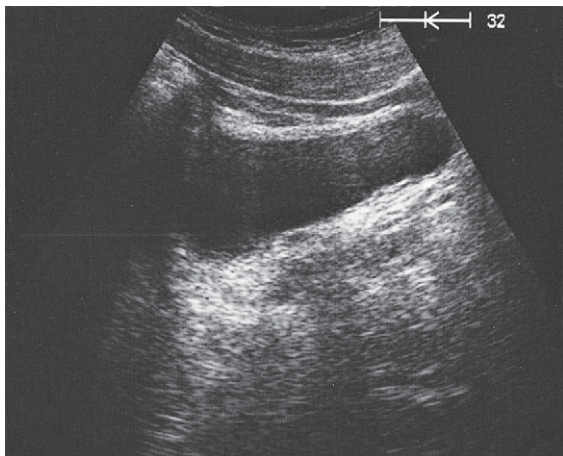
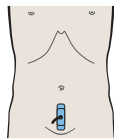


Behind the prostate is the rectum, usually appearing as a gas-filled structure.

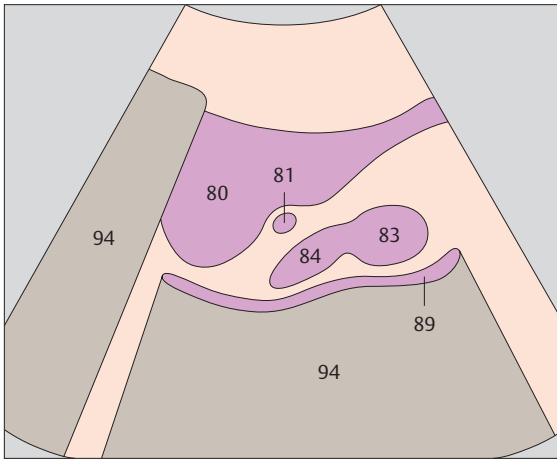




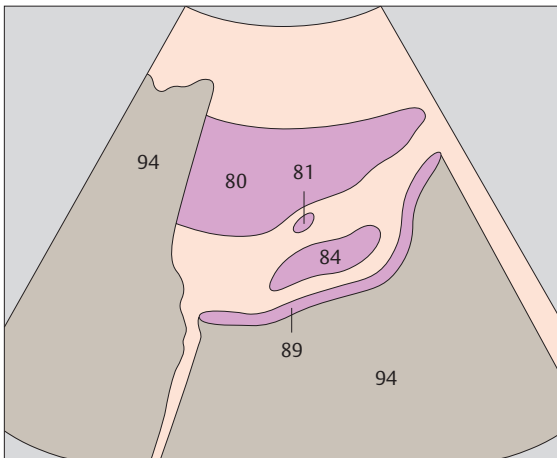
▶ 221 Prostate, seminal vesicles



▶ 222 Prostate, seminal vesicles

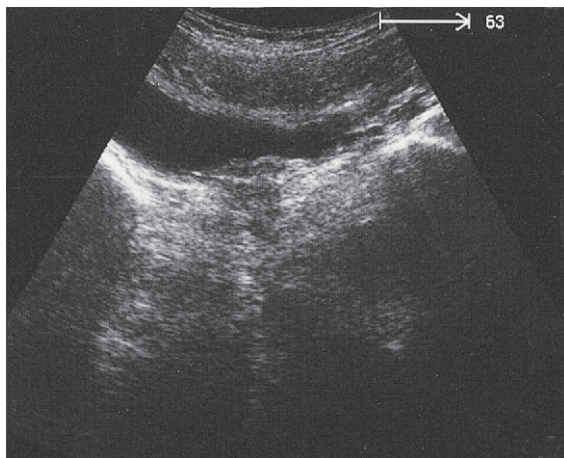
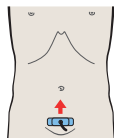


The seminal vesicles are in contact with the bladder over their entire length.

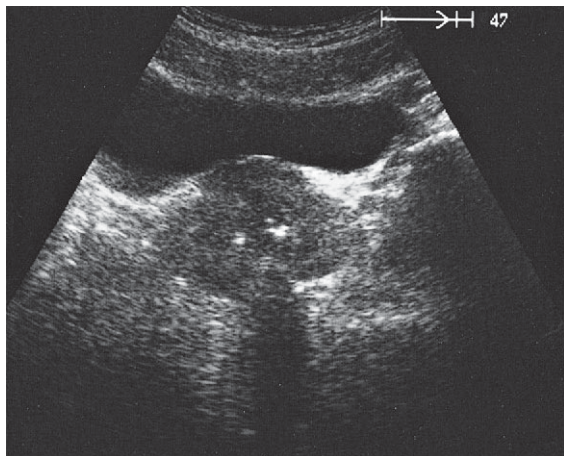
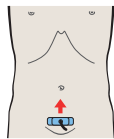


The seminal vesicles are located lateral and cranial to the prostate.

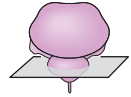
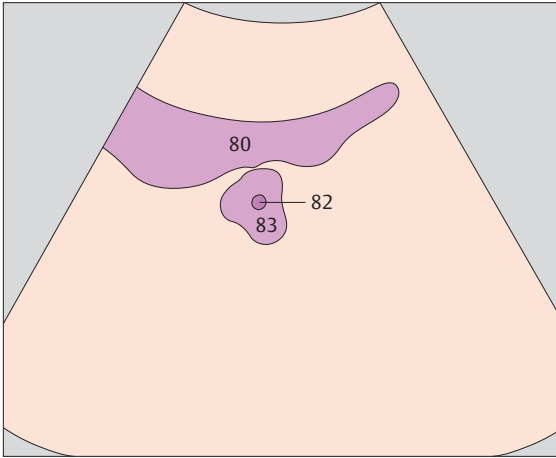




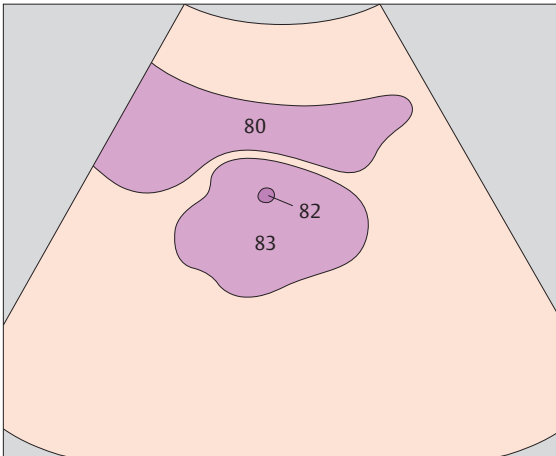
▶ 223 Prostate, urethra, bladder



▶ 224 Prostate, urethra, bladder

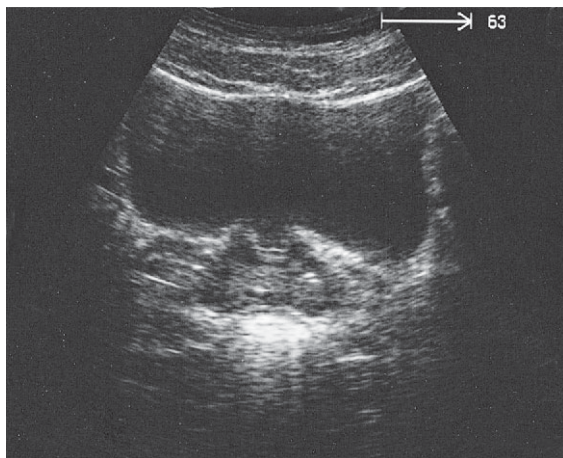
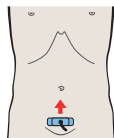


The urethra can be identified as a hypoechoic round structure within the prostate.

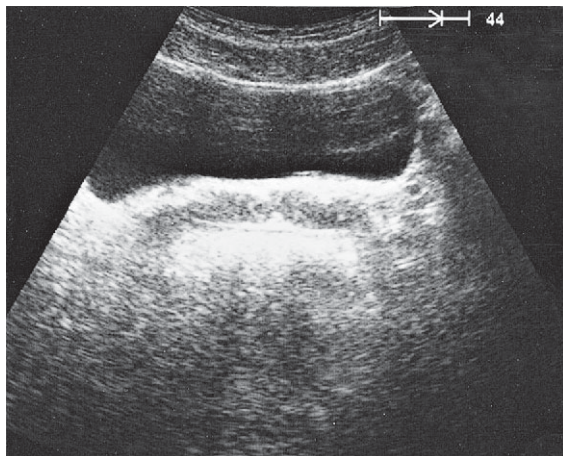
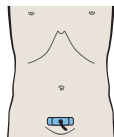


The prostate presents an oval, chestnut-like shape in cross section.

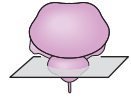
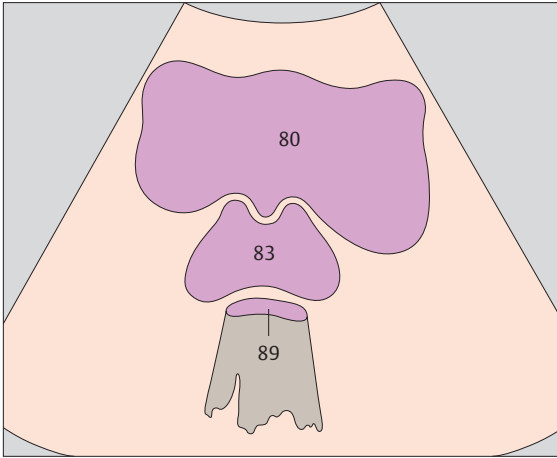




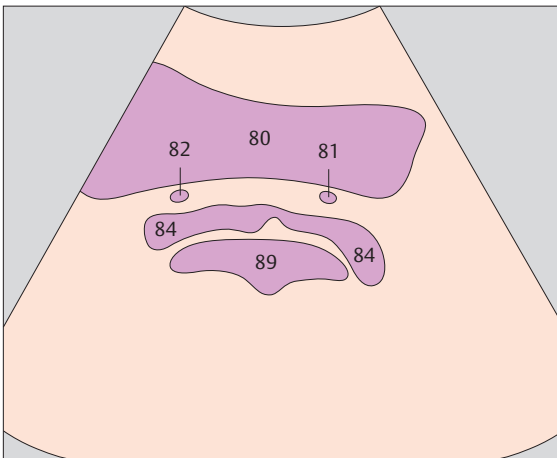
▶ 225 Prostate, bladder



▶ 226 Seminal vesicles, bladder



The middle lobe of the prostate with the urethral orifice may protrude somewhat into the bladder.



The seminal vesicles, around 5 cm long and 1 cm thick, can be seen on the posterior wall of the bladder.



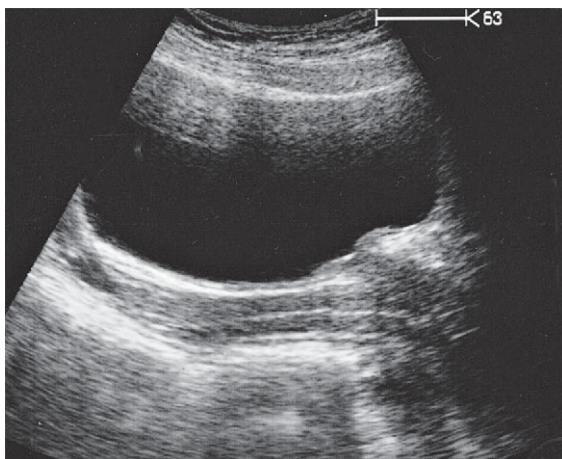
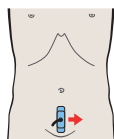
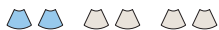11 Uterus

Uterus in Longitudinal Sections

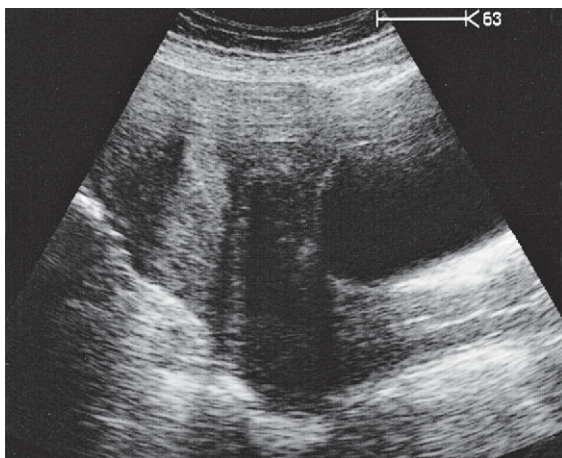
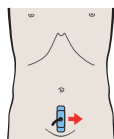
- 227** Vagina, bladder
- 228** Vagina, uterus, bladder
- 229** Vagina, uterus, bladder
- 230** Uterus, bladder
- 231** Uterus, ovary, bladder
- 232** Bladder, ovary

Uterus in Transverse Sections

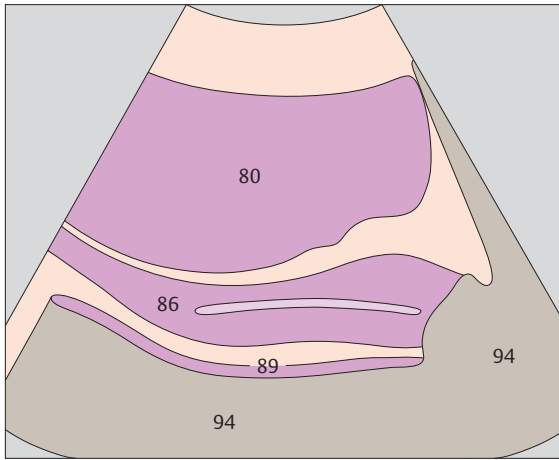
- 233** Vagina, bladder, rectum
- 234** Uterus, bladder, rectum
- 235** Uterus, bladder, rectum, ovary
- 236** Uterus, bladder, rectum, ovaries



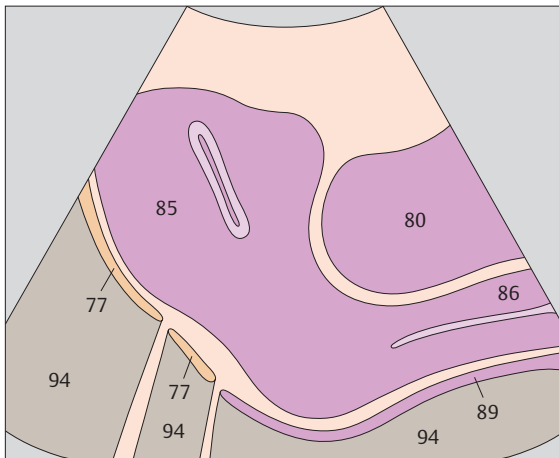
▶ 227 Vagina, bladder



▶ 228 Vagina, uterus, bladder

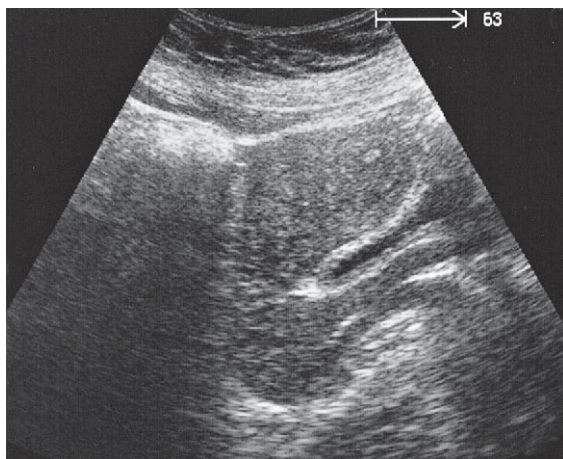
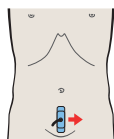
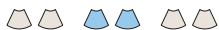

The vagina appears posterior to the bladder as an elongated, hypoechoic structure with a more echogenic central band.

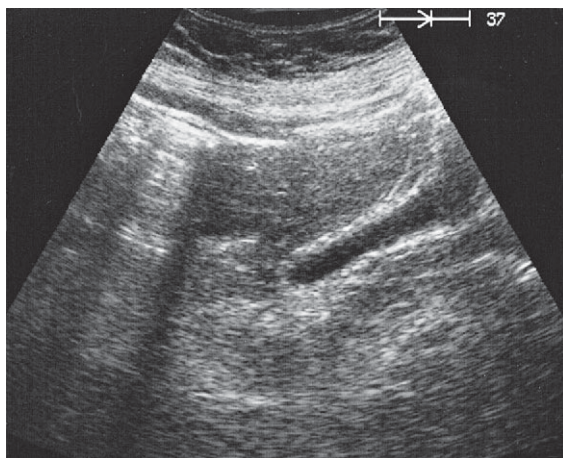
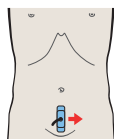


The uterine cavity can be visualized with ultrasound only during menstruation or pregnancy.

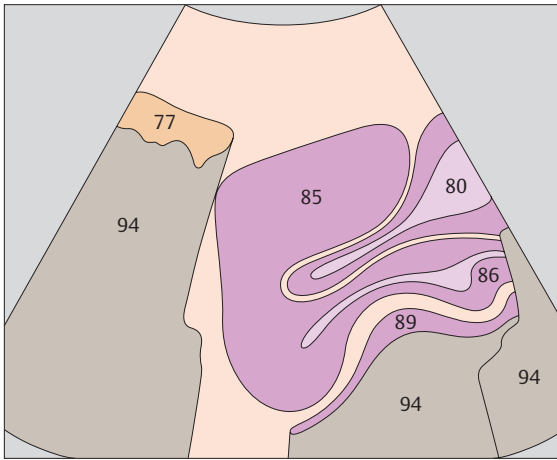




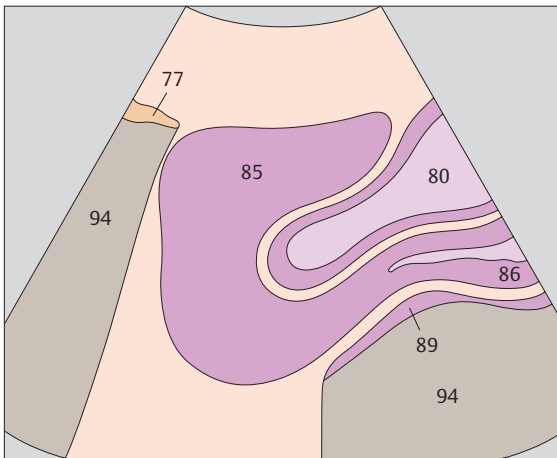
▶ 229 Vagina, uterus, bladder



▶ 230 Uterus, bladder

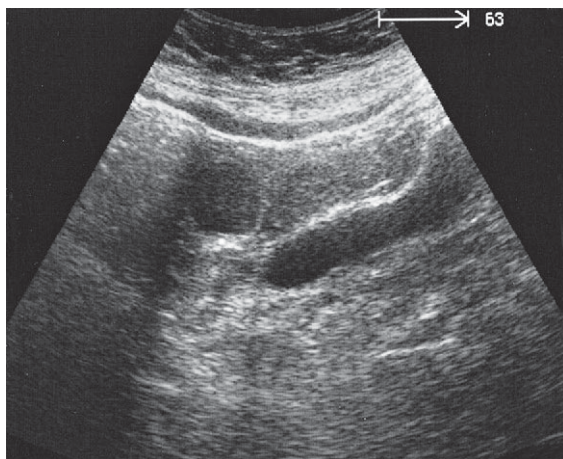
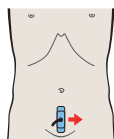
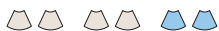

The uterus is seen to consist of a fundus, corpus, and cervix.

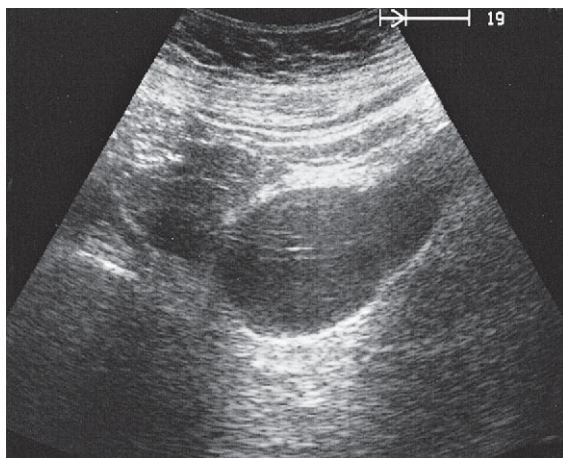
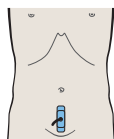


In most cases the uterus is anteflexed and is located cranial and posterior to the bladder, lying between it and the rectum and small bowel. The uterine corpus merges at a variable angle with the cervix, which widens slightly in its vaginal portion.

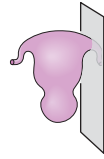
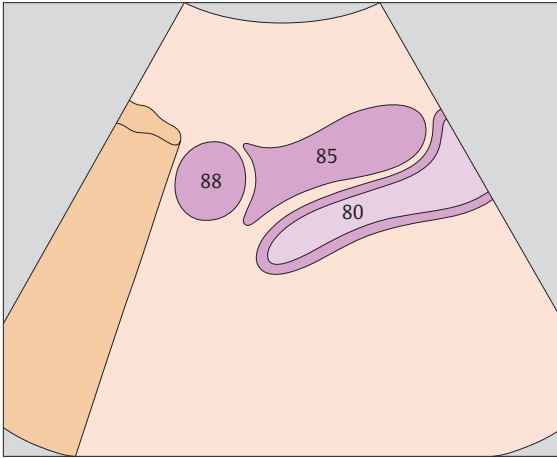




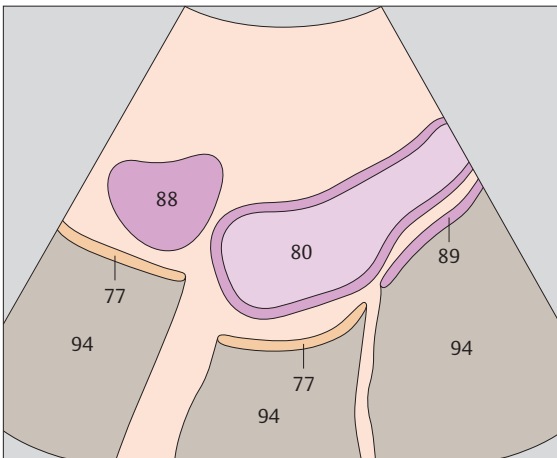
▶ 231 Uterus, ovary, bladder



▶ 232 Bladder, ovary

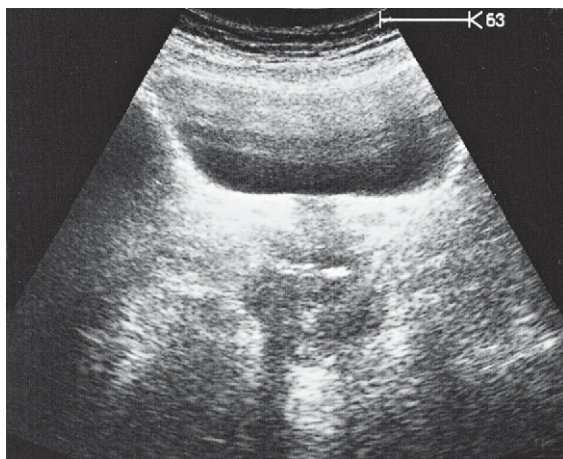
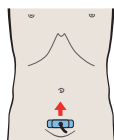


As the scan moves laterally across the uterus, the ovary comes into view at its superior border.

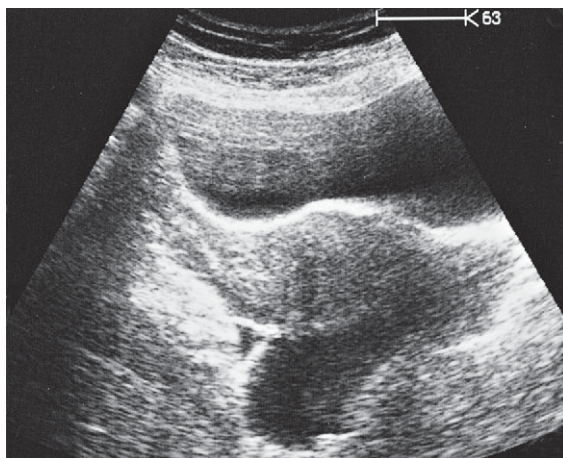
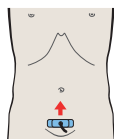


The ovaries are situated laterally at the upper edge of the full bladder.

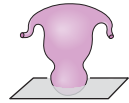
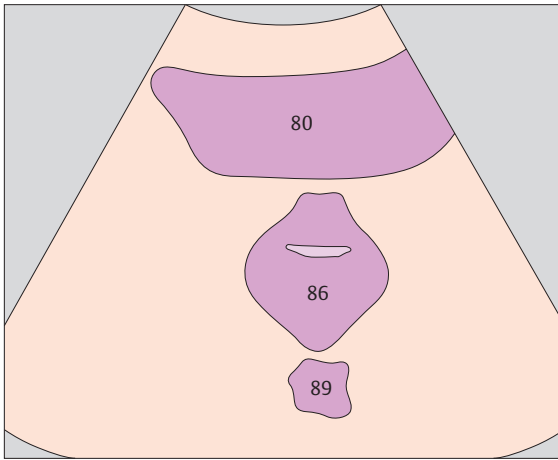




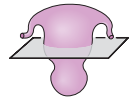
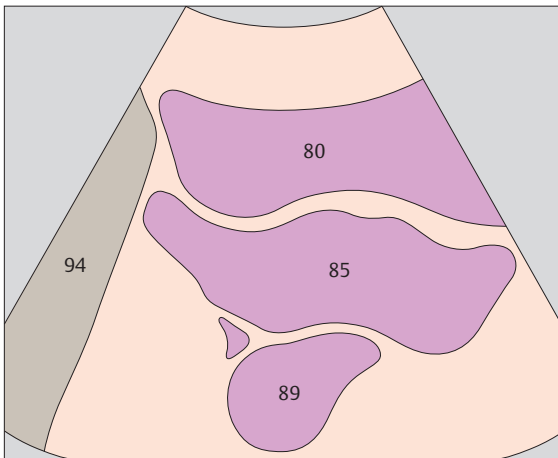
▶ 233 Vagina, bladder, rectum



▶ 234 Uterus, bladder, rectum

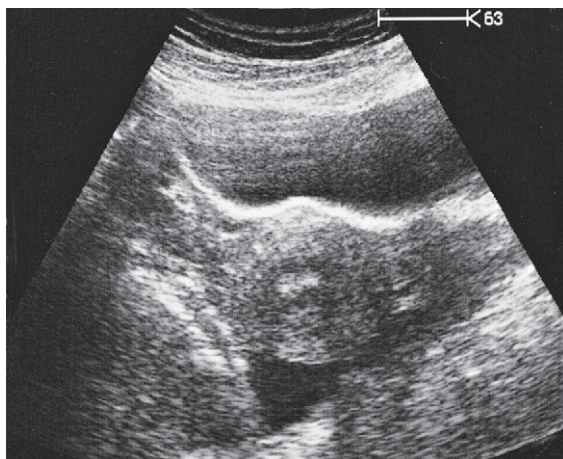
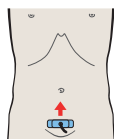


The vagina displays a streak-like lumen in cross section.

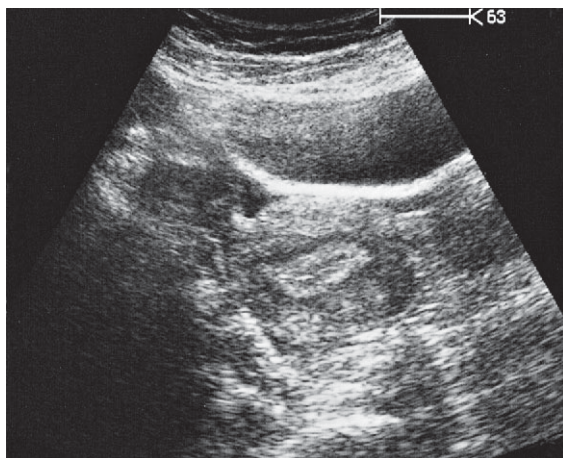
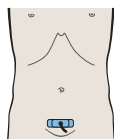


A transverse scan of the female pelvis displays the following structures, from front to back: the bladder, vesicouterine pouch, uterus, and rectum.

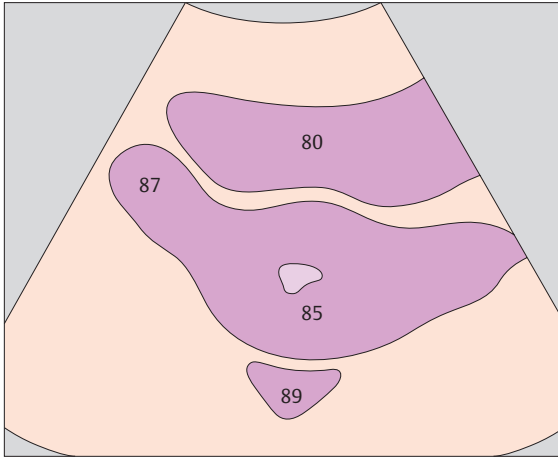




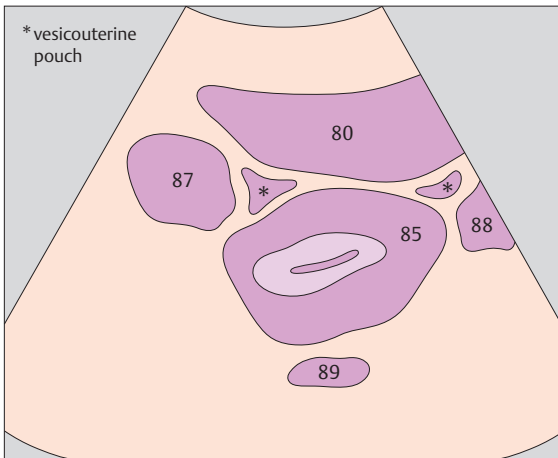
▶ 235 Uterus, bladder, rectum, ovary



▶ 236 Uterus, bladder, rectum, ovaries



The ovaries are usually found lateral to the uterus, at the level of the uterine corpus.



The ovaries are rounded structures approximately 3 cm long. They are extremely variable in their location.



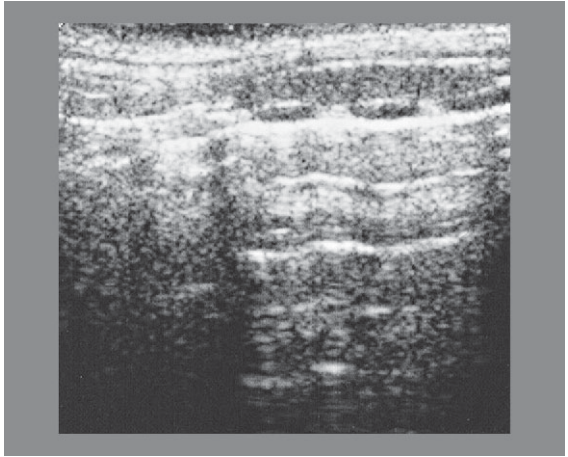
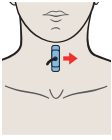
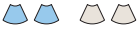12 Thyroid Gland

Thyroid Gland in Longitudinal Sections

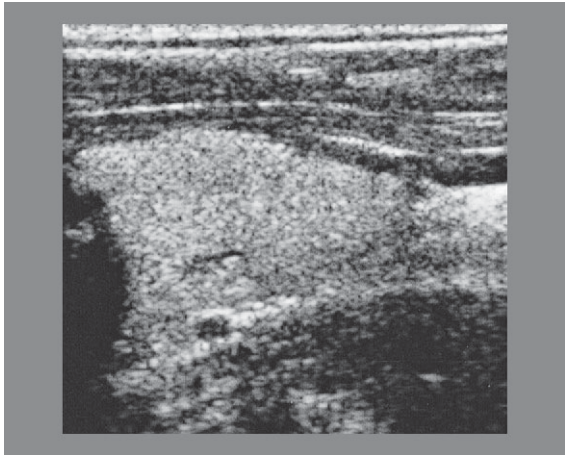
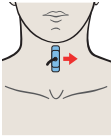
- 237** Isthmus of thyroid gland
- 238** Left lobe of thyroid gland, sternohyoid muscle, sternothyroid muscle
- 239** Left lobe of thyroid gland, sternohyoid muscle, sternothyroid muscle, internal jugular vein
- 240** Left lobe of thyroid gland, sternocleidomastoid muscle, common carotid artery, internal jugular vein

Thyroid Gland in Transverse Sections

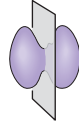
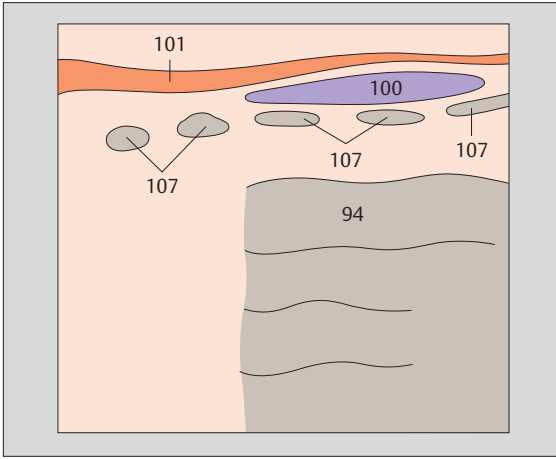
- 241** Right lobe of thyroid gland, sternocleidomastoid muscle, common carotid artery, internal jugular vein
- 242** Left lobe of thyroid gland, sternocleidomastoid muscle, omohyoid muscle, common carotid artery, internal jugular vein
- 243** Right lobe of thyroid gland, sternocleidomastoid muscle, omohyoid muscle, sternohyoid muscle, common carotid artery, internal jugular vein
- 244** Right lobe of thyroid gland, sternocleidomastoid muscle, omohyoid muscle, sternohyoid muscle, common carotid artery, internal jugular vein



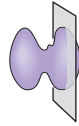
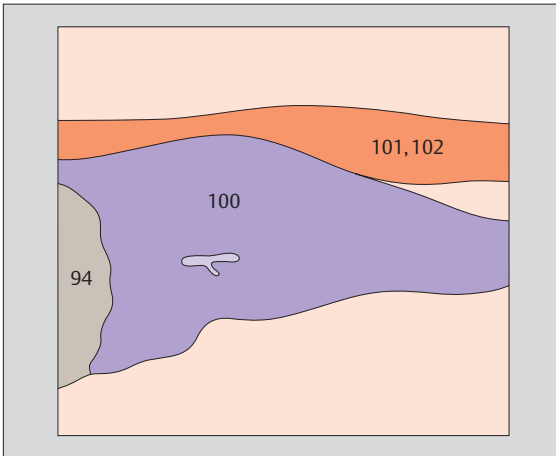
▶ 237 Isthmus of thyroid gland



▶ 238 Left lobe of thyroid gland, sternohyoid muscle, sternothyroid muscle

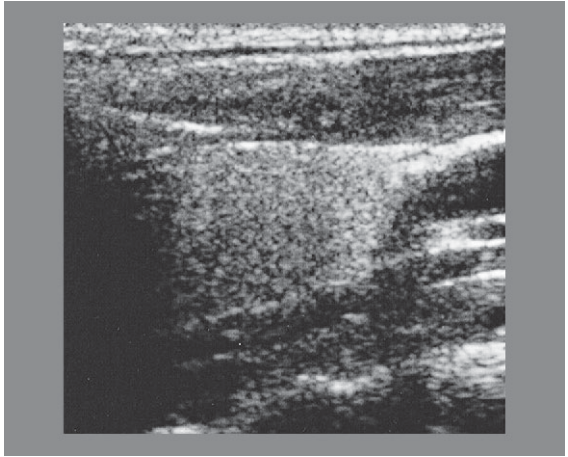
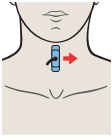


The trachea is located directly behind the thyroid isthmus.

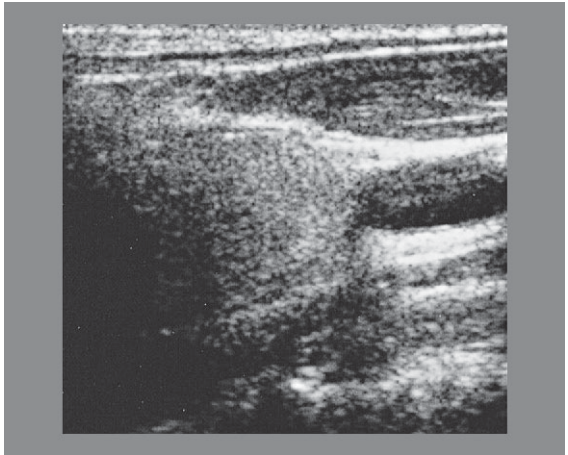
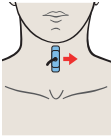


Blood vessels are seen only sporadically in the thyroid parenchyma.

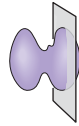
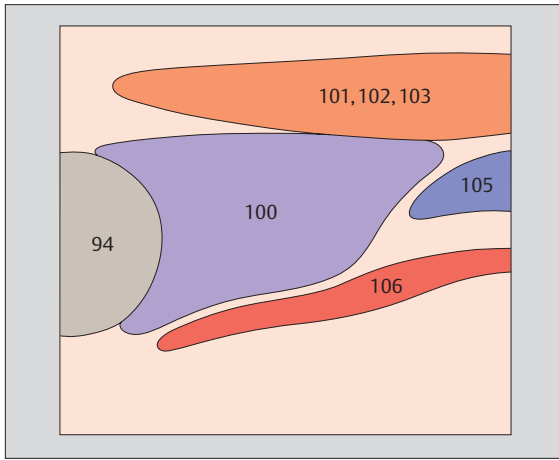




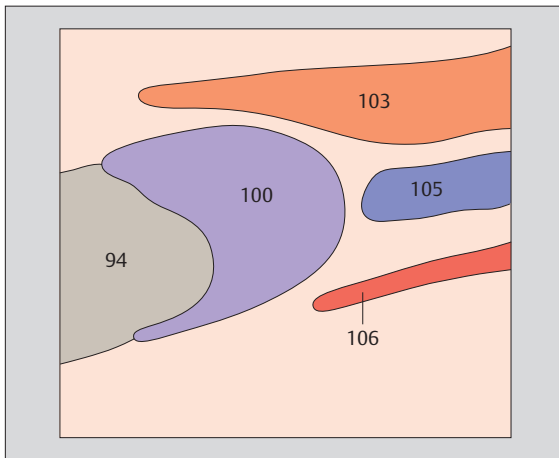
- ▶ **239** Left lobe of thyroid gland, sternohyoid muscle, sternothyroid muscle, sternocleidomastoid muscle, common carotid artery, internal jugular vein



- ▶ **240** Left lobe of thyroid gland, sternocleidomastoid muscle, common carotid artery, internal jugular vein

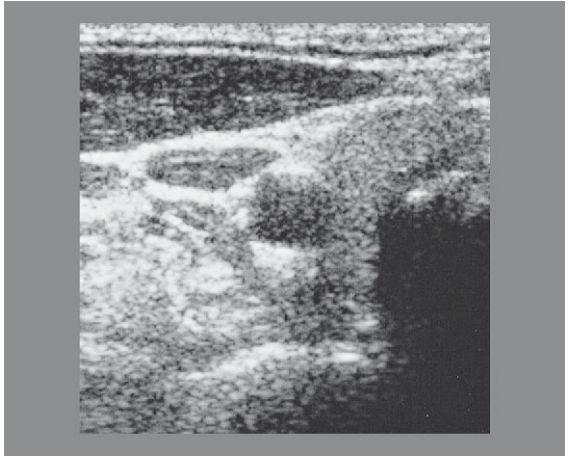
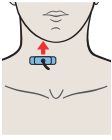


The sternohyoid and sternothyroid muscles are located anterior to the thyroid gland.

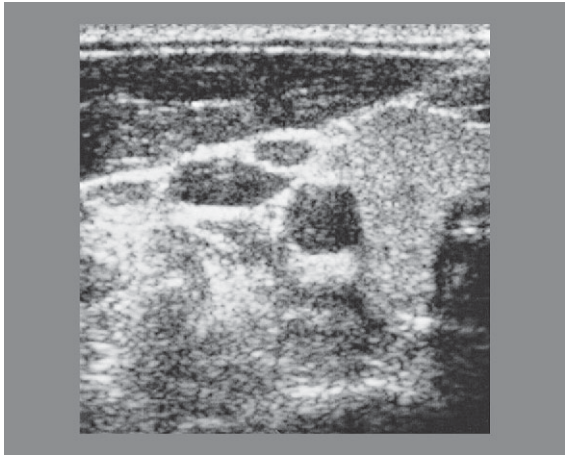
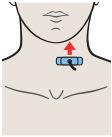


The sternocleidomastoid muscle is located anterior and lateral to the thyroid gland.

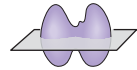
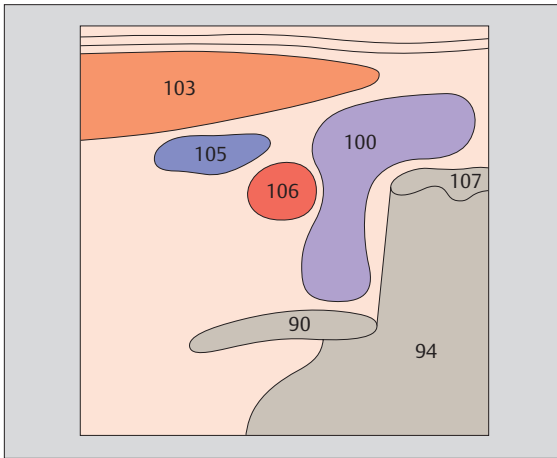




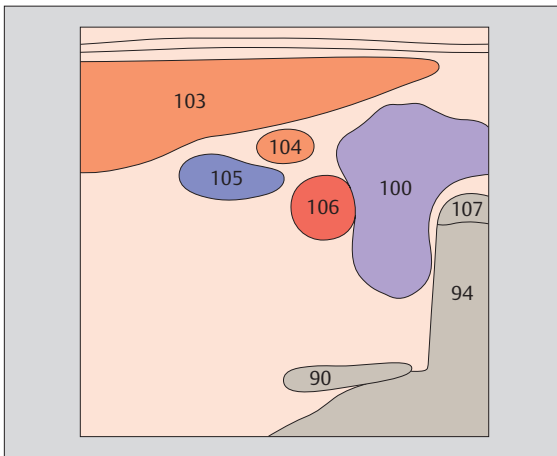
- ▶ **241** Right lobe of thyroid gland, sternocleidomastoid muscle, common carotid artery, internal jugular vein



- ▶ **242** Left lobe of thyroid gland, sternocleidomastoid muscle, omohyoid muscle, common carotid artery, internal jugular vein

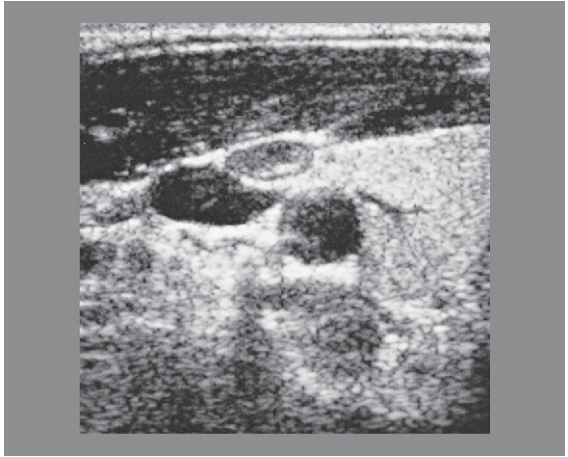
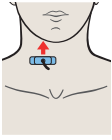


The large vessels of the neck run alongside the thyroid gland, in close proximity to it.

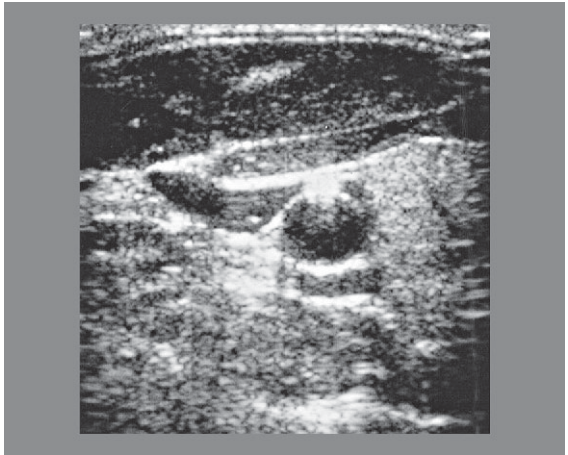
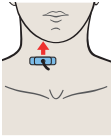


The thyroid is a butterfly-shaped gland with smooth outlines and high-level internal echoes.

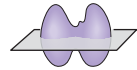
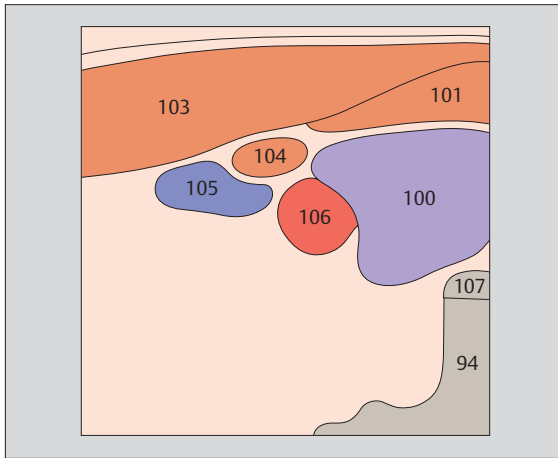




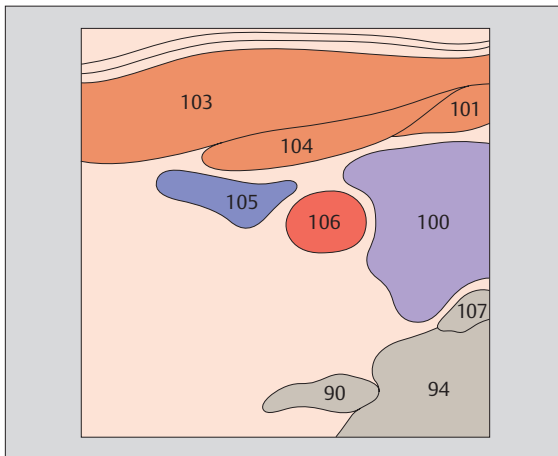
- ▶ **243** Right lobe of thyroid gland, sternocleidomastoid muscle, omohyoid muscle, sternohyoid muscle, common carotid artery, internal jugular vein



- ▶ **244** Right lobe of thyroid gland, sternocleidomastoid muscle, omohyoid muscle, sternohyoid muscle, common carotid artery, internal jugular vein



*The common carotid artery is posterolateral.
The internal jugular vein is lateral or anterolateral.*

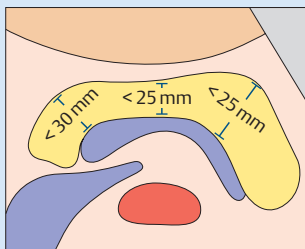
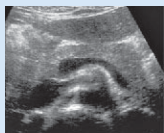

*The parathyroid glands are located behind the upper
and lower poles of the thyroid gland. Unless enlarged,
they cannot be visualized with ultrasound.*

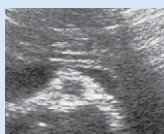

Normal Sonographic Dimensions of the Pancreas, Spleen, and Kidneys

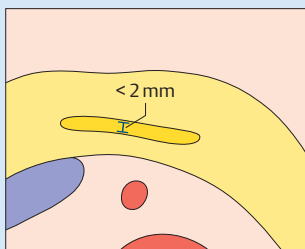
► Pancreas



Head < 30 mm
Body < 25 mm
Tail < 25 mm

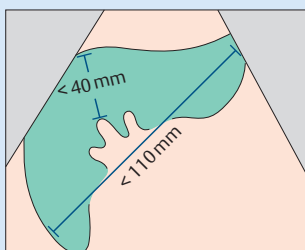
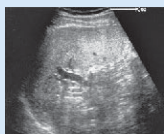

Pancreatic duct



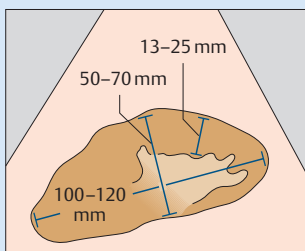
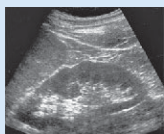Pancreatic duct
< 2 mm

► Spleen



In longitudinal flank scan:
Length < 110 mm
Thickness < 40 mm

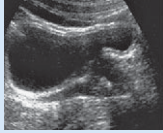► Kidneys



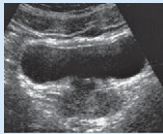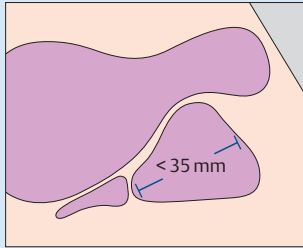
length 100–120 mm
width 50–70 mm
Width of parenchyma:
13–25 mm
Parenchymal-pelvic
ratio:
60 years or younger 1.6 : 1
Over 60 years 1.1 : 1

Normal Sonographic Dimensions of the Prostate and Thyroid Gland

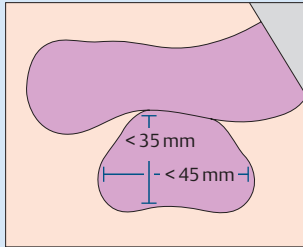
▶ Prostate



In longitudinal section

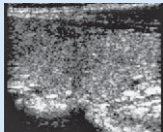


In transverse section

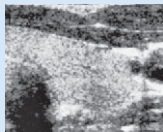
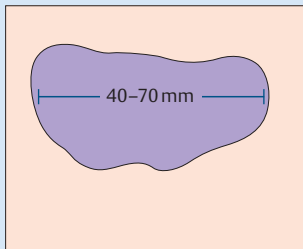


Width < 45 mm
Depth < 35 mm
Length < 35 mm
Volume < 25 mL

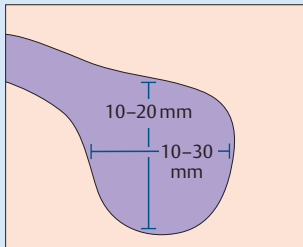
▶ Thyroid gland



In longitudinal section



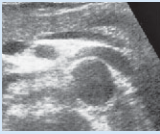In transverse section



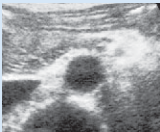
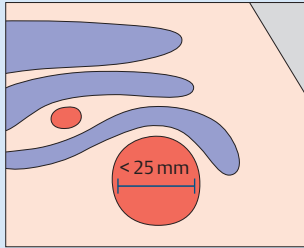
Length 40–70 mm
Width 10–30 mm
Depth 10–20 mm
Volume in men:
< 25 mL
Volume in women:
< 20 mL

Normal Sonographic Dimensions of Major Vessels

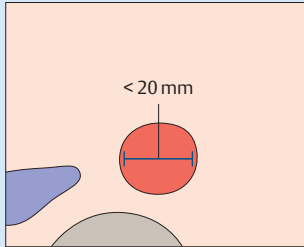
▶ Aorta



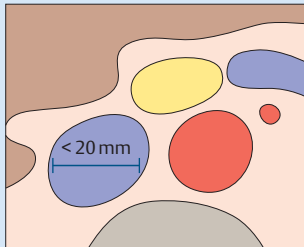
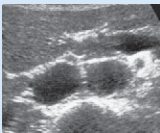
Cranial part



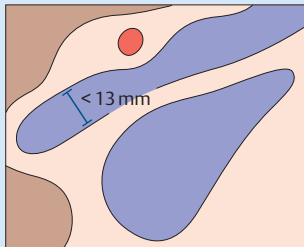
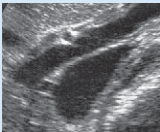
Caudal part



▶ Vena cava

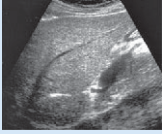

▶ Portal vein

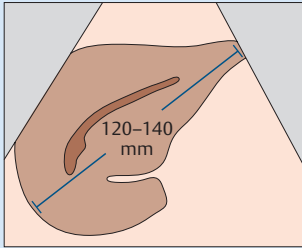


Normal Sonographic Dimensions of the Liver, Gallbladder, and Bile Duct

▶ Liver



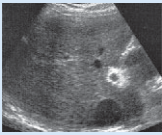
In longitudinal section



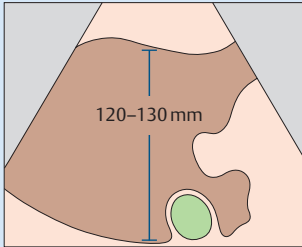
Craniocaudal
< 140 mm

Antero-
posterior
< 120 mm

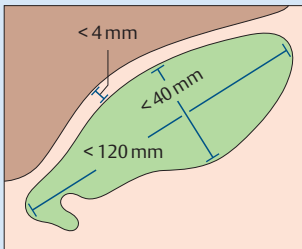
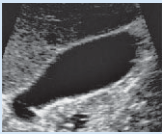Angle of
inferior border:
Left < 30°
Right < 45°



In transverse section



▶ Gallbladder

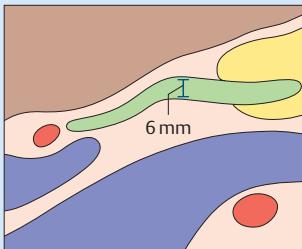
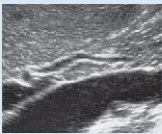


Length
< 120 mm

Width
< 40 mm

Wall thickness
< 4 mm

▶ Bile duct



Normal width
< 6 mm

After chole-
cystectomy
< 9 mm

1	Aorta	60	Right kidney
2	Iliac artery	61	Left kidney
3	Celiac trunk	62	Renal cortex
4	Hepatic artery	63	Renal columns
5	Splenic artery	64	Pyramids
6	Left gastric artery	65	Renal pelvis
7	Superior mesenteric artery	66	Ureter
8	Right renal artery	67	–
9	Left renal artery	68	–
10	Vena cava	69	Adrenal gland
11	Left hepatic vein	70	Stomach
12	Middle hepatic vein	71	Fundus of stomach
13	Right hepatic vein	72	Body of stomach
14	Right renal vein	73	Antrum of stomach
15	Left renal vein	74	Cardia
16	Iliac vein	75	Duodenal bulb
17	Portal vein	76	Duodenum
18	Splenic vein	77	Small bowel
19	Superior mesenteric vein	78	Right colic flexure
20	Right lobe of liver	79	Left colic flexure
21	Left lobe of liver	80	Bladder
22	Quadrante lobe	81	Opening of ureter
23	Caudate lobe	82	Urethra
24	Ligamentum teres	83	Prostate
25	Ligamentum venosum	84	Seminal vesicle
26	Lateral segment	85	Uterus
27	Medial segment	86	Vagina
28	Anterior segment	87	Right ovary
29	Posterior segment	88	Left ovary
30	Gallbladder	89	Rectum
31	Fundus of gallbladder	90	Spinal column
32	Body of gallbladder	91	Symphysis pubis
33	Neck of gallbladder	92	Acoustic shadow
34	Infundibulum	93	Gas
35	Spiral folds	94	Artifact
36	Bile duct	95	Psoas muscle
37	Cystic duct	96	Diaphragm
40	Pancreas	97	Pelvic bone
41	Head of pancreas	98	Heart
42	Body of pancreas	100	Thyroid gland
43	Tail of pancreas	101	Sternohyoid muscle
44	Uncinate process	102	Sternothyroid muscle
45	Pancreatic duct	103	Sternocleidomastoid muscle
50	Spleen	104	Omohyoid muscle
51	Accessory spleen	105	Internal jugular vein
		106	Common carotid artery
		107	Tracheal cartilage